

Root Resorption in Orthodontics: An Evidence-Based Approach

Leandro Silva Marques¹, Paulo Antônio Martins-Júnior¹,
Maria Leticia Ramos-Jorge¹ and Saul Martins Paiva²

¹*Federal University of Vales do Jequitinhonha e Mucuri*

²*Federal University of Minas Gerais
Brazil*

1. Introduction

Root resorption is a pathological process that causes a shortening of the dental root. Although this condition is generally asymptomatic and missed in diagnosis, it may result in tooth mobility and even tooth loss if not diagnosed and treated early (Ahangari et al., 2010). In orthodontics, induced inflammatory root resorption is a form of pathologic root resorption related to the removal of hyalinized areas of the periodontal ligament following the application of orthodontic forces and is considered an undesirable but unavoidable iatrogenic consequence of orthodontic treatment (Brezniak & Wasserstein, 2002a; Brezniak & Wasserstein, 2002b).

The root resorption may compromise the continued existence and functional capacity of the affected tooth, depending on their magnitude (Brezniak & Wasserstein, 1993a, Brezniak & Wasserstein, 1993b), since the root structure (volume and contour) is changed (Consolaro, 2002). However, as the process of root resorption during orthodontic treatment is usually smooth and ends when the force is removed (Brezniak & Wasserstein, 1993; Levander et al., 1994) some authors have pointed out that the aesthetic and functional improvements justify the risks (Brezniak & Wasserstein, 1993).

1.1 Aims of the chapter

The aims of this chapter are to give a detailed description of root resorption, how it begins, the mechanisms involved in this condition and how the risk factors described in the literature contribute toward the development of root resorption related to orthodontic treatment. The importance of a thorough patient history and early diagnosis are also discussed. The value of high-quality research, such as longitudinal cohort and prospective studies, randomized clinical trials, systematic reviews and meta-analysis, is stressed in light of the current emphasis on evidence-based dentistry. Care and recommendations, legal implications and a case description of a patient with root resorption following orthodontic treatment are also presented.

2. Etiology of root resorption

Determining the cause of root resorption requires a thorough history, rescuing the previous dental history, addiction, accidents, previous treatment, associated diseases and other details relevant to pathogenesis, but not always remembered by patients and identified by orthodontists. Several authors have pointed out that the multifactor etiology of root resorption is complex, but the condition appears to result from a combination of individual biologic variability, genetic predisposition and the effect of mechanical factors (Bartley et al., 2011; Weltman et al., 2010; Zahrowski & Jeske, 2011). However, no definitive conclusion has been drawn as to whether sex (Harris et al., 1997; Hendrix et al., 1994; Sameshina & Sinclair, 2001), age (Baumrind et al., 1996; Costopoulos & Nanda, 1996; Harris et al., 1997; Harris & Baker, 1990; Owmann-Moll et al., 1995), tooth extractions (Baumrind et al., 1996; Blake et al., 1995; Hendrix et al., 1994; McNab et al., 2000) and duration of active treatment (Baumrind et al., 1996; Beck & Harris, 1994; Harris et al., 1997; Kaley & Phillips, 1991; Kurol et al., 1996; Mirabella & Artun, 1995; Sameshina & Sinclair, 2001) are risk factors for root resorption. Conflicting data are reported on the relationship between root resorption and hypodontia or partial anodontia (Artun, 2000; Kjaer, 1995, 2000; Lee et al., 1999) and ectopic teeth (Kjaer, 2000; Lee et al., 1999).

2.1 How root resorption begins?

Orthodontic tooth movement is based on force-induced periodontal ligament and alveolar bone remodeling (Abuabara, 2007). So, orthodontic forces represent a physical agent capable of inducing inflammatory reaction in the periodontium (Giannopoulou et al., 2008). When a tooth moves, a necrosis of periodontal ligament on the pressure side with formation of a cell-free hyaline zone occurs. This event is followed by osteoclast resorption of the neighbouring alveolar bone and bone apposition by osteoblasts on the tension side (Abuabara, 2007). The resorption process of dental hard tissues seems to be triggered by the activity of some cytokines as well as that of bone. Immune cells migrate out of the capillaries in the periodontal ligament and interact with locally residing cells by elaborating a large array of signal molecules (Jäger et al., 2005). According Consolaro et al. (2011), the causes of root resorption should be related to the loss of root surface cementoblasts.

2.2 Orthodontic treatment-related factors

The ideal force for tooth movement would mimic a physiologic balance between tooth movement and bony adaptation (Paetyangkul et al., 2009). Schwarz (1932) advocated the optimal force level for tooth movement between 7 and 26 g per square centimeter. He also stated that, when force exceeded this threshold, root resorption occurs. When pressure decreases below this limit, root resorption ceases (Owman Moll et al., 1996). This was later confirmed by King and Fischlschweiger (1982), who found that light forces produced insignificant root resorption, whereas intermediate or heavy forces resulted in substantial crater formation.

In this context, several aspects have been related to induce root resorption during orthodontic treatment. This aspects are as follows: treatment duration (Casa et al., 2001; Fox, 2005; Levander & Malmgren, 1988; Otis et al., 2004; Paetyangkul et al., 2011; Sameshima & Sinclair, 2004; Segal et al., 2004), magnitude of the applied forces (Barbagallo et al., 2008; Bartley et al., 2011; Casa et al., 2001; Chan et al., 2005; Harris et al., 2006; Paetyangkul et al.,

2011), direction of tooth movement (Barbagallo et al., 2008; Han et al., 2005) amount of apical displacement (Fox, 2005; Segal et al., 2004), force application method (continuous vs. intermittent) (Brezniak & Wasserstein, 2002; Faltin et al., 2001), type of appliance (Brezniak & Wasserstein, 1993; Pandis et al., 2008) and treatment technique (Bartley et al., 2011; Beck & Harris, 1994; Janson et al., 1999; Marques et al., 2010; Pandis et al., 2008; Parker & Harris, 1998; Scott et al., 2008).

2.2.1 Treatment duration, force application method and magnitude of the applied forces

In a study, Acar et al. (1999) compared a 100-g force with elastics in either an interrupted (12 hours per day) or a continuous (24 hours per day) application. Group who has teeth experiencing orthodontic movement had significantly more root resorption than the control group. Besides that, continuous force produced significantly more root resorption than discontinuous force application.

Later, Ballard et al. (2009) conducted a prospective randomized clinical trial to compare root resorption with two force application patterns (continuous and intermittent) and they concluded that the application of intermittent orthodontic forces of 225 cN for 8 weeks (14 days of force application, 3 days of rest, then 4 days of force application repeated for 6 weeks) caused less root resorption than continuous forces of 225 cN for 8 weeks. The authors stated that, although it might not be clinically practical, compared with continuous forces, intermittent forces might be a safer method to prevent significant root resorption.

More recently, Paetyangkul et al. (2011) investigated the amounts of root resorption volumetrically after the application of controlled light and heavy forces in the buccal direction for 4, 8, and 12 weeks. They found significant differences in the extent of root resorption between 4, 8, and 12 weeks of force application ($P < 0.001$), with substantially more severe resorption in the longer force duration groups. The light force produced significantly less root resorption than did the heavy force. The authors argued that the duration of force application appears to be an important factor in orthodontic root resorption. Even though the application of light orthodontic forces did not show a significant difference between 4 and 8 weeks of buccal force application, the amount of root resorption increased significantly from 8 to 12 weeks of force application. So the duration of orthodontic force application caused more root resorption even when light forces of 25 g were used. This finding agrees with others studies published by Vardimon et al. (1991) and Gonzales et al. (2008). Paetyangkul et al. (2011) affirmed that this might be due to the increased osteoclastic activity around 8 weeks of force application.

In another study, Chan and Darendeliler (2006) found that the mean volume of the resorption craters was 11.59 times greater in the heavy-force group than in the control group. Barbagallo et al. (2008), in a prospective randomized clinical trial compared forces applied with removable thermoplastic appliances (TA) and fixed orthodontic appliances. The results showed that teeth experiencing orthodontic movement had significantly more root resorption than did the control teeth. They also found that heavy force produced significantly more root resorptions (9 times greater than the control) than light force (5 times greater than the control).

In this context, Harris et al. (2006) conducted a prospective randomized clinical trial to quantify the amount of root resorption when controlled light and heavy intrusive forces

were applied to human premolars and to establish the sites where root resorption is more prevalent. They found that the volume of the root resorption craters after intrusion was directly proportional to the magnitude of the intrusive force applied. The findings showed that the control group had fewer and smaller root resorption craters, the light force group had more and larger root resorption craters than the control group, and the heavy force group had the most and the largest root resorption craters of all groups. A trend of linear increase in the volume of the root resorption craters was observed from control to light to heavy groups, and these differences were statistically significant. The mean volumes of the resorption craters in the light and heavy force groups were 2 and 4 times greater than in the control groups, respectively. The mesial and distal surfaces had the greatest resorption volume, with no statistically significant difference between the 2 surfaces.

2.2.2 Direction of tooth movement

Evaluating the direction of tooth movement (intrusive vs. extrusive force), Han et al. (2005) found that root resorption from extrusive force was not significantly different from the control group. Intrusive force significantly increased the percentage of resorbed root area (4 fold). The correlation between intrusion or extrusion and root resorption in the same patient was $r = 0.774$ ($P = 0.024$).

2.2.3 Amount of apical displacement

In orthodontics, total apical displacement might represent a better marker for overall treatment activation. A tooth that is moved greater distances through bone is subjected to longer durations of activation. There is no way to move a tooth between two points with fixed appliances, without causing hyalinization. Perhaps, this is why maxillary incisors are most likely to exhibit severe levels of root resorption (Segal et al., 2004). Segal et al. (2004) conducted a meta-analysis to elucidate possible treatment-related etiological factors - such as, duration of treatment and apical displacement - for external root resorption and they found that mean apical root resorption was strongly correlated with total apical displacement ($r = 0.822$) and treatment duration ($r = 0.852$). In 2005, Fox also found that treatment-related root resorption is correlated with the distance the apex moves and the length of time the treatment took.

2.2.4 Archwire sequence

Mandall et al. (2006) compared 3 orthodontic archwire sequences in terms of: (1) patient discomfort, (2) root resorption, and (3) time to working archwire. In that study, all patients were treated with maxillary and mandibular preadjusted edgewise appliances (0.022-in slot), and all archwires were manufactured by the same manufacturer. The results showed that there was no statistically significant difference between archwire sequences, for maxillary left central incisor root resorption (F ratio, $P = 0.58$). There was also no statistically significant difference between the proportion of patients with and without root resorption between archwire sequence groups ($P = 0.8$).

2.2.5 Type of appliance

Reukers et al. (1998) compared the prevalence and severity of root resorption after treatment with a fully programmed edgewise appliance (FPA) and a partly programmed edgewise

appliance (PPA). All FPA patients were treated with 0.022-in slot Roth prescription ("A" Company, San Diego, Calif), and misplaced brackets were rebonded. All PPA patients were treated with 0.018-in slot Microloc brackets (GAC, Central Islip, NY), and the archwires were adjusted for misplaced brackets. They found no statistically significant differences in the amount of tooth root loss (FPA, 8.2%; PPA, 7.5%) or prevalence of root resorption (FPA, 75%; PPA, 55%) between the groups.

More recently, Scott et al. (2008) investigated the effect of either Damon3 self-ligating brackets or a conventional orthodontic bracket system on mandibular incisor root resorption. Patients were treated with Damon3 self-ligating or Synthesis (both, Ormco, Glendora, Calif) conventionally ligated brackets with identical archwires and sequencing in all patients. The results showed that mandibular incisor root resorption was not statistically different (Damon3, 2.26 mm, SD 2.63; Syn-thesis, 1.21 mm, SD 3.39) between systems.

2.2.6 Treatment technique

Brin et al. (2003) examined the effect of 2-phase vs 1-phase Class II treatment on the incidence and severity of root resorption. The results showed that children treated in 2 phases with a bionator followed by fixed appliances had the fewest incisors with moderate to severe root resorption, whereas children treated in 1 phase with fixed appliances had the most resorption. However, the difference was not statistically significant. As treatment time increased, the odds of root resorption also increased ($P = 0.04$). The odds of a tooth experiencing severe root resorption were greater with a large reduction in overjet during phase 2.

2.3 Patient-related risk factors

Possible patient-related risk factors include a previous history of root resorption (Brezniak & Wasserstein, 1993; Hartsfield et al., 2004; Marques et al., 2010), tooth/root morphology, length and roots with developmental abnormalities (Brin et al., 2003; Fox, 2005; ; Marques et al., 2010; Sameshima & Sinclair, 2001, 2004; Smale et al., 2005), genetic influences (Al-Qawasmi et al., 2003; Bollen, 2002; Hartsfield et al., 2004; Ngan et al., 2004; Sameshima & Sinclair, 2001), systemic factors (Adachi et al., 1994; Igarashi et al., 1996), including drugs (nabumetone) (Villa et al., 2005), hormone deficiency, hypothyroidism, hypopituitarism (Loberg & Engstrom, 1994; Poumpros et al., 1994), asthma (Brezniak & Wasserstein, 2002; McNab et al., 1999), proximity of root to cortical bone (Horiuchi et al., 1998; Kaley & Phillips, 1991; Otis et al., 2004), alveolar bone density (Midgett et al., 1981; Otis et al., 2004), previous trauma (Brezniak & Wasserstein, 2002; Brin et al., 2003; Hartsfield et al., 2004; Mandall et al., 2006), endodontic treatment (Brezniak & Wasserstein, 2002; Hamilton et al., 1999), severity and type of malocclusion (Brin et al., 2003; Sameshima & Sinclair, 2001; Segal et al., 2004), patient age (Bishara et al., 1999; Fox, 2005; Harris et al., 1993; Levander & Malmgren, 1998; Mavragani et al., 2002) and gender (Chan & Darendeliler, 2006; Fox, 2005; Harris et al., 1997; Sameshima & Sinclair, 2001).

2.3.1 Genetic influences

Although several studies proved that there is a relationship between orthodontic force and root resorption, individual susceptibility also appears to influence the occurrence of root

resorption. Since mechanical forces and other environmental factors do not adequately explain the variation seen among individual expressions of root resorption, interest has increased on genetic factors influencing the susceptibility to root resorptions (Hartsfield, 2009). The reaction to orthodontic force, including rate of tooth movement, can differ depending on the individual's genetic background (Abass & Hartsfield, 2007; Iwasaki et al., 2008).

In this context, pro-inflammatory cytokines like interleukin-1 (IL-1) and tumour necrosis factor (TNF) are known to induce synthesis of various proteins that, in turn, elicit acute or chronic inflammation. Al-Qawasmi et al. (2003) identified linkage disequilibrium between the IL-1B gene and root resorption in orthodontically treated individuals. The polymorphism variation was found to account for 15% of the variation in root resorption in that sample. Persons in their sample homozygous for the IL-1B allele 1 had a 5.6 fold (95 % CI 1.9-21.2) increased risk of root resorption greater than 2 mm as compared with those who are not homozygous for the IL-1 beta allele 1. Data indicate that allele 1 at the IL-1B gene, known to decrease the production of IL-1 cytokine in vivo (Pociot et al., 1992), significantly increases the risk of root resorption (Al-Qawasmi et al., 2003).

2.3.2 Systemic factors

A study conducted by Nishioka et al. (2006) determined whether there is an association between excessive root resorption and immune system factors. The prevalence of root resorption found was 10.3%. Allergy, abnormalities in root morphology and asthma showed be high risk factors for the development of excessive root resorption during orthodontic tooth movement. The modifying effect of several pharmacological agents on orthodontic root resorption also has been examined. Among them, L-thyroxine has been shown to have an inhibitory effect and clinical application has been attempted (Shirazi et al., 1999). Studies have been published describing anti-inflammatory properties of tetracyclines (and their chemically modified analogues) unrelated to their antimicrobial effect. A significant reduction in the number of mononucleated cells on the root surface was observed. Such cells have been related to root resorption (Mavragani et al., 2005).

Some authors have pointed that bone turnover has an important influence during orthodontic treatment. High bone turnover, found in patients with hyperthyroidism, can increase the amount of tooth movement compared with the normal or low bone turnover state and adult patients. Low bone turnover, found in patients with hypothyroidism, can result more root resorption, suggesting that in subjects where a decreased bone turnover rate is expected, the risk of root resorption could be increased (Verna et al., 2003). Bisphosphonates, potent inhibitors of bone resorption, causes a significant dose-dependent inhibition of root resorption in rats after force application. These results prompt that a thorough case history regarding possible pathophysiological conditions influencing bone metabolism should be performed on an individual patient basis. In subjects where increased bone turnover rates are expected, the reactivation of the appliance could be performed more frequently. However, in patients where decreased bone turnover rates are expected, the reactivation should be carried out less frequently and the risk of root resorption should be carefully evaluated (Verna et al., 2003).

Most studies agree that patients who have extractions during orthodontic treatment have greater chances of severe resorption than those treated without extractions (Beck & Harris,

1994; Harris & Baker, 1990; Hendrix et al., 1994; McNab et al., 2000). One possible explanation for this could be the increased movement and retraction of the apex to close extraction spaces.

Another risk factor for severe root resorption is triangular roots (Marques et al., 2010). The geometric form of dental roots influences the distribution of forces on the alveolar bone and the dental structure itself. Blunt roots and pipette-shaped apices (triangular) tend to concentrate the forces in a smaller area than roots with a normal shape (Marques et al., 2010). Most studies agree that pointed roots undergo resorption more frequently than those with normal shape (Hartsfield et al., 2004; Nigul & Jagomagi, 2006; Ng'ang'a & Ng'ang'a, 2003; Sameshima & Sinclair, 2001; Smale et al., 2005; Stenvik & Mjor, 1970).

2.4 How root resorption is repaired?

The transition of active root resorption into a process of repair is associated with the invasion of fibroblast-like cells from the circumference of the resorption crater into the active root resorption site even with a light force. The formation of new tooth-supporting structures is seen in the periphery of the resorption lacunae, whereas active resorption by multinucleated odontoclast-like cells took place in the central parts. When orthodontic force is discontinued, the reparative process is similar to early cementogenesis during tooth development (Brudvik & Rygh, 1995a, Brudvik & Rygh, 1995b). It has been suggested that the epithelial cell rests of Malassez might have a significant role in mediating repair cementogenesis (Brice et al., 1991; Hasegawa et al., 2003). The resorptive defects are repaired by the deposition of new cementum and the reestablishment of new periodontal ligament (Andreasen, 1973; Barber & Sims, 1981; Brice et al., 1991; Brudvik & Rygh, 1995b; Langford & Sims, 1982; Reitan, 1974).

3. Quality of research

Most of the studies cited in this chapter offer a low amount of scientific evidence and therefore do not yet allow the precise prediction of the interaction between orthodontic treatment, genetic/systemic factors and root resorption. Part of this insufficient evidence may be explained by the different methodological criteria employed, different sample sizes and the heterogeneity of the study populations. Thus, the findings have been conflicting, which compromises both the credibility and clinical application of the results. Also, the current state of knowledge does not allow orthodontists to identify which patients are vulnerable. In a recent systematic review, Weltman et al. (2010) stated that "only 11 trials were considered appropriate for inclusion in this review, and their protocols were too variable to proceed with a quantitative synthesis. This reflects the state of the published scientific research on this topic."

Furthermore, although severe root resorption can have drastic consequences to both treatment and patient health, there is only one study that specifically addresses the risk factors for this condition (Marques et al., 2010). The main factors directly involved in severe root resorption are extraction of first premolars, triangle-shaped roots and root resorption before treatment. In cases of extensive root resorption induced by orthodontic movement, there might be flaws in the predictability, prevention, and early diagnosis of this condition.

It is therefore important to determine the magnitude and prevalence of root resorption in various populations as well as related risk factors (Marques et al., 2010).

However, some challenging situations may appear to the orthodontist during orthodontic treatments. For example, in the study published by Marques et al. (2010), they found an excessive percentage of patients (6%) that experienced pauses in the mechanical treatment, there was a severe root resorption at the end of the treatment. This finding suggests the influence of genetic factors and further increases the responsibility of orthodontists with regard to this issue. If severe root resorption is identified, the treatment plan should be reassessed with the patient. Alternative options might include prosthetic solutions to close spaces, releasing teeth from active archwires if possible, stripping instead of extracting, and early fixation of resorbed teeth (Brezniak & Wasserstein, 2002).

4. Care and recommendations

Determining the cause of root resorption requires a thorough medical history, including the past history of the tooth involved as well as vices, accidents, types of sports practiced, previous treatment and associated diseases. Relevant details, such as mild trauma (concussion and subluxation) should be analyzed in detail (Consolaro et al., 2011).

As root resorption is often asymptomatic, radiographic images constitute the best way to detect the condition and measure its severity in order to establish an early diagnosis (Eraso et al., 2007), especially control radiographs obtained after six to 12 months of orthodontic treatment (Artun et al., 2009; Weltman et al., 2010). Digital radiography (DR) and digital subtraction radiography (DSR) can be used for the detection of apical root resorption as small as 0.5 mm and lingual resorption of 1 mm or more. In this context, DSR frequently performs better than DR (Ono et al., 2011).

When an orthodontist identifies root resorption in a patient, the severity of the condition is decreased with a pause in active orthodontic movement for two to three months with a use of a passive archwire (Weltman et al., 2010; Zahrowski & Jeske, 2011). However, if the resorption is severe, the orthodontist and patient should reassess the treatment plan (Weltman et al., 2010). Alternative options include prosthetic solutions to close spaces, releasing teeth from active archwires when possible, stripping instead of extracting and early fixation of resorbed teeth (Brezniak & Wasserstein, 2002). If root resorption is diagnosed on the final radiographs after treatment, follow-up radiographic examinations are recommended until the resorption has stabilized (Weltman et al., 2010). However, if it continues, sequential root canal therapy with calcium hydroxide may be considered (Pizzo et al., 2007).

There is little evidence that previous trauma (with no history of root resorption) and unusual tooth morphology play roles in increasing root resorption (Weltman et al., 2010). Caution should be used when retaining the teeth with fixed appliances, as occlusal trauma to the fixed teeth or segments may lead to extreme root resorption (Brezniak & Wasserstein, 2002). As the magnitude of force has been documented to be directly correlated with the severity of root resorption (Casa et al., 2001; Darendeliler et al., 2004; Faltin et al., 2001; Harris et al., 2006), the ideal force for dental movement would mimic a physiologic balance between tooth movement and bone adaptation (Paetyangkul et al.,

2011). It is therefore recommended to employ light forces, especially for intrusive movements (Weltman et al., 2010).

5. Case report

The case described below illustrates an atypical situation, since with only four months of treatment using alignment and leveling wires (0.14 and 0.16), a severe root resorption was detected. This situation led the orthodontist to stop the orthodontic treatment. Fortunately, the case had low complexity and did not involve extensive tooth movements. In such cases, the orthodontist should be aware of the systematic radiological examinations.

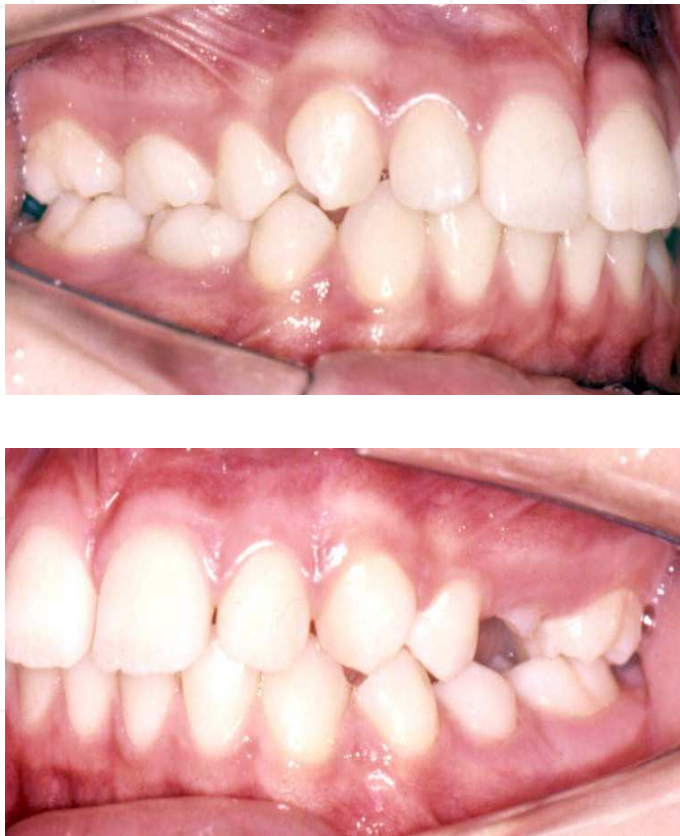

Fig. 1. Initial situation of the patient.

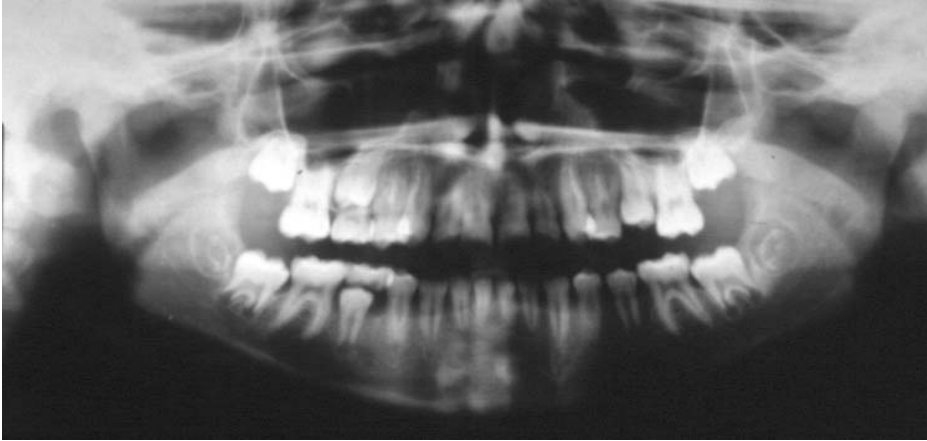


Fig. 2. Panoramic radiograph.

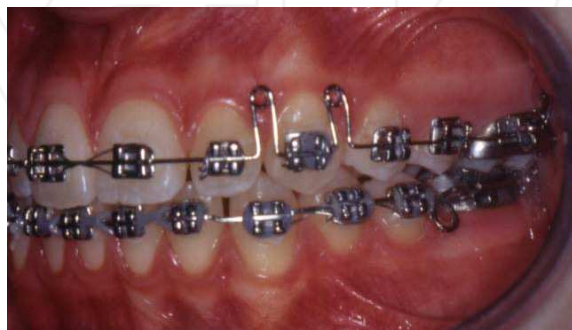
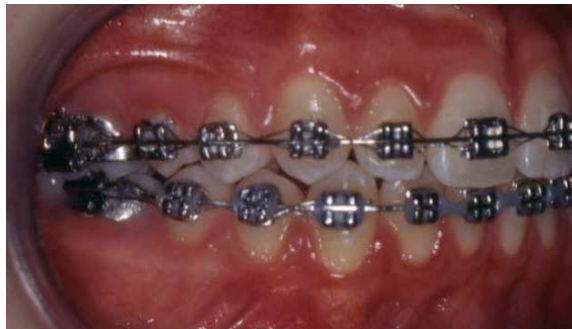
Fig. 3. (a, b). Alignment using wire 0.14.

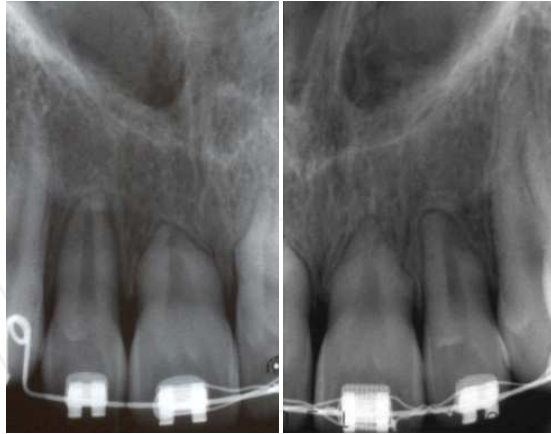


Fig. 4. (a, b). Periapical radiographs showing root resorption of superior incisors.

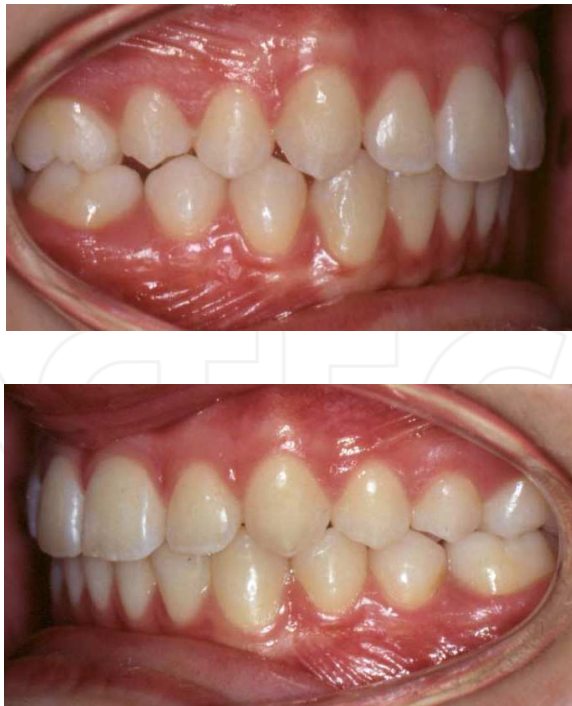

Fig. 5. (a, b). Final aspect of treatment.

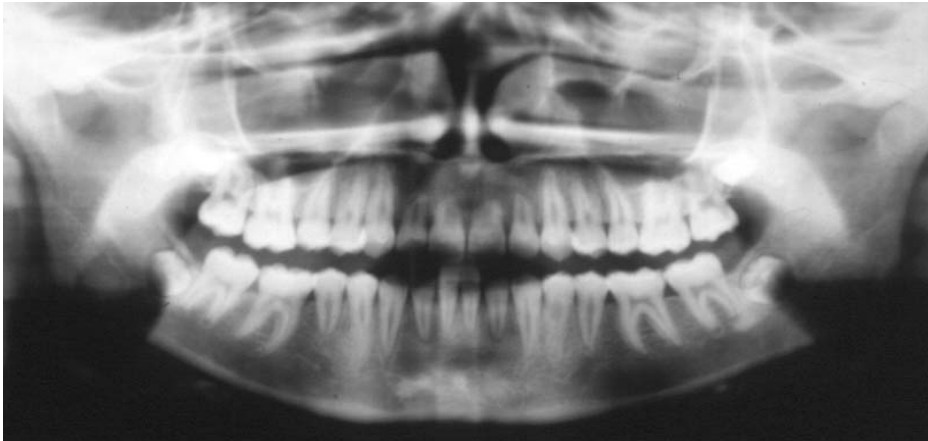


Fig. 6. Final panoramic radiograph.

6. Conclusions

While science provides no consistent evidence for the precise identification of the orthodontic patient that will develop root resorption, orthodontists should keep in mind the various indicators known and promote systematic radiographic to monitor their patients. Individualize the diagnosis and treatment plan could mean the difference between the success and failure of orthodontic treatment.

7. Acknowledgments

The authors thank the Coordenação de Aperfeiçoamento de Pessoal de Nível Superior (CAPES) for financial support to carry out this research.

8. References

- Abass, S.K.; Hartsfield, J.K. Jr. (2007) Orthodontics and external apical root resorption. *Semin Orthod*, 13, 246-56.
- Abuabara, A. (2007). Biomechanical aspects of external root resorption in orthodontic therapy. *Med Oral Patol Oral Cir Bucal*, 12, 8, E610-3.
- Acar, A.; Canyurek, U.; Kocaaga, M.; Erverdi, N. (1999). Continuous vs. dis-continuous force application and root resorption. *Angle Orthod*, 69, 159-63.
- Adachi, H.; Igarashi, K.; Mitani, H.; Shinoda, H.; (1994). Effects of topical administration of a bisphosphonate (risedronate) on orthodontic tooth movement in rats. *J Dent Res*, 73, 1478-86.
- Ahangari, Z.; Nasser, M.; Mahdia, M.; Fedorowicz, Z.; Marchesan, M.A. (201). Interventions for the management of external root resorption. *Cochrane Database Syst Rev*, Jun 16, 6, CD008003.
- Al-Qawasmi, R.A.; Hartsfield, J.K. Jr, Everett, E.T. et al. (2003). Genetic predisposition to external apical root resorption in orthodontic patients: linkage of chromo-some-18 marker. *J Dent Res*, 82, 356-60.

- Andreasen, J.O. (1973). Cementum repair after apicoectomy in humans. *Acta Odontol Scand*, 31, 211-21.
- Årtun, J.; Van 't Hullenaar, R.; Doppel, D.; Kuijpers-Jagtman, A.M. (2009) Identification of orthodontic patients at risk of severe apical root resorption. *Am J Orthod Dentofacial Orthop*, 135, 4, 448-55.
- Årtun, J. (2000). Revisiting root resorption. *Am J Orthod Dentofacial Orthop*, 118, 3, 14A.
- Ballard, D.J.; Jones, A.S.; Petocz, P.; Darendeliler, M.A. (2009). Physical properties of root cementum: part 11. Continuous vs intermittent controlled orthodontic forces on root resorption. A microcomputed tomography study. *Am J Orthod Dentofacial Orthop*, 136, 1, 8.e1-8, discussion 8-9.
- Barbagallo, L.J.; Jones, A.S.; Petocz, P.; Darendeliler, M.A. (2008). Physical properties of root cementum: part 10. Comparison of the effects of invisible removable thermoplastic appliances with light and heavy orthodontic forces on premolar cementum. A microcomputed-tomography study. *Am J Orthod Dentofacial Orthop*, 133, 218-27.
- Barber, A.F.; Sims, M.R. (1981). Rapid maxillary expansion and external root resorption in man: a scanning electron microscope study. *Am J Orthod*, 79, 630-52.
- Bartley, N.; Türk, T.; Colak, C.; Elekdağ-Türk, S.; Jones, A.; Petocz, P.; Darendeliler, M.A. (2011). Physical properties of root cementum: Part 17. Root resorption after the application of 2.5° and 15° of buccal root torque for 4 weeks: a microcomputed tomography study. *Am J Orthod Dentofacial Orthop*, 139, 4, e353-60.
- Baumrind, S.; Korn, E.L.; Boyd, R.L. (1996). Apical root resorption in orthodontically treated adults. *Am J Orthod Dentofacial Orthop*, 110, 311-20.
- Beck, B.W.; Harris, E.F. (1994). Apical root resorption in orthodontically treated subjects: analysis of edgewise and light wire mechanics. *Am J Orthod Dentofacial Orthop*, 105, 350-61.
- Blake, M.; Woodside, D.G.; Pharoah, M.J. (1995). A radiographic comparison of apical root resorption after orthodontic treatment with the edge-wise and Speed appliances. *Am J Orthod Dentofacial Orthop*, 108, 76-84.
- Bishara, S.E.; Vonwald, L.; Jakobsen, J.R. (1999). Changes in root length from early to mid-adulthood: resorption or apposition? *Am J Orthod Dentofacial Orthop*, 115, 563-8.
- Bollen, A.M. (2002). Large overjet and longer teeth are associated with more root resorption when treated orthodontically. *J Evid Based Dent Pract*, 2, 44-5.
- Brezniak, N.; Wasserstein, A. (1993). Root resorption after orthodontic treatment: Part 1. Literature review. *Am J Orthod Dentofacial Orthop*, 103, 1, 62-6.
- Brezniak, N.; Wasserstein, A. (1993). Root resorption after orthodontic treatment: Part 2. Literature review. *Am J Orthod Dentofacial Orthop*, 103, 2, 138-46.
- Brezniak, N.; Wasserstein, A. (2002). Orthodontically induced inflammatory root resorption. Part I: The basic science aspects. *Angle Orthod*, 72, 2, 175-9.
- Brezniak, N.; Wasserstein, A. (2002). Orthodontically induced inflammatory root resorption. Part II: the clinical aspects. *Angle Orthod*, 72, 180-4.
- Brice, G.L.; Sampson, W.J.; Sims, M.R. (1991). An ultrastructural evaluation of the relationship between epithelial rests of Malassez and orthodontic root resorption and repair in man. *Aust Orthod J*, 12, 90-4.
- Brin, I.; Tulloch, J.F.; Koroluk, L.; Philips, C. (2003). External apical root resorption in Class II malocclusion: a retrospective review of 1- versus 2-phase treatment. *Am J Orthod Dentofacial Orthop*, 124, 2, 151-6.

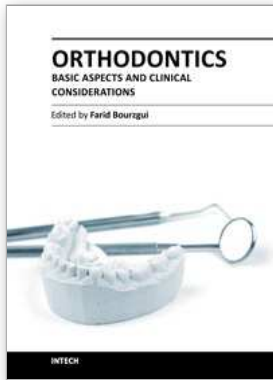
- Brudvik, P.; Rygh, P. (1995). The repair of orthodontic root resorption: an ultrastructural study. *Eur J Orthod*, 17, 189-98.
- Brudvik, P.; Rygh, P. (1995). Transition and determinants of orthodontic root resorption-repair sequence. *Eur J Orthod*, 17, 177-88.
- Casa, M.A.; Faltin, R.M.; Faltin, K.; Sander, F.G.; Arana Chavez, V.E. (2001). Root resorptions in upper first premolars after application of continuous torque moment. Intra-individual study. *J Orofac Orthop*, 62, 285-95.
- Chan, E.; Darendeliler, M.A. (2005). Physical properties of root cementum: part 5. Volumetric analysis of root resorption craters after application of light and heavy orthodontic forces. *Am J Orthod Dentofacial Orthop*, 127, 186-95.
- Chan, E.; Darendeliler, M.A. (2006). Physical properties of root cementum: part 7. Extent of root resorption under areas of compression and tension. *Am J Orthod Dentofacial Orthop*, 129, 4, 504-10.
- Consolaro, A. (2002). Reabsorções dentária na movimentação ortodôntica. In: *Reabsorções dentárias nas especialidades clínicas*. Dental Press Editora pp. 259-289, Maringá.
- Consolaro, A.; Franscischone, T.R.G.; Furquim, L.Z. (2011). As reabsorções As múltiplas ou severas não estão relacionadas a fatores sistêmicos, suscetibilidade individual, tendência familiar e predisposição individual. *Dent Press J Orthod*, 16,1, 17-21.
- Costopoulos, G.; Nanda, R. (1996). An evaluation of root resorption incident to orthodontic intrusion. *Am J Orthod Dentofacial Orthop*, 109,543-8.
- Darendeliler, M.A.; Kharbanda, OP.; Chan, E.K.M et al. (2004). Root resorption and its association with alterations in physical properties, mineral contents and resorption craters in human premolars following application of light and heavy controlled orthodontics forces. *Orthod Craniofac Res*, 7, 79-97.
- Eraso, F.E.; Parks, E.T.; Roberts, W.E.; Hohlt, W.F.; Ofner, S. (2007). Density value means in the evaluation of external apical root resorption: an in vitro study for early detection in orthodontic case simulations. *Dentomaxillofac Radiol*, 36, 3, 130-7.
- Faltin, R.M.; Faltin, K.; Sander, F.G.; Arana Chavez, V.E. (2001). Ultrastructure of cementum and periodontal ligament after continuous intrusion in humans: a transmission electron microscopy study. *Eur J Orthod*, 23, 35-49.
- Fox, N. (2005). Longer orthodontic treatment may result in greater external apical root resorption. *Evid Based Dent*, 6, 1, 21.
- Giannopoulou, C.; Dudic, A.; Montet, X.; Kiliaridis, S.; Mombelli, A. (2008). Periodontal parameters and cervical root resorption during orthodontic tooth movement. *J Clin Periodontol*, 35, 6, 501-6.
- Gonzales, C.; Hotokezaka, H.; Yoshimatsu, M.; Yozgatian, J.H.; Darendeliler, M.A.; Yoshida, N. (2008). Force magnitude and duration effects on amount of tooth movement and root resorption in the rat molar. *Angle Orthod*, 78, 502-9.
- Han, G.; Huang, S.; Von den Hoff, J.W.; Zeng, X.; Kuijpers-Jagtman, A.M. (2005). Root resorption after orthodontic intrusion and extrusion: an intraindividual study. *Angle Orthod*, 75, 912-8.
- Hamilton, R.S.; Gutmann, J.L. (1999). Endodontic-orthodontic relationships: a review of integrated treatment planning challenges. *Int Endod J*, 32, 343-60.
- Harris, D.A.; Jones, A.S., Darendeliler, M.A. (2006). Physical properties of root cementum: part 8. Volumetric analysis of root resorption craters after application of controlled

- intrusive light and heavy orthodontic forces: a microcomputed tomography scan study. *Am J Orthod Dentofacial Orthop*, 130, 639-47.
- Harris, E.F.; Baker, W.C. (1990). Loss of root length and crestal bone height before and during treatment in adolescent and adult orthodontic patients. *Am J Orthod Dentofacial Orthop*, 98, 463-9.
- Harris, E.F.; Kineret, S.E.; Tolley, E.A. (1997). A heritable component for external apical root resorption in patients treated orthodontically. *Am J Orthod Dentofacial Orthop*, 111, 301-9.
- Hartsfield, J.K. Jr.; Everett, E.T.; Al-Qawasmi, R.A. (2004). Genetic factors in external apical root resorption and orthodontic treatment. *Crit Rev Oral Biol Med*, 15: 115-22.
- Hartsfield, J.K. Jr. (2009). Pathways in external apical root resorption associated with orthodontia. *Orthod Craniofac Res*, 12, 3, 236-42.
- Hasegawa, N.; Kawaguchi, H.; Ogawa, T.; Uchida, T.; Kurihara, H. (2003). Immunohistochemical characteristics of epithelial cell rests of Malassez during cementum repair. *J Periodontal Res*, 38, 51-6.
- Hendrix, I.; Carels, C.; Kuijpers-Jagtman, A.M.; Van 'T Hof, M. (1994). A radiographic study of posterior apical root resorption in orthodontic patients. *Am J Orthod Dentofacial Orthop*, 105, 345-9.
- Horiuchi, A.; Hotokezaka, H.; Kobayashi, K. (1998). Correlation between cortical plate proximity and apical root resorption. *Am J Orthod Dentofacial Orthop*, 114, 311-8.
- Igarashi, K.; Adachi, H.; Mitani, H.; Shinoda, H. (1996). Inhibitory effect of topical administration of a bisphosphonate (risedronate) on root resorption incident to orthodontic tooth movement in rats. *J Dent Res*, 75, 1644-9.
- Iwasaki, L.R.; Crouch, L.D.; Nickel, J.C. (2008). Genetic factors and tooth movement. *Semin Orthod*, 14, 135-45.
- Janson, G.R.; De Luca Canto, G.; Martins, D.R.; Henriques, J.F.; De Freitas, M.R. (1999). A radiographic comparison of apical root resorption after orthodontic treatment with 3 different fixed appliance techniques. *Am J Orthod Dentofacial Orthop*, 118, 262-73.
- Jäger, A.; Zhang, D.; Kawarizadeh, A.; Tolba, R.; Braumann, B.; Lossdörfer, S.; Götz, W. (2005). Soluble cytokine receptor treatment in experimental orthodontic tooth movement in the rat. *Eur J Orthod*, 27, 1, 1-11.
- Kaley, J.; Phillips, C. (1991). Factors related to root resorption in edgewise practice. *Angle Orthod*, 61, 125-32.
- King, G.J.; Fischlschweiger, W. (1982). The effect of force magnitude on extractable bone resorptive activity and cemental cratering in orthodontic tooth movement. *J Dent Res*, 61, 775-9.
- Kjaer, I. (1995). Morphological characteristics of dentitions developing excessive root resorption during orthodontic treatment. *Eur J Orthod*, 17, 25-34.
- Kjaer, I. (2000). Revisiting root resorption. *Am J Orthod Dentofacial Orthop*, 117, 4, 23A.
- Kurol, J.; Owman-Moll, P.; Lundgren, D. (1996). Time-related root resorption after application of a controlled continuous orthodontic force. *Am J Orthod Dentofacial Orthop*, 110, 303-10.
- Langford, S.R.; Sims, M.R. (1982). Root surface resorption, repair, and periodontal attachment following rapid maxillary expansion in man. *Am J Orthod*, 81, 108-15.
- Lee, R.Y.; Årtun, J.; Alonzo, T.A. (1999). Are dental anomalies risk factors for apical root resorption in orthodontic patients? *Am J Orthod Dentofacial Orthop*, 116, 187-95.

- Levander, E.; Malmgren, O.; Eliasson, S. (1994). Evaluation of root resorption in relation to two orthodontic treatment regimes. A clinical experimental study. *Eur J Orthod*, 16, 3, 223-8.
- Levander, E.; Malmgren, O.; Stenback, K. (1998). Apical root resorption during orthodontic treatment of patients with multiple aplasia: a study of maxillary incisors. *Eur J Orthod*, 20, 427-34.
- Loberg, E.L.; Engstrom, C. (1994). Thyroid administration to reduce root resorption. *Angle Orthod*, 64, 395-9.
- Mandall, N.; Lowe, C.; Worthington, H. et al. (2006). Which orthodontic archwire sequence? A randomized clinical trial. *Eur J Orthod*, 28, 6, 61-6.
- Marques, L.S.; Chaves, K.C.; Rey, A.C.; Pereira, L.J.; Ruellas, A.C. (2011). Severe root resorption and orthodontic treatment: clinical implications after 25 years of follow-up. *Am J Orthod Dentofacial Orthop*, 139, 4, S166-9.
- Mavragani, M.; Boe, O.E.; Wisth, P.J.; Selvig, K.A. (2002). Changes in root length during orthodontic treatment: advantages for immature teeth. *Eur J Orthod*, 24, 91-7.
- Mavragani, M.; Brudvik, P.; Selvig, K.A. (2005). Orthodontically induced root and alveolar bone resorption: inhibitory effect of systemic doxycycline administration in rats. *Eur J Orthod*, 27, 3, 215-25.
- McNab, S.; Battistutta, D.; Taverne, A.; Symons, A.L. (1999). External apical root resorption of posterior teeth in asthmatics after orthodontic treatment. *Am J Orthod Dentofacial Orthop*, 116, 545-51.
- McNab, S.; Battistutta, D.; Taverne, A.; Symons, A.L. (2000). External apical root resorption following orthodontic treatment. *Angle Orthod*, 70, 227-32.
- Midgett, R.J.; Shaye, R.; Fruge, J.F. Jr. (1981). The effect of altered bone metabolism on orthodontic tooth movement. *Am J Orthod*, 80, 256-62.
- Mirabella, A.D.; Årtun, J. (1995). Risk factors for apical root resorption of maxillary anterior teeth in adult orthodontic patients. *Am J Orthod Dentofacial Orthop*, 108, 48-55.
- Ng'ang'a, P.M.; Ng'ang'a, R.N. (2003). Maxillary incisor root forms in orthodontic patients in Nairobi, Kenya. *East Afr Med J*, 80, 101-4.
- Ngan, D.C.S.; Kharbanda, O.P.; Byloff, F.K.; Darendeliler, M.A. (2004). The genetic contribution to orthodontic root resorption: a retrospective twin study. *Aust Orthod J*, 20, 1-9.
- Nigul, K.; Jagomagi, T. (2006). Factors related to apical root resorption of maxillary incisors in orthodontic patients. *Stomatologija*, 8, 76-9.
- Nishioka, M.; Ioi, H.; Nakata, S.; Nakasima, A.; Counts, A. (2006). Root resorption and immune system factors in the Japanese. *Angle Orthod*, 76, 1, 103-8.
- Ono, E.; Medici Filho, E.; Faig Leite, H.; Tanaka, J.L.; De Moraes, M.E.; De Melo Castilho, J.C. (2011). Evaluation of simulated external root resorptions with digital radiography and digital subtraction radiography. *Am J Orthod Dentofacial Orthop*, 139, 3, 324-33.
- Otis, L.; Hong, J.; Tuncay, O. (2004). Bone structure effect on root resorption. *Orthod Craniofac Res*, 21, 165-77.
- Owman-Moll, P.; Kurol, J.; Lundgren, D. (1995). Continuous versus interrupted continuous orthodontic force related to early tooth movement and root resorption. *Angle Orthod*, 65, 395-401.

- Owman-Moll, P.; Kurol, J.; Lundgren, D. (1996). The effects of a four-fold increased orthodontic force magnitude on tooth movement and root resorptions. An intra-individual study in adolescents. *Eur J Orthod*, 1996, 18, 287-94.
- Paetyangkul, A.; Türk, T.; Elekdağ-Türk, S.; Jones, A.S.; Petocz, P.; Darendeliler, M.A. (2009). Physical properties of root cementum: part 14. The amount of root resorption after force application for 12 weeks on maxillary and mandibular premolars: a microcomputed-tomography study. *Am J Orthod Dentofacial Orthop*, 136, 4, 492.e1-9.
- Pandis, N.; Nasika, M.; Polychronopoulou, A.; Eliades, T. (2008). External apical root resorption in patients treated with conventional and self-ligating brackets. *Am J Orthod Dentofacial Orthop*, 134, 646-51.
- Parker, R.J.; Harris, E.F. (1998). Directions of orthodontic tooth movements associated with external apical root resorption of the maxillary central incisor. *Am J Orthod Dentofacial Orthop*, 114, 672-83.
- Pizzo, G.; Licata, M.E.; Guiglia, R.; Giuliana, G. (2007). Root resorption and orthodontic treatment. Review of the literature. *Minerva Stomatol*, 56, 1-2, 31-44.
- Pociot, F.; Mølviq, J.; Wogensen, L.; Worsaae, H.; Nerup, J. (1992). A TaqI polymorphism in the human interleukin-1 beta (IL-1 beta) gene correlates with IL-1 beta secretion in vitro. *Eur J Clin Invest*, 22, 6, 396-402.
- Poumpros, E.; Loberg, E.; Engstrom, C. (1994). Thyroid function and root resorption. *Angle Orthod*, 64, 389-93.
- Reitan, K. (1974). Initial tissue behavior during apical root resorption. *Angle Orthod*, 44, 68-82.
- Reukers, E.A.; Sanderink, G.C.; Kuijpers-Jagtman, A.M.; van't Hof, M.A. (1998). Radiographic evaluation of apical root resorption with 2 different types of edgewise appliances. Results of a randomized clinical trial. *J Orofac Orthop*, 59, 2, 100-9. Erratum in: *J Orofac Orthop*, 59, 4, 251.
- Sameshima, G.T.; Sinclair, P.M. (2001). Predicting and preventing root resorption: part I. Diagnostic factors. *Am J Orthod Dentofacial Orthop*, 119, 505-10.
- Sameshima, G.T.; Sinclair, P.M. (2004). Characteristics of patients with severe root resorption. *Orthod Craniofac Res*, 7, 2, 108-14.
- Scott, P.; DiBiase, A.T.; Sherriff, M.; Cobourne, M.T. (2008). Alignment efficiency of Damon3 self-ligating and conventional orthodontic bracket systems: a randomized clinical trial. *Am J Orthod Dentofacial Orthop*, 134, 470.e1-8.
- Schwarz, A.M. (1932). Tissue changes incidental to orthodontic tooth movement. *Int J Orthod*, 18, 331-52.
- Segal, G.; Schiffman, P.; Tuncay, O. (2004). Meta analysis of the treatment-related factors of external apical root resorption. *Orthod Craniofac Res*, 7, 71-8.
- Shirazi, M.; Dehpour, A.R.; Jafari, F. (1999). The effect of thyroid hormone on orthodontic tooth movement in rats. *J Clin Pediatr Dent*, 23, 3, 259-64.
- Smale, I.; Artun, J.; Behbehani, F.; Doppel, D.; van't Hof, M.; Kuijpers-Jagtman, A.M. (2005). Apical root resorption 6 months after initiation of fixed orthodontic appliance therapy. *Am J Orthod Dentofacial Orthop*, 128, 1, 57-67.
- Stenvik, A.; Mjor, I.A. (1970). Pulp and dentine reactions to experimental tooth intrusion. A histologic study of the initial changes. *Am J Orthod*, 57, 370-85.
- Vardimon, A.D.; Graber, T.M.; Voss, L.R.; Lenke, J. (1991). Determinants control-ling iatrogenic external root resorption and repair during and after palatal expansion. *Angle Orthod*, 61, 113-22.

- Verna, C.; Dalstra, M.; Melsen, B. (2003). Bone turnover rate in rats does not influence root resorption induced by orthodontic treatment. *Eur J Orthod*, 25, 4, 359-63.
- Villa, P.A.; Oberti, G.; Moncada, C.A. et al. (2005). Pulp-dentine complex changes and root resorption during intrusive orthodontic tooth movement in patients prescribed nabumetone. *J Endod*, 31, 61-6.
- Weltman, B.; Vig, K.W.; Fields, H.W.; Shanker, S.; Kaizar, E.E. (2010). Root resorption associated with orthodontic tooth movement: a systematic review. *Am J Orthod Dentofacial Orthop*, 137, 4, 462-76, discussion 12A.
- Zahrowski, J.; Jeske, A. (2011). Apical root resorption is associated with comprehensive orthodontic treatment but not clearly dependent on prior tooth characteristics or orthodontic techniques. *J Am Dent Assoc*, 142, 1, 66-8.



Orthodontics - Basic Aspects and Clinical Considerations

Edited by Prof. Farid Bourzgui

ISBN 978-953-51-0143-7

Hard cover, 446 pages

Publisher InTech

Published online 09, March, 2012

Published in print edition March, 2012

The book reflects the ideas of nineteen academic and research experts from different countries. The different sections of this book deal with epidemiological and preventive concepts, a demystification of cranio-mandibular dysfunction, clinical considerations and risk assessment of orthodontic treatment. It provides an overview of the state-of-the-art, outlines the experts' knowledge and their efforts to provide readers with quality content explaining new directions and emerging trends in Orthodontics. The book should be of great value to both orthodontic practitioners and to students in orthodontics, who will find learning resources in connection with their fields of study. This will help them acquire valid knowledge and excellent clinical skills.

How to reference

In order to correctly reference this scholarly work, feel free to copy and paste the following:

Leandro Silva Marques, Paulo Antônio Martins-Júnior, Maria Letícia Ramos-Jorge and Saul Martins Paiva (2012). Root Resorption in Orthodontics: An Evidence-Based Approach, Orthodontics - Basic Aspects and Clinical Considerations, Prof. Farid Bourzgui (Ed.), ISBN: 978-953-51-0143-7, InTech, Available from: <http://www.intechopen.com/books/orthodontics-basic-aspects-and-clinical-considerations/root-resorption-in-orthodontics-an-evidence-based-approach>

INTECH
open science | open minds

InTech Europe

University Campus STeP Ri
Slavka Krautzeka 83/A
51000 Rijeka, Croatia
Phone: +385 (51) 770 447
Fax: +385 (51) 686 166
www.intechopen.com

InTech China

Unit 405, Office Block, Hotel Equatorial Shanghai
No.65, Yan An Road (West), Shanghai, 200040, China
中国上海市延安西路65号上海国际贵都大饭店办公楼405单元
Phone: +86-21-62489820
Fax: +86-21-62489821