

# Guidelines for “Surgery First” Orthodontic Treatment

Jeong Hwan Kim<sup>1</sup>, Niloufar Nouri Mahdavia<sup>2</sup> and Carla A. Evans<sup>2</sup>

<sup>1</sup>Private Practice, Seoul

<sup>2</sup>University of Illinois at Chicago, Chicago

<sup>1</sup>Korea

<sup>2</sup>USA

## 1. Introduction

Pre-surgical orthodontic preparation was uncommon for patients requiring orthognathic surgery until the 1960's. However, as surgical techniques advanced and the number of patients choosing an orthognathic approach increased, the patients' and clinicians' desire for optimal esthetic and occlusal results led to the most common current treatment approach. This approach involves pre-surgical orthodontic decompensation of the occlusal relationships and attainment of normal dental alignment. As most orthognathic treatment is planned now, there are two phases of orthodontic tooth movement, namely before and after orthognathic surgery. The disadvantages of having orthodontic interventions both before and after orthognathic surgery include a long treatment time and temporary worsening of facial appearance. Many patients become discouraged.

In recent years, a trend toward implementing treatment plans that achieve immediate facial change has arisen. In “Surgery First” treatment plans, the presurgical orthodontic treatment phase is eliminated or greatly reduced, the jaws are surgically repositioned into the desired locations, and orthodontic tooth movement follows. Patients appreciate the immediate improvement in facial appearance while the orthodontist can utilize the increased bone turnover to achieve accelerated tooth movement.

Caution is important when embarking on a “Surgery First” course of treatment. Even for the highly experienced orthodontist and surgeon, it is difficult to identify the occlusal relationship that will accompany an ideal facial and functional result. The planning process is time-consuming and requires choosing the desired appearance and skeletal relationships, mounting the casts in the position determined by the skeletal change, and then planning the post-operative orthodontic tooth movements. The surgical movement must be sufficient to allow dental decompensation after the surgical procedure. Surgical splints are fabricated on the articulated study models. Generally, the teeth are bonded/banded and a passive archwire is placed pre-surgically. Active orthodontic tooth movement begins within a relatively short period of time after the jaw(s) are repositioned to capitalize on the potential for accelerated tooth movement.

This chapter illustrates step-by-step concepts for “Surgery First” treatment with case records of increasing complexity. Surgical fixation and skeletal anchorage are discussed as well.

### 1.1 Background

Ever since the first orthognathic surgery procedure was performed by Hüllihen in 1848, many new techniques and methods have been introduced. The introduction of orthognathic surgery widened the possibilities for treatment of severe malocclusions which could not be treated by orthodontics alone. As shown by Kondo and her colleagues (2000, 2005), the limits of orthodontic treatment alone for severe malocclusions are broadening, but the underlying skeletal imbalances remain. Until the 1960’s, orthognathic surgeries were usually performed without any pre-surgical orthodontic treatment. In fact, when Hüllihen performed the first mandibular sub-apical osteotomy on a burn victim, he was able to correct the prognathism but created an edge-to-edge occlusion anteriorly (Aziz, 2004).

The three stage philosophy of orthognathic surgery was later adapted and is still valid today in the majority of cases. These stages involve pre-orthognathic orthodontic treatment to relieve the dental compensations followed by the orthognathic surgical procedure and finally post-surgical orthodontics to finish the case and settle the occlusion.

### 1.2 Challenges associated with conventional orthognathic surgery cases

The pre-surgical orthodontic treatment of patients requiring orthognathic surgery has been criticized to be the most time consuming stage of treatment (O’Brien et al., 2009). The mean length of this stage has been reported anywhere between 7 to 47 months (Luther et al., 2003). The longer pre-operative treatment phase can potentially aggravate the dental caries and periodontal problems and negatively influence patient compliance.

The worsening of facial profile prior to surgery which results from dentoalveolar decompensation is also a great disadvantage. This is even more so noticeable in Class III patients. The removal of natural dental compensation in these patients often results in advancement of the lower lip as well as retrusion of the upper lip which together accentuate the soft tissue disharmony. Considering the fact that patients who desire to undergo orthognathic surgery are often very concerned about facial esthetics, the long pre-surgical orthodontic preparation delays addressing the patient’s chief complaint.

### 1.3 “Surgery First” orthognathics

The challenges involved with the conventional three stage model of orthognathic surgery have given rise to new concepts such as what is known as “Surgery First” orthognathics. In 1991 Brachvogel proposed this approach with the goal of reducing some of the disadvantages and inconveniences of pre-surgical orthodontics (Brachvogel et al., 1991). In that article the advantages of post-surgical orthodontics are outlined as follows: 1) Orthodontic movement does not interfere with compensatory biological responses, 2) Dental movements can be based on an already corrected skeletal pattern, and 3) Some surgical relapse can be managed during treatment. Informative case reports have been published by Tsuruda et al. (2003) and Sugawara et al. (2008).

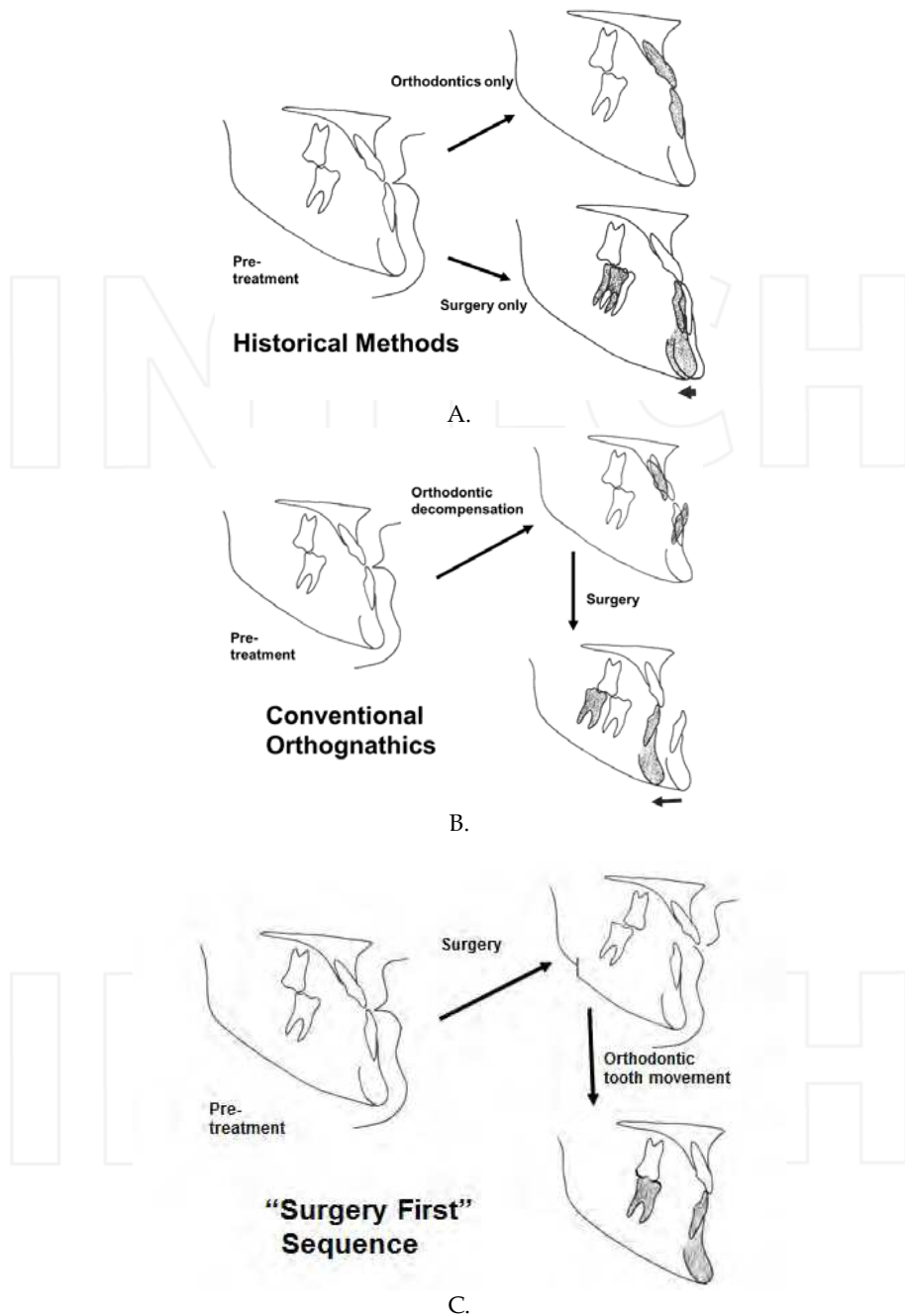


Fig. 1. Various approaches to the treatment of severe skeletal disharmonies. A. Historical methods. B. Conventional orthognathics. C. "Surgery First" sequence.

A major driving motive for performing surgery first orthognathics has been the reduced treatment time reported in the literature (Yu et al., 2010; Villegas et al., 2010; Liou et al., 2011a, 2011b). Traditionally, a number of studies have focused on accelerated orthodontics as a result of corticotomy procedures with or without bone augmentation. It has been shown that orthodontic treatment time decreases by using alveolar osteotomy procedures (Wilcko et al., 2001; Wilcko et al., 2009). The proposed mechanism for this decrease in treatment time is the increase in cortical bone porosity which translates to decreased resistance to tooth movement (Wilcko et al., 2009). The same concept can be applied to performing orthognathic surgery before orthodontic treatment begins, but actual supporting data are sparse.

It has been shown that during the healing process after orthognathic surgery, there is an increase in blood flow above the pre-surgical levels (Justus et al., 2001). The increase in blood flow facilitates the healing process and stimulates bone turnover which can potentially speed up orthodontic tooth movement. Despite the postulated hypothesis, there is very limited information about the molecular basis for accelerated tooth movement. Moreover, the decrease in treatment time has only been documented as case reports. As knowledge becomes available about the reasons for increased bone turnover after osteotomies of the jaws (Iliopoulos et al., 2010), new surgical techniques will improve treatment options for the patients.

In recent years, more attention has been given to the subject and more and more cases are being treated with the “Surgery First” approach. The basic concept that underlies surgery first orthognathics is the elimination of the pre-surgical orthodontic phase and elimination of soft tissue imbalance accompanying the dentofacial deformity. The most important consideration in using this technique is the fact that it is a complicated approach that requires close cooperation of a highly experienced orthodontist and the orthognathic surgeon. Prediction of the desired final occlusion is a very difficult task. Also, the surgeon must be able to arrange the skeletal components to match the predicted skeletal positions and occlusion precisely. More importantly, the advent of rigid fixation was the key which allowed the surgery first approach to be implemented. With the conventional wire fixation, the mobility of the bony segments would not allow for a stable position of bone post surgically. Hence, any attempted movement could potentially result in movement of the skeletal components. Skeletal relapse caused by occlusal instability can be partially overcome with rigid fixation (Liao et al., 2010). In a series of case studies, it seems that the postoperative skeletal changes are similar between surgery first and conventional treatment of Class III malocclusions (Baek et al, 2011; Liao et al, 2010). Postoperatively in both types of treatment there was some forward superior movement of the mandible, but overall the needed posterior movement of the mandible was achieved and preserved.

The following segmental osteotomy case demonstrates the concepts of surgery first technique before getting into conventional one or two-jaw orthognathic surgery cases. Figure 2 shows the initial presentation of a patient with a chief complaint of unattractive smile and broken front teeth. On examination it was revealed that the bimaxillary protrusion could be resolved by extraction of upper and lower first premolars and segmental osteotomy procedures to retract the maxillary and mandibular dentoalveolar segments. After model surgery was performed (Figure 3), it was decided to remove the teeth at the time of surgery and utilize the surgery first approach. Maxillary and mandibular first

premolars were extracted at the time of surgery and the anterior dentoalveolar segments were set back before any orthodontic treatment was initiated. An advancement genioplasty was done simultaneously; bony continuity between the right and left sides of the mandible could be maintained because the vertical dimension of the mandibular symphysis was large.

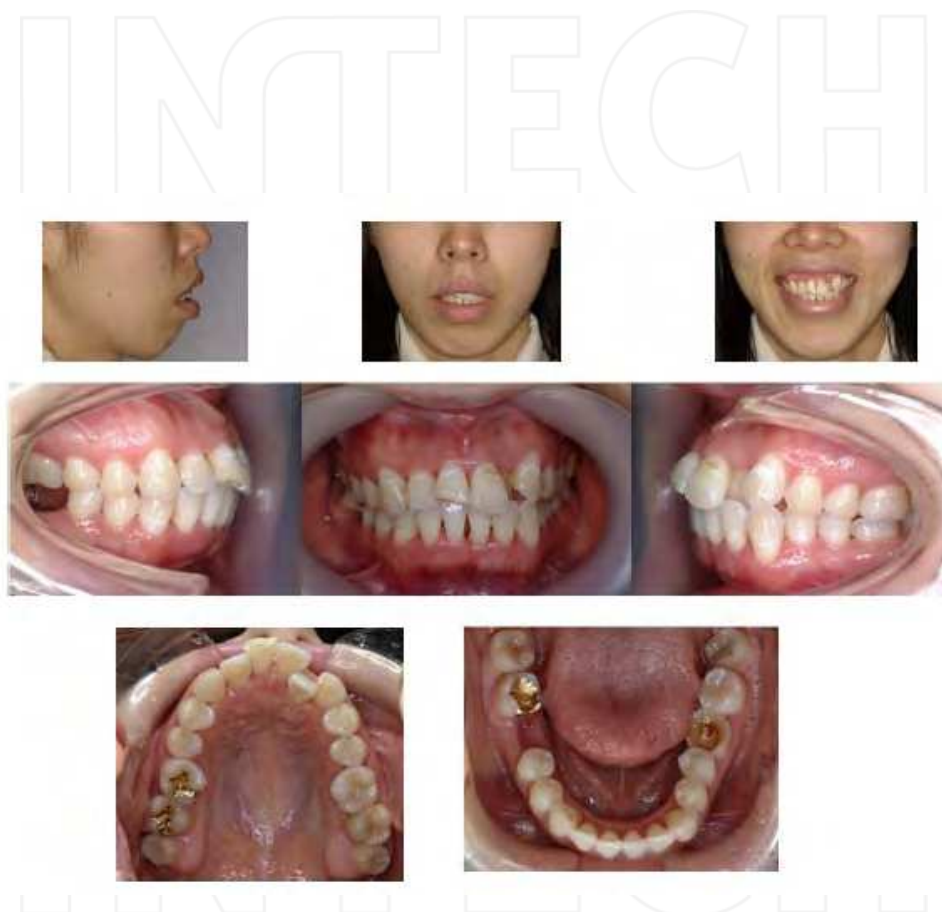

Fig. 2. Initial Presentation.

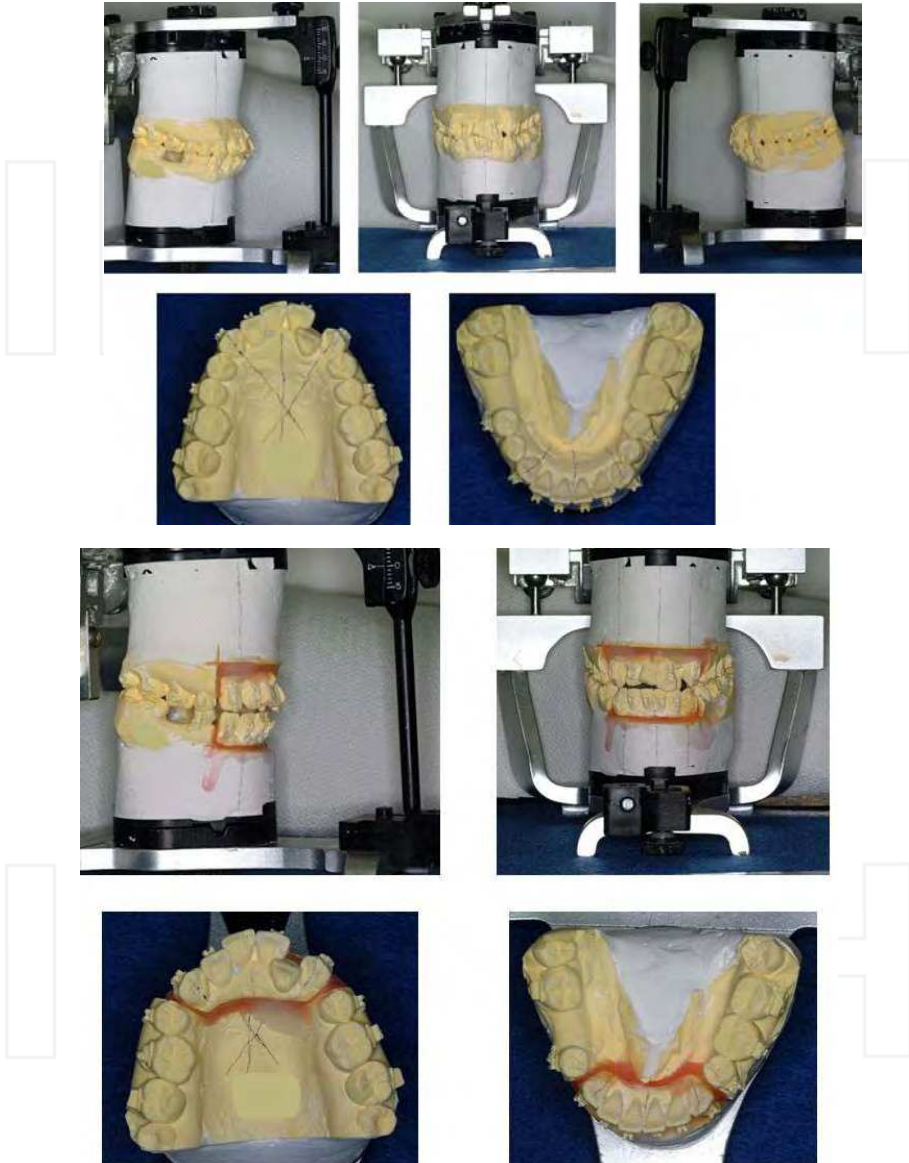


Fig. 3. A) Initial Models B) Model Set-up.

Figure 4 shows the patient immediately following the procedure. The occlusion immediately following surgery shows the same occlusion as was predicted in the model surgery. Orthodontic treatment was initiated 3 weeks after surgery and case was finished in 15 months. The treatment time in this case was longer than typical anterior segmental osteotomy cases due to the need for Class II correction. Subsequently the maxillary anterior teeth were restored for better esthetics. The final intra-oral and extra-oral pictures are shown in Figure 5.

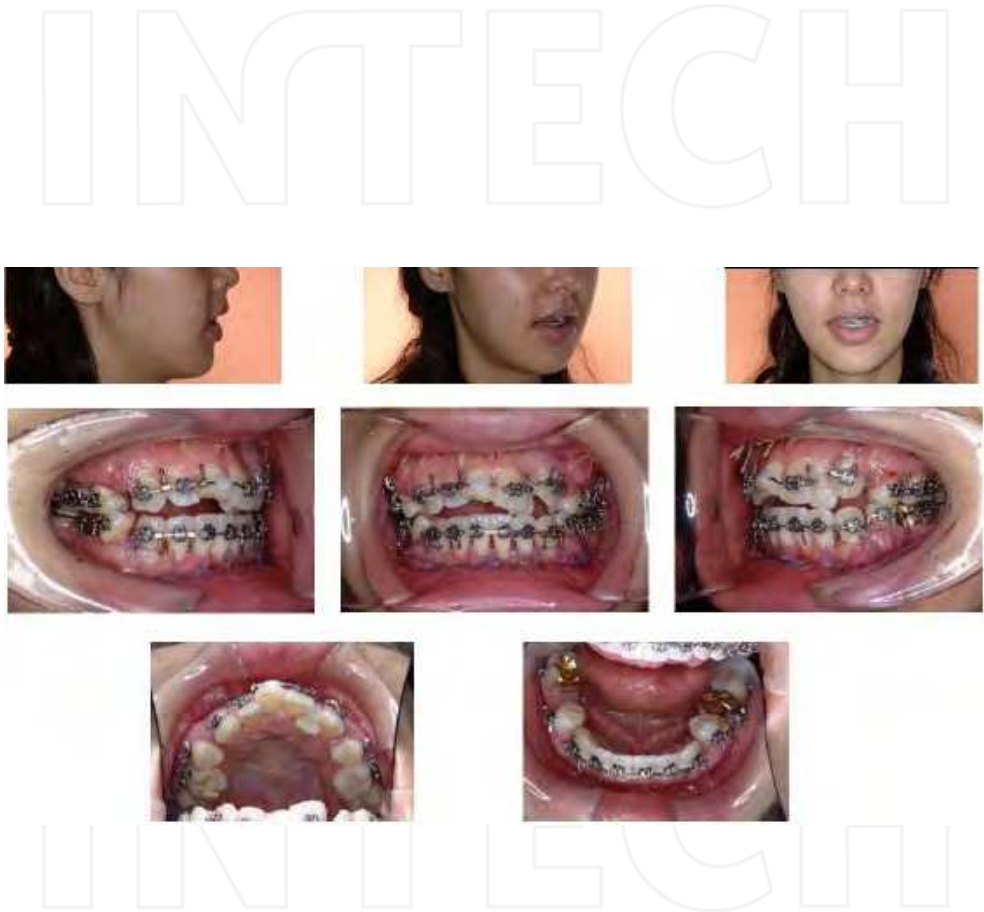


Fig. 4. Records immediately after surgery.



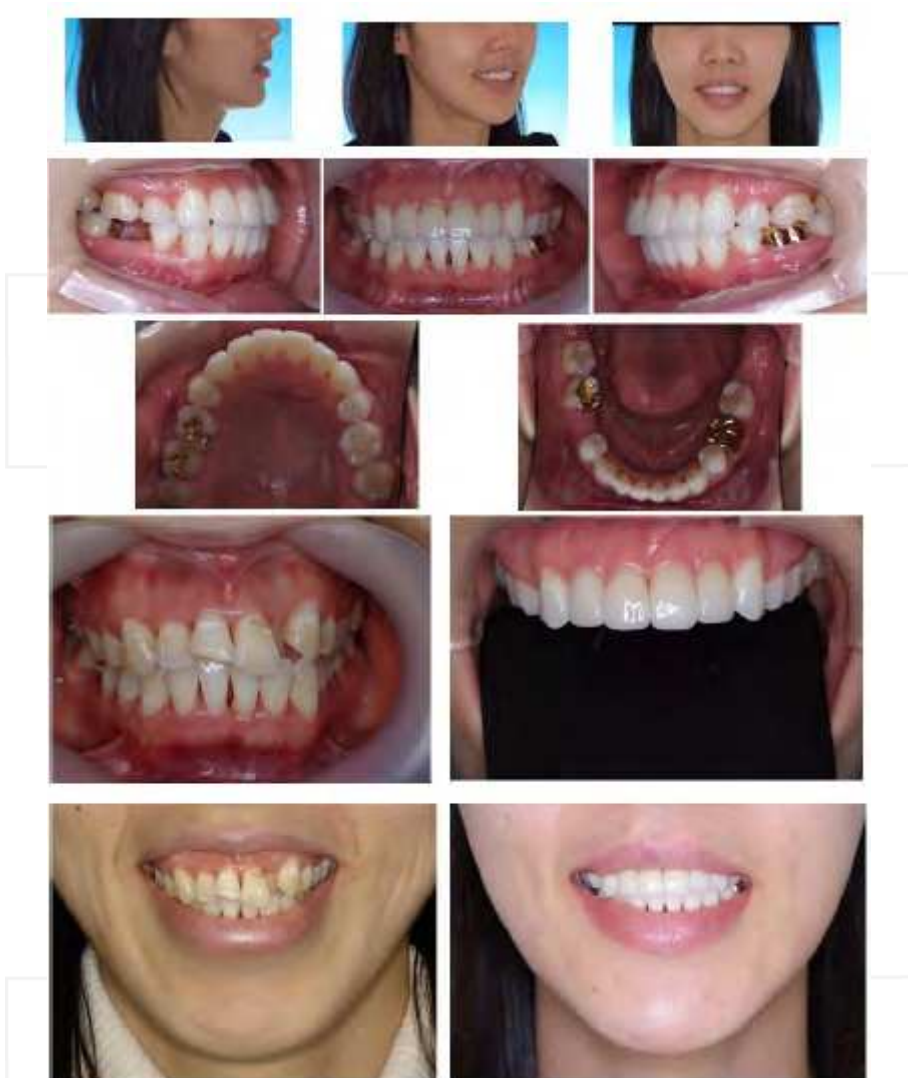

Fig. 5. Final Presentation.

By performing surgery first, patient was very satisfied with the reduction in protrusion as soon as the surgery was performed. The reduced treatment time also was an advantage.

## 2. Surgery first orthognathics indications

The surgery first approach can be used to treat a variety of cases depending on the specific characteristics of the malocclusion and the dentofacial deformity. Nonetheless, there are certain criteria which can make a case the ideal surgery first case.



In the ideal situation, the malocclusion accompanying the skeletal deformity represents mild to moderate crowding, normal to mild proclination and retroclination of upper and lower incisors, and minimal transverse discrepancies (Liou et al., 2011a, 2011b).

Even though the surgery first technique can be applied to Class II as well as Class III malocclusions, the majority of cases treated using this approach have been cases with Class III malocclusion meeting the above criteria. A possible explanation is that a Class III skeletal relationship results in a more pronounced soft tissue imbalance. Often, Class II skeletal deformities can be masked as the patient shifts the mandible forward, but the equivalent backward shift of the mandible to mask Class III deformities is physically impossible. In the traditional approach, decompensation of the arches results in an even more disfiguring profile for Class III patients. Hence, these patients seem to see the benefit of the surgery first approach to a greater extent than Class II cases and possibly seek this new approach more. It is also likely that for Class II patients, advancing a retrognathic mandible into the correct position will create an anterior crossbite temporarily worsening the patient's appearance until orthodontic treatment can upright and retract the lower incisors; this occurrence doesn't fit with surgery first concepts.

Figure 6 illustrates an ideal case which was treated using the surgery first approach. Patient presented at the age of 22. After the case was treatment planned and the model surgery was performed, the surgery first approach was indicated. Teeth were bonded and passive stainless steel arch wires were placed a few days prior to surgery. A two-jaw orthognathic surgery was performed and the patient returned five weeks after surgery for the initiation of orthodontic treatment. As it will be discussed later in this chapter, immediately after surgery there was a lateral open bite as can be seen in Figure 7. This transitional malocclusion was predicted during the model surgery procedure. Since the skeletal discrepancy was no longer present, the case could subsequently be treated as a Class I skeletal case. Figure 7 shows the occlusion at the start of orthodontic treatment followed by settling of the bite and improvement of overbite and overjet after eight months of orthodontic movement. The case was finished after a total treatment time of 20 months (19 months of orthodontic treatment) with lateral incisor restorations and satisfactory results in terms of facial aesthetics and occlusion as evident in the final records (Figure 8).

### 3. Advantages of surgery first orthognathics

In most cases, patients who receive orthognathic surgery in order to correct a dento-skeletal deformity present to the orthodontist's office with a chief complaint that includes dissatisfaction with their facial appearance. Hence, the main concern of the patient must be addressed during the course of treatment. The conventional three-stage approach in orthognathic surgery requires decompensation of the teeth which often results in worsening of the facial profile especially in patients with Class III malocclusion. The improvement in facial aesthetics in these patients does not occur until months later when the actual surgery is performed. Having surgery first eliminates the unsightly pre-surgical profile and allows the chief complaint of the patient to be addressed at the beginning of treatment. With the conventional approach, it is very difficult for the patient and the orthodontist to predict the exact time of surgery. Since the surgical procedure precedes orthodontic treatment, the patient has the opportunity to choose the timing of surgery to allow for the postoperative healing period.

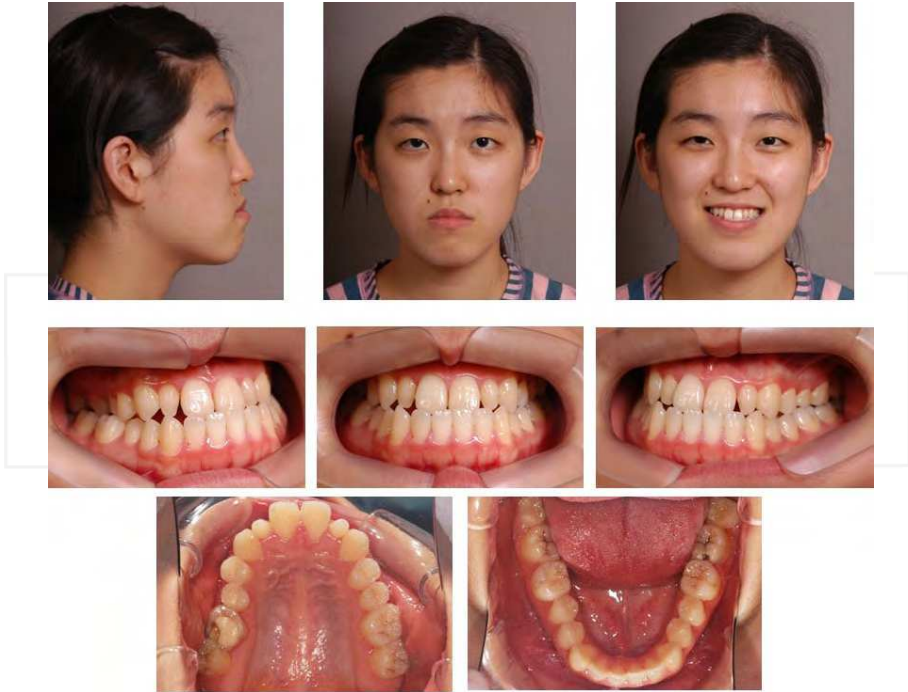

Fig. 6. Initial Presentation.

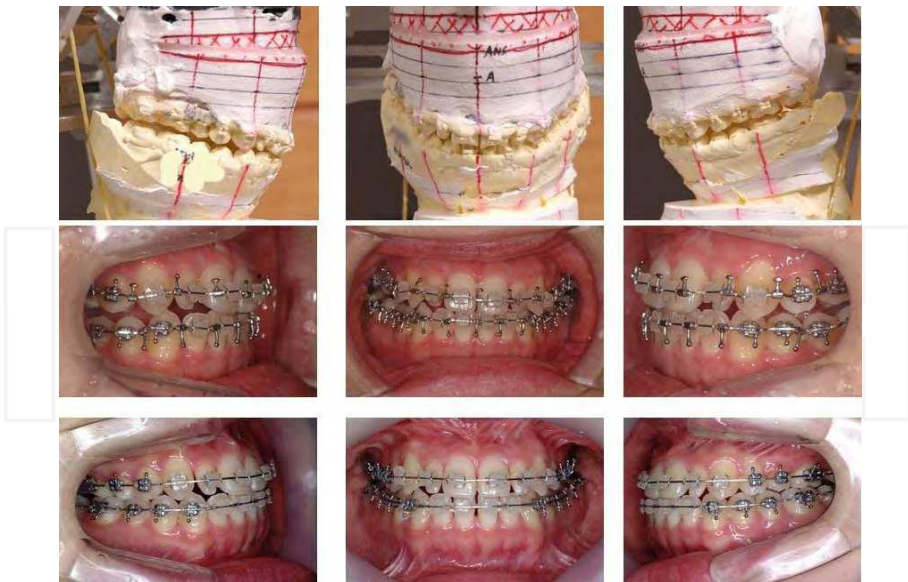

Fig. 7. A) Model Surgery B) Progress records at the start of orthodontic treatment and C) Progress records 8 months into orthodontic treatment.

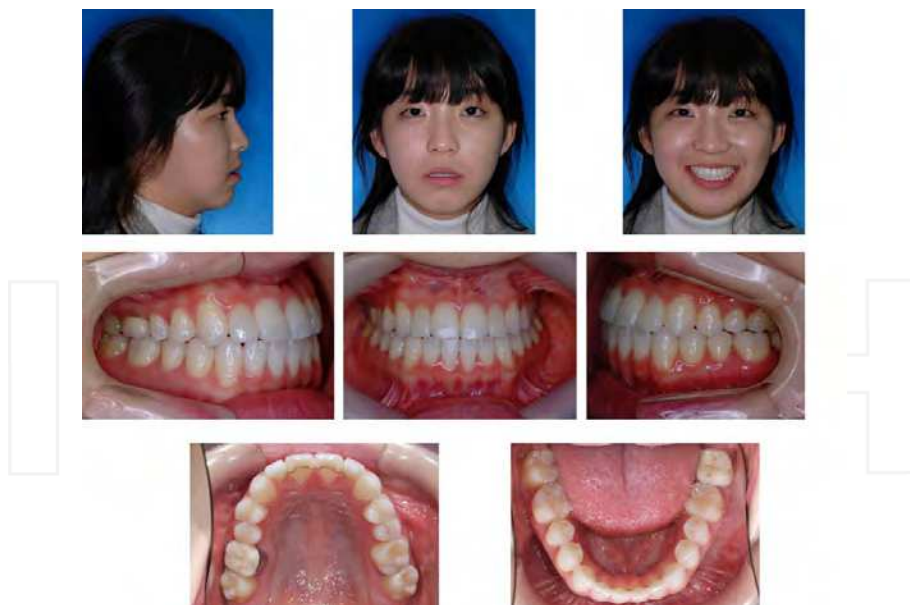

Fig. 8. Final Presentation.

The total treatment time in surgery first cases is reduced. Treatment times as short as seven months have been reported in the literature (Villegas et al., 1997). The pre-surgical orthodontic phase in conventional three-step orthognathic surgery cases is the most time consuming step. Bypassing this step results in an overall shortened treatment time to 1 to 1.5 years or less (Liou et al., 2011a, 2011b). The treatment time varies depending on the treating orthodontist's experience and the orthodontist's standard for finishing.

Immediate resolution of the soft tissue and skeletal imbalance is an added advantage in surgery first approach (Baek et al, 2010; Nagasaka et al, 2009). Dentoalveolar decompensation which is performed in conventional pre-surgical orthodontics works against the physiological compensatory dentoalveolar processes. In other words, the orthodontist tries to achieve a pre-operative occlusion which is against what the soft tissue and skeletal components dictate. This has been thought of as one of the challenges in decompensating the arches prior to surgery. When surgery is completed first, the skeletal and soft tissue discrepancy is relieved and the teeth can be aligned without the need to fight with the physiological limitations.

### 3.1 Reduced treatment time in surgery first orthodontics

The reduced treatment time in surgery first approach can be attributed to two main factors: 1) the resolution of skeletal and soft tissue imbalance prior to initiation of tooth movement and 2) the regional acceleratory phenomenon.

As mentioned previously, the resolution of skeletal and soft tissue imbalance through surgery allows the orthodontist to move the teeth in a normal skeletal and soft tissue envelope which facilitates the orthodontic movement. For example, in a Class III skeletal pattern, the relationship between the upper and lower jaw is not ideal. The imbalance between the two jaws results in dentoalveolar compensation which throughout an

individual's lifetime, attempts to minimize and mask the skeletal deformity by maintaining contact between the teeth. This often results in proclination of upper incisors and retroclination of lower incisors in an attempt to minimize the negative overjet.

Figure 9 illustrates the initial presentation of a male patient. The skeletal Class III relationship in this patient was camouflaged by proclined upper incisors as well as slightly

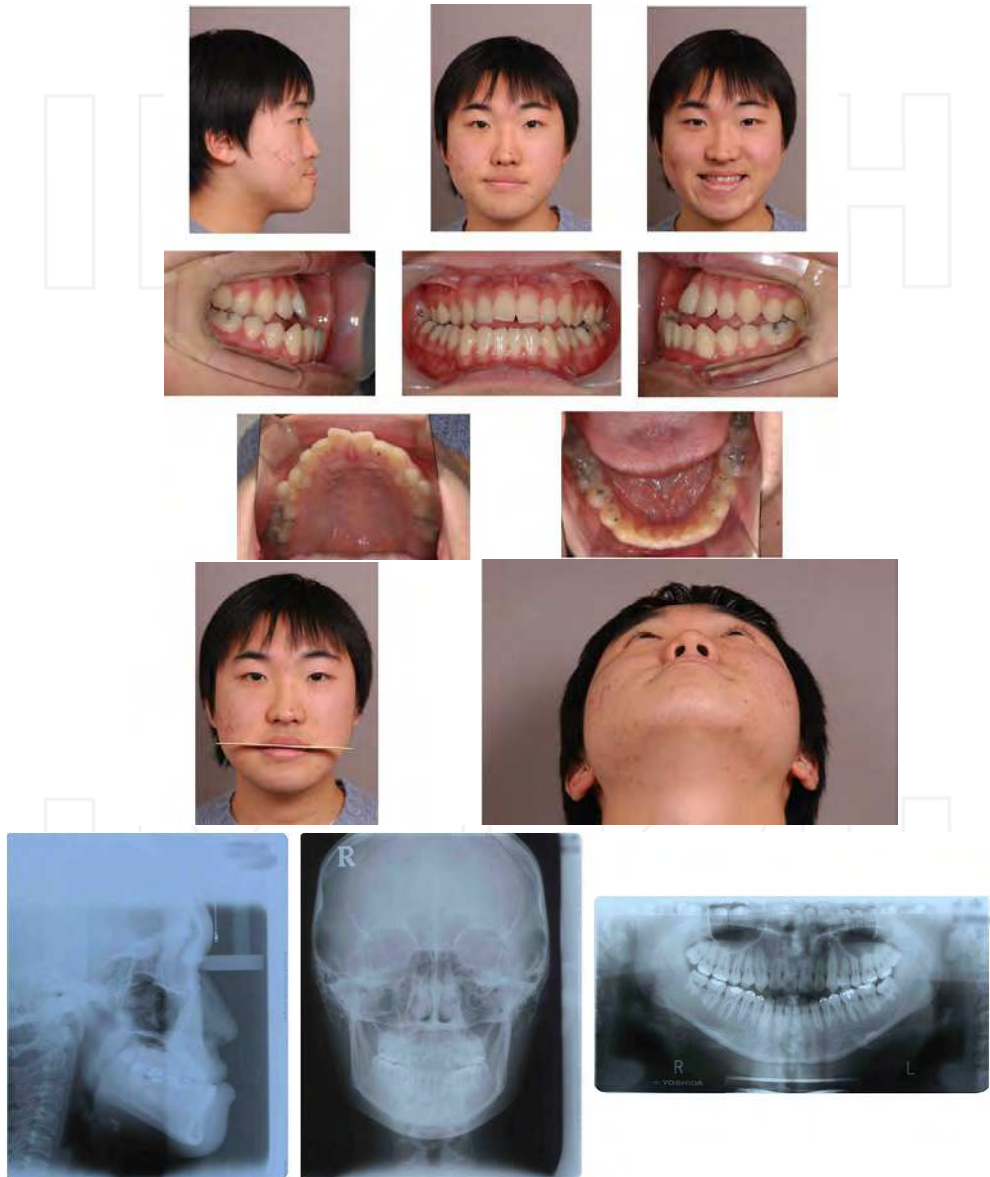


Fig. 9. Initial Records.



retroclined lower incisors. Anterior open bite was present and the chin was deviated to the right side. Such compensation had given him the best possible soft tissue profile and occlusion biologically possible with such skeletal disharmony. If this case was to be treated with the conventional protocol for orthognathic surgery, the upper incisors would need to be retroclined and the lower incisors would need to be proclined in order to de-compensate the upper and lower arches, achieve sufficient negative overjet, and finally perform the orthognathic surgical procedure. This decompensation would place the teeth in a position which is not "natural" for the current skeletal relationship and is against the compensatory mechanisms which have been at work for many years. The price would have been paid by a relatively long pre-surgical treatment time.

Figure 10 shows the model surgery and fabrication of the intermediate splint to position the maxilla which is then followed by prediction of the final occlusion and preparation of the final splint. The final occlusion is predicted on the models.

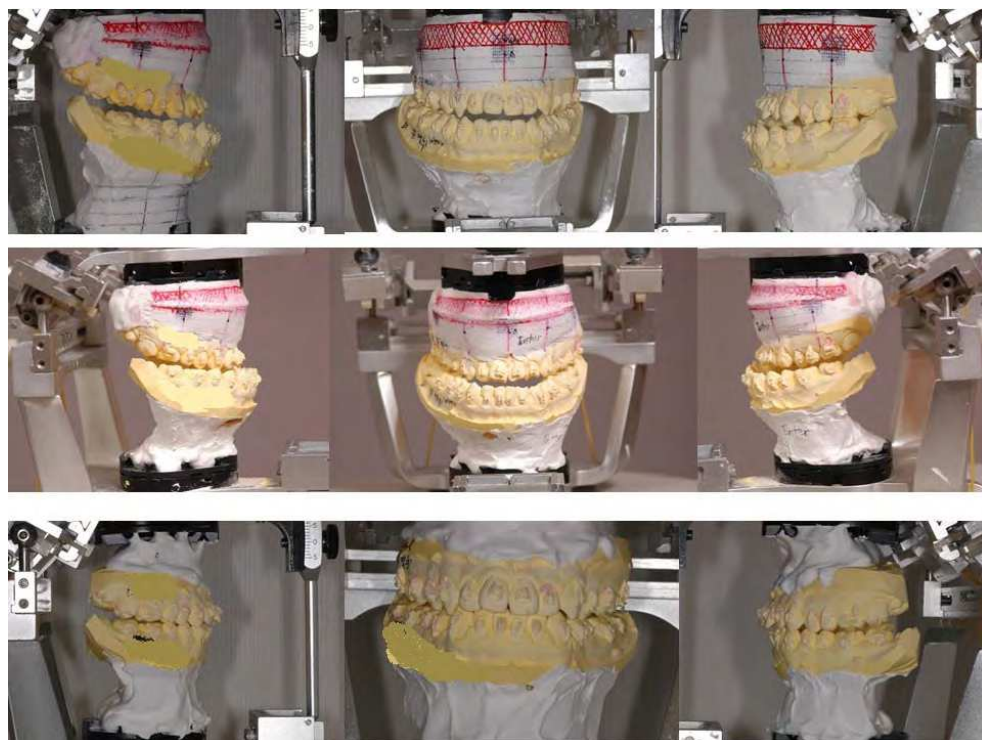


Fig. 10. Progress Records.

The surgery first approach was instead utilized in treating this patient. Brackets were bonded three days prior to surgery and passive arch wires were placed. A two-jaw surgical procedure was performed and orthodontic treatment was started in six weeks. Figure 11 shows the bonding of brackets before surgery followed by progress records of the patient. The bite settled as the teeth were aligned and decompensated. Patient was debonded after finishing and detailing. The total treatment time was eighteen months. Figure 12 shows the final records of the patient at the time the appliances were removed.

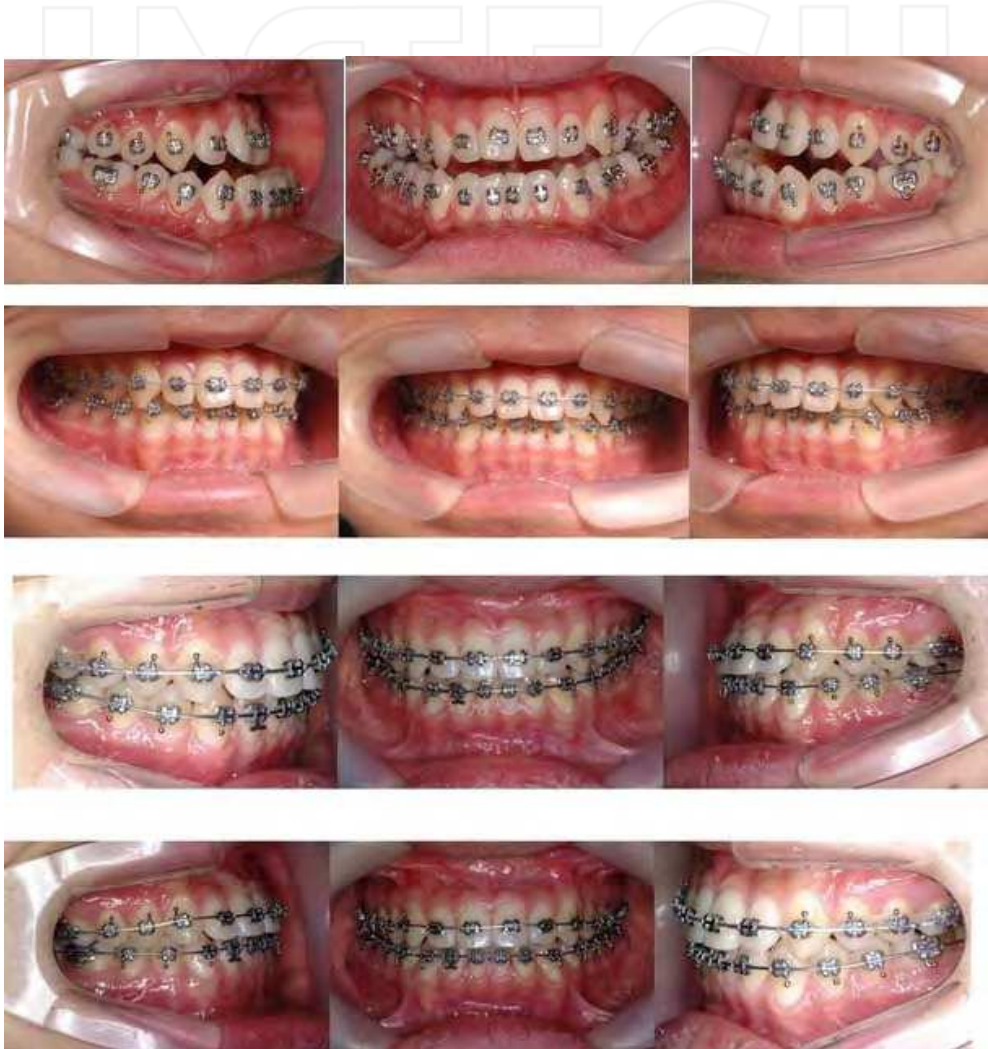

Fig. 11. Progress Records A) Bracket position before placement of passive arch wires, B) 4 months after surgery, C) 9 months after surgery, D) 11 months after surgery.

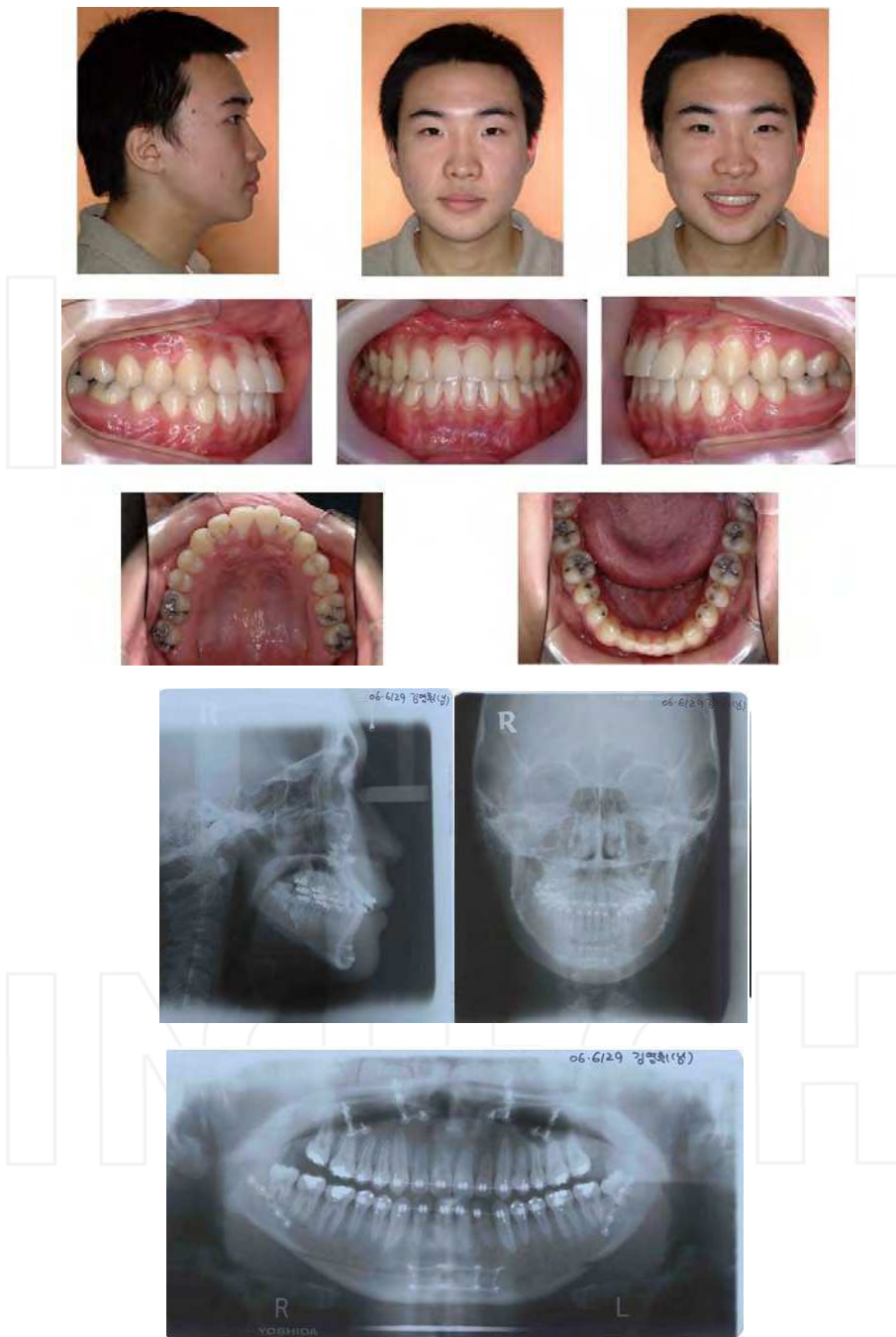


Fig. 12. Final Records



### 3.2 Regional Acceleratory Phenomenon (RAP)

The regional acceleratory phenomenon (RAP) was well described by Frost in 1993. After an osteotomy, bone remodeling around the healing tissue facilitates the healing process. This regional acceleratory phenomenon can be utilized by the orthodontist following orthognathic surgery to accelerate tooth movement. By performing surgery first, this period of rapid metabolic activity within the tissues can be harvested for efficient orthodontic treatment.

The extent and duration of this window of opportunity becomes an important issue in these cases. In order to answer this question, the by-products of bone metabolism have been measured in patients' blood samples following orthognathic surgery. Alkaline phosphatase and C-terminal telopeptide of type I collagen are two bone markers which have been studied. The former is associated with osteoblastic activity while the latter is a by-product of osteoclastic breakdown of bone. The results of one such study show that orthognathic surgery triggers three to four months of higher osteoclastic activities and metabolic changes in the dentoalveolus (Liou et al., 2011a, 2011b). This short period of regional acceleratory phenomenon is a possible explanation for shortened treatment time in surgery first orthodontics.

The regional acceleratory phenomenon is not exclusive to surgery first approach. In the conventional approach, this phenomenon is seen after decompensation has been accomplished and patient has had the surgical procedure completed. The surgery first approach however, utilizes this golden opportunity to speed up the decompensation process which occurs after the surgery unlike the traditional approach. Since the decompensation of the arches is the most time consuming step of the way, the regional acceleratory phenomenon is used when it is needed the most.

Despite the findings demonstrated as case reports on shortened treatment time, the actual duration of the window of time during which the regional acceleratory phenomenon can be utilized for orthodontic tooth movement is still unknown. Various studies have shown different lengths of accelerated tooth movement. Hence, more studies are required at the time being to give sufficient evidence on the actual molecular basis for the accelerated tooth movement as well as the duration of this phenomenon after surgical procedures.

## 4. Treatment planning considerations

Careful planning is the key to the success of any orthognathic surgery case especially when the surgical procedure is to be performed prior to orthodontic treatment. As with any orthodontic treatment, obtaining high quality records including intraoral and extra-oral pictures, models, and radiographs is the first step.

Multiple treatment planning considerations must be taken into account when orthognathic surgery is being performed without prior orthodontic treatment. The orthodontist plans the surgery on the pre-operative models in such a way that a relatively stable occlusion can be achieved during surgery. The teeth will be decompensated to normal positions and angulations following surgery; therefore, the transitional occlusion must allow for post surgical movement of teeth. Since the incisors cannot be used as a guide to predict the final occlusion in surgery first cases, the molar relationship can be utilized as a starting point to come up with a temporary occlusion.

The inclination of upper incisors is important in determining the need for possible extractions. If the upper incisor is excessively proclined, extractions may be considered to allow retraction of upper incisors post-operatively. As a rule of thumb, if the upper incisor to occlusal plane angulation is less than 53 to 55 degrees (Liao et al., 2010), extraction must be considered. Another possibility involves changing the position of the whole maxilla so that the occlusal plane is steeper and producing more upright maxillary incisors. Also, one might distalize the maxillary posterior segments using zygomatic plates as shown by Nagasaka et al. (2009) and Villegas et al. (2010) thus opening space to retrocline the maxillary incisors.

When placing upper and lower models into occlusion, the transverse dimension of the arches in many cases does not allow perfect interdigitation. Hence, the transverse dimension often poses a special challenge when performing model surgery in surgery first cases. The midlines must be coincident or close to it after surgery and proper buccal overjet must be established bilaterally. Depending on the degree of discrepancy between the two arches, the orthodontist can resolve this issue by planning for segmental osteotomies in more severe cases or possibly plan on resolving the issue post-surgically by arch coordination and elastics.

The most challenging and time consuming step in preparing for surgery first orthodontics is the prediction of the final occlusion based on the current position of teeth. The experience of the orthodontist plays a very important role in the process. The term intended transitional malocclusion (ITM) is used to describe the occlusion which will be used to fabricate the surgical splint and is the surgeon's guide during surgery (Park et al., 2011). The ITM must be stable enough to allow predictable splint fabrication and skeletal movement. Therefore, at least a three-point contact must be established between the upper and lower models when deciding on the ITM. In cases where such temporary occlusion cannot be established, it is advisable to initiate some orthodontic movement in order to relieve some of the interferences and allow for a more stable transitional malocclusion to be established. In a Class III skeletal malocclusion after surgery, a Class I or II malocclusion with the characteristic dental compensations of a Class III malocclusion is established. The decompensation of the teeth is performed following surgery. The following cases demonstrate the importance of meticulous treatment planning in surgery first orthodontics.

Figure 13 demonstrates the initial records of a 24 year old female patient who presented with chief complaints of a long face, strong chin, and difficulty in pronunciation (lisp sound).

Upon initial examination, the patient had a Class III malocclusion with anterior open bite. The upper second premolars were displaced palatally and the upper right first premolar was restored with an ill-fitting full coverage crown due to lack of sufficient space which compromised the tooth esthetically and periodontally. It was determined that extractions in the maxillary arch will be needed to allow for decompensation of teeth after surgery. Model surgery was performed allowing upper second premolar extraction during surgery. The concept behind extraction of upper second premolars can be explained in terms of conventional decompensation procedure as well. If the case was being treated with orthodontic decompensation of teeth prior to surgery, one way to achieve sufficient negative overjet would have been to extract the upper premolars to allow retraction and retroclination of upper incisors. In surgery first approach, extracting the premolars during

surgery provides for the space needed to decrease the overjet and retract the incisors after surgery. Careful planning and precise surgical delivery is of utmost importance in such cases due to the added complexity of simultaneous extractions. Figure 14 shows the model surgery and set-up of the case during surgical planning.

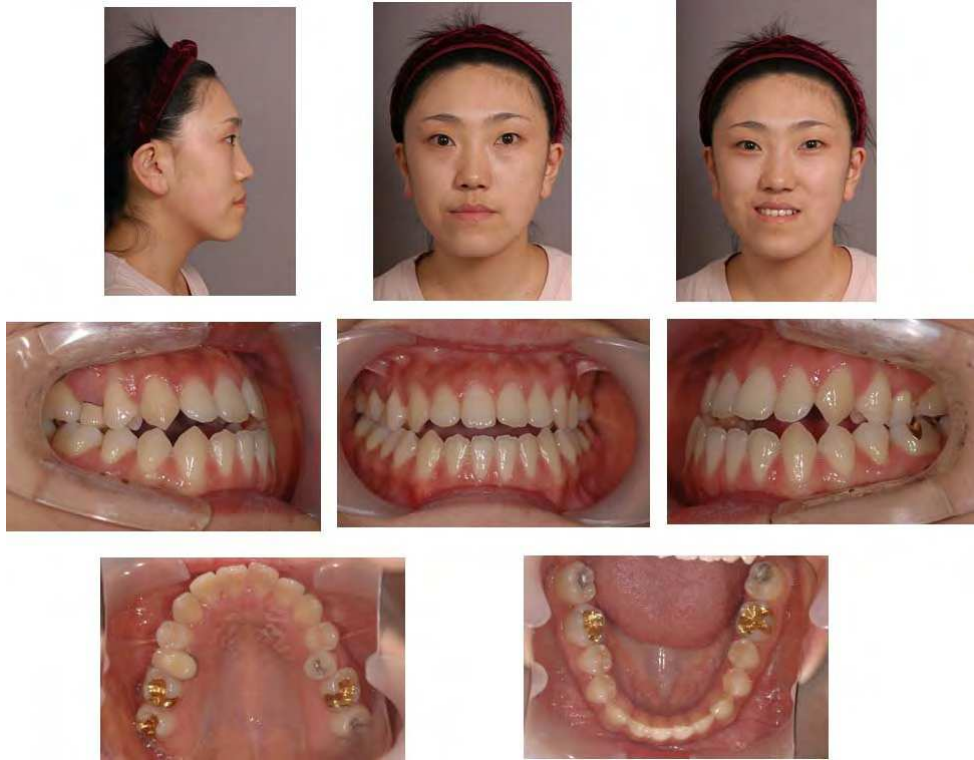

Fig. 13. Initial Records.

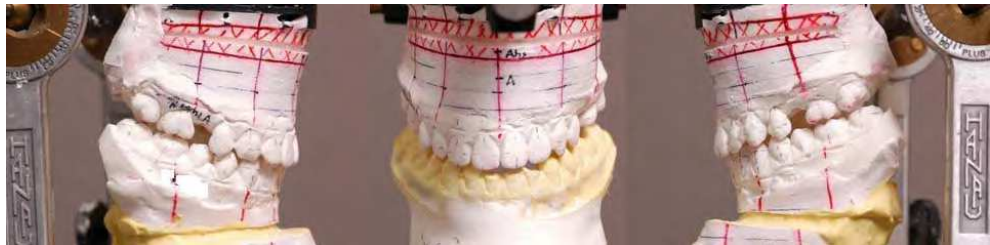

Fig. 14. Model Surgery.

The indirect bonding technique was used in this case which allowed the bending of stainless steel passive arch-wires on the models. The bonding of brackets, placement of the wire, and splint try-in were done at the same visit a few days prior to surgery. Orthodontic movement was initiated 7 weeks after the surgical procedure was completed (Figure 15).

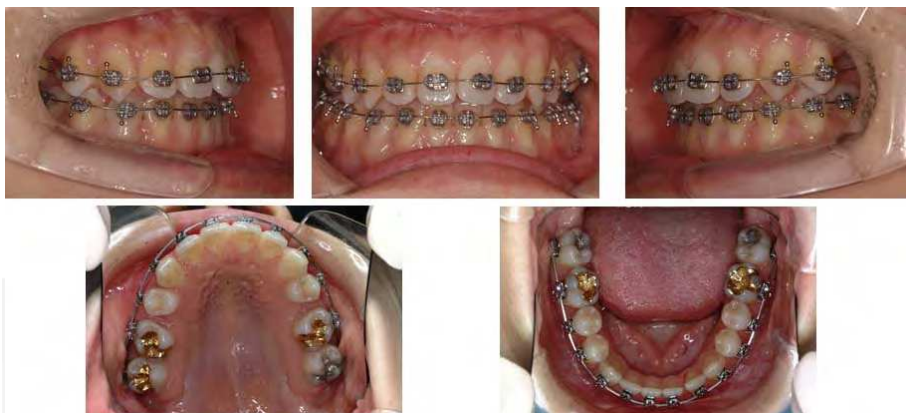

Fig. 15. Initiation of orthodontic movement.

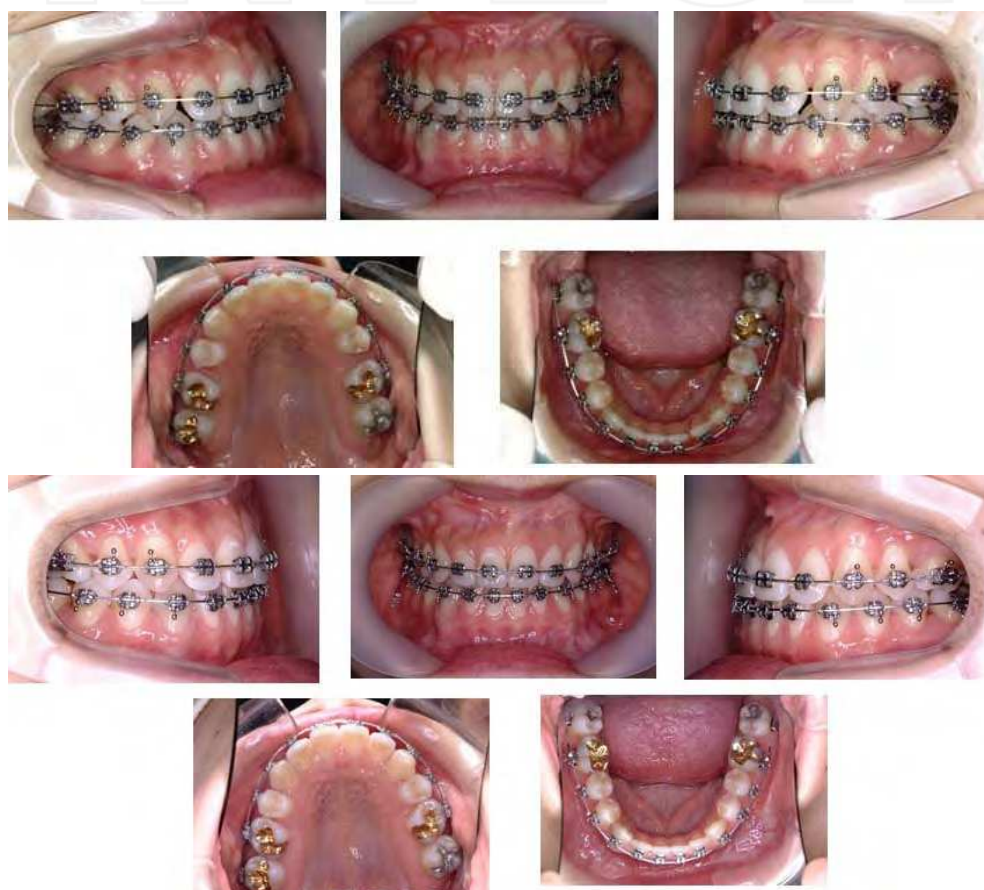

Fig. 16. Orthodontic Treatment in Progress A) 5 months B) 13 months into treatment.

Case was debonded after 16 months of active orthodontics. Figure 17 shows the final records with good occlusion and esthetics.

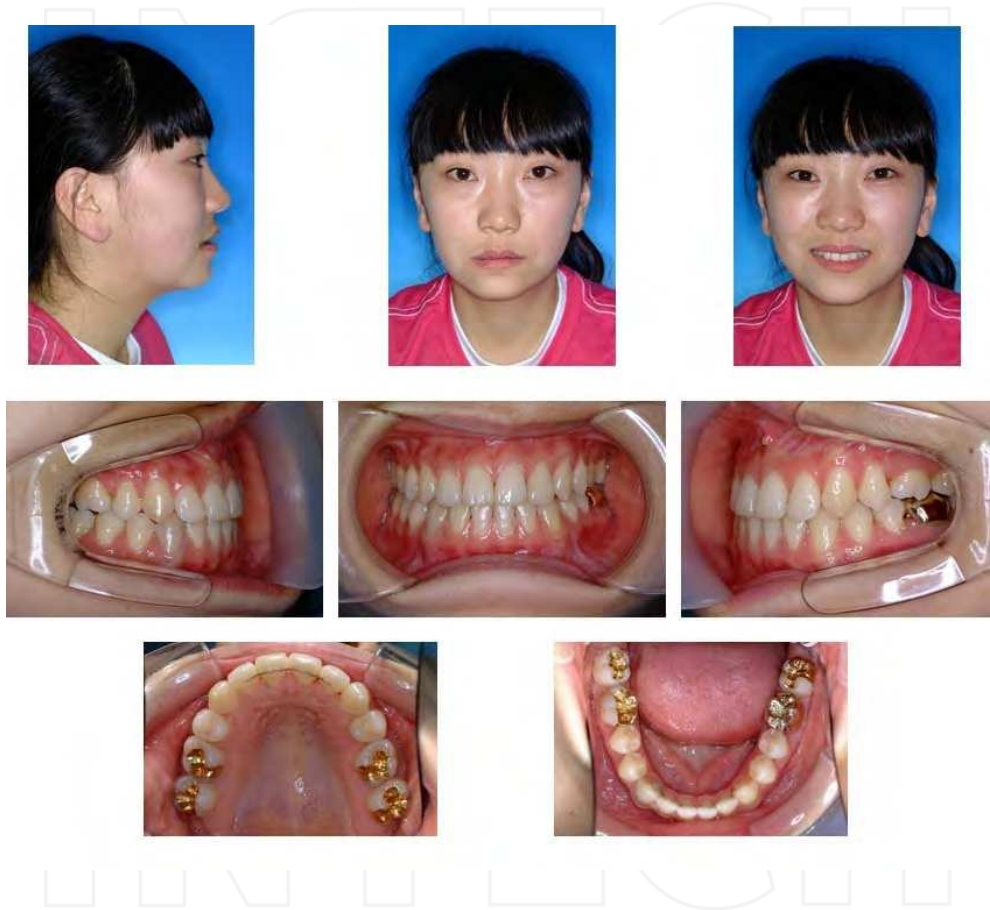

Fig. 17. Final Records.

The results of this particular case were stable over a two year retention period. Figure 18 shows the intraoral images at two years after removal of the orthodontic appliances.



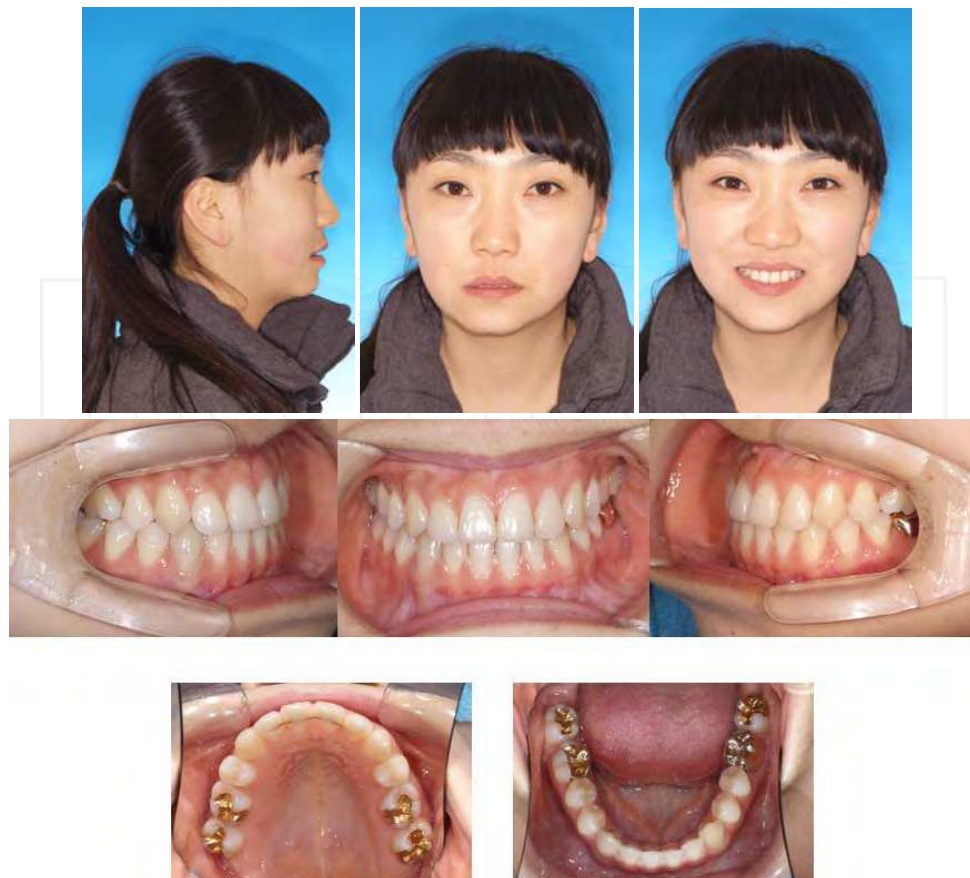

Fig. 18. Retention after two years.

#### 4.1 Protocol variations

While the sequence of treatment is similar, different protocols are being used to prepare the patient for surgery, perform the surgical procedure, and initiate orthodontic treatment. Orthodontists often have their own customized preferences which have developed in their years of practice.

In most cases, the brackets and the wires are placed right before surgery. While some clinicians prefer to bond the wire directly to the surface of teeth, others choose to utilize the conventional orthodontic attachments. Although bonding the wire directly to the teeth is very fast, it makes post-surgical orthodontics a problem since teeth need to be bonded at that point. Given the healing period after surgery, it is very difficult to place brackets on teeth while minimizing patient discomfort.

Different types of wires are being used by orthodontists across the globe prior to surgery. Contrary to conventional orthognathic surgery cases, in surgery first treatments leveling and aligning have not yet been performed which makes it very difficult to place the wire.

Some orthodontists prefer to place a passive stainless steel wire which has been bent and adapted to each tooth to prevent any tooth movement. The first author's preference is to use 0.022 slot brackets as well as passive stainless steel wires of 0.017 inch x 0.025 inch dimensions. Other orthodontists who use the surgery first approach have opted to use nickel-titanium wires at time of surgery. Finally, a few orthodontists prefer not to place any wires at the time of surgery.

The use of nickel-titanium wires translates into immediate tooth movement after surgery which can be an advantage. However, in doing so, the orthodontist loses the opportunity to observe the stability of the surgical correction prior to starting the tooth movement. The rapid acceleratory phenomenon not only affects the tooth movement but also can affect the alveolar bone. Hence, it is the first author's preference not to use these wires or elastics immediately after surgery to prevent unwanted movement of the alveolar process and rather wait for about 4 to 6 weeks after surgery.

The use of surgical splint during and after surgery also varies between different orthodontists. While some advocate the use of the splint only during surgery, other groups have advocated its use anywhere between one to four weeks after surgery. Nagasaka et al. have used removable Gelb-type splints post operatively (Nagasaka et al., 2009). The first author's preference is to leave the splint in for about 4 to 6 weeks after surgery and if an open bite is observed, to use elastic between the splint and the mini-screws or to leave the splint for a longer period of time. The use of mini-screws will further be discussed in the following section. Also, during the post-surgical period, the first author tries to avoid vertical elastics and allows the bite to settle as the dental compensations resolve. Table 1 summarizes the first author's protocol in comparison to other existing protocols.

First Author's Protocol	Other Protocol Variations
.022 bracket slots	0.018 brackets No brackets ( wires bonded directly to teeth)
0.017 x 0.025 stainless steel passive wires prior to surgery	Nickel titanium wires No wires
Heavy intermaxillary elastics full time for 2-3 weeks, then check if teeth go into splint smoothly without elastics Release splint from maxilla but patient continues to use splint and simple elastics	No use of splints after surgery (splints only used during surgery) Use of splint 4 weeks after surgery
If mandible is stable, at 5-7 weeks start moving teeth with NiTi or copper NiTi	Start moving teeth soon after surgery ( less than 1 month)

Table 1. Comparison of first author's protocol with other protocol variations.

#### 4.2 Use of skeletal anchorage in conjunction with surgery first approach

In recent years, temporary anchorage devices have become very popular in orthodontics. The use of skeletal anchorage has provided for more predictable orthodontic movements while minimizing the undesirable side effects. Some authors have placed great emphasis on the use of mini plates and mini screws to control the inclination of the upper incisors and to prevent the relapse of an anterior crossbite in Class III cases (Liao et al., 2010).

The surgery first approach requires meticulous treatment planning and collaboration between the orthodontist and the orthognathic surgeon. The model surgery is based on the



orthodontist's vision on what is achievable post orthodontically based on previous experience. Hence, many uncertainties remain at the time the patient is sent to surgery. By utilizing the temporary anchorage devices, many orthodontists try to have a "back-up" system which can be used to help in post-surgical orthodontic phase. These devices are anywhere from single mini-implants to titanium plates which can be placed at the time of surgery.

Nagasaka et al. have advocated the use of zygomatic plates as temporary anchorage devices to aid in post-operative orthodontic movement (Nagasaka et al., 2009). In one case report, a Class III surgery first case was corrected surgically to a Class I skeletal relationship with a Class II dental tendency. Since the teeth were not decompensated prior to surgery, after the surgery the occlusion was expected to exhibit excessive overjet. During orthognathic surgery zygomatic plates were placed. The plates were then used to distalize the upper arch post-operatively to achieve Class I canines and ideal overjet (Nagasaka et al., 2009).

Figure 19 shows the initial presentation of a female patient. The skeletal Class III pattern was accompanied by open bite and mild crowding in both arches. the upper incisors had previously been restored with full coverage crowns.

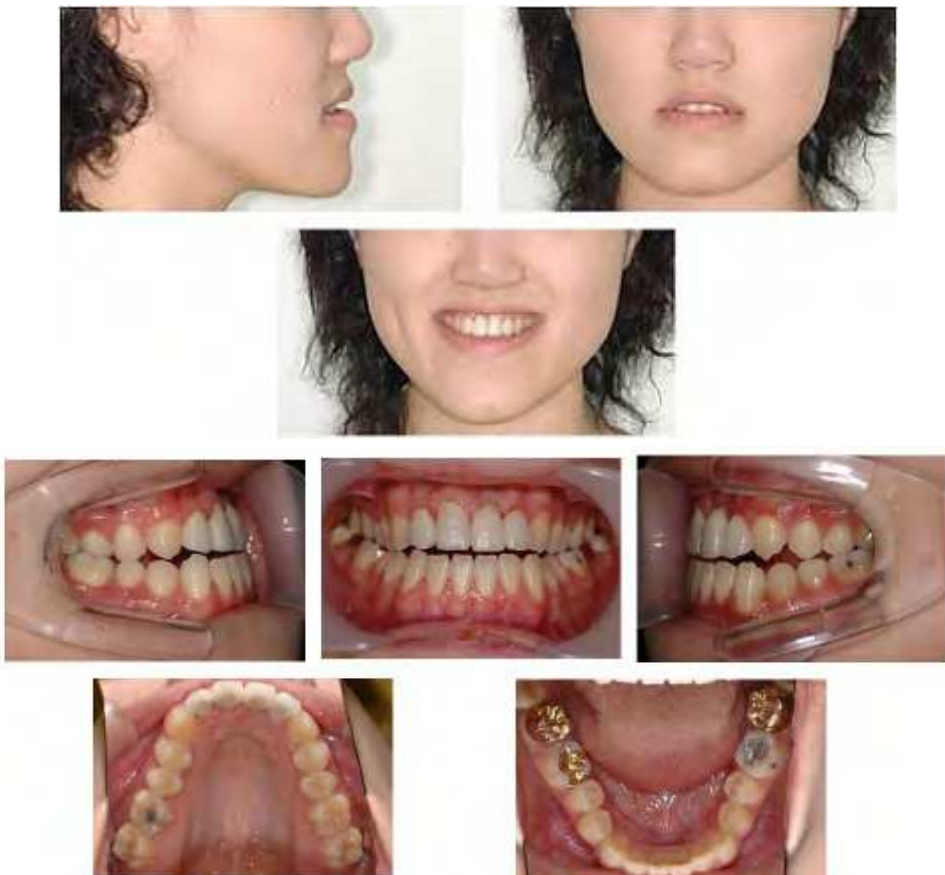

Fig. 19. Initial Records.

After careful treatment planning, model surgery was performed to predict the final position of teeth and fabricate the splint. Prior to surgery, teeth were bonded and stainless steel arch wires were passively engaged (Figure 20). Patient underwent a two-jaw surgical procedure and at the time of surgery four mini-implants were placed mesial to upper and lower canines. The mini-implants were used after surgery to settle the bite with elastics. Figure 21 shows the progress of the case and the use of temporary anchorage devices in settling the bite.

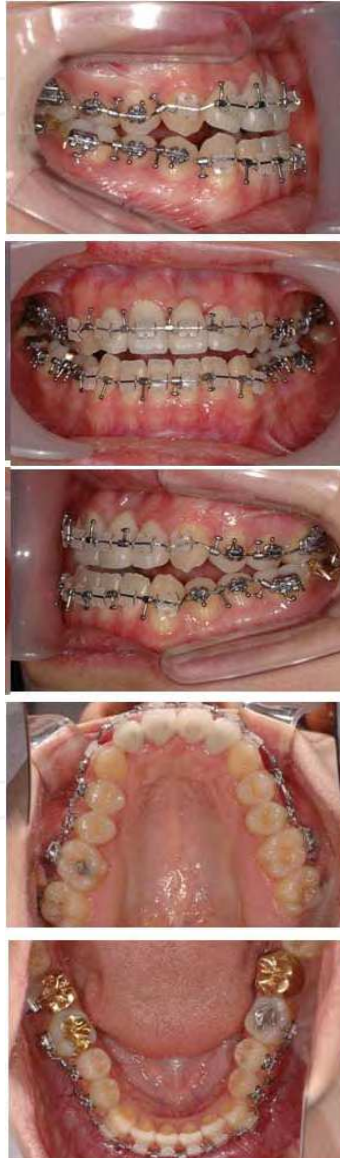

Fig. 20. Placement of passive stainless steel wires prior to surgery.

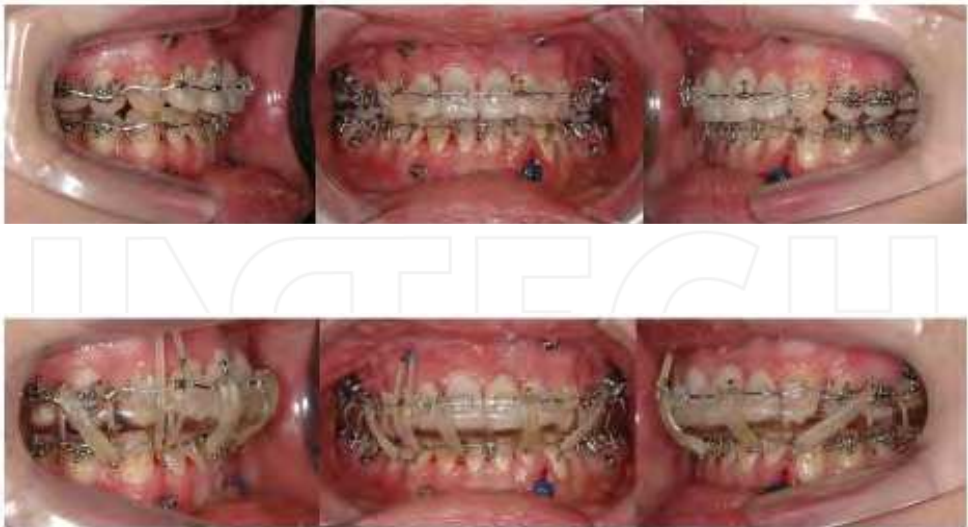
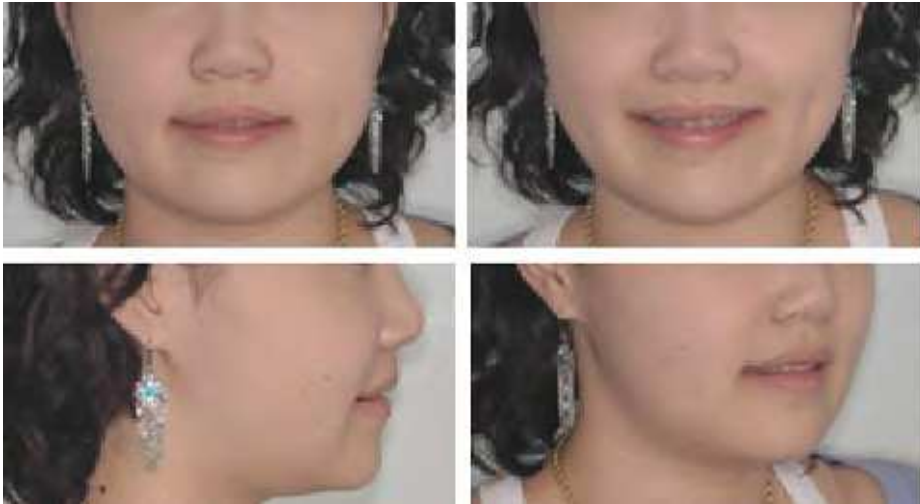
Fig. 21. Progress Records.

Case was finished in nineteen months with acceptable occlusion and facial aesthetics achieved. Figure 22 shows the final records.

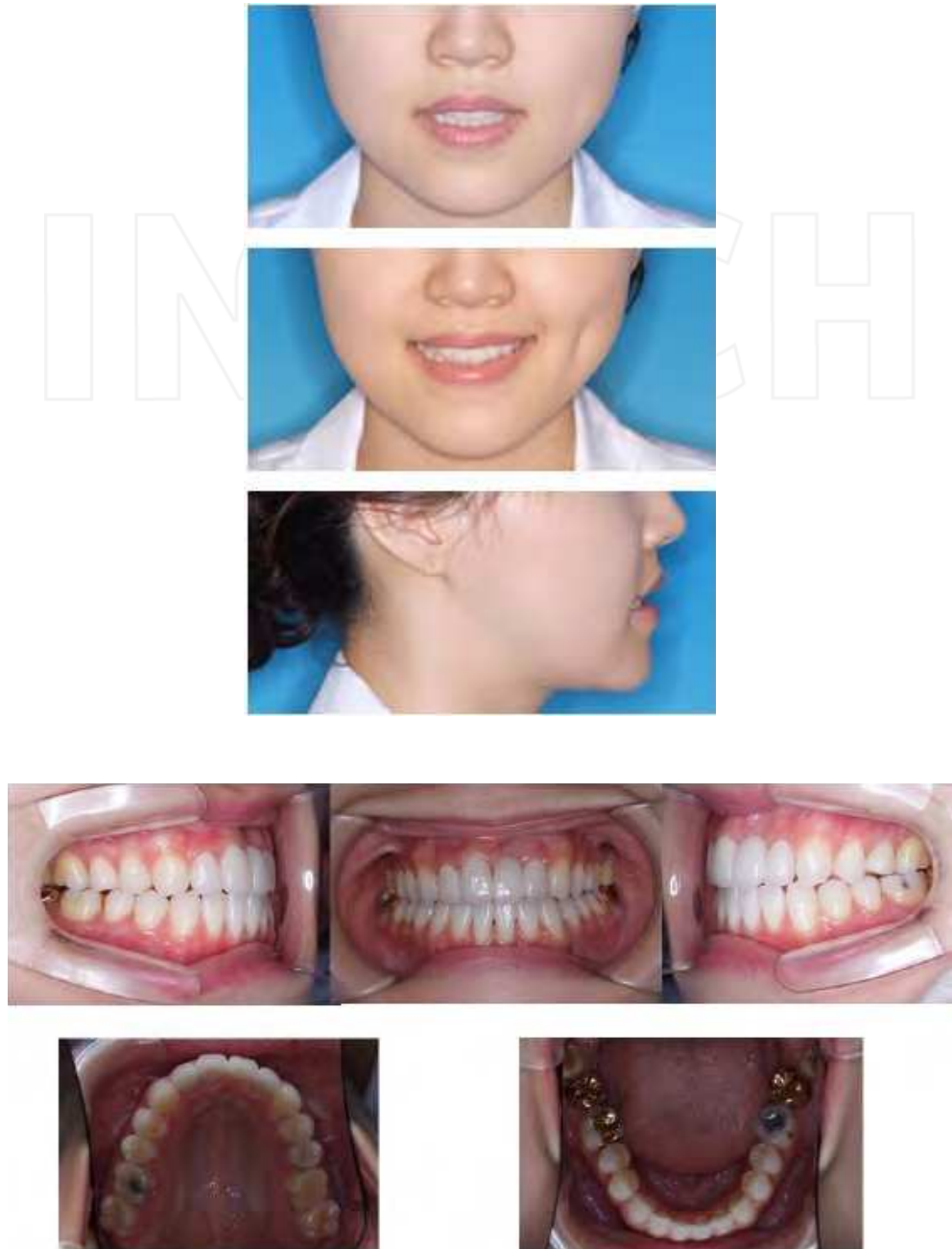

Fig. 22. Final Records.

The use of temporary anchorage devices becomes more crucial in more complicated cases that are attempted with the surgery first approach. When extractions or segmented osteotomies are planned, prediction of the final occlusion is far more challenging and placement of mini-implants during the surgery allows for efficient mechanics post- surgically. Figure 23 shows the initial presentation of a female patient who was treatment planned for three-piece maxillary osteotomy and mandibular set-back procedures due to a severe transverse discrepancy between the upper and lower jaws and excessive proclination of upper incisors.

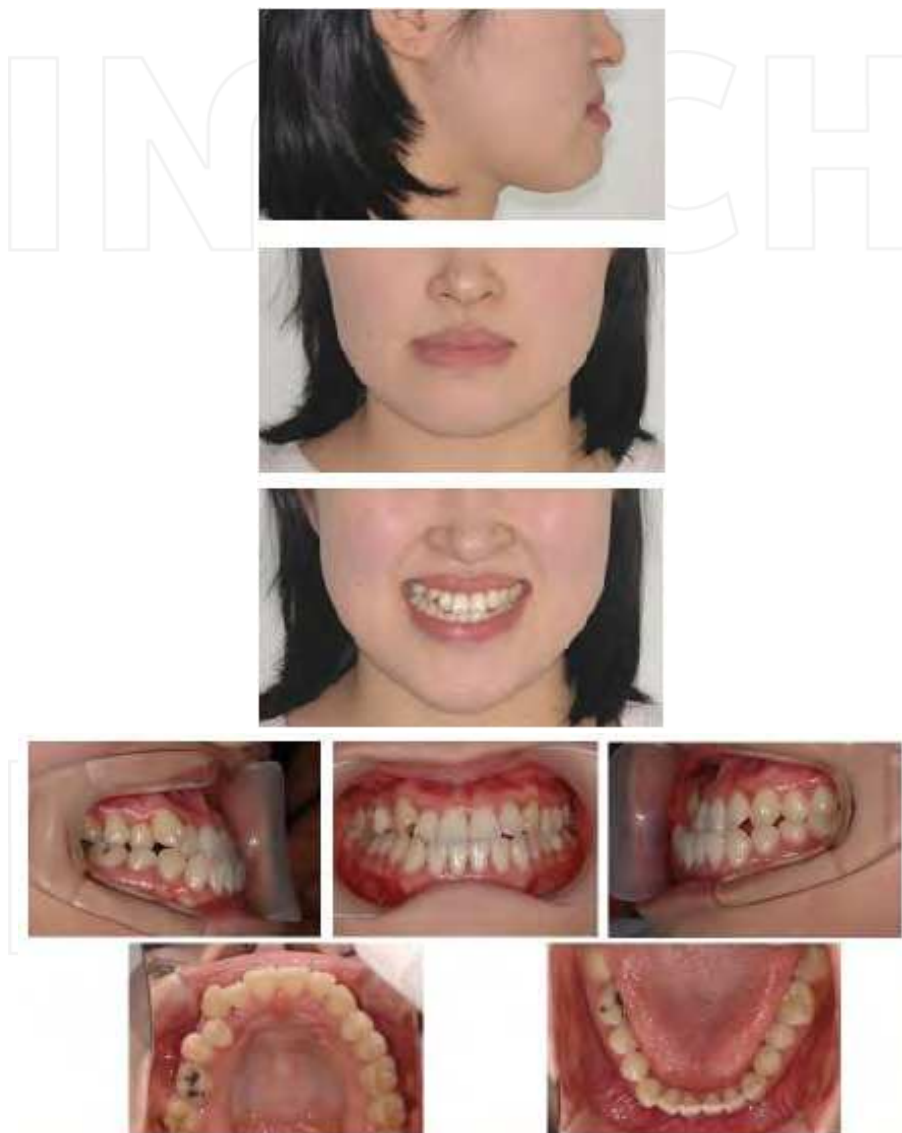

Fig. 23. Initial Records.



Upper first premolars were extracted during the surgical procedure and at the same time eight mini-implants were placed. Figure 24 shows the progress of the case immediately after surgery and in weeks that followed.

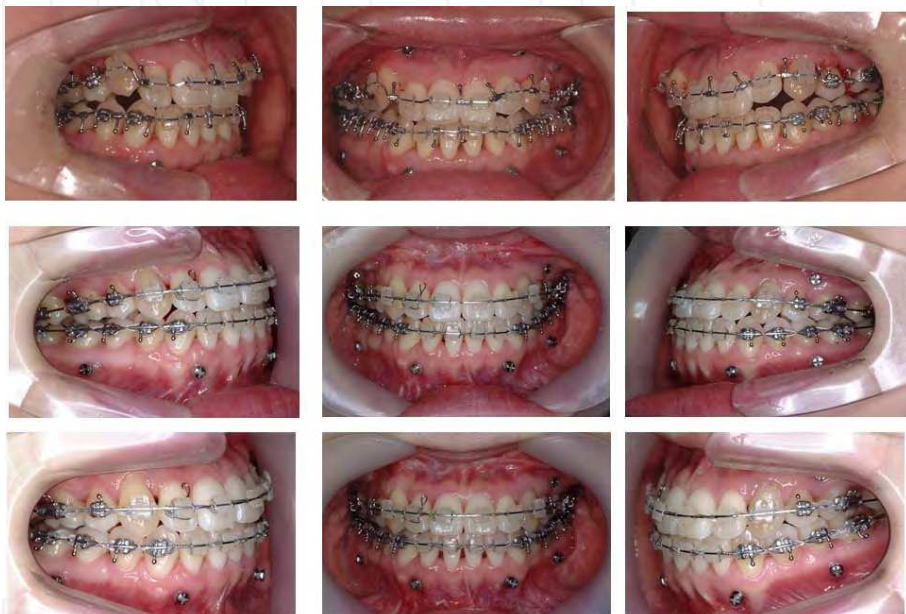


Fig. 24. Progress Records.

The case was finished in nineteen months and the patient was very pleased with the results. Figure 25 illustrates the final records of the patient at the time of appliance removal. Considering the complexity of the case, the treatment time was significantly reduced. However, the upper left canine showed discoloration as treatment continued possibly indicating necrosis as a result of the segmental osteotomy procedure.

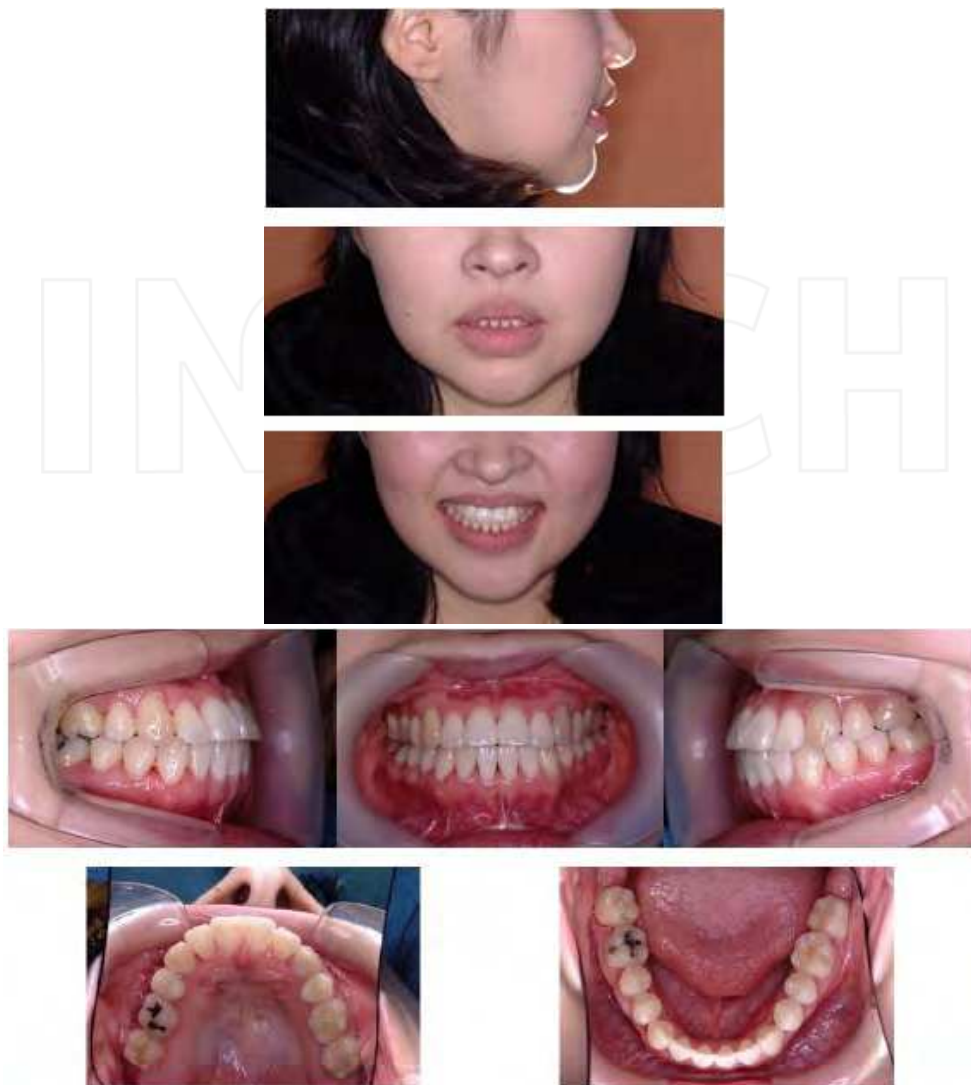

Fig. 25. Final Records.

## 5. Disadvantages and potential problems

Performing the surgical procedure prior to orthodontic treatment has multiple advantages, particularly the shortened treatment time. However, there are many drawbacks to this approach which should be taken into consideration.

Predicting the final occlusion is the hardest challenge with surgery first approach. In many cases, the upper and lower models cannot be placed in an ideal occlusion due to multiple dental interferences. If the predicted final occlusion is not achievable or is not planned



accurately, the result will be far from ideal. Cases requiring extractions are especially very difficult to plan when performing surgery first. Thus, case selection is of utmost importance.

Even when the final occlusion has been determined carefully by the orthodontist, the surgical procedure must be performed meticulously since any minor surgical error can compromise the result. Hence, the treating orthodontist and orthognathic surgeon must be experienced enough to be able to know the limitations and possibilities.

The planning process is very time consuming in contrast to the total treatment time which is usually shortened. This becomes a financial issue for the treating orthodontist in many cases. Increasing the treatment fee is one solution but it should be reasonable to the patient.

When passive stainless steel wires are placed prior to surgery each wire must be bent to rest passively on the surface of each tooth. This is also another challenging and time consuming procedure for the orthodontist especially when teeth are severely rotated and misaligned. To simplify the pre-surgical bonding procedure, some orthodontists bond the wires directly to the surface of teeth without using any brackets. Even though this can simplify the pre-surgical appointment, the authors note that there is a higher failure rate during surgery and the need for another bonding appointment at the initiation of orthodontic treatment. Indirect bonding technique can be utilized to allow for accurate bracket positioning as well as bending the passive arch wires beforehand.

To utilize the maximum potential of the regional acceleratory phenomenon, two jaw surgeries are preferred. Also, severe transverse discrepancies sometimes lead to two-piece or three-piece Le Fort I osteotomies. The increase in the number and complexity of osteotomy procedures poses a greater risk to the patient.

## **6. A look into the future of “Surgery First” approach**

Despite the many challenges associated with performing the orthognathic surgery prior to decompensation of the arches, the basics of this approach can be incorporated into treatment planning other surgical cases to reduce the pre-surgical treatment time. Careful treatment planning and prioritizing the steps that are absolutely necessary prior to the surgical procedure while leaving other steps until the surgery is performed can speed up the process. In doing so, the patient will be able to have the surgery sooner than the traditional approach and the orthodontist will be able to use the rapid acceleratory phenomenon when it is needed the most.

Figure 26 shows the initial presentation of a patient who presented with severe skeletal Class III malocclusion and anterior open bite. The upper incisors were proclined and the lower incisors were severely retroclined. The lower right lateral incisor was lingually blocked out and the lower arch was constricted with lingually tipped teeth.

The complexity of the case called for starting the orthodontic treatment before performing surgery. However, during the treatment planning process the emphasis was placed on doing minimal orthodontic preparation for surgery to reduce the time spent in pre-surgical orthodontics. The decompensation process in this case would have otherwise taken a very long time if the conventional approach was utilized.

One month after placement of brackets on the upper arch, a lower Schwartz expansion appliance was used to expand the lower arch and upright the lower posterior segments. The

expansion screw was activated two times per week. Figure 27 shows the progress of the case at 1 month, 2 months, and 6 months after the initiation of orthodontic treatment.

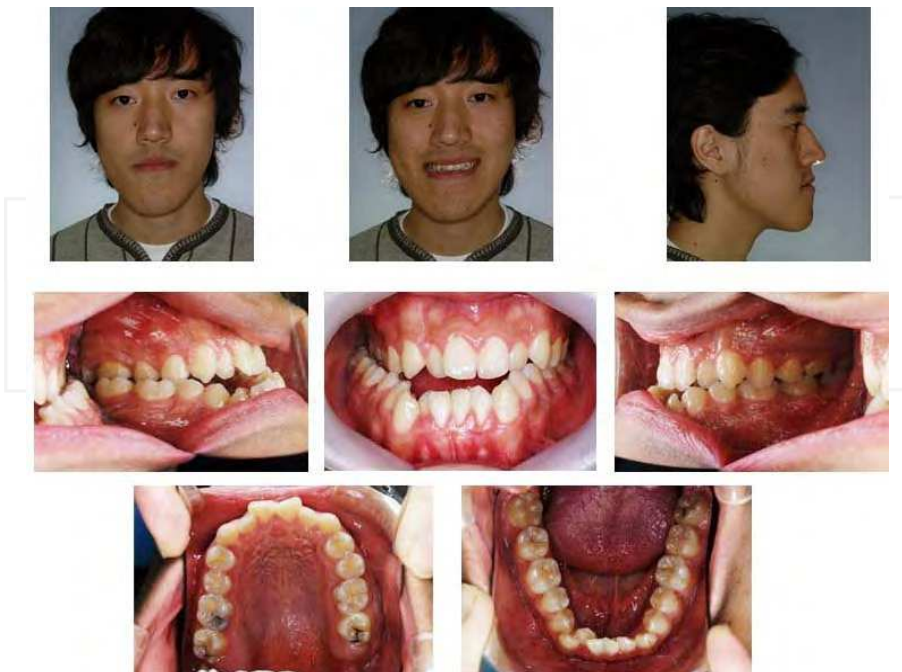


Fig. 26. Initial Records.

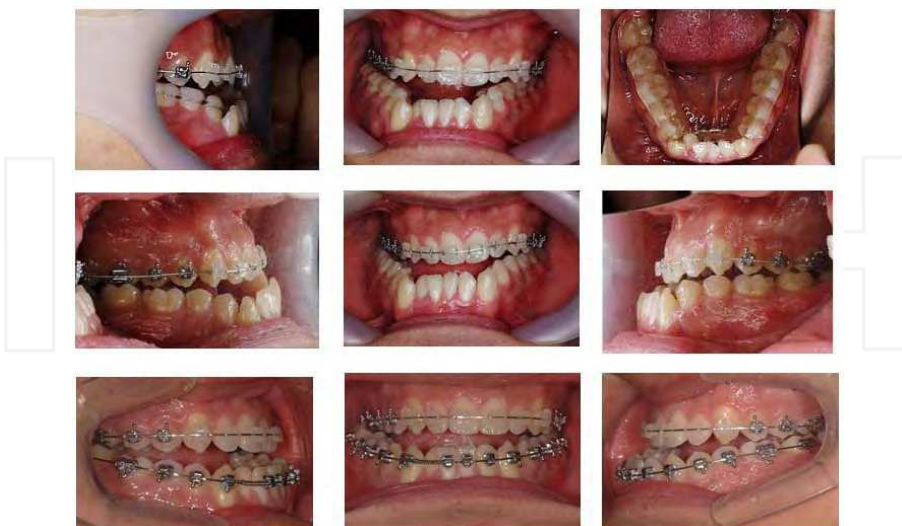

Fig. 27. Progress Records.

The upper right second molar required a significant amount of buccal root torque in preparation of surgery. A temporary anchorage device was placed palatally between the upper right first and second molars and a power chain was used from the screw to achieve ideal torque. After eight months of orthodontic preparation, the case was ready for orthognathic surgery. Note that the alignment of the arches was not complete but the model surgery performed at this point indicated that the surgical procedure could be performed and the remainder of orthodontic tooth movements could be finished after surgery utilizing the regional acceleratory phenomenon. Figure 28 shows the model surgery and the intraoral pictures at the time of placement of passive archwires for surgery.

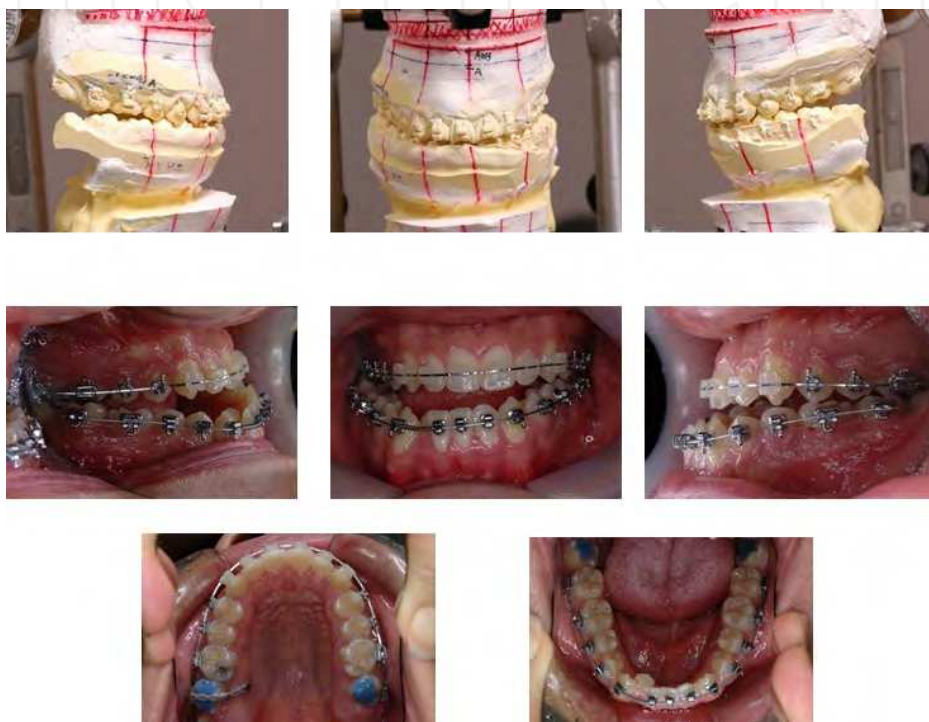


Fig. 28. Model surgery and records right before surgery.

After the operation was performed, the leveling, alignment, and the decompensation were completed in one year. Figure 29 shows the progress of the case immediately after, one month, four months, and twelve months after surgery. Note the use of temporary anchorage devices post-surgically.

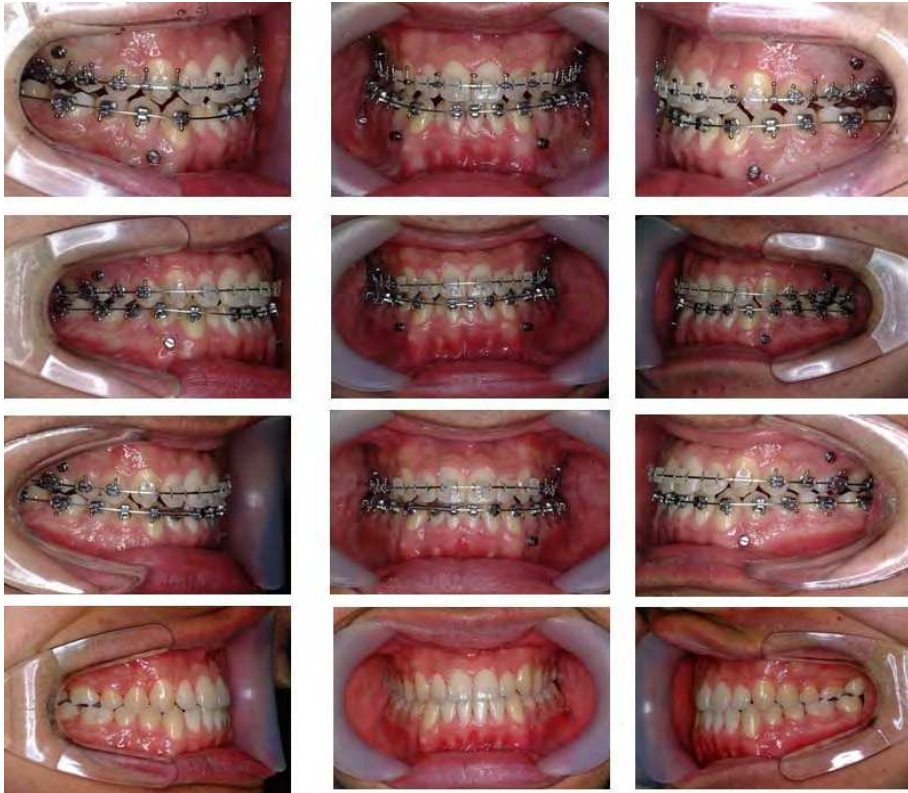


Fig. 29. Progress records A) immediately after, B) one month C) four months D) twelve months after surgery.

The case was debonded after a total treatment time of 22 months which included 8 months of presurgical orthodontics. Figure 30 shows the final records of the patient at the time of appliance removal.



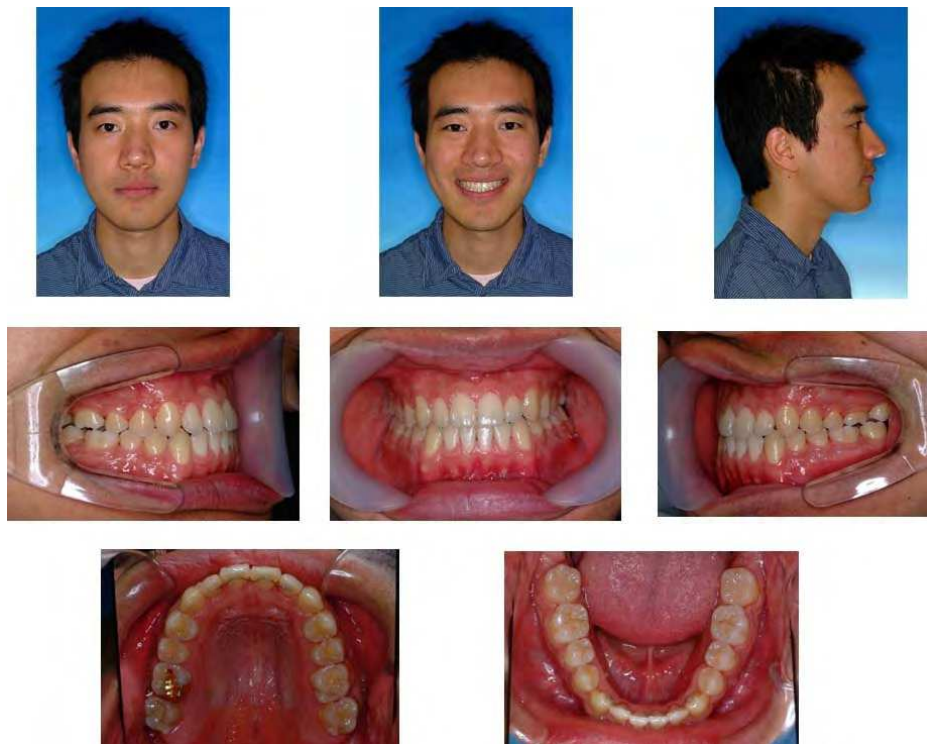


Fig. 30. Final Records.

This case illustrates that the surgery first approach concepts can be modified to fit the specific needs of the patient. The main principle to keep in mind is not to spend countless months to achieve the absolute ideal presurgical decompensation and leveling. The surgical procedure should be performed as soon as the occlusion allows for a stable post-surgical transitional occlusion. Once again, the experience of the orthodontist and the surgeon are extremely important in treating these cases.

## 7. Conclusion

Performing orthognathic surgery before orthodontic treatment has multiple advantages including but not limited to shortened treatment time, increased patient acceptance, and the utilization of the regional acceleratory phenomenon. If the cases are selected carefully, the orthodontist and the surgeon are experienced enough to predict the final occlusion beforehand, and the level of cooperation between the clinicians is high, the results are very promising. However, even the slightest error during the treatment planning, surgical, and post-surgical orthodontic steps can be very difficult to correct. By utilizing the principles of surgery first technique, the pre-surgical orthodontics period can be shortened even if it is not eliminated. As with any other surgical procedure, the patient's well-being and chief complaint should always be the first priority. The future of orthognathic surgery is geared toward minimizing the overall treatment time without compromising the final results.

## 8. Acknowledgments

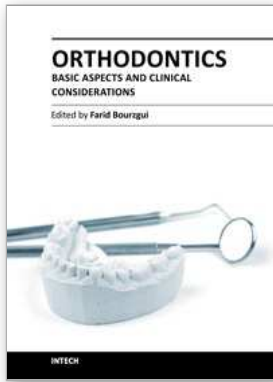
Jeong Kim thanks Dr. Sang H. Park for his collaboration and Dr. Barry Grayson for guidance.

## 9. References

- Aziz, S.R. (2004). Simon P. Hullahen and the Origin of Orthognathic Surgery. *Journal of Oral and Maxillofacial Surgery*, Vol.62, No.10, (October, 2004), pp. 1303-1307, ISSN 0278-2391
- Baek, S.H.; Ahn, H.W.; Kwon, Y.H. & Choi, J.Y. (2010). Surgery First Approach in Skeletal Class III Malocclusion Treated with 2-Jaw Surgery: Evaluation of Surgical Movement and Postoperative Orthodontic Treatment. *Journal of Craniofacial Surgery*, Vol.21, No.3, (March, 2010), pp. 332-338, ISSN 1049-2275
- Brachvogel, P.; Berten, J.L. & Hausamen, J.E. (1991). Surgery before orthodontic treatment: a concept for timing the combined therapy of skeletal dysgnathias. *Deutsche Zahn-, Mund-, und Kieferheilkunde mit Zentralblatt*, Vol.79, No.7, (July, 1991), pp. 557-563, ISSN 0940-855X
- Frost, H.M. (1983). The Regional Acceleratory Phenomenon: a Review. *Henry Ford Hospital Medical Journal*, Vol.31, No.1, (January, 1983), pp. 3-9, ISSN 0018-0416
- Iliopoulos, C.; Zouloumis, L. & Lazaridou, M. (2010). Physiology of Bone Turnover and Its Application in Contemporary Maxillofacial Surgery. A review, *Hippokratia*, Vol.14, No.4, (October-December, 2010), pp. 244-248, ISSN 1108-4189
- Justus, T.; Chang, B.I.; Bloomquist, D. & Ramsay D.S. (2001). Human Gingival and Pulpal Blood Flow During Healing After Le Fort I Osteotomy. *Journal of Oral and Maxillofacial Surgery* Vol. 59, No.1, (January, 2001), pp. 2-7, ISSN 0278-2391
- Ko, E.W.; Hsu, S.S.; Hsieh, H.Y.; Wang, Y.C.; Huang, C.S. & Chen YR. (2011). Comparison of Progressive Cephalometric Changes and Postsurgical Stability of Skeletal Class III Correction With and Without Presurgical Orthodontic Treatment, *Journal of Oral and Maxillofacial Surgery*, Vol.69, No.5, (May, 2011), pp. 1469-1477, ISSN 0278-2391
- Kondo E. & Aoba, T.J. (2000). Nonsurgical and Nonextraction Treatment of Skeletal Class III Open Bite: Its Long-Term Stability. *American Journal of Orthodontics and Dentofacial Orthopedics*, Vol.117, No.3, (March, 2000), pp. 267-287, ISSN 0889-5406
- Kondo E. & Arai, S. (2005). Nonsurgical and Nonextraction Treatment of a Skeletal Class III Adult Patient with Severe Prognathic Mandible. *World Journal of Orthodontics*, Vol.6, No.3, (Fall, 2005), pp. 233-247, ISSN 2160-2999
- Lee, R.T. (1994). The Benefits of Post-Surgical Orthodontic Treatment. *British Journal of Orthodontics*, Vol.21, No.3, (August, 1994), pp. 265-274, ISSN 0301-228X
- Liao, Y.F.; Chiu, Y.T.; Huang, C.S.; Ko, E.W. & Chen, Y.R. (2010). Presurgical Orthodontics Versus No Presurgical Orthodontics: Treatment Outcome of Surgical Orthodontic Correction For Skeletal Class III Open Bite, *Plastic and Reconstructive Surgery*, Vol.126, No.6, (December 2010), pp. 2074-2083, ISSN 0032-1052
- Liou, E.J.; Chen, P.H.; Wang, Y.C.; Yu, C.C.; Huang, C.S. & Chen, Y.R. (2011). Surgery-First Accelerated Orthognathic Surgery: Orthodontic Guidelines and Setup For Model Surgery, *Journal of Oral and Maxillofacial Surgery*, Vol.69, No.3, (March, 2011), pp. 771-780, ISSN 0278-2391

- Liou, E.J.; Chen, P.H.; Wang, Y.C.; Yu, C.C.; Huang, C.S. & Chen, Y.R. (2011). Surgery-First Accelerated Orthognathic Surgery: Postoperative Rapid Orthodontic Tooth Movement, *Journal of Oral and Maxillofacial Surgery*, Vol.69, No.3, (March, 2011), pp. 781-785, ISSN 0278-2391
- Luther, F.; Morris, D.O. & Hart, C. (2003). Orthodontic Preparation for Orthognathic Surgery: How Long Does It Take and Why? A Retrospective Study. *British Journal of Oral and Maxillofacial Surgery*, Vol.41, No.6, (December, 2003), pp. 401-406, ISSN 0266-4356
- Nagasaka, H.; Sugawara, J.; Kawamura, H. & Nanda, R. (2009). "Surgery First" Skeletal Class III Correction Using the Skeletal Anchorage System. *Journal of Clinical Orthodontics*, Vol.43, No.2, (February, 2009), pp. 97-105, ISSN 0022-3875
- O'Brien, K.; Wright, J.; Conboy, F.; Appelbe, P.; Bearn, D.; Caldwell, S.; Harrison, J.; Hussain, J.; Lewis, D.; Littlewood, S.; Mandall, N.; Morris, T.; Murray, A.; Oskouei, M.; Rudge, S.; Sandler, J.; Thiruvengkatachari, B.; Walsh, T. & Turbill, E. (2009). Prospective, Multi-Center Study of the Effectiveness of Orthodontic/Orthognathic Surgery Care in the United Kingdom, *American Journal of Orthodontics and Dentofacial Orthopedics*, Vol.135, No.6, (June, 2009), pp. 709-714, ISSN 0889-5406
- Park, S.; Hyon, W.L.; Lee, J.G.; Lee, S.; Lee, Y. & Shin, S. (2011). Increasing Efficiency and Improving Patient Compliance/Affordability/Orthognathic Surgery With Surgery First Orthognathic Approach (SFOA) . Abstract from *Proceedings of the 3<sup>rd</sup> William H. Bell Lectureship Symposium, "Accelerated Orthognathic Surgery and Increased Orthodontic Efficiency,"* March 18-20, 2011, Houston, Texas
- Sugawara, J.; Aymach, Z.; Nagasaka, D.H.; Kawamura, H. & Nanda, R. (2010). "Surgery First" Orthognathics to Correct a Skeletal Class II Malocclusion with an Impinging Bite. *Journal of Clinical Orthodontics*, Vol.44, No.7, (July, 2010), pp. 429-438, ISSN 0022-3875
- Tsuroda, H. & Miyamoto, Y. (2003). None or Minimum Pre-operative Orthodontic Treatment for Orthognathic Surgery in Answer to Patient's Request of Immediate Facial Aspect Change. *Journal of Japan Society of Aesthetic Plastic Surgery*, Vol.25, No.2, (February, 2003), pp. 79-86, ISSN 0288-2027
- Villegas, C.; Uribe, F.; Sugawara, J. & Nanda, R. (2010). Expedited Correction of Significant Dentofacial Asymmetry Using a "Surgery First" Approach. *Journal of Clinical Orthodontics*, Vol.44, No.2, (February, 2010), pp. 97-103, ISSN 0022-3875
- Wilcko, W.M.; Wilcko, T.; Bouquot, J.E. & Ferguson, D.J. (2001) Rapid Orthodontics With Alveolar Reshaping: Two Case Reports of Decrowding. *International Journal of Periodontics & Restorative Dentistry*, Vol.21, No.1, (February, 2001), pp. 9-19, ISSN 0198-7569
- Wilcko, M.T.; Wilcko, W.M.; Pulver, J.J.; Bissada, N.F. & Bouquot, J.E. (2009) Accelerated Osteogenic Orthodontics Technique: a 1-Stage Surgically Facilitated Rapid Orthodontic Technique With Alveolar Augmentation. *Journal of Oral Maxillofacial Surgery*, Vol.67, No.10, (October, 2009), pp.2149-2159, ISSN 0278-2391
- Yu, C.C.; Chen, P.H.; Liou, E.J.; Huang, C.S. & Chen, Y.R. (2010). A Surgery-First Approach in Surgical-Orthodontic Treatment of Mandibular Prognathism – A Case Report, *Chang Gung Medical Journal*, Vol.33, No.6, (November-December, 2010), pp. 699-705, ISSN 2072-0939





## **Orthodontics - Basic Aspects and Clinical Considerations**

Edited by Prof. Farid Bourzgui

ISBN 978-953-51-0143-7

Hard cover, 446 pages

**Publisher** InTech

**Published online** 09, March, 2012

**Published in print edition** March, 2012

The book reflects the ideas of nineteen academic and research experts from different countries. The different sections of this book deal with epidemiological and preventive concepts, a demystification of cranio-mandibular dysfunction, clinical considerations and risk assessment of orthodontic treatment. It provides an overview of the state-of-the-art, outlines the experts' knowledge and their efforts to provide readers with quality content explaining new directions and emerging trends in Orthodontics. The book should be of great value to both orthodontic practitioners and to students in orthodontics, who will find learning resources in connection with their fields of study. This will help them acquire valid knowledge and excellent clinical skills.

### **How to reference**

In order to correctly reference this scholarly work, feel free to copy and paste the following:

Jeong Hwan Kim, Niloufar Nouri Mahdavia and Carla A. Evans (2012). Guidelines for "Surgery First" Orthodontic Treatment, Orthodontics - Basic Aspects and Clinical Considerations, Prof. Farid Bourzgui (Ed.), ISBN: 978-953-51-0143-7, InTech, Available from: <http://www.intechopen.com/books/orthodontics-basic-aspects-and-clinical-considerations/orthodontic-guidelines-for-the-surgery-first-treatment-of-severe-malocclusions>

**INTECH**  
open science | open minds

### **InTech Europe**

University Campus STeP Ri  
Slavka Krautzeka 83/A  
51000 Rijeka, Croatia  
Phone: +385 (51) 770 447  
Fax: +385 (51) 686 166  
[www.intechopen.com](http://www.intechopen.com)

### **InTech China**

Unit 405, Office Block, Hotel Equatorial Shanghai  
No.65, Yan An Road (West), Shanghai, 200040, China  
中国上海市延安西路65号上海国际贵都大饭店办公楼405单元  
Phone: +86-21-62489820  
Fax: +86-21-62489821