

---

# Cleft Lip and Palate Surgery

---

Koroush Taheri Talesh and  
Mohammad Hosein Kalantar Motamedi

Additional information is available at the end of the chapter

<http://dx.doi.org/10.5772/55147>

---

## 1. Introduction

The treatment of cleft lip and palate deformities requires thoughtful consideration of the anatomic complexities of the deformity and the delicate balance between intervention and growth. Comprehensive and coordinated care from infancy through adolescence is essential in order to achieve an ideal outcome, and surgeons with formal training and experience in all of the phases of care must be actively involved in the planning and treatment. Specific goals of surgical care for children born with cleft lip and palate include the following:

- Normalized esthetics of the lip and nose
- Intact primary and secondary palate
- Normal speech, language, and hearing
- Nasal airway patency
- Class I occlusion with normal masticatory function
- Good dental and periodontal health
- Normal psychosocial development

Successful management of the child born with a cleft lip and palate requires coordinated care provided by a number of different specialties including oral/maxillofacial surgery, otolaryngology, genetics, speech pathology, orthodontics, prosthodontics, and others. In most cases care of patients with congenital clefts has become a subspecialty area of clinical practice within these different professions. In addition to surgery for cleft repair, treatment plans routinely involve multiple treatment interventions to achieve the above-stated goals. Because care is provided over the entire course of the child's development, long-term follow-up is critical

under the care of these different health care providers. The formation of interdisciplinary cleft palate teams has served two key objectives of successful cleft care: [1] coordinated care provided by all of the necessary disciplines, and [2] continuity of care with close interval follow-up of the patient throughout periods of active growth and ongoing stages of reconstruction. The best outcomes are achieved when the team's care is centered on the patient, family, and community rather than a particular surgeon, specialty, or hospital. The idea of having an objective team that does not revolve around the desires of one particular individual or discipline is sometimes impeded by competitive interactions between surgical specialties. Historic battles over surgical domains between surgical specialties and economic factors contribute to these conflicts and negatively affect the work of the team. Healthy team dynamic and optimal patient care are achieved when all members are active participants, when team protocols and referral patterns are equitable and based on the surgeons' formal training and experience instead of specialty identity, and when the needs of the child are placed above the needs of the team. [1-3]

## 2. Prevalence and classification

The occurrence of oral clefts in the United States has been estimated as 1 in 700 births.<sup>1</sup> Clefts exhibit interesting racial predilections, occurring less frequently in blacks but more so in Asians. Boys are affected by orofacial clefts more often than girls, by a ratio of 3:2. Cleft lip and palate (together) occurs about twice as often in boys as in girls, whereas isolated clefts of the palate (without cleft lip) occur slightly more often in girls. Oral clefts commonly affect the lip, alveolar ridge, and hard and soft palates. Three fourths are unilateral deformities; one fourth are bilateral. The left side is involved more frequently than the right when the defect is unilateral. The cleft may be incomplete, that is, it may not extend the entire distance from lip to soft palate. cleft palate may occur without clefting of the lip. A useful classification divides the anatomy into primary and secondary palates. The primary palate involves those structures anterior to the incisive foramen—the lip and alveolus; the secondary palate consists of those structures posterior to the incisive foramen—the hard and soft palates. Thus an individual may have clefting of the primary palate, the secondary palate, or both. Clefts of the lip may range from a minute notch on the edge of the vermilion border to a wide cleft that extends into the nasal cavity and thus divides the nasal floor. Clefts of the soft palate may also show wide variations from a bifid uvula to a wide inoperable cleft. The bifid uvula is the most minor form of cleft palate, in which only the uvula is clefted. Submucosal clefts of the soft palate are occasionally seen. These clefts are also called occult clefts, because they are not readily seen on cursory examination. The defect in such a cleft is a lack of continuity in the musculature of the soft palate. However, the nasal and oral mucosa is continuous and covers the muscular defect. To diagnose such a defect, the dentist inspects the soft palate while the patient says "ah". This action lifts the soft palate, and in individuals with submucosal palatal clefts, a furrow in the midline is seen where the muscular discontinuity is present. The dentist can also palpate the posterior aspect of the hard palate to detect the absence of the posterior nasal spine, which

is characteristically absent in submucosal clefts. If a patient shows hypernasal speech without an obvious soft palatal cleft, the dentist should suspect a submucosal cleft of the soft palate.[4]

### 3. Embryology

From an anatomic standpoint the cleft surgeon must have an appreciation for the failure of embryogenesis that results in clefting. There are critical points in the development of the fetus when the fusion of various prominences creates continuity and form to the lip, nose, and palate. Anomalies occur when the normal developmental process is disturbed between these components. Each of these prominences is made up of ectomesenchyme derived from neural crest tissue of the mesencephalon and rhombencephalon. Mesoderm is also present within these prominences as mesenchymal tissue. The prescribed destiny of each of these cells and tissues is controlled by various genes to alter the migration, development, and apoptosis and form the normal facial tissues of the fetus. At the molecular level there are many interdependent factors such as signal transduction, mechanical stress, and growth factor production that affect the development of these tissues. Currently only portions of this complex interplay of growth, development, and apoptosis are clear. At approximately 6 weeks of human embryologic development the median nasal prominence fuses with the lateral nasal prominences and maxillary prominences to form the base of the nose, nostrils, and upper lip. The confluence of these anterior components becomes the primary palate. When this mechanism fails, clefts of the lips and/or maxilla occur. At approximately 8 weeks the palatal shelves elevate and fuse with the septum to form the intact secondary palate. When one palatal shelf fails to fuse with the other components, then a unilateral cleft of the secondary palate occurs. If both of the palatal shelves fail to fuse with each other and the midline septum, then a bilateral cleft of the palate occurs. Fusion occurs when programmed cell death (apoptosis) occurs at the edges of the palatal shelves. The ectodermal component disintegrates and the mesenchyme fuses to form the intact palate. Soon after this the anterior primary palate fuses with the secondary palate and ossification occurs. At any point, if failure of fusion occurs with any of the above components, a cleft will occur of the primary and/or secondary palates. Clefts may be complete or incomplete based on the degree of this failure of fusion.[5-7]

### 4. Treatment of cleft lip and palate

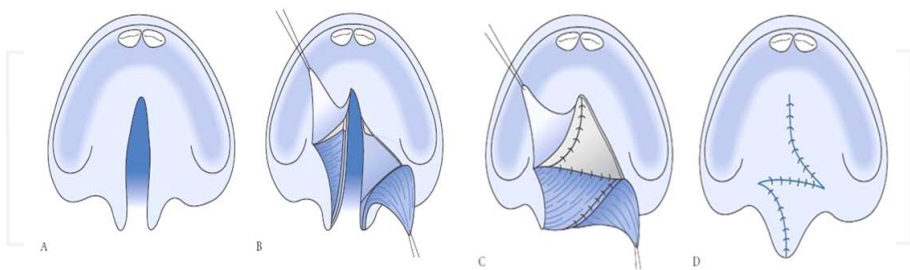
The aim of treatment of cleft lip and palate is to correct the cleft and associated problems surgically and thus hide the anomaly so that patients can lead normal lives. This correction involves surgically producing a face that does not attract attention, a vocal apparatus that permits intelligible speech, and a dentition that allows optimal function and esthetics. Operations begin early in life and may continue for several years. In view of the gross distortion of tissues surrounding the cleft, it is amazing that success is ever achieved. However, with modern anesthetic techniques, excellent pediatric care centers, and surgeons who have had a

wealth of experience because of the frequency of the cleft deformity, acceptable results are commonplace.[3]

## 5. Timing of surgical repair

The timing of the surgical repair has been and remains one of the most debated issues among surgeons, speech pathologists, audiologists, and orthodontists. It is tempting to correct all of the defects as soon as the baby is able to withstand the surgical procedure. The parents of a child born with a facial cleft would certainly desire this mode of treatment, eliminating all of the baby's clefts as early in life as possible. Indeed the cleft lip is usually corrected as early as possible. Most surgeons adhere to the proven "rule of 10" as determining when an otherwise healthy baby is fit for surgery (i.e., 10 weeks of age, 10 lb in body weight, and at least 10 g of hemoglobin per deciliter of blood). However, because surgical correction of the cleft is an elective procedure, if any other medical condition jeopardizes the health of the baby, the cleft surgery is postponed until medical risks are minimal.[8]

Although different cleft teams time the surgical repair differently, a widely accepted principle is compromise. The lip is corrected as early as is medically possible. The soft palatal cleft is closed between 8 and 18 months of age, depending upon a host of factors. Closure of the lip as early as possible is advantageous, because it performs a favorable "molding" action on the distorted alveolus. It also assists the child in feeding and is of psychologic benefit. The palatal cleft is closed next, to produce a functional velopharyngeal mechanism when or before speech skills are developing. The hard palatal cleft is occasionally not repaired at the time of soft palate repair, especially if the cleft is wide. In such cases, the hard palate cleft is left open as long as possible so that maxillary growth will proceed as unimpeded as possible (Fig. 1). [8]



**Figure 1.** A, Cleft of the secondary palate (both hard and soft) from the incisive foramen to the uvula. B, Furlow double-opposing Z-plasty technique; Z-plasty flaps developed on the oral and then nasal side. Note the cutbacks creating the nasal side flaps highlighted in blue. C, The flaps are then transposed to lengthen the soft palate. A nasal side closure is completed in the standard fashion anterior to the junction of the hard and soft palate. Generally this junction is the highest area of tension and can be difficult to close. This contributes to the higher fistula rate in this type of repair. D, The oral side flaps are then transposed and closed in a similar fashion completing the palate closure.

Closure of the hard palatal cleft can be postponed at least until all of the deciduous dentition has erupted. This postponement facilitates the use of orthodontic appliances and allows more maxillary growth to occur before scarring from the surgery is induced. Because a significant portion of maxillary growth has already occurred by ages 4 to 5, closure of the hard palate at this time is usually performed before the child's enrollment in school. Removable palatal obturators can be fitted and worn in the meantime to partition the oral and nasal cavities (Table 1).[8]

<b>Staged Reconstruction of Cleft Lip and Palate Deformities</b>	
<i>Procedure</i>	<i>Timing</i>
Cleft lip repair	After 10 weeks
Cleft palate repair	9–18 months
Pharyngeal flap or pharyngoplasty	3–5 years or later based on speech development
Maxillary/alveolar reconstruction with bone grafting	6–9 years based on dental development
Cleft orthognathic surgery	14–16 years in girls, 16–18 years in boys
Cleft rhinoplasty	After age 5 years but preferably at skeletal maturity; after orthognathic surgery when possible
Cleft lip revision	Anytime once initial remodeling and scar maturation is complete but best performed after age 5 years

**Table 1.** Staged reconstruction of cleft lip and palate deformities

## 6. Cleft lip and palate repair

### 6.1. Presurgical taping and presurgical orthopedics

Facial taping with elastic devices is used for application of selective external pressure and may allow for improvement of lip and nasal position prior to the lip repair procedure. In the authors' opinions these techniques often have greater impact in cases of wide bilateral cleft lip and palate where manipulation of the premaxillary segment may make primary repair technically easier. Although one of the basic surgical tenets of wound repair is to close wounds under minimal tension, attempts at improving the arrangement of the segments using taping methods have not shown a measurable improvement. Some surgeons prefer presurgical orthopedic (PSO) appliances rather than lip taping to achieve the same goals. PSO appliances are composed of a custom-made acrylic base plate that provides improved anchorage in the molding of lip, nasal, and alveolar structures during the presurgical phase of treatment. PSOs also add significant cost and time to treatment early in the child's life. Many appliances require a general anesthetic for the initial impression used to fabricate the device. Frequent appoint-

ments are necessary for monitoring of the anatomic changes and periodic appliance adjustment.[9-12]

## 7. Cheilorrhaphy

Cheilorrhaphy is the surgical correction of the cleft lip deformity. The cleft of the upper lip disrupts the important circumoral orbicularis oris musculature. The lack of continuity of this muscle allows the developing parts of the maxilla to grow in an uncoordinated manner so that the cleft in the alveolus is accentuated. At birth the alveolar process on the unaffected side may appear to protrude from the mouth. The lack of sphincteric muscle control from the orbicularis oris will cause a bilateral cleft lip to exhibit a premaxilla that protrudes from the base of the nose and produces an unsightly appearance. Thus restoration of this muscular sphincter with lip repair has a favorable effect on the developing alveolar segments.[8]

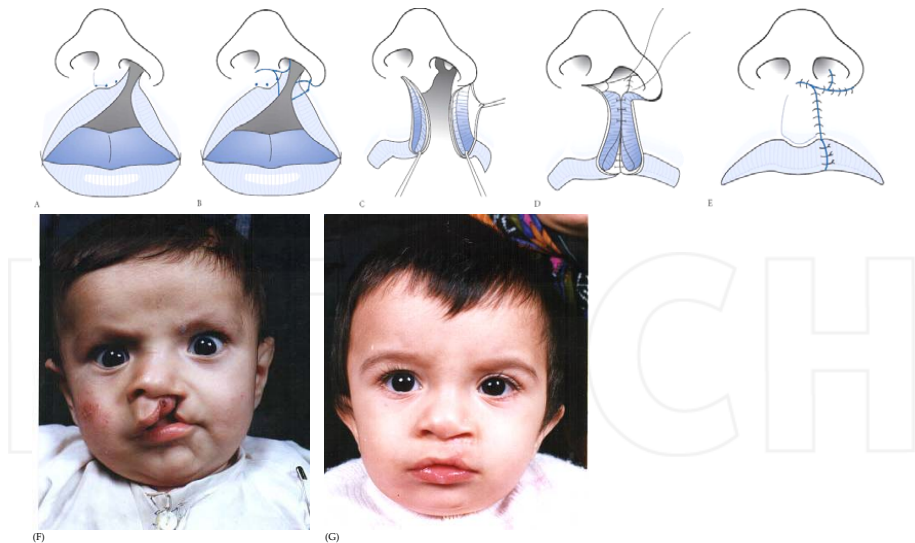
## 8. Unilateral cleft lip repair

Clefts of the lip and nose that are unilateral present with a high degree of variability, and thus each repair design is unique. The basic premise of the repair is to create a three-layered closure of skin, muscle, and mucosa that approximates normal tissue and excises hypoplastic tissue at the cleft margins. Critical in the process is the reconstruction of the orbicularis oris musculature into a continuous sphincter. The Millard rotation-advancement technique has the advantage of allowing for each of the incision lines to fall within the natural contours of the lip and nose. This is an advantage because it is difficult to achieve "mirror image" symmetry in the unilateral cleft lip and nose with the normal side immediately adjacent to the surgical site. A Z-plasty technique such as the Randall-Tennison repair may not achieve this level of symmetry because the Z-shaped scar is directly adjacent to the linear non-clefted philtrum. Achieving symmetry is more difficult when the rotation portion of the cleft is short in comparison to the advancement segment. Primary nasal reconstruction may be considered at the time of lip repair to reposition the displaced lower lateral cartilages and alar tissues. Several techniques are advocated, and considerable variation exists with respect to the exact nasal reconstruction performed by each surgeon. The primary nasal repair may be achieved by releasing the alar base, augmenting the area with allogeneic subdermal grafts, or even a formal open rhinoplasty (Fig. 2).[13-15]

## 9. Bilateral lip repair

Bilateral cleft lip repair can be one of the most challenging technical procedures performed in children with clefts. The lack of quality tissue present and the widely displaced segments are major challenges to achieving exceptional results, but superior technique and adequate

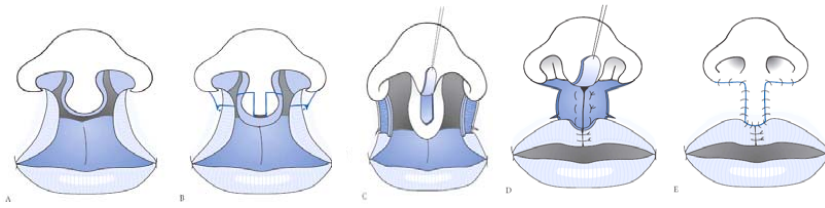




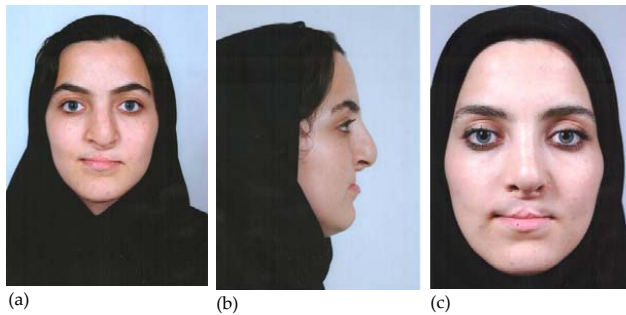
**Figure 2.** A, Complete unilateral cleft of the lip highlighting the hypoplastic tissue in the cleft site that is not used in the reconstruction. Nasal deformities are typical in the unilateral cleft, including displaced lower lateral nasal cartilages, deviated anterior septum, and nasal floor clefting. B, The typical markings for the authors' preferred repair are shown highlighting the need to excise the hypoplastic tissue and approximate good vermilion and white roll tissue for the repair. C, Once the hypoplastic tissue has been excised, the three layers of tissue are dissected (skin, muscle, and mucosa). It is important to completely free the orbicularis oris from its abnormal insertions on the anterior nasal spine area and lateral alar base. Nasal flaps are also incorporated into the dissection to repair the nasal floor (not shown). D, The orbicularis oris muscle is approximated with multiple interrupted sutures, and the vermilion border/white roll complex is reconstructed. The nasal floor and mucosal flaps are approximated. E, The lateral flap is advanced and the medial segment is rotated downward to create a healing scarline that will resemble the natural philtral column on the opposite side. The incision lines are hidden in natural contours and folds of the nose and lip. F, Four month-old boy with complete unilateral cleft lip and severe step maxillary segment. G, Lip closure was done by Millard II technique.

mobilization of the tissue flaps usually yields excellent esthetic results. Additionally the columella may be quite short in length, and the premaxillary segment may be significantly rotated. Adequate mobilization of the segments and attention to the details of only using appropriately developed tissue will yield excellent results even in the face of significant asymmetry. Some surgeons have used aggressive techniques to surgically lengthen the columella and preserve hypoplastic tissue using banked fork flaps. Early and aggressive tissue flaps in the nostril and columella areas do not look natural after significant growth has occurred and result in abnormal tissue contours. While surgical attempts at lengthening the columella may look good initially, they frequently look abnormally long and excessively angular later in life (Fig. 3).[16]

In severe cleft lip with protruded premaxilla early closure of the cleft and aligning of orbicularis oris muscle and return of lip sphinctric function ultimately cause setbacking of the premaxilla reducing the alveolar cleft gap and step and facilitate anterior palate and alveolar cleft repair (Fig. 4).



**Figure 3.** A, Complete bilateral cleft of the lip and maxilla showing hypoplastic tissue along the cleft edges. The importance of the nasal deformity is evident in the shorter columella and disrupted nasal complexes. B, Markings of the authors' preferred repair are shown with emphasis on excision of hypoplastic tissue and approximating more normal tissue with the advancement flaps. C, A new philtrum is created by excising the lateral hypoplastic tissue and elevating the philtrum superiorly. Additionally the lateral advancement flaps are dissected into three distinct layers (skin, muscle, and mucosa). Nasal floor reconstruction is also performed. D, The orbicularis oris musculature is approximated in the midline with multiple interrupted and/or mattress sutures. This is critical in the total reconstruction of the functional lip. There is no musculature present in the premaxillary segment, and this must be brought to the midline from each lateral advancement flap. The nasal floor flaps are sutured at this time as well. The new vermillion border is reconstructed in the midline with good white-roll tissue advanced from the lateral flaps. E, Final approximation of the skin and mucosal tissues is performed leaving the healing incision lines in natural contours of the lip and nose.



**Figure 4.** A, 20 year-old girl with severe bilateral cleft lip and alveolar cleft with protruded premaxilla. B, After early closure of cleft lip with Veau's technique the protruded premaxilla was corrected. C, After closed Rhinoplasty and columella lengthening.

## 10. Palatorrhaphy

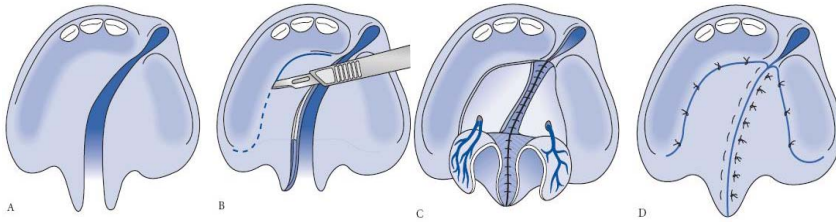
Palatorrhaphy is usually performed in one operation, but occasionally it is performed in two. In two operation the soft palate closure is usually performed first and the hard palate closure is performed second. The primary purpose of the cleft palate repair is to create a mechanism capable of speech and deglutition without significantly interfering with subsequent maxillary growth. Thus creation of a competent velopharyngeal mechanism and partitioning of the nasal and oral cavities are prerequisites to achieving these goals. The aim is to obtain a long and mobile soft palate capable of producing normal speech. Extensive stripping of soft tissues from bone will create more scar formation. The exact timing of repair of a palate cleft is controversial.



Generally the velum must be closed prior to the development of speech sounds that require an intact palate. On average this level of speech production is observed by about 18 months of age in the normally developing child. If the repair is completed after this time, compensatory speech articulations may result. Repair completed prior to this time allows for the intact velum to close effectively, appropriately separating the nasopharynx from the oropharynx during certain speech sounds. When repair of the palate is performed between 9 and 18 months of age, the incidence of associated growth restriction affecting the maxillary development is approximately 25%. If repair is carried out earlier than 9 months of age, then severe growth restriction requiring future orthognathic surgery is seen with greater frequency. At the same time proceeding with palatoplasty prior to 9 months of age is not associated with any increased benefit in terms of speech development so the result is an increase in growth related problems with an absence of any functional benefit. Using only the chronologic age it seems that carrying out the operation during the 9 to 18 months timeline best balances the need to address functional concerns such as speech development with the potential negative impact on growth. Many techniques have been described for repair of the palate. The Bardach two-flap palatoplasty uses two large full-thickness flaps that are mobilized with layered dissection and brought to the midline for closure. This technique preserves the palatal neurovascular bundle as well as a lateral pedicle for adequate blood supply. The von Langenbeck technique is similar to the Bardach palatoplasty but preserves an anterior pedicle for increased blood supply to the flaps. This technique is also successful in achieving a layered closure but may be more difficult when suturing the nasal mucosa near the anteriorly based pedicle attachments. The authors do not favor push-back techniques as they may incur more palatal scarring, restrict growth, and do not show a measurable benefit in speech. Another common technique is the Furlow double-opposing Z plasty, which attempts to lengthen the palate by taking advantage of a Z-plasty technique on both the nasal mucosa and the oral mucosa. This technique can be effective at closing the palate but has been reported by some to have a higher rate of fistula formation at the junction of the soft and hard palates where theoretical lengthening of the soft palate may compromise the closure (Fig 5). [17-19]

## 11. Alveolar cleft grafts

The alveolar cleft defect is usually not corrected in the original surgical correction of either the cleft lip or the cleft palate. As a result, the cleft-afflicted individual may have residual oronasal fistulae in this area, and the maxillary alveolus will not be continuous because of the cleft. Because of this, five problems commonly occur: [1] oral fluids escape into the nasal cavity, [2] nasal secretion drains into the oral cavity, [3] teeth erupt into the alveolar cleft, [4] the alveolar segments collapse, and [5] if the cleft is large, speech is adversely affected. Alveolar cleft bone grafts provide several advantages: First, they unite the alveolar segments and help prevent collapse and constriction of the dental arch, which is especially important if the maxilla has been orthodontically expanded. Second, alveolar cleft bone grafts provide bone support for teeth adjacent to the cleft and for those that will erupt into the area of the cleft. Frequently, the bone support on the distal aspect of the central incisor is thin, and the height of the bone support



**Figure 5.** A, Unilateral cleft of the primary and secondary palates with typical involvement from the anterior vestibule to the uvula. B, Bardach palatoplasty technique requires two large full-thickness mucoperiosteal flaps to be elevated from each palate shelf. The anterior portion (anterior to the incisive foramen) of the cleft is not reconstructed until the mixed dentition stage. C, A layered closure is performed in the Bardach palatoplasty by reapproximating the nasal mucosa. The muscle bellies of the levator palatini are elevated off of their abnormal insertions on the posterior palate. They are then reapproximated in the midline to create a dynamic functional sling for speech purposes. D, Once the nasal mucosa and musculature of the soft palate are approximated, the oral mucosa is closed in the midline. The lateral releasing incisions are quite easily closed primarily due to the length gained from the depth of the palate. In rare cases, in very wide clefts a portion of the lateral incisions may remain open and granulate by secondary intention.

varies. These teeth may show slight mobility because of this lack of bone support. Increasing the amount of alveolar bone for this tooth will help ensure its periodontal maintenance. The canine tends to erupt into the Cleft site and, with healthy bone placed into the cleft will maintain good periodontal support during eruption and thereafter. The third benefit of alveolar cleft grafts is closure of the oronasal fistula, which will partition the oral and nasal cavities and prevent escape of fluids between them.[20]

Cleft management should always involve a multidisciplinary team, with the expertise to develop a proper treatment plan. Difficulties may arise when the priorities of one specialty compete with those of another. If the surgical team is faced with an orthodontic provider who feels strongly that it is appropriate to align the maxillary central incisors as soon as they erupt, it will be necessary for the alveolar defect to be grafted earlier to prevent compromise of osseous support for the central incisors. Some orthodontists and surgeons believe that palatal expansion is necessary prior to grafting. These teams may find that it is more appropriate to graft patients at a later age, as it may take months to achieve the desired expansion prior to the graft.

## 12. Source of bone graft

The selection of the ideal grafting material is somewhat dependent on the timing of the graft. In primary bone grafting, the rib is the only site for adequate quantity of bone with acceptable morbidity. In the mixed dentition stage, the rib is not as appropriate as other sites such as the calvaria or iliac crest. These options would also be possible sources for bone for late secondary grafting, as well as grafts from the mandibular symphysis and possibly the tibia.

### **13. Iliac crest**

Potential advantages of the iliac crest bone graft include low morbidity and high volume of viable osteoblastic cells (cancellous bone); two teams may work simultaneously, and this procedure is well accepted by the patient.

### **14. Allogeneic bone and bone substitutes**

In an effort to eliminate the morbidity and time necessary to harvest bone from any autogenous site, some authors have evaluated allogeneic bone as a potential source of graft material. Studies have shown that allogeneic bone can be used successfully to graft secondary alveolar cleft defects and that results can be compared favorably with those achieved with autogenous bone. However, the demands of bone healing in the alveolar defect where there is potential communication between the graft and the nasal and oral cavity may make this less predictable in large cleft defects or bilateral clefts. In general, bone healing with autogenous bone is biologically different than with allogeneic bone. Autogenous bone grafts initiate an angioblastic response early in the healing process, and some of the transplanted cells remain viable, resulting in a more rapid formation of new bone. In contrast, allogeneic bone grafts demonstrate slower revascularization, as there are no viable cells transferred with the graft. In summary, autogenous bone harvested from the iliac crest remains the most predictable technique.[21]

### **15. Surgical technique for grafting the cleft alveolus**

The ideal technique will meet the following criteria:

1. Predictable closure of the nasal floor produces a watertight barrier between the graft and the nasal cavity
2. Access to closure of residual palatal and labial fistula
3. Keratinized attached tissue is maintained around the teeth adjacent to the cleft and at the site where the yet unerupted lateral incisor and canine will erupt
4. Mobilization of tissue is adequate to close large defects without tension, when such defects are present
5. The vestibule is not shortened, and scarring is not excessive

Given these requirements, the technique most often used employs advancing buccal gingival and palatal flaps. This approach has some disadvantages, including the following:

1. Difficulty obtaining closure in large bilateral clefts, which heal by secondary intention of full-thickness wounds created by the advancement

2. A four-corner suture line that approximates the flaps directly overlying the graft, which may lead to dehiscence
3. The possibility that elevating large full thickness mucoperiosteal flaps leads to growth alteration in young patients. However, when compared with finger flaps and trapezoidal flaps, which can shorten the vestibule and placenonkeratinized tissue around the dentition, this approach remains the best.[21]

In our center we prefer harvesting bone graft orally from the symphysis or anterior border of ramus without changing patient position because of easy access and the rate of success is comparable to other methods.

## Author details

Koroush Taheri Talesh<sup>1</sup> and Mohammad Hosein Kalantar Motamedi<sup>2</sup>

1 Oral and Maxillofacial Surgery Tabriz University of Medical Sciences and Azad University of Medical Sciences, Tehran, Iran

2 Oral and Maxillofacial Surgery Baqiyatallah University of Medical Sciences Trauma Research Center, Tehran, Iran

## References

- [1] Costello, B. J, Ruiz, R. L, & Turvey, T. Surgical management of velopharyngeal insufficiency in the cleft patient. In: Oral and maxillofacial surgery clinics of North America: secondary cleft surgery. Philadelphia (PA): W.B. Saunders; (2002). , 539-551.
- [2] Ruiz, R. L, Costello, B. J, & Turvey, T. Orthognathic surgery in the cleft patient. In: Ogle O, editor. Oral and maxillofacial surgery clinics of North America: secondary cleft surgery. Philadelphia (PA): W.B. Saunders; (2002). , 491-507.
- [3] Costello, B. J, Shand, J, & Ruiz, R. L. Craniofacial and orthognathic surgery in the growing patient. Selected Readings Oral Maxillofacial Surg (2003). , 11(5), 1-20.
- [4] Tolarova, M. M, & Cervenka, J. Classification and birth prevalence of orofacial clefts. Am J Med Genet (1998). , 75, 126-37.
- [5] Tolarova, M. Etiology of clefts of lip and/or palate: 23 years of genetic follow-up in 3660 individual cases. In: Pfeifer G, editor. Craniofacial abnormalities and clefts of the lip, alveolus, and palate. Stuttgart: Thieme; (1991). , 16-23.

- [6] Gorlin, R, Cohen, M. J, & Levin, L. Syndromes of the head and neck. 4th ed. New York (NY):Oxford University Press; (2003). orofacial clefting. Cleft lip and palate: a physiological approach, *Oral Maxillofac Clin North Am* 2000;; 12, 379-97.
- [7] Shaikh, D, Mercer, N. S, Sohan, K, et al. Prenatal diagnosis of cleft lip and palate. *Br J PlastSurg* (2001). , 54, 288-9.
- [8] Posnick, J. C. The staging of cleft lip and palate reconstruction: infancy through adolescence.In: Posnick JC, editor. *Craniofacial and maxillofacial surgery in children and young adults*. Philadelphia (PA):W.B. Saunders;(2000). , 785-826.
- [9] Poole, R, & Farnworth, T. K. Preoperative lip taping in the cleft lip. *Ann Plast Surg* (1994). , 32, 243-9.
- [10] Shaw, W. C, & Semb, G. Current approaches to the orthodontic management of cleft lip and palate. *J R Soc Med* (1990). , 83, 30-3.
- [11] Ross, R. B. MacNamera MC. Effect of presurgical infant orthopedics on facial esthetics in complete bilateral cleft lip and palate. *Cleft Palate Craniofac J* (1994). , 31, 68-73.
- [12] Grayson, B. H, Santiago, P. E, Brecht, L. E, et al. Presurgical nasoalveolar molding in infants with cleft lip and palate. *Cleft Palate Craniofac J* (1999). , 36, 486-98.
- [13] Randall, P. Long-term results with the triangular flap technique for unilateral cleft lip repair. In: Bardach J, Morris H, editors. *Multidisciplinary management of cleft lip and palate*. Philadelphia (PA): W.B. Saunders;(1990). , 173.
- [14] Millard, D. R. Cleft craft: the evolution of its surgery. *Alveolar and palatal deformities*. Boston (MA): Little Brown; (1980). , 3
- [15] Posnick, J. C. Cleft-orthognathic surgery: the unilateral cleft lip and palate deformity. In:Posnick JC, editor. *Craniofacial and maxillofacial surgery in children and young adults*. Philadelphia (PA): W.B. Saunders;(2000). , 860-907.
- [16] Posnick, J. C. Cleft-orthognathic surgery: the bilateral cleft lip and palate deformity. In: Posnick JC, editor. *Craniofacial and maxillofacial surgery in children and young adults*. Philadelphia (PA): W.B. Saunders;(2000). , 908-950.
- [17] Posnick, J. C. Cleft-orthognathic surgery: the isolated palate deformity. In:Posnick JC, editor. *Craniofacial and maxillofacial surgery in children and young adults*. Philadelphia (PA): W.B. Saunders; (2000). , 951-978.
- [18] Posnick, J. C, & Tompson, B. Cleft-orthognathic surgery. Complications and long-term results. *Plast Reconstr Surg* (1995).
- [19] Dorf, D. S, & Curtin, J. W. Early cleft palate repair and speech outcome: a ten year experience. In: Bardach J,Morris HL.*Multidisciplinary management of cleft lip and palate*.Philadelphia (PA): W.B. Saunders; (1990). , 341-348.

- [20] Sindet-pedersen, S, & Enemark, H. Reconstruction of alveolar clefts with mandibular or iliac crest bone graft: a comparative study. *JOral Maxillofac Surg* (1990). , 48, 554-8.
- [21] Sadove, A. M, Nelson, C. L, Eppley, B. L, et al. An evaluation of calvarial and iliac donor sites in alveolar cleft grafting. *Cleft Palate J* (1990). , 27, 225-8.

INTECH

INTECH