
AIDS/HIV Associated Lesions and Management

Candidiasis: pseudomembranous, erythematous, angular cheilitis, candida leukoplakia

Kaposi's sarcoma

Oral hairy leukoplakia

Linear gingival erythema

HIV periodontitis

Necrotizing ulcerative gingivitis

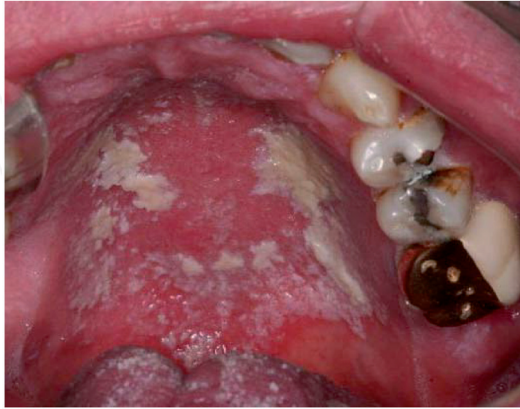Major aphthae

Infection with the human immunodeficiency virus (HIV) is now a well-recognized chronic disease that leads to severe immunosuppression and acquired immunodeficiency syndrome (AIDS). Since the early days when the disease was first recognized, one of the common complications secondary to the immunosuppression was the presence of a variety of oral lesions and conditions that required constant care. Patients had an increased load of circulating viruses and their lymphocytes, characterized by the phenotype CD4, were being destroyed by the virus and presented in the peripheral blood in very low numbers. With the advent of a combination of antiviral drugs called highly active antiretrovirus therapy or HAART, it became possible to partially restore immunocompetence by decreasing the viral load and increasing the number of circulating CD4 cells. With this advance in therapy, common oral lesions observed in this patient population became more difficult to find, as long as the patients were responding well to HAART. However, there are still many infected individuals who have not yet been diagnosed with HIV and individuals who fail HAART who could develop oral lesions. Therefore, it is very important that the clinician be aware of some of the common oral complications of HIV infection and AIDS. Following we will describe some common oral complications of HIV infection and AIDS.

1. Pseudomembranous candidiasis

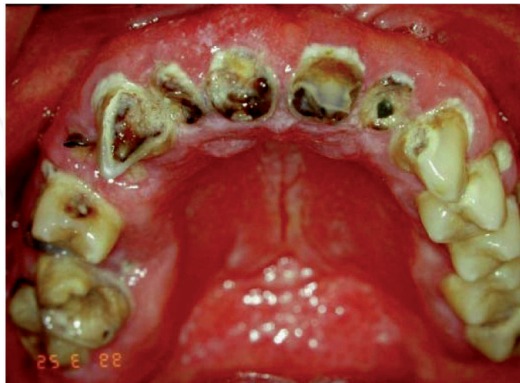The patient in the photograph presented with white plaques of candida organisms on the palate. These areas can be scraped off with gauze and may leave an erythematous surface underneath. Patients may complain of burning, discomfort, lack of taste and difficulty in

swallowing if the infection migrates to the oropharynx. Symptoms may be the same in all forms of candidiasis.



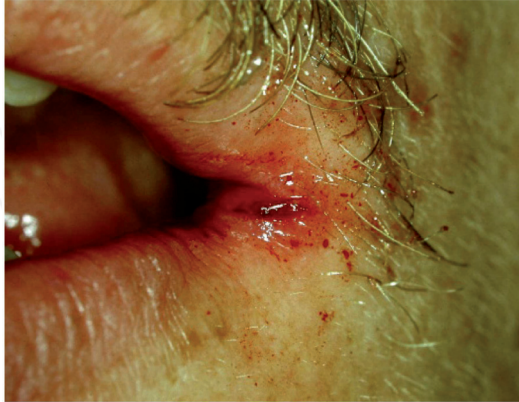2. Erythematous candidiasis

Note the areas of erythema generalized over the oral mucous membranes.



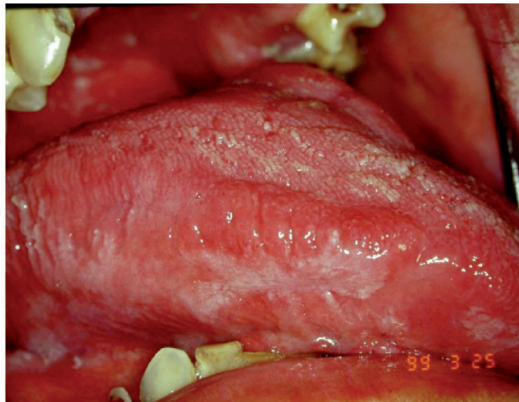3. Angular cheilitis

Note the cracking of the lip commissure with bleeding as a result of the patient opening the mouth.



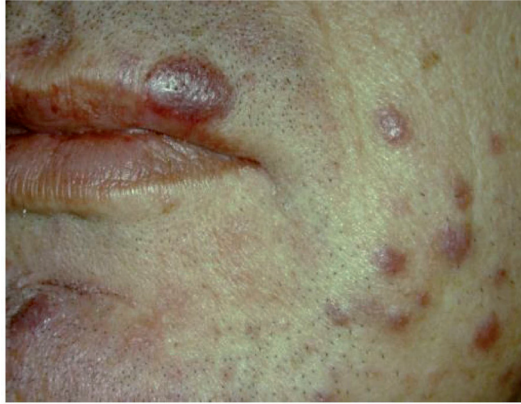4. Candidal leukoplakia

Note the white plaque on the lateral border of the tongue. This lesion cannot be removed by scraping because the candida organisms are intra-epithelial and the infection is causing the growth of the keratin layer.



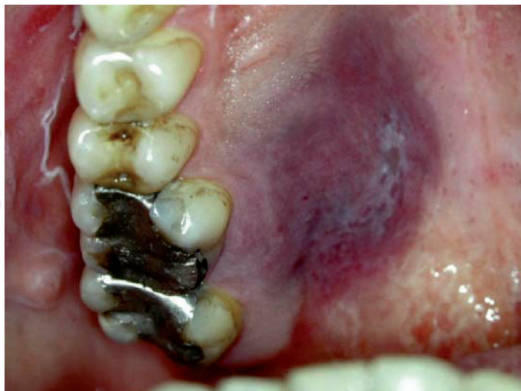5. Kaposi's sarcoma (KS)

Note the multiple purple macules on the patient's face representing individual lesions of KS. The lesions are asymptomatic, but represent a serious cosmetic problem for the patient. Today we know that this tumor is associated with a herpes type of virus, the Human Herpes Virus type 8 (HHV-8) that can infect the entire body of the patient if not treated.



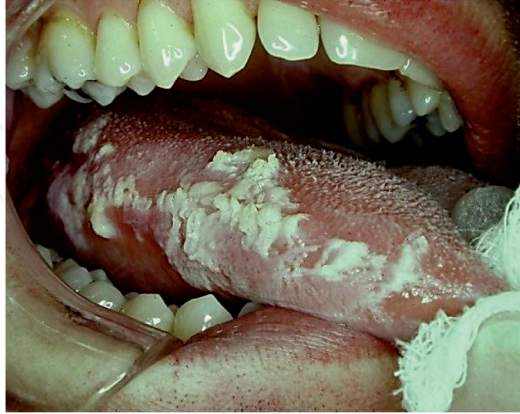
6. Kaposi's sarcoma of the palate

Notice the purple/bluish lesion on the hard palate. This lesion is asymptomatic and can acquire an exophytic growth pattern if not treated.



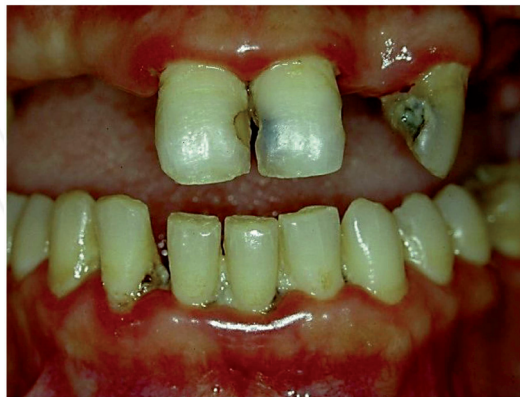7. Oral hairy leukoplakia

Note the white lesion with a corrugated surface that does not scrape off and is associated with the Epstein Barr Virus. It is asymptomatic.



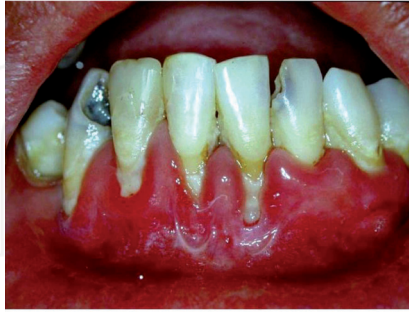8. Linear gingival erythema

Note the linear erythema along the marginal gingival border. This clinical change is associated with the microbial flora of the periodontium, including *C.albicans*, in the HIV infected patient. It is asymptomatic.



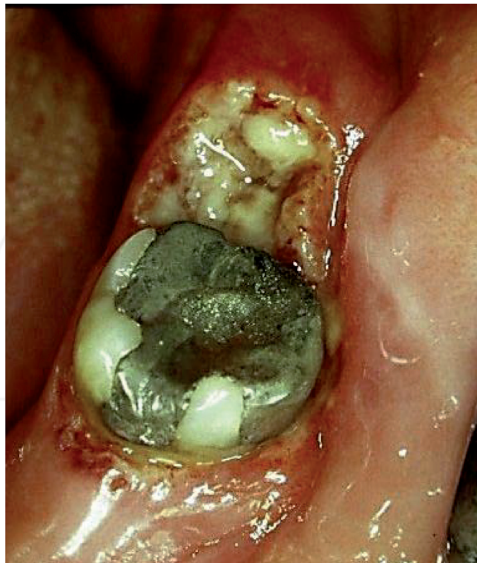9. HIV periodontitis

Note severe periodontal destruction and inflammation associated with severe immunosuppression in an individual infected with HIV.



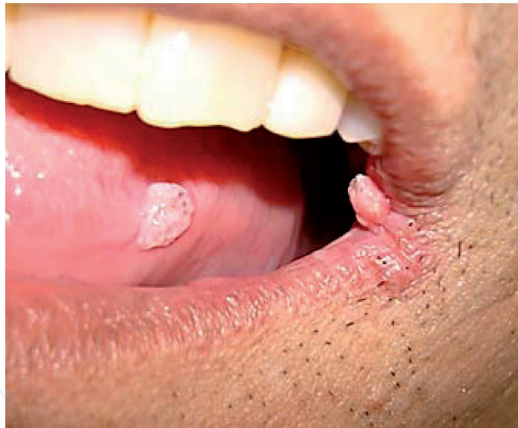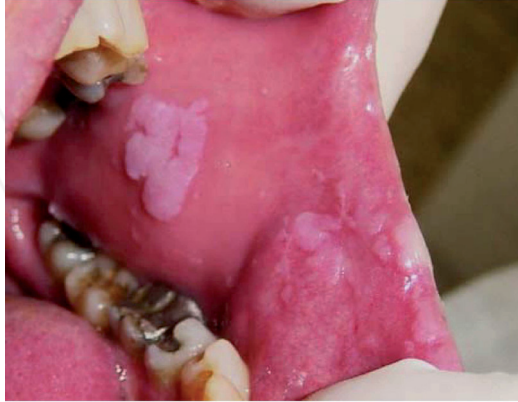10. Necrotizing ulcerative gingivitis

Note the severe and painful ulceration on the retromolar pad, extending to the marginal gingiva around the molar. Such lesions may be associated with many different bacterial microorganisms and require local debridment and topical and systemic antibiotics.



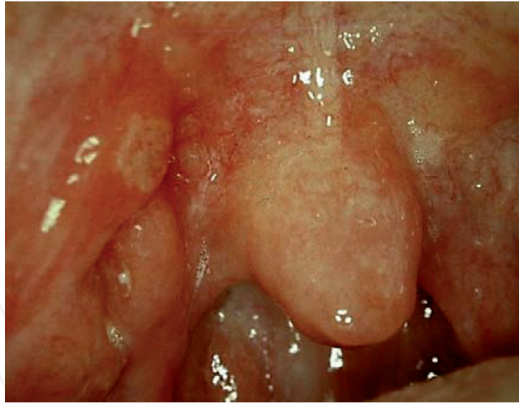
11. Condyloma acuminatum

Note the different clinical presentations of condylomas associated with the Human Papilloma Virus (HPV). These lesions are sexually transmitted and associated with HPV types 6 and 11. Although asymptomatic, they require surgical excision and have a high recurrence rate.



12. Major aphthae

Individuals infected with HIV may develop aphthous-like lesions in the oral mucosa. Some may be of the major type, being over 1 cm in diameter. These lesions are very painful and can significantly alter the patient's quality of life. They require therapy with topical steroids if they are single or with systemic steroids when they are multiple.



Additional reading

<http://www.hivdent.org/>. Extensive information about HIV/AIDS and the oral cavity. Last accessed on Aug 13, 2013

INTECH