

---

## Bony Lesions

---

Idiopathic osteosclerosis

Condensing Osteitis

Nasopalatine duct cyst

Lateral periodontal cyst

Dentigerous cyst

Odontoma (complex/compound)

Stafne defect

Cemento-osseous dysplasia (Focal/florid)

Odontogenic keratocyst (keratocystic odontogenic tumor)

Ameloblastoma

---

### 1. Idiopathic osteosclerosis (bone island, bone scar, focal periapical osteopetrosis, enostosis)

**Description:** Idiopathic osteosclerosis (IO) is an intraosseous growth of non-inflammatory trabecular bone.

**Etiology:** Unknown origin, but may be considered as a normal developmental anatomic bone variation.

**Prevalence:** Greater prevalence among Chinese and Blacks than Caucasians. No difference in frequency between males and females.

**Location:** More often in the posterior mandible rather than the maxilla. Most of the lesions are associated with root apices.

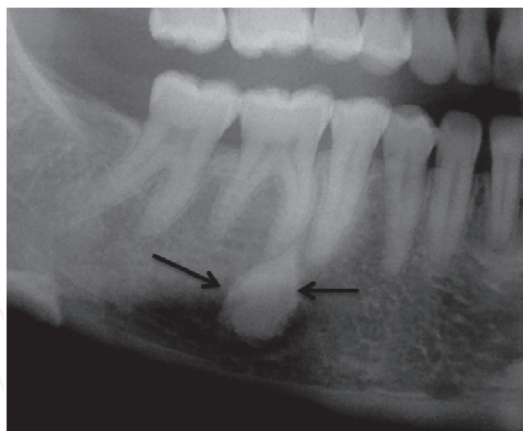
**Signs and symptoms:** Asymptomatic and diagnosed as an incidental finding on a radiograph.

**Radiographic findings:** In general, IO appears as a round, elliptical or irregular area of increased bone density. Usually appears as a well-defined homogeneous radiopacity that blends in with the surrounding bone.

**Treatment:** Treatment is neither indicated nor necessary.

**Differential diagnosis:** Condensing osteitis.

---



Idiopathic osteosclerosis in close proximity to the mesial root of mandibular first molar.

## 2. Condensing osteitis (chronic focal sclerosing osteomyelitis, sclerosing osteitis, bone eburnation)

**Description:** Localized pathologic growth of maxillomandibular bones with mild clinical symptoms.

**Etiology:** Bone-appositioning inflammatory processes from infection of periapical tissues by organisms of low virulence.

**Prevalence:** Greater prevalence among children and young adults. No difference in frequency between males and females.

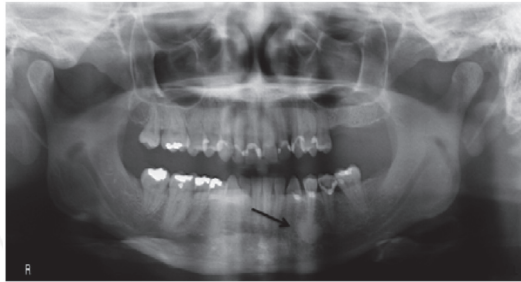
**Location:** More often in the posterior mandible. Most of lesions surrounds the apices of teeth with pulpitis or pulpal necrosis.

**Signs and symptoms:** Usually asymptomatic, but the associated low-grade chronic pulpal infection may produce mild symptoms.

**Radiographic findings:** Uniform dense periapical radiopacity with ill-defined sclerotic margins and large transition to the surrounding bone. The lesion is usually non-expansile and is associated with a carious tooth, which exhibits loss of lamina dura and widening of the periodontal ligament space. The size of CO may vary from 1 mm to 22 mm with mean width and height of 5 mm, and as to shape, it may vary from round to irregular.

**Treatment:** In symptomatic cases, endodontic therapy or extraction are the choices depending on the particular tooth condition. Asymptomatic cases without obvious caries should be followed with periodic x-ray examination.

Differential diagnosis: Idiopathic osteosclerosis, cementoblastoma.



Condensing osteitis associated with left mandibular premolar with large cervical restoration.

### 3. Nasopalatine duct cyst (median anterior maxillary cyst, incisive canal cyst)

**Description:** Developmental non-odontogenic cyst with intraosseous and extraosseous variants.

**Etiology:** Unknown origin, but this lesion develops from epithelial remnants of the nasopalatine duct contents.

**Prevalence:** May occur in any age, but is rare in the first decade of life. More frequent in males.

**Location:** Midline of the anterior palate.

**Signs and symptoms:** Palatal swelling, anterior tooth displacement, sublabial swelling, low-grade pain, transient salty taste. Adjacent teeth are vital.

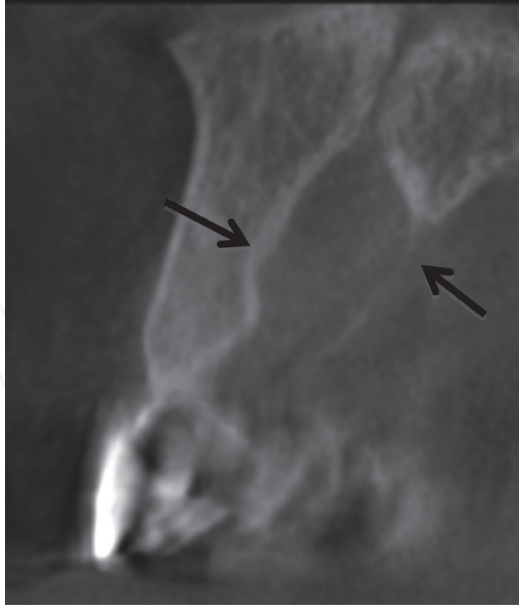
**Radiographic findings:** Usually intraosseous lesions present as round or ovoid well-defined radiolucency with unique appearance of a “heart shape” caused by the superimposition of the anterior nasal spine over the superior portion of the lesion. Central incisors may be displaced, but radicular resorption is rare. In large lesions, expansion and thinning of the palatal and buccal cortices may be present.

Extraosseous lesions do not present abnormal radiographic findings, because they are entirely within soft tissue.

**Prognosis:** Good. This cyst rarely recurs.

**Treatment:** Surgical enucleation for small lesions. Marsupialization for larger cysts.

**Differential diagnosis:** Large nasopalatine duct, radicular cyst or granuloma, central giant cell granuloma.



Nasopalatine duct cysts. Note expansion of the incisive canal with soft tissue extension.

#### 4. Lateral inflammatory periodontal cyst (inflammatory periodontal cyst)

**Description:** Intrabony cystic lesion.

**Etiology:** This lesion arises from epithelial rests in the lateral periodontium of the root.

**Prevalence:** Usually identified from second to the ninth decades of life. No gender predilection.

**Location:** Higher incidence in the mandibular lateral incisor to second premolar and between maxillary lateral incisor and canine.

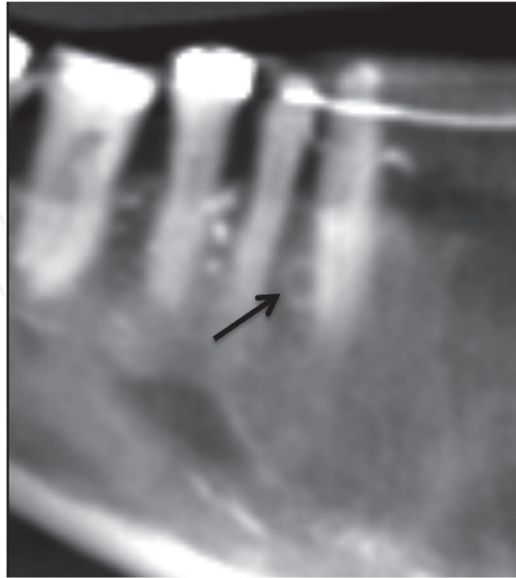
**Signs and symptoms:** Asymptomatic unless secondary infected.

**Radiographic findings:** Well-defined round or oval shape radiolucency with sclerotic borders. Usually unilocular with less than 1 cm in diameter. Larger and multilocular lesions have been reported (botryoid odontogenic cysts). In small lesions, associated lamina dura may be absent. In large lesions, cortical expansion and dental displacement may be present.

**Treatment:** Excisional biopsy or enucleation.

**Prognosis:** Good. These cysts do not tend to recur.

**Differential diagnosis:** In small lesions, keratocystic odontogenic tumor, neurofibroma, radicular cyst or mental foramen.



Lateral inflammatory periodontal cyst associated with the distal aspect of mandibular canine. (Image courtesy of Dr. Marcel Noujeim, UTHSCSA).

## 5. Dentigerous cyst (follicular cyst, eruption cyst)

**Description:** Pericoronal cystic lesion associated with unerupted dentition. It is classified in eruption, circumferential or lateral dentigerous cysts according to its relationship with an unerupted or supernumerary tooth.

**Etiology:** Originates from hemodynamic pooling of fluid beneath the enamel epithelium or between the epithelium and the crown of an unerupted tooth.

**Prevalence:** After radicular cysts, dentigerous cysts are the second most common type of cyst in the jaws. Usually, these cysts are identified in patients younger than 20 years of age.

**Location:** Above the crown, attached to the cemento-enamel junction. Higher occurrence associated with maxillary and mandibular third molars and maxillary canines.

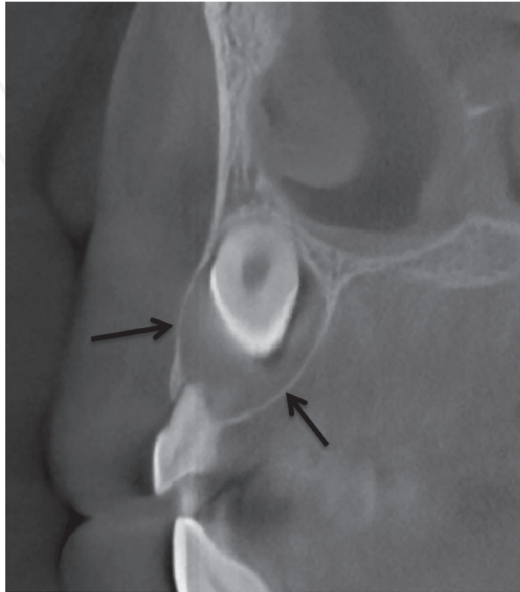
**Signs and symptoms:** Typically no pain or discomfort. Missing tooth or teeth with hard swelling and facial asymmetry.

**Radiographic findings:** Typically well-defined unilocular radiolucency with sclerotic outline unless secondarily infected. Radicular resorption and cortical expansion may be present.

**Treatment:** Enucleation with extraction of associated tooth.

**Prognosis:** Excellent.

**Differential diagnosis:** Keratocystic odontogenic tumor, ameloblastoma.



Dentigerous cyst associated with impacted maxillary canine. Note buccal and lingual cortical expansion, relationship with the CEJ of the teeth of origin and radicular resorption of the primary tooth. (Image courtesy of Dr. Marcel Noujeim, UTHSCSA).

## 6. Odontoma (complex/compound)

**Description:** Hamartomatous or benign mixed odontogenic tumor. Two forms classified as complex (gross mixture of dental tissues) or compound (multiple tooth-like structures).

**Etiology:** Unknown.

**Prevalence:** Usually identified in young patients in the first or second decades of life.

**Location:** Within the alveolar region of the jaws. Complex form most commonly noted in the mandibular posterior area. Compound form most commonly noted in the maxillary anterior area.

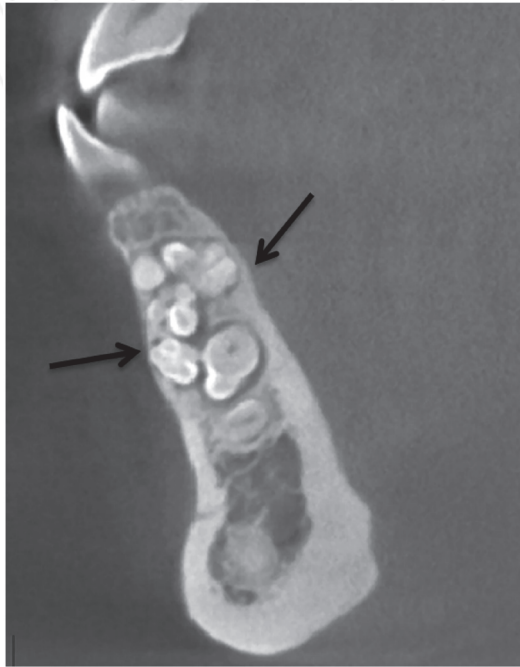
**Signs and symptoms:** Usually asymptomatic, but pain and swelling have been reported.

**Radiographic findings:** Well-defined, mixed radiolucent and radiopaque lesion. Jaw expansion may be present with large lesions.

**Treatment:** Conservative excision/curettage.

**Prognosis:** Excellent.

**Differential diagnosis:** Focal sclerosing osteitis, osteoma, ameloblastic fibro-odontoma, adenomatoid odontogenic tumor, calcifying odontogenic tumor.



Odontoma (compound) in the anterior mandible. Note multiple tooth-like structures and slight cortical expansion characteristic of this lesion.

## 7. Stafne defect (salivary gland depression, lingual bone defect, static bone cyst)

**Description:** Bone concavity in the lingual surface of the mandible with intact buccal cortex filled with salivary gland or adipose tissue

**Etiology:** Unknown origin, but it is considered a developmental defect.

**Prevalence:** Generally detected in patients in the 5<sup>th</sup> and 6<sup>th</sup> decade of life.

**Location:** Usually in the posterior mandible within the submandibular fossa, between the mandibular canal and inferior border of the mandible. Anterior variant is commonly found near the apex of the bicuspids.

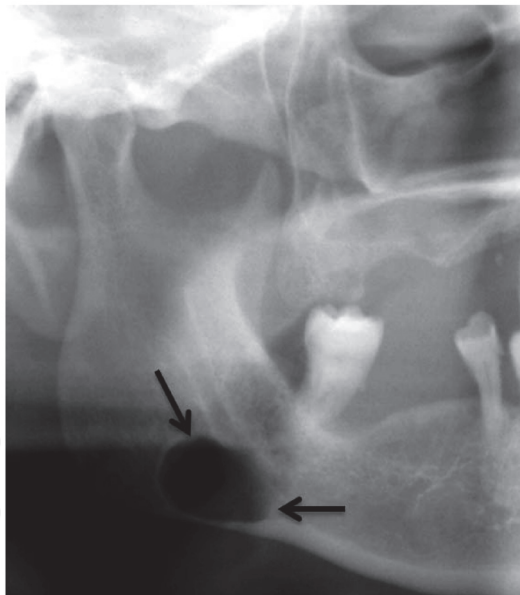
**Signs and symptoms:** Asymptomatic. Usually discovered incidentally.

**Radiographic findings:** Usually well-defined round or ovoid radiolucency of variable width with hypercorticated margins.

**Treatment:** Treatment is neither indicated nor necessary.

Prognosis: Excellent.

**Differential diagnosis:** Variants in anterior mandible may present similar radiographic features of odontogenic lesions, such as cysts.



Stafne defect in the right posterior mandible. Note location below the mandibular canal and image features similar to a odontogenic cyst.



## 8. Cemento-osseous dysplasia (periapical/florid)

**Description:** Gradual replacement of normal cancellous bone by fibrous tissue, abnormal bone and cementum. Periapical COD (PCOD) classifies alterations located in the anterior region. Florid COD (FCOD) classifies to more extensive conditions involving more than 1 quadrant.

**Etiology:** Unknown origin, but it is considered as a reactive or dysplastic process.

**Prevalence:** Higher in middle-aged women. More often in Blacks than Whites. Frequently seen in Asians.

**Location:** Usually confined to the tooth-bearing areas of the jaws or to edentulous alveolar processes. Usually in the apex of mandibular dentition.

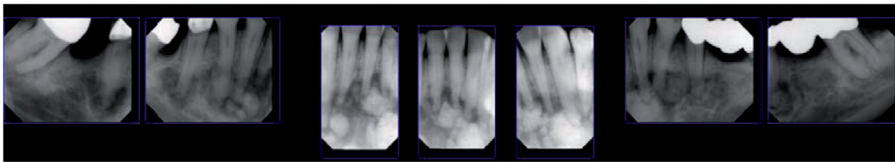
**Signs and symptoms:** Typically asymptomatic but may be associated with pain, swelling, dental sensitivity and mobility.

**Radiographic findings:** Radiolucent in early stages, mixed (radiolucent-radiopaque) and radiopaque in late stages. Usually radiolucencies show radiopaque sclerotic bone margins with variable width. Cortical expansion may be present in large lesions.

**Treatment:** Usually, no treatment is necessary unless patient states symptoms (e.g. pain or discomfort) associated with atrophy of alveolar ridge and exposure of cementum. Infection should be consider.

**Prognosis:** Good, however osteomyelitis may occur if secondarily infected.

**Differential diagnosis:** Vary with the stage of development of the lesion. Radiolucent stage: radicular granuloma or cyst. Mixed stage: chronic sclerosing osteomyelitis. Radiopaque stage: odontoma, cementoblastoma.



Cemento-osseous dysplasia (florid form).

## 9. Keratocystic odontogenic tumor (odontogenic keratocyst)

**Description:** Odontogenic benign and aggressive cystic neoplasm. Nevoid basal cell carcinoma syndrome should be considered in cases of multiple lesions.

**Etiology:** Developmental tumor.

**Prevalence:** Predilection for White males. Peaks in the second and third decades of life.

**Location:** Most common in the posterior body and ramus of the mandible.

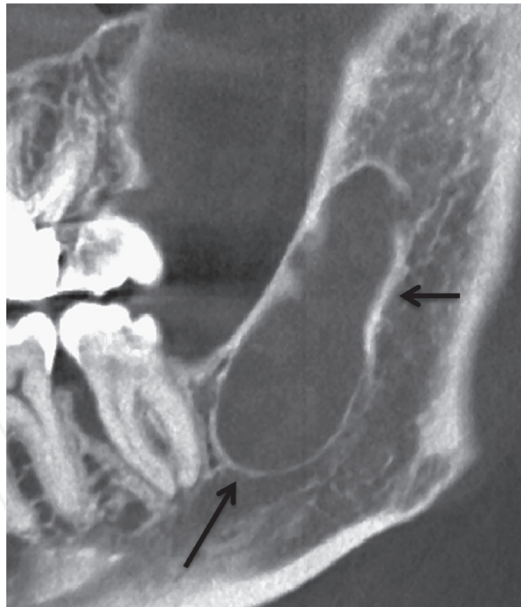
**Signs and symptoms:** Usually asymptomatic. Pain, swelling and drainage due to secondary infection.

**Radiographic findings:** Usually scalloped multilocular radiolucency with sclerotic borders. Minimal cortical expansion in the body of the mandible. Considerable expansion in the maxilla or ramus and coronoid process of the mandible.

**Treatment:** Managed in a case-by-case basis. Excision with bony curettage. No recurrence is reported after resection; however the invasive nature of the procedure should be taken into consideration.

**Prognosis:** Variable. 1 to 56% of recurrence rate depending on the treatment. Long-term follow-up is recommended.

**Differential diagnosis:** Dentigerous cyst, ameloblastoma, simple bone cyst, odontogenic myxoma, central giant cell granuloma, central mucoepidermoid carcinoma.



Kerotocystic odontogenic tumor in the posterior mandible extending into the ramus. Note sclerotic borders and displacement of the mandibular canal.

## 10. Simple bone cyst (traumatic bone cyst, solitary bone cyst)

**Description:** Cavity in the jaws without epithelial lining. It may be empty or filled with small amount of fluid. May be associated with cemento-osseous dysplasia.

**Etiology:** Unknown in most cases. Questionable trauma relationship.

**Prevalence:** Male predilection. Most lesions occur in the first and second decades of life. When associated with cemento-osseous dysplasia, simple bone cysts tend to occur in the fourth decade of life and in female patients.

**Location:** Mostly found in the ramus or posterior mandible.

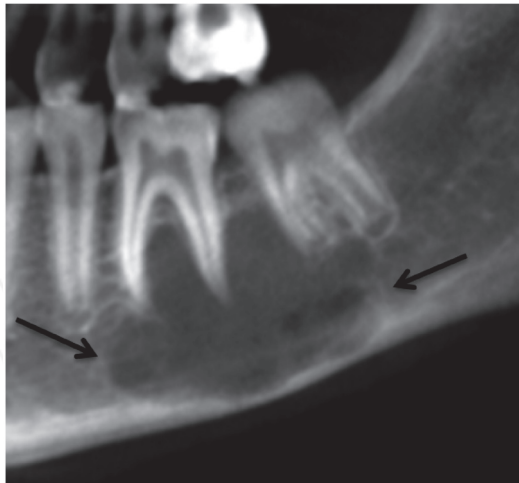
**Signs and symptoms:** Usually asymptomatic. Empty bony space. Pain and tenderness associated with secondarily infected lesions. Swelling may be observed.

**Radiographic findings:** Well-defined and scalloped radiolucency extending between the dental roots.

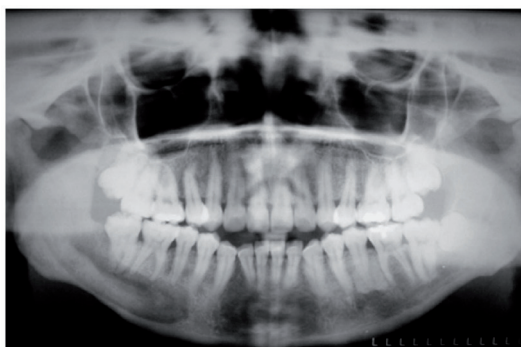
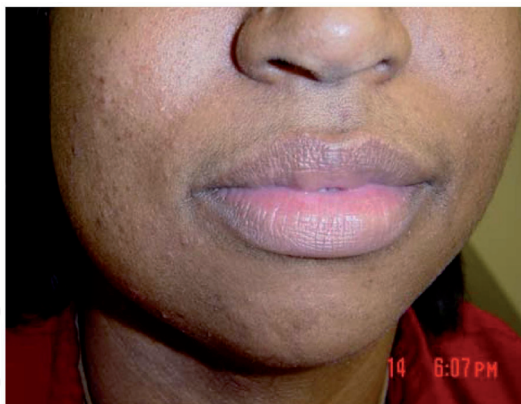
**Treatment:** Surgical exploration and observation for resolution.

**Prognosis:** Excellent. Small risk of recurrence.

**Differential diagnosis:** Hemangioma, early stage of fibrous-osseous lesions, central giant cell granuloma.



Simple bone cyst in the posterior mandible. Note scalloped margins extending between the roots of the molars.



Simple bone cyst

## 11. Ameloblastoma (adamantinoma)

**Description:** Benign and aggressive tumor. Malignant variants described.

**Etiology:** Odontogenic epithelial origin.

**Prevalence:** Most common odontogenic tumor after odontoma. Most lesions occur in the third to fifth decades of life. Slight predilection for males and Blacks.

**Location:** Most often in the posterior mandible, mainly in the molar and ramus region and associated with unerupted tooth.

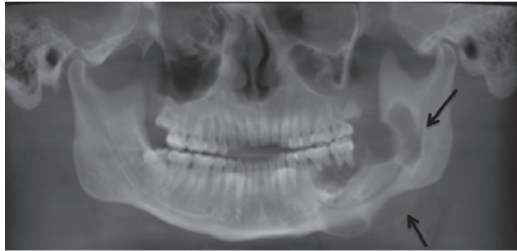**Signs and symptoms:** Slow growth. Deformity with facial asymmetry. Minimal symptoms. Usually discovered as an incidental finding.

**Radiographic findings:** Unilocular or multilocular radiolucency with sclerotic margins. Cortical expansion with or without perforation.

**Treatment:** Less aggressive and unicystic forms may be treated with local excision. Multicystic form requires local excision or resection.

**Prognosis:** Good. Recurrence may be higher with conservative treatment. Long-term follow-up is recommended.

**Differential diagnosis:** Dentigerous cyst, keratocystic odontogenic tumor, odontogenic myxoma, central giant cell granuloma.



Ameloblastoma in the left mandible. Note multilocular and expansile lesion with "knife-edge" radicular resorption of the molars.

## 12. Odontogenic myxoma (myxofibroma, fibromyxoma)

**Description:** Benign intra-osseous infiltrative tumor. Rarely aggressive, develops only in the facial bones.

**Etiology:** Odontogenic ectomesenchymal origin.

**Prevalence:** Relatively rare. Wide age range, but usually identified in the first to third decade of life. Slight female predilection.

**Location:** Commonly affect the posterior maxilla or mandible.

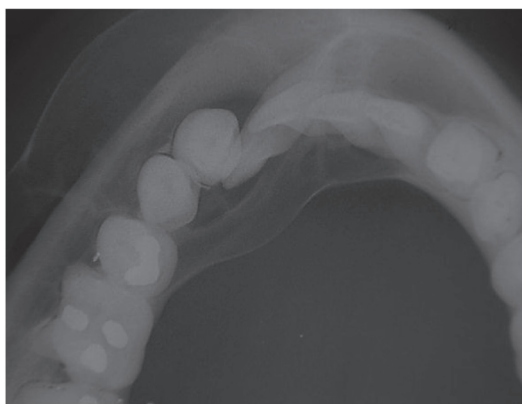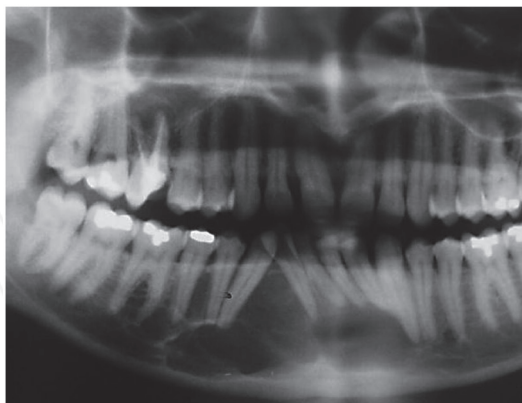**Signs and symptoms:** Slow growth. Usually asymptomatic.

**Radiographic findings:** Most often multilocular well-defined radiolucency with cortical thinning and expansion. Uncommon cortical perforation. Maxillary sinus and zygomatic process may be involved.

**Treatment:** Excision with bony curettage. Bloc resection is indicated in large lesions.

**Prognosis:** Good, however high recurrence rate is reported. Long-term follow-up is recommended.

**Differential diagnosis:** Ameloblastoma, keratocystic odontogenic tumor, central giant cell granuloma, central hemangioma.



Courtesy of Dr. Celso Lemos - Department of Oral Medicine, School of Dentistry, Sao Paulo University

## Additional reading

### Idiopathic osteosclerosis

Bsoul SA, Alborz S, Terezhalmay GT, Moore WS. Idiopathic osteosclerosis (enostosis, dense bone silands, focal periapical osteopetrosis). *Quintessence Int* 2004 Jul-Aug;35(7):590-1.

Geist JR, Katz JO. The frequency and distribution of idiopathic osteosclerosis. *Oral Surg Oral Med Oral Pathol* 1990 Mar;69(3):388-93.

Noujeim M, Bsoul S, Huber M. Unusual presentation of idiopathic osteosclerosis: a case report. *Gen Dent* 2008 Mar-Apr;56(2):182-5.

### **Condensing osteitis**

Holly D, Jurkovic R, Mracna J. Condensing osteitis in oral region. *Bratisl Lek Listy* 2009;110(11):713-5.

Marmary Y, Kutiner G. A radiographic survey of periapical jawbone lesions. *Oral Surg Oral Med Oral Pathol* 1986 Apr;61(4):405-8.

Cure JK, Vattoth S, Shah R. Radiopaque jaw lesions: an approach to the differential diagnosis. *Radiographics* 2012 Nov;32(7):1909-25.

### **Nasopalatine duct cyst**

Cecchetti F, Ottria L, Bartuli F, Bramanti NE, Arcuri C. Prevalence, distribution, and differential diagnosis of nasopalatine duct cysts. *Oral Implantol (Rome)* 2012 Apr;5(2-3):47-53.

Aldealmi TN, Khalil AA. Diagnosis and surgical management of nasopalatine duct cysts. *J Craniofac Surg* 2012 Sep;23(5):e472-4.

### **Lateral inflammatory periodontal cyst**

Eliasson S, Isacson G, Kondell PA. Lateral periodontal cysts. Clinical, radiographical and histopathological findings. *Int J Oral Maxillofac Surg* 1989 Aug;18(4):191-3.

Dubey KN, Garg S, Atri R. Diagnosis and osseous healing of a lateral periodontal cyst mimicking a deep unusual interdental pocket in a young patient. *Contemp Clin Dent* 2010 Jan;1(1):47-50.

### **Dentigerous cyst**

Shear M. Developmental odontogenic cysts. An update. *J Oral Pathol Med* 1994 Jan;23(1):1-11.

Maxymiw WG, Wood RE. Carcinoma arising in a dentigerous cyst: a case report and review of the literature. *J Oral Maxillofac Surg* 1991 Jun;49(6):639-43.

Main DM. Follicular cysts of mandibular third molar teeth: radiological evaluation of enlargement. *Dentomaxillofac Radiol* 1989 Nov;18(4):156-9.

Lustmann J, Bodner L. Dentigerous cysts associated with supernumerary teeth. *Int J Oral Maxillofac Surg* 1988 Apr;17(2):100-2.

### **Odontoma**

Boffano P, Zavattero E, Rocca F, Gallesio C. Complex and compound odontomas. *J Craniofac Surg* 2012 May;23(3):685-8.

Morgan PR. Odontogenic tumors: a review. *Periodontol* 2000 2011 Oct;57(1):160-76.

### **Stafne defect**

Quesada-Gomez C, Valmaseda-Castellon E, Berini-Aytes L, Gay-Escoda C. Stafne bone cavity: a retrospective study of 11 cases. *Med Oral Patol Oral Cir Bucal* 2006 May;11(3):E277-80.

### **Cemento-osseous dysplasia**

Alsufyani NA, Lam EW. Osseous (cemento-osseous) dysplasia of the jaws: clinical and radiographic analysis. *J Can Dent Assoc* 2011;77:b70.

Macdonald-Jankowski DS. Focal cemento-osseous dysplasia: a systematic review. *Dentomaxillofac Radiol* 2008 Sep;37(6):350-60.

### **Keratocystic odontogenic tumor**

Grasmuck EA, Nelson BL. Keratocystic odontogenic tumor. *Head Neck Pathol* 2010 Mar;4(1):94-6.

Boffano P, Ruga E, Gallesio C. Keratocystic odontogenic tumor (odontogenic keratocyst): preliminary retrospective review of epidemiologic, clinical, and radiologic features of 261 lesions from University of Turin. *J Oral Maxillofac Surg* 2010 Dec;68(12):2994-9.

### **Simple bone cyst**

Kaugars GE, Cale AE. Traumatic bone cyst. *Oral Surg Oral Med Oral Pathol* 1987 Mar;63(3):318-24.

Eversole R, Su L, ElMofty S. Benign fibro-osseous lesions of the craniofacial complex. A review. *Head Neck Pathol* 2008 Sep;2(3):177-202.

### **Ameloblastoma**

Gomes CC, Duarte AP, Diniz MG, Gomez RS. Review article: Current concepts of ameloblastoma pathogenesis. *J Oral Pathol Med* 2010 Sep;39(8):585-91.

Stoelinga PJ. The management of aggressive cysts of the jaws. *J Maxillofac Oral Surg* 2012 Mar;11(1):2-12.

### **Odontogenic myxoma**

Kansy K, Juergens P, Krol Z, Paulussen M, Baumhoer D, Bruder E, et al. Odontogenic myxoma: diagnostic and therapeutic challenges in paediatric and adult patients--a case series and review of the literature. *J Craniomaxillofac Surg* 2012 Apr;40(3):271-6.

Leiser Y, Abu-El-Naaj I, Peled M. Odontogenic myxoma--a case series and review of the surgical management. *J Craniomaxillofac Surg* 2009 Jun;37(4):206-9.