

Molar Incisor Hypomineralization: Morphological, Aetiological, Epidemiological and Clinical Considerations

Márcia Pereira Alves dos Santos^{1,2} and Lucianne Cople Maia²

¹*School of Dentistry, Fluminense Federal University,*

²*School of Dentistry, Federal University of Rio de Janeiro, Brazil*

1. Introduction

The prevalence of dental caries has been reduced over the years due to increased access of fluorides, such as fluoride tooth paste, to dental services and to oral health education on the great part of the population. However, a significant portion of the same population still remains undertreated and show dental cavities as after-effects of this oral disease. In spite of dental caries is strongly influenced by social, economic, cultural, religious and environmental factors, its severity may be increased by structural changes of enamel/dentin such those observed in cases of molar incisor hypomineralization (MIH). In a Brazilian survey, children with MIH showed higher caries experience in the permanent dentition than the general population of similar age. (da Costa-Silva et al., 2010) The MIH increases the dental caries risk as consequence of affected teeth because they are not only soft and porous enamel teeth but also very sensitive to stimuli making effective oral hygiene difficult. (Kilpatrick, 2009) Several aetiological factors are mentioned as the cause of MIH (Alaluusua, 2010, Lygidakis et al., 2010, Crombie et al., 2009, Brook, 2009) and they are frequently associated with childhood diseases or nutritional conditions during the first three years of life. (Fagrell et al., 2011)

Clinically, MIH can create serious drawbacks for the dentist as well as for the child affected. For dentists, the problems are related to unexpectedly rapid caries development in the erupting first permanent molar and unpredictable behaviour of apparently intact opacities. Moreover, these teeth are very sensitive and often require extensive treatment since rapid breakdown of tooth structure may occur, giving rise to acute symptoms and complicated treatments. Defected enamel teeth require complex treatment solutions and the different treatment options will depend on the extension of the defect, the degree of tooth eruption, the oral hygiene and diet habits of the patient. According to the severity of the case, the treatment ranges from topical fluoride varnish, to the use of adhesive materials for restorative procedures, or even the extraction of the teeth associated with orthodontic therapy. (Lygidakis et al., 2010, Lygidakis, 2010) The child, on the other hand, will experience pain and sensitivity, even when the enamel is intact, suffering from toothache during teeth brushing. Often, there is more difficulty to anaesthetize the MIH molars when treatment is indicated. Furthermore, children may also complain about the appearance and

stainment of their affected incisor. (William et al., 2006a) In such circumstance, the esthetic complaint may also be considerable. Apart from the restorative difficulties faced by clinicians, children with MIH have dental fear and anxiety and these behaviour problems can be related to pain experienced by the patients during multiple treatment appointments, as many of them were either inadequately anesthetized or even had treatment without local analgesia (Jalevik & Klingberg, 2002). It has been shown that children with MIH receive much more dental treatment than unaffected children. (Jalevik & Klingberg, 2002, Kotsanos et al., 2005) Thus, treatment planning should also consider the long-term prognosis of teeth suffering from this condition.

Children during the period of eruption of their first permanent molars and/or incisors should be monitored very carefully in order to obtain an early diagnosis and immediate treatment for MIH. Considering all aspects mentioned above, MIH is one of the biggest challenges to great challenge of great clinical interest for dental practice because MIH has a great impact on the oral health as consequently, on the quality of life of children and adolescents. Thus, the objective of this chapter is to describe some epidemiological, morphological and treatment management considerations about MIH.

1.1 Definition

Developmental defects of enamel were commonly defined as hypoplasia, but according to the FDI Commission on Oral Health, Research and Epidemiology (1992), these defects are best classified into two distinct categories: a) hypomineralized enamel or enamel opacities (Figures 1A and 1B) and enamel hypoplasia (Figures 1C and 1D). While opacity is defined as a qualitative defect of the enamel, hypoplasia is defined as a quantitative defect of the enamel. (Suckling, 1989) There are others differences between developmental defects of enamel that can be seen in Table 1.

In the dental literature a wide variety of terminology or definitions were used for developmental defects of enamel in molars, with or without association with post eruptive breakdown of enamel as non-fluoride enamel opacities, internal enamel hypoplasia, non-endemic mottling of enamel, opaque spots, idiopathic enamel opacities, enamel opacities or cheese molars. (Koch et al., 1987, van Amerongen & Kreulen, 1995) However, to better understand the occurrence of molar incisor hypomineralisation and its impact on the oral health, the use of a uniform terminology is strongly recommended. (Weerheijm, 2004, Weerheijm et al., 2003)

The term molar incisor hypomineralisation (MIH) was firstly cited by WEERHEIJM ET AL., 2001. (Weerheijm et al., 2001) and further, this terminology was definitively adopted by the international dental scientific community as a result of a consensus after innumerable discussions in relation to developmental defects of enamel (Weerheijm et al., 2003). Then, MIH was defined as the clinical appearance of morphological enamel defects involving the occlusal and/or incisal third of one or more permanent molars or incisors as result as "hypomineralisation of systemic origin." (Weerheijm, 2004) The first permanent molar enamel is affected to an extent ranging from mild to severe; in many cases the incisor enamel is affected, but often, minimally not necessarily involving a macroscopic defect of tooth. Furthermore, this specific form of developmental defects of enamel (Baroni & Marchionni, 2011) show opacities asymmetrically often distributed, with marked variation in severity within an individual and ranges from small demarcated white, yellow or brown

opacities (Figures 2A to 2F) to those covering much or the entire crown affecting cuspal areas and sparing the cervical areas. (Brook, 2009) CHAWLA ET AL. 2008 (Chawla et al., 2008) suggested that yellow-brown enamel defects are more severe than white-opaque ones it means that the stained degree of MIH enamel, may be used clinically to reflect the severity of the defect. (Farah et al., 2010a) In severe cases, the defective enamel is lost shortly after molar eruption, exposing underlying dentine favoring the tooth sensitivity and the dental carious lesion. (Kilpatrick, 2009)





Developmental defects of enamel		
Characteristics	Hypomineralised enamel or enamel opacities	Enamel hypoplasia
Enamel defect	Qualitative	quantitative
Clinical aspects	Normal thickness of the enamel Demarcated opacities of white to yellow-brown coloration Enamel is soft, porous and poorly delineated from normal tooth tissue Post eruptive breakdown in molars Assymmetrical opacities	Partial or total absence of enamel White colored lesions Deep fissures, horizontal or vertical grooves Edges with adjacent normal enamel are smooth Symmetrical or isolated lesions
Clinical appearance	 Fig. 1. A - Assymmetrical opacities in incisors  Fig. 1. B - Assymmetrical opacities in upper first permanent molars	 Fig. 1. C - Symmetrical opacities in incisors  Fig. 1. D - Isolated opacity in left upper incisor
Aetiological factors	Remains obscure	Identifiable systemic or local insult (trauma or local infection in primary teeth)

Table 1. Differences between two developmental defects of enamel according to FDI Commission on Oral Health, Research and Epidemiology (FDI, 1982)

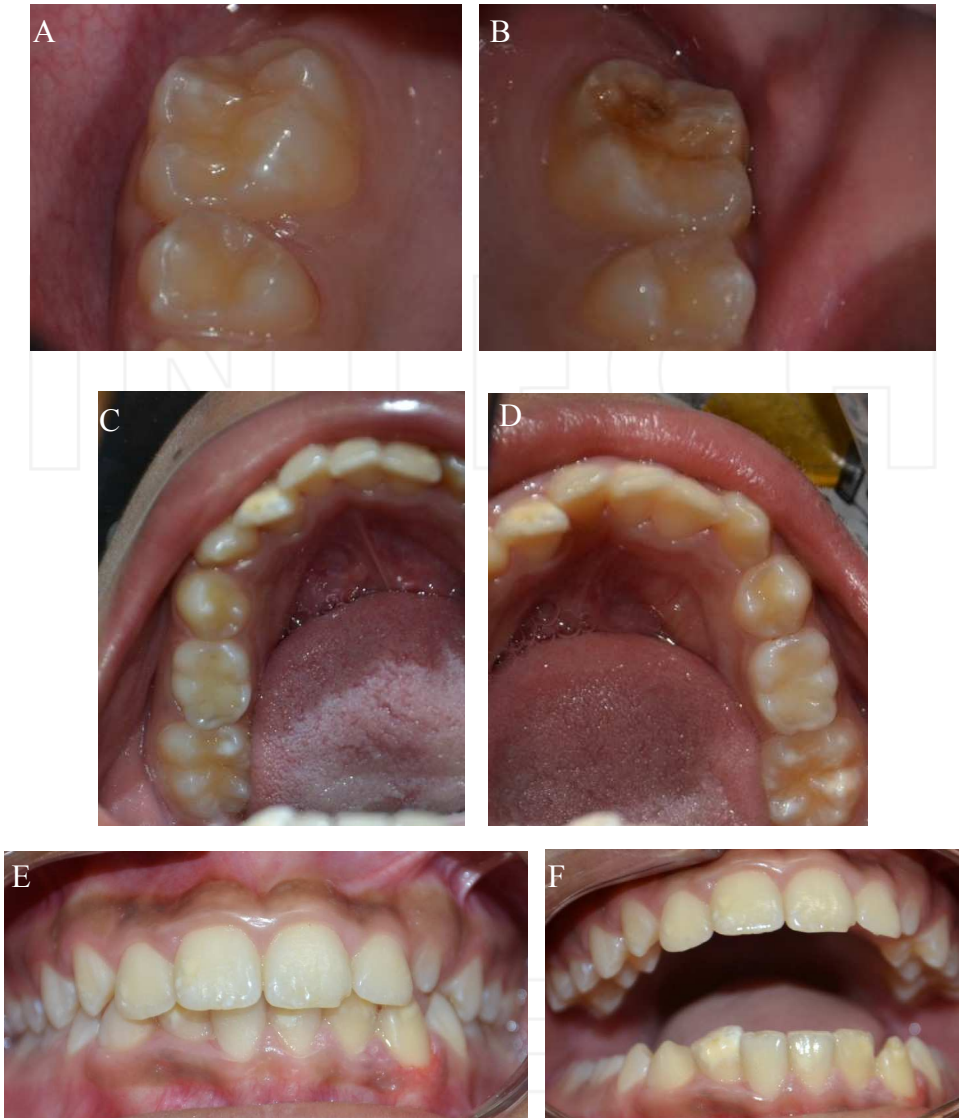

Fig. 2. A to F - In the same patient, note the presence of asymmetry and the different levels severity of lesions associated to the color opacities in molars and incisors.

Lately, MIH is understood as a hypocalcified subtype of enamel defect with reduced mineral content, low residual content of amelogenins and the presence of more than 16 types of proteins in affected teeth, thirteen of which are found in saliva and crevicular fluid (Kojima et al., 2000, Denny et al., 2008) and the three others (hemoglobin, albumin, complement C3) are major components of blood. Moreover, protein composition of MIH enamel varies with severity of enamel defect. (Mangum et al., 2010a)

2. Morphological considerations about MIH

2.1 Amelogenesis and developmental defects of enamel

Tooth development is strictly genetically controlled but sensitive to environmental disturbances (Suckling et al., 1988) since teeth have been formed they do not undergo remodeling. (Brook, 2009) During dental development, a single layer of inner enamel epithelial cells undergoes a remarkable change in cell shape in preparation for the secretion of enamel extracellular matrix. These cells develop into tall ameloblasts with cellular extensions called Tomes' processes, which function during enamel matrix secretion. Following generation of the enamel layer, the ameloblasts shorten and reorganize during the transition stage; they then enter maturation, where they change histologically from ruffle-ended to smooth-ended at the location where Tomes' processes have retracted. These cells reduce the enamel protein content and increase the mineral content so that the enamel layer can develop into the hardest tissue in the body. Finally, the cells shorten further and adhere to the enamel surface until just before eruption of the tooth into the oral cavity (Smith, 1979). In other words, enamel formation occurs in three stages:

1. matrix formation during which proteins involved in amelogenesis are produced;
2. calcification during which mineral content is acquired and the proteins are removed;
3. maturation during which the enamel is calcified and the remaining proteins are removed.

The mineralization of the enamel matrix is described as a two-step process. Firstly, the ameloblasts secrete an organic matrix that is immediately mineralized to about 30% by weight. Secondly, when the full thickness of enamel has been secreted by an ameloblast, a progressive increase in mineral content begins. Smooth-ended ameloblasts remove water and proteins from the enamel matrix, whereas ruffle-ended ameloblasts participate in the active transport of calcium and phosphate into the matrix. The principal proteins acted in the enamel matrix are:

- a. amelogenins (the major protein ~90% secreted into the enamel matrix) is a group of heterogeneous proteins (20-30 kDa) that are hydrophobic and rich in proline, histidine and glutamine and they are thought to play a role in the organization and regulation of crystal growth;
- b. ameloblastins (Amelin, Sheathelin) constitutes 5-10% of the enamel matrix. It is thought to promote mineralization and crystal elongation; and
- c. enamelines (60-80 kDa) are a heterogeneous group of proteins that may be involved in crystal nucleation. They are responsible for the progressive proteolytic cleavage of amelogenins. The processing of amelogenins to smaller peptides is necessary for the regulation of crystal organization and growth of enamel.

According to BROOK, 2009 (Brook, 2009) in the secretory stage the enamel protein matrix deposited by the ameloblasts is predominantly formed of amelogenin (85%). At the mid-secretory stage for appositional crystal growth and structural maintenance amelogenin is essential. However, while enamelin contributes less than 5% of the matrix it plays a major role in controlling the initiation of hydroxyapatite formation in early amelogenesis, being necessary for creating and maintaining enamel crystallite elongation at the mineralization front immediately adjacent to ameloblasts. The further enamel protein ameloblastin is a cell-adhesion molecule that maintains the differentiation stage of secreting ameloblasts and

controls their secretion. The subsequent breakdown and removal of matrix proteins by means of proteolytic processing is essential for further development and mineralisation. Enamelysin (Mmp20), a matrix metalloproteinase, and the enamel serine protease kallikrein 4 (Klk4) are two major molecules involved in this process. (Wright et al., 2009, Bartlett et al., 2011) Mmp20 is expressed in secretory stage ameloblasts and also has effects on them maturation stage as well as on the mineralisation of mantle dentine. Klk4, present in both ameloblasts and odontoblasts, is expressed at the enamel transition and maturation phase. KLK4 which is secreted into the enamel by ameloblasts during the transition and maturation stages of amelogenesis. Klk4 degrades the organic matrix remaining from the secretion stage. This facilitates the continued deposition of minerals into enamel required for full mineralisation of hard enamel. Amelogenin is cleaved by Mmp20 and later degraded during maturation by Klk4. Within the ameloblasts Dlx3 and Dlx6 are expressed throughout the presecretory, secretory and maturation stages. During secretion Dlx2 is switched off and Dlx1 expression is upregulated. The Dlx homeobox genes may influence enamel formation by the regulation of amelogenin expression. Normal enamel thickness may be achieved by Runx2 suppressing enamel protein expression at the end of the secretory stage to give normal enamel thickness. In the maturation phase Runx2 induces Klk4 and upregulates basal membrane protein expression to induce ameloblast attachment to the enamel matrix. (Brook, 2009, Wright et al., 2009, Bartlett et al., 2011)

In general, systemic factors that disturb the ameloblasts during the secretory stage cause restrictions of crystal elongation and result in pathologically thin, or hypoplastic enamel. On the other hand, disturbances during the transitional and/or maturation stage of amelogenesis result in pathologically soft (hypomaturated, hypomineralised) enamel of normal thicknesses. (Suga, 1989) According to REID AND DEAN, 2006 (Reid & Dean, 2006), enamel formation as a whole takes approximately one thousand days. Two thirds of this time is devoted to the maturation stage of amelogenesis. Considering this, the most critical period for enamel defects of first permanent molars and incisors is the first year of life coinciding with their early maturation (Alaluusua, 2010). In this period ameloblasts are highly sensitive to environmental disturbances. (Suckling, 1989) Hypomineralisation may also develop later because enamel maturation in the first permanent molars takes several years (later maturation stage). (Alaluusua, 2010)

2.2 Amelogenesis and MIH

As mentioned previously, there are no hypoplastic defects in MIH affected teeth because there is not any discernable reduction in enamel thickness teeth. (Farah et al., 2010a, Fearn et al., 2004) It suggests that any reduction in enamel thickness seen clinically is indicative of post-eruption disintegration of enamel. Furthermore, this clarify that whatever insult affects the developing tooth it happens after the enamel secretion is completed and affects the maturation phase of the mineralization process in a localized area of enamel. (Farah et al., 2010a)

2.3 Characteristics of MIH affected teeth

MIH is a qualitative defective enamel classified as hypomineralised type that follows the natural incremental lines of enamel formation, from cuspal to cement-enamel junction. (Farah et al., 2010a, Fearn et al., 1994) In the most cervical section, the enamel is sound with

no evidence of defective structure. At a more occlusal level, the defect is confined to the inner enamel while the outer enamel does not appear to be affected. As move occlusally, the hypomineralisation becomes more evident, eventually spreading to span the entire thickness of the enamel. The defects usually did not involve the cusp tips; but if a marginal ridge was involved, its maximum height was affected. (Farah et al., 2010a)

Microstructural analysis of sound and hypomineralised enamel showed two marked changes in microstructure in the MIH affected enamel region; less dense prism structure with loosely packed apatite crystals and wider sheath regions. (Xie et al., 2008) These changes appear to occur during enamel maturation and may be responsible for the marked reduction in hardness and elastic modulus of the affected enamel. (Fagrell et al., 2010) In addition, the enamel in the transitional region adjacent to the demarcated defects in MIH has also notable alterations in their prism sheaths. Despite the translucent, normal appearance, the transitional region between the affected and unaffected regions in MIH teeth had weakened prism sheaths which compromised its overall mechanical properties. (Chan et al., 2010) The reason for this is unclear but may be also related to the lack of organization of the enamel crystals due poorly demarcated prism boundaries in the affected regions (Mahoney et al., 2004) and the packing of the crystals seemed to be less tight and less well organized in the porous parts. The borders of the enamel rods were indistinct and the interrod zones hardly visible, or the rods were very thin with wide interrod zones. (Jalevik et al., 2005)

Semi-quantitative analysis by energy dispersive X-ray spectrometry in extracted MIH affected teeth showed that the mineral composition of this type of enamel is low (Javelik & Norén, 2001), on average the mineral density is about 19 % lower than sound enamel (Baroni & Marchionni, 2011, Farah et al., 2010a, Jalevik & Noren, 2000, Schulze et al., 2004), there is a decrease in Ca:P ratio in the enamel (Rodd et al., 2007a, Jalevik, 2001) related to an increase in C content. (Fearne et al., 2004)

Also, MIH enamel has substantially higher protein content than normal enamel, but a near-normal level of residual amelogenins. This characteristic distinguishes MIH from hypomaturational defects that contain high residual amelogenins such as *Amelogenesis Imperfecta* or Fluorosis (Mangum et al., 2010a, Wright et al., 1996, Wright et al., 1997) and in turn typifies MIH as a hypocalcification defect as mentioned above. Pathogenically, it points to a pre-eruptive disturbance of mineralization involving albumin probably due to an over-abundance of albumin that interferes with the mineralisation process. It justifies the porosities exhibited in the subsurface (Jalevik & Noren, 2000) because albumin degradation may be a prerequisite for maximal crystal growth in the maturation stage of enamel. (Farah et al., 2010b, Farah et al., 2010c, Mangum et al., 2010b) The presence of excessive albumin seemed to be promote KLK4 inactivity resulting in enamel with elevated protein content and reduced mineral content. In cases of MIH with post-eruptive breakdown, on the exposed surface there is a subsequent protein adsorption on the exposed hydroxyapatite matrix. An indicator of the severity of MIH affected teeth is the actual organic content of its enamel (Farah et al., 2010a) Brown enamel, the most severe MIH lesion, has the highest protein content (15–21-fold greater), whilst the protein content of white/opaque and yellow enamel are both markedly higher (8-fold greater) than sound enamel. (Farah et al., 2010a) For sound enamel, when subjected to mechanical forces the controlling deformation mechanism was distributed shearing within nanometer thick protein layer between its

constituent mineral crystals; whereas for hypomineralised enamel micro cracking and subsequent crack growth were more evident in its less densely packed microstructure. (Xie et al., 2009) Thereafter, the ability of dental enamel to absorb energy and sustain deformation without catastrophic failure is attributed to its viscoelastic protein layers. Thus, the change in the protein content in teeth with MIH induces the enamel fracture when subjected to the masticatory efforts.

In relation to the dentin of MIH affected teeth it was observed that the Ca/P ratios for dentin below hypomineralized enamel were in principle identical to those of normal enamel; but when the Ca/C ratio was analyzed, dentin below hypomineralized enamel had the lowest values and the level of C was highest for dentin below hypomineralized enamel. In addition, O and P levels in dentin below normal enamel were higher compared with values in dentin below hypomineralized and N values for dentin below hypomineralized enamel are the highest. (Heijs et al., 2007)

This enhanced knowledge concerning the microstructural changes in hypomineralised enamel improves the understanding of some of the problems associated with the clinical management of these teeth. In particular, the frequent occurrence of enamel fractures and inadequate retention of adhesive materials both of which are recognized as significant clinical challenges preventing successful restoration of these compromised teeth. It is known that organic matter such as proteins have poor acid solubility. The presence of increased amounts of organic matter in the hypomineralised enamel, specifically within both prism structure and sheath regions may inhibit the creation of an adequate etch profile which in turn compromises the adhesion between resin based restorative materials and the defective enamel. (William et al., 2006b) Improved clinical outcomes are likely to depend, at least in part, on the successful treatment of these proteins prior to any enamel etching or adhesive strategies. (Baroni & Marchionni, 2011, Xie et al., 2008)

3. Aetiological considerations

Etiological factors of causing changes in organic/inorganic composition of MIH affected teeth are still unknown as showed by two systematic reviews. (Alaluusua, 2010, Crombie et al., 2009) As far, MIH may have a multifactor aetiology (Figure 3) acting additionally or even synergistically (Alaluusua, 2010, Crombie et al., 2009, Fagrell et al., 2011), with a genetic predisposition associated with one or more of a range of systemic insults occurring at a susceptible stage in the development of specific teeth. (Figure 3) It explains why in a seeming random manner several teeth are severely affected while their antimeres are unaffected. (Brook, 2009)

Notwithstanding, FAGRELL et al., 2011 (Fagrell et al., 2011) evaluated the etiological factors for severe demarcated enamel opacities in the first permanent molars from a database that contained approximately 4,000 variables with the purpose to prospectively investigate risk factors for immune mediate diseases in All Babies in Southeast Sweden project. Approximately, 17,000 children take part in the study. Medical data, information from interviews, questionnaires were collected at delivery, at 1, 2.5 years, of age with follow up at 5, at 8-9 and at 12 years. All information collected, about 4,000 variables for each child covering somatic growth: in pre-, peri-, and neonatal data from the child and its mother; diseases during first 3 years of child life; medication and vaccinations during the same

period, socioeconomic factors and nutrition during first 3 years of child life were entered into databank. Besides, in this study, randomly, there were two-age and sex-matched children to each MIH child. After a regression logistic analyses, the results showed a positive association between severe demarcated opacities in permanent first molars with breastfeeding for more than 6 months, late introduction of gruel and late introduction of infant formula. Moreover, a combination of these variables increased the risk to develop severe demarcated opacities by more five times. According these results, the authors concluded that nutritional conditions during first 6 months of life may influence the risk to develop severe demarcated opacities in first permanent molars. (Fagrell et al., 2011)

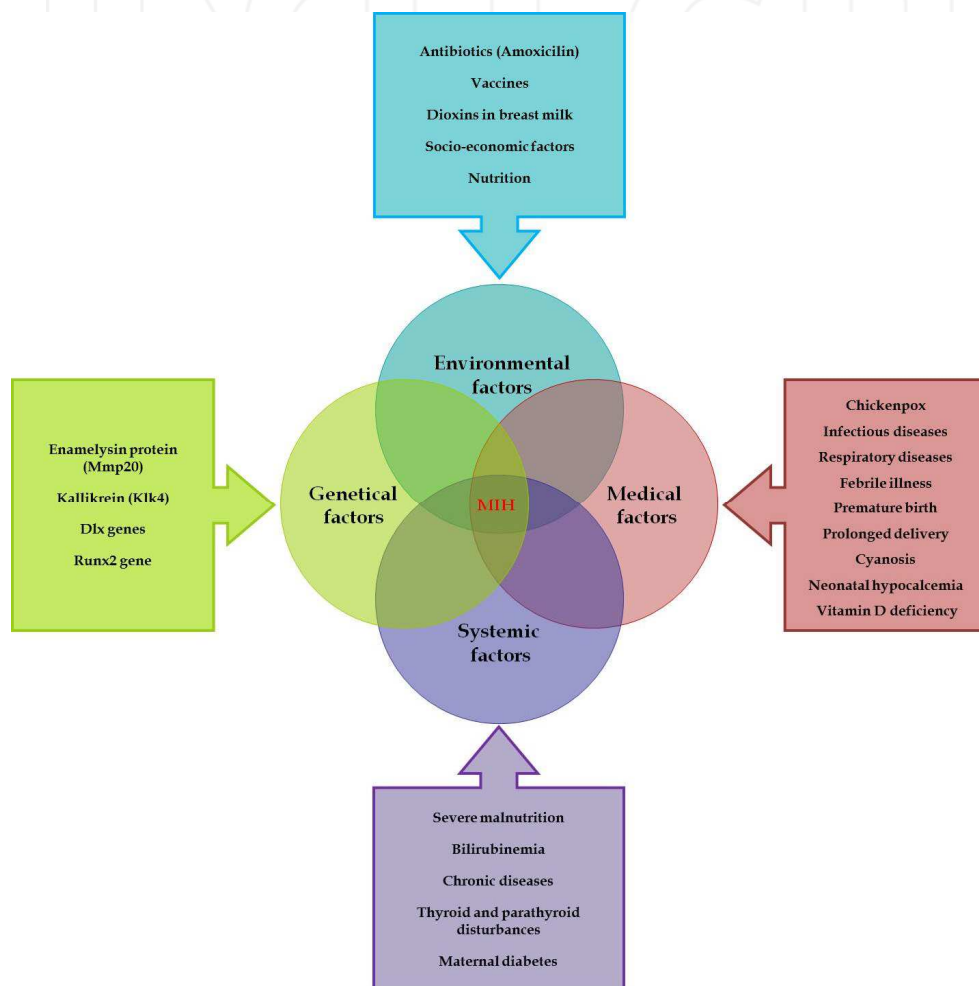

Fig. 3. Multifactorial aetiology of MIH

4. Epidemiological considerations about MIH

4.1 Diagnose of MIH

Traditionally, a wide variety of terms and definitions have been used to describe various developmental defects of enamel (DDE). However, this original index turned out to be too complicated to use in practice and a modified DDE index (mDDE) was presented by FDI (1992). The modified development dental enamel (DDE) index was considered to be too time consuming and not adequate for MIH prevalence studies because the post-eruptive breakdown is a pathognomonic feature in MIH but the mDDE index does not clearly distinguish PEB from enamel hypoplasia.

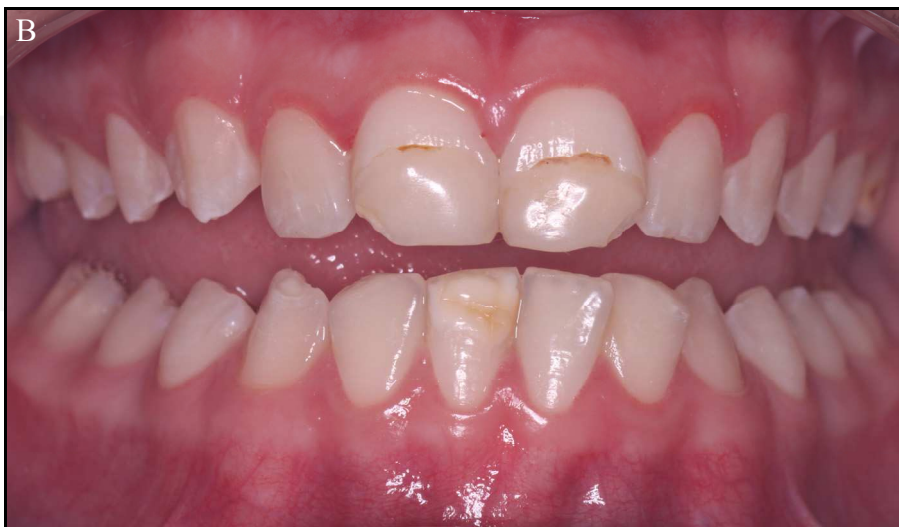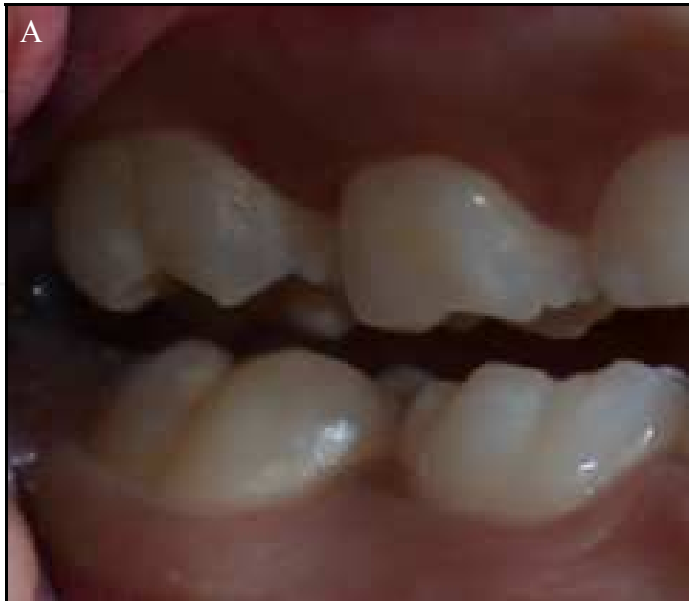According to European Academy of Pediatric Dentistry seminar (EAPD) placed in Athens in 2003. (Weerheijmet al., 2003) The diagnose of MIH must be based on scores range from 0 to 10 (Table 2). (Ghanim et al., 2011) The screening of MIH must be done in children eight years of age; examination for MIH should be performed on wet teeth after removing debris with cotton roll; first permanent molars and incisors should be examined, each tooth as seen in Table 2.

Code	Criteria
0	Enamel defect free
1	White/creamy demarcated opacities, no PEB
1a	White/creamy demarcated opacities, with PEB
2	Yellow/brown demarcated opacities, no PEB
2a	Yellow/brown demarcated opacities, with PEB
3	Atypical restoration
4	Missing because of MIH
5	Partially erupted (i.e., less than one-third of the crown high) with evidence of MIH
6	Unerupted/partially erupted with no evidence of MIH
7	Diffuse opacities (not MIH)
8	Hypoplasia (not MIH)
9	Combined lesion (diffuse opacities/hypoplasia with MIH)
10	Demarcated opacities in incisors only

Table 2. Criteria for scoring molar incisor hypomineralisation (MIH) according to European Academy of Paediatric Dentistry recommendations cited by GHANIM et al., 2011 (Ghanim et al., 2011).

Clinically, the enamel defects can vary from white, cream, yellow to brownish, but they always show a sharp demarcation between the affected and sound enamel. The tooth surface enamel initially develops to a normal thickness, but can chip off under masticatory forces called post eruption breakdown (PEB) (Figure 2B) PEB is characterized by poor aesthetic appearance and sensitivity to thermal and mechanical stimuli. After such PEB, the clinical pictures can resemble enamel hypoplasia. However, the margins of the disintegrated areas are irregular, whereas those in hypoplasia are smooth and rounded. The demarcated lesions in MIH should also be distinguished from the diffuse opacities typical of fluorosis. Dentitions with generalized opacities present on all teeth such as in Amelogenesis *Imperfecta*, rather than limited to the first permanent molars and incisors, are not considered to have MIH. Nowadays, to simplify the use of MIH scores, the severity of MIH can be

determined by dividing the affected teeth in only two groups: mild defect (demarcated opacities) (Figures 4A, B) and moderate/severe defect (enamel breakdown and atypical restorations) (Lygidakis et al., 2008) (Figures 4B, C).



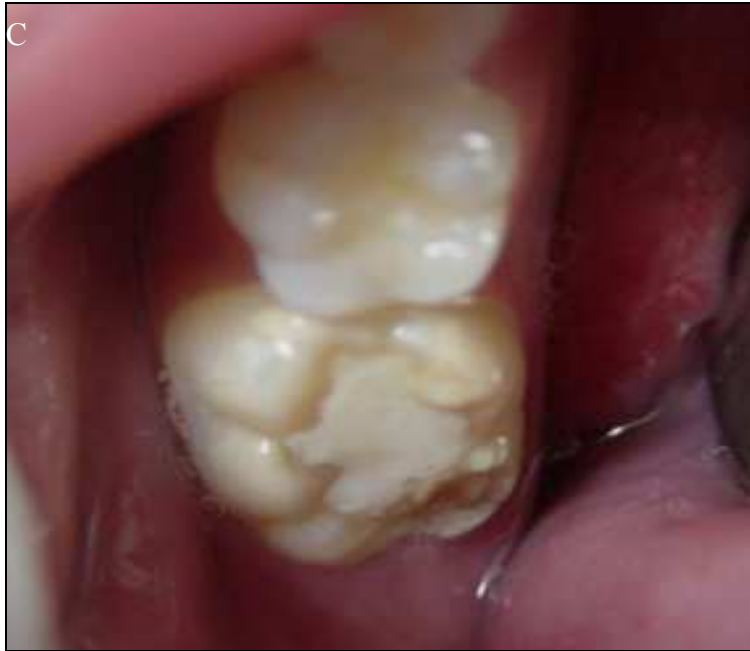

Fig. 4. A to C - Mild defect opacities in right FPM (A). Atypical restorations in upper incisors (B) and in left lower FPM (C). Note the opacities in the vestibular surface of the right lower incisor (B), left upper FPM (B). Post restoration enamel fracture in lower right FPM (C).

Dental diseases have a detrimental effect on quality of life both in childhood and older age. (Moynihan & Petersen, 2004) Several authors have discussed whether developmental defects of enamel (DDE) are a public health problem. (Mathu-Muju & Wright, 2006) For a condition to be considered of public health significance, several criteria need to be reviewed, particularly the prevalence its impact on an individual in terms of symptoms, functioning, psychological and social should be considerate. (Marshman et al., 2009) Besides its clinical implications in the field of public health, MIH have taken on importance as strong predictors of dental caries. This result highlights the importance of establishing priority programs of prevention and early treatment for these groups of children both for aesthetic and functional reasons, as well as to minimize the increased risk of dental caries.

In view of MIH having a potentially large impact on treatment needs in child populations and a cost-effectiveness treatment from public or private health insurance, it is relevant to identify the prevalence of MIH in epidemiological studies, with the concern only studies using the MIH index as epidemiological criteria. (Weerheijm et al., 2003, Weerheijm et al., 2001, Weerheijm, 2003)

4.2 Prevalence of MIH

A first epidemiological study was carried out in Swedish children in the late 1970s, whose first permanent molars (FPM) called "cheese" molars, were described as creamy-white to yellow-brown enamel opacities; or with disintegration in severe cases (Koch et al., 1987)

After that, epidemiological data comes from studies conducted in European countries and reported the prevalence of MIH had varied from 3.6 to 25%. (Weerheijm & Mejare, 2003) Lately, a systematic review showed a wide variation in the prevalence of MIH (2.4 - 40.2 %) and stated that the cross comparison of the results of the various studies were difficult because of use of different indices and criteria, examination variability, methods of recording and different age groups. (Jalevik, 2010)

Based on this, we performed a nonsystematic hand-searching screening in the PUBMED data base using the terms: EAPD; MIH; limited to: at least 100 subjects and the data of study - after 2003 and the results could be found (Table 3). According to results, it was possible observed that at least one country in each continent already demonstrates concern for the impact of MIH regarding the condition of oral health of the population, which makes it a public health problem. Taking searching results of the more recent studies into account, the prevalence of MIH varies from 3.5% to 40.2%. This could be explained by methodological variability, by different socio-demographic-ethnic characteristics of samples and by the access to health services (favorable x unfavorable). It worthwhile mentions that only one population-based well designed study could be found and it highlights the prevalence of 3.5% for MIH in Southeast Sweden. (Fagrell et al., 2011) These results are also found in China and Bulgaria epidemiological surveys.

Country	Prevalence	Subjects (n)	Years age (mean \pm SD)	Authors
Argentina	15.9%	1,098	11.3 years (11.08-11.39)	Biondi et al, 2011 (Biondi et al., 2011)
Boznia and Herzegovina	12.3%	560	12 years	Muratbegovic et al., 2008 (Muratbegovic et al., 2008)
Brazil	19.8%	918	6-12 years	da Costa-Silva et al., 2010 (da Costa-Silva et al., 2010)
Brazil	40.2%	249	7-13 years	Soviero et al., 2009 (Soviero et al., 2009)
Bulgaria	3.58%	2,960	7-14 years	Kukleva et al., 2008 (Kukleva et al., 2008)
China	2.8%	2,635	11.0-14.0 years (12 years \pm 0.6)	Cho et al., 2008 (Cho et al., 2008)
Germany	14.3%	442	9 years	Jasulaityte et al., 2008 (Jasulaityte et al., 2008)
Greece	10.2%	3,518	5.5-12 years (8.17 \pm 1.38)	Lygidakis et al., 2008 (Lygidakis et al., 2008)
Instanbul	14.9%	147	7-9 years	Kusku et al., 2008 (Kusku et al., 2008)
Iraq	21.5%	823	7-9 years	Ghanim et al., 2011 (Ghanim et al., 2011)
Jordan	17.6%	3,666	7-9 years	Zawaideh et al., 2011 (Zawaideh et al., 2011)

Country	Prevalence	Subjects (n)	Years age (mean \pm SD)	Authors
Libya	9%	378	7-8.9 years	Fteita et al., 2006 (Fteita et al., 2006)
Lithuania	14.9%	1,277	7-9 years	Jasulaityte et al., 2007 (Jasulaityte et al., 2007)
Northern England	15.9%	3,233	12 years	Balmer et al., 2011 (Balmer et al., 2011)
Southeast Sweden	3.5%	17,055	Children born from 1, October-1997 to 1, 1999	Fagell et al., 2011 (Fagrell et al., 2011)
Spain	17.8%	505	6-14 years	Martinez Gomez et al., 2011 (Martinez Gomez et al., 2011)

Table 3. Distribution of MIH in some countries in the world. Selected studies were conducted using only MIH index criteria as suggested by EAPD.

In spite of having still need of further investigation considering population-based samples, with standardization of methodology, it is clearly seen that different countries from different regions of the world are performing epidemiological surveys using MIH index. This is essential to ascertain the occurrence of the MIH and may otherwise be systematized not only strategies to MIH diagnosis, but also treatments and monitoring as well as outlining scientific researches considering this topic. Thus, it is essential to do well design clinical studies considering MIH pathology.

5. Clinical considerations and management of MIH

5.1 Dentino-pulpal complex considerations and MIH

Patients with MIH affected teeth suffer from dentine sensitivity once often report exacerbated sensitivity to a variety of normally innocuous thermal, mechanical and osmochemical stimuli (Jalevik & Klingberg, 2002) due to the presence of porous enamel and sometimes, the exposed dentine. Based on the immunocytochemical findings in hypomineralised permanent first molars, changes in pulpal innervation, vascularity, and immune cell accumulation were indicative of an inflammatory response. (Rodd et al., 2007a) Besides, the morphological aspects of MIH may favor ingress of bacterial contaminants (Fagrell et al., 2008), thereby resulting in chronic inflammation of the pulp (Rodd et al., 2007b) Following tissue inflammation, a variety of morphological and cytochemical neuronal changes may occur including neuronal branching and altered expression of neuropeptides and ion channels (Rodd et al., 2007b, Rodd & Boissonade, 2002) that seems to be related with an overexpressed dental sensitive.

From a clinical perspective, these findings would support early interventions in order to avoid the development of pulpal inflammation and associated hypersensitivity. Thus, toothpastes and/or chewing gums with mineralizing products, such as Casein

Phosphopeptide-Amorphous Calcium Phosphate (CCP-ACP) (Baroni & Marchionni, 2011) or the application of desensitizers (2 % potassium nitrate plus 2% sodium fluoride) or sealers have been indicated. (Lygidakis et al., 2010, Lygidakis, 2010)

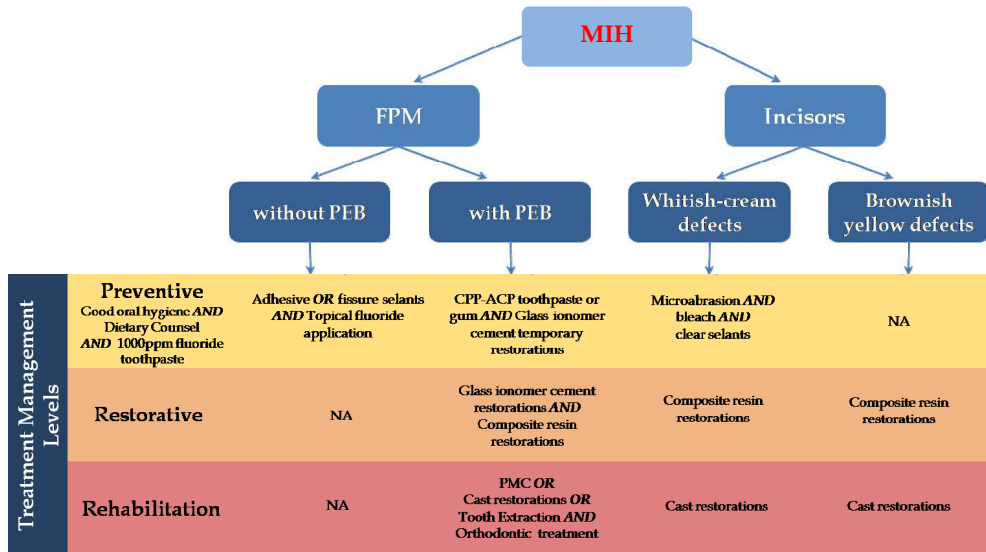
Dental pain and the severity of hypomineralisation or enamel loss in molar-incisor hypomineralisation are major determinants for the choice of treatment. (William et al., 2006a) The most conservative interventional treatment consists of bonding a tooth colored material to the tooth to protect it from further wear or sensitivity although the nature of the enamel prevents formation of an acceptable bond. (William et al., 2006b) Less conservative treatment options, but frequently necessary include use of stainless steel crowns, permanent cast crowns or extraction of affected teeth in association with the orthodontic appliance or teeth replacement with a bridge or implant.

5.2 Clinical management of MIH

In accordance with the European Academy of Pediatric Dentistry until now there are only a limited number of evidence based research papers on MIH affected teeth. (Lygidakis et al., 2010) Because of this, the guidelines diagram according to Scottish Intercollegiate Guidelines Network (SIGN) methodology (SIGN, 1999) is impossible to be made. However, treatment modalities in children with teeth affected by MIH were systematically reviewed by LYGIDAKIS, 2010. (Lygidakis, 2010) Thus, the clinical management of MIH was resumed by the present authors as seen in Figure 5. These clinical guidelines approach were organized considering the type of MIH affected teeth (permanent first molars or incisors) and the severity of defects. Then, it was also considered, the treatment management of the first permanent molars (FPM) without post eruptive breakdown (PEB) or with post-eruptive breakdown; as well as to the incisors with different levels of opacities (Figure 3). It worthwhile be emphasized the necessity of not only randomized controlled clinical trials but also the laboratory studies to support and better understand the specificities of MIH condition.

Therefore, a detailed study under magnification of the unerupted molar and incisor crowns on any available radiographs should be done. (William et al., 2006a) During teeth eruption, when MIH is confirmed, it should be made a diet counseling for dietary modifications to avoid dental caries, dental erosion and dental sensitivity; It should be recommended a toothpaste with a fluoride or, in cases of dental sensitivity, aiming to produce a non-sensitivity and hypermineralized surface layer which provides a super saturated environment of calcium and phosphate on enamel surface, a desensitizing toothpaste with casein phosphopeptide-amorphous calcium phosphate (CPP-ACP) should be indicated. (Baroni & Marchionni, 2011)

Fissure sealants should be applied early after molars eruption and before enamel breakdown. (Kilpatrick, 2009, Lygidakis et al., 2010, Lygidakis, 2010, William et al., 2006a, Crombie et al., 2008) Taking the morphological aspects of MIH affected teeth into account, for first permanent molars, highly viscosity glass ionomer cements can be considered as an alternative material of choice for fissure sealing due to its stable chemical adhesion on the substrate (Welbury et al., 2004) which ensures its clinical longevity even if disappeared macroscopically in the follow-ups. (Frencken & Wolke, 2010)



NA - Not applicable

Fig. 5. Flow chart illustrated by the authors of clinical management of MIH Children with a history of putative aetiological factors in the first 3 years should be screening at risk for MIH (Alaluusua, 2010, Crombie et al., 2009, Fagrell et al., 2011)

As suggested by LIGYDIKIS ET AL., 2010 (Lygidakis et al., 2010), when children express their concern on mild discolorations, at late mixed dentition, incisors with whitish-creamy opacities may occasionally respond to bleaching with carbamide peroxide. (Fayle, 2003) Another conservative approach is microabrasion with either 18% hydrochloric acid or 37% phosphoric acid and pumice for 60s. (Lygidakis et al., 2010, Wright, 2002, Gotler & Ratson, 2010, Willmott et al., 2008) More pronounced enamel defects might be dealt with by combining the two methods (Sundfeld et al., 2007a), bleaching and microabrasion. However, bleaching for young children may induce hypersensitivity, mucosal irritation and enamel surface alterations (Joiner, 2006), whilst microabrasion may result in loss of enamel. (Sundfeld et al., 2007b) An etch-bleach-seal technique by involving:

- 60 seconds etch with 37% phosphoric acid;
- bleach with 5% sodium hypochlorite for 5-10 min.
- re-etch and application of fissure sealant over the surface to occlude the porosities appears as another management treatment possibility. (Wright, 2002)

On the other hand, the replacement of micro-abrasion by local enamel thickness reduction, using high-speed headpiece, should be also evaluated by the professional.

The others clinical problems for patients with MIH are attrition, exposed dentin, atypical cavities or complete coronal destruction. (Kilpatrick, 2009, Jalevik & Noren, 2000) Moreover, pain experience during dental treatment has led some MIH children to be significantly less compliant and more dentally anxious than their peers. (Jalevik & Klingberg, 2002) In this

case, the adjunctive use of nitrous oxide-oxygen analgesia may alleviate anxiety and reduce dental pain. In last case, general anesthesia may be required for restorative treatment. (William et al., 2006a) The maintenance of existing tooth structure and pain relief can be achieved with temporary restorations, often in sub-optimal clinical conditions, through the use of glass ionomer cements. In mild and moderate MIH cases composite restorations using self-etching primer adhesive bonding systems is the treatment of choice (William et al., 2006b) and may last for many years until indirect restorations would be placed. (Lygidakis et al., 2010, Lygidakis, 2010) For cavities involving large areas of dentine, glass ionomer cement has been proposed to be used as a sub-layer under the composite restoration (Mathu-Muju & Wright, 2006). A more definitive restorative approach, albeit still temporary solution, is the preformed metal crown (PMC) which placed on first permanent molars provide an excellent medium term restorative solution. (Kilpatrick, 2009) For that, it requires an excellent analgesia and patient cooperation which may not be forthcoming. In severe cases, transitional treatment for function and aesthetics can be provided until adolescence when permanent prosthetic approach with crowns in molars and veneers or crowns in incisors can be indicated. Cast restorations (full coverage crown, tooth-colored crown, porcelains or veneers) have been used. (Lygidakis et al., 2010, Lygidakis, 2010) However, they are not recommended for teeth in early post-eruptive stage because of the continuous eruption exposing the crown margins, the large pulp size, short crown height, and difficulties in obtaining a good impression for subgingival crown margins. (Koch & Garcia-Godoy, 2000) At last case, any extraction of first permanent molars should only be carried out with consideration of the possible orthodontic implications.

6. Conclusion

Despite a fall in the prevalence and in the speed of progression of dental caries disease, often, the clinicians and the pedodontics can find first permanent molars and incisors with hypomineralised enamel defected. MIH must be regarded as a public health problem which brings painful consequences, aesthetic and a negative impact on the quality of life of individuals suffering from MIH. A difficult and complex problem resolution, therefore all effort should converge towards the sense of real knowledge of the MIH aetiology to allow more accurate diagnosis and more appropriate treatment. People seized with MIH pathology have made sure that their expectations in relation to intervention proposal is based on high efficiency and effectiveness scientific evidences by ensuring the quality of life not only these people but also of their families. The etiology of MIH as a result of synergistic action of environmental factors and, suddenly genetic expressions leaving disturbances in enamel formation of molars and incisors in the first year of life, is the challenge to be overcome. Ultimately, the discovery of new genes and novel proteins such as amelotin and apin (Nishio, 2008) that they are also produced by ameloblasts, but during the stage of maturation, with important enamel mineralization function in relation to obtaining final hardness of enamel point to a promissory future in relation to knowledge of dental development. Well-being, understanding the genetic sequential and signaling pathways of developmental normal of enamel will provide us with an invaluable tool for understanding the pathways and mechanisms of tissue maintenance, repair and regeneration. It will enable us to manipulate genetic and environmental factors and ultimately, aid in the development of dental developmental defects of enamel therapy.

7. Acknowledgment

We would like to thank Ms. Maja Bozicevic for giving us the opportunity to write this chapter, Andre Caula for illustrations and Andre Alves for technical support.

8. References

- (1992). A review of the developmental defects of enamel index (DDE Index). Commission on Oral Health, Research & Epidemiology. Report of an FDI Working Group. *Int Dent J*. Vol. 42, No. 6, (Dec, 1992), pp. 411-426. 0020-6539 (Print) 0020-6539 (Linking) 0164-1263 (Linking)
- Alaluusua, S. (2010). Aetiology of Molar-Incisor Hypomineralisation: A systematic review. *Eur Arch Paediatr Dent*. Vol. 11, No. 2, (Apr, 2010), pp. 53-58. 1818-6300 (Print) 1818-6300 (Linking)
- Balmer, R. et al. (2011). The prevalence of molar incisor hypomineralisation in Northern England and its relationship to socioeconomic status and water fluoridation. *Int J Paediatr Dent*, No., (Oct 20, 2011), 1365-263X (Electronic) 0960-7439 (Linking)
- Baroni, C. & Marchionni, S. (2011). MIH supplementation strategies: prospective clinical and laboratory trial. *J Dent Res*. Vol. 90, No. 3, (Mar, 2011), pp. 371-376. 1544-0591 (Electronic) 0022-0345 (Linking)
- Bartlett, J. D. et al. (2011). MMP20 cleaves E-cadherin and influences ameloblast development. *Cells Tissues Organs*. Vol. 194, No. 2-4, 2011), pp. 222-226. 1422-6421 (Electronic) 1422-6405 (Linking)
- Biondi, A. M. et al. (2011). Prevalence of molar incisor hypomineralization in the city of Buenos Aires. *Acta Odontol Latinoam*. Vol. 24, No. 1, 2011), pp. 81-85. 0326-4815 (Print) 0326-4815 (Linking)
- Brook, A. H. (2009). Multilevel complex interactions between genetic, epigenetic and environmental factors in the aetiology of anomalies of dental development. *Arch Oral Biol*. Vol. 54 Suppl 1, No., (Dec, 2009), pp. S3-17. 1879-1506 (Electronic) 0003-9969 (Linking)
- Chan, Y. L. et al. (2010). Degraded prism sheaths in the transition region of hypomineralized teeth. *J Dent*. Vol. 38, No. 3, (Mar, 2010), pp. 237-244. 1879-176X (Electronic) 0300-5712 (Linking)
- Chawla, N. et al. (2008). Clinical studies on molar-incisor-hypomineralisation part 1: distribution and putative associations. *Eur Arch Paediatr Dent*. Vol. 9, No. 4, (Dec, 2008), pp. 180-190. 1818-6300 (Print) 1818-6300 (Linking)
- Cho, S. Y. et al. (2008). Molar incisor hypomineralization in Hong Kong Chinese children. *Int J Paediatr Dent*. Vol. 18, No. 5, (Sep, 2008), pp. 348-352. 1365-263X (Electronic) 0960-7439 (Linking)
- Crombie, F. A. et al. (2008). Molar incisor hypomineralization: a survey of members of the Australian and New Zealand Society of Paediatric Dentistry. *Aust Dent J*. Vol. 53, No. 2, (Jun, 2008), pp. 160-166. 0045-0421 (Print) 0045-0421 (Linking)
- Crombie, F. et al. (2009). Aetiology of molar-incisor hypomineralization: a critical review. *Int J Paediatr Dent*. Vol. 19, No. 2, (Mar, 2009), pp. 73-83. 1365-263X (Electronic) 0960-7439 (Linking)

- da Costa-Silva, C. M. et al. (2010). Molar incisor hypomineralization: prevalence, severity and clinical consequences in Brazilian children. *Int J Paediatr Dent.* Vol. 20, No. 6, (Nov, 2010), pp. 426-434. 1365-263X (Electronic) 0960-7439 (Linking)
- Denny, P. et al. (2008). The proteomes of human parotid and submandibular/sublingual gland salivas collected as the ductal secretions. *J Proteome Res.* Vol. 7, No. 5, (May, 2008), pp. 1994-2006. 1535-3893 (Print) 1535-3893 (Linking)
- Fagrell, T. G. et al. (2008). Bacterial invasion of dentinal tubules beneath apparently intact but hypomineralized enamel in molar teeth with molar incisor hypomineralization. *Int J Paediatr Dent.* Vol. 18, No. 5, (Sep, 2008), pp. 333-340. 1365-263X (Electronic) 0960-7439 (Linking)
- Fagrell, T. G. et al. (2010). Chemical, mechanical and morphological properties of hypomineralized enamel of permanent first molars. *Acta Odontol Scand.* Vol. 68, No. 4, (Jul, 2010), pp. 215-222. 1502-3850 (Electronic) 0001-6357 (Linking)
- Fagrell, T. G. et al. (2011). Aetiology of severe demarcated enamel opacities—an evaluation based on prospective medical and social data from 17,000 children. *Swed Dent J.* Vol. 35, No. 2, (2011), pp. 57-67. 0347-9994 (Print) 0347-9994 (Linking)
- Farah, R. A. et al. (2010b). Protein content of molar-incisor hypomineralisation enamel. *J Dent.* Vol. 38, No. 7, (Jul, 2010b), pp. 591-596. 1879-176X (Electronic) 0300-5712 (Linking)
- Farah, R. A. et al. (2010c). Mineral density of hypomineralised enamel. *J Dent.* Vol. 38, No. 1, (Jan, 2010c), pp. 50-58. 1879-176X (Electronic) 0300-5712 (Linking)
- Farah, R. et al. (2010a). Linking the clinical presentation of molar-incisor hypomineralisation to its mineral density. *Int J Paediatr Dent.* Vol. 20, No. 5, (Sep 1, 2010a), pp. 353-360. 1365-263X (Electronic) 0960-7439 (Linking)
- Fayle, S. A. (2003). Molar incisor hypomineralisation: restorative management. *Eur J Paediatr Dent.* Vol. 4, No. 3, (Sep, 2003), pp. 121-126. 1591-996X (Print) 1591-996X (Linking)
- Fearne, J. et al. (2004). 3D X-ray microscopic study of the extent of variations in enamel density in first permanent molars with idiopathic enamel hypomineralisation. *Br Dent J.* Vol. 196, No. 10, (May 22, 2004), pp. 634-638; discussion 625. 0007-0610 (Print) 0007-0610 (Linking)
- Fearne, J. M. et al. (1994). Deciduous enamel defects in low-birth-weight children: correlated X-ray microtomographic and backscattered electron imaging study of hypoplasia and hypomineralization. *Anat Embryol (Berl).* Vol. 189, No. 5, (May, 1994), pp. 375-381. 0340-2061 (Print) 0340-2061 (Linking)
- Frencken, J. E. & Wolke, J. (2010). Clinical and SEM assessment of ART high-viscosity glass-ionomer sealants after 8-13 years in 4 teeth. *J Dent.* Vol. 38, No. 1, (Jan, 2010), pp. 59-64. 1879-176X (Electronic) 0300-5712 (Linking)
- Fteita, D. et al. (2006). Molar-incisor hypomineralization (MIH) in a group of school-aged children in Benghazi, Libya. *Eur Arch Paediatr Dent.* Vol. 7, No. 2, (Jun, 2006), pp. 92-95. 1818-6300 (Print) 1818-6300 (Linking)
- Ghanim, A. et al. (2011). Molar-incisor hypomineralisation: prevalence and defect characteristics in Iraqi children. *Int J Paediatr Dent.* Vol. 21, No. 6, (Nov, 2011), pp. 413-421. 1365-263X (Electronic) 0960-7439 (Linking)

- Gotler, M. & Ratson, T. (2010). Molar incisor hypomineralization (MIH)--a literature review. *Refuat Hapeh Vehashinayim*. Vol. 27, No. 2, (Apr, 2010), pp. 10-18, 60. 0792-9935 (Print) 0792-9935 (Linking)
- Heijs, S. C. et al. (2007). Morphology and chemical composition of dentin in permanent first molars with the diagnose MIH. *Swed Dent J*. Vol. 31, No. 4, (2007), pp. 155-164. 0347-9994 (Print) 0347-9994 (Linking)
- Jalevik, B. (2001). Enamel hypomineralization in permanent first molars. A clinical, histomorphological and biochemical study. *Swed Dent J Suppl*, No. 149, (2001), pp. 1-86. 0348-6672 (Print) 0348-6672 (Linking)
- Jalevik, B. (2010). Prevalence and Diagnosis of Molar-Incisor- Hypomineralisation (MIH): A systematic review. *Eur Arch Paediatr Dent*. Vol. 11, No. 2, (Apr, 2010), pp. 59-64. 1818-6300 (Print) 1818-6300 (Linking)
- Jalevik, B. et al. (2005). Scanning electron micrograph analysis of hypomineralized enamel in permanent first molars. *Int J Paediatr Dent*. Vol. 15, No. 4, (Jul, 2005), pp. 233-240. 0960-7439 (Print) 0960-7439 (Linking)
- Jalevik, B. & Klingberg, G. A. (2002). Dental treatment, dental fear and behaviour management problems in children with severe enamel hypomineralization of their permanent first molars. *Int J Paediatr Dent*. Vol. 12, No. 1, (Jan, 2002), pp. 24-32. 0960-7439 (Print) 0960-7439 (Linking)
- Jalevik, B. & Noren, J. G. (2000). Enamel hypomineralization of permanent first molars: a morphological study and survey of possible aetiological factors. *Int J Paediatr Dent*. Vol. 10, No. 4, (Dec, 2000), pp. 278-289. 0960-7439 (Print) 0960-7439 (Linking)
- Jasulaityte, L. et al. (2007). Molar incisor hypomineralization: review and prevalence data from the study of primary school children in Kaunas/Lithuania. *Eur Arch Paediatr Dent*. Vol. 8, No. 2, (Jun, 2007), pp. 87-94. 1818-6300 (Print) 1818-6300 (Linking)
- Jasulaityte, L. et al. (2008). Prevalence of molar-incisor-hypomineralisation among children participating in the Dutch National Epidemiological Survey (2003). *Eur Arch Paediatr Dent*. Vol. 9, No. 4, (Dec, 2008), pp. 218-223. 1818-6300 (Print) 1818-6300 (Linking)
- Joiner, A. (2006). The bleaching of teeth: a review of the literature. *J Dent*. Vol. 34, No. 7, (Aug, 2006), pp. 412-419. 0300-5712 (Print) 0300-5712 (Linking)
- Kilpatrick, N. (2009). New developments in understanding development defects of enamel: optimizing clinical outcomes. *J Orthod*. Vol. 36, No. 4, (Dec, 2009), pp. 277-282. 1465-3133 (Electronic) 1465-3125 (Linking)
- Koch, G. et al. (1987). Epidemiologic study of idiopathic enamel hypomineralization in permanent teeth of Swedish children. *Community Dent Oral Epidemiol*. Vol. 15, No. 5, (Oct, 1987), pp. 279-285. 0301-5661 (Print) 0301-5661 (Linking)
- Koch, M. J. & Garcia-Godoy, F. (2000). The clinical performance of laboratory-fabricated crowns placed on first permanent molars with developmental defects. *J Am Dent Assoc*. Vol. 131, No. 9, (Sep, 2000), pp. 1285-1290. 0002-8177 (Print) 0002-8177 (Linking)
- Kojima, T. et al. (2000). Human gingival crevicular fluid contains MRP8 (S100A8) and MRP14 (S100A9), two calcium-binding proteins of the S100 family. *J Dent Res*. Vol. 79, No. 2, (Feb, 2000), pp. 740-747. 0022-0345 (Print) 0022-0345 (Linking)

- Kotsanos, N. et al. (2005). Treatment management of first permanent molars in children with Molar-Incisor Hypomineralisation. *Eur J Paediatr Dent*. Vol. 6, No. 4, (Dec, 2005), pp. 179-184. 1591-996X (Print) 1591-996X (Linking)
- Kukleva, M. P. et al. (2008). Molar incisor hypomineralisation in 7-to-14-year old children in Plovdiv, Bulgaria--an epidemiologic study. *Folia Med (Plovdiv)*. Vol. 50, No. 3, (Jul-Sep, 2008), pp. 71-75. 0204-8043 (Print) 0204-8043 (Linking)
- Kusku, O. O. et al. (2008). The prevalence and aetiology of molar-incisor hypomineralisation in a group of children in Istanbul. *Eur J Paediatr Dent*. Vol. 9, No. 3, (Sep, 2008), pp. 139-144. 1591-996X (Print) 1591-996X (Linking)
- Lygidakis, N. A. (2010). Treatment modalities in children with teeth affected by molar-incisor enamel hypomineralisation (MIH): A systematic review. *Eur Arch Paediatr Dent*. Vol. 11, No. 2, (Apr, 2010), pp. 65-74. 1818-6300 (Print) 1818-6300 (Linking)
- Lygidakis, N. A. et al. (2008). Molar-incisor-hypomineralisation (MIH). Retrospective clinical study in Greek children. I. Prevalence and defect characteristics. *Eur Arch Paediatr Dent*. Vol. 9, No. 4, (Dec, 2008), pp. 200-206. 1818-6300 (Print) 1818-6300 (Linking)
- Lygidakis, N. A. et al. (2010). Best Clinical Practice Guidance for clinicians dealing with children presenting with Molar-Incisor-Hypomineralisation (MIH): An EAPD Policy Document. *Eur Arch Paediatr Dent*. Vol. 11, No. 2, (Apr, 2010), pp. 75-81. 1818-6300 (Print) 1818-6300 (Linking)
- Mahoney, E. et al. (2004). Mechanical properties across hypomineralized/hypoplastic enamel of first permanent molar teeth. *Eur J Oral Sci*. Vol. 112, No. 6, (Dec, 2004), pp. 497-502. 0909-8836 (Print) 0909-8836 (Linking)
- Mangum, J. E. et al. (2010a). Surface integrity governs the proteome of hypomineralized enamel. *J Dent Res*. Vol. 89, No. 10, (Oct, 2010a), pp. 1160-1165. 1544-0591 (Electronic) 0022-0345 (Linking)
- Mangum, J. E. et al. (2010b). Proteomic analysis of dental tissue microsamples. *Methods Mol Biol*. Vol. 666, No., 2010b), pp. 309-325. 1940-6029 (Electronic) 1064-3745 (Linking)
- Marshman, Z. et al. (2009). The impact of developmental defects of enamel on young people in the UK. *Community Dent Oral Epidemiol*. Vol. 37, No. 1, (Feb, 2009), pp. 45-57. 1600-0528 (Electronic) 0301-5661 (Linking)
- Martinez Gomez, T. P. et al. (2011). Prevalence of molar-incisor hypomineralisation observed using transillumination in a group of children from Barcelona (Spain). *Int J Paediatr Dent*, No., (Aug 24, 2011), 1365-263X (Electronic) 0960-7439 (Linking)
- Mathu-Muju, K.&Wright, J. T. (2006). Diagnosis and treatment of molar incisor hypomineralization. *Compend Contin Educ Dent*. Vol. 27, No. 11, (Nov, 2006), pp. 604-610; quiz 611. 1548-8578 (Print) 1548-8578 (Linking)
- Moynihhan, P. & Petersen, P. E. (2004). Diet, nutrition and the prevention of dental diseases. *Public Health Nutr*. Vol. 7, No. 1A, (Feb, 2004), pp. 201-226. 1368-9800 (Print) 1368-9800 (Linking)
- Muratbegovic, A. et al. (2008). Molar-incisor-hypomineralisation impact on developmental defects of enamel prevalence in a low fluoridated area. *Eur Arch Paediatr Dent*. Vol. 9, No. 4, (Dec, 2008), pp. 228-231. 1818-6300 (Print) 1818-6300 (Linking)
- Nishio C. Formação do esmalte dentário, novas descobertas, novos horizontes. *R Dental Press Ortodon Ortop Facial Maringá*, v. 13, n. 4, p. 17-18, jul./ago. 2008.

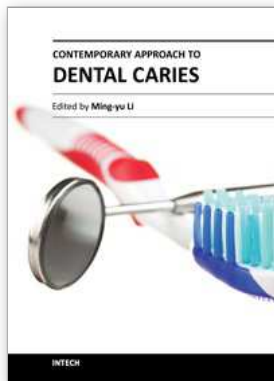
- Reid, D. J. & Dean, M. C. (2006). Variation in modern human enamel formation times. *J Hum Evol.* Vol. 50, No. 3, (Mar, 2006), pp. 329-346. 0047-2484 (Print) 0047-2484 (Linking)
- Reid, D. J. & Ferrell, R. J. (2006). The relationship between number of striae of Retzius and their periodicity in imbricational enamel formation. *J Hum Evol.* Vol. 50, No. 2, (Feb, 2006), pp. 195-202. 0047-2484 (Print) 0047-2484 (Linking)
- Rodd, H. D. et al. (2007a). Pulpal status of hypomineralized permanent molars. *Pediatr Dent.* Vol. 29, No. 6, (Nov-Dec, 2007a), pp. 514-520. 0164-1263 (Print) 0164-1263 (Linking)
- Rodd, H. D. et al. (2007b). Pulpal expression of TRPV1 in molar incisor hypomineralisation. *Eur Arch Paediatr Dent.* Vol. 8, No. 4, (Dec, 2007b), pp. 184-188. 1818-6300 (Print) 1818-6300 (Linking)
- Rodd, H. D. & Boissonade, F. M. (2002). Comparative immunohistochemical analysis of the peptidergic innervation of human primary and permanent tooth pulp. *Arch Oral Biol.* Vol. 47, No. 5, (May, 2002), pp. 375-385. 0003-9969 (Print) 0003-9969 (Linking)
- Schulze, K. A. et al. (2004). Micro-Raman spectroscopic investigation of dental calcified tissues. *J Biomed Mater Res A.* Vol. 69, No. 2, (May 1, 2004), pp. 286-293. 1549-3296 (Print) 1549-3296 (Linking) Scottish Intercollegiate Guidelines Network. Clinical guidelines and SIGN. March, 2004, pp:1
<http://cys.bvsalud.org/lildbi/docsonline/9/5/159-sign50section1.pdf> Accessed: Nov 2011.
- Smith, C. E. (1979). Ameloblasts: secretory and resorptive functions. *J Dent Res.* Vol. 58, No. Spec Issue B, (Mar, 1979), pp. 695-707. 0022-0345 (Print) 0022-0345 (Linking)
- Soviero, V. et al. (2009). Prevalence and distribution of demarcated opacities and their sequelae in permanent 1st molars and incisors in 7 to 13-year-old Brazilian children. *Acta Odontol Scand.* Vol. 67, No. 3, (2009), pp. 170-175. 1502-3850 (Electronic) 0001-6357 (Linking)
- Suckling, G. et al. (1988). The macroscopic and scanning electron-microscopic appearance and microhardness of the enamel, and the related histological changes in the enamel organ of erupting sheep incisors resulting from a prolonged low daily dose of fluoride. *Arch Oral Biol.* Vol. 33, No. 5, (1988), pp. 361-373. 0003-9969 (Print) 0003-9969 (Linking)
- Suckling, G. W. (1989). Developmental defects of enamel--historical and present-day perspectives of their pathogenesis. *Adv Dent Res.* Vol. 3, No. 2, (Sep, 1989), pp. 87-94. 0895-9374 (Print) 0895-9374 (Linking)
- Suga, S. (1989). Enamel hypomineralization viewed from the pattern of progressive mineralization of human and monkey developing enamel. *Adv Dent Res.* Vol. 3, No. 2, (Sep, 1989), pp. 188-198. 0895-9374 (Print) 0895-9374 (Linking)
- Sundfeld, R. H. et al. (2007a). Enamel microabrasion followed by dental bleaching for patients after orthodontic treatment--case reports. *J Esthet Restor Dent.* Vol. 19, No. 2, (2007a), pp. 71-77; discussion 78. 1496-4155 (Print) 1496-4155 (Linking)
- Sundfeld, R. H. et al. (2007b). Considerations about enamel microabrasion after 18 years. *Am J Dent.* Vol. 20, No. 2, (Apr, 2007b), pp. 67-72. 0894-8275 (Print) 0894-8275 (Linking)
- van Amerongen, W. E. & Kreulen, C. M. (1995). Cheese molars: a pilot study of the etiology of hypocalcifications in first permanent molars. *ASDC J Dent Child.* Vol. 62, No. 4, (Jul-Aug, 1995), pp. 266-269. 1945-1954 (Print) 1945-1954 (Linking)

- Weerheijm, K. L. (2003). Molar incisor hypomineralisation (MIH). *Eur J Paediatr Dent*. Vol. 4, No. 3, (Sep, 2003), pp. 114-120. 1591-996X (Print) 1591-996X (Linking)
- Weerheijm, K. L. (2004). Molar incisor hypomineralization (MIH): clinical presentation, aetiology and management. *Dent Update*. Vol. 31, No. 1, (Jan-Feb, 2004), pp. 9-12. 0305-5000 (Print) 0305-5000 (Linking)
- Weerheijm, K. L. et al. (2001). Molar-incisor hypomineralisation. *Caries Res*. Vol. 35, No. 5, (Sep-Oct, 2001), pp. 390-391. 0008-6568 (Print) 0008-6568 (Linking)
- Weerheijm, K. L. et al. (2003). Judgement criteria for molar incisor hypomineralisation (MIH) in epidemiologic studies: a summary of the European meeting on MIH held in Athens, 2003. *Eur J Paediatr Dent*. Vol. 4, No. 3, (Sep, 2003), pp. 110-113. 1591-996X (Print) 1591-996X (Linking)
- Weerheijm, K. L. & Mejare, I. (2003). Molar incisor hypomineralization: a questionnaire inventory of its occurrence in member countries of the European Academy of Paediatric Dentistry (EAPD). *Int J Paediatr Dent*. Vol. 13, No. 6, (Nov, 2003), pp. 411-416. 0960-7439 (Print) 0960-7439 (Linking)
- Welbury, R. et al. (2004). EAPD guidelines for the use of pit and fissure sealants. *Eur J Paediatr Dent*. Vol. 5, No. 3, (Sep, 2004), pp. 179-184. 1591-996X (Print) 1591-996X (Linking)
- William, V. et al. (2006a). Molar incisor hypomineralization: review and recommendations for clinical management. *Pediatr Dent*. Vol. 28, No. 3, (May-Jun, 2006a), pp. 224-232. 0164-1263 (Print) 0164-1263 (Linking)
- William, V. et al. (2006b). Microshear bond strength of resin composite to teeth affected by molar hypomineralization using 2 adhesive systems. *Pediatr Dent*. Vol. 28, No. 3, (May-Jun, 2006b), pp. 233-241. 0164-1263 (Print) 0164-1263 (Linking)
- Willmott, N. S. et al. (2008). Molar-incisor-hypomineralisation: a literature review. *Eur Arch Paediatr Dent*. Vol. 9, No. 4, (Dec, 2008), pp. 172-179. 1818-6300 (Print) 1818-6300 (Linking)
- Wright, J. T. (2002). The etch-bleach-seal technique for managing stained enamel defects in young permanent incisors. *Pediatr Dent*. Vol. 24, No. 3, (May-Jun, 2002), pp. 249-252. 0164-1263 (Print)
- Wright, J. T. et al. (1996). Protein characterization of fluorosed human enamel. *J Dent Res*. Vol. 75, No. 12, (Dec, 1996), pp. 1936-1941. 0022-0345 (Print) 0022-0345 (Linking)
- Wright, J. T. et al. (1997). The protein composition of normal and developmentally defective enamel. *Ciba Found Symp*. Vol. 205, No., (1997), pp. 85-99; discussion 99-106. 0300-5208 (Print) 0300-5208 (Linking)
- Wright, J. T. et al. (2009). Human and mouse enamel phenotypes resulting from mutation or altered expression of AMEL, ENAM, MMP20 and KLK4. *Cells Tissues Organs*. Vol. 189, No. 1-4, (2009), pp. 224-229. 1422-6421 (Electronic) 1422-6405 (Linking)
- Xie, Z. et al. (2008). Transmission electron microscope characterisation of molar-incisor-hypomineralisation. *J Mater Sci Mater Med*. Vol. 19, No. 10, (Oct, 2008), pp. 3187-3192. 0957-4530 (Print) 0957-4530 (Linking)
- Xie, Z. et al. (2009). Structural integrity of enamel: experimental and modeling. *J Dent Res*. Vol. 88, No. 6, (Jun, 2009), pp. 529-533. 1544-0591 (Electronic) 0022-0345 (Linking)

Zawaideh, F. I. et al. (2011). Molar incisor hypomineralisation: prevalence in Jordanian children and clinical characteristics. *Eur Arch Paediatr Dent*. Vol. 12, No. 1, (Feb, 2011), pp. 31-36. 1818-6300 (Print) 1818-6300 (Linking)

INTECH

INTECH



Contemporary Approach to Dental Caries

Edited by Dr. Ming-Yu Li

ISBN 978-953-51-0305-9

Hard cover, 488 pages

Publisher InTech

Published online 14, March, 2012

Published in print edition March, 2012

With an update of the recent progress in etiology, pathogenesis, diagnosis, and treatment of caries, it may be said that the final defeat of dental caries is becoming possible soon. Based on the research in this area in recent decades, "Contemporary Approach to Dental Caries" contained the caries in general, the diagnosis of caries, caries control and prevention, the medical treatment of caries, dental caries in children and others such as secondary caries. This book provides the reader with a guide of progress on the study of dental caries. The book will appeal to dental students, educators, hygienists, therapists and dentists who wish to update their knowledge. It will make you feel reading is profitable and useful for your practice.

How to reference

In order to correctly reference this scholarly work, feel free to copy and paste the following:

Márcia Pereira Alves dos Santos and Lucianne Cople Maia (2012). Molar Incisor Hypomineralization: Morphological, Aetiological, Epidemiological and Clinical Considerations, Contemporary Approach to Dental Caries, Dr. Ming-Yu Li (Ed.), ISBN: 978-953-51-0305-9, InTech, Available from: <http://www.intechopen.com/books/contemporary-approach-to-dental-caries/molar-incisor-hypomineralization-epidemiological-morphological-and-clinical-considerations->

INTECH
open science | open minds

InTech Europe

University Campus STeP Ri
Slavka Krautzeka 83/A
51000 Rijeka, Croatia
Phone: +385 (51) 770 447
Fax: +385 (51) 686 166
www.intechopen.com

InTech China

Unit 405, Office Block, Hotel Equatorial Shanghai
No.65, Yan An Road (West), Shanghai, 200040, China
中国上海市延安西路65号上海国际贵都大饭店办公楼405单元
Phone: +86-21-62489820
Fax: +86-21-62489821