

# Uprighting of the Impacted Second Mandibular Molar with Skeletal Anchorage

Stefano Sivoletta, Michela Roberto, Paolo Bressan, Eriberto Bressan,  
Serena Cernuschi, Francesca Miotti and Mario Berengo  
*University of Padua, Departments of Oral Surgery and Orthodontics  
Italy*

## 1. Introduction

Eruption disorder of the mandibular second permanent molars is quite rare, but it does need to be treated early.

There are many functional, periodontal, hygienic and prosthetic reasons which justify retrieving a second molar with eruption problems.

In terms of occlusion, the patient is assured of the proper arch length, with obvious functional and masticatory advantages, and any extrusion of the antagonist is avoided, especially when the eruption of third molars is unpredictable. (McAboy et al., 2003)

Oral hygiene at home becomes more straightforward and effective, thanks to the elimination of the pseudo-pocket. The incidence of caries is much higher in impacted teeth, and there is often radiographic evidence of severe damage to the crown or root of the first permanent molar. (Shellhart & Oesterle, 1999)

Adult and elderly patients often present with molars which are over-erupted and mesially inclined. Tipping of the first molar may initiate a vicious cycle of traumatic occlusion and periodontal problems mesial to the tipped tooth.

### 1.1 Epidemiology and causes

The permanent teeth most often affected by eruption problems are the mandibular and maxillary third molars, maxillary canines, central incisors and, more rarely, second mandibular premolars. (Aitasalo et al., 1972)

The incidence of eruption disorder involving the second molars is quite rare, ranging in the literature between 0.03-0.04% of all impacted teeth. (Mead, 1930), (Grover & Norton, 1985). The problem is encountered more frequently in the mandible, often only on one side, and with a predilection for the female gender. (Frank, 2000)

Because second-molar impaction is a relatively rare clinical problem, there is only a limited amount of literature regarding case management.

The main cause of second molar eruption anomalies is shortage of space. (Mead, 1930) The space required for the second molar to erupt in the mandible derives from resorption-

apposition processes typical of normal growth, which lead to remodeling of the anterior border of the mandibular ramus. During the normal growth and development of the lower jaw, the molar tooth buds distal to the first permanent mandibular molar have a mesial inclination, which is usually self-correcting as the anterior border of the mandibular ramus resorbs. In addition to this, the mesial drift of the first permanent molar creates approximately 2.7 mm of space per side for angular adjustment. (Majourau & Norton, 1995)

Functional impairment of this natural process leads to molar eruption problems, due to inadequate arch length. A further increase in the available space stems from the mesial migration of the first mandibular molar into the leeway space. (Majourau & Norton, 1995) Orthodontic treatment designed to prevent such migration, e.g., using the lingual arch or lip bumper, may increase the risk of eruption anomalies. (Kokich & Mathews, 1993)

Other important iatrogenic factors include an incorrectly fitted band cemented on the first mandibular molar, or of the first maxillary molar previous orthodontic sagittal expansion. (Eckhart, 1998)

Another reason for impaction is sometimes an excessive amount of space, because the eruption of the second molar needs to be guided by the roots of the first molar. (Shapira et al., 1998) This may give rise to eruption problems even though there is too much space between the two teeth, g.e. when orthodontic expansion of the maxillary arch occurs. The molar may also sometimes undergo spontaneous eruption anomalies, due to excessive mesioversion of the tooth germ or the presence of the third molar. Other problems may be due to premature extraction of the first permanent molar, molar ankylosis, odontogenic cysts, or odontomas. (Frank, 2000)

## 1.2 Surgical options

Extraction of an impacted mandibular second molar which appears to have no chance of uprighting itself may allow the third molar to erupt into the second molar position. This requires precise manipulation by the oral surgeon, who must carefully consider the unpredictability of these eruption patterns. (Tinerfe & Blakey, 2000)

Surgical methods vary from simply uncovering the tooth to third molar extraction and surgical second molar repositioning, with or without bone grafts in the medullar space. Surgical uprighting and repositioning of the mandibular second molar, with or without extraction of the third molar, is a possible option.

When a molar tooth is severely impacted, surgical uprighting may provide a quick and easy solution, particularly when orthodontic treatment is contraindicated. (Johnson & Quirk, 1987)

Typical orthodontic treatment for these molars may not be an option if patient commitment is minimal, or if the position of the tooth does not provide the proper environment for bonding a bracket.

When the decision has been made to perform surgical uprighting and repositioning second molars, Tinerfe and Blakey (Tinerfe & Blakey, 2000) recommend that certain criteria be considered.

These include ascertainment of root length/form, available space within the dental arch, arc of rotation, occlusion, periodontal status and jaw development. The optimal root length

should be one-third to half of the eventual length of the fully formed root, to enhance revascularization after tipping and bodily movement. As adequate space must be available in the arch, third molars may need to be prophylactically removed.

Ideally, the tooth to be uprighted should not be buccally or lingually inclined, since the buccal and lingual cortical plates are needed for primary stabilization once the second molar is surgically uprighted.

The angle of rotation for uprighting the second molar should not exceed 90° because, as Pogrel suggested (1995), uprighting teeth by more than 90° causes them to behave like transplants, thus diminishing the chance of future vitality.

Once the molar has been uprighted, any occlusion should be carefully checked for interferences which may lead to occlusal trauma. The uprighted tooth also should be positioned in a manner which allows healthy soft tissue attachment and ease of access for appropriate hygiene. Careful handling and positioning of the keratinized gingiva during the procedure are critical for the long-term periodontal health of uprighted molars.

It is also important that vertical jaw growth should be nearly complete, to achieve ideal occlusion and prevent tooth submersion during growth. If these criteria are met, surgical second molar uprighting has been shown to be a predictable procedure and a viable option when other types of treatment are not possible. (McAboy et al., 2003)

### 1.3 Orthodontic treatment

The best timing for treating impacted second molars is between 11 and 14 years of age, when the root is still not fully developed. The type of treatment depends on the slant of the tooth and the amount of orthodontic movement required.

Minor malpositioning can be corrected by placing an elastic separator between the two teeth. (Moro et al., 2002)

More severe malpositioning demands the use of surgical methods or orthodontically assisted eruptions, with or without surgical disinclusion of the tooth.

Mesially inclined molars should be differentiated not only by degree of impaction, but also by the types of tooth movement required for correction in all three spatial planes. For any particular tooth movement, it is very difficult to plan a correct force system with respect to the center of resistance. In the sagittal plane, the appropriate combination of vertical movement and uprighting must be determined. (Melsen et al., 1996)

A good treatment option is orthodontically assisted eruption, with or without surgical uncovering. The general approach is an attachment bonded to the surgically uncovered buccal or distobuccal surface of the second mandibular molar, followed by application of an uprighting force delivered by tip-back cantilever (Melsen et al., 1996), (Sawicka et al., 2007), NiTi-coil spring (Aksoy & Aras 1998), super-elastic NiTi wire (Going & Reyes-Lois, 1999), a variety of uprighting springs (Shapira & Borell 1998), (Park, 1999), (Majourau & Norton 1995), a fixed appliance (Carano et al. 1996), (Miao & Zhong, 2006) or a sectional arch wire (Alessandri Bonetti et al., 1999), (Kogod M & Kogod HS, 1991).

Molar uprighting may be secured by pure rotation obtained by applying a couple force system with a high moment-to-force ratio (so that the center of rotation is very close to the

center of resistance). A long cantilever gives a high moment-to-force ratio, which results in a clinical effect very close to that of pure rotation. The magnitude of the moment required to rotate a molar has been suggested to be 800–1500 g/mm. (Romeo & Burstone, 1977)

The cantilever produces effects on the tooth in three planes, mainly in the mesiodistal (distal crown tipping) and vertical directions (molar extrusion). Determining the forces on teeth also requires defining the forces delivered to the cantilever inserted in the molar tube. The activation force is directed to the occlusal plane and is opposed by the apically directed force which the molar tube exerts on the wire. Mesial and distal aspects of the molar tube also exert forces on the wire which oppose the counterclockwise rotation resulting from activation forces. The forces acting on the teeth are of the same magnitude as, but of opposite direction to, those acting on the wire. Thus, the intrusive force is on the anterior segment and the extrusive force on the molar, and the couple distally rotates. (Sawicka et al., 2007)

In traditional orthodontic biomechanics, when the molar is to be extruded, uprighting is often performed with simple tipback mechanics. If significant extrusion is needed, the force delivered to the bracket should be relatively large compared with the moment. If little or no extrusion is desired, the moment should be larger and the cantilever as long as possible. (Melsen et al., 1996)

Melsen et al. believe that, when molar intrusion is required, the biomechanics become more complex. The law of equilibrium states that the moment added to the molar must be smaller than the moment added to the anterior unit. This force system corresponds to what Burstone and Koenig defined as a geometry V, and can be obtained by proper activation of a root spring, as described by Roberts and colleagues. (Roberts et al., 1982)

It is also important to consider the force system generated in the horizontal plane. Although both the root spring and the V bend act parallel to the dental arch, in close proximity to the center of resistance, the cantilevers may have their point of force application on either side of the center of resistance, and thus generate tipping in either the buccal or the lingual direction. (Melsen et al., 1996)

The difficulty of managing these complex biomechanics has led many authors to seek easier alternative solutions, such as appliance design specifications.

The distal jet appliance, modified for use in the lower arch (uprighter-jet), is an example of a fixed appliance associated with an open-coil spring for proper lower molar uprighting. (Carano et al., 1996) The appliance design involves soldering an 0.036" tube to the premolar band, parallel to the occlusal plane but below the level of the edentulous ridge, so as not to interfere with the occlusion. The tube is oriented so that a wire with a bayonet bend can be slid into the tube from the distal end. A loop is bent into the distal end of this wire and attached to the molar band with a screw. Thus, wire and molar band are held together but are free to rotate around a common axis.

An adjustable screw-clamp and a 150g nickel titanium open-coil spring is placed over the tube. The two premolars are connected with a soldered lingual wire to form the anchorage unit. As the clamp is moved distally, the coil spring is compressed and a distalizing force is applied. Because the connection of the molar band to the wire is not rigid, the line of action

of this force is at the molar crown and the point of force application is at the screw. The molar crown will therefore be tipped distally.

Often, however, these stages of treatment are impossible, due to the severe mesio-inclination angle and the gingival position of the element which does not permit proper bonding. Many techniques have therefore been proposed involving, for example, segmented TMA (Majourau & Norton 1995) to avoid the problem or for pre-positioning the element.

Miao et al. (Miao & Zhong, 2006) proposed using a fixed appliance composed of a mini-hook and a push-spring (arrow) to move the crown of an impacted molar distally.

The mini-hook is made of 0.014" stainless steel wire and is conventionally bonded to the distal surface of a horizontally impacted molar or the occlusal surface of a mesially impacted molar, so that the hook opens mesially. Surgical exposure is needed only if horizontal impaction is so severe that the molar has not erupted at all. In such a case, the distal surface of the impacted tooth should be exposed just enough to bond the mini-hook.

A stainless steel wire, about 60 mm long, is soldered to the middle of the lingual surface of the mesially adjacent molar band. The wire is bent at the distolingual corner of the band, extended 2-3 mm buccally, and then turned distally, making a double- or triple-bend push-spring. The band with the push-spring is cemented to the mesially adjacent molar. The spring is stretched 4-5 mm distally and attached to the open mesial end of the mini-hook. The push-spring will then exert a distalizing and uprighting force. It should be reactivated monthly until the impacted molar is upright.

All these techniques present complex biomechanics which require careful evaluation to avoid side-effects such as extrusion or loss of anchorage.

Placing titanium miniscrews in the retromolar area for molar uprighting has been recommended as the most predictable and easiest method to manage. (Park et al., 2002), (Giancotti et al, 2003, 2004), (Nęcka et al., 2010)

## 2. Skeletal anchorage

The most common problem of classical distalization techniques is the frequent loss of anchorage and adverse effect on adjacent teeth.

Anchorage is a direct consequence of Newton's Third Law, i.e., "For every action there is an equal and opposite reaction", and is defined as the resistance to unwanted tooth movement. (Daskalogiannakis, 2000)

Orthodontic anchorage can also be defined as the "amount of movement allowed to the reactive unit", where the latter is composed of tooth/teeth acting as anchorage units during movement of the active unit, and the active unit is composed of tooth/teeth undergoing movement. (Cope, 2007)

Orthodontists often have inadequate mechanical systems to control anchorage, which leads to loss of anchorage in the reactive unit and thus incomplete correction of malocclusion. To avoid this kind of side-effect, clinicians often associate acrylic or extraoral appliances which, when combined with the ever-challenging problem of uncooperative patients, are often

futile attempts at best. As even a small reactive force can cause undesirable movements, it is important to ensure that anchorages are solidly based. (Pilon et al., 1996)

Absolute or infinite anchorage is defined as no movement of the anchorage unit (zero anchorage loss) as a consequence to the reaction forces applied to move teeth. (Daskalogiannakis, 2000)

This kind of anchorage can only be obtained with ankylosed teeth or dental implants as anchors, both of which rely on bone to inhibit undesired movement.

The need to check anchorage during orthodontic treatment has led clinicians to develop many types of Temporary Anchorage Devices (TAD). These may be defined as devices which are temporarily fixed to bone for the purpose of enhancing orthodontic anchorage by supporting the teeth of the reactive unit (indirect anchorage) or by obviating the need for the reactive unit altogether (direct anchorage) and are subsequently removed after use. (Cope, 2007).

The idea of using screws fixed to bone to obtain absolute anchorage goes back to 1945, when Gainsforth and Higley (Gainsforth & Higley, 1945) placed Vitallium screws in the ascending ramus of six dogs to retract their canines. The first clinical use reported in the literature came in 1983, when Creekmore and Eklund (Creekmore & Eklund, 1983) used a Vitallium bone screw inserted in the anterior nasal spine to treat a patient with a deep overbite. However, miniscrew implants for orthodontic anchorage were not immediately popular. Thereafter, a number of papers focused on other means of obtaining skeletal anchorage for orthodontic tooth movement, such as dental implants, onplants and palatal implants. (Papadopoulos et al., 2009)

In 1997, Kanomi (1997) described a mini-implant specifically made for orthodontic use and, in 1998, Costa et al. (1998) presented a screw with a bracket-like head requiring a simplified procedure: only local anesthesia, placement of a drill-free screw, and immediate loading.

Labauskaite et al. (2005) suggested the following classification of implants for orthodontic anchorage:

1. according to shape and size:
  - conical (cylindrical)
  - miniscrew implants
  - palatal implants
  - prosthodontic implants
  - mini-plate implants
  - disc implants (onplants);
2. according to implant bone contact
  - bone-integrated
  - not bone-integrated;
3. according to application
  - used only for orthodontic purposes (orthodontic implants)
  - used for prosthodontic and orthodontic purposes (prosthodontic implants).

With the exception of the Orthodontic Mini-Implant, which is made of stainless steel, all other above-mentioned systems are made of medical type IV or type V titanium alloy.

Miniscrew implants can be used as anchorages for tooth movements which could not otherwise be achieved, as in patients with insufficient teeth for conventional anchorages to be applied, when the forces on the reactive unit would generate adverse side-effects, in patients requiring asymmetrical tooth movements in all spatial planes and, in some cases, as an alternative to orthognathic surgical procedures. (Melsen B. 2005)

Using the retromolar area to position orthodontic implants was proposed by Roberts et al. in 1990. The authors used an experimental titanium bone-integrated implant to obtain absolute anchorage for second and third molar protraction after a first extracted molar replacement.

The retromolar area is particularly suitable for screw insertion, due to the presence of compact cortical bone tissue which immediately provides excellent primary stability (Figures 1 and 2).

The side-effects of positioning screws in this area are the risk of inflammation and hypertrophy of the movable mucosa, which may cover the screw entirely, resulting in difficult case management and the need for additional gingivectomy. Care must be taken in evaluating the position of the mandibular canal, in order to avoid neurological complications (e.g., damage to the inferior alveolar nerve).

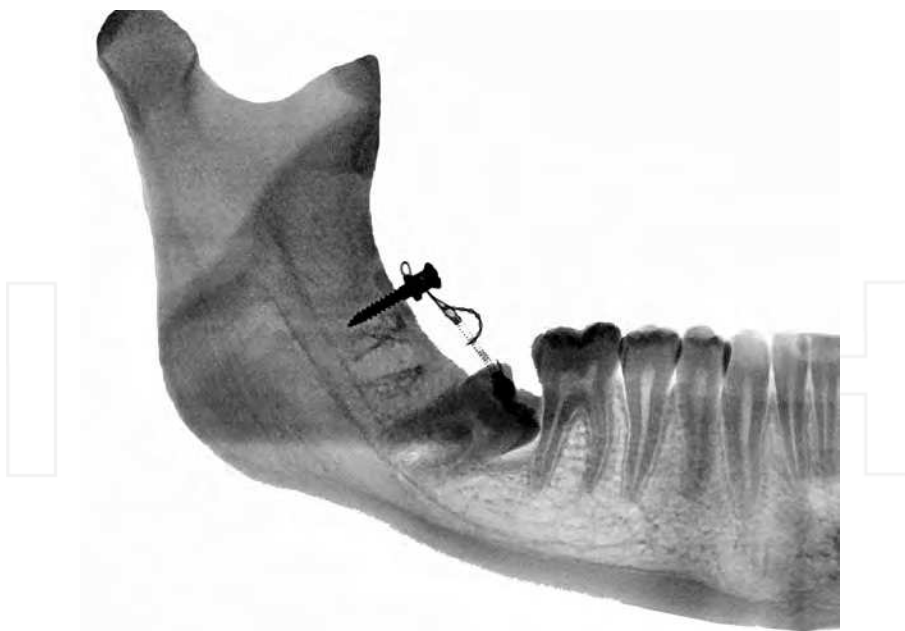


Fig. 1. Example of screw positioning in retromolar area. Lateral view.

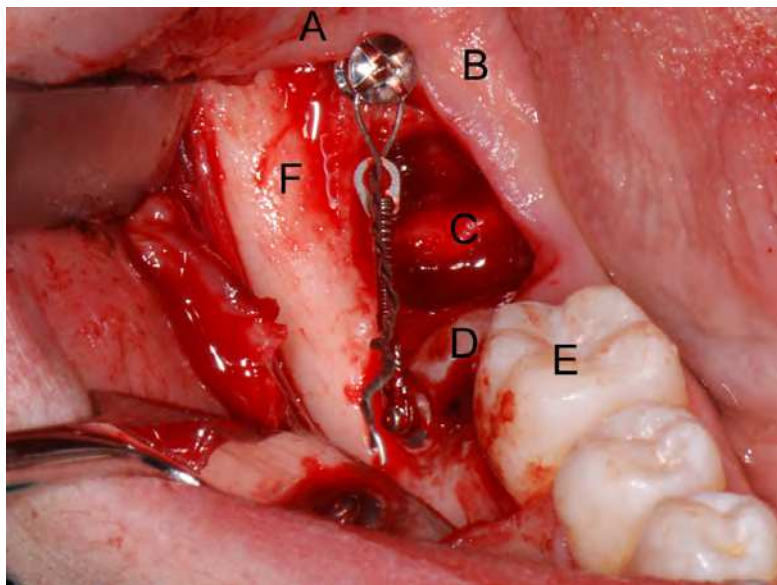


Fig. 2. Example of screw positioning in retromolar area. (A) Retromolar area. (B) Screw and device in place. (C) Third molar extraction socket. (D). Impacted second molar. (E) First molar. (F) Oblique external line.

Using implants as a method of skeletal anchorage for second lower molar uprighting was first proposed by Shellhart et al. These Authors placed a bone-integrated implant in an edentulous site, from which the first molar had previously been extracted. (Shellhart et al., 1996)

Park, first proposed the use of orthodontics implants for uprighting of the second molar by placing miniscrews in retromolar area. (Park H.S., 2002) The distalizing force is exerted through the use of elastomeric threads using perhaps rather low forces, about 50-80g. Other authors (Giancotti, 2003, 2004), (Nęcka et al., 2010) propose a very similar method, involving elastomeric chains, with monthly reactivations, or 50g-force closed Ni-Ti coil springs. The average treatment time in all these case reports was 7-9 months.

In an adolescent patient with a developing third molar, however, it is difficult to insert a miniscrew in the retromolar area unless the third molar is extracted. Thick overlying soft tissue and poor accessibility of the insertion site can also hinder miniscrew insertion. In such cases, the miniscrew can be inserted into the buccal alveolar bone on the mesial side to generate a "pushing" force. Lee et al. proposed to position the microscrew in interradicular area between second premolar and first molar and the use of a 0.016" or 0.016"x0.022" stainless steel wire with welded hook and open-coil spring for force delivery. (Lee et al., 2007)

Other Authors (Sohn et al., 2007) proposed a mesial positioning, using the screw as an anchor for the indirect stabilization of the first molar and second premolar. A 0.016"x0.022" stainless steel wire directly bonded with composite on teeth surface was used to connect dental elements and microscrews.



### 3. Combined surgical and orthodontic treatment using a distal screw as skeletal anchorage

This chapter describes a multidisciplinary surgical and orthodontic procedure for the treatment of second lower molar impaction.

#### 3.1 Materials and methods

A brief and schematic description of the materials and methods is given in this section.

1. Orthodontic evaluation of the patient and diagnosis of second molar inclusion. If the patient is still not in orthodontic treatment, before surgical disinclusion, a bracket is placed on the buccal surface of the lower first molar ipsilateral to facilitate the stabilization of the metal ligature wire and to improve patient comfort; (Figure 3-6)
2. Surgical workup to define the procedure;
3. Surgical procedure. A full-thickness flap is performed with distal extension, the third molar ipsilateral to the impacted tooth is extracted and, at the same time, in the site distal to the extracted tooth, a surgical steel screw for orthodontic traction with a head complete with a slot and holes is inserted. During the same session, the crown of the impacted second molar is surgically exposed and one or more orthodontic bracket are placed in position; the second molar is connected to the screw by means of two metal ligatures with eyelets for attaching the intermediate traction module or an NiTi closed coil-spring. The flap is repositioned and sutured; (Figure 7-15)
4. Sutures are removed and an early orthodontic traction element emplaced;
5. Follow-up is carried out every 3 weeks, according to patient requirements (including any intermediate gingivectomies, and adjusting the position of the bracket on the tooth as necessary) until the tooth has been uprighted; (Figure 16-19).
6. A further orthodontic step may be necessary to complete the process and finalize occlusion.

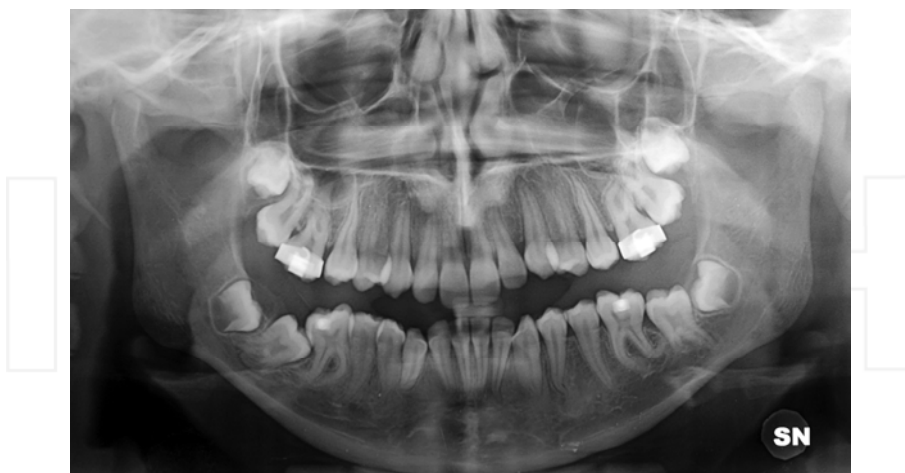

Fig. 3. Patient MF, aged 14 at the beginning of the therapy, had the following Orthodontic characteristics: I skeletal class with a normal vertical dimension, mild II molar and canine class, increased overjet, moderate anterior-inferior and anterior-superior crowding, cross bite 1.6-4.6, 2.6-3.6, eruption disorder of the right second lower molar with complete gingival inclusion.

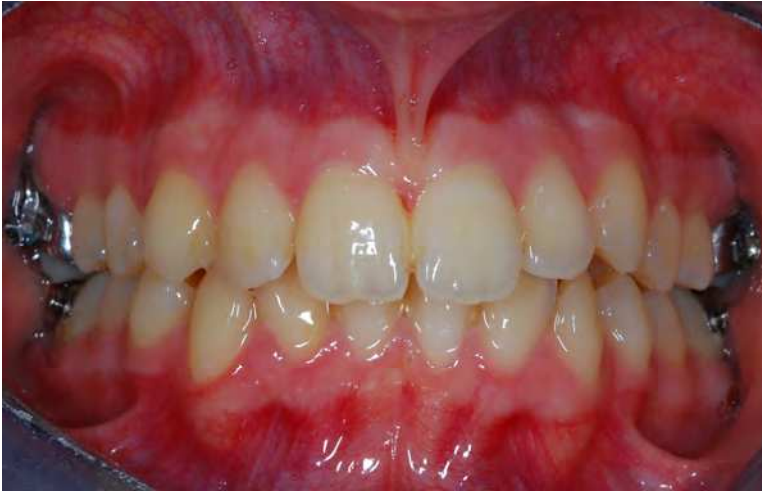

Fig. 4. Intraoral frontal view before treatment. The patient was treated by the use of criss-cross elastic for the correction of XB and EOT for the correction of molar Class II.

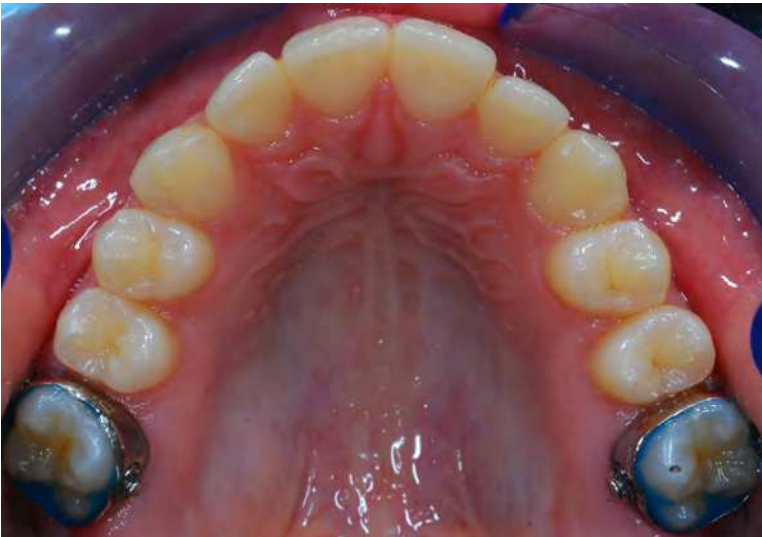

Fig. 5. Upper dental arch after distalization.

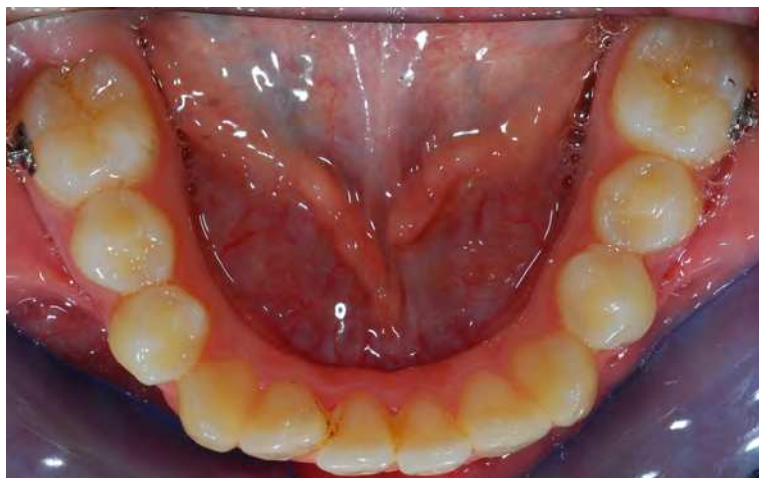

Fig. 6. Lower dental arch before surgical-orthodontic treatment. Patient simultaneously underwent the procedure for the surgical-orthodontic disinclination of the element 47, during the last phase of interceptive treatment.



Fig. 7. The screw used in the proposed case has the following features: 2.0mm screws, 8-12mm thread lengths, made of 316L extra-hard stainless steel for maximum strength; self-drilling, self-tapping for one-step insertion; groove under screw-head secures wires or elastics; cruciform head design; two cross-holes with align cruciform head slots; a 4-mm capstan-style head to hold the wire away from the mucosa (Synthes, West Chester, Pennsylvania).

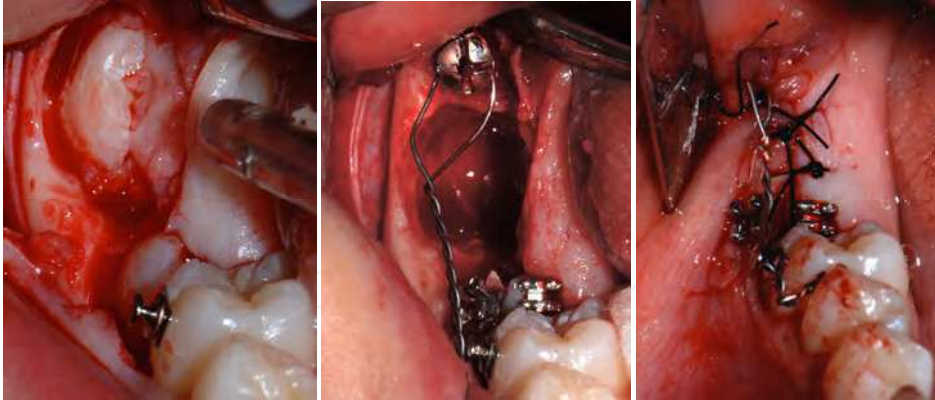


Fig. 8, 9 and 10. Surgical phases. The left mandibular third molar was extracted (germectomy), and a skeletal anchorage (2.0mm diameter/12mm length screw, Synthes, West Chester, Pennsylvania) was immediately applied. Two brackets, Roth Prescription slots 0.22, were positioned on the second molar (vestibular and occlusal) to optimize traction direction. Second molar was immediately connected to the screw by means of two metal ligatures with eyelets to attach intermediate traction elastic module. Eyelet to anchor the screw was modeled with 0.010" metallic ligature wire.

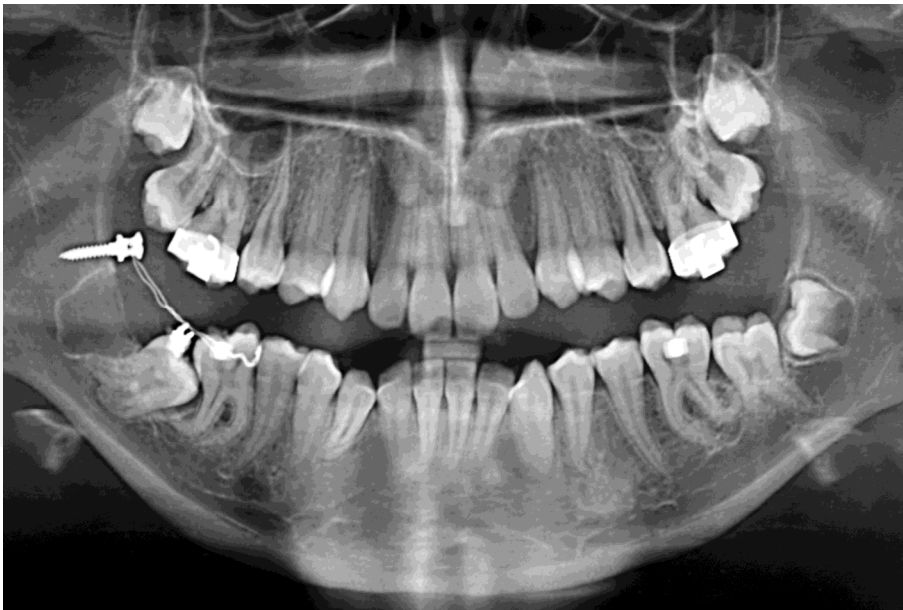

Fig 11. Immediately post operatively ortopantomography.

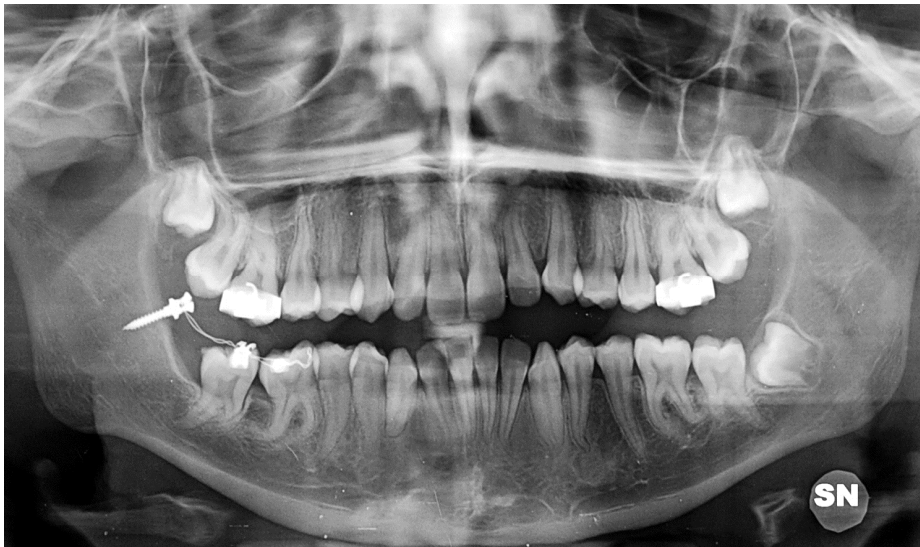

Fig. 12. Radiological check taken approximately 11 months later. The second left mandibular molar is in the correct position, the screw is still in place with no signs of bone inflammation. The time of treatment to achieve uprighting: about 9 months.

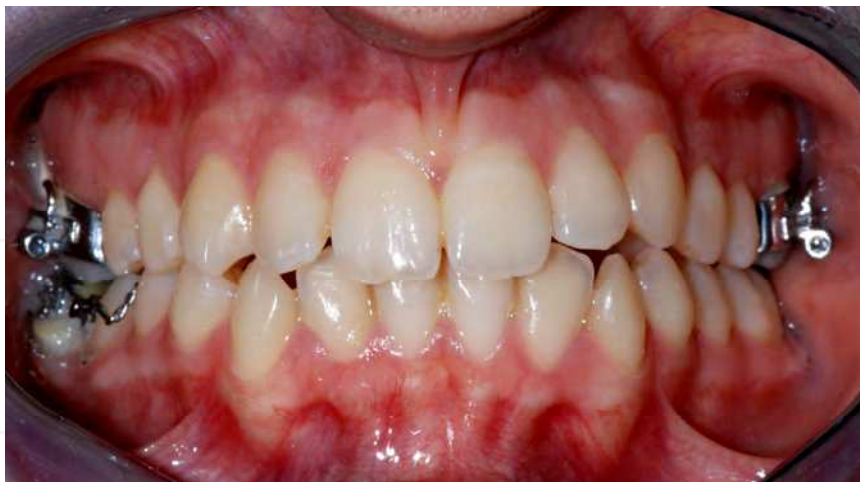

Fig. 13. Intraoral frontal view after treatment. The periodic checks to reactive the elastic traction, performed monthly at patient's request, rather than twice a week, caused a lengthening of time required to achieve the therapeutic effects. The patient was often advised to maintain good oral hygiene to prevent hypertrophy of the mucosa in the area of screw insertion.

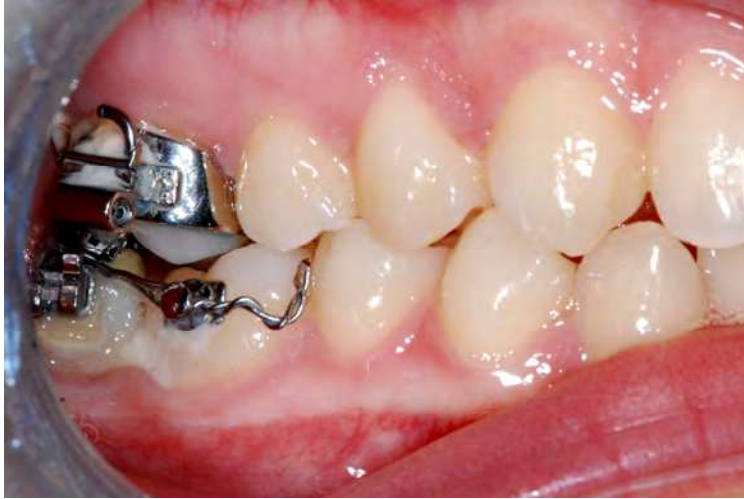

Fig. 14. Intraoral right lateral view after treatment. Passive ligature metallic wire still anchored on element 46. Only one gingivectomy was necessary during treatment, to set bracket in better position.

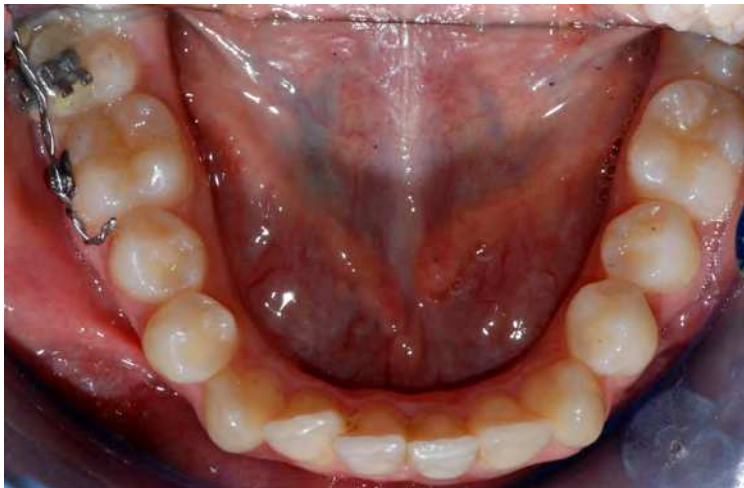

Fig. 15. Lower dental arch after treatment. Case will conclude with fixed orthodontic treatment to correct and finalize the occlusion.

#### 4. Cases presentation

Until now, the Authors successfully treated five cases of eruptive disorder of the second lower molar with the described technique (table 1).

Patients' mean age was 15.8 years; only one was female. When present, the third molar was always extracted. No damage to the inferior alveolar nerve or other major complications

were encountered. Patients' compliance was crucial: oral hygiene at home and relatively frequent clinical checks (about every 3 weeks) were important to prevent inflammation, hypertrophy of soft tissues and pain. When present, these minor complications did not affect the outcome of the procedure. The average duration of treatment for uprighting was 10.4 months. Results remained stable over 5 year follow-up.

Patient number	1	2	3	4	5
Age at start of treatment	14	16	15	18	16
Gender	F	M	M	M	M
Tooth	4.8	4.8	3.8	4.8	3.8
Type of inclusion	Mucosa inclusion	Bone inclusion	Mucosa inclusion	Partial bone inclusion	Mucosa inclusion
Presence of third molar	Yes	No	Yes	Yes	Yes
Duration of therapy	9 months	14 months	10 months	11 months	10 months
Undesired effects	Low compliance	None	Low hygiene	Mucosa hypertrophy	None

Table 1. Patients treated with Combined Surgical and Orthodontic treatment using a distal screw as skeletal anchorage.

## 5. Discussion and conclusions

This chapter discusses the application of a skeletal anchorage device to achieve a very complex orthodontic movement such as second lower molar uprighting, an issue relatively little discussed in the literature due to the low prevalence of this kind of malocclusion.

The method described is minimally invasive, as the surgery needed to expose the impacted tooth and emplace the screw is quite simple and can be completed in a single session, together with extraction of the third molar, which is necessary in most cases. It also seems that the creation of a cortico-medullar void distal to the second molar, after third molar extraction or appositely surgically performed (Finotti et al, 2009), is important in shortening treatment time.

The dimensions of the device are minimal. It only requires one miniscrew and a single bracket or button attachment, and is more comfortable for the patient than complex segmental biomechanics.

Miniscrew insertion, preparation of the appliance and delivery can all be done during a single appointment, unlike conventional treatment which requires impressions and laboratory work. The simple design reduces chair time compared with more complex indirect anchorages. This system guarantees the utmost respect of periodontal tissues, soft tissues and bone. The method allows absolute control of the anchorage and no unwanted movement of adjacent teeth. (Park et al., 2002), (Giancotti et al, 2003, 2004), (Nečka et al., 2010)

The direct application of force to the target tooth eliminates any unwanted movement of the anchorage unit, which may occur even with indirect miniscrew anchorage as a result of

technical errors in passive bracket placement or weak attachment between miniscrew and anchor tooth.

Removing the anchoring screw is straightforward, with negligible risks and consequences for the patient. The use of miniscrews and their success rate are predictable. (Degichi et al., 2003), (Motoyoshi et al., 2007), (Yanosky & Holmes, 2008), (Moon et al., 2008), (Manni et al., 2010).

Temporary skeletal anchorage devices enable orthodontic movements that were previously considered difficult, if not impossible, without consequences for the other teeth (e.g., anchorage loss, unwanted extrusion). Treatment involving skeletal anchorage requires interdisciplinary collaboration and planning with regular interaction, ongoing education, improvement of materials and continual reviews of the latest literature.

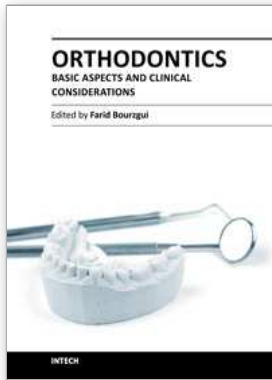
## 6. References

- Aitasalo K., Lehtinen R., Oksala E. (1972). An orthopantomographic study of prevalence of impacted teeth. *International Journal of Oral Surgery*, Vol 1, No. 3, (1972), pp.117-120.
- Aksoy A., Aras S. (1998). Use of nickel titanium coil spring for partially impacted second molars. *Journal of Clinical Orthodontics*. Vol. 32, (1998), pp. 479- 482.
- Alessandri Bonetti G., Pelliccioni G.A., Checchi. L. (1999). Management of bilaterally impacted mandibular second and third molars. *Journal of the American Dental Association*. Vol. 130, No. 8, (August 1999), pp. 1190-1194.
- Carano A., Testa M., Siciliani G. (1996). The Distal Jet for Uprighting Lower Molars. *Journal of Clinical Orthodontics*, Vol. 30, No. 12, (1996), pp. 707-710
- Cope, J. (2007). *ORTHOTADS. The clinical Guide and Atlas*, Under Dog Media, ISBN 978-0-9776301-0-3, Dallas, Texas
- Costa A., Raffaini M., Melsen B. (1998). Miniscrews as orthodontic anchorage: a preliminary report. *International Journal Adult Orthodontics & Orthognathic Surgery*, Vol. 13, (1998), pp. 201-209.
- Creekmore TD, Eklund MK. The possibility of skeletal anchorage. *J Clin Orthod* 1983;17:266-9.
- Daskalogiannakis J. *Glossary of orthodontic terms*. (2000). Leipzig: Quintessence Publishing Co.
- Deguchi T., Takano-Yamamoto T., Kanomi R., Hartsfield J.K., Roberts W.E., Garetto L.P. (2003). The use of small titanium screws for orthodontic anchorage. *Journal of Dental Research*, Vol. 82, (2003), pp. 377-381.
- Eckhart J.E. (1998). Orthodontic uprighting of horizontally impacted mandibular second molars. *Journal of Clinical Orthodontics*. Vol. 32, (1998), pp. 621- 624.
- Finotti M., Del Torre M., Roberto M., Miotti F.A. Could the distalization of the mandibular molars be facilitated? A new therapeutic method. *Orthodontie Francaise*. Vol. 80, No. 4, (December 2009), pp. 371-378.
- Frank C. (2000). Treatment options for impacted teeth. *Journal of the American Dental Association*, Vol. 131, (2000), pp. 623-32.
- Gainsforth BL, Higley LB. A study of orthodontic anchorage possibilities in basal bone. *Am J Orthod Oral Surg* 1945;31:406-17.
- Giancotti A., Muzzi F., Santini F., Arcuri C. (2003). Miniscrew treatment of ectopic mandibular molar. *Journal of Clinical Orthodontics*. Vol. 37, (2003), pp. 380-383.



- Giancotti A., Arcuri C., Barlattani A., (2004). Treatment of ectopic mandibular second molar with titanium miniscrews. *American Journal of Orthodontics and Dentofacial Orthopedics*, Vol. 126, No. 1 (July 2004), pp. 113-117
- Going R.E., Reyes-Lois D.B. (1999). Surgical exposure and bracketing technique for uprighting impacted mandibular second molars. *Journal of Oral Maxillofacial Surgery*. Vol. 57, (1999), pp. 209-212.
- Grover P.S., Norton L. (1985). The incidence of unerupted permanent teeth and related clinical cases. *Oral Surgery, Oral Medicine, Oral Pathology, Oral Radiology and Endodontology*, Vol. 59, (1985), pp. 420-425.
- Johnson J.V., Quirk G.D. (1987). Surgical repositioning of impacted second molar teeth. *American Journal of Orthodontics and Dentofacial Orthopedics*. Vol. 91, (1987), pp. 242-251
- Kanomi R. (1997). Mini-implant for orthodontic anchorage. *Journal of Clinical Orthodontics*; Vol. 31, (1997), pp. 763-767.
- Kogod M., Kogod H.S. (1991). Molar uprighting with the piggyback buccal sectional arch wire technique. *American Journal of Orthodontics and Dento-facial Orthopedics*. Vol. 99, (1991), pp. 276-280.
- Kokich V.G., Mathews D.P. (1993). Surgical and orthodontic management of impacted teeth. *Dental Clinics of North America*. Vol. 37, (1993), pp.198-201
- Labanauskaite B., Jankauskas G., Vasiliauskas A., Haffar N. (2005). Implants for orthodontic anchorage. Meta-analysis. *Stomatologija*, Vol. 7 (200), pp. 128-32.
- Lee KJ, Park Y.C., Hwang W.S., Seong E.H. (2007). Uprighting mandibular second molars with direct miniscrew anchorage. *Journal of Clinical Orthodontics*, Vol. 41, No. 10 (October 2007) Oct, pp. 627-35.
- Majourau A., Norton L.A. (1995). Uprighting impacted second molars with segmented springs. *American Journal of Orthodontics and Dentofacial Orthopedics*. Vol. 107, (1995), pp. 235-238.
- Manni A., Cozzani M., Tamborrino F., De Rinaldis S., Menini A. (2011). Factors influencing the stability of miniscrews. A retrospective study on 300 miniscrews. *European Journal of Orthodontics*. Vol. 33, No. 4, (August 2011), pp. 388-395.
- McAboy C.P., Grumet J.T., Siegel E.B., Iacopino A.M. (2003). Surgical uprighting and repositioning of severely impacted mandibular second molars. *Journal of American Dental Association*. Vol. 134, (2003), pp. 1459- 1462.
- Mead S. (1930). Incidence of impacted teeth. *International J Orthodontics*, Vol. 16, (1930), pp. 885-890.
- Melsen B., Fiorelli G., Bergamini A. (1996). Uprighting of lower molars. *Journal of Clinical Orthodontics*. Vol. 30, No. 11, (November 1996), pp. 640-645.
- Melsen B. (2005). Mini-implants: where are we? *Journal of Clinical Orthodontics*, Vol. 39, (2005), pp. 539-47.
- Miao Y.Q., Zhong H. (2006). An uprighting appliance for impacted mandibular second and third molars. *Journal of Clinical Orthodontics*, Vol. 40, No.2 (February 2006), pp. 110-116.
- Moon C.H., Lee D.G., Lee H.S., Im J.S., Baek S.H. (2008). Factors associated with the success rate of orthodontic miniscrews placed in the upper and lower posterior buccal region. *Angle Orthodontics*. Vol. 78, No. 1 (January 2008), pp. 101-106.

- Moro N., Murakami T., Tanaka T., Ohto C. (2002). Uprighting of impacted third molars using brass ligature wire. *Australian Orthodontic Journal*, Vol. 18, (2002), pp. 35-38
- Motoyoshi M., Yoshiba T., Ono A., Shimizu N. (2007). Effect of cortical bone thickness and implant placement torque on stability of orthodontic mini-implants. *International Journal of Oral & Maxillofacial Implants*, Vol. 22, No. 5, (September-October 2007) pp. 779-84
- Nęcka A., Skrzypczyński J., Antoszevska J. (2010). Miniscrew-Anchorage in Treatment of Impacted Second Molar in Mandible – Case Report. *Dental and Medical Problems*, Vol. 47, No. 3, (2010) 379-383
- Papadopoulos M.A., Papageorgiou S.N., Zogakis I.P. (2009). Clinical effectiveness of orthodontic miniscrew implants: a meta-analysis. *Journal of Dental Research*, Vol. 90, No. 8, (Aug 2011), pp. 969-76.
- Park D.K. (1999). Australian uprighting spring for partially impacted second molars. *Journal of Clinical Orthodontics*, Vol. 33, (1999), pp. 404-405.
- Park H.S., Kyung H.M., Sung J.H. (2002). A simple method of molar uprighting with micro-implant anchorage. *Journal of Clinical Orthodontics*, Vol. 36, (2002) pp. 592-6
- Pilon J.J., Kuijpers-Jagtman A.M., Maltha J.C. (1996). Magnitude of orthodontic forces and rate of bodily tooth movement. An experimental study. *American Journal of Orthodontics and Dentofacial Orthopedics*, Vol. 110, No.16, (1996), pp. 16-23.
- Pogrel A. (1995). The surgical uprighting of mandibular second molars. *American Journal of Orthodontics and Dento-facial Orthopedics*, Vol. 108, (1995), pp. 180-183.
- Roberts W.E., Marshall K.J., Mozsary P.G. (1990). Rigid endosseous implant utilized as anchorage to protract molars and close an atrophic extraction site. *Angle Orthodontics*. Vol. 60, No. 2, (Summer 1990), pp. 135-152.
- Roberts W.W., Chacker F.M., Burstone C.J. (1982). A segmental approach to mandibular molar uprighting. *American Journal of Orthodontics*. Vol. 81, (1982), pp. 177-184.
- Romeo D.A., Burstone C.J. (1977). Tip-back mechanics. *Am J Orthod*. 1977; 72:414-421.
- Sawicka M., Racka-Pilszak B., Rosnowska-Mazurkiewicz A. (2007). Uprighting partially impacted permanent second molars. *Angle Orthodontics*. Vol. 77, No. 1, (January 2007), pp. 148-154.
- Shapira Y., Borell G., Nahlieli O., Kufninec M.M. (1998). Uprighting mesially impacted mandibular permanent second molars. *Angle Orthodontics*.;No. 68, (1998), pp. 173-178.
- Shellhart W.C., Moawad M., Lake P. (1996). Case report: implants as anchorage for molar uprighting and intrusion. *Angle Orthodontics*, Vol. 66, No. 3, (1996), pp. 169-72
- Shellhart W.C., Oesterle L.J. (1999). Uprighting molars without extrusion. *Journal of American Dental Association*. Vol. 130, (1999), pp. 381-385.
- Sohn B.W., Choi J.H., Jung S.N., Lim K.S. (2007). Uprighting mesially impacted second molars with miniscrew anchorage. *Journal of Clinical Orthodontics*. Vol. 41, No. 2, (February 2007), pp. 94-97
- Tinerfe T.J., Blakey G.H. (2000). *Oral and maxillofacial surgery*. (2000) Saunders, Philadelphia
- Yanosky M.R., Holmes J.D. (2008). Mini-implant temporary anchorage devices: orthodontic applications. *Compendium of Continuing Education in Dentistry* (January-February 2008), Vol. 29, No. 1, pp. 12-21



## **Orthodontics - Basic Aspects and Clinical Considerations**

Edited by Prof. Farid Bourzgui

ISBN 978-953-51-0143-7

Hard cover, 446 pages

**Publisher** InTech

**Published online** 09, March, 2012

**Published in print edition** March, 2012

The book reflects the ideas of nineteen academic and research experts from different countries. The different sections of this book deal with epidemiological and preventive concepts, a demystification of cranio-mandibular dysfunction, clinical considerations and risk assessment of orthodontic treatment. It provides an overview of the state-of-the-art, outlines the experts' knowledge and their efforts to provide readers with quality content explaining new directions and emerging trends in Orthodontics. The book should be of great value to both orthodontic practitioners and to students in orthodontics, who will find learning resources in connection with their fields of study. This will help them acquire valid knowledge and excellent clinical skills.

### **How to reference**

In order to correctly reference this scholarly work, feel free to copy and paste the following:

Stefano Sivoella, Michela Roberto, Paolo Bressan, Eriberto Bressan, Serena Cernuschi, Francesca Miotti and Mario Berengo (2012). Uprighting of the Impacted Second Mandibular Molar with Skeletal Anchorage, *Orthodontics - Basic Aspects and Clinical Considerations*, Prof. Farid Bourzgui (Ed.), ISBN: 978-953-51-0143-7, InTech, Available from: <http://www.intechopen.com/books/orthodontics-basic-aspects-and-clinical-considerations/uprighting-of-the-impacted-second-mandibular-molar-with-skeletal-anchorage>

**INTECH**  
open science | open minds

### **InTech Europe**

University Campus STeP Ri  
Slavka Krautzeka 83/A  
51000 Rijeka, Croatia  
Phone: +385 (51) 770 447  
Fax: +385 (51) 686 166  
[www.intechopen.com](http://www.intechopen.com)

### **InTech China**

Unit 405, Office Block, Hotel Equatorial Shanghai  
No.65, Yan An Road (West), Shanghai, 200040, China  
中国上海市延安西路65号上海国际贵都大饭店办公楼405单元  
Phone: +86-21-62489820  
Fax: +86-21-62489821