

Diagnosis and Management of Desquamative Gingivitis

Hiroyasu Endo¹ and Terry D. Rees²

¹*Department of Periodontology, Nihon University,
School of Dentistry at Matsudo*

²*Department of Periodontics, Baylor College of Dentistry,
Texas A&M Health Science Center, Dallas, TX,*

¹*Japan*

²*USA*

1. Introduction

Desquamative gingivitis (DG) is characterized by erythematous gingiva, desquamation and erosion of the gingival epithelium, and blister formation. It is a clinical manifestation common to several diseases (Endo et al., 2008a; Lo Russo et al., 2008; Rees, 2011). It is seen mainly in adults, especially women, although rare cases have been observed in children (Barnett et al., 1981; Cheng et al., 2001; Leao et al., 2008; Lo Russo et al., 2009; Yih et al., 1998). Nisengard and Levine (1995) cited the following as the standard for the clinical appearance of DG: 1) Gingival erythema not resulting from plaque, 2) Gingival desquamation, 3) Other intraoral and sometimes extraoral lesions, and 4) Complaint of sore mouth, particularly after eating spicy foods. Nikolsky's sign often shows a positive reaction in patients with DG (Fig. 1). This sign involves the application of a shearing force on normal-appearing gingiva, producing epithelial desquamation. The specificity of Nikolsky's sign was higher (96.3%) than the sensitivity (46.7%), indicating that Nikolsky's sign is useful in the preliminary diagnosis of oral blistering diseases and may represent a simple clinical tool for oral health practitioners (Mignogna et al., 2008).

It was previously thought that DG was caused by a hormone imbalance since it often occurred in middle-aged and older women. However, advanced diagnosis using immunological techniques indicates that most cases of DG are caused by mucocutaneous diseases, the most common ones being lichen planus (LP), mucous membrane pemphigoid (MMP), and pemphigus vulgaris (PV) (Endo et al., 2008a; Leao et al., 2008; Lo Russo et al., 2008; Lo Russo et al., 2009; Nisengard & Rogers, 1987; Rees, 2011; Yih et al., 1998). Contact allergic reactions to various oral hygiene products have also been reported to present as DG (Endo & Rees, 2006, 2007; Endo et al., 2010; Lamey et al., 1990; Rees, 1998, 1999, 2011). Although a definitive diagnosis of the specific disease or disorder causing DG is required to provide proper treatment, it is almost impossible to do so based solely on clinical manifestations. Therefore, histopathological examination and direct immunofluorescence (DIF) testing are often required to establish the final diagnosis. According to a summary of results using DIF, 75.4% of the 174 cases that were clinically diagnosed as DG were caused by mucocutaneous diseases (Nisengard & Rogers, 1987), the most commonly recognized

ones being cicatricial pemphigoid (cicatricial pemphigoid was renamed MMP; 48.9%), LP (23.6%) and PV (2.3%). Recent studies of the clinical associations of DG found that LP seems to be the most frequent cause. Leao et al. (2008) evaluated 187 patients with DG, and found LP to be the most common (70.5%) while MMP (14%) and PV (13%) were less prevalent. When Lo Russo et al. (2009) evaluated 125 patients with DG, they found the most common cause was LP (75%), whereas DG due to MMP occurred in only a small percentage of patients (9%).

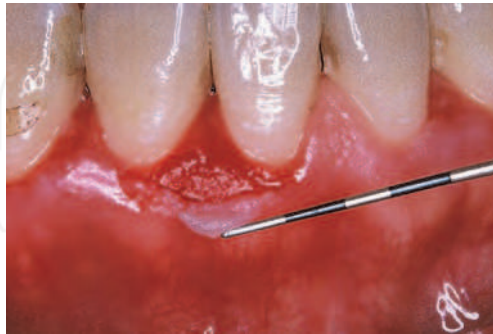


Fig. 1. Positive Nikolsky sign associated with PV. The epithelium could be peeled away easily by slightly scratching the surface of the gingiva.

The management of DG has been a major problem, largely because the etiology of the disease has been elusive. In this chapter we will review the current literature on the pathogenesis, diagnosis and management of DG.

2. Oral Lichen Planus

LP is a chronic inflammatory mucocutaneous disease caused by an unknown etiology (Mollaoglu, 2000; Roopashree et al., 2010; Scully et al., 1998). The disease commonly occurs in middle-aged and older people, and the morbidity rate of women is higher than that of men (Camacho-Alonso et al., 2007; Eisen, 2002; Ingafou et al., 2006; Mignogna et al., 2005; Xue et al., 2005). DG is recognized in about 30% of oral LP patients (Mignogna et al., 2005) (Fig. 2). Lesions are found mainly in the skin, genitalia, or oral mucosa and may be found in multiple regions, although they are confined to the gingiva alone in some patients (Eisen, 2002; Ingafou et al., 2006; Mignogna et al., 2005; Mollaoglu, 2000; Scully et al., 1998; Xue et al., 2005).

Histopathologically, LP is characterized by band-like lymphocyte infiltration below the epithelium accompanied by basal cell liquefaction (Lo Russo et al., 2008; Rees, 2011). As pronounced basal cell liquefaction occurs, the epithelium may detach from the underlying connective tissue. DIF findings for LP are useful so as to rule out other mucocutaneous diseases. The findings are nonspecific but supportive if fibrin or fibrinogen deposition is found in the basement membrane zone (BMZ) in a linear pattern (Lo Russo et al., 2008; Rees, 2011; Rinaggio et al., 2007; Yih et al., 1998). It may not be necessary to routinely conduct DIF testing, since the histopathological findings of LP are usually diagnostic. Since LP is idiopathic, the therapeutic goal is the remission or suppression of the symptoms. Spontaneous remissions of oral LP are infrequent (Ingafou et al., 2006). Skin lesions are often

transient in nature, whereas lesions of oral LP may demonstrate a chronic and protracted clinical course (Al-Hashimi et al., 2007; Endo et al., 2008b; Ingafou et al., 2006; Plemons et al., 1999). Although it is still subject to some controversy, LP may have premalignant potential (Eisen, 2002; Ingafou et al., 2006; Mignogna et al., 2005; Xue et al., 2005). Therefore, it is important to provide treatment and long-term follow-up examinations for patients with LP.

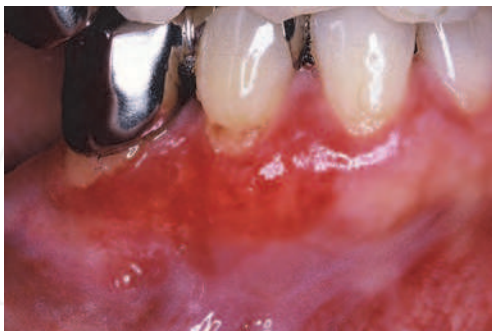

Fig. 2. Patchy erythematous attached gingiva associated with LP.

3. Mucous Membrane Pemphigoid

MMP is one of a group of autoimmune, subepithelial blistering diseases that predominantly affect the mucous membranes (Bagan et al., 2005; Chan et al., 2002; Fleming & Korman, 2000; Scully & Lo Muzio, 2008). Most patients with this disease are in the fifth or sixth decade of life, and the majority of them are women (Chan et al., 2002; Fleming & Korman, 2000; Scully & Lo Muzio, 2008). Oral lesions are observed in almost all cases, and the primary lesion often appears in the oral cavity (Chan et al., 2002; Fleming & Korman, 2000; Scully & Lo Muzio, 2008). DG is a common manifestation of MMP (Carrozzo et al., 2004; Endo et al., 2006a) (Figs. 3 and 4). The gingiva appears erythematous with a diffuse or patchy distribution. Vesiculobullous lesions on the gingiva break easily and form erosions with irregular margins. Other oral sites include the buccal mucosa, palate, alveolar ridge, tongue, and lip (Chan et al., 2002; Fleming & Korman, 2000). Extraoral mucous membranes including the conjunctiva, skin, pharynx, external genitalia, nose, larynx, anus and esophagus may also be affected (Chan et al., 2002; Fleming & Korman, 2000).

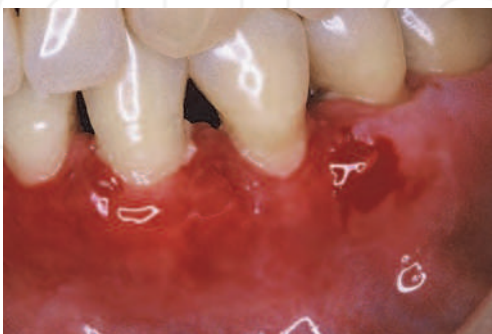

Fig. 3. Desquamative lesions with bleeding on the attached gingiva associated with MMP.

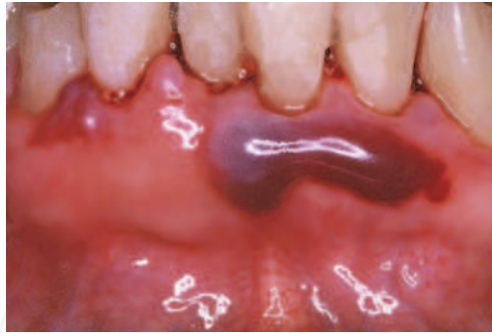

Fig. 4. Localized blood-filled bulla found on the gingiva associated with MMP.

Scarring and an associated loss of function are the major sequelae of some forms of MMP. Life-threatening airway obstruction and sight-threatening ocular scarring have been reported (Alexandre et al., 2006; Higgins et al., 2006, 2010; Thorne et al., 2004; Trimarchi et al., 2009). However, scarring is rarely seen on the oral mucosa. Early detection and early treatment of ocular lesions are especially important because the conjunctiva is the second most-frequent site of involvement (Fleming & Korman, 2000; Thorne et al., 2004). It has been reported that ocular lesions were observed in 64% of MMP patients and that MMP patients with oral lesions frequently have asymptomatic ocular lesions (Fleming & Korman, 2000; Higgins et al., 2006; Thorne et al., 2004). These observations indicate that all patients diagnosed with MMP should undergo ophthalmic examination. The early manifestation of ocular MMP includes chronic intractable conjunctival irritation in which the patients complain of a burning sensation, dryness, or a foreign body sensation. Scar-like adhesions of the eyelid to the conjunctiva (symblepharon) may occur after repeated conjunctival fibrosis and progressive symblepharon may lead to blindness (Fleming & Korman, 2000). Skin lesions are observed in up to 24% of MMP patients (Fleming & Korman, 2000). Fifteen percent of MMP patients experience nasal lesions, which may present in the form of crusty ulcers on the septum or turbinates (Alexandre et al., 2006; Fleming & Korman, 2000). Scarring and adhesion can also take place and may result in nasal airway obstruction (Alexandre et al., 2006; Trimarchi et al., 2009). Laryngeal MMP is a rare condition (12.2%) and the supraglottis is the most commonly affected site (Higgins et al., 2010).

Histopathologically, MMP is characterized by subepithelial bulla formation (Lo Russo et al., 2008; Rees, 2011). In the DIF testing of MMP patients, the linear deposition of C3, IgG or other immune globulin is observed in the BMZ (Lo Russo et al., 2008; Rees, 2011; Rinaggio et al., 2007; Yih et al., 1998). Multiple target antigens of MMP were identified in BMZ components by circulating autoantibodies in the patients' serum. These antigens include bullous pemphigoid (BP) 180, BP230, laminin 5, laminin 6, beta 4 integrin and unknown antigens (Chan et al., 2002). There is presently no firm correlation between specific clinical phenotypes and the target antigens in MMP patients (Carrozzo et al., 2004; Chan et al., 2002). To date, the most common target antigen associated with MMP is BP180 (Balding et al., 1996; Bedane et al., 1997; Calabresi et al., 2007). The extracellular domain of BP180 is considered to have a number of MMP-reactive antigenic sites of which at least two sites have been identified. One is the non-collagenous 16 a (NC16a) domain located in the upper lamina lucida, and the other is the carboxy-terminus domain at the lamina lucida/lamina densa interface (Bagan et al., 2005; Balding et al., 1996; Bedane et al., 1997; Calabresi et al.,

2007; Van den Bergh & Giudice, 2003). The authors evaluated circulating IgG autoantibody specific for BP180NC16a using enzyme-linked immunosorbent assay (ELISA) (Endo et al., 2006a). In five cases of MMP, the BP180NC16a ELISA was positive in three cases, although the antibody was present in low titers (Endo et al., 2006a). The presence or absence of the autoantibodies to BP180NC16a was inconsistent with the severity of the oral lesions or the presence of the extraoral lesions (Endo et al., 2006a). To date, there is no general consensus regarding the establishment of a prognostic indicator for MMP. There is also no known correlation between antigen-specific autoantibodies and the disease prognosis. Autoantibodies against various BMZ components probably play a role in the pathogenesis of MMP but there are still many questions about their pathogenic role.

4. Pemphigus Vulgaris

PV is an autoimmune disease characterized by acantholysis in the epithelium (Bystryń & Rudolph, 2005; Scully & Mignogna, 2008). Most patients with PV are in their fourth and fifth decade of life, and the disease is equally common in men and women (Bystryń & Rudolph, 2005; Scully & Mignogna, 2008). Early symptoms of PV develop in the oral cavity in about 80% of the patients (Sirois et al., 2000), so it is often detected first by dentists. PV is rare among the mucocutaneous diseases causing DG (Endo et al., 2008a; Leao et al., 2008; Lo Russo et al., 2009; Nisengard & Rogers, 1987), and it can be fatal as well.

In PV bullae rupture rapidly and intact bullae formation in the oral cavity is rarely seen. Oral PV is often regarded as difficult to diagnose in its early stages because less characteristic oral manifestations are produced than those associated with cutaneous PV. Diagnostic delays greater than 6 months are common in oral PV (Sirois et al., 2000). If the treatment is delayed due to misdiagnosis or inadequate initial management, the risk of the disease spreading or other complications may increase. Clinically, PV frequently begins with oral lesions and later progresses to skin lesions. Lesions may occur anywhere on the oral mucosa (Bystryń & Rudolph, 2005; Mignogna et al., 2001). On occasion, the gingiva is the only site involved in early lesions, and DG is a common manifestation of the disease (Endo et al., 2005, 2008c; Mignogna et al., 2001) (Figs. 5 and 6). Acantholytic (Tzanck) cells can be confirmed in cytologic smears obtained by scratching the gingiva (Endo et al., 2008a; Mignogna et al., 2001). Tzanck cells show degenerative changes, including round, swollen hyperchromatic nuclei with a homogenous cytoplasm (Endo et al., 2008a).

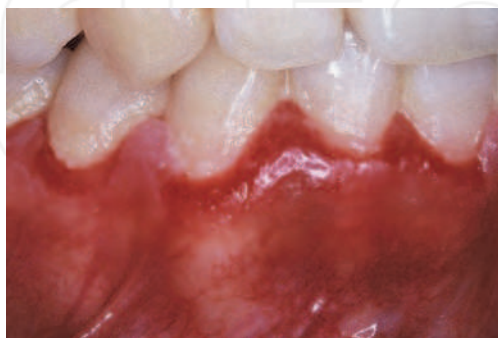

Fig. 5. Mild erythema and swelling of gingiva associated with PV.

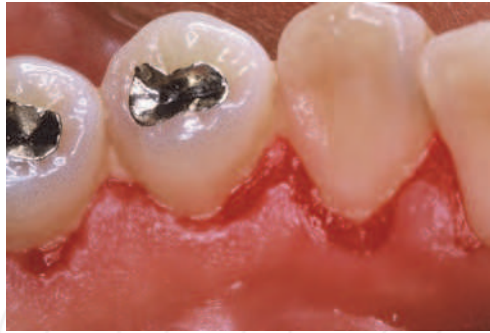

Fig. 6. Eroded gingival surface with ragged edges associated with PV.

In a histopathologic examination, PV is characterized by intraepithelial bullae formation (Lo Russo et al., 2008; Rees, 2011). In the DIF testing of PV patients, deposition of IgG and C3 is often found between the epithelial cells and is characterized by a fishnet pattern (Lo Russo et al., 2008; Rees, 2011; Rinaggio et al., 2007; Yih et al., 1998). The main target antigen of PV is desmoglein (Dsg) 3, a constituent of the extracellular region of desmosomes on keratinocytes (Amagai, 1999). In well developed disease almost all PV patients have circulating autoantibodies to Dsg3 (Amagai et al., 1999; Daneshpazhooh et al., 2007; Harman et al., 2000). More than 50% of PV patients also have Dsg 1 autoantibodies, the primary antigen of pemphigus foliaceus (Amagai et al., 1999; Daneshpazhooh et al., 2007; Harman et al., 2000). In some PV patients, the Dsg autoantibody profile correlates with the clinical manifestations (Daneshpazhooh et al., 2007; Endo et al., 2008c). The authors reported PV in a 31-year-old woman with only gingival involvement at the onset of the disease, but later she developed more extensive oral and skin lesions (Endo et al., 2008c). Using ELISA, the authors confirmed a change in the autoantibody profile of sera corresponding with the transition from mucosal PV type (lesions limited to the oral mucosa) to mucocutaneous PV type (lesions found in the oral mucosa and skin) (Endo et al., 2008c). When the lesions were limited to the oral cavity, the Dsg3 ELISA was high, and the Dsg1 ELISA was very low (Endo et al., 2008c). After having oral and skin lesions for 26 months, both the Dsg3 and Dsg1 ELISA levels of the patient were high (Endo et al., 2008c). It is believed that the autoantibodies to Dsg3 were produced initially for unknown reasons, causing the gingival PV lesions. As the autoantibody reaction spread, autoantibodies to Dsg1 as well as Dsg3 were produced, which led to the expression of mucocutaneous PV lesions. The pattern of the dynamic Dsg autoantibody profile displayed by this PV patient may be indicative of the phenomenon called "epitope spreading" (Endo et al., 2008c). The authors concluded that PV patients with oral lesions only should be closely followed and immediately referred to other experts (dermatologists, internists or other physicians) if they develop lesions on parts of their body other than the mouth.

5. Hypersensitivity reactions as cause of DG

Localized or generalized epithelial desquamation, erythema, ulceration, and/or vesiculobullous lesions of the gingiva is sometimes elicited by contact hypersensitivity reactions to various foodstuffs, preservatives, oral hygiene products and dental restorative materials (Endo & Rees, 2006; Endo et al., 2010; Lamey et al., 1990; Rees, 1998, 1999, 2011)

(Figs. 7 and 8). These reactions may appear identical to DG and be difficult to differentiate from mucocutaneous diseases. Non-specific histopathologic findings with submucosal perivascular inflammatory cell infiltration should raise suspicion of a contact hypersensitivity etiology (Endo & Rees, 2006; Endo et al., 2010). Patient maintenance of a 1 to 2 week food diary is often beneficial in identifying the causative agent(s). It is also recommended that the patients record the use and frequency of oral hygiene products. Patients are considered to have allergic reactions to a relevant allergen if their patch test results are positive. Eliminating causative agent(s) leads to disappearance of gingival lesions in most contact hypersensitivity cases.

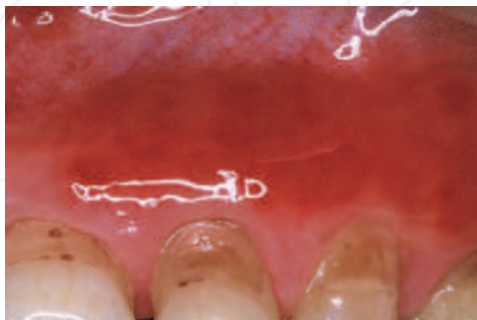

Fig. 7. Gingival erythema following use of a toothpaste

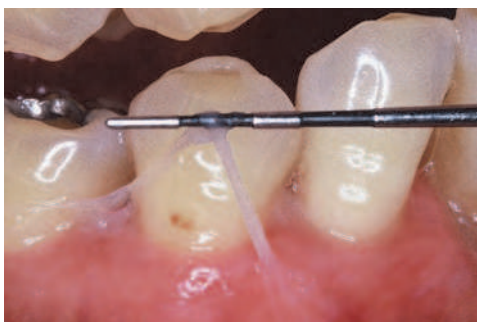

Fig. 8. Epithelial sloughing following use of a mouthrinse

6. Management of DG

The therapeutic approaches to DG are based on expert opinion rather than empirical evidence. Several treatment methods have been reported (Carrozzo & Gandolfo, 1999; Chan et al., 2002; Endo et al., 2008b; Fatahzadeh et al., 2006; Kirtschig et al., 2003; Lamey et al., 1992; Motta et al., 2009; Nisengard, 1996; Nisengard & Levine, 1995). However, treatment may achieve only a temporary effect if idiopathic or autoimmune diseases are causing the DG. A wide range of medications has been advocated for DG but few have been subjected to adequate placebo-controlled trials. The specific disease or disorder causing the DG, the severity of the DG lesions, the presence or absence of extraoral lesions, and the medical history of the patient are the key factors in determining the selection of a topical or systemic treatment (Figs. 9,10,11,12).

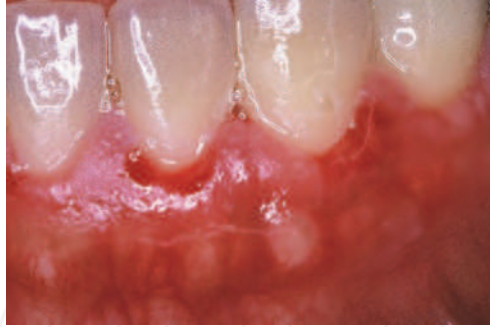

Fig. 9. Initial presentation associated with PV in a 31-year-old woman. The initial examination revealed localized erosions in the marginal gingiva, which is the only site involved in this patient.

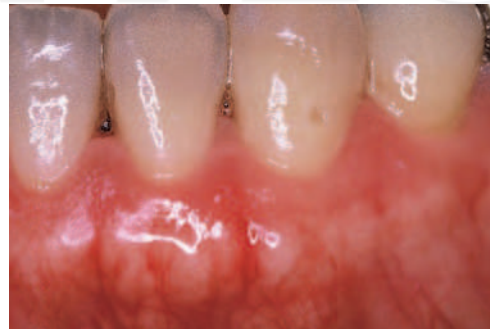

Fig. 10. Treatment response associated with PV in a 31-year-old woman. The gingival lesions went into remission with the topical corticosteroid therapy. However, the circulating autoantibody titer to desmoglein 3 was consistently high, so the patient should be closely followed.

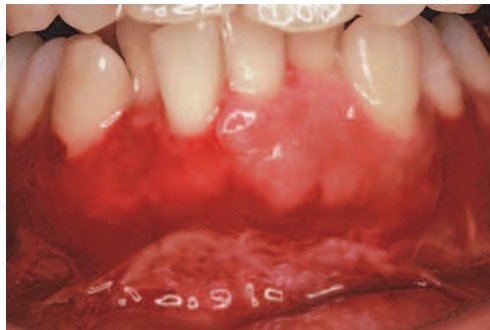

Fig. 11. Initial presentation associated with PV in a 46-year-old woman. The initial examination revealed severe desquamation and erosion on the gingiva. Lesions were also found on the tongue, soft palate, floor of mouth and skin. The patient complained of pain on swallowing.

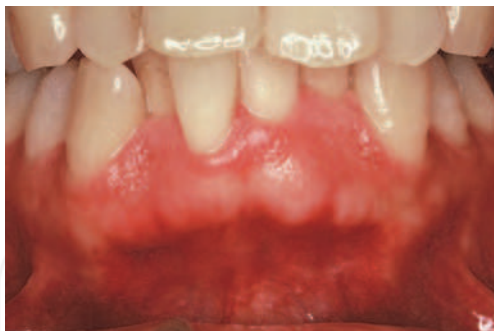

Fig. 12. Treatment response associated with PV in a 46-year-old woman. DG was successfully managed with systemic treatment by a dermatologist.

Treatment of DG requires elimination or control of local irritants. Rough restorations, ill-fitting dentures, traumatic oral hygiene procedures, and dysfunctional oral habits should be corrected (Endo et al., 2006b; Fatahzadeh et al., 2006). Prosthetic treatment for patients having DG should be limited to a fixed prosthesis, since wearing a tissue-borne prosthesis may be uncomfortable (Erpenstein, 1985; Fatahzadeh et al., 2006). In some cases, DG can be successfully managed with topical corticosteroids combined with effective plaque control (Endo et al., 2005; Endo et al., 2008b; Endo et al., 2008c; Guiglia et al., 2007) (Figs. 13 and 14). The symptoms of the gingiva were improved by meticulous oral hygiene habits in some DG patients with oral LP (Erpenstein, 1985; Guiglia et al., 2007; Holmstrup et al., 1990) (Figs. 15 and 16). Plaque accumulation may be a stimulus factor to make DG worse, but the plaque itself does not cause DG. Therefore, it should be noted that the underlying causes of DG cannot be eliminated by plaque control alone.

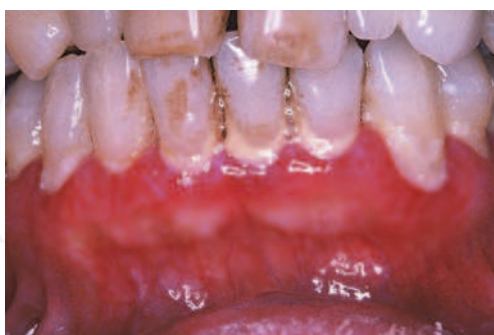

Fig. 13. Initial presentation associated with MMP in a 51-year-old woman. The initial examination revealed mild erythema and swelling of the gingiva with plaque and calculus deposits. The gingiva bled easily, and it was hard for her to brush her teeth.

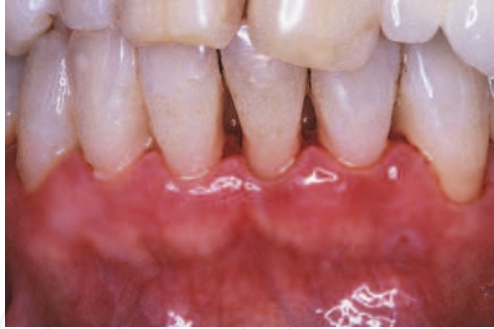

Fig. 14. Treatment response associated with MMP in a 51-year-old woman. The symptoms of the gingiva improved due to a topical corticosteroid combined with effective plaque control.

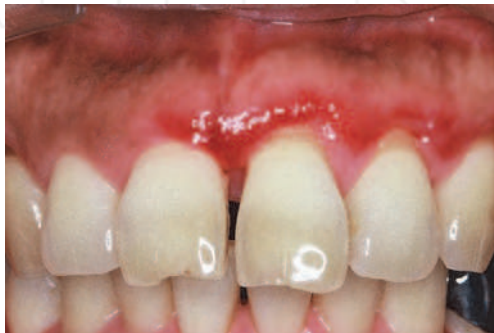

Fig. 15. Initial presentation associated with LP in a 55-year-old woman. The initial examination revealed moderate erythematous attached gingiva.

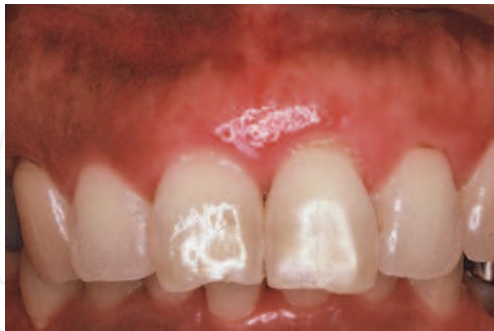

Fig. 16. Treatment response associated with LP in a 55-year-old woman. The condition of the gingiva improved with effective plaque control alone. The improved gingival condition was maintained for a long period.

Periodontal and dental problems are often observed in DG patients. However, little information is available regarding the periodontal and dental management of DG patients

(Damoulis & Gagari, 2000; Lilly et al., 1995; Rees, 1995). There are several case reports on periodontal surgery or implant therapy performed on patients with DG (Endo et al., 2005; Esposito et al., 2003; Fatahzadeh et al., 2006; Lorenzana et al., 2001; Penarrocha-Diago et al., 2000). Lorenzana et al. (2001) described the successful treatment of multiple gingival recessions in a patient with cicatricial pemphigoid. Following the elimination of the pemphigoid-associated lesions, the gingival recessions were treated using connective tissue grafts. During the surgical and healing phases of treatment, the patient continued with applications of a topical corticosteroid. After a follow-up period of 18 months, nearly 100% root coverage was evident with favorable esthetics (Lorenzana et al., 2001). Endo et al. (2005) described a PV patient with a favorable outcome after the effective treatment of oral lesions. A buccal frenulectomy was performed to improve the abnormal attachment position of the frenulum. There were no adverse effects on the wound healing, since a low potency corticosteroid was used for the treatment, and the treatment period was short. The patient maintained lesion-free oral mucosa for the following six months (Endo et al., 2005). Desquamation of tissue and a lack of tissue elasticity caused by active mucosal disease can disturb the manipulation of the mucosal flap (Brain et al., 1999). Increasing medication dosage and/or frequency and strict mucosal disease control prior to surgical intervention may facilitate tissue manipulation and reduce the surgical complications (Toscano et al., 2010). However, the long-term use of topical corticosteroids may adversely affect normal wound healing, which is a factor complicating the surgical management of these patients. Implant therapy is likely to enhance the quality of life in patients with systemic diseases and may help them maintain long-term masticatory function (Nakadai et al., 2010). Published case reports indicated that DG patients associated with PV (Fatahzadeh et al., 2006), LP (Esposito et al., 2003) and epidermolysis bullosa (Penarrocha-Diago et al., 2000) can be successfully treated with osseointegrated implants. These reports indicate that the degree of disease control may be more important than the nature of the disease itself in regard to the effects on osseointegration.

It is difficult for patients with DG to brush their teeth due to pain and bleeding. Therefore, their oral hygiene is likely to be ineffective, making it difficult to treat this condition (Arduino et al., 2011; Pradeep et al., 2010; Ramon-Fluixa et al., 1999). Lack of correct oral hygiene and the accumulation of plaque may increase the long-term risk for plaque-induced periodontal diseases. However, there is some controversy about the relationship between the existence of DG and periodontal status (Akman et al., 2008; Arduino et al., 2011; Lo Russo et al., 2010; Ramon-Fluixa et al., 1999; Schellinck et al., 2009; Tricamo et al., 2006). Akman et al. (2008) evaluated the periodontal status of PV patients and compared it with that of healthy controls. The results showed that the periodontal condition is worse in PV patients. They concluded that PV patients should be encouraged to continue long-term periodontal follow-ups (Akman et al., 2008). Arduino et al. (2011) showed that patients diagnosed with MMP have higher levels of gingival and periodontal inflammation than healthy controls due to a substantial difference in the oral hygiene of the study groups. A pair of recent studies (Schellinck et al., 2009; Tricamo et al., 2006) showed that patients with MMP appeared to be no more at risk than their matched healthy controls for developing an increased progression of periodontal disease. In the first of these studies (Tricamo et al., 2006) the periodontal health of patients with MMP was compared to that of age and sex matched control patients without MMP or other forms of DG. MMP patients were found to have significantly more Class I furcation defects and more gingivitis but were otherwise

similar to controls. In a 5 year follow-up of the same MMP patients and the same controls (Schellinck et al., 2009), both groups experienced some progression of periodontal disease but there were no significant differences between groups. Ramon-Fluixa et al. (1999) reported that the periodontal status in patients with oral LP was no worse than that observed among healthy controls even if patients with atrophic-erosive gingival lesions exhibited higher plaque and calculus deposits. Furthermore, Lo Russo et al. (2010) showed that in sites where DG lesions are present, the probing depth and clinical attachment loss, full-mouth plaque score and full-mouth bleeding score are not significantly different from sites where DG lesions are absent.

7. Conclusions

The clinical and diagnostic features of DG were reviewed in this chapter. Although a definitive diagnosis is required to provide proper treatment, it is almost impossible to differentiate between the diseases and disorders reported to cause DG based solely on the clinical presentation. Both histopathological examination and DIF testing are often essential to establish a definitive diagnosis. If biopsy testing is inconclusive, other etiologic factors such as hypersensitivity reactions to oral hygiene products should be suspected. The management of DG can be challenging for oral health practitioners. Since it is possible for the lesions to recur after DG goes into remission, patients should be observed for a long period of time. Periodic follow-ups should be performed and treatment started immediately when gingival lesions recur.

8. References

- Akman, A., Kacaroglu, H., Yilmaz, E., & Alpsoy, E. (2008). Periodontal status in patients with pemphigus vulgaris. *Oral Dis*, Vol.14, No.7, (October 2008), pp. 640-3
- Alexandre, M., Brette, M.D., Pascal, F., Tsianakas, P., Fraitag, S., Doan, S., Caux, F., Dupuy, A., Heller, M., Lievre, N., Lepage, V., Dubertret, L., Laroche, L., & Prost-Squarcioni, C. (2006). A prospective study of upper aerodigestive tract manifestations of mucous membrane pemphigoid. *Medicine (Baltimore)*, Vol.85, No.4, (July 2006), pp. 239-52
- Al-Hashimi, I., Schifter, M., Lockhart, P.B., Wray, D., Brennan, M., Migliorati, C.A., Axell, T., Bruce, A.J., Carpenter, W., Eisenberg, E., Epstein, J.B., Holmstrup, P., Jontell, M., Lozada-Nur, F., Nair, R., Silverman, B., Thongprasom, K., Thornhill, M., Warnakulasuriya, S., & van der Waal, I. (2007). Oral lichen planus and oral lichenoid lesions: diagnostic and therapeutic considerations. *Oral Surg Oral Med Oral Pathol Oral Radiol Endod*, Vol.103, No.S25, (March 2007), pp. e1-12
- Amagai M. (1999). Autoimmunity against desmosomal cadherins in pemphigus. *J Dermatol Sci*, Vol.20, No.2, (June 1999), pp. 92-102
- Amagai, M., Komai, A., Hashimoto, T., Shirakata, Y., Hashimoto, K., Yamada, T., Kitajima, Y., Ohya, K., Iwanami, H., & Nishikawa, T. (1999). Usefulness of enzyme-linked immunosorbent assay using recombinant desmogleins 1 and 3 for serodiagnosis of pemphigus. *Br J Dermatol*, Vol.140, No.2, (February 1999), pp. 351-7
- Arduino, P.G., Farci, V., D'Aiuto, F., Carcieri, P., Carbone, M., Tanteri, C., Gardino, N., Gandolfo, S., Carrozzo, M., & Brocchetto, R. (2011). Periodontal status in oral

- mucous membrane pemphigoid: initial results of a case-control study. *Oral Dis*, Vol.17, No.1, (January 2011), pp. 90-4
- Bagan, J., Lo Muzio, L., & Scully, C. (2005). Mucosal disease series. Number III. Mucous membrane pemphigoid. *Oral Dis*, Vol.11, No.4, (July 2005), pp. 197-218
- Balding, S.D., Prost, C., Diaz, L.A., Bernard, P., Bedane, C., Aberdam, D., & Giudice, G.J. (1996). Cicatricial pemphigoid autoantibodies react with multiple sites on the BP180 extracellular domain. *J Invest Dermatol*, Vol.106, No.1, (January 1996), pp. 141-6
- Barnett, M.L., Wittwer, J.W., & Miller, R.L. (1981). Desquamative gingivitis in a 13-year-old male. Case report. *J Periodontol*, Vol.52, No.5, (May 1981), pp. 270-4
- Bedane, C., McMillan, J.R., Balding, S.D., Bernard, P., Prost, C., Bonnetblanc, J.M., Diaz, L.A., Eady, R.A., & Giudice, G.J. (1997). Bullous pemphigoid and cicatricial pemphigoid autoantibodies react with ultrastructurally separable epitopes on the BP180 ectodomain: evidence that BP180 spans the lamina lucida. *J Invest Dermatol*, Vol.108, No.6, (June 1997), pp. 901-7
- Brain, J.H., Paul, B.F., & Assad, D.A. (1999). Periodontal plastic surgery in a dystrophic epidermolysis bullosa patient: review and case report. *J Periodontol*, Vol.70, No.11, (November 1999), pp. 1392-6
- Bystryjn, J.C., & Rudolph, J.L. (2005). Pemphigus. *Lancet*, Vol.66, No.9479, (July 2005), pp. 61-73
- Calabresi, V., Carrozzo, M., Cozzani, E., Arduino, P., Bertolusso, G., Tirone, F., Parodi, A., Zambruno, G., & Di Zenzo, G. (2007). Oral pemphigoid autoantibodies preferentially target BP180 ectodomain. *Clin Immunol*, Vol.122, No.2, (February 2007), pp. 207-13
- Camacho-Alonso, F., Lopez-Jornet, P., & Bermejo-Fenoll, A. (2007). Gingival involvement of oral lichen planus. *J Periodontol*, Vol.78, No.4, (April 2007), pp. 640-4
- Carrozzo, M., & Gandolfo, S. (1999). The management of oral lichen planus. *Oral Dis*, Vol.5, No.3, (July 1999), pp. 196-205
- Carrozzo, M., Cozzani, E., Broccoletti, R., Carbone, M., Pentenero, M., Arduino, P., Parodi, A., & Gandolfo, S. (2004). Analysis of antigens targeted by circulating IgG and IgA antibodies in patients with mucous membrane pemphigoid predominantly affecting the oral cavity. *J Periodontol*, Vol.75, No.10, (October 2004), pp. 1302-8
- Chan, L.S., Ahmed, A.R., Anhalt, G.J., Bernauer, W., Cooper, K.D., Elder, M.J., Fine, J.D., Foster, C.S., Ghohestani, R., Hashimoto, T., Hoang-Xuan, T., Kiritschig, G., Korman, N.J., Lightman, S., Lozada-Nur, F., Marinkovich, M.P., Mondino, B.J., Prost-Squarcioni, C., Rogers, R.S. 3rd, Setterfield, J.F., West, D.P., Wojnarowska, F., Woodley, D.T., Yancey, K.B., Zillikens, D., & Zone, J.J. (2002). The first international consensus on mucous membrane pemphigoid: definition, diagnostic criteria, pathogenic factors, medical treatment, and prognostic indicators. *Arch Dermatol*, Vol.138, No.3, (March 2002), pp. 370-9
- Cheng, Y.S., Rees, T.D., Wright, J.M., & Plemons, J.M. (2001). Childhood oral pemphigoid: a case report and review of the literature. *J Oral Pathol Med*, Vol.30, No.6, (July 2001), pp. 372-7

- Damoulis, P.D., & Gagari, E. (2000). Combined treatment of periodontal disease and benign mucous membrane pemphigoid. Case report with 8 years maintenance. *J Periodontol*, Vol.71, No.10, (October 2000), pp. 1620-9
- Daneshpazhooh, M., Chams-Davatchi, C., Khamesipour, A., Mansoori, P., Taheri, A., Firooz, A., Mortazavi, H., Esmaili, N., & Dowlati, Y. (2007). Desmoglein 1 and 3 enzyme-linked immunosorbent assay in Iranian patients with pemphigus vulgaris: correlation with phenotype, severity, and disease activity. *J Eur Acad Dermatol Venereol*, Vol.21, No.10, (November 2007), pp. 1319-24
- Eisen, D. (2002). The clinical features, malignant potential, and systemic associations of oral lichen planus: a study of 723 patients. *J Am Acad Dermatol*, Vol.46, No.2, (February 2002), pp. 207-14
- Endo, H., Rees, T.D., Matsue, M., Kuyama, K., Nakadai, M., & Yamamoto, H. (2005). Early detection and successful management of oral pemphigus vulgaris: a case report. *J Periodontol*, Vol.76, No.1, (January 2005), pp. 154-60
- Endo, H., & Rees, T.D. (2006). Clinical features of cinnamon-induced contact stomatitis. *Compend Contin Educ Dent*, Vol.27, No.7, (July 2006), pp. 403-9; 410, 421
- Endo, H., Rees, T.D., Kuyama, K., Kono, Y., & Yamamoto, H. (2006a). Clinical and diagnostic features of mucous membrane pemphigoid. *Compend Contin Educ Dent*, Vol.27, No.9, (September 2006), pp. 512-6; 517-8
- Endo, H., Rees, T.D., Hallmon, W.W., Kono, Y., & Kato, T. (2006b). Self-inflicted gingival injuries caused by excessive oral hygiene practices. *Tex Dent J*, Vol.123, No.12, (December 2006), pp. 1098-104
- Endo, H., & Rees, T.D. (2007). Cinnamon products as a possible etiologic factor in orofacial granulomatosis. *Med Oral Patol Oral Cir Bucal*, Vol.12, No.6, (October 2007), pp. e440-4
- Endo, H., Rees, T.D., Kuyama, K., Matsue, M., & Yamamoto, H. (2008a). Use of oral exfoliative cytology to diagnose desquamative gingivitis: a pilot study. *Quintessence Int*, Vol.39, No.4, (April 2008), pp. e152-61
- Endo, H., Rees, T.D., Kuyama, K., Matsue, M., & Yamamoto, H. (2008b). Successful treatment using occlusive steroid therapy in patients with erosive lichen planus: a report on 2 cases. *Quintessence Int*, Vol.39, No.4, (April 2008), pp. e162-72
- Endo, H., Rees, T.D., Hallmon, W.W., Kuyama, K., Nakadai, M., Kato, T., Kono, Y., & Yamamoto, H. (2008c). Disease progression from mucosal to mucocutaneous involvement in a patient with desquamative gingivitis associated with pemphigus vulgaris. *J Periodontol*, Vol.79, No.2, (February 2008), pp. 369-375
- Endo, H., Rees, T.D., Sisilia, F., Kuyama, K., Ohta, M., Ito, T., Kato, T., Kono, Y., & Yamamoto, H. (2010). atypical gingival manifestations that mimic mucocutaneous diseases in a patient with contact stomatitis caused by toothpaste. *The Journal of Implant and Advanced Clinical Dentistry*, Vol.2, No.2, (March 2010), pp. 101-6
- Erpenstein, H. (1985). Periodontal and prosthetic treatment in patients with oral lichen planus. *J Clin Periodontol*, Vol.12, No.2, (February 1985), pp. 104-12

- Esposito, S.J., Camisa, C., & Morgan, M. (2003). Implant retained overdentures for two patients with severe lichen planus: a clinical report. *J Prosthet Dent*, Vol.89, No.1, (January 2003), pp. 6-10
- Fatahzadeh, M., Radfar, L., & Sirois, D.A. (2006). Dental care of patients with autoimmune vesiculobullous diseases: case reports and literature review. *Quintessence Int*, Vol.37, No.10, (November-December 2006), pp. 777-87
- Fleming, T.E., & Korman, N.J. (2000). Cicatricial pemphigoid. *J Am Acad Dermatol*, Vol.43, No.4, (October 2000), pp. 571-91; 591-4
- Guiglia, R., Di Liberto, C., Pizzo, G., Picone, L., Lo Muzio, L., Gallo, P.D., Campisi, G., & D'Angelo, M. (2007). A combined treatment regimen for desquamative gingivitis in patients with oral lichen planus. *J Oral Pathol Med*, Vol.36, No.2, (February 2007), pp. 110-6
- Harman, K.E., Gratian, M.J., Bhogal, B.S., Challacombe, S.J., & Black, M.M. (2000). A study of desmoglein 1 autoantibodies in pemphigus vulgaris: racial differences in frequency and the association with a more severe phenotype. *Br J Dermatol*, Vol.143, No.2, (August 2000), pp. 343-8
- Higgins, G.T., Allan, R.B., Hall, R., Field, E.A., & Kaye, S.B. (2006). Development of ocular disease in patients with mucous membrane pemphigoid involving the oral mucosa. *Br J Ophthalmol*, Vol.90, No.8, (August 2006), pp. 964-7
- Higgins, T.S., Cohen, J.C., & Sinacori, J.T. (2010). Laryngeal mucous membrane pemphigoid: a systematic review and pooled-data analysis. *Laryngoscope*, Vol.120, No.3, (March 2010), pp. 529-36
- Holmstrup, P., Schiotz, A.W., & Westergaard, J. (1990). Effect of dental plaque control on gingival lichen planus. *Oral Surg Oral Med Oral Pathol*, Vol.69, No.5, (May 1990), pp. 585-90
- Ingafou, M., Leao, J.C., Porter, S.R., & Scully, C. (2006). Oral lichen planus: a retrospective study of 690 British patients. *Oral Dis*, Vol.12, No.5, (September 2006), pp. 463-8
- Kirtschig, G., Murrell, D., Wojnarowska, F., & Khumalo, N. (2003). Interventions for mucous membrane pemphigoid and epidermolysis bullosa acquisita. *Cochrane Database Syst Rev*, Vol.1, CD004056
- Lamey, P.J., Lewis, M.A., Rees, T.D., Fowler, C., Binnie, W.H., & Forsyth, A. (1990). Sensitivity reaction to the cinnamonaldehyde component of toothpaste. *Br Dent J*, Vol.168, No.3, (February 1990), pp. 115-8
- Lamey, P.J., Rees, T.D., Binnie, W.H., & Rankin, K.V. (1992). Mucous membrane pemphigoid. Treatment experience at two institutions. *Oral Surg Oral Med Oral Pathol*, Vol.74, No.1, (July 1992), pp. 50-3
- Leao, J.C., Ingafou, M., Khan, A., Scully, C., & Porter, S. (2008). Desquamative gingivitis: retrospective analysis of disease associations of a large cohort. *Oral Dis*, Vol.14, No.6, (September 2008), pp. 556-60
- Lilly, J.P., Spivey, J.D., & Fotos, P.G. (1995). Benign mucous membrane pemphigoid with advanced periodontal involvement: diagnosis and therapy. *J Periodontol*, Vol.66, No.8, (August 1995), pp. 737-41

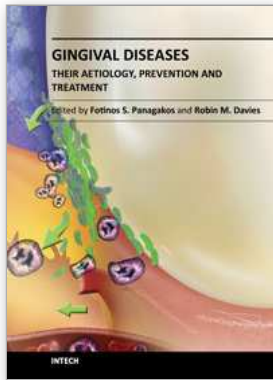
- Lorenzana, E.R., Rees, T.D., & Hallmon, W.W. (2001). Esthetic management of multiple recession defects in a patient with cicatricial pemphigoid. *J Periodontol*, Vol.72, No.2, (February 2001), pp. 230-7
- Lo Russo, L., Fedele, S., Guiglia, R., Ciavarella, D., Lo Muzio, L., Gallo, P., Di Liberto, C., & Campisi, G. (2008). Diagnostic pathways and clinical significance of desquamative gingivitis. *J Periodontol*, Vol.79, No.1, (January 2008), pp. 4-24
- Lo Russo, L., Fierro, G., Guiglia, R., Compilato, D., Testa, N.F., Lo Muzio, L., & Campisi, G. (2009). Epidemiology of desquamative gingivitis: evaluation of 125 patients and review of the literature. *Int J Dermatol*, Vol.48, No.10, (October 2009), pp. 1049-52
- Lo Russo, L., Guiglia, R., Pizzo, G., Fierro, G., Ciavarella, D., Lo Muzio, L., & Campisi, G. (2010). Effect of desquamative gingivitis on periodontal status: a pilot study. *Oral Dis*, Vol.16, No.1, (January 2010), pp. 102-7
- Mignogna, M.D., Lo Muzio, L., & Bucci, E. (2001). Clinical features of gingival pemphigus vulgaris. *J Clin Periodontol*, Vol.28, No.5, (May 2001), pp. 489-93
- Mignogna, M.D., Lo Russo, L., & Fedele, S. (2005). Gingival involvement of oral lichen planus in a series of 700 patients. *J Clin Periodontol*, Vol.32, No.10, (October 2005), pp. 1029-33
- Mignogna, M.D., Fortuna, G., Leuci, S., Ruoppo, E., Marasca, F., & Matarasso, S. (2008). Nikolsky's sign on the gingival mucosa: a clinical tool for oral health practitioners. *J Periodontol*, Vol.79, No.12, (December 2008), pp. 2241-6
- Mollaoglu, N. (2000). Oral lichen planus: a review. *Br J Oral Maxillofac Surg*, Vol.38, No.4, (August 2000), pp. 370-7
- Motta, A.C., Domaneschi, C., Komesu, M.C., Souza Cda, S, Aoki, V., & Migliari, D.A. (2009). Double-blind, crossover, placebo-controlled clinical trial with clobetasol propionate in desquamative gingivitis. *Braz Dent J*, Vol.20, No.3, pp. 231-6
- Nakadai, M., Endo, H., Rees, T.D., Tamaki, H., Okada, H., Kato, T., & Yamamoto, H. (2010). Successful treatment using dental implants in patients with systemic sclerosis: a report on two cases. *The Journal of Implant and Advanced Clinical Dentistry*, Vol.1, No.9, (December/January 2010), pp. 55-62
- Nisengard, R.J., & Rogers, R.S. 3rd. (1987). The treatment of desquamative gingival lesions. *J Periodontol*, Vol.58, No.3, (March 1987), pp. 167-72
- Nisengard, R.J., & Levine, R.A. (1995). Diagnosis and management of desquamative gingivitis. *Periodontal Insights*, Vol.2, (July 1995), pp. 4-10
- Nisengard, R.J. (1996). Periodontal implications: mucocutaneous disorders. *Ann Periodontol*, Vol.1, No.1, (November 1996), pp. 401-38
- Plemons, J.M., Gonzales, T.S., & Burkhart, N.W. (1999). Vesiculobullous diseases of the oral cavity. *Periodontol 2000*, Vol.21, (October 1999), pp. 158-75
- Pradeep, A.R., Manojkumar, S.T., & Arjun, R. (2010). Pemphigus vulgaris with significant periodontal findings: a case report. *J Calif Dent Assoc*, Vol.38, No.5, (May 2010), pp. 343-6
- Ramon-Fluixa, C., Bagan-Sebastian, J., Milian-Masanet, M., & Scully, C. (1999). Periodontal status in patients with oral lichen planus: a study of 90 cases. *Oral Dis*, Vol.5, No.4, (October 1999), pp. 303-6

- Rees, T.D. (1995). Vesiculo-ulcerative diseases and periodontal practice. *J Periodontol*, Vol.66, No.8, (August 1995), pp. 747-8
- Rees, T.D. (1998). Drugs and oral disorders. *Periodontol 2000*, Vol.18, (October 1998), pp. 21-36
- Rees, T.D. (1999). Orofacial granulomatosis and related conditions, *Periodontol 2000*, Vol.21, (October 1999), pp. 145-57
- Rees, T.D. (2011). Desquamative gingivitis/ mucocutaneous diseases commonly affecting the gingiva, In: *Hall's Critical Decisions in Periodontology, 5th ed.*, Harpenau, L.A., Kao, R.T, Lundergan, W.P. & Sanz, M., People's Medical Publishing House, ISBN 978-1607950462
- Rinaggio, J., Crossland, D.M., & Zeid, M.Y. (2007). A determination of the range of oral conditions submitted for microscopic and direct immunofluorescence analysis. *J Periodontol*, Vol.78, No.10, (October 2007), pp. 1904-10
- Roopashree, M.R., Gondhalekar, R.V., Shashikanth, M.C., George, J., Thippeswamy, S.H., & Shukla, A. (2010). Pathogenesis of oral lichen planus--a review. *J Oral Pathol Med*, Vol.39, No.10, (November 2010), pp. 729-34
- Schellinck, A.E., Rees, T.D., Plemons, J.M., Kessler, H.P., Rivera-Hidalgo, F., & Solomon, E.S. (2009). A comparison of the periodontal status in patients with mucous membrane pemphigoid: a 5-year follow-up. *J Periodontol*, Vol.80, No.11, (November 2009), pp. 1765-73
- Scully, C., Beyli, M., Ferreiro, M.C., Ficarra, G., Gill, Y., Griffiths, M., Holmstrup, P., Mutlu, S., Porter, S., & Wray, D. (1998). Update on oral lichen planus: etiopathogenesis and management. *Crit Rev Oral Biol Med*, Vol.9, No.1, pp. 86-122
- Scully, C., & Lo Muzio, L. (2008). Oral mucosal diseases: mucous membrane pemphigoid. *Br J Oral Maxillofac Surg*, Vol.46, No.5, (July 2008), pp. 358-66
- Scully, C., & Mignogna, M. (2008). Oral mucosal disease: pemphigus. *Br J Oral Maxillofac Surg*, Vol.46, No.4, (June 2008), pp. 272-7
- Sirois, D.A., Fatahzadeh, M., Roth, R., & Ettlin, D. (2000). Diagnostic patterns and delays in pemphigus vulgaris: experience with 99 patients. *Arch Dermatol*, Vol.136, No.12, (December 2000), pp. 1569-70
- Thorne, J.E., Anhalt, G.J., & Jabs, D.A. (2004) Mucous membrane pemphigoid and pseudopemphigoid. *Ophthalmology*, Vol.111, No.1, (January 2004), pp. 45-52
- Toscano, N.J., Holtzclaw, D.J., Shumaker, N.D., Stokes, S.M., Meehan, S.C., & Rees, T.D. (2010). Surgical considerations and management of patients with mucocutaneous disorders. *Compend Contin Educ Dent*, Vol.31, No.5, (June 2010), pp. 344-50, 352-9; 362, 364
- Tricamo, M.B., Rees, T.D., Hallmon, W.W., Wright, J.M., Cueva, M.A., & Plemons, J.M. (2006). Periodontal status in patients with gingival mucous membrane pemphigoid. *J Periodontol*, Vol.77, No.3, (March 2006), pp. 398-405
- Trimarchi, M., Bellini, C., Fabiano, B., Gerevini, S., & Bussi, M. (2009). Multiple mucosal involvement in cicatricial pemphigoid. *Acta Otorhinolaryngol Ital*, Vol.29, No.4, (August 2009), pp. 222-5
- Van den Bergh, F., & Giudice, G.J. (2003). BP180 (type XVII collagen) and its role in cutaneous biology and disease. *Adv Dermatol*, Vol.19, pp. 37-71

- Xue, J.L., Fan, M.W., Wang, S.Z., Chen, X.M., Li, Y., & Wang, L. (2005). A clinical study of 674 patients with oral lichen planus in China. *J Oral Pathol Med*, Vol.34, No.8, (September 2005), pp. 467-72
- Yih, W.Y., Maier, T., Kratochvil, F.J., & Zieper, M.B. (1998). Analysis of desquamative gingivitis using direct immunofluorescence in conjunction with histology. *J Periodontol*, Vol.69, No.6, (June 1998), pp. 678-85

INTECH

INTECH



Gingival Diseases - Their Aetiology, Prevention and Treatment

Edited by Dr. Fotinos Panagakos

ISBN 978-953-307-376-7

Hard cover, 230 pages

Publisher InTech

Published online 22, September, 2011

Published in print edition September, 2011

Gingival diseases are a family of distinct pathological entities that involve the gingival tissues. These signs and symptoms of these diseases are so prevalent in populations around the world that they are often considered to be "normal" features. The diseases are now classified into two main groups namely: Plaque-Induced and Non-Plaque Induced Gingival Diseases. This book provides dentists, dental hygienists, dental therapists and students with a comprehensive review of gingival diseases, their aetiology and treatment.

How to reference

In order to correctly reference this scholarly work, feel free to copy and paste the following:

Hiroyasu Endo and Terry D. Rees (2011). Diagnosis and Management of Desquamative Gingivitis, *Gingival Diseases - Their Aetiology, Prevention and Treatment*, Dr. Fotinos Panagakos (Ed.), ISBN: 978-953-307-376-7, InTech, Available from: <http://www.intechopen.com/books/gingival-diseases-their-aetiology-prevention-and-treatment/diagnosis-and-management-of-desquamative-gingivitis>

INTECH

open science | open minds

InTech Europe

University Campus STeP Ri
Slavka Krautzeka 83/A
51000 Rijeka, Croatia
Phone: +385 (51) 770 447
Fax: +385 (51) 686 166
www.intechopen.com

InTech China

Unit 405, Office Block, Hotel Equatorial Shanghai
No.65, Yan An Road (West), Shanghai, 200040, China
中国上海市延安西路65号上海国际贵都大饭店办公楼405单元
Phone: +86-21-62489820
Fax: +86-21-62489821