

**BLACKWELL'S**

**UNDERGROUND CLINICAL VIGNETTES**

# **BIOCHEMISTRY, 3E**

**VIKAS BHUSHAN, MD**

University of California, San Francisco, Class of 1991  
Series Editor, Diagnostic Radiologist

**VISHAL PALL, MBBS**

Government Medical College, Chandigarh, India, Class of 1996  
Series Editor, U. of Texas, Galveston, Resident in Internal Medicine &  
Preventive Medicine

**TAO LE, MD**

University of California, San Francisco, Class of 1996

**JOSE M. FIERRO, MD**

La Salle University, Mexico City

**HOANG NGUYEN, MD, MBA**

Northwestern University, Class of 2001

*b*

Blackwell  
Science

---

## CONTRIBUTORS

**Tisha Wang**

University of Texas Medical Branch, Class of 2002

**Fadi Abu Shahin, MD**

University of Damascus, Syria, Class of 1999

**Vipal Soni, MD**

UCLA School of Medicine, Class of 1999

© 2002 by Blackwell Science, Inc.

**Editorial Offices:**

Commerce Place, 350 Main Street, Malden,  
Massachusetts 02148, USA  
Osney Mead, Oxford OX2 0EL, England  
25 John Street, London WC1N 2BS, England  
23 Ainslie Place, Edinburgh EH3 6AJ, Scotland  
54 University Street, Carlton, Victoria 3053,  
Australia

**Other Editorial Offices:**

Blackwell Wissenschafts-Verlag GmbH,  
Kurfürstendamm 57, 10707 Berlin, Germany  
Blackwell Science KK, MG Kodemmacho Building,  
7-10 Kodemmacho Nihombashi, Chuo-ku,  
Tokyo 104, Japan  
Iowa State University Press, A Blackwell Science  
Company, 2121 S. State Avenue, Ames, Iowa  
50014-8300, USA

**Distributors:**

*The Americas*  
Blackwell Publishing  
c/o AIDC  
P.O. Box 20  
50 Winter Sport Lane  
Williston, VT 05495-0020  
(Telephone orders: 800-216-2522;  
fax orders: 802-864-7626)

*Australia*  
Blackwell Science Pty, Ltd.  
54 University Street  
Carlton, Victoria 3053  
(Telephone orders: 03-9347-0300;  
fax orders: 03-9349-3016)

*Outside The Americas and Australia*  
Blackwell Science, Ltd.  
c/o Marston Book Services, Ltd.  
P.O. Box 269  
Abingdon  
Oxon OX14 4YN  
England  
(Telephone orders: 44-01235-465500;  
fax orders: 44-01235-465555)

All rights reserved. No part of this book may be reproduced in any form or by any electronic or mechanical means, including information storage and retrieval systems, without permission in writing from the publisher, except by a reviewer who may quote brief passages in a review.

Acquisitions: Laura DeYoung  
Development: Amy Nuttbrock  
Production: Lorna Hind and Shawn Girsberger  
Manufacturing: Lisa Flanagan  
Marketing Manager: Kathleen Mulcahy  
Cover design by Leslie Haimes  
Interior design by Shawn Girsberger  
Typeset by TechBooks  
Printed and bound by Capital City Press

**Blackwell's Underground Clinical Vignettes:**

**Biochemistry, 3e**

ISBN 0-632-04545-0

Printed in the United States of America  
02 03 04 05 5 4 3 2 1

The Blackwell Science logo is a trade mark of Blackwell Science Ltd., registered at the United Kingdom Trade Marks Registry

**Library of Congress Cataloging-in-Publication Data**

Bhushan, Vikas.  
Blackwell's underground clinical vignettes.  
Biochemistry / author, Vikas Bhushan. – 3rd ed.  
p. : cm. – (Underground clinical vignettes)  
Rev. ed. of: Biochemistry / Vikas Bhushan ... [et al.].  
2nd ed. c1999. ISBN 0-632-04545-0 (pbk.)  
1. Biochemistry – Case studies. 2. Physicians –  
Licenses – United States – Examinations –  
Study guides.  
[DNLM: 1. Biochemistry – Case Report.  
2. Biochemistry – Problems and Exercises.  
QU 18.2 B575b 2002] I. Title: Underground clinical  
vignettes. Biochemistry. II. Title: Biochemistry.  
III. Biochemistry. IV. Title. V. Series.  
RB112.5 .B48 2002  
572.8'076–dc21

2001004933

---

**Notice**

The authors of this volume have taken care that the information contained herein is accurate and compatible with the standards generally accepted at the time of publication. Nevertheless, it is difficult to ensure that all the information given is entirely accurate for all circumstances. The publisher and authors do not guarantee the contents of this book and disclaim any liability, loss, or damage incurred as a consequence, directly or indirectly, of the use and application of any of the contents of this volume.

## CONTENTS

<b>Acknowledgments</b>	<b>x</b>	
<b>Preface to the 3rd Edition</b>	<b>xiii</b>	
<b>How to Use This Book</b>	<b>xvi</b>	
<b>Abbreviations</b>	<b>xvii</b>	
<i>Endocrinology</i>	17-Alpha-Hydroxylase Deficiency	1
	5-Alpha-Reductase Deficiency	2
	Acromegaly	3
	Addison's Disease	4
	Bartter's Syndrome	5
	Congenital Adrenal Hyperplasia	6
	Diabetes Insipidus	7
	Diabetic Ketoacidosis	8
	Glucagonoma	9
	Hirsutism—Idiopathic	10
	Hyperaldosteronism—Primary	11
	Hypercalcemia	12
	Hyperparathyroidism—Primary	13
	Hyperthyroidism (Graves' Disease)	14
	Hypocalcemia from Pancreatitis	15
	Hypokalemia	16
	Hypomagnesemia	17
	Hyponatremia	18
	Insulinoma	19
	Kallmann's Syndrome	20
	Kwashiorkor	21
	Lactic Acidosis	22
	Metabolic Alkalosis	23
	Nonketotic Hyperosmolar Coma	24
	Osteomalacia	25
	Pheochromocytoma	26
	Precocious Puberty	27
	Pseudohypoparathyroidism	28
	Rickets	29
	SIADH	30
	Thyroid Storm	31
	Vitamin A Deficiency	32
	Vitamin B <sub>1</sub> Deficiency (Beriberi)	33
	Vitamin B <sub>3</sub> Deficiency (Pellagra)	34
	Vitamin C Deficiency (Scurvy)	35
	Vitamin K Deficiency	36
<i>Gastroenterology</i>	Carcinoid Syndrome	37
	Crigler-Najjar Syndrome	38

*Genetics*

Dubin–Johnson Syndrome	39
Gilbert’s Disease	40
Wilson’s Disease	41
Acute Intermittent Porphyrria	42
Albinism	43
Alkaptonuria	44
Cystic Fibrosis	45
Cystinuria	46
Ehlers–Danlos Syndrome	47
Fabry’s Disease	48
Familial Hypercholesterolemia	49
Familial Hypertriglyceridemia	50
Fanconi’s Anemia	51
Fragile X Syndrome	52
Galactosemia	53
Gaucher’s Disease	54
Hereditary Fructose Intolerance	55
Homocystinuria	56
Hunter’s Disease	57
Hurler’s Disease	58
Kartagener’s Syndrome	59
Klinefelter’s Syndrome	60
Krabbe’s Disease	61
Lesch–Nyhan Syndrome	62
Maple Syrup Urine Disease	63
Metachromatic Leukodystrophy	64
Niemann–Pick Disease	65
Orotic Aciduria	66
Phenylketonuria (PKU)	67
Phosphoenolpyruvate Carboxykinase Deficiency	68
Pompe’s Disease	69
Porphyria Cutanea Tarda	70
Pyruvate Kinase Deficiency	71
Tay–Sachs Disease	72
von Gierke’s Disease	73
Xeroderma Pigmentosum	74
Anemia—Folate Deficiency	75
Anemia—Iron Deficiency	76
Anemia—Vitamin B <sub>12</sub> Deficiency	77
Glucose-6-Phosphate Dehydrogenase Deficiency	78
Hemophilia, Type A	79
Hereditary Spherocytosis	80

*Hematology/Oncology*

	Methemoglobinemia	81
	Paroxysmal Nocturnal Hemoglobinuria	82
<i>Nephrology/Urology</i>	Renal Tubular Acidosis	83
	Rhabdomyolysis	84
<i>Neurology</i>	Duchenne's Muscular Dystrophy	85
	Wernicke-Korsakoff Syndrome	86
<i>Gynecology</i>	Primary Amenorrhea—Testicular Feminization	87
	Secondary Amenorrhea	88
<i>Orthopedics</i>	Osteogenesis Imperfecta	89
<i>Psychopharmacology</i>	Antabuse Effect	90
<i>Pulmonary</i>	Hyaline Membrane Disease	91
	Alpha-1-Antitrypsin Deficiency	92
	Hyperventilation	93
	Carbon Monoxide Poisoning	94
<i>Rheumatology</i>	Gout	95

## ACKNOWLEDGMENTS

Throughout the production of this book, we have had the support of many friends and colleagues. Special thanks to our support team including Anu Gupta, Andrea Fellows, Anastasia Anderson, Srishti Gupta, Mona Pall, Jonathan Kirsch and Chirag Amin. For prior contributions we thank Gianni Le Nguyen, Tarun Mathur, Alex Grimm, Sonia Santos and Elizabeth Sanders.

We have enjoyed working with a world-class international publishing group at Blackwell Science, including Laura DeYoung, Amy Nuttbrock, Lisa Flanagan, Shawn Girsberger, Lorna Hind and Gordon Tibbitts. For help with securing images for the entire series we also thank Lee Martin, Kristopher Jones, Tina Panizzi and Peter Anderson at the University of Alabama, the Armed Forces Institute of Pathology, and many of our fellow Blackwell Science authors.

For submitting comments, corrections, editing, proofreading, and assistance across all of the vignette titles in all editions, we collectively thank:

Tara Adamovich, Carolyn Alexander, Kris Alden, Henry E. Aryan, Lynman Bacolor, Natalie Barteneva, Dean Bartholomew, Debashish Behera, Sumit Bhatia, Sanjay Bindra, Dave Brinton, Julianne Brown, Alexander Brownie, Tamara Callahan, David Canes, Bryan Casey, Aaron Caughey, Hebert Chen, Jonathan Cheng, Arnold Cheung, Arnold Chin, Simion Chiosea, Yoon Cho, Samuel Chung, Gretchen Conant, Vladimir Coric, Christopher Cosgrove, Ronald Cowan, Karekin R. Cunningham, A. Sean Dalley, Rama Dandamudi, Sunit Das, Ryan Armando Dave, John David, Emmanuel de la Cruz, Robert DeMello, Navneet Dhillon, Sharmila Dissanaiké, David Donson, Adolf Etchegaray, Alea Eusebio, Priscilla A. Frase, David Frenz, Kristin Gaumer, Yohannes Gebreegziabher, Anil Gehi, Tony George, L.M. Gotanco, Parul Goyal, Alex Grimm, Rajeev Gupta, Ahmad Halim, Sue Hall, David Hasselbacher, Tamra Heimert, Michelle Higley, Dan Hoit, Eric Jackson, Tim Jackson, Sundar Jayaraman, Pei-Ni Jone, Aarchan Joshi, Rajni K. Jutla, Faiyaz Kapadi, Seth Karp, Aaron S. Kesselheim, Sana Khan, Andrew Pin-wei Ko, Francis Kong, Paul Konitzky, Warren S. Krackov, Benjamin H.S. Lau, Ann LaCasce, Connie Lee, Scott Lee, Guillermo Lehmann, Kevin Leung, Paul Levett, Warren Levinson, Eric Ley, Ken Lin,



---

Pavel Lobanov, J. Mark Maddox, Aram Mardian, Samir Mehta, Gil Melmed, Joe Messina, Robert Mosca, Michael Murphy, Vivek Nandkarni, Siva Narayanan, Carvell Nguyen, Linh Nguyen, Deanna Nobleza, Craig Nodurft, George Noumi, Darin T. Okuda, Adam L. Palance, Paul Pamphrus, Jinha Park, Sonny Patel, Ricardo Pietrobon, Riva L. Rahl, Aashita Randeria, Rachan Reddy, Beatriu Reig, Marilou Reyes, Jeremy Richmon, Tai Roe, Rick Roller, Rajiv Roy, Diego Ruiz, Anthony Russell, Sanjay Sahgal, Urmimala Sarkar, John Schilling, Isabell Schmitt, Daren Schuhmacher, Sonal Shah, Fadi Abu Shahin, Mae Sheikh-Ali, Edie Shen, Justin Smith, John Stulak, Lillian Su, Julie Sundaram, Rita Suri, Seth Sweetser, Antonio Talayero, Merita Tan, Mark Tanaka, Eric Taylor, Jess Thompson, Indi Trehan, Raymond Turner, Okafo Uchenna, Eric Uyguanco, Richa Varma, John Wages, Alan Wang, Eunice Wang, Andy Weiss, Amy Williams, Brian Yang, Hany Zaky, Ashraf Zaman and David Zipf.

For generously contributing images to the entire *Underground Clinical Vignette* Step 1 series, we collectively thank the staff at Blackwell Science in Oxford, Boston, and Berlin as well as:

- Axford, J. *Medicine*. Osney Mead: Blackwell Science Ltd, 1996. Figures 2.14, 2.15, 2.16, 2.27, 2.28, 2.31, 2.35, 2.36, 2.38, 2.43, 2.65a, 2.65b, 2.65c, 2.103b, 2.105b, 3.20b, 3.21, 8.27, 8.27b, 8.77b, 8.77c, 10.81b, 10.96a, 12.28a, 14.6, 14.16, 14.50.
- Bannister B, Begg N, Gillespie S. *Infectious Disease, 2<sup>nd</sup> Edition*. Osney Mead: Blackwell Science Ltd, 2000. Figures 2.8, 3.4, 5.28, 18.10, W5.32, W5.6.
- Berg D. *Advanced Clinical Skills and Physical Diagnosis*. Blackwell Science Ltd., 1999. Figures 7.10, 7.12, 7.13, 7.2, 7.3, 7.7, 7.8, 7.9, 8.1, 8.2, 8.4, 8.5, 9.2, 10.2, 11.3, 11.5, 12.6.
- Cuschieri A, Hennessy TPJ, Greenhalgh RM, Rowley DA, Grace PA. *Clinical Surgery*. Osney Mead: Blackwell Science Ltd, 1996. Figures 13.19, 18.22, 18.33.
- Gillespie SH, Bamford K. *Medical Microbiology and Infection at a Glance*. Osney Mead: Blackwell Science Ltd, 2000. Figures 20, 23.
- Ginsberg L. *Lecture Notes on Neurology, 7<sup>th</sup> Edition*. Osney Mead: Blackwell Science Ltd, 1999. Figures 12.3, 18.3, 18.3b.
- Elliott T, Hastings M, Desselberger U. *Lecture Notes on Medical Microbiology, 3<sup>rd</sup> Edition*. Osney Mead: Blackwell Science Ltd, 1997. Figures 2, 5, 7, 8, 9, 11, 12, 14, 15, 16, 17, 19, 20, 25, 26, 27, 29, 30, 34, 35, 52.

- 
- Mehta AB, Hoffbrand AV. *Haematology at a Glance*. Osney Mead: Blackwell Science Ltd, 2000. Figures 22.1, 22.2, 22.3.

Please let us know if your name has been missed or misspelled and we will be happy to make the update in the next edition.

## PREFACE TO THE 3RD EDITION

We were very pleased with the overwhelmingly positive student feedback for the 2nd edition of our *Underground Clinical Vignettes* series. Well over 100,000 copies of the UCV books are in print and have been used by students all over the world.

Over the last two years we have accumulated and incorporated **over a thousand “updates”** and improvements suggested by you, our readers, including:

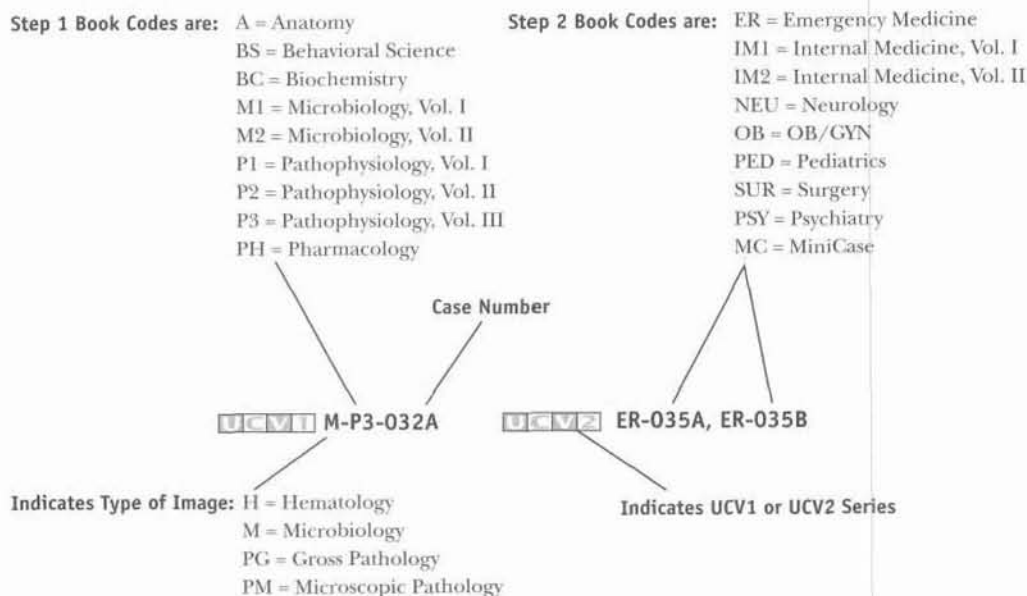
- many additions of specific boards and wards testable content
- deletions of redundant and overlapping cases
- reordering and reorganization of all cases in both series
- a new master index by case name in each Atlas
- correction of a few factual errors
- diagnosis and treatment updates
- addition of 5–20 new cases in every book
- and the addition of clinical exam photographs within *UCV—Anatomy*

And most important of all, the third edition sets now include two brand new **COLOR ATLAS** supplements, one for each Clinical Vignette series.

- The *UCV—Basic Science Color Atlas (Step 1)* includes over 250 color plates, divided into gross pathology, microscopic pathology (histology), hematology, and microbiology (smears).
- The *UCV—Clinical Science Color Atlas (Step 2)* has over 125 color plates, including patient images, dermatology, and funduscopy.

Each atlas image is descriptively captioned and linked to its corresponding Step 1 case, Step 2 case, and/or Step 2 MiniCase.

## How Atlas Links Work:



- If the Case number (032, 035, etc.) is not followed by a letter, then there is only one image. Otherwise A, B, C, D indicate up to 4 images.

**Bold Faced Links:** In order to give you access to the largest number of images possible, we have chosen to cross link the Step 1 and 2 series.

- If the link is bold-faced this indicates that the link is direct (i.e., Step 1 Case with the Basic Science Step 1 Atlas link).
- If the link is not bold-faced this indicates that the link is indirect (Step 1 case with Clinical Science Step 2 Atlas link or vice versa).

We have also implemented a few structural changes upon your request:

- Each current and future edition of our popular *First Aid for the USMLE Step 1* (Appleton & Lange/McGraw-Hill) and *First Aid for the USMLE Step 2* (Appleton & Lange/McGraw-Hill) book will be linked to the corresponding UCV case.
- We eliminated UCV → First Aid links as they frequently become out of date, as the *First Aid* books are revised yearly.

- 
- The Color Atlas is also specially designed for quizzing—captions are descriptive and do not give away the case name directly.

We hope the updated UCV series will remain a unique and well-integrated study tool that provides compact clinical correlations to basic science information. They are designed to be easy and fun (comparatively) to read, and helpful for both licensing exams and the wards.

We invite your corrections and suggestions for the fourth edition of these books. For the first submission of each factual correction or new vignette that is selected for inclusion in the fourth edition, you will receive a personal acknowledgment in the revised book. If you submit over 20 high-quality corrections, additions or new vignettes we will also consider **inviting you to become a “Contributor” on the book of your choice**. If you are interested in becoming a potential “Contributor” or “Author” on a future UCV book, or working with our team in developing additional books, please also e-mail us your CV/resume.

We prefer that you submit corrections or suggestions via electronic mail to [UCVteam@yahoo.com](mailto:UCVteam@yahoo.com). Please include “Underground Vignettes” as the subject of your message. If you do not have access to e-mail, use the following mailing address: Blackwell Publishing, Attn: UCV Editors, 350 Main Street, Malden, MA 02148, USA.

*Vikas Bhushan*

*Vishal Pall*

*Tao Le*

October 2001

## HOW TO USE THIS BOOK

This series was originally developed to address the increasing number of clinical vignette questions on medical examinations, including the USMLE Step 1 and Step 2. It is also designed to supplement and complement the popular *First Aid for the USMLE Step 1* (Appleton & Lange/McGraw Hill) and *First Aid for the USMLE Step 2* (Appleton & Lange/McGraw Hill).

Each UCV 1 book uses a series of approximately 100 “**supra-prototypical**” cases as a way to condense testable facts and associations. The clinical vignettes in this series are designed to incorporate as many testable facts as possible into a cohesive and memorable clinical picture. The vignettes represent composites drawn from general and specialty textbooks, reference books, thousands of USMLE style questions and the personal experience of the authors and reviewers.

Although each case tends to present all the signs, symptoms, and diagnostic findings for a particular illness, **patients generally will not present with such a “complete” picture either clinically or on a medical examination.** Cases are not meant to simulate a potential real patient or an exam vignette. All the **boldfaced “buzzwords” are for learning purposes** and are not necessarily expected to be found in any one patient with the disease.

Definitions of selected important terms are placed within the vignettes in (SMALL CAPS) in parentheses. Other parenthetical remarks often refer to the pathophysiology or mechanism of disease. The format should also help students learn to present cases succinctly during oral “bullet” presentations on clinical rotations. The cases are meant to serve as a condensed review, not as a primary reference. The information provided in this book has been prepared with a great deal of thought and careful research. This book should not, however, be considered as your sole source of information. Corrections, suggestions and submissions of new cases are encouraged and will be acknowledged and incorporated when appropriate in future editions.

## ABBREVIATIONS

5-ASA	5-aminosalicylic acid
ABGs	arterial blood gases
ABVD	adriamycin/bleomycin/vincristine/dacarbazine
ACE	angiotensin-converting enzyme
ACTH	adrenocorticotrophic hormone
ADH	antidiuretic hormone
AFP	alpha fetal protein
AI	aortic insufficiency
AIDS	acquired immunodeficiency syndrome
ALL	acute lymphocytic leukemia
ALT	alanine transaminase
AML	acute myelogenous leukemia
ANA	antinuclear antibody
ARDS	adult respiratory distress syndrome
ASD	atrial septal defect
ASO	anti-streptolysin O
AST	aspartate transaminase
AV	arteriovenous
BE	barium enema
BP	blood pressure
BUN	blood urea nitrogen
CAD	coronary artery disease
CALLA	common acute lymphoblastic leukemia antigen
CBC	complete blood count
CHF	congestive heart failure
CK	creatine kinase
CLL	chronic lymphocytic leukemia
CML	chronic myelogenous leukemia
CMV	cytomegalovirus
CNS	central nervous system
COPD	chronic obstructive pulmonary disease
CPK	creatine phosphokinase
CSF	cerebrospinal fluid
CT	computed tomography
CVA	cerebrovascular accident
CXR	chest x-ray
DIC	disseminated intravascular coagulation
DIP	distal interphalangeal
DKA	diabetic ketoacidosis
DM	diabetes mellitus
DTRs	deep tendon reflexes
DVT	deep venous thrombosis

---

EBV	Epstein–Barr virus
ECG	electrocardiography
Echo	echocardiography
EF	ejection fraction
EGD	esophagogastroduodenoscopy
EMG	electromyography
ERCP	endoscopic retrograde cholangiopancreatography
ESR	erythrocyte sedimentation rate
FEV	forced expiratory volume
FNA	fine needle aspiration
FTA-ABS	fluorescent treponemal antibody absorption
FVC	forced vital capacity
GFR	glomerular filtration rate
GH	growth hormone
GI	gastrointestinal
GM-CSF	granulocyte macrophage colony stimulating factor
GU	genitourinary
HAV	hepatitis A virus
hcG	human chorionic gonadotrophin
HEENT	head, eyes, ears, nose, and throat
HIV	human immunodeficiency virus
HLA	human leukocyte antigen
HPI	history of present illness
HR	heart rate
HRIG	human rabies immune globulin
HS	hereditary spherocytosis
ID/CC	identification and chief complaint
IDDM	insulin-dependent diabetes mellitus
Ig	immunoglobulin
IGF	insulin-like growth factor
IM	intramuscular
JVP	jugular venous pressure
KUB	kidneys/ureter/bladder
LDH	lactate dehydrogenase
LES	lower esophageal sphincter
LFTs	liver function tests
LP	lumbar puncture
LV	left ventricular
LVH	left ventricular hypertrophy
Lytes	electrolytes
MCHC	mean corpuscular hemoglobin concentration
MCV	mean corpuscular volume
MEN	multiple endocrine neoplasia



MGUS	monoclonal gammopathy of undetermined significance
MHC	major histocompatibility complex
MI	myocardial infarction
MOPP	mechlorethamine/vincristine (Oncovorin)/procarbazine/prednisone
MR	magnetic resonance (imaging)
NHL	non-Hodgkin's lymphoma
NIDDM	non-insulin-dependent diabetes mellitus
NPO	nil per os (nothing by mouth)
NSAID	nonsteroidal anti-inflammatory drug
PA	posteroanterior
PIP	proximal interphalangeal
PBS	peripheral blood smear
PE	physical exam
PFTs	pulmonary function tests
PMI	point of maximal intensity
PMN	polymorphonuclear leukocyte
PT	prothrombin time
PTCA	percutaneous transluminal angioplasty
PTH	parathyroid hormone
PTT	partial thromboplastin time
PUD	peptic ulcer disease
RBC	red blood cell
RPR	rapid plasma reagin
RR	respiratory rate
RS	Reed–Sternberg (cell)
RV	right ventricular
RVH	right ventricular hypertrophy
SBFT	small bowel follow-through
SIADH	syndrome of inappropriate secretion of ADH
SLE	systemic lupus erythematosus
STD	sexually transmitted disease
TFTs	thyroid function tests
tPA	tissue plasminogen activator
TSH	thyroid-stimulating hormone
TIBC	total iron-binding capacity
TIPS	transjugular intrahepatic portosystemic shunt
TPO	thyroid peroxidase
TSH	thyroid-stimulating hormone
TTP	thrombotic thrombocytopenic purpura
UA	urinalysis
UGI	upper GI
US	ultrasound

---

VDRL	Venereal Disease Research Laboratory
VS	vital signs
VT	ventricular tachycardia
WBC	white blood cell
WPW	Wolff-Parkinson-White (syndrome)
XR	x-ray

**ID/CC** A 16-year-old girl is referred to an endocrinologist owing to **lack of menses** (PRIMARY AMENORRHEA) and absence of pubic hair, axillary hair, and breast development (LACK OF SECONDARY SEXUAL CHARACTERISTICS).

**HPI** She also complains of frequent **headaches and ringing in her ears** (due to hypertension).

**PE** VS: **hypertension** (BP 160/105). PE: funduscopic exam normal; no lymphadenopathy; no hepatosplenomegaly; absence of breast tissue; no abdominal or pelvic masses palpable; no axillary or pubic hair; vulvar labia normal.

**Labs** Lytes: **hypokalemia**; hypernatremia. ABGs: metabolic **alkalosis** (due to mineralocorticoid action of 11-deoxycorticosterone and corticosterone). Suppressed renin; increase in urinary gonadotropins (due to attempt to compensate for lack of sex hormones); diminished 17-ketosteroids (product of sex hormones); increased progesterone, pregnenolone, 11-deoxycorticosterone, and corticosterone.

**Treatment** Glucocorticoids. Sex hormones.

**Discussion** A decrease in 17- $\alpha$ -hydroxylase produces an increase in 11-deoxycorticosterone and corticosterone (due to shifting metabolism of sex hormones to aldosterone pathway); renin is suppressed (due to aldosterone negative feedback). Females fail to develop secondary sexual characteristics; males develop ambiguous external genitalia (MALE PSEUDOHERMAPHRODITISM).

- ID/CC** A neonatal boy is brought to the pediatrician by his father, who recently discovered that his son **does not urinate through his penis**.
- HPI** The patient's father also reports that he cannot find his son's testes (due to cryptorchidism).
- PE** Penis small for age (**MICROPHALLIA**); testes located in inguinal canal bilaterally (**CRYPTORCHIDISM**); urinary meatus lies in perineum (**HYPOSPADIAS**); scrotal sac bifid.
- Labs** **Markedly reduced dihydrotestosterone with normal testosterone level.** Decreased 5- $\alpha$ -reductase activity.
- Imaging** Pelvic US: confirms cryptorchidism and absent uterus.
- Treatment** Psychosocial support. Gender assignment. Consider appropriate hormonal replacement therapy.
- Discussion** An **autosomal-recessive** disorder of virilization affecting genetic males. 5- $\alpha$ -reductase converts testosterone to dihydrotestosterone. Lack of type 2 isozyme of 5-alpha-reductase produces a decrease in dihydrotestosterone, which is responsible for virilization of the external genitalia.

- ID/CC** A 43-year-old white male comes to the emergency room complaining of severe retro-orbital **headache** (behind his eyes) along with **blurred vision**.
- HPI** He also complains of weakness over the past few months and an **increase in hat size** as well as an inability to wear his wedding ring (due to growth in finger width). His family also notes a **coarsening of his facial features and deepening of his voice**.
- PE** VS: hypertension (BP 150/100). PE: skin thick and oily; **prominent forehead and jaw**; enlarged tongue and widening gaps between teeth; **large hands and feet**; **bitemporal hemianopsia**; **cardiomegaly**; hepatosplenomegaly.
- Labs** **Hyperglycemia**; hyperphosphatemia; **increased IGF-1**; **increased levels of GH** that **fail to suppress** after oral glucose load. UA: increased urinary calcium.
- Imaging** XR: thickening of skull; erosion and **enlargement of sella turcica**; widening distal phalanges in hands and feet. MR, head: enlarged pituitary gland containing a 2 cm mass.
- Gross Pathology** Acidophilic adenoma of pituitary gland with ill-defined capsule exerts mass effects on pituitary and nearby optic chiasm; tumor rarely malignant.
- Micro Pathology** Densely packed, mature cells that are highly granulocytic and eosinophilic; stains highly for GH.
- Treatment** Transsphenoidal microsurgical adenomectomy is the treatment of choice; radiotherapy to reduce further growth of tumor. Medical therapy with octreotide and/or bromocriptine if surgery fails or is contraindicated.
- Discussion** The most common cause of acromegaly is **pituitary adenoma**. If excess GH secretion is present in **childhood, gigantism** appears; **in adults, acromegaly** appears. Headache and joint pain are early complaints; blurred vision and visual-field changes occur later. Almost every organ in the body increases in size; 25% of patients exhibit glucose intolerance. Visual field changes (e.g., bitemporal hemianopsia) may occur secondary to compression of the nerves of the optic chiasm by the tumor.

Atlas Links [UCV1](#) PM-BC-003 [UCV2](#) MC-084

**ID/CC** A 37-year-old female is admitted to the internal medicine ward for evaluation of **increasing weakness** and intermittent episodes of **dizziness, nausea, and vomiting related to stress and exercise**.

**HPI** She is a vegetarian, takes no drugs or medications, and does not drink alcohol or smoke cigarettes. She reports an excessive **craving for salty foods** such as chips and salted peanuts.

**PE** VS: **tachycardia** (HR 110); **hypotension** (BP 90/65). PE: thin with dry mucous membranes; **pigmentation of buccal mucosa and palms of hands**; no neck masses; chest auscultation normal; no abdominal masses; no hepatosplenomegaly; no lymphadenopathy.

**Labs** CBC: normal. Lytes: **hyponatremia; hyperkalemia. Glucose low; increased BUN with normal creatinine**; amylase and LFTs normal; **high ACTH; low cortisol**.

**Treatment** Glucocorticoid and mineralocorticoid hormones. Hydrocortisone on an emergent basis.

**Discussion** Primary hypoadrenalism (ADDISON'S DISEASE) may be caused by **autoimmune mechanisms**, tuberculous infection, or sudden discontinuation of chronic steroid administration. Secondary hypoadrenalism is due to abnormalities of hypothalamic-pituitary function.

- ID/CC** A 15-year-old female is admitted to the hospital for evaluation of persistent **weakness** for the last 6 months that has been unresponsive to multivitamin treatment.
- HPI** She denies allergies, surgeries, psychological problems, transfusions, drug use, or any relevant past medical history.
- PE** VS: heart rate normal; no fever; **normal BP** (excludes primary hyperaldosteronism). PE: well hydrated; pupils equal and reactive to light and accommodation; no neck masses; no lymphadenopathy; chest normal; abdomen soft and nontender; no masses; neurologic exam normal; **no peripheral edema**; sexual development appropriate for age.
- Labs** CBC: normal. Lytes: **hyponatremia; hypokalemia**. ABGs: **metabolic alkalosis. Increased plasma renin** (excludes primary hyperaldosteronism); increased urinary excretion of prostaglandins.
- Micro Pathology** **Juxtaglomerular cell hyperplasia** on renal biopsy.
- Treatment** Indomethacin to decrease prostaglandin synthesis. Potassium chloride supplements and potassium-sparing diuretics.
- Discussion** Bartter's syndrome is a hereditary disorder characterized by a defective  $\text{Na}^+\text{-K}^+\text{-2Cl}^-$  cotransporter in the thick ascending loop of Henle. This results in an impaired reabsorptive conservation mechanism of sodium (due to end-organ resistance to angiotensin), with urinary sodium wasting and a consequent increase in renin production (through increased renal prostaglandins). Therefore, there is an increase in aldosterone activity with hypokalemic alkalosis. Hypokalemia perpetuates the cycle by stimulating renin activity.

**ID/CC** A newborn is evaluated by a neonatologist because the intern who performed the delivery **cannot tell whether the child is male or female** (AMBIGUOUS GENITALIA).

**HPI** The child is also **lethargic** and lacks sufficient strength to suck on mother's milk adequately (due to salt wasting).

**PE** Ambiguous external genitalia; **increase in size of clitoris; fusion of labia** to the point of resembling scrotal sac.

**Labs** Lytes: hyponatremia; **hyperkalemia. Increase in 17- $\alpha$ -OH progesterone** and its metabolite, **pregnanetriol; increase in urinary 17-ketosteroids** (defect is distal to 17, 20-desmolase); elevated serum ACTH. Prenatal diagnosis is possible at 14 to 16 weeks (due to increase in 17- $\alpha$ -OH progesterone). Karyotype: 46,XX female.


**Treatment** Cortisol, dehydrocorticosterone acetate if salt wasting is present.

**Discussion** Lack of 21-hydroxylase causes a decrease in cortisol with a consequent increase in ACTH, which in turn produces hyperplasia of the adrenals—resulting in an increase in androgen production that gives rise to signs of female pseudohermaphroditism (as in this case) or enlarged genitalia in the male. May occur with or without salt wasting.



- ID/CC** A 27-year-old white male complains of **excessive thirst** (POLYDIPSIA) and **increased urination** (POLYURIA) with very diluted urine.
- HPI** The patient drinks several liters of water every day. He was well until this time. The patient also admits to frequent urination (including nocturia) of large volumes that are clear and watery.
- PE** VS: slight tachycardia. PE: mild dryness of mucous membranes; visual field testing normal; no papilledema; pupils equal and reactive.
- Labs** **Low urine specific gravity** (< 1.006); **low urine osmolality** (< 200 mOsm/L); **elevated serum osmolality** (> 290 mOsm/L); **hypernatremia**; **water deprivation test** demonstrates inability to concentrate urine with fluid restriction (urinary osmolality continues to be low).
- Imaging** CT: may show masses or lesions in hypothalamus.
- Treatment** Central (primary) diabetes insipidus: intranasal desmopressin, diuretics and ADH-releasing drugs such as chlorpropamide, carbamazepine and clofibrate. Nephrogenic (secondary) diabetes insipidus: add indomethacin, amiloride, and/or hydrochlorothiazide.
- Discussion** Diabetes insipidus is caused by an ADH deficiency (PRIMARY) or by renal unresponsiveness to ADH (NEPHROGENIC OR SECONDARY). Primary diabetes insipidus can be caused by surgical, traumatic, or anoxic damage to the hypothalamus or pituitary stalk during pregnancy (SHEEHAN'S SYNDROME). Deficiency of ADH results in **renal loss of free water and hypernatremia**.

- ID/CC** A 28-year-old seamstress is admitted to the internal medicine ward because of malaise, **confusion**, **abdominal pain**, vomiting, and diarrhea.
- HPI** She is a known **insulin-dependent diabetic** (IDDM type I, juvenile onset). One day before her admission, she went out to celebrate her birthday and drank **alcohol** until she became intoxicated (she also forgot to administer insulin).
- PE** VS: tachycardia (HR 92); hypotension (BP 90/50) (due to hypovolemia); **rapid, deep breathing** (KUSSMAUL RESPIRATION). PE: **dehydration**; peripheral cyanosis; cold, **dry skin**; **peculiar fruity breath smell** (due to ketone bodies, acetoacetate, and  $\beta$ -OH-butyrate).
- Labs** CBC: leukocytosis (14,000) (without infection). Lytes: hyponatremia (130 mEq/L). ABGs: **markedly reduced bicarbonate** (10 mEq/L); **acidosis** (pH = 7.1). Increased ketones in blood; increased creatinine; **hyperglycemia**; **increased anion gap** (between 10 and 18) (anion gap is calculated as follows:  $[\text{Na} + \text{K}] - [\text{Cl} + \text{HCO}_3]$ ); increased amylase (without pancreatitis). UA: glycosuria; ketonuria.
- Treatment** Nasogastric tube, correction of fluid deficit (caution owing to risk of producing cerebral edema). **Potassium**. Gradual lowering of glucose with **insulin**.
- Discussion** Ketoacidosis might be the first manifestation of diabetes. It is more common in insulin-dependent diabetics than hyperosmolar coma. It usually follows a period of physical or mental stress (e.g., MI, acute grief) or infection.

- ID/CC** A 58-year-old white **female** comes to see her internist because of the development of **polyuria, polydipsia** (due to hyperglycemia), and a **skin eruption** that comes and goes in different parts of her body (NECROLYTIC MIGRATORY RASH).
- HPI** She also complains of increasing intermittent **diarrhea, nausea, vomiting, weight loss**, and occasional weakness and dizziness.
- PE** VS: normal. PE: patient well hydrated; marked pallor; **erythematous rash on anterior chest, legs, and arms**; no neck masses; lungs clear to auscultation; heart sounds rhythmic; abdomen soft; no masses; no peritoneal signs; no lymphadenopathy.
- Labs** CBC: anemia (Hb 7.4 mg/dL). **Markedly increased serum glucagon levels; hyperglycemia.**
- Imaging** MR/CT: 2.5-cm enhancing mass in body and tail of pancreas; several liver metastases.
- Treatment** Surgical removal. Streptozocin if metastatic; insulin; prophylactic heparin and zinc (for skin rash); octreotide.
- Discussion** Glucagonoma is a pancreatic islet cell neoplasm (of  $\alpha$  cells) that secretes abnormally high amounts of glucagon with resulting **symptomatic hyperglycemia**; it may also secrete gastrin, ACTH, and serotonin. Glucagonomas arise from  $\alpha_2$  islet cells in the pancreas, and the majority (> 70%) are malignant. Glucagonomas may also be associated with multiple endocrine neoplasia (MEN) type I.
- Atlas Links**  PM-BC-009A, PM-BC-009B

- ID/CC** A 24-year-old woman is referred to the endocrinologist because of concern over **excessive facial hair** along with hair on her central chest and thighs.
- HPI** The patient's **menses are regular**, with an average flow lasting 3 to 4 days. She is not taking any drugs.
- PE** Hirsutism noted; **no clitoromegaly** present (no evidence of virilization); no abdominal or pelvic mass palpable per abdomen or per vagina.
- Labs** **Normal total testosterone** levels; **normal DHEAS**; normal urine for 17-ketosteroids.
- Imaging** US, abdomen and pelvis: both adrenals and ovaries normal.
- Treatment** No therapy required.
- Discussion** Hirsutism that is disproportionate to the patient's ethnic background and is accompanied by normal periods is termed idiopathic. If testosterone and DHEAS levels are normal, the patient can be reassured that the condition is benign. If the onset of hirsutism is pubertal with irregular periods, the possibility of polycystic ovarian syndrome exists. Recent-onset hirsutism in an adult female, especially when associated with amenorrhea, requires complete investigation to exclude an adrenal or ovarian tumor.

- ID/CC** A 39-year-old woman is referred to an internist by her family practitioner because of persistent **hypertension** that has been **unresponsive to conventional treatment**; she also complains of profound **muscle weakness** (due to hypokalemia).
- HPI** She is a two-pack-a-day smoker who drinks occasionally.
- PE** VS: normal heart rate; **hypertension** (BP 200/100). PE: no pallor; **retinal hemorrhages, exudates, and AV nicking**; lungs clear; no heart murmurs; abdomen soft; no palpable masses; no lymphadenopathy.
- Labs** CBC: increased hematocrit. Lytes: **hypokalemia; hypernatremia** (secondary to hyperaldosteronism). ABGs: **high serum bicarbonate**. Glucose normal (vs. ectopic ACTH production). ECG: left ventricular hypertrophy and strain. UA: no proteinuria. **Aldosterone levels high; renin levels low** (primary hyperaldosteronism).
- Imaging** CT/MR: 1.7-cm enhancing left adrenal mass. NP-59 iodocholesterol scintigraphy positive. Adrenal venous sampling shows >10:1 ratio of aldosterone on the left versus right.
- Micro Pathology** Glomerulosa-cell benign **adrenal adenoma**.
- Treatment** Left adrenalectomy.
- Discussion** Primary hyperaldosteronism typically presents with hypertension, hypokalemia, hypernatremia, and increased bicarbonate due to increased secretion of aldosterone by an adrenal adenoma (CONN'S SYNDROME) or hyperplasia. Hypertension is characteristically **unresponsive to ACE inhibitors**. Surgically correctable causes of hypertension include Conn's syndrome, pheochromocytoma, renal artery stenosis, and coarctation of the aorta.

**ID/CC** A 55-year-old menopausal female comes to see her internist because of progressive **constipation** and **excessive urination** over the past 2 months; she also complains of **palpitations** both at rest and during exercise.

**HPI** She has read “all about” osteoporosis during menopause and is afraid of developing it, so she has been taking **abundant calcium supplements** and vitamin D injections.

**PE** VS: heart rate 80 with skipped beats heard (VENTRICULAR EXTRASYSTOLES). PE: lungs clear; no neck masses; thyroid not palpable; no lymphadenopathy; **muscle weakness with hyporeflexia**; abdomen soft with decreased bowel sounds; no masses; no abnormal pigmentation; **soft tissue calcification** in skin of arms and legs.

**Labs** **Markedly increased serum calcium** (12 mg/dL) (always correct calcium level for serum albumin). Phosphorus normal (makes primary hyperparathyroidism less likely). ABGs: metabolic alkalosis. Increased BUN. ECG: **short Q-T**. No PTH-related protein detected.

**Treatment** Aggressive rehydration with normal saline; diuresis with furosemide to increase sodium and concomitant calcium excretion. Calcitonin, plicamycin, or bisphosphonates (etidronate, pamidronate) may be necessary.

**Discussion** Hypercalcemia may occur in hyperparathyroidism, milk-alkali syndrome, multiple myeloma, Addison’s disease, sarcoidosis, prolonged immobilization, metastatic neoplastic disease (due to increased osteoclastic resorption), and primary neoplastic disease (due to production of a PTH-like substance). Fifty percent of serum calcium is bound to albumin; most of the rest is actively reabsorbed in the proximal tubule together with sodium. This reabsorption is decreased with expansion of extracellular fluid volume.

- ID/CC** A 53-year-old white **female** goes to her family doctor for a routine physical and is found to be **hypercalcemic**.
- HPI** She is asymptomatic except for mild **polyuria**.
- PE** VS: mild **hypertension**. PE: no neck masses; thyroid not palpable; no lymphadenopathy; lungs clear; heart sounds normal; abdomen soft; no masses.
- Labs** **Increased serum calcium; phosphorus low; elevated PTH; increased alkaline phosphatase**. UA: increased urinary calcium; elevated urinary cAMP and hydroxyproline levels. ABGs: **hyperchloremic metabolic acidosis** (normal anion gap). ECG: **short Q-T**.
- Imaging** XR: subperiosteal bone resorption; **cystic long-bone lesions** (BROWN TUMORS). Nuc: increased bone uptake on bone scan.
- Gross Pathology** Soft, round, well-encapsulated, yellowish-brown single parathyroid adenoma weighing 2 g.
- Micro Pathology** Chief cells within adenoma.
- Treatment** Surgical removal.
- Discussion** Primary hypersecretion of parathyroid hormone may be caused by an **adenoma** (vast majority of cases), chief-cell hyperplasia, or carcinoma of the parathyroid glands; it is commonly asymptomatic and is frequently recognized during routine physical exams. When it is symptomatic, peptic ulcer pain, polyuria, polydipsia, constipation, and pancreatitis may be the presenting symptoms. May be associated with multiple endocrine neoplasia (MEN) syndromes I and II.
- Atlas Links** [UCVI](#) PM-BC-013, PG-BC-013

**ID/CC** A 36-year-old female visits her family doctor because of anxiety, palpitations, **intolerance to heat**, nervousness with **trembling hands**, and **weight loss** despite a normal appetite.

**HPI** She is also concerned about increasing **protrusion of her eyes** (EXOPHTHALMOS).

**PE** VS: **tachycardia**; hypertension (BP 150/80). PE: wide pulse pressure; sweaty palms; warm skin; exophthalmos (due to enlargement of extraocular muscles); **generalized enlargement of thyroid gland** with bruit (DIFFUSE GOITER); nodular lesions over anterior aspect of lower legs (PRETIBIAL MYXEDEMA).

**Labs** **Markedly decreased TSH** (due to negative feedback of autonomously secreted thyroid hormones); **increased T<sub>3</sub>, T<sub>4</sub>, and free T<sub>4</sub> index**; positive TSH receptor antibodies and antinuclear antibodies; hypercalcemia. CBC: anemia.

**Imaging** Nuc: increased radioactive iodine uptake measurement; enlarged gland.

**Gross Pathology** Increased vascularity of thyroid gland with symmetrical enlargement.

**Micro Pathology** Thyroid gland hypertrophy and hyperplasia; reduced thyroid hormone storage and colloid; infiltrative ophthalmopathy.

**Treatment** Antithyroid drugs; radioactive iodine.

**Discussion** Also called diffuse toxic goiter, Graves' disease is the most common cause of hyperthyroidism. It is idiopathic in nature but has an **autoimmune basis** and is associated with HLA-B8 and HLA-DR3. LATS, an IgG, is responsible for some manifestations. Signs and symptoms are due to excess circulating thyroid hormone.

**Atlas Links** [UCM1](#) PM-BC-014      [UCM2](#) MC-090A, MC-090B



- ID/CC** A 41-year-old obese female comes to the ER with **severe epigastric pain radiating to the back** accompanied by nausea and vomiting; she had been advised to undergo laparoscopic removal of symptomatic **small gallbladder stones**.
- HPI** She was admitted to the surgical floor and treated for pancreatitis. On the third day, she developed **numbness of the fingers and around the mouth and tongue as well as painful leg cramps (HYPOCALCEMIC TETANY)**.
- PE** VS: hypotension; tachycardia; fever. PE: dehydrated and in acute distress; bilateral basal hypoventilation; abdomen tender in epimesogastrium; hypocalcemic signs present; abduction and flexion of foot when peroneal nerve is tapped (**POSITIVE PERONEAL SIGN**); hyperexcitability while using galvanic current (**ERB'S SIGN**); facial spasm on tapping over cheek (**CHVOSTEK'S SIGN**); carpal spasm seen with arterial occlusion by blood pressure cuff (**TROUSSEAU'S SIGN**).
- Labs** CBC: marked leukocytosis (17,000) with neutrophilia. **Amylase and lipase markedly elevated** (due to acute pancreatitis). ECG: **Q-T prolongation**. Markedly **reduced serum calcium**; normal serum albumin.
- Imaging** KUB: increase in gastrocolic space; **sentinel loop**. CXR: small left pleural effusion.
- Gross Pathology** Hemorrhagic pancreatitis with edema and areas of gray-white necrosis; intraperitoneal free hemorrhagic fluid; chalky-white fat necrosis (**saponification of calcium with lipids**).
- Treatment** Treat pancreatitis. IV calcium gluconate.

**ID/CC** A 73-year-old female complains of **weakness, painful muscle cramps, and constipation.**

**HPI** She suffers from chronic congestive heart failure (CHF) that has been treated with **digoxin** and **furosemide**. She was also on oral potassium tablets but has discontinued them because of gastric upset.

**PE** VS: irregularly irregular pulse (atrial fibrillation); hypertension (BP 145/90); no fever. PE: well hydrated; conjunctiva normal; jugular venous pulse slightly increased, S3 heard; mild hepatomegaly and pitting edema of lower legs (all due to CHF); deep tendon **reflexes hypoactive.**

**Labs** CBC: normal. Lytes: **hypokalemia.** ECG: flattening of S-T segment and T waves; **prominent U waves.**

**Treatment** Potassium-rich foods (chick peas, bananas, papaya); oral potassium supplements; gastric mucosal protective agents; magnesium supplements (deficiency of magnesium frequently coexists). Potassium-sparing diuretics.

**Discussion** Potent diuretics such as furosemide frequently cause excessive renal loss of potassium with symptomatic hypokalemia which, if severe, may be life-threatening. **In patients on digoxin, hypokalemia greatly increases toxicity.**

- ID/CC** A 48-year-old female who has been on **total parenteral nutrition** for 2 weeks complains of **weakness, cramps, palpitations, tremors, and depression.**
- HPI** One week ago, she underwent her fifth major abdominal operation for intestinal fistula and sepsis.
- PE** VS: **tachycardia**; hypotension. PE: patient looks **confused** and “run down”; agitation with muscular **spasticity and hyperreflexia**; heart sounds disclose skipped beats; mild hypoaeration at lung bases; abdomen with three colostomy bags at site of fistula; no peritoneal irritation; no surgical wound infection.
- Labs** CBC: neutrophilic leukocytosis. Lytes: **hypomagnesemia** ( $< 0.8$  mmol/L); borderline hypokalemia; **hypocalcemia** (severe hypomagnesemia reduces PTH secretion); low 24-hour urinary magnesium excretion. ECG: **prolonged P-R and Q-T intervals; wide QRS; tall T waves; premature ventricular ectopic contractions.**
- Treatment** Magnesium supplementation. Hypokalemia and hypocalcemia resolve with magnesium replacement.
- Discussion** Homeostasis of magnesium is achieved through a balance between intestinal (small bowel) absorption and urinary excretion. Deficiency is associated with the use of a large amount of IV fluids, alcoholism, intestinal malabsorption or diarrhea, inadequate replacement in parenteral nutrition, kwashiorkor or marasmus, prolonged GI suction, intestinal fistula, renal tubular acidosis, and use of drugs such as diuretics, cisplatin, methotrexate, amphotericin B, cyclosporine and aminoglycosides.

**ID/CC** A 37-year-old white female complains of **nausea, vomiting, and headache** on her first postoperative day; the charge nurse found her having a grand mal seizure.

**HPI** She had **elective surgery** for a benign left ovarian cyst. Her medical history discloses no previous illness.

**PE** VS: no fever; normal heart rate. PE: well hydrated; slight **confusion and lethargy** as well as general **weakness**; slight increase in JVP; no bleeding or dehiscence (opening of surgical wound) or infection from surgical wound; no peritoneal signs; significant bilateral lower extremity edema.

**Labs** CBC: normal. Lytes: hyponatremia (Na 115). Remainder of routine lab exams normal; normal cortisol (done to exclude possible adrenal insufficiency); serum osmolality < 280.

**Treatment** For hyper- or isovolemic hyponatremia: water restriction (with caution to avoid osmotic central pontine myelinolysis syndrome, which can occur while restoring sodium levels too quickly). For hypovolemic hyponatremia: isotonic saline, slowly.

**Discussion** Hyponatremia is the most common electrolyte disturbance seen in hospitalized patients and is often iatrogenic in nature. In a postoperative setting, the metabolic response to trauma is to increase secretion of ADH, among other hormones, which, coupled with overzealous IV administration of hypotonic fluids, may lead to symptomatic hyponatremia.

- ID/CC** A 48-year-old obese white female who works as a janitor is brought to the ER **in a coma** after being found on the floor of her room.
- HPI** Her husband reveals that she has been having **episodes of early-morning dizziness** and confusion associated with **hunger** and walking; he adds that these **symptoms disappear after eating**. He also states that the patient has frequently been **nervous and irritable**.
- PE** VS: tachycardia (HR 105); BP normal. PE: patient comatose; mild skin pallor; **cold, sweaty hands**; no focal neurologic deficits; heart sounds rhythmic; no murmurs; lungs clear; abdomen soft; no masses; peristalsis present.
- Labs** Normal hemoglobin (14.4 mg/dL); BUN and creatinine normal. Lytes: normal. **Hypoglycemia** (blood glucose 38 mg/dL); elevated insulin; **elevated plasma immunoreactive C-peptide** (vs. exogenous insulin administration, where C-peptide is low). Positive 72 hour fasting test (increased insulin levels despite hypoglycemia).
- Imaging** CT: 1.5-cm **mass in tail of pancreas**. Nuc: mass takes up octreotide.
- Gross Pathology** Single adenomatous mass.
- Micro Pathology** Findings according to type of islet cell involved.
- Treatment** Immediate IV glucose infusion; surgical resection.
- Discussion** The most common pancreatic islet cell tumor is  $\beta$ -cell insulinoma (usually benign). Other types include glucagonomas, somatostatinomas, gastrinomas (ZOLLINGER-ELLISON SYNDROME), and excessive VIP-secreting tumor (VERNER-MORRISON SYNDROME). Islet cell tumors may be seen in multiple endocrine neoplasia (MEN) syndromes.

- ID/CC** An 18-year-old female is brought to a local clinic because she has never had a menstrual period (PRIMARY AMENORRHEA) and shows a **lack of breast development**.
- HPI** She has a **cleft lip and palate**. On directed questioning, she reports a diminished sense of smell (HYPOSMIA).
- PE** VS: normal. PE: left cleft lip and incomplete unilateral cleft palate; marked **hyposmia** on olfactory testing; heart and lung sounds within normal limits; no palpable mass in abdomen and pelvis; **no pubic or axillary hair; no breast tissue**.
- Labs** CBC/Lytes: normal. LFTs normal; **decreased GnRH; low FSH and LH**.
- Imaging** XR, skull: normal sella turcica. MR, brain: absent olfactory bulb(s).
- Treatment** Gonadotropins.
- Discussion** Kallmann's syndrome is an **X-linked** disorder characterized by deficiency of GnRH with a resulting decrease in FSH and LH levels, producing an isolated hypogonadotropic hypogonadism. It is typically associated with agenesis or hypoplasia of the olfactory bulbs, producing anosmia or hyposmia (lack of stimulus for GnRH production due to absent olfactory bulb catecholamine synthesis). More common in **men**.

- ID/CC** A 2-year-old girl, the daughter of an African immigrant, is admitted to the pediatric ward owing to an **increase in abdominal girth** and **failure to thrive**.
- HPI** She recently arrived in the United States from her home country. She was breast-fed until 1 year of age, at which time her mother ran out of milk. She is apathetic and irritable and has been having frequent episodes of diarrhea.
- PE** **Height and weight in fifth percentile; skin and hair depigmentation;** thinning of hair; dry skin; hyperkeratosis on axillae and groin; hepatomegaly and **ascites;** generalized pitting **edema;** loss of muscle; lethargy.
- Labs** CBC: anemia; lymphopenia. **Hypoalbuminemia** (normal in marasmus). Lytes: hypokalemia; hypomagnesemia.
- Imaging** US/CT: fatty liver. KUB: pancreatic calcification (due to tropical pancreatitis). XR: delayed bone age.
- Gross Pathology** **Fatty infiltration of liver.**
- Micro Pathology** Intestinal mucosal atrophy with loss of brush border enzymes; atrophy of pancreatic islet cells; widespread fatty infiltration of liver.
- Treatment** Restore acid-base and electrolyte balance; treat infections; gradually initiate high-protein diet with vitamins and minerals.
- Discussion** Kwashiorkor is a form of malnutrition caused by **protein deprivation** with **normal total caloric intake**.

**ID/CC** A 68-year-old obese male is rushed to the ER after he was found **unconscious** on the floor of his office.

**HPI** He had been on medication for coronary artery disease.

**PE** On admission, he is found to be in an acute state of tissue **hypoperfusion** (SHOCK) with a barely palpable pulse, hypothermia, and bradycardia. Immediate treatment for cardiac shock is begun.

**Labs** ECG: acute anteroseptal myocardial infarction. **Increased serum lactate**; hyperphosphatemia. ABGs: **severe metabolic acidosis** (pH 7.27); bicarbonate 14 mEq/L (low). **Increased anion gap** (19) with no ketoacids; BUN and creatinine normal.

**Treatment** Treat precipitating cause of acidosis; administer bicarbonate if pH is < 7.2. Treat shock.

**Discussion** A state of increased levels of lactic acid in blood (LACTIC ACIDOSIS) may be due to a number of causes, including **shock** and **sepsis** (both of which increase lactic acid production due to hypoxia), methanol poisoning, metformin toxicity, and liver failure (due to failure of lactic acid to be removed from blood by its transformation to glucose). The anion gap is an estimation of the total unmeasured plasma anions, such as proteins, organic acids, phosphate, and sulfate. Increased anion-gap metabolic acidosis is due to salicylate poisoning, alcohol (e.g., methanol, ethanol, propylene glycol) intoxication, lactic acidosis, renal failure, and diabetic ketoacidosis.



**ID/CC** A 1-year-old female is taken to the emergency room because of **persistent vomiting** (20 times in 24 hours) that has been unresponsive to intramuscular antiemetics.

**HPI** While on a family vacation to Florida, she was given vanilla ice cream that was being sold on the street (dairy and meat products may harbor staphylococcal enterotoxins that produce food poisoning).

**PE** VS: tachycardia; mild fever; hypotension. PE: low urinary volume; **eyes sunken**; **poor skin turgor** with dryness of skin and mucous membranes; **lethargy and proximal muscle weakness** (due to hypokalemia).

**Labs** CBC: increased hematocrit (due to hemoconcentration); increased BUN. Lytes: **hypokalemia**; hypochloremia. UA: proteinuria; **high specific gravity**. ABGs: **metabolic alkalosis**. ECG: ST-segment and T-wave depression; U waves (hypokalemia).

**Treatment** Fluid and electrolyte replacement.

**Discussion** Dehydration may be isotonic, hypotonic, or hypertonic. When caused by protracted vomiting, it leads to metabolic alkalosis due to a decrease in hydrogen ion concentration with a compensatory rise in  $PCO_2$  (due to diminished alveolar ventilation). The contraction of volume stimulates the proximal renal tubular cells to reabsorb bicarbonate in spite of alkalosis.

**ID/CC** A 56-year-old man who is a known non-insulin-dependent **diabetic** (NIDDM **type II**, maturity onset) and who has been receiving an oral hypoglycemic agent is brought to the emergency room in a **stuporous state**.

**HPI** For approximately 2 weeks, he had been treated for a **URI** with oral antibiotics and bronchodilators.

**PE** VS: **tachycardia**; hypotension. PE: severe **dehydration** with dry oral mucosa and low urinary volume; patient **semiconscious** and **confused**; pupils react bilaterally and normally to light; evidence of proliferative diabetic retinopathy on fundoscopic exam; no focal neurologic deficit found.

**Labs** CBC: mild leukocytosis (12,600). **Markedly increased blood glucose** (900 mg/dL); **increased serum and urinary osmolality** (> 350 mOsm/kg). Lytes: hypernatremia; mild hypokalemia. **Normal anion gap**. ABGs: normal serum bicarbonate (no acidosis). Elevated BUN and serum creatinine (suggestive of prerenal azotemia). UA: **glycosuria with no ketonuria**.

**Treatment** Hypotonic (one-half normal) saline. Insulin infusion (e.g., lower dose than in ketoacidosis). Potassium and phosphate supplement as needed.

**Discussion** Hyperosmolar, hyperglycemic nonketotic coma occurs mainly in older NIDDM patients and is usually associated with an episode of physical or mental stress (check for silent MI); it is not associated with ketosis or ketoacidosis. Volume depletion is severe (average fluid deficit 25% of total body water), and the mortality rate is high.

- ID/CC** A 44-year-old male is admitted to the orthopedic department because he sustained a **femoral neck fracture when he fell from a small stool**; the type and magnitude of the fracture are not compatible with the patient's age and impact.
- HPI** The patient recently emigrated from Somalia and states that he has been suffering from increasing **leg weakness** and persistent **lower back pain**.
- PE** VS: normal. PE: complete right femoral neck fracture; on palpation, **tenderness of lumbar vertebrae** and pelvic rim.
- Labs** Mild anemia (Hb 10 g/dL). Lytes: normal. **Increased alkaline phosphatase; decreased levels of 25-OH-D<sub>3</sub>; hypocalcemia; hypophosphatemia; increased PTH.**
- Imaging** XR, hip: surgical neck femoral fracture. XR, lumbar spine: **collapse of lumbar vertebrae; generalized osteopenia; pseudofractures** (appearance of nondisplaced fractures representing local bone resorption).
- Micro Pathology** Excess osteoid but poor mineralization.
- Treatment** Vitamin D, calcium (and sometimes phosphate) supplements; surgical treatment of fracture, physiotherapy.
- Discussion** A poor diet in vitamin D and calcium, **lack of sunlight exposure, intestinal malabsorption, renal insufficiency**, or target organ resistance may lead to osteomalacia in the adult (or rickets in children), with defective calcification of osteoid.

**ID/CC** A 40-year-old male visits his internist for an evaluation of sudden (PAROXYSMAL) **attacks of headache, perspiration, and anxiety**; attacks are precipitated by exercise, emotional stress, postural changes, and, at times, urination.

**HPI** **Very high blood pressure** has been recorded at the time of previous paroxysms. The patient has a good appetite but looks cachectic; blood pressure recorded between paroxysms is normal. The patient has no history suggestive of renal disease.

**PE** VS: **hypertension** (BP 180/120). PE: hypertensive retinopathy changes on funduscopic exam.

**Labs** **Elevated blood sugar** (due to increased catecholamines). Lytes: normal. **Increased** 24-hour urinary free **catecholamines** and **vanillylmandelic acid (VMA)** levels.

**Imaging** CT/MR: 5-cm left **adrenal mass**; very high signal on T2-weighted MR. Nuc: MIBG localizes to tumor and metastases.

**Gross Pathology** Encapsulated, **dusky-colored**, round tumor mass with compressed adrenal gland remnants at periphery and foci of necrosis and hemorrhage.

**Micro Pathology** Nests of pleomorphic large cells with basophilic cytoplasm and **chrome-staining granules** in vascular stroma; argentaffin stains positive; membrane-bound secretory granules on electron microscopy.

**Treatment** Treat hypertensive crises with pharmacologic alpha and beta blockade (pretreat with alpha blockers prior to beta blockers); resection of tumor.

**Discussion** Pheochromocytoma is the most common **tumor of the adrenal medulla** in adults; its symptoms are produced by **increased production of catecholamines**. Of these tumors, 10% are extra-adrenal, 10% bilateral, 10% malignant, and 10% familial; 10% occur in children, and 10% calcify. May be associated with multiple endocrine neoplasia (MEN) IIA or IIB syndromes.

**Atlas Links**  **PM-BC-026, PG-BC-026A, PG-BC-026B**

- ID/CC** A 9-year-old female is brought to her pediatrician because of **breast enlargement**.
- HPI** Her mother also reports **cyclical vaginal bleeding** and the appearance of **pubic and axillary hair** since the age of 4; an older cousin developed similar signs and symptoms.
- PE** Fully developed breasts; axillary and pubic hair present; normal mental development; height and weight greater than average for her age; no focal neurologic signs.
- Labs** **Increased plasma FSH, LH**, and estradiol; pubertal pattern of increased gonadotropins after infusion of GnRH.
- Imaging** XR: **advanced bone age**. US: ovary enlarged to pubertal size with cyst formation. CT/MR: no pituitary lesion.
- Gross Pathology** **Ovarian cyst** formation (luteal); in idiopathic variety, no structural abnormality found.
- Treatment** GnRH agonists; psychiatric support; continuous search for possible cause.
- Discussion** The most common cause of precocious puberty is idiopathic or constitutional; less common causes include hypothalamic-pituitary tumors (pinealomas, hamartomas, gliomas) or lesions causing gonadotropin-dependent precocious puberty.

- ID/CC** A 5-year-old **boy** is brought to the pediatrician because of intermittent **numbness and leg cramps**.
- HPI** His father is also concerned about the fact that his child is **shorter** than his classmates.
- PE** **Full, round face**; short neck; flat nasal bridge; right convergence squint and left **cataract**; **delayed dentition**; positive Chvostek's and Trousseau's signs.
- Labs** CBC: normal. Lytes: **hypocalcemia** (< 8.8 mg/dL); **hyperphosphatemia** (> 5 mg/dL). **Increased plasma PTH**; **no increase** in renal **cAMP** and phosphate clearance **with PTH infusion**.
- Imaging** XR: **fourth and fifth metacarpals** are **short**; **premature physeal closure**; thickening of cortices with demineralization.
- Treatment** Calcitriol and calcium supplementation.
- Discussion** Also called Seabright-Bantam syndrome, pseudohypoparathyroidism is an **X-linked dominant** disorder in which there is **resistance to PTH action on the renal tubule** and bone with resulting hypocalcemia. Two types exist according to the response of cAMP to PTH. In type I (as in this case), patients fail to exhibit a phosphaturic response or increased cAMP after administration of PTH. Type II is associated with Albright's hereditary osteodystrophy.

- ID/CC** A 15-month-old Eskimo boy is brought to the pediatric clinic by his parents because of **delayed dentition, poor growth and development**, frequent crying, and weakness.
- HPI** The infant's diet is **deficient in** eggs and **dairy products**, and he spends most of his time indoors (i.e., he has **no exposure to sunlight**).
- PE** Irritability; poor muscular development and muscle tone; abdominal distention; hypotonia of all muscles; anterior fontanelle open; **softening of occipital and parietal bones with elastic recoil** (CRANIOTABES); frontal bossing; enlargement of **costochondral junctions** (RACHITIC ROSARY); **bowing of legs**; **lineal chest depression along diaphragm** (HARRISON'S GROOVE).
- Labs** Serum calcium normal or slightly low; decreased serum phosphorus; increased alkaline phosphatase; low 1,25(OH)<sub>2</sub>-vitamin D level.
- Imaging** XR: **widening of growth plates**; osteopenia of cranial and long bones; irregularity and cupping of distal ends of long bones; pseudofractures in metaphysis (LOOSER'S LINES).
- Gross Pathology** Excess amount of **uncalcified bone** at junction of cartilage; bone stretched and pulled out of shape by gravity; increased osteoid seams; osteopenia; frontal bossing of skull; **pigeon breast deformity**.
- Micro Pathology** Defective mineralization of osteoid in epiphysis and diaphysis.
- Treatment** Increase calcium and vitamin D in diet.
- Discussion** Rickets is a disease of infancy and childhood involving **defective mineralization of osteoid** in bone skeleton and the neuromuscular system because of **low vitamin D** or calcium in the diet; it can also be due to low sunlight exposure (vitamin D conversion in skin) and chronic renal failure (BUN and phosphorus levels are high).
- Atlas Link** [UCVM2](#) MC-308

**ID/CC** A 61-year-old male smoker presents with headache, weakness, **fatigue**, and **decreased urinary output** (OLIGURIA).

**HPI** He was recently diagnosed with **oat cell carcinoma of the lung**.

**PE** Cardiac sounds normal; no murmurs; no arrhythmias; no pitting edema; no hepatomegaly; no jugular plethora (no evidence of cardiac disease); no asterixis, jaundice, spider nevi, or parotid enlargement (no evidence of hepatic disease).

**Labs** **Decreased serum sodium** (HYPONATREMIA); **decreased serum osmolality** (< 280 mOsm/kg); normal or low BUN and serum creatinine; no proteinuria (no renal disease); adrenal and thyroid function tests normal. UA: **urine osmolality markedly increased** (versus psychogenic polydipsia where osmolality is decreased); hypernatruria (urinary Na > 20 mEq/L). **Diminished blood uric acid level** (HYPOURICEMIA).

**Treatment** **Water restriction** plus a high-salt diet. **Demeclocycline**.

**Discussion** **Syndrome of inappropriate** (increased) secretion of **antidiuretic hormone** (SIADH) occurs with either increased hypothalamic secretion (e.g., CNS disease, postoperative states) or ectopic secretion (e.g., tumors such as oat cell carcinoma of the lung). There may also be increased sensitivity to the effect of ADH (as occurs with chlorpropamide, fluoxetine, and carbamazepine).



- ID/CC** A 29-year-old female is brought by ambulance to the emergency room from her workplace owing to **confusion, agitation**, diarrhea, and **vomiting**.
- HPI** Her sister has myasthenia gravis. She gives a history of **recent weight loss** (7 kg) and a **recent severe URI**.
- PE** VS: **fever** (39.3°C); **tachycardia** with irregular pulse; hypotension (BP 100/50). PE: irritability; **delirium**; exophthalmos; diffuse increase in size of thyroid gland (**GOITER**); lungs clear; abdomen soft and nontender; no masses; no peritoneal irritation; deep tendon reflexes brisk; no neck stiffness or focal neurologic signs.
- Labs** CBC/Lytes: normal. LP: CSF values normal. ECG: atrial fibrillation. **Elevated T<sub>4</sub>**, free **T<sub>4</sub>**, and **T<sub>3</sub>**; **low TSH**.
- Treatment** Treatment involves inhibition of thyroid hormone synthesis (with propylthiouracil or methimazole); inhibition of stored thyroid hormone (with iodide and corticosteroids); suppression of the peripheral effects of thyroid hormone (with propranolol); digitalization of patients with CHF and atrial fibrillation; acetaminophen for fever; and treatment of precipitating factors (e.g., antibiotics for infections).
- Discussion** Thyroid storm, a medical emergency, is usually precipitated by surgical or medical stress (e.g., infection) placed on untreated or undertreated hyperthyroid patients. Prevention of postoperative crises is effected through use of iodine and antithyroid drugs.

**ID/CC** A 27-year-old Cuban political dissident visits a medical clinic complaining of **diminished visual acuity, primarily at night**.

**HPI** He recently arrived in the United States by boat after spending several years in prison.

**PE** VS: normal. PE: conjunctiva shows diminished tear lubrication with dryness (XEROSIS; when localized, it forms patches known as Bitot's spots) as well as keratinization and small corneal ulcers (XEROPHTHALMIA).

**Micro Pathology** Keratinizing metaplasia in conjunctiva; follicular hyperkeratosis with glandular plugging.

**Treatment** Vitamin A supplementation.

**Discussion** Vitamin A (RETINOL) is a fat-soluble vitamin derived from  $\beta$ -carotenes that is used for the synthesis of rhodopsin in the retina, for wound healing, and for epithelial cell growth and differentiation. Night blindness (NYCTALOPIA) is an early symptom of vitamin A deficiency; conjunctival xerosis and Bitot's spots are early signs. Corneal ulcers may progress to erosions and eventual destruction of cornea (KERATOMALACIA).

- ID/CC** A 36-year-old black male who is known to be an **alcoholic** comes to the emergency room with shortness of breath, confusion, **foot drop**, and swelling of his legs.
- HPI** He admits to getting drunk at least three times a week. His **diet** consists mainly of canned soup and cheap “junk food” that he eats during the periods in which he is not drunk.
- PE** VS: tachycardia. PE: dyspnea; jugular venous distention; **extremities warm** to touch; cardiomegaly; hepatomegaly; 2+ pitting edema of both lower extremities; confusion with **nystagmus**; decreased deep tendon reflexes.
- Labs** **Increased RBC transketolase activity** coefficient; low serum and urine thiamine levels.
- Imaging** CXR: cardiomegaly with basal lung congestion.
- Gross Pathology** Wernicke’s encephalopathy shows congestion, hemorrhages, and necrosis in thalamus, hypothalamus (**mammillary bodies**), and paraventricular regions.
- Micro Pathology** Demyelination of peripheral nerves with axonal degeneration and fragmentation.
- Treatment** **Thiamine**. Before administering glucose to an alcoholic, thiamine should be given to prevent encephalopathy (due to depletion of thiamine in glycolysis pathways). Alcoholics should also receive IV or oral folate and multivitamins.
- Discussion** Lack of thiamine produces Wernicke-Korsakoff syndrome as well as **high-output heart failure (wet beriberi) and polyneuropathy (dry beriberi)**. Thiamine pyrophosphate (TPP) is a cofactor for the Krebs cycle enzymes  $\alpha$ -ketoglutarate dehydrogenase and pyruvate dehydrogenase as well as transketolase (pentose phosphate pathway).

**ID/CC** A 45-year-old **alcoholic** Hispanic male who recently underwent a strangulated hernia repair becomes irritable and weak, suffers significant weight loss, and develops a **rash** on his face, his neck, and the dorsum of his hands; he also suffers from **diarrhea** and **altered mental status**.

**HPI** After his operation (which involved a 5-cm small bowel resection), the patient became torpid and anorexic with lack of proper return of bowel function for about 3 weeks. His **diet** had been based on **corn** products.

**PE** Erythematous, nonpruritic, hyperpigmented, scaling rash of face, neck (**CASAL'S NECKLACE**), and dorsum of hands; angular stomatitis (**CHEILOSI**) and glossitis; diminished touch and pain sensation in all four extremities; apathy, confusion, and disorientation.

**Labs** UA: low levels of urinary N-methylnicotinamide.

**Micro Pathology** Atrophy and ulceration of gastric and intestinal mucosa; posterior columns show neuronal degeneration and demyelination.

**Treatment** Oral nicotinamide.

**Discussion** Vitamin B<sub>3</sub> (**NIACIN**) deficiency (**PELLAGRA**) is commonly seen in alcoholics and is less frequently seen in patients with GI disorders or in elderly patients. In patients with carcinoid syndrome, tryptophan, the precursor of niacin, is used up to form serotonin. It is usually accompanied by other B vitamin deficiencies. The typical observed triad consists of **dermatitis, dementia, and diarrhea**.

- ID/CC** A 9-month-old white female is brought to the pediatric clinic because of **listlessness and anorexia**.
- HPI** She is the daughter of an unemployed **poor** urban couple and has never before seen a pediatrician or taken any medication. Her parents report a diet of **unsupplemented cow's milk**.
- PE** Weakness; pallor; **hyperkeratosis** and **hemorrhagic perifolliculitis** of skin of lower extremities, forearms, and abdomen; purpuric skin rashes; **splinter hemorrhages** in nail beds of hands; tenderness and swelling of distal femur and costochondral junctions; **bleeding gums**; **petechiae** seen over nasal and oral mucosa.
- Labs** CBC: microcytic, hypochromic anemia; leukopenia. Plasma and platelet levels of ascorbic acid low; **prolonged bleeding time**.
- Imaging** XR: subperiosteal hemorrhages; both legs and knees show "ground glass" appearance of bones and epiphyses.
- Gross Pathology** Growing bone shows diminished osteoid formation, hemarthrosis, and subperiosteal and periarticular hemorrhage; **defective collagen** (vitamin C hydroxylates proline and lysine); endochondral bone formation ceases (osteoblasts fail to form osteoid); existing trabeculae brittle and susceptible to fracture.
- Treatment** Oral ascorbic acid (high doses may produce oxalate and uric acid stones).
- Discussion** Vitamin C (**ASCORBIC ACID**) deficiency, or scurvy, is observed in smokers, oncologic patients, alcoholics, infants, and the elderly.

**ID/CC** A 47-year-old homeless **alcoholic** man (with a diet deficient in leafy vegetables) comes into the emergency room with weakness, **bleeding** gums, swelling in his right knee due to blood collection (HEMARTHROSIS), and **bloody vomit** (HEMATEMESIS).

**HPI** The patient's diet consists of one meal a day of leftovers from fast-food restaurants. He was **given ampicillin** for diarrhea **2 weeks ago** (leading to suppression of vitamin K synthesis by colonic bacteria).

**PE** Thin and **malnourished** with poor hygiene; conjunctival and nail bed pallor; **subcutaneous ecchymosis** in arms and legs; right knee **hemarthrosis**.

**Labs** Anemia (Hb 9.7); **prolonged PT and PTT**; normal platelet count, fibrinogen level, and thrombin time.

**Treatment** Vitamin K supplementation.

**Discussion** Coagulation factors II, VII, IX, and X are dependent on vitamin K for their activity (through  $\gamma$ -carboxylation). Broad-spectrum antibiotic use, malabsorption, and lack of dietary vitamin K result in deficiency, manifested as bleeding. Since these factors are made by the liver, severe liver disease can cause coagulopathy.

- ID/CC** A 47-year-old male high-school teacher visits his internist because of **chronic watery diarrhea** and **hot flashes while drinking alcohol**; a few months ago he also noticed a peculiar **redness of his face**.
- HPI** Every time he works or exercises in the sun, he develops a rash on exposed areas (PHOTODERMATITIS).
- PE** VS: normal. PE: in no acute distress; **redness of face**; no neck masses or increased JVP; **systolic ejection murmur grade I/IV at pulmonary area**, increasing with inspiration (pulmonary stenosis); wheezing heard; abdomen soft and nontender; mild **hepatomegaly**.
- Labs** CBC/Lytes: normal. Glucose, BUN, creatinine, and LFTs normal; no ova or parasites in stool. UA: **increased 5-hydroxyindoleacetic acid (5-HIAA)** in urine (a product of serotonin degradation).
- Imaging** KUB: ladder-step air-fluid levels. UGI: small bowel loops kinked, causing obstruction. CT: starlike thickening of mesentery due to desmoplastic retraction; vague liver metastatic lesions.
- Gross Pathology** Firm, yellow, submucosal nodule in a segment of ileum.
- Micro Pathology** Argentophilic cells (**KULCHITSKY CELLS**) in the intestinal crypts of Lieberkühn invading into mesentery; marked fibrotic reaction.
- Treatment** Octreotide, cyproheptadine (SOMATOSTATIN ANALOG).
- Discussion** Carcinoid tumors arise from the gastrointestinal tract or bronchi. These tumors secrete **serotonin (5-HYDROXYTRYPTAMINE)**, producing the typical clinical syndrome. There may be stenosis of the pulmonic and tricuspid valve and **right-sided heart failure**.

- ID/CC** A 3-week-old male is seen by a neonatologist because of **severe jaundice** that appeared at birth and has been worsening ever since.
- HPI** He is the first-born child of a healthy **Jewish** couple. His mother had an uneventful pregnancy and delivery.
- PE** Average weight and height for age; in no acute distress; **marked jaundice** (jaundice appears at levels of bilirubin around 2.5 to 3.0 mg/dL); slight hepatomegaly.
- Labs** **Markedly increased serum unconjugated bilirubin** (15 mg/dL); **very low fecal urobilinogen**.
- Treatment** Phenobarbital for type II. For type I, the prognosis is guarded, with the likelihood of death in the first year of life.
- Discussion** Crigler–Najjar syndrome is an inherited disorder of bilirubin metabolism that is characterized by a **deficiency** of the enzyme **glucuronyl transferase** and hence by an inability to conjugate bilirubin, with accumulation of indirect bilirubin and risk of kernicterus with brain damage (at bilirubin concentrations of > 20 mg/dL). There are two types: type I, which is more severe and is autosomal recessive, and type II, which is autosomal dominant.



- ID/CC** A 21-year-old female college student visits her gastroenterologist for an evaluation of fatigability and intermittent **right upper quadrant and epigastric pain**.
- HPI** She asked her family doctor to refer her to a gastroenterologist because she was concerned about her pain despite her doctor's reassurance that it was "nothing important."
- PE** VS: normal. PE: mild **jaundice** in conjunctiva and underneath tongue; well hydrated and in no acute distress; no hepatosplenomegaly on abdominal exam; no signs of hepatic failure.
- Labs** **Increased direct bilirubin** (vs. Gilbert's syndrome, in which hyperbilirubinemia is indirect) **and indirect bilirubin; liver enzymes mildly elevated**. UA: bilirubin and urobilinogen (vs. Gilbert's syndrome); **ratio of coproporphyrin I and coproporphyrin III in urine 5:1** (normal = 1).
- Imaging** US: no gallstones; liver normal. Nuc: no biliary excretion on HIDA.
- Gross Pathology** **Liver** normal size and **dark green** in color (versus Rotor syndrome, which has no gross liver abnormalities); absence of gallbladder inflammation or stones.
- Micro Pathology** Centrilobular, lysosomal granules with brownish pigment (catecholamines).
- Treatment** Supportive.
- Discussion** Dubin–Johnson syndrome is a benign **autosomal-recessive** disorder (vs. Gilbert's syndrome) of **defective canalicular bilirubin excretion** characterized by episodes of intermittent jaundice.

**ID/CC** A 19-year-old male with a URI visits his family doctor because he is concerned about **yellowness in his eyes** (JAUNDICE), which he has noticed **whenever he is fatigued** or is suffering from a minor infection.

**HPI** He has no history of dark-colored urine, clay-colored stools, abdominal pain, blood transfusions, or drug use. He is immunized against hepatitis B and does not drink alcohol.

**PE** **Normal except for mild scleral icterus**; no hepatosplenomegaly; no signs of chronic liver failure.

**Labs** Moderately **increased serum bilirubin, predominantly unconjugated**; normal serum transaminases and alkaline phosphatase; normal serum albumin; **serum bilirubin rises after 24-hour fast**.

**Treatment** No metabolic treatment available or necessary.

**Discussion** The most common example of idiopathic hyperbilirubinemia is Gilbert's disease, which is autosomal dominant with variable penetrance. It is due to **defective bilirubin uptake by liver cells** and **low glucuronyl transferase activity**. Bilirubin levels seldom exceed 5 mg/dL, mainly unconjugated, and may vary inversely with caloric intake.

**ID/CC** A 19-year-old female is brought to her family doctor by her parents, who have noticed that she has started **behaving oddly**; 2 days ago they noticed that her **eyes were yellow**.

**HPI** She also complains of **tremor of her hands at rest** and some **rigidity** when trying to grasp objects (basal ganglia affectation). The **parents** of the patient are **first cousins**.

**PE** Patient shows flapping tremor (**ASTERIXIS**) of hands; slit-lamp examination reveals **copper deposits in Descemet's membrane** of the cornea (**KAYSER–FLEISCHER RINGS**); abdominal palpation shows moderate **splenomegaly**.

**Labs** CBC: hemolytic anemia (due to oxidative RBC damage by copper). **AST and ALT elevated** as well as alkaline phosphatase and bilirubin, both direct and indirect; **decrease in serum ceruloplasmin** (copper-transporting protein); **increased urinary copper** (**HYPERCUPRIURIA**); increased urinary uric acid (**HYPERURICOSURIA**).

**Imaging** US: enlargement of liver and spleen.

**Gross Pathology** Copper accumulation in liver, brain, and cornea.

**Micro Pathology** Liver biopsy shows acute inflammation, increased copper levels, and periportal fibrosis (macronodular cirrhosis); **intracytoplasmic hyaline bodies** (**MALLORY BODIES**) seen; **degeneration of basal ganglia** with cavitation, especially of putamen; hyperplasia with glial proliferation of the lenticular nuclei.

**Treatment** **Penicillamine** (copper chelating drug), pyridoxine. Consider liver transplantation.

**Discussion** Wilson's disease is an **autosomal-recessive** inherited disorder of copper metabolism mapped to chromosome 13. It is characterized by **increased absorption of copper from the intestine and diminished excretion in the bile** with resultant copper deposition, primarily in the brain and liver.

**ID/CC** A 23-year-old white **female** is brought to the ER because of strange, dreamlike **hallucinations and blurred vision** that she experienced 1 day **after spending all morning in the sun** painting her house (exposure to sun may precipitate attacks).

**HPI** The patient had undergone two **previous laparotomies** for apparent acute abdomen, but **no pathology was found**. She has had several episodes of **recurrent abdominal pain**.

**PE** VS: no fever or tachycardia. PE: pupils are of unequal size (**ANISOCORIA**); generalized weakness and hypoactive deep-tendon reflexes; disorientation; **foot drop**; **urine very dark** and foul-smelling. No photosensitive skin lesions.

**Labs** UA: **increased urine porphobilinogen and  $\gamma$ -aminolevulinic acid**. Lytes: hyponatremia.

**Gross Pathology** Liver infiltrated with porphobilinogen; central and peripheral nervous system myelin sheath degeneration.

**Micro Pathology** Degeneration of myelin sheath.

**Treatment** High-carbohydrate diet; glucose; hematin.

**Discussion** Acute intermittent porphyria is an **autosomal-dominant deficiency in an enzyme of porphyrin metabolism (porphobilinogen deaminase)** that leads to systemic symptoms, acute abdominal pain, neuropsychiatric signs and symptoms, and CNS and peripheral neuropathy. Acute intermittent porphyria is differentiated from other porphyrias by its **lack of photosensitive skin lesions**. Sun exposure and drugs (e.g., sulfa, barbiturates) may precipitate attacks.

**ID/CC** A 27-year-old **farmer from Florida** (with abundant sun exposure) comes to see his dermatologist for an evaluation of a recent **increase in size and change in color of a skin lesion** that has been present on the dorsum of his hand (a sun-exposed area) for 6 years.

**HPI** The patient is an **albino**, but he has not been able to comply with his dermatologist's orders to wear long sleeves while working in the field.

**PE** **White hair, including eyelashes and eyebrows**; eye exam shows **nystagmus** and poor development of macula with blue iris; poor visual acuity (20/350); skin is pink-white with lack of pigmentation throughout body; numerous actinic (SOLAR) keratoses on face and scalp as well as on dorsum of hands; **ulcerated lesion with indurated edges** on dorsum of hand with hyperpigmentation.

**Labs** Tyrosine assay shows **absence** of the enzyme.

**Gross Pathology** Patches of scaly, irregular, hypertrophied skin in sun-exposed areas (**actinic keratosis**).

**Micro Pathology** Biopsy of lesion on dorsum of hand shows epidermoid (**squamous cell**) cancer with epithelial pearls.

**Treatment** Surgery and/or chemotherapy for skin cancers, avoidance of sun exposure, management of visual impairment.

**Discussion** Albinism is a hereditary disorder that may be generalized or localized and is transmitted as an autosomal-dominant or autosomal-recessive trait. It is always distinguished by various degrees of **hypopigmentation** of the skin, hair, iris, and retina. The defect lies in the pigmentation, not in the number of melanocytes present in the body. The cause is an **absence of tyrosinase**, the enzyme that catalyzes the conversion of tyrosine to dihydroxyphenylalanine and melanin. There is a marked increase in the risk of skin cancer.

- ID/CC** A 37-year-old man presents with **dark, blackened spots in his sclera and ear cartilage** as well as **back pain** and restriction of motion with **pain and swelling of both knee joints**.
- HPI** Directed questioning reveals that his **urine turns black** if left standing.
- PE** **Increased pigmentation** in ears, conjunctiva, nasal bridge, neck, and anterior thorax (**OCHRONOSIS**); arthritis of spine, both knee joints, and fingers.
- Labs** UA: **elevated urine homogentisic acid** (causes urine to darken upon standing or with addition of alkaline substances).
- Imaging** XR: calcification in cartilage of knee menisci and wrist; premature arthritic changes.
- Treatment** Symptomatic treatment of arthritis.
- Discussion** Also called **ochronosis**, alkaptonuria is an autosomal-recessive disorder of tyrosine metabolism characterized by the **absence of homogentisate oxidase** due to a defective gene on chromosome 3 with accumulation of homogentisic acid in cartilage, giving a dark blue discoloration to the tissues and leading to degenerative joint disease.

- ID/CC** An 11-year-old white female is brought to the ER by her parents because of fever, **difficulty breathing**, and a **productive cough with greenish sputum**.
- HPI** Her parents are of northern European descent. She has a history of **recurrent UTIs and foul-smelling diarrhea** since infancy.
- PE** VS: tachycardia; tachypnea (RR 45). PE: mild cyanosis; malnourishment; **nasal polyps**; hyperresonance to lung percussion with **barrel-shaped chest**; scattered rales; hepatomegaly.
- Labs** **High sodium and chloride** concentrations in **sweat test**; *Pseudomonas aeruginosa*, *Haemophilus influenzae* and *Staphylococcus aureus* in sputum culture. PFTs: increased RV/TLC ratio. Increased **fecal fat**. ABGs: hypoxemia; hypercapnia.
- Imaging** CXR: few dilated bronchi (BRONCHIECTASIS) filled with mucus; emphysema; XR, paranasal sinuses: opacification of sinuses.
- Gross Pathology** Atrophic pancreas with almost complete disruption of acini and replacement of exocrine pancreas with fibrous tissue and fat; mucous plugging of canaliculi.
- Micro Pathology** Inflammatory change.
- Treatment** Antibiotics, low-fat diet, and supportive measures; recombinant human DNase (cleaves extracellular DNA from neutrophils in sputum); inhaled amiloride, nasal corticosteroids, systemic corticosteroids, decongestants; consider lung transplant.
- Discussion** Cystic fibrosis is an **autosomal-recessive** disease that is due to a mutation in the long arm of **chromosome 7** (band q31) in the cystic fibrosis transmembrane conductance regulator (CFTR) gene. If CFTR function is deficient, **chloride** and water transport is slowed and secretions are inspissated.

**ID/CC** A 15-year-old female is brought to the emergency room from school following the sudden development of **severe, intermittent right-flank pain** together with nausea, vomiting, and **blood in her urine** (a picture typical of renoureteral stone).

**HPI** Her medical and family history is unremarkable.

**PE** VS: tachycardia; normal BP; slight fever. PE: short stature (due to lysine deficiency); in acute distress; **constantly switches positions in bed** (due to renal colic); abdominal tenderness; no peritoneal irritation; costovertebral angle tenderness.

**Labs** **Increased urinary excretion of cysteine, ornithine, arginine, and lysine** on urine amino acid chromatography (due to intestinal and renal **defect in reabsorption**). UA: hematuria; hexagonal crystals (CYSTEINE) upon cooling of acidified urine sediment.

**Imaging** KUB/IVP/CT urography: radiopaque stone in area of right kidney.

**Treatment** **Low-methionine diet**; increase fluid intake; alkalinize urine; penicillamine.

**Discussion** Cystinuria is an **autosomal-recessive** disorder of dibasic amino acid metabolism (due to impaired renal tubular reabsorption); it leads to increased cysteine urinary excretion and **kidney stone formation**.



- ID/CC** A 9-year-old boy is brought to the emergency room with pain, inability to move his left shoulder, and flattening of the normal rounded shoulder contour (**SHOULDER DISLOCATION**) that occurred when he tried to hit a ball with his bat at a local baseball field.
- HPI** He has **dislocated his left shoulder nine times before and his right shoulder three times before**. He also has a history of **easy bruising**.
- PE** **Hyperelastic skin; “cigarette paper” scars** in areas of trauma; **hyperextensibility of joints**; left shoulder dislocated; multiple bruises over skin.
- Labs** Clotting profile normal.
- Imaging** XR: left shoulder dislocated.
- Micro Pathology** Collagen fibrils of dermis of skin larger than normal and irregular in outline on electron microscopy.
- Treatment** Supportive.
- Discussion** Ehlers–Danlos syndrome is also known as cutis hyperelastica. **Faulty collagen synthesis** produces 10 types of Ehlers–Danlos syndrome, some of which are autosomal recessive (type VI), others autosomal dominant (type IV), and others associated with X-linked recessive transmission (type IX). Prone to aneurysm and dissection in the great vessels.

- ID/CC** A 17-year-old **male** presents with episodes of **painful, burning paresthesias along his palms and soles** along with markedly **diminished vision** in his right eye.
- HPI** His maternal **uncle died of chronic renal failure** at the age of 40.
- PE** Clusters of **purplish-red, hyperkeratotic lesions** on skin around umbilicus, buttocks, and scrotum (**ANGIOKERATOMAS**); **right corneal leukomatous opacity**; neurologic exam normal except for painful paresthesias along arms and soles; pitting edema in lower extremities.
- Labs** **Elevated serum creatinine and BUN** (patients usually die of renal failure). UA: proteinuria; broad casts. PBS: leukocytes reveal deficiency of  $\alpha$ -galactosidase.
- Micro Pathology** Lipid deposition in epithelial and endothelial cells of glomeruli and tubules (**FOAM CELLS**) on renal biopsy; **lysosomal accumulation of glycosphingolipid (ceramide trihexoside)** in the form of “myelin bodies” on electron microscopy of skin, heart, kidneys, and CNS.
- Treatment** Treat pain crises symptomatically; renal failure may require renal transplantation.
- Discussion** Fabry’s disease, a sphingolipidosis, is a **rare X-linked recessive disorder** of glycosphingolipid metabolism caused by a **deficiency of  $\alpha$ -galactosidase A** and by the consequent accumulation of ceramide trihexoside.

- ID/CC** A 28-year-old white male complains of severe **retrosternal pain** radiating to his left arm and jaw.
- HPI** He has not had a physical exam in a long time. He adds that his **father died at a young age of a myocardial infarction.**
- PE** Anguished, dyspneic, diaphoretic male with hand clutched to chest (indirect sign of myocardial pain); soft, **elevated plaques on eyelids** (XANTHELASMAS); arcus senilis; painful **xanthomas of Achilles tendons** and patellae.
- Labs** Elevated CK-MB; elevated troponin T and I. ECG: MI. Extremely **high levels of LDL.**
- Imaging** Angio: coronary artery disease.
- Gross Pathology** **Premature atherosclerosis** in large arteries.
- Micro Pathology** Foam cells with lipid characteristic of atherosclerotic plaques.
- Treatment** Diet, exercise and cholesterol-lowering drugs (although HMG-CoA reductase inhibitors are ineffective in homozygous FH patients due to complete lack of LDL receptors). Consider portocaval anastomosis or liver transplantation.
- Discussion** Familial hypercholesterolemia is also called type II hyperlipoproteinemia; it is an **autosomal-dominant defect in LDL receptor** with a gene frequency of 1:500. Homozygotes may have an LDL count eight times that of normal.

**ID/CC** A 16-year-old white female complains of sudden **midepigastric pain and nausea** after eating french fries.

**HPI** Her history reveals that **she and a sibling** have had similar episodes of abdominal pain in the past. Careful questioning discloses that she experiences **flushing** every time she **drinks alcohol**.

**PE** **Nonpainful, yellowish papules on face, scalp, elbows, knees, and buttocks** (ERUPTIVE XANTHOMATOSIS); lipemia retinalis on fundoscopic exam; hepatosplenomegaly; abdominal muscle guarding and palpable tenderness.

**Labs** **Elevated serum amylase** and lipase; **very high triglycerides**; moderate elevation of serum cholesterol and phospholipids.

**Micro Pathology** Lipid-laden foam cells.

**Treatment** **Low-fat diet**; avoidance of alcohol; exercise; **fibric acid** and **niacin** in selected cases.

**Discussion** Familial hypertriglyceridemia is an autosomal-dominant disorder. Abdominal pain stems from **recurrent acute pancreatitis**.

**ID/CC** An 8-year-old boy is referred to the pediatric clinic for evaluation of **anemia and multiple developmental anomalies**.

**HPI** His parents report that he **bleeds easily**.

**PE** Pale and **mentally retarded**; small head (**MICROCEPHALIA**); low height and weight for age; hyperpigmentation of torso and thighs with café-au-lait spots; **decrease in size of penis**; decrease in size of eyes (**MICROPHTHALMIA**); **absence of both thumbs**.

**Labs** CBC: decreased WBCs (**LEUKOPENIA**), platelets (**THROMBOCYTOPENIA**), and RBCs (**ANEMIA**) (**PANCYTOPENIA**). Increased levels of HbF. Bone marrow chromosomes show diverse alterations (breaks, constrictions, and translocations).

**Imaging** XR: **bilateral absence of radii**. IVP/CT: **hypoplastic kidneys**.

**Treatment** **Marrow transplantation**, androgens, corticosteroids.

**Discussion** Fanconi's anemia is a congenital, autosomal-recessive disorder characterized by constitutional **aplastic anemia due to defective DNA repair**, presumably as a result of viral infection causing hypersensitivity to DNA cross linking agents. It is associated with multiple musculoskeletal and visceral anomalies, proximal renal tubular acidosis, and a higher incidence of leukemia.

**ID/CC** A 10-year-old **male** is referred to a genetic evaluation clinic by his pediatrician because of **mental retardation**.

**HPI** His mother did not take any drugs during her pregnancy, did not suffer from any major illnesses, was seen by an obstetrician periodically, and was monitored intrapartum.

**PE** Patient well developed physically with grade I mental retardation; no evidence of cardiovascular, genitourinary, or hepatic disease.

**Labs** Patient has been subjected to basic and endocrinologic lab profiles, all of which have yielded normal results. Karyotype: **“fragile gap” at end of the long arm on X chromosome.**

**Treatment** Supportive.

**Discussion** The **second most common cause of mental retardation** after Down’s syndrome **in males** (women are carriers), fragile X syndrome should be suspected in any male patient whose mental retardation cannot be explained by other disease processes. It is often associated with macro-orchidism, large ears and jaw, a high-pitched voice, and connective tissue abnormalities and demonstrates genetic **anticipation** (worsening of the disorder in successive generations) owing to the expansion of **trinucleotide repeats**.

- ID/CC** A 2-month-old white male is taken to his family doctor because of lethargy, **feeding difficulties**, and yellowish skin (**JAUNDICE**).
- HPI** The child has been **vomiting** on and off since birth.
- PE** Irritability; **jaundice**; **cataracts**; **hepatomegaly**; growth and development in fifth percentile; edema.
- Labs** UA: **galactosuria**; aminoaciduria; albuminuria. **Hypoglycemia**; increased ALT and AST; elevated direct and indirect bilirubin; prolonged PT; erythrocytes have **markedly reduced galactose-1-phosphate uridyl transferase activity** and elevated galactose-1-phosphate.
- Imaging** US/CT: enlarged fatty liver.
- Gross Pathology** Early hepatomegaly and fatty change with giant cells leading to cirrhosis; gliosis of cerebral cortex, basal ganglia, and dentate nucleus of cerebellum; cataracts.
- Micro Pathology** Liver, eyes, and brain most severely affected by **deposits of galactose-1-phosphate and galactitol**; kidney, heart, and spleen also involved.
- Treatment** Limit intake of milk and other galactose- and lactose-containing foods.
- Discussion** Galactosemia is an **autosomal-recessive** lack of enzyme galactose-1-phosphate uridyl transferase; the presence of **cataracts** differentiates it from other causes of jaundice in the newborn.

**ID/CC** An 11-year-old **Jewish** male presents with weakness, **epistaxis**, and a left-sided abdominal mass.

**HPI** He has a history of **bruising easily** and sustaining fractures following minimal trauma.

**PE** Mental retardation; multiple **purpuric patches**; skin pigmentation; mild hepatomegaly; **massive splenomegaly**; marked pallor; no lymphadenopathy or icterus.

**Labs** CBC: normocytic, normochromic anemia; thrombocytopenia; low normal WBC count. LFTs normal; bone marrow biopsy characteristic; isolated WBCs demonstrate reduced  $\beta$ -glucosidase activity; elevated serum acid phosphatase.

**Imaging** XR, spine: biconcave (H-shaped) vertebral bodies. XR, knee: Erlenmeyer flask deformity of distal femur; osteopenia. CT/US: enlarged spleen with multiple nodules.

**Micro Pathology** Bone marrow biopsy shows myelophthisis; replaced by Gaucher's cells 20 to 100  $\mu\text{m}$  in size; characteristic "**wrinkled paper**" **cytoplasm** due to intracytoplasmic glucocerebroside deposition; PAS stain positive.

**Treatment** Symptomatic, enzyme replacement with purified placental or recombinant acid  $\beta$ -glucosidase, splenectomy.

**Discussion** Gaucher's disease is an **autosomal-recessive deficiency of glucocerebroside** with accumulation of glucosyl-acylsphingosine in bone marrow, spleen, and liver.



- ID/CC** A 5-month-old male is brought to the doctor because of frequent nausea, **vomiting**, night sweats, tremors, and **lethargy**.
- HPI** When the patient was exclusively breast fed (i.e., during the initial four months after birth), he was well; the **onset of symptoms coincided with** the occasional **addition of fruit juices** to the baby's diet.
- PE** Lazy-looking, slightly **jaundiced** baby; mild growth retardation; **hepatomegaly**.
- Labs** **Marked hypoglycemia; fructosemia**. UA: fructosuria; urine test for reducing sugar positive; dipstick for glucose negative; fructose tolerance test not advisable (may cause severe hypoglycemia).

**Micro Pathology** Liver biopsy reveals **low aldolase B activity** (confirmatory test).

**Treatment** Return to breast feeding as sole food; avoid fruit juices, fruits, and sweets.

**Discussion** Any food containing fructose or sucrose (fructose + glucose) may cause symptoms in patients with fructose intolerance, an **autosomal-recessive deficiency of aldolase B** (enzyme used to split fructose-1-phosphate into glyceraldehyde and dihydroxyacetone phosphate), resulting in accumulation of fructose-1-phosphate within liver cells. This inhibits glycolysis, gluconeogenesis and glycogenolysis. If long-standing, it may lead to cirrhosis and kidney failure. Differential diagnosis is galactosemia.

**ID/CC** A 9-year-old male is referred to the pediatric clinic because of progressive **mental retardation**, **diminished visual acuity**, and **bone deformity** in the thorax.

**HPI** The boy was born in Malaysia and never had any prenatal screening.

**PE** Tall and thin with elongated limbs (Marfanoid appearance); fine hair; **abnormally long fingers** (ARACHNODACTYLY); **pectus excavatum**; **lenticular dislocation** (ECTOPIA LENTIS); malar flush; high-arched palate; genu valgum; cardiovascular exam normal.

**Labs** **Increased serum methionine; increased urinary homocystine.**

**Imaging** XR: generalized **osteoporosis**.

**Micro Pathology** Brain gliosis; fatty liver; arterial intimal thickening without lipid deposition; degeneration of zonular ligaments of lens.

**Treatment** High-dose pyridoxine (cofactor for cystathionine synthetase; effective only in some forms of disease); methionine-restricted diet; cysteine and folate supplements.

**Discussion** Homocystinuria is an autosomal-recessive **disturbance of methionine metabolism** caused by a **deficiency of cystathionine synthetase** in liver cells with accumulation of homocystine. Major arterial and venous **thromboses** are a constant threat because of vessel wall changes and increased platelet adhesiveness due to the toxicity of homocystine to the vascular endothelium.

- ID/CC** An 11-year-old **male** is sent to the audiometry clinic by his pediatrician for an evaluation of **deafness**.
- HPI** His teachers note that he has not been paying attention at school and add that his academic performance has suffered as a result.
- PE** **Coarse facies and large tongue**; short stature; **corneas clear** (vs. Hurler's disease); dimpled skin in back of arms and thighs; no gibbus (acute-angle kyphosis) present (vs. Hurler's disease); nonpainful nodular lesions on left scapular area; stiffening of joints; **deafness**.
- Labs** UA: **increased urinary heparan sulfate and dermatan sulfate**.
- Imaging** Metacarpal thickening with tapering at ends.
- Micro Pathology** Metachromatic granules (**REILLY BODIES**) in bone marrow leukocytes; amniotic fluid culture during pregnancy may detect abnormality.
- Treatment** Supportive.
- Discussion** Hunter's disease, or type II mucopolysaccharidosis, is an **X-linked recessive** disease and is less severe than Hurler's syndrome (type I). Hunter's disease can be differentiated from Hurler's syndrome in that it features no corneal opacities and either no mental retardation or less severe retardation than that found in Hurler's; however, deafness is present. Caused by a **deficiency of iduronosulfate sulfatase**.

**ID/CC** A 2-year-old white male is brought to the ophthalmologist for an evaluation of **eye clouding**.

**HPI** The child has a physical and **mental disability** very similar to that of his older **brother**.

**PE** **Short stature**; very **coarse, elongated facial features** (GARGOYLISM); **bilateral corneal opacities**; retinal degeneration and papilledema; saddle nose deformity; systolic murmur in second right intercostal space; **enlarged heart, liver, and spleen**; **kyphoscoliosis** with lumbar gibbus (acute angle kyphosis); stiff, immobile, and contracted large joints.

**Labs** Dermatan sulfate and heparan sulfate in urine;  **$\alpha$ -L-iduronidase deficiency in WBCs**.

**Imaging** XR: dolichocephaly; increased diameter of sella turcica; deformation of vertebral bodies with scoliosis and kyphosis.

**Gross Pathology** Increased mucopolysaccharide (MPS) deposition in heart, eye, connective tissue, CNS, cartilage, heart, and bone.

**Micro Pathology** Enlarged heart; thickened endocardium; MPS infiltration in intima of coronary arteries; meningeal and neuronal deposits producing hydrocephalus; metachromatic granules in lymphocytes and histiocytes.

**Treatment** Supportive ophthalmologic, skeletal, and cardiovascular treatment. Consider bone marrow transplant.

**Discussion** Also known as gargoylism, Hurler's syndrome is the most common mucopolysaccharidosis (TYPE I). It is **autosomal recessive** and is caused by a **deficiency of  $\alpha$ -iduronidase**. Death usually occurs by 6 to 10 years of age, usually secondary to cardiovascular complications.

**Atlas Link** [UCM2](#) Z-BC-058

**ID/CC** A 25-year-old male visits a fertility clinic as part of an **evaluation of infertility** that he is undergoing with his wife.

**HPI** His medical history discloses frequent **sinus infections** (SINUSITIS) and chronic cough with sputum formation (BRONCHIECTASIS).

**PE** VS: normal. PE: apical impulse felt on fifth **right intercostal space**; all auscultatory foci reversed (DEXTROCARDIA); liver on left side and spleen on right (SITUS INVERSUS).

**Labs** CBC/Lytes: normal. Semen analysis shows **immotile spermatozoa**.

**Imaging** CXR: dextrocardia. KUB: situs inversus.

**Discussion** Kartagener's syndrome (also called immotile cilia syndrome) is an **autosomal-recessive** disorder characterized by **lack of dynein** (ATPASE) arms from the microtubules of axonemes in the cilia of the sinuses and bronchi, rendering them immotile. Sperm are also immotile (due to flagellar lack of dynein). The lack of mucus-clearing action causes frequent infections.

**ID/CC** A 19-year-old male visits his family physician because he is **embarrassed at having large breasts**.

**HPI** He also complains of frequent headaches and **impotence**.

**PE** **Tall, eunuchoid** body habitus; mild mental retardation; testes small and firm; breast enlargement (**GYNECOMASTIA**); female distribution of hair.

**Labs** UA: increased urinary FSH; decreased 17-ketosteroid.

**Imaging** XR: delayed physeal closure; short fourth metacarpal.

**Gross Pathology** Testicular atrophy.

**Micro Pathology** **Testicular fibrosis and hyalinization; lack of spermatogenesis**; Leydig's interstitial cells scarce and have foamy cytoplasmic change; **female sex chromatin bodies (BARR BODIES)** in cells.

**Treatment** Testosterone.

**Discussion** Also known as **testicular dysgenesis**, Klinefelter's syndrome is the most common cause of male hypogonadism. Alteration is due to the presence of three sex chromosomes (karyotype 47,XXY).

- ID/CC** A **5-month-old** child is brought to the pediatrician because of **growth retardation** and **difficulty feeding**.
- HPI** His parents note that the child has been **irritable** and “stiff” (**SPASTICITY**).
- PE** VS: normal. PE: patient **underdeveloped** for age; **reflexes hyperactive**; paravertebral muscles and hamstrings tense (**RIGIDITY**); maternal milk **sucking reflex weak** and punctuated by periods of regurgitation.
- Labs** Basic lab work within normal limits. LP: increased protein in CSE.
- Gross Pathology** Axonal and white-matter cerebral, cerebellar, and basal ganglia **demyelination**.
- Micro Pathology** Basophilic perivascular multinucleated globoid cells (**MACROPHAGES**) with cytoplasmic inclusion bodies consisting of cerebroside.
- Treatment** Poor prognosis, with death usually occurring rapidly.
- Discussion** Also called **globoid leukodystrophy**, Krabbe’s disease is an **autosomal-recessive**, familial genetic disorder characterized by a **deficiency of galactosylceramide  $\beta$ -galactosidase**.

**ID/CC** A 2-year-old **male** is brought to the pediatrician by his mother because of repeated, **self-mutilating biting of his fingers and lips**; the patient's mother has also noticed abundant, **orange-colored "sand"** (uric acid crystals) **in the child's diapers**.

**HPI** The mother reports that some months ago the child's urine was red, but she took no action at the time.

**PE** Poor head control, difficulty walking, and difficulty maintaining an erect, seated position; **choreoathetoid movements**, spasticity, and **hyperreflexia** on neurologic exam.

**Labs** **Hyperuricemia** (>10 mg/dL). UA: crystalluria; microscopic hematuria (due to renal calculi).

**Imaging** XR: irregular amputation of several fingers.

**Treatment** Allopurinol. Removal of primary teeth.

**Discussion** Lesch–Nyhan syndrome is an **X-linked recessive** metabolic disease resulting from a deficiency of an enzyme of purine metabolism, **HGPRT**. If left untreated, patients develop full-blown **gouty arthritis** and urate nephropathy as well as subcutaneous tophaceous deposits. Compulsive, uncontrollable destructive behavior is typical of the disorder. Prenatal diagnosis is possible.



- ID/CC** A **5-day-old** male presents with **seizures**, difficulty feeding, and vomiting; his mother reports a **peculiar, maple-sugar-like odor on his diapers**.
- HPI** His mother had an unremarkable full-term vaginal delivery.
- PE** VS: no fever. PE: full-term neonate with irregular respirations, **muscular rigidity** (SPASTICITY), and obtunded sensorium; fundus normal; peculiar odor in urine and sweat; when child's head support (hand) is suddenly withdrawn in supine position, patient fails to react with normal extension-abduction followed by flexion and adduction of arms (ABSENCE OF MORO REFLEX).
- Labs** **Hypoglycemia**. ABGs: metabolic acidosis. **Marked elevation in blood and urine levels of the branched chain amino acids** leucine, isoleucine, alloisoleucine, and valine as well as decreased levels of alanine, threonine, and serine.
- Gross Pathology** Edema of brain with gliosis and white matter **demyelination**.
- Treatment** **Restricting intake of branched-chain amino acids from diet**; dialysis; thiamine supplementation.
- Discussion** Maple syrup urine disease is an **autosomal-recessive** branched-chain  $\alpha$ -ketoaciduria that results from defective oxidative decarboxylation of the branched-chain  $\alpha$ -ketoacids. This decarboxylation is usually accomplished by a complex enzyme system ( **$\alpha$ -ketodehydrogenase**) using thiamine as a coenzyme. A **deficiency** of this enzyme system causes urine to have the characteristic maple syrup odor and causes CNS symptoms in the first few weeks of life.

<b>ID/CC</b>	A 3-year-old white male is brought to the pediatrician because of <b>increasing difficulty walking</b> due to <b>spasticity</b> .
<b>HPI</b>	The child had been developing normally up to now, and his medical history is unremarkable.
<b>PE</b>	<b>Difficulty climbing stairs; ataxia; wide-based gait;</b> extensor plantar response and hyperreflexia.
<b>Labs</b>	LP: increased protein in CSF (vs. cerebral palsy). Decreased peripheral nerve conduction velocity.
<b>Imaging</b>	MR, brain: demyelination.
<b>Gross Pathology</b>	Generalized <b>demyelination</b> (due to deficiency of arylsulfatase A interfering with normal metabolism of myelin lipids) with gliosis.
<b>Micro Pathology</b>	Toluidine blue staining shows brownish ( <b>METACHROMATIC</b> ) granules in oligodendrocytes and neurons of globus pallidus, thalamus, and dentate nucleus.
<b>Treatment</b>	Poor prognosis; patients become invalids within a few years and die before puberty.
<b>Discussion</b>	Metachromatic leukodystrophy is an <b>autosomal-recessive</b> disorder of sphingolipid metabolism that is due to a <b>deficiency in the enzyme arylsulfatase A</b> with accumulation of sulfatides in the central and peripheral nervous system as well as in the kidneys. Intrauterine diagnosis is possible.

- ID/CC** An 11-month-old **Jewish** male of **Ashkenazi** descent presents with globally delayed development and **diminished visual acuity**.
- HPI** His parents feel that the baby is not acquiring new skills and that existing ones are regressing. They also feel that their child cannot see or hear properly.
- PE** **Lymphadenopathy; hepatosplenomegaly; cherry-red spot on macula** on funduscopy; malnourished infant with protuberant abdomen; global developmental delay; hypoacusis.
- Labs** CBC: mild normochromic, normocytic anemia.
- Micro Pathology** Bone marrow biopsy reveals sphingomyelinase deficiency in cultured skin fibroblasts; characteristic “foam cells” containing sphingomyelin and cholesterol.
- Treatment** No treatment available. Carries a poor prognosis, with death occurring within a few years of birth.
- Discussion** Niemann–Pick disease is an **autosomal-recessive deficiency of sphingomyelinase with accumulation of sphingomyelin in the lysosomes** of histiocytes in the brain, bone marrow, spleen, and liver.

**ID/CC** A 2-year-old female is referred to a pediatric clinic for evaluation of **lethargy, weakness, and persistent anemia** that has been unresponsive to treatment with iron, folic acid, and vitamins C and B<sub>12</sub>.

**HPI** She is the third-born child of a healthy white couple; her mother had an uneventful pregnancy and a eutopic delivery. Both brothers are healthy.

**PE** **Low weight and height** for age; **marked pallor**; flaccidity and lethargy; **sleepiness**. No focal neurologic signs; lungs clear; heart sound with slight aortic systolic ejection murmur (due to anemia); abdomen soft; no masses; no hepatomegaly; spleen barely palpable; no lymphadenopathy.

**Labs** CBC: **megaloblastic anemia**; elevated mean corpuscular volume. UA: increased orotic acid excretion with formation of **orotic acid crystals**.

**Treatment** Administration of **uridine** and cytidine. Steroids.

**Discussion** Orotic aciduria is an **autosomal-recessive disorder of pyrimidine synthesis**; it is caused by a deficiency of the enzyme system orotidylic pyrophosphorylase-orotidylic decarboxylase with resultant megaloblastic anemia due to impaired synthesis of nucleic acids necessary for hematopoiesis.

- ID/CC** A 3-year-old male presents with progressive **mental retardation**, **vomiting**, and **hyperactivity** with purposeless movements.
- HPI** The child developed normally for the first 2 to 3 months. He is fairer than his siblings and, unlike them, has blue eyes. He was born outside the United States and did not undergo any screening for congenital disorders.
- PE** Child is **blond with blue eyes**, **perspires** heavily, is mentally retarded, and has **peculiar “mousy” odor**; **hypertonia** with hyperactive deep tendon reflexes on neurologic exam.
- Labs** Guthrie test (bacterial inhibition assay method) positive (due to **increased blood phenylalanine levels**); increased urinary phenylpyruvic and ortho-hydroxyphenylacetic acid; **normal concentration of tetrahydrobiopterin**.
- Imaging** XR: delayed bone age.
- Treatment** Diet formulas low in phenylalanine. Avoid aspartame. **Tyrosine supplementation**.
- Discussion** PKU is an **autosomal-recessive disorder** caused by a **deficiency of the enzyme phenylalanine hydroxylase**. A neonatal screening program for the detection of PKU is in effect throughout the United States.

**ID/CC** A 7-year-old female presents with anxiety, **dizziness**, **sweating**, and nausea **following** brief episodes of **exercise**.

**HPI** These symptoms are **relieved by eating** and do not occur if the patient is frequently fed small meals.

**PE** Physical exam unremarkable.

**Labs** **Hypoglycemia** following brief fasting; alanine fails to increase blood sugar; fructose or glycerol administration restores blood glucose to normal.

**Micro Pathology** Liver biopsy for enzyme assays reveals deficiency of phosphoenolpyruvate carboxykinase, an enzyme of gluconeogenesis; **no excess glycogen storage** revealed.

**Treatment** Frequent small meals to prevent episodes of hypoglycemia.

**Discussion** Phosphoenolpyruvate carboxykinase (PEPCK) deficiency prevents pyruvate from being converted to phosphoenolpyruvate. This deficiency interferes with gluconeogenesis from 3-carbon precursors (e.g., alanine) that enter the gluconeogenic pathway at or below the pyruvate level.

- ID/CC** A **2-month-old** child is brought to the pediatrician because of **failure to gain weight**, increasing **weakness**, insufficient strength to breast feed, and **lethargy**.
- HPI** He is the second-born son of a healthy white couple; his mother's pregnancy and delivery were uneventful.
- PE** Mild cyanosis; shallow respirations; increase in size of tongue (**MACROGLOSSIA**); moderate hepatomegaly; **significant generalized muscular flaccidity**.
- Labs** CBC: normal. Lytes: normal. **Glucose**, BUN, creatinine **normal**. ECG: **short P-R; wide QRS; left-axis deviation**.
- Imaging** CXR: **extreme cardiomegaly** and congestive heart failure.
- Gross Pathology** Significant increase in size and weight of heart (up to five times normal); to lesser extent, hepatomegaly.
- Micro Pathology** Extensive intracytoplasmic and lysosomal deposition of glycogen on myocardial fibers as well as in striated muscle fibers, kidney, and liver.
- Treatment** Poor prognosis; associated with early death from **cardiopulmonary failure**.
- Discussion** Pompe's disease is a **type II glycogen storage disease** (generalized). This fatal disorder is caused by an **autosomal-recessive deficiency in the lysosomal enzyme** (only glycogenolysis with lysosomal involvement)  **$\alpha$ -1,4-glucosidase** (**ACID MALTASE**), with resulting accumulation of structurally normal glycogen in the heart, muscle, kidney, and liver.

- ID/CC** A 40-year-old **male** visits his family doctor because of a **chronic, recurrent rash** on his hands, face, and other **sun-exposed areas**; the patient's **urine turns dark brown-black if left standing**, and he has noticed that recurrences coincide with **alcohol intake**.
- HPI** He reports having used **hexachlorobenzene as a pesticide** for some years (a fungicide shown to be associated with porphyria cutanea tarda).
- PE** Skin erythema with **vesicles and bullae on sun-exposed areas**; skin at these sites is friable and shows presence of whitish plaques ("MILIA") (due to photosensitizing effect of uroporphyrin); skin of face also shows hypertrichosis and hyperpigmentation.
- Labs** Watson–Schwartz test negative. UA: **markedly elevated urinary uroporphyrin levels; slightly elevated urinary coproporphyrin levels**. Fecal isocoproporphyrin normal; **elevated transferrin, serum and hepatic iron**; elevated serum transaminases.
- Gross Pathology** Liver shows siderosis, bullae, fibrosis, and inflammatory changes.
- Micro Pathology** Skin biopsy demonstrates iron deposits, intense porphyrin fluorescence, and long, thin cytoplasmic inclusions.
- Treatment** Repeated phlebotomies; avoidance of sunlight, alcohol, iron, and estrogens. Low dose antimalarials.
- Discussion** Porphyria cutanea tarda (PCT), in contrast to other hepatic porphyrias, is more common among men than women. PCT is caused by partial loss of activity of **hepatic uroporphyrinogen decarboxylase**; lesions are caused by overproduction and excretion of uroporphyrin.



- ID/CC** A 5-year-old girl is referred to a hematologist for an evaluation of chronic **anemia that has been unresponsive to nutritional supplementation**.
- HPI** Both parents are clinically normal and are **first cousins** who are **Amish**. The patient has no history of passage of dark-colored urine or recurrent infections.
- PE** Low weight and height for age; pallor; mild **jaundice**; spleen barely palpable; liver not enlarged.
- Labs** CBC/PBS: **anemia; markedly increased reticulocyte count**; peripheral blood reveals macro-ovalocytosis with a few echinocytes; no sickle cells or spherocytes seen. Hyperbilirubinemia (primarily unconjugated), UA: urinary hemosiderin present. Reduced serum haptoglobin; **diminished activity of pyruvate kinase** in RBCs on spectrophotometry.
- Treatment** · **Exchange transfusions**. Splenectomy.
- Discussion** Pyruvate kinase deficiency is inherited as an **autosomal-recessive** trait and usually produces mild symptoms (hemolytic anemia); **2,3-diphosphoglycerate accumulates**, shifting the hemoglobin-oxygen dissociation curve to the right (due to reduced affinity of RBCs for oxygen).

**ID/CC** A **6-month-old** male is brought to a pediatrician for evaluation of **listlessness**, lethargy, and **fixed gaze**.

**HPI** His parents are **Ashkenazi Jews**.

**PE** **Excessive extensor startle response to noise** (HYPERACUSIS); child is sleepy and hypotonic with poor head control and a fixed gaze; appears to have translucent skin; **cherry-red macular spot** found on fundoscopic exam.

**Gross Pathology** Diffuse gliosis; cerebral and macular degeneration; up to 50% increase in brain weight (due to deposition of sphingolipid).

**Micro Pathology** Neuronal swelling with cytoplasmic **deposits of gangliosides** (ZEBRA BODIES).

**Treatment** Poor prognosis; patients usually die of pneumonia before reaching the age of 3.

**Discussion** Tay-Sachs disease is an autosomal-recessive disorder of sphingolipid metabolism characterized by the **absence of the enzyme hexosaminidase A**, producing excessive storage of ganglioside GM-2 in lysosomes **restricted to the cells of the central nervous system**. **Ganglioside GM-2** is a glycosphingolipid with sphingosine, a long-chain basic molecule, as its backbone along with an attached sugar and a terminal N-acetylglucosamine. Prenatal diagnosis can be made at the 14th week of pregnancy.

- ID/CC** A 7-year-old male is brought to a pediatrician for evaluation of episodes of **fatigue**, restlessness, anxiety, nausea, **lightheadedness**, vomiting, and **sweating**.
- HPI** The symptoms appear when he does not eat frequent meals and subside while he is eating. He also has a history of **bruising easily**.
- PE** Patient has “**doll-face**” **facies**; weight low for age; tendon xanthomas; purpuric patches over skin; **marked hepatomegaly**.
- Labs** Lactic acidosis; hyperlipidemia; **marked increase in serum uric acid** (patient may exhibit gout symptoms); **marked hypoglycemia**; prolonged bleeding time; **lack of rise in serum glucose following SC epinephrine** or IV glucagon but striking increase in lactate; normal urinary catecholamines.
- Imaging** US: hepatomegaly; kidneys also enlarged bilaterally.
- Gross Pathology** **Liver and kidneys enlarged** (vs. type III glycogen storage disease, or Cori’s disease, in which there is no renal involvement).
- Micro Pathology** Hepatocytes containing variable-sized **glycogen-lipid droplets** on liver biopsy; nuclear glycogenosis seen; large glycogen deposits in kidney; skeletal and cardiac muscle not involved (vs. type V glycogen storage disease, or McArdle’s disease, in which skeletal muscle is involved).
- Treatment** Frequent meals to prevent hypoglycemia.
- Discussion** Von Gierke’s disease is an autosomal-recessive glycogen storage disease (type I) resulting from a **deficiency of glucose-6-phosphatase** and accumulation of structurally normal glycogen in the liver and kidneys.

**ID/CC** A 10-year-old girl is brought by her parents to a dermatologist because of a recent **change in color and increase in size of a warty lesion** on her face.

**HPI** She has been suffering from **excessive sensitivity to sunlight** and thus does her best to avoid the sun as much as possible.

**PE** Abundant **freckles** on all sun-exposed areas; **telangiectases**; areas of redness (**ERYTHEMA**) and hypopigmentation; **hyperkeratosis** on face and dorsum of hands; hard, nodular lesion on right cheek; no regional lymphadenopathy.

**Labs** Basic lab work normal.

**Gross Pathology** Generalized hyperpigmentation with desquamative spots on sun-exposed areas.

**Micro Pathology** Biopsy of cheek lesion reveals hyperkeratosis with melanin deposition; **squamous cell carcinoma**.

**Treatment** Avoidance of sunlight, protection against sunlight. Surgical removal of cancer.

**Discussion** Xeroderma pigmentosum is an **autosomal-recessive** disorder that is usually manifested in childhood. It is characterized by excessive sensitivity to ultraviolet light due to **impaired endonuclease excision repair mechanism of ultraviolet light-damaged DNA** UV light causes (cross linking of pyrimidine residues) in dermal fibroblasts. There is a marked tendency to develop **skin cancer** (squamous cell and basal cell carcinoma).

- ID/CC** A 40-year-old woman presents with **weakness, easy fatigability, nausea, and diarrhea**.
- HPI** She has had a long and severe course of rheumatoid arthritis for which she has been taking **methotrexate** (a folic acid antagonist).
- PE** VS: normal. PE: **pallor**; mild tongue inflammation (GLOSSITIS); fundoscopic exam normal; chest sounds within normal limits; abdomen shows no hepatosplenomegaly; no lymphadenopathy; **no neurologic signs** (vs. vitamin B<sub>12</sub> deficiency megaloblastic anemia).
- Labs** CBC: **hypersegmented PMNs** (> 5 to 7 lobes); **megaloblastic RBCs** (mean corpuscular volume >100); **vitamin B<sub>12</sub> level normal; folate level in RBCs low** (vs. vitamin B<sub>12</sub> deficiency megaloblastic anemia).
- Treatment** Folic acid supplementation.
- Discussion** Folic acid is found mainly in green leaves and is important for the **synthesis of DNA and RNA**. It also acts as a coenzyme for 1-carbon transfer and is involved in **methylation reactions**. Deficiency is associated with alcoholism, pregnancy (MEGALOBlastic ANEMIA OF PREGNANCY), dietary deficiencies, and drugs such as TMP-SMX, methotrexate, phenytoin, and proguanil.

- ID/CC** A 1-year-old infant presents at a clinic with **lassitude, poor muscle tone**, and delayed motor development.
- HPI** The mother is a known IV drug user and has two older children who are in the custody of the state social services agency.
- PE** VS: tachycardia; tachypnea. PE: **pallor**; partial alopecia; ulceration of skin at corners of mouth (**CHEILOSI**S); smooth tongue; **nails break easily and are spoon shaped** (**KOILONYCHIA**).
- Labs** PBS: abnormally **small and pale RBCs** (**MICROCYTIC, HYPOCHROMIC ANEMIA**); RBCs of different sizes (**ANISOCYTOSIS**) and different shapes (**POIKILOCYTOSIS**). **Decreased serum iron**; increased total iron-binding capacity and reduced percentage saturation; artificial **increased transferrin** (due to attempt to transport as much iron as possible); **low serum ferritin** (due to insufficient iron stored as ferritin).

**Gross Pathology** Atrophic glossitis.

**Micro Pathology** Erythroid hyperplasia with **decreased bone marrow iron stores on Prussian blue staining** (vs. anemia of chronic disease, which is characterized by increased iron stores).

**Treatment** Control cause of iron deficiency; supplemental iron.

**Discussion** Iron-deficiency anemia is the most common cause of **chronic blood loss**, usually gastrointestinal or gynecologic; it is secondary to a deficiency of iron required for normal hemoglobin synthesis. Differentiate from anemia of chronic disease, in which ferritin is high and transferrin is low.

**ID/CC** A 58-year-old black female complains of **weakness, dizziness, anorexia, nausea, and occasional vomiting** over the past 3 months.

**HPI** She has also experienced **shortness of breath** (due to diminished oxygen-carrying capacity) as well as **numbness and tingling** in the extremities (due to megaloblastic peripheral neuritis).

**PE** Slightly icteric eyes; hepatosplenomegaly; smooth, beefy-red tongue (GLOSSITIS); **loss of balance, vibratory, and position sense** in both lower extremities (due to posterior and lateral column involvement; vs. folic acid deficiency).

**Labs** CBC: **macrocytic, hypochromic anemia** (MCV > 100); **leukopenia** (4,000) with **hypersegmented neutrophils**; thrombocytopenia. Hyperbilirubinemia (2.5 mg/dL; normal 0.1 to 1.0 mg/dL); **achlorhydria** (no hydrochloric acid in gastric juice); positive Schilling test; **low blood vitamin B<sub>12</sub> levels**; RBC folate normal.

**Gross Pathology** Dorsal and lateral spinal columns are small, with axonal degeneration; flat, atrophic mucosa; loss of rugal folds in stomach; increased red marrow in bone.

**Micro Pathology** **Megaloblastic and hypercellular bone marrow** with erythroid hyperplasia; accumulation of hemosiderin in Kupffer cells; chronic atrophic gastritis.

**Treatment** Parenteral vitamin B<sub>12</sub>.

**Discussion** Pernicious anemia is megaloblastic anemia caused by malabsorption of vitamin B<sub>12</sub> because of **lack of intrinsic factor** in gastric juice (intrinsic factor, secreted by parietal cells, is indispensable for vitamin B<sub>12</sub> absorption). **Antibodies against gastric parietal cells** are almost invariably present in the adult form of the disease.

**Atlas Links** [UCM1 H-BC-077](#) [UCM2 IM1-043](#)

**ID/CC** A 31-year-old **black male** who works as a Peace Corps volunteer in Ghana visits his medical officer complaining of extreme **weakness and fatigue**; he also complains of a **yellowing of his skin** and **slight fever**.

**HPI** He was prescribed **primaquine** for radical treatment of malaria (due to *Plasmodium vivax*).

**PE** VS: tachycardia (HR 95). PE: mild jaundice; circumoral and nail bed **pallor**; no hepatosplenomegaly; remainder of PE normal.

**Labs** **Elevated indirect bilirubin**. CBC/PBS: **low hemoglobin and hematocrit** (9.3/33) with reticulocytosis (HEMOLYSIS); **spherocytes** in peripheral blood smear; **Heinz bodies** (precipitated hemoglobin) in RBCs; **low blood levels of G6PD** (diagnostic). UA: hemoglobinuria.

**Treatment** Withdrawal of offending drug.

**Discussion** Glucose-6-phosphate dehydrogenase (G6PD) deficiency is an **X-linked recessive** disorder seen in about 15% of American black males. With infections or exposure to certain drugs (e.g., sulfa drugs, antimalarials, nitrofurantoin), patients deficient in G6PD present with a **hemolytic anemia due to increased RBC sensitivity to oxidant damage**. G6PD is the rate-limiting enzyme in the HMP shunt that provides NADPH.



- ID/CC** A 7-year-old male is brought to the emergency room because of weakness and the **spontaneous appearance** of painful swelling of both knee joints (due to hemarthrosis) as well as black, tarry stools (GI bleeding).
- HPI** The child has a **history of prolonged bleeding following minor injuries**. His maternal uncle died of a "bleeding disorder."
- PE** Pallor; swollen, erythematous, tender knee joints with blood accumulation in synovial capsule (**HEMARTHROSIS**); numerous **bruises** seen at areas of minimal repeated trauma.
- Labs** Bleeding time and PT normal; **prolonged PTT**; reduced levels of factor VIII on immunoassay; synovial fluid hemorrhagic.
- Imaging** XR: bilateral knee effusions.
- Micro Pathology** Synovium may show hyperplasia with hemosiderin in synovial macrophages.
- Treatment** Nonpharmacologic therapy involves patient education, **avoidance of contact sports, avoidance of aspirin** and other NSAIDs (due to antiplatelet aggregating effect), **orthopedic evaluation** and physical therapy, and **hepatitis vaccination**. **Factor VIII supplementation** is effective in controlling spontaneous and traumatic hemorrhage. **Desmopressin** may be used prophylactically in patients with mild hemophilia, prior to minor surgical procedures. **Aminocaproic acid** may be used to stop bleeding that is unresponsive to factor VIII or desmopressin.
- Discussion** Hemophilia A is an **X-linked recessive disorder** that is manifested by bleeding and is due to a **deficiency in coagulation factor VIII**.
- Atlas Link** [UCVM2](#) PED-018

**ID/CC** A 9-month-old infant is brought to the pediatrician because of **jaundice**, lethargy, and **easy fatigability**.

**HPI** The parents of the child are immigrants of **northern European origin**.

**PE** Pallor; mild jaundice; palpable **splenomegaly**.

**Labs** CBC/PBS: microcytic **anemia**; small, **rounded**, dark RBCs lacking central pallor; negative Coombs' test. **Elevated indirect bilirubin; increased reticulocytes; increased mean corpuscular hemoglobin count (> 35); decreased MCV; abnormal RBC osmotic lysis test.**

**Treatment** **Folic acid. Splenectomy.**

**Discussion** Hereditary spherocytosis is a congenital, **autosomal-dominant** disorder characterized by **hemolytic anemia with spherical RBCs** and splenomegaly. It is caused by a **defect in RBC membrane spectrin** with loss of the normal biconcavity and a higher rate of splenic sequestration and hemolysis. If left untreated, it may give rise to pigment **gallstones** and **cholecystitis**.

- ID/CC** A newborn male in the normal nursery is noted to be **cyanotic**; the pediatrician is called even though the child does not seem to be in respiratory distress.
- HPI** That morning he had undergone circumcision (a **benzocaine** ointment was used).
- PE** **Cyanotic**; lungs clear and well ventilated; heart sounds rhythmic; no murmurs heard; no cardiopulmonary problems evident.
- Labs** CBC/Lytes: normal. Platelets, LFTs, BUN, and creatinine normal. ABGs: **PO<sub>2</sub> normal. Methemoglobin level 18% total hemoglobin.**
- Imaging** CXR: normal
- Treatment** Oxygen for acute symptoms. **Methylene blue** (increases activity of methemoglobin reductase).
- Discussion** Methemoglobin is an oxidized (FERRIC) form of hemoglobin that cannot function properly as a carrier of oxygen. The diminished oxygen-carrying capacity that results produces headache, lightheadedness, and dyspnea. Drugs such as dapsone and benzocaine as well as dyes such as anilines oxidize hemoglobin to its ferric form, as do **deficiencies of NADH methemoglobin reductase**. In neonates there is a transient deficiency of this enzyme, and HbF is more susceptible than HbA to oxidation.

**ID/CC** A 19-year-old **male** comes to see the nurse at the college health department complaining of **abdominal and lumbar pain**, which characteristically occurs **when he takes his multivitamin pills** two times a week (iron, infections, and vaccination are precipitating factors); he has also noticed **dark brown urine the morning** after he has the pain (due to hemolysis).

**HPI** He has just left his parents to go to college and is excited about his newfound freedom; he likes to drink excessive amounts of beer.

**PE** Marked **pallor**; lung fields clear to auscultation; heart sounds normal; abdomen soft and nontender with no masses or peritoneal signs; no focal neurologic signs.

**Labs** CBC: normocytic, normochromic **hemolytic anemia** with reticulocytosis. **Hemoglobinemia and hemoglobinuria; sucrose hemolysis test positive; acidified serum test positive (HAM'S TEST); decreased haptoglobin; elevated LDH; decreased leukocyte alkaline phosphatase.**

**Gross Pathology** Hemosiderosis of liver, spleen, and kidney.

**Treatment** Steroids, transfusion of saline-washed RBCs during crises. Oral iron supplementation may be useful but should be used cautiously, as it may precipitate transient hemolysis. Similarly, heparin may accelerate hemolysis, but its use in thrombotic complications appears warranted.

**Discussion** Paroxysmal nocturnal hemoglobinuria is an **acquired** defect of the red blood cell membrane, making erythrocytes unusually sensitive to serum complement (there is also increased binding of C3b). It is characterized by episodes of hemolysis with hemoglobinuria that occur during sleep because of carbon dioxide retention (which lowers the pH, thus enhancing complement activity; first voided urine in the morning is red-brown). Patients are also predisposed to developing venous thromboses.

- ID/CC** A 33-year-old woman presents to a clinic with **marked weakness** (due to hypokalemia).
- HPI** Two years ago, she underwent a ureterolithotomy for **renoureteral stones**.
- PE** VS: tachypnea. PE: **generalized muscle weakness**; heart sounds with a few skipped beats (hypokalemia gives rise to severe arrhythmias); diminished intestinal peristalsis; no peritoneal signs.
- Labs** Lytes: increased urinary potassium excretion (due to insufficient hydrogen ion available, with potassium exchanged for sodium), resulting in **marked hypokalemia** (2.3 mEq/L). ABGs: decreased  $\text{HCO}_3^-$  (due to failure to maintain normal gradient of hydrogen ions in distal renal tubules, with  $\text{HCO}_3^-$  loss); **hyperchloremic metabolic acidosis** (normal anion gap). Normal serum calcium; high alkaline phosphatase. UA: urine alkaline; hypercalciuria.
- Imaging** KUB: radiopaque left kidney stones; medullary renal calcification.
- Gross Pathology** Nephrocalcinosis.
- Treatment** Bicarbonate; potassium and vitamin D.
- Discussion** Metabolic acidosis is caused by renal tubular defects in transport. Type I (distal) involves selective deficiency of tubular  $\text{H}^+$  secretion (produces typical hyperchloremic-hypokalemic acidosis with normal anion gap). Type II (proximal) involves the inability to reabsorb  $\text{HCO}_3^-$  (also hypokalemic). Type III entails the inability to produce  $\text{NH}_3$  due to persistently low GFR volumes (normokalemic). Type IV is due to primary or drug-induced hypoaldosteronism (hyperkalemic).

**ID/CC** A 38-year-old electrician is rushed to the emergency room after receiving an accidental high-voltage **electric shock** while fixing a power line.

**HPI** On admission, a Foley catheter is inserted, yielding **reddish-brown urine** (due to myoglobin).

**PE** VS: tachycardia; BP normal. PE: confusion; disorientation; patient complains of **muscle pain** in right arm, leg, and buttock; hand severely swollen and has an oblique-shaped **burn**; "outlet wound" located in right gluteal region and ankle.

**Labs** **Markedly increased serum BUN and creatinine** (due to acute tubular necrosis); urea normal. Lytes: **hyperkalemia**. Hyperphosphatemia; hyperuricemia; hypocalcemia (due to calcium binding to necrotic muscle); **increased serum CK** (due to muscle destruction); **myoglobinuria**.

**Treatment** Urine alkalization (with IV bicarbonate); vigorous **rehydration** (to prevent pigment deposition and acute tubular necrosis); mannitol; prevent further muscle damage from compartment syndromes (evaluate need for fasciotomy). Correct electrolyte abnormalities. Hemodialysis may be required in severe cases.

**Discussion** Myoglobinuria and reduced renal perfusion from volume depletion may cause acute tubular damage. Other causes of rhabdomyolysis (**destruction of striated muscle**) include crush injuries, heroin overdose, prolonged unconsciousness in one position, arterial occlusion, alcohol abuse, and seizures.

**ID/CC** A 4-year-old **male** is brought to the pediatric clinic because of **easy fatigability and difficulty walking** of a few months' duration.

**HPI** The child's mother has noticed that his calves have increased in size (**pseudohypertrophy**).

**PE** Child well developed but shows **proximal muscle weakness** in shoulder and pelvic girdle; difficulty standing and walking; "climbs up on himself" to rise from sitting to standing (**GOWERS' SIGN**).

**Labs** **CK, LDH, and glucose phosphoisomerase elevated; absent dystrophin** expression on immunostain of **muscle biopsy**.

**Gross Pathology** Replacement of normal muscle protein with fibrofatty tissue, giving rise to pseudohypertrophy.

**Micro Pathology** Degeneration and atrophy of muscle fibers with ringed fibers surrounding normal tissue.

**Treatment** Prognosis is poor, with disability occurring within a few years and death by the early 20s. Treatment is supportive. Refer for genetic counseling.

**Discussion** Duchenne's muscular dystrophy is an **X-linked recessive** disorder characterized by a deficiency in muscle **dystrophin**, a subsarcolemmal cytoskeletal protein that stabilizes the sarcolemma during contraction and relaxation. Its course is relentlessly progressive, ending in death from cardiac and respiratory muscle involvement.

**Atlas Links** [UCV1](#) PG-BC-085, PM-BC-085 [UCV2](#) PED-049

**ID/CC** A 40-year-old male is brought to the ER from a **bar** because of **confusion** after falling from a bar stool.

**HPI** The patient's friends say that his diet consists mainly of **alcoholic drinks**. They also state that he has told **detailed and believable stories about his past adventures** that have **subsequently been found to be untrue** (CONFABULATION). His **short- and long-term memory is severely impaired**.

**PE** **Ataxia; oculomotor abnormalities**, including **nystagmus** and **ophthalmoplegia**.

**Labs** CBC: macrocytic anemia (most likely secondary to folate deficiency). **Low thiamine (B<sub>1</sub>) levels**.

**Gross Pathology** **Bilateral atrophy of mammillary bodies** and thalamus.

**Micro Pathology** Neuronal degeneration in mammillary bodies and thalamus.

**Treatment** Immediate thiamine (B<sub>1</sub>) administration parenterally; the sooner treatment is administered, the less permanent the sequelae. Alcoholics should also receive oral or IV folate as well as a multivitamin. Monitor carefully for **delirium tremens** secondary to alcohol withdrawal.

**Discussion** Wernicke's encephalopathy is for the most part **reversible with thiamine treatment**. A delay in treatment may cause progression to Korsakoff's psychosis with permanent dementia. Patients rarely return to normal. Patients also often have **wet beriberi** (high-output cardiac failure), **dry beriberi** (peripheral neuropathy with impairment of distal motor and sensory function), and cerebral beriberi (motor and cognitive impairment). **Wernicke's encephalopathy** consists of a triad of **confusion, ataxia, and ophthalmoplegia**. Korsakoff's psychosis is characterized by **retrograde/anterograde amnesia and confabulation**.

**Atlas Link** [UCMT](#) PG-BC-087



- ID/CC** After a routine pelvic exam, a 23-year-old **female** is referred by her family physician to an endocrinologist for an evaluation of **“lack of a palpable cervix.”**
- HPI** The patient states that she **has never had a menstrual period.**
- PE** **Bilateral breast tissue present; absence of pubic and axillary hair; vagina ends in blind pouch; clitoromegaly; small atrophic testis found** on right inguinal canal.
- Labs** **Increased LH and testosterone.** Karyotype: **46,XY.**
- Imaging** US: uterus and ovaries absent.
- Treatment** **Treat as woman,** resect cryptorchid testis and look for the intra-abdominal one (due to high risk of malignancy).
- Discussion** Also known as androgen insensitivity syndrome, testicular feminization is characterized by a genotypically male individual (KARYOTYPE 46,XY) who presents with a female body habitus with breast development and cryptorchidism; it is due to a Y chromosome gene defect that causes the **testosterone receptor protein to be unresponsive to androgenic stimulation.**

- ID/CC** A 20-year-old black female visits her gynecologist because she thinks she might be pregnant because of **lack of menses for the past 4 months**.
- HPI** She is a **pentathlon athlete** who is training to compete in her home state's tournament next fall. She is sexually active, uses the "rhythm method" for birth control, **and has never missed a menstrual period**.
- PE** No breast enlargement; no softening of cervix; no bluish discoloration of cervix (both presumptive signs of pregnancy); no abdominal or pelvic masses or palpable uterus; no hirsutism or virilization.
- Labs** Serum and urinary  $\beta$ -hCG **negative for pregnancy**; serum prolactin and TSH normal; **decreased serum FSH**; no withdrawal bleeding after administration of progesterone.
- Imaging** XR, skull: normal sella.
- Treatment** Advise patient to either gain enough weight to restore menses or take oral contraceptives to prevent osteoporosis.
- Discussion** The **most common cause of secondary amenorrhea is pregnancy**. Women who are involved in vigorous physical exercise and who lose weight may present with a functional gonadotropin deficit. When body weight falls > 15% of ideal weight, GnRH secretion from the hypothalamus is decreased, producing a secondary amenorrhea. The inhibitory effect of estrogens on bone resorption is also lost, predisposing patients to an increased risk for osteoporosis.

- ID/CC** A 5-year-old white male is brought to the emergency room with a fracture of his right forearm that he sustained after falling off a couch.
- HPI** This is the **fifth bone fracture** that the child has sustained **in the past 2 years**.
- PE** **Bluish sclera**; right leg and right arm slightly deformed from poor healing of past fractures; mild **kyphosis and scoliosis** of thoracic spine; **hypotonia and laxity** of right leg and arm; **partial conduction deafness** in both ears.
- Imaging** XR: fracture of radius and ulna with evidence of osteopenia.
- Micro Pathology** **Marked thinning of bone cortices** (EGGSHELL CORTEX) and rarefaction of trabeculae (due to **abnormal synthesis of type I collagen**); abnormal softening of tooth enamel.
- Treatment** Supportive.
- Discussion** Also called brittle bone disease, osteogenesis imperfecta is an **autosomal-dominant** disorder of type I collagen synthesis in which there is deficient ossification due to inadequate osteoid formation.
- Atlas Link** [UCM2](#) PED-052

- ID/CC** A 45-year-old male chess player is brought to the emergency room complaining of acute **nausea**; he has **vomited** five times, feels very **lightheaded**, and has a severe **headache**.
- HPI** He went out **drinking** last night to celebrate his victory in a chess tournament he attended last week in Mexico. While in Mexico, he contracted acute amebiasis that is currently being treated with **metronidazole**.
- PE** VS: marked tachycardia (HR 120); **hypotension** (BP 90/60). PE: anxious, dehydrated, and confused with severe nausea.
- Labs** CBC/LFTs: normal. Amylase normal. ABG/Lytes: mild hypokalemia and metabolic alkalosis (due to vomiting).
- Treatment** Supportive, IV fluids, antiemetics, discontinuance of alcohol.
- Discussion** Ethanol is degraded by alcohol dehydrogenase to acetaldehyde, which in turn is degraded to acetic acid by another acetaldehyde dehydrogenase. This **acetaldehyde dehydrogenase is inhibited** by disulfiram, resulting in the **accumulation of acetaldehyde**, which produces nausea, vomiting, headache, and hypotension (**ANTABUSE EFFECT**). Metronidazole, some cephalosporins, and other drugs have an Antabuse-like effect when consumed concomitantly with alcohol.

**ID/CC** A **premature** (32-week-old) white male infant is brought to the intensive care unit after a **cesarean** delivery.

**HPI** His mother had third-trimester **bleeding** and contractions that did not stop with rest and conservative treatment.

**PE** VS: tachypnea. PE: child weighs 3.8 lb; **cyanosis**; **dyspnea**; uses accessory muscles of respiration; **nasal flaring**.

**Labs** ABGs: hypoxemia; hypercapnia. Decreased lecithin/sphingomyelin (L/S) ratio (L/S ratio normally > 2; 1.5 to 2.0 in 40% of newborns with respiratory distress syndrome).

**Imaging** CXR: bilateral **reticular pulmonary infiltrates** and atelectasis.

**Gross Pathology** Generalized atelectasis in purple-colored lung; eosinophilic fibrinous hyaline membrane formation.

**Treatment** Ventilatory support, fluid, acid-base and electrolyte balance, antibiotics; administration of surfactant; steroids before birth to speed lung maturity.

**Discussion** **Respiratory distress syndrome** of the newborn is the most common cause of death in premature infants. It is due to a **deficiency of surfactant**, a lipoprotein produced by type II pneumocyte cells that contains the phospholipid dipalmitoyl lecithin. Fetal lung maturity may be measured by the L/S ratio. The syndrome might be prevented by giving **betamethasone** to pregnant women, since type II pneumocyte cell differentiation is dependent on steroids. Complications include patent ductus arteriosus, pulmonary air leaks, and bronchopulmonary dysplasia.

**Atlas Link** [UCVT](#) PG-BC-083

**ID/CC** A 36-year-old female **nonsmoker** visits her family doctor because she has become increasingly **short of breath** (DYSPNEA); her symptoms first appeared only during exercise but now occur even when she is at rest.

**HPI** She also complains of frequent URIs and moderate **weight loss**.

**PE** **Thin** female with **increased anteroposterior diameter of chest** (BARREL-SHAPED CHEST); decreased breath sounds bilaterally; **hyperresonance** to percussion; retardation of expiratory flow.

**Labs** CBC: increased hematocrit. PFTs: **FEV<sub>1</sub>/FVC < 75%** (diagnostic of airflow obstruction). ECG: right ventricular hypertrophy.

**Imaging** CXR: hyperlucent lung fields; flattening of diaphragm and decreased lung markings at periphery.

**Gross Pathology** Destruction of alveolar walls distal to the terminal bronchiole with hyperaeration (EMPHYSEMA); **panacinar type** (COTTON CANDY LUNG); more severe at lung bases.

**Treatment** Standard treatment for COPD patients. Replacement therapy with  $\alpha_1$ -protease inhibitor.

**Discussion** Pollutants, cigarette smoke, and infections increase PMNs and macrophages in the lung and thus produce a number of proteolytic enzymes. Damage to lung tissue due to these enzymes is controlled by the globulin  **$\alpha_1$ -antitrypsin**, which inhibits trypsin, neutrophil, elastase, and collagenase. A deficiency of this enzyme causes excessive lung tissue destruction and **panacinar emphysema** (cigarette smoking is associated with the centrilobular type). Patients may also develop **liver damage**.

- ID/CC** A 23-year-old female college student is brought to the emergency room because of **numbness** of her face and feet together with a **sensation of suffocation** and **stiff twisting of the hands** (CARPOPEDAL SPASM); these symptoms arose following an argument with her boyfriend.
- HPI** A friend reports that the patient has a **history of anxiety-induced colitis, gastritis, and migraine**.
- PE** VS: **marked tachypnea** (RR 40); tachycardia (HR 90); hypertension (BP 140/90). PE: patient **apprehensive** and anxious; physical exam otherwise normal.
- Labs** ABGs: **low Pco<sub>2</sub>; respiratory alkalosis** (cause of tetany); **low bicarbonate** (to compensate for primary lowering of Pco<sub>2</sub>).
- Imaging** CXR: normal
- Treatment** Have patient **breathe in and out of a bag** or give 5% CO<sub>2</sub> mixture.
- Discussion** Anxiety hyperventilation is a common occurrence in ERs. The anxiety state produces an increase in the frequency of respirations (HYPERVENTILATION), causing a lowering of Pco<sub>2</sub>; the resulting respiratory alkalosis produces an unstable depolarization of the distal segments of motor nerves with symptomatic tetany. Alkalosis also sets in motion a compensatory decrease in bicarbonate level to maintain pH as close to normal as possible.

**ID/CC** A 36-year-old divorcee living in rural Maine is brought by ambulance to the ER with her two children, who were **all found unconscious in her home** by military personnel.

**HPI** A recent “El Niño” produced bad weather that resulted in a power failure; as a result, she had been using charcoal and a **wooden stove inside her house** for heating purposes.

**PE** **Skin bright red** (CHERRY-RED CYANOSIS); pulse arrhythmic; patient regains consciousness soon after administration of 100% oxygen but remains drowsy, **disoriented**, and nauseous and complains of a severe **headache** (due to cerebral edema); **hyperreflexia** noted as well as positive Romberg’s test.

**Labs** **Increased carboxyhemoglobin** (> 25%). ABGs: metabolic acidosis.

**Imaging** CT/MR: bilateral globus pallidus lesions.

**Treatment** One hundred percent **oxygen**, assisted ventilation if necessary. Hyperbaric oxygen chamber.

**Discussion** Common sources of CO are car exhaust, pipes, and fires. Carbon monoxide has a much greater affinity for hemoglobin than oxygen (250 times more). If patient is pregnant, damage to the fetus is devastating (HbF has greater affinity to CO than HbA). Long-term side effects such as memory problems, lack of coordination, and even convulsions are common after intoxication.



- ID/CC** A 52-year-old obese white male comes to his family doctor complaining of severe pain in the **first metatarsophalangeal (MTP) joint** (PODAGRA) that began at **night** after an episode of **binge eating** and **drinking**.
- HPI** He admits to being an avid **meat** eater and drinks **red wine** every night. His history is significant for removal of **kidney stones** (uric acid stones).
- PE** VS: **fever** (38.2°C). PE: **right MTP joint** red, hot, and swollen; painful to active and passive motion; **tophaceous** deposits in left ear and olecranon bursitis.
- Labs** **Elevated serum uric acid**. UA: urate crystals. **Increased ESR**. CBC: leukocytosis with neutrophilia.
- Imaging** XR: punched-out erosions in right big toe at MTP joint, producing “**overhanging**” spicules.
- Gross Pathology** Tophi are white, soft, nodular masses of urate deposits with calcifications seen mainly in synovial membranes, tendon sheaths, and ear cartilages.
- Micro Pathology** Tophi and synovial fluid aspiration show characteristic negatively **birefringent, needle-shaped crystals** of uric acid salts; giant cell formation with neutrophilic infiltration.
- Treatment** Colchicine for acute stage; administer hourly until negatively diarrhea occurs or pain disappears; combine with aspirin or NSAIDs. Long-term treatment with allopurinol and/or probenecid.
- Discussion** Gout is a disorder of purine metabolism with a resulting increase in serum uric acid level and deposits in several tissues; 10% to 20% of cases may develop nephrolithiasis. In late stages, urate deposits in the kidney may lead to chronic pyelonephritis, arteriolar sclerosis, hypertension, and renal failure.
- Atlas Links** [UCVM1](#) PM-BC-094 [UCVM2](#) IM2-052A, IM2-052B

