

www.GetPedia.com

- * More than 150,000 articles in the search database
- * Learn how almost everything works



KAPLAN[®]
medical

USMLE[™]

Step 2 CK

Lecture Notes

**Obstetrics and
Gynecology**

2005–2006 Edition

*USMLE is a joint program of the Federation of State Medical Boards of the United States, Inc. and the National Board of Medical Examiners.

USMLE Step 2 CK

Obstetrics and Gynecology Lecture Notes

**KAPLAN[®]
medical**

*USMLE is a joint program of the Federation of State Medical Boards of the United States, Inc. and the National Board of Medical Examiners.

©2005 Kaplan, Inc.

All rights reserved. No part of this book may be reproduced in any form, by photostat, microfilm, xerography or any other means, or incorporated into any information retrieval system, electronic or mechanical, without the written permission of Kaplan, Inc.

Not for resale.

Authors

Elmar Peter Sakala, M.D., M.A., M.P.H., F.A.C.O.G.

Editor in Chief of Kaplan USMLE Step 2 Notes

Professor of Gynecology and Obstetrics

Codirector of Student Clerkship

Department of Gynecology and Obstetrics

Loma Linda University School of Medicine

Loma Linda, California

Manuel Penalver, M.D., F.A.C.O.G.

Professor and Chairman

Department of Obstetrics and Gynecology

University of Miami School of Medicine

Miami, Florida

Contents

Chapter 1. Human Genetics	1
Chapter 2. Physiology of Pregnancy	15
Chapter 3. Antenatal Care and Fetal Testing	19
Chapter 4. Perinatal Infections	35
Chapter 5. Pregnancy Bleeding	45
Chapter 6. Obstetrical Complications: Obstetrics	51
Chapter 7. Obstetrical Complications: Hypertension	61
Chapter 8. Obstetrical Complications: Medical	67
Chapter 9. Intrapartum Events	77
Chapter 10. Postpartum Issues	97
Chapter 11. Gynecologic Neoplasia and Cancer	103
Chapter 12. Benign Gynecology	125
Chapter 13. Reproductive Endocrinology	147
Chapter 14. Breast Disease	169

Human Genetics

INDICATIONS FOR GENETIC COUNSELING

A 37-year-old G5 P0 Ab4 comes for prenatal care at 7 weeks' gestation. She has experienced four previous spontaneous first-trimester abortions. She is concerned about the likelihood of her next pregnancy being successful.

- *Advanced maternal age:* women ≥ 35 years of age at increased risk of fetal nondisjunction trisomies (e.g., trisomies 21 and 18)
- *Incidence of Chromosomal Abnormalities by Maternal Age:*

<u>Age</u>	<u>Down Syndrome</u>	<u>Total Risk</u>
20	1 in 1,670	1:525
25	1 in 1,250	1:475
30	1 in 885	1:385
35	1 in 365	1:180
40	1 in 110	1:63
45	1 in 32	1:18
49	1 in 12	1:7

- *Multiple fetal losses*
- *Previous child:* neonatal death, mental retardation, aneuploidy, known genetic disorder
- *Pregnancy or fetal losses:* stillborn with birth defect, multiple pregnancy or fetal losses
- *Family history:* genetic diseases, birth defects, mental retardation
- *Abnormal prenatal tests:* triple marker screen, sonogram
- *Parental aneuploidy*

PRENATAL DIAGNOSTIC TESTING PROCEDURES

A 24-year-old G2 P1 at 11 weeks' gestation comes to the office. Her previous baby has trisomy 21, and she is concerned that this fetus may also have the condition. She inquires about possible diagnostic testing for this pregnancy.

Ultrasound

This noninvasive imaging modality is used for guidance of invasive prenatal diagnostic procedures. *No adverse fetal effects* have been identified when using low-energy transducers. Current recommendations are to perform sonography in pregnancy only for obstetric indications. Optimal gestational age for identification of fetal anatomic structural anomalies is *18–20 weeks*. Accuracy of gestational dating is ± 5 days at less than 12 weeks, and ± 7 days between 12 and 18 weeks. Specificity and sensitivity for identification of fetal anomalies is less than perfect.

Chorionic Villous Sampling (CVS)

This refers to aspiration of placental tissue precursors under sonographic guidance for fetal karyotyping. It is performed between *9 and 12 weeks'* gestation. Follow-up testing with triple marker screening and sonogram is needed to assess for neural tube defects. Placental mosaicism may be rarely present although fetal karyotype is normal. *Pregnancy loss rate is 0.7%*. Advantages include the early gestational age at which karyotype is available.

Amniocentesis

This refers to transabdominal needle withdrawal of amniotic fluid under sonographic guidance. When performed for genetic purposes (fetal karyotyping, α -fetoprotein determination, biochemical studies), the gestational age is usually *15–20 weeks*. When performed for Rh isoimmunization (bilirubin level), the gestational age is usually after *24 weeks*. When performed for fetal maturity studies (lecithin-sphingomyelin ratio, phosphatidyl glycerol, TDx-FLM test), the gestational age is after *34 weeks*. *Pregnancy loss rate is 0.5%*.

Percutaneous Umbilical Blood Sampling (PUBS)

This refers to sonographically guided transabdominal aspiration of fetal blood from the umbilical vein. It is performed *after 20 weeks* for fetal karyotyping, IgM antibody detection, blood typing, and intrauterine blood transfusion. *Pregnancy loss rate is 1–2%*.

Fetoscopy

This largely *experimental* procedure refers to sonographically guided transabdominal placement of a fiberoptic scope for purposes of fetal tissue biopsy and coagulation of placental vessels in twin-twin transfusion syndrome. It is performed between *18 and 20 weeks* in suspected congenital ichthyosis. *Pregnancy loss rate is 3–5%*.

CHROMOSOMAL ABERRATIONS

Aneuploidy

This refers to *numeric chromosome abnormalities* in which cells do not contain two complete sets of 23 chromosomes. This usually occurs because of *nondisjunction*. The most common aneuploidy is *trisomy*, the presence of an extra chromosome. Most autosomal trisomies result in spontaneous abortions. The most common trisomy in first-trimester abortions is trisomy 16. The most common trisomy at term is trisomy 21.

Polyploidy

This refers to numeric chromosome abnormalities in which cells contain complete *sets of extra chromosomes*. The most common polyploidy is *triploidy* with 69 chromosomes, followed by *tetraploidy* with 92 chromosomes. An example of triploidy is *incomplete molar pregnancies*, which occurs from fertilization of an egg by two sperm.

Structural Alterations

This refers to conditions in which chromosomal material is deleted, gained, or rearranged. It can involve single or multiple chromosomes. An example of a chromosomal deletion is *del (5p)* or *cri du chat syndrome*, which is a deletion of the short arm of chromosome 5.

Mosaicism

This refers to the presence of two or more cytogenetically distinct cell lines in the same individual. Mosaicism can involve the placenta, the fetus, or both. Gonadal mosaicism can result in premature ovarian failure and predispose the gonad to malignancy.

TRANSLOCATIONS

Reciprocal

This involves any two or more nonhomologous chromosomes, and occurs when there is a *breakage and reunion* of portions of the involved chromosomes to yield new products. Carriers of *balanced reciprocal translocations* have 46 chromosomes, with both derivative chromosomes present. The offspring may also have 46 chromosomes but have only one of the derivative chromosomes present.

Robertsonian

This always involves the *acrocentric chromosomes*, and is caused by centric fusion after loss of the satellite region of the short arms of the original acrosomic chromosome. The karyotype of a balanced Robertsonian translocation will appear to have only 45 chromosomes; however, the full complement of genetic material is present, and there are no clinical effects. The offspring may have 46 chromosomes but have double the genetic material of a particular chromosome.

GENETICS OF PREGNANCY LOSS

Miscarriage

At least 50% of first-trimester abortuses have abnormal chromosomes. Fifty percent of these abnormalities are autosomal trisomies, with trisomy 16 being the most common. Twenty percent are 45,X, or Turner syndrome, the *most common* single aneuploidy seen.

Turner Syndrome (45,X)

Also known as *gonadal dysgenesis* or *monosomy X*, *Turner syndrome* is seen in 1 in 10,000 births. In most cases it is the result of loss of the paternal X chromosome. Most of these fetuses abort spontaneously. Obstetric ultrasound shows the characteristic nuchal skin-fold thickening and *cystic hygroma*. Those fetuses that survive to term have absence of secondary sexual development, short stature, streak gonads, primary amenorrhea, primary infertility, broad chest, and neck webbing. Urinary tract anomalies and aortic coarctation are commonly seen. Intelligence is usually normal. Mosaic patterns can occur with ovarian follicles present.

Klinefelter Syndrome (47,XXY)

Klinefelter syndrome is seen in 1 in 2,000 births. Diagnosis is seldom made before puberty. Physical findings include testicular atrophy, azoospermia, gynecomastia, and truncal obesity. Learning disorders and low IQ are common.

Down Syndrome

Trisomy 21 is seen in 1 in 800 births and accounts for 50% of all cytogenetic diseases. T21 incidence increases with advancing maternal age. The syndrome is characterized by mental retardation, short stature, muscular hypotonia, brachycephaly, and short neck. The typical facial appearance is oblique orbital fissures, flat nasal bridge, small ears, nystagmus, and protruding tongue. Congenital heart disease (endocardial cushion defects) is more common along with duodenal atresia.

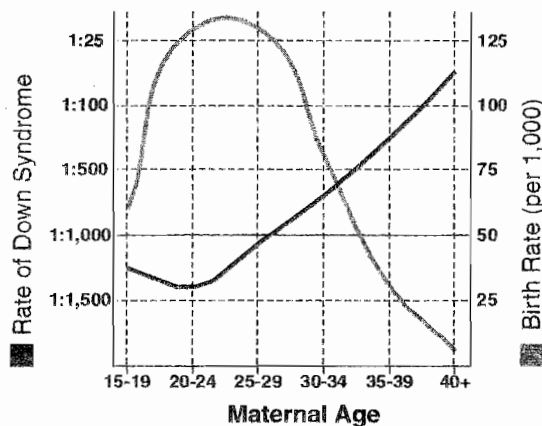


Figure 1-1. Birth Rate and Rate of Down Syndrome Versus Maternal Age

Edward Syndrome

Trisomy 18 is seen more frequently with advancing maternal age. It is associated with profound mental retardation. Survival to 1 year of age is only 40%.

Patau Syndrome

Trisomy 13 is also seen more frequently with advancing maternal age. It is associated with profound mental retardation. Survival to 1 year of age is only 40%.

MENDELIAN GENETICS

A 23-year-old black primigravida is seen at 12 weeks' gestation. She has been diagnosed with sickle cell trait (AS). Her husband and father of the baby is also AS. She inquires as to the risk of her baby having sickle cell disease (SS).

Prevalence

About 1% of liveborn infants have a congenital Mendelian disorder. *Fifteen percent* of all birth defects are attributable to Mendelian disorders. Of these, 70% are autosomal dominant. The remainder are autosomal recessive, X-linked, or multifactorial.

Autosomal Dominant Genetics

Transmission occurs equally to males and females, and serial generations are affected. *Gross anatomic abnormalities* are the *most common* findings. Age of onset is usually delayed, with variability in clinical expression. Each affected individual has an affected parent (unless this is a new mutation). Affected individuals will transmit the disease to 50% of their offspring. Unaffected individuals will bear unaffected children (if penetrance is complete). *There are no carrier states.*

Autosomal dominant examples:

Polydactyly	Marfan syndrome	Polycystic kidneys
Huntington chorea	Myotonic dystrophy	Neurofibromatosis
Achondroplasia		Osteogenesis imperfecta

Autosomal Recessive

Transmission occurs equally to males and females, but the disease often skips generations. *Enzyme deficiencies* are *most common* findings. Age of onset is usually earlier with consistency in clinical expression. If both parents are heterozygous for the gene, 25% of offspring are affected, 50% are carriers, and 25% are normal. If one parent is homozygous and one is heterozygous, 50% of offspring will be affected, and 50% will be carriers. If both parents are homozygous, 100% of children will be affected. *Carrier states are common.*

Autosomal recessive examples:

Deafness	Albinism	Phenylketonuria
Cystic fibrosis	Sickle cell anemia	Congenital adrenal hyperplasia
Thalassemia	Tay-Sachs disease	Wilson disease

X-Linked Recessive

These conditions are functionally dominant in men, but may be dominant or recessive in women. There is *no male-to-male transmission* (because the father gives only his Y chromosome to his son), but transmission is 100% male to female. The usual transmission is from heterozygous females to male offspring in an autosomally dominant pattern. The disease is *expressed in all males* who carry the gene. Family history reveals the disorder is only found in male relatives, and commonly in maternal uncles.

X-linked recessive examples:

- | | | |
|-------------------------|--------------------|-----------------------------|
| Hemophilia A | Diabetes insipidus | G-6-PD deficiency |
| Color blindness | Hydrocephalus | Duchenne muscular dystrophy |
| Testicular feminization | | |

X-Linked Dominant

These conditions may show up as two types of disorders. (1) The disease is manifested in female heterozygotes as well as carrier males (hemizygotes). Example is hypophosphatemic rickets. (2) The disease is manifested in female heterozygotes, but is lethal in males. The increased spontaneous abortion rate represents male fetuses. Examples are incontinentia pigmenti, focal dermal hypoplasia, and orofacioidigital syndrome.

	A	S
A		
A		

	A	S
A		
S		

	S	S
A		
S		

Calculations of AR Risk

	X	X ^H
X		
Y		

Figure 1-2. Calculations of X-linked Risk (Hemophilia)

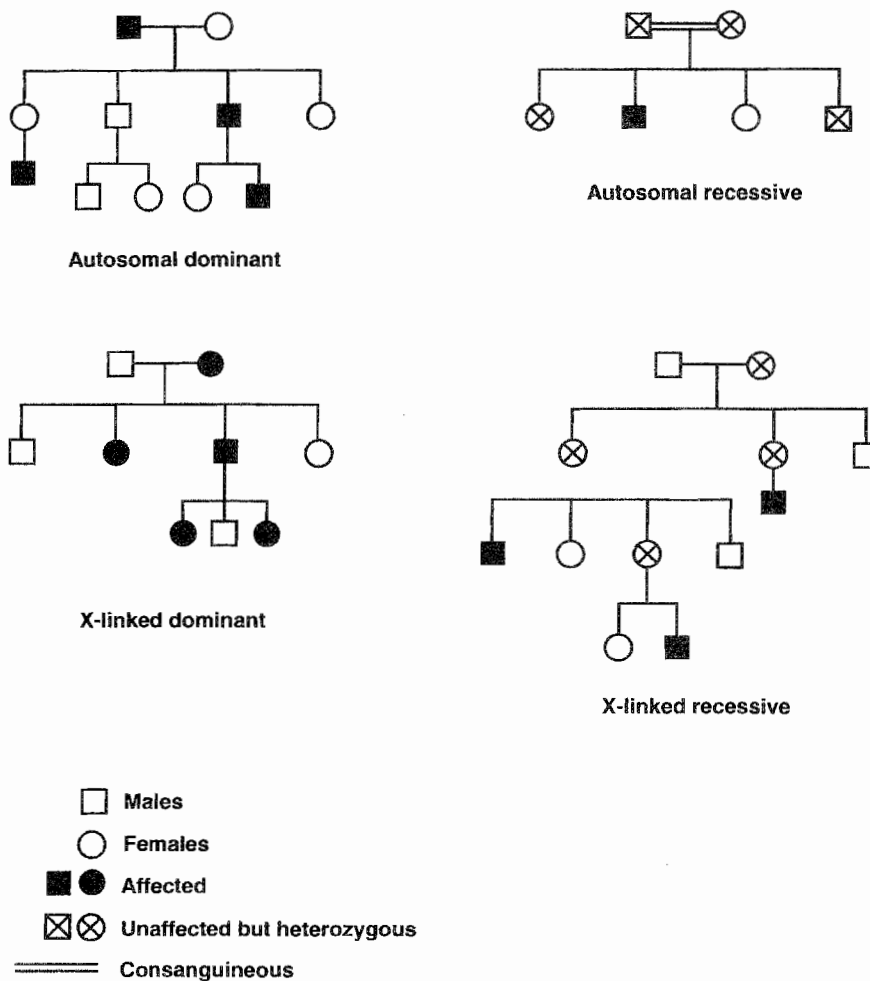


Figure 1-3. Familial Transmission Patterns of Inheritance

MULTIFACTORIAL INHERITANCE

A 32-year-old woman with corrected tetralogy of Fallot is pregnant at 18 weeks' gestation with a male fetus. She inquires as to the chance that her son has congenital heart disease.

Prevalence

The majority of birth defects (70%) are multifactorial or polygenic in origin, which means there is an interaction of multiple genes with environmental factors. Characteristic Mendelian patterns are not found, but there is an increased frequency of the disorder or phenotype in families. *The overall recurrence rate is 2–3%.* The more severe the malformation, the higher the risk for recurrence. Examples of multifactorial inheritance include neural tube defects, congenital heart disease, cleft lip and palate, and pyloric stenosis.

Neural Tube Defects (NTD)

The incidence of NTD is 1–2 per 1,000 births. These anomalies result from failure of neural tube closure by *days 26–28* of embryonic life. The spectrum ranges from anencephaly to very slight vertebral defects. Anencephaly and spina bifida occur with equal frequency. Polyhydramnios is frequently seen. *Preconception folic acid* supplementation may decrease incidence of NTD. Women with high risk for NTD should take *4 mg* of folic acid. All women should take *0.4 mg* of folic acid.

Congenital Heart Disease (CHD)

The incidence of CHD is 1% of births. The majority of isolated CHD are multifactorial *with an overall recurrence risk of 2%*. However, the specific recurrence risk depends on the defect and the family history details. It is important to distinguish isolated defects from those that are part of a syndrome with a higher recurrence risk. Preconception folate reduces the risk of congenital CHD, as well as NTD.

Cleft Lip and Palate

The incidence is 1 per 1,000 births. The risk of cleft lip in a second child of unaffected parents is 4%. If two children are affected, the risk of the third child being affected is 10%.

Pyloric Stenosis

This condition is more common in males. The risk of the condition in the offspring of an affected parent is much greater if that parent is female.

EMBRYOLOGY

Embryonic and Fetal Development

Postconception Week 1

The most significant event of week 1 is the *implantation of the blastocyst* on the endometrium. Week 1 begins with fertilization of the egg and ends with implantation of the blastocyst onto the endometrial surface. Fertilization usually occurs in the distal part of the oviduct. The egg is capable of being fertilized for 12–24 h.

Week 1 can be divided into two phases:

- The *intratubal phase* extends through the first half of the first week. It begins at conception (*day 0*) and ends with the entry of the morula into the uterine cavity (*day 3*). The conceptus is traveling down the oviduct as it passes through the two-cell, four-cell, and eight-cell stages.
- The *intrauterine phase* begins with entry of the morula into the uterus (*day 3*) and ends with implantation of the blastocyst onto the endometrial surface (*day 6*). During this time the morula differentiates into a hollow ball of cells. The outer layer will become the trophoblast or placenta, and the inner cell mass will become the embryo.

Postconception Week 2

The most significant event of week 2 is the development of the *bilaminar germ disk* with *epiblast* and *hypoblast* layers. These layers will eventually give rise to the three primordial germ layers.

Another significant event is the invasion of the maternal sinusoids by syncytiotrophoblast. Because β -human chorionic gonadotropin (β -hCG) is produced in the syncytiotrophoblast, this now allows β -hCG to enter the maternal blood stream. *β -hCG pregnancy test now can be positive for the first time.*

Postconception Week 3

The most significant event of week 3 is the migration of cells through the primitive streak between the epiblast and hypoblast to form the *trilaminar germ disk* with *ectoderm*, *mesoderm*, and *endoderm* layers. These layers will give rise to the major organs and organ systems.

Postconception Week 4–8

During this time the major organs and organ systems are being formed. This is the period of major teratogenic risk.

- *Ectoderm*—central and peripheral nervous systems; sensory organs of seeing and hearing; integument layers (skin, hair, and nails).
- *Mesoderm*—muscles, cartilage, cardiovascular system, urogenital system.
- *Endoderm*—lining of the GI and respiratory tracts.

Paramesonephric (Müllerian) Duct

This duct is present in all early embryos and is the primordium of the female internal reproductive system. *No hormonal stimulation is required.* In males the Y chromosome induces gonadal secretion of müllerian inhibitory factor (*MIF*), which causes the müllerian duct to involute. In females, without *MIF*, development continues to form the fallopian tubes, corpus of the uterus, cervix, and proximal vagina.

Female External Genitalia

No hormonal stimulation is needed for differentiation of the external genitalia into labia majora, labia minora, clitoris, and distal vagina.

Mesonephric (Wolffian) Duct

This duct is also present in all early embryos and is the primordium of the male internal reproductive system. *Androgen stimulation is required* for development to continue to form the vas deferens, seminal vesicles, epididymis, and efferent ducts. This is present in males from testicular sources. In females, without androgen stimulation, the Wolffian duct undergoes regression. If a genetic male has an absence of androgen receptors, the Wolffian duct will also undergo regression.

Male External Genitalia

Androgen stimulation (dihydrotestosterone) is needed for differentiation of the external genitalia into a penis and scrotum. If a genetic male has an absence of androgen receptors, external genitalia will differentiate in a female direction.

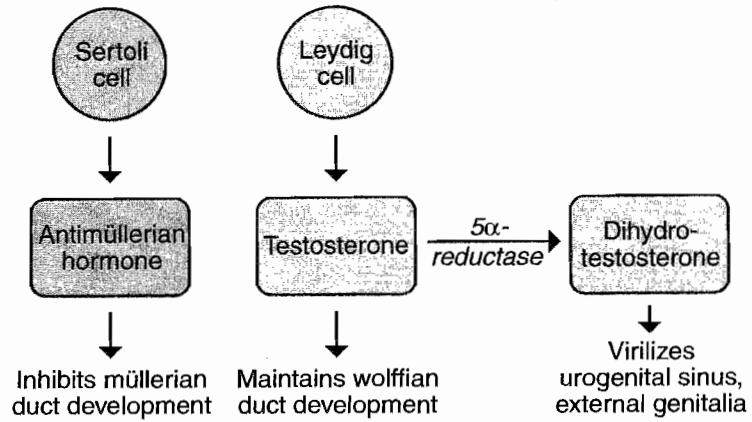


Figure 1-4. Testicular Function

Table 1-1. Embryology

Primordia	Female	Male	Major Determinant Factors
<i>Gonadal</i> Germ cells Coelomic epithelium Mesenchyme Mesonephros	Oogonia Granulosa cells Theca cells Rete ovarii	Spermatogonia Sertoli cells Leydig cells Rete testis	Sex chromosomes
<i>Ductal</i> Paramesonephric (Müllerian) Mesonephric (Wolffian) Mesonephric tubules	Fallopian tubes Uterus Part of vagina Gartner's duct Epoophoron Paraophoron	Testis hydatid Vas deferens Seminal vesicles Epididymis Efferent ducts	Absence of Y chromosome Testosterone Müllerian-inhibiting factor
<i>External Genitalia</i> Urogenital sinus Genital tubercle Urogenital folds Genital folds	Vaginal contribution Skene's glands Bartholin's glands Clitoris Labia minora Labia majora	Prostate Bulbourethral glands Prostatic utricle Penis Corpora spongiosa Scrotum	Presence or absence of testosterone, dihydrotestosterone, and 5-alpha reductase enzyme

TERATOLOGY

A 36-year-old woman underwent a barium enema for rectal bleeding on February 1 with estimated radiation dose of 4 rad. Her last menstrual period (LMP) was January 1 and she has 35-day cycles. She was not using any contraception. A urine pregnancy test was positive on March 15. She inquires about the risk to her fetus of teratogenic injury.

Definition of a Teratogen

A teratogen is any agent that disturbs normal fetal development and affects subsequent function. The nature of the agent as well as its timing and duration after conception are critical.

Stages of Teratogenesis

- *From conception to end of second week*—The embryo will either *survive intact or die* because the three germ layers have not yet been formed.
- *Postconception weeks 3–8*—This is the *period of greatest teratogenic risk* from formation of the three germ layers to completion of organogenesis.
- *After week 9 of postconception*—During this time *teratogenicity is low*, but adverse effects may include diminished organ hypertrophy and hyperplasia.

Types of Agents Resulting in Teratogenesis or Adverse Outcomes

Infectious

Agents in this category include bacteria (e.g., chlamydia and gonorrhea cause neonatal eye and ear infections), viral (e.g., rubella, cytomegalovirus, herpes virus), spirochetes (e.g., syphilis), or protozoa (e.g., toxoplasmosis).

Ionizing radiation

No single diagnostic procedure results in radiation exposure to a degree that would threaten the developing pre-embryo, embryo, or fetus. The greatest risk of exposure is between 8 and 15 weeks' gestation with the risk a nonthreshold, linear function at doses of at least 20 rads.

Chemotherapy

Risk is predominantly a first-trimester phenomenon. Second- and third-trimester fetuses are remarkably resistant to chemotherapeutic agents.

Environmental

Tobacco is associated with intrauterine growth retardation (IUGR) and preterm delivery, but no specific syndrome. Alcohol is associated with fetal alcohol syndrome: midfacial hypoplasia, microcephaly, mental retardation, and IUGR.

Recreational drugs

Cocaine is associated with placental abruption, preterm delivery, intraventricular hemorrhage, and IUGR. Marijuana is associated with preterm delivery but not with any syndrome.

Medications

These agents account for 1–2% of congenital malformations. The ability of a drug to cross the placenta to the fetus depends on molecular weight, ionic charge, lipid solubility, and protein binding. Drugs are listed by the FDA as category A, B, C, D, and X.

FDA Categories of Drugs

- **Category A**—*Controlled studies show no risk.* Adequate studies show no risk to the fetus in any pregnancy trimester. This includes acetaminophen, thyroxine, folic acid, and magnesium sulfate.
- **Category B**—*No evidence of risk in humans.* Controlled studies show no risk to humans despite adverse findings in animals. This includes penicillins, cephalosporins, methyldopa, insulin, Pepcid, Reglan, Tagamet, ritodrine, Vistaril, Paxil, Prozac, Benadryl, and Dramamine.
- **Category C**—*Risk cannot be ruled out.* Controlled studies are lacking in humans and animals. This includes codeine, Decadron, methadone, Bactrim, Cipro, AZT, β -blockers, Prilosec, heparin, Protamine, Thorazine, Alupent, Robitussin, and Sudafed.
- **Category D**—*Positive evidence of risk.* Studies demonstrate fetal risk, but potential benefits of the drug may outweigh the risk. This includes aspirin, Valium, tetracycline, Dilantin, Depakote, and Lithium.
- **Category X**—*Contraindicated in pregnancy.* Studies demonstrate fetal risk, which outweighs any possible benefit. This includes Accutane (isotretinoin), Danocrine, Pravachol, Coumadin, and Cafegot.

Specific Syndromes

Alcohol

Fetal alcohol syndrome—IUGR, *midfacial hypoplasia*, developmental delay, short palpebral fissures, *long philtrum*, multiple joint anomalies, cardiac defects.

Diethylstilbestrol

DES syndrome—*T-shaped uterus*, *vaginal adenosis* (with predisposition to *vaginal clear cell carcinoma*), cervical hood, incompetent cervix, preterm delivery.

Dilantin

Fetal hydantoin syndrome. IUGR, *craniofacial dysmorphism* (epicanthal folds, depressed nasal bridge, oral clefts), *mental retardation*, *microcephaly*, nail hypoplasia, heart defects.

Isotretinoin (Accutane)

Congenital deafness, *microtia*, CNS defects, congenital heart defects.

Lithium

Ebstein's anomaly (right heart defect).

Streptomycin

VIII nerve damage, hearing loss.

Tetracycline

After fourth month, deciduous teeth discoloration.

Thalidomide

Phocomelia, limb reduction defects, ear/nasal anomalies, cardiac defects, pyloric or duodenal stenosis.

Trimethadione

Facial dysmorphism (short upturned nose, slanted eyebrows), cardiac defects, IUGR, mental retardation.

Valproic acid (Depakote)

Neural tube defects (spina bifida), cleft lip, renal defects.

Warfarin (coumadin)

Chondrodysplasia (stippled epiphysis), microcephaly, mental retardation, optic atrophy.

Physiology of Pregnancy

2

PREGNANCY HORMONES

Human Chorionic Gonadotropin (hCG)

Source—It is produced by the placental *syncytiotrophoblast*, first appearing in maternal blood 10 days after fertilization, *peaking at 9–10 weeks*, and then gradually falling to a *plateau level at 20–22 weeks*.

Structure—By chemical structure it is a glycoprotein with *two subunits*. The α -subunit is similar to luteinizing hormone, follicle-stimulating hormone, and thyrotropin. The β -subunit is specific.

Purposes

- *Maintain corpus luteum* production of progesterone until the placenta can take over maintenance of the pregnancy.
- *Regulate steroid biosynthesis* in the placenta and fetal adrenal gland as well.
- *Stimulate testosterone production* in the fetal male testes.

If levels are excessive—*twin pregnancy, hydatidiform mole, choriocarcinoma, embryonal carcinoma*.

If levels are inadequate—*ectopic pregnancy, threatened abortion, missed abortion*.

Human Placental Lactogen

Structure—Chemically it is similar to anterior pituitary *growth hormone* and prolactin.

Pregnancy change—Its level parallels placental growth, rising throughout pregnancy.

Effect—It *antagonizes* the cellular action of *insulin*, decreasing insulin utilization, thereby contributing to the predisposition of pregnancy to glucose intolerance and diabetes.

If levels are low—threatened abortion, intrauterine growth retardation (IUGR).

Progesterone

Structure—This is a steroid hormone produced after ovulation by the *luteal cells of the corpus luteum* to induce endometrial secretory changes favorable for blastocyst implantation.

Source—It is initially produced exclusively by the *corpus luteum* up to 6–7 menstrual weeks. Between 7 and 9 weeks, both the corpus luteum and the placenta produce progesterone. After 9 weeks the corpus luteum declines, and progesterone production is exclusively by the *placenta*.

Purposes

- *In early pregnancy* it induces endometrial secretory changes favorable for blastocyst implantation.
- *In later pregnancy* its function is to induce immune tolerance for the pregnancy and prevent myometrial contractions.

Estrogen

These are steroid hormones, which occur in three forms, each of unique significance during a woman's life.

Estradiol is the predominant moiety *during* the nonpregnant *reproductive years*. It is converted from androgens (produced from cholesterol in the follicular theca cells), which diffuse into the *follicular granulosa cells* containing the *aromatase enzyme* that completes the transformation into estradiol.

Estriol is the main estrogen *during pregnancy*. Dehydroepiandrosterone-sulfate (DHEA-S) from the *fetal adrenal gland* is the precursor for 90% of estriol converted by sulfatase enzyme in the placenta.

Estrone is the main form *during menopause*. Postmenopausally, adrenal androstenedione is converted in *peripheral adipose tissue* to estrone.

CHANGES IN SPECIFIC ORGAN SYSTEMS

Skin

Striae gravidarum—"Stretch marks" that develop in genetically predisposed women on the abdomen and buttocks.

Spider angiomata and **palmer erythema**—From increased skin vascularity.

Chadwick sign—Bluish or purplish discoloration of the vagina and cervix as a result of increased vascularity.

Line nigra—Increased pigmentation of the lower abdominal midline from the pubis to the umbilicus.

Chloasma—Blotchy pigmentation of the nose and face.

Cardiovascular

Arterial blood pressure—Systolic and diastolic values both *decline* early in the first trimester, reaching a nadir by 24–28 weeks, then they gradually rise toward term but never return quite to prepregnancy baseline. Diastolic falls more than systolic, as much as 15 mm Hg. *Arterial blood pressure is never normally elevated in pregnancy.*

Venous blood pressure—Central venous pressure (*CVP*) is *unchanged* with pregnancy, but femoral venous pressure (*FVP*) increases two- to threefold by 30 weeks' gestation.

Plasma volume—Plasma volume *increases* up to 50% with a significant increase by the first trimester. Maximum increase is by 30 weeks. This increase is even greater with multiple fetuses.

Peripheral vascular resistance (PVR)—PVR equals blood pressure (BP) divided by cardiac output (CO). Because BP decreases and CO increases, PVR *declines* by 30%, reaching its nadir by 20 weeks. This enhances uteroplacental perfusion.

Cardiac output (CO)—CO *increases* up to 50% with the major increase by 20 weeks. CO is the product of heart rate (HR) and stroke volume (SV), and both increase in pregnancy. HR increases by 20 beats/min by the third trimester. SV increases by 30% by the end of the first trimester. CO *is dependent on maternal position*. CO is the lowest in the supine position because of inferior vena cava compression resulting in decreased cardiac return. CO is the highest in the left lateral position. CO increases progressively through the three stages of labor.

Murmurs—A systolic ejection murmur along the left sternal border is normal in pregnancy owing to increased CO passing through the aortic and pulmonary valves. *Diastolic murmurs are never normal in pregnancy and must be investigated.*

Hematologic

Red blood cells (RBC)—RBC mass *increases* by 30% in pregnancy; thus, oxygen-carrying capacity increases. However, because plasma volume increases by 50%, the calculated hemoglobin and hematocrit values *decrease* by 15%. The nadir of the hemoglobin value is at 28–30 weeks' gestation. *This is a physiologic dilutional effect, not a manifestation of anemia.*

White blood cells (WBC)—WBC count *increases* progressively during pregnancy with a mean value of up to 16,000/mm³ in the third trimester.

Erythrocyte sedimentation rate (ESR)—ESR *increases* in pregnancy because of the increase in gamma globulins.

Platelet count—Platelet count normal reference range is *unchanged* in pregnancy.

Coagulation factors—Factors VII, VIII, IX, and X *increase* progressively in pregnancy, leading to a hypercoagulable state.

Gastrointestinal

Stomach—Gastric motility *decreases* and emptying time *increases* from the progesterone effect on smooth muscle. This increase in stomach residual volume, along with upward displacement of intraabdominal contents by the gravid uterus, predisposes to aspiration.

Large bowel—Colonic motility *decreases* and transit time *increases* from the progesterone effect on smooth muscle. This predisposes to increased colonic fluid absorption resulting in constipation.

Pulmonary

Tidal volume (VT)—VT is volume of air that moves in and out of the lungs at rest. VT *increases* with pregnancy to 40%. It is the only lung volume that does not decrease with pregnancy.

Minute ventilation (\dot{V}_E)— \dot{V}_E *increases* up to 40% with the major increase by 20 weeks. \dot{V}_E is the product of respiratory rate (RR) and VT. RR remains unchanged with VT increasing steadily throughout the pregnancy into the third trimester.

Residual volume (RV)—RV is the volume of air trapped in the lungs after deepest expiration. RV *decreases* up to 20% by the third trimester. To a great extent this is because of the upward displacement of intraabdominal contents against the diaphragm by the gravid uterus.

Blood gases—The rise in VT produces a *respiratory alkalosis* with a decrease in PCO_2 from 40 to 35 mm Hg and an increase in pH from 7.40 to 7.45. An increased renal loss of bicarbonate helps compensate, resulting in an alkalotic urine.

Renal

Kidneys—The kidneys *increase* in size because of the increase in renal blood flow. This hypertrophy doesn't reverse until 3 months postpartum.

Ureters—Ureteral diameter *increases* owing to the progesterone effect on smooth muscle. The right side dilates more than the left in 90% of patients.

Glomerular filtration rate (GFR)—GFR, renal plasma flow, and creatinine clearance all *increase* by 50% as early as the end of the first trimester. This results in a 25% decrease in serum blood urea nitrogen (BUN), creatinine, and uric acid.

Glucosuria—Urine glucose normally *increases*. Glucose is freely filtered and actively reabsorbed. However, the tubal reabsorption threshold falls from 195 to 155 mg/dL.

Proteinuria—Urine protein remains *unchanged*.

Endocrine

Pituitary—Pituitary size *increases* by 100% by term from increasing vascularity. This makes it susceptible to ischemic injury (Sheehan syndrome) from postpartum hypotension.

Adrenals—Adrenal gland size is *unchanged*, but production of cortisol *increases* two- to three-fold.

Thyroid—Thyroid size *increases* 15% from increased vascularity. Thyroid binding globulin (TBG) increases, resulting in *increased* total T_3 and T_4 , although free T_3 and free T_4 remain *unchanged*.

Fetal Circulation

Three in utero shunts exist within the fetus. The **ductus venosus** carries blood from the umbilical vein to the inferior vena cava. The **foramen ovale** carries blood from the right to the left atrium, and the **ductus arteriosus** shunts blood from the pulmonary artery to the descending aorta.

Antenatal Care and Fetal Testing

3

DIAGNOSIS OF PREGNANCY

Presumptive signs of pregnancy include *amenorrhea*, breast tenderness, nausea and vomiting, increased skin pigmentation, and skin striae.

Probable signs of pregnancy include *enlargement of the uterus*, maternal sensation of uterine contractions or fetal movement, Hegar sign (softening of the junction between the corpus and cervix), and positive urine or *serum β -human chorionic gonadotropin (β -hCG)* testing.

Positive signs of pregnancy include hearing *fetal heart tones*, *sonographic visualization of a fetus*, perception of fetal movements by an external examiner, and x-ray showing a fetal skeleton.

IDENTIFICATION OF RISK FACTORS

Obstetrical history—Number of pregnancies, pregnancy duration, complications, mode of delivery, perinatal outcome.

Medical and surgical history—Diabetes mellitus, hypertension, cardiac, thyroid, seizure disorder, anemia.

Social history—Educational level, marital status, social support, abusive relationships.

Family history—Inherited diseases, mental retardation, birth defects, perinatal deaths.

Sexual history—Age of first intercourse, current partners, lifetime sexual partners, previous sexual abuse.

Lifestyle—Alcohol, tobacco, recreational drugs, poor nutrition, eating disorders.

Teratogenic exposure—*X-radiation, toxins, chemicals, prescription medications.*

PREGNANCY DURATION

Conception Dating

Normal pregnancy duration postconception is 266 days or 38 weeks. However, most women can't identify conception date accurately.

Menstrual Dating

Because the last menstrual period (LMP) is more easily identified than conception, pregnancy duration in most cases is determined to be 280 days or 40 weeks from the LMP. We assume a 28-day menstrual cycle in which ovulation occurs on day 14 after the beginning of the LMP.

Naegele's Rule

Assuming 28-day cycles, the due date can be estimated as the LMP minus 3 months plus 7 days.

PREGNANCY DATING

Basal Body Temperature (BBT)

The rise in BBT is assumed to be caused by the thermogenic effect of progesterone produced by the corpus luteum that formed after ovulation. The accuracy of BBT is ± 1 week.

Menstrual History

Menstrual dating assumes ovulation occurred on day 14 after the first day of the LMP. However, normal menstrual cycles can vary from 21 to 35 days, making ovulation possible on day 7 to day 21. Because most women's cycles are more or less than 28 days, adjustment of the due date may be necessary. Accuracy of menstrual dating is variable depending on the patient's memory and record keeping. The accuracy of menstrual history is ± 1 week.

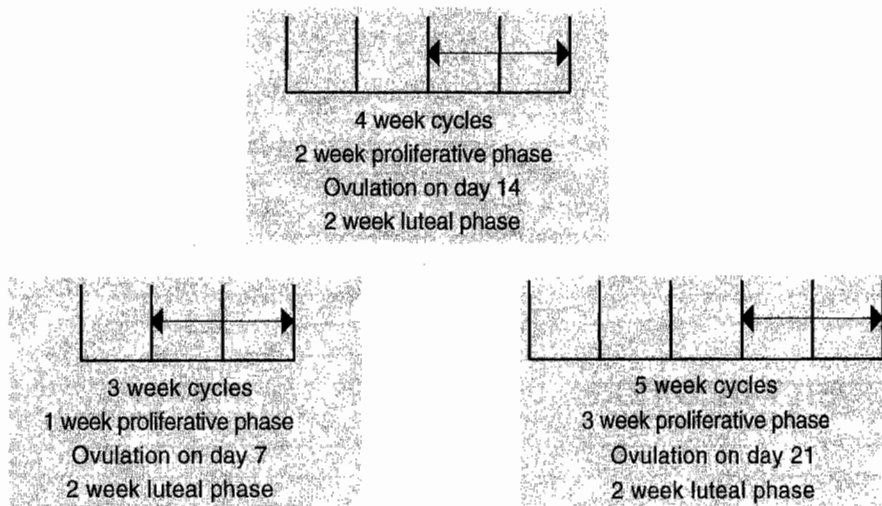


Figure 3-1. Variations in Menstrual Cycle

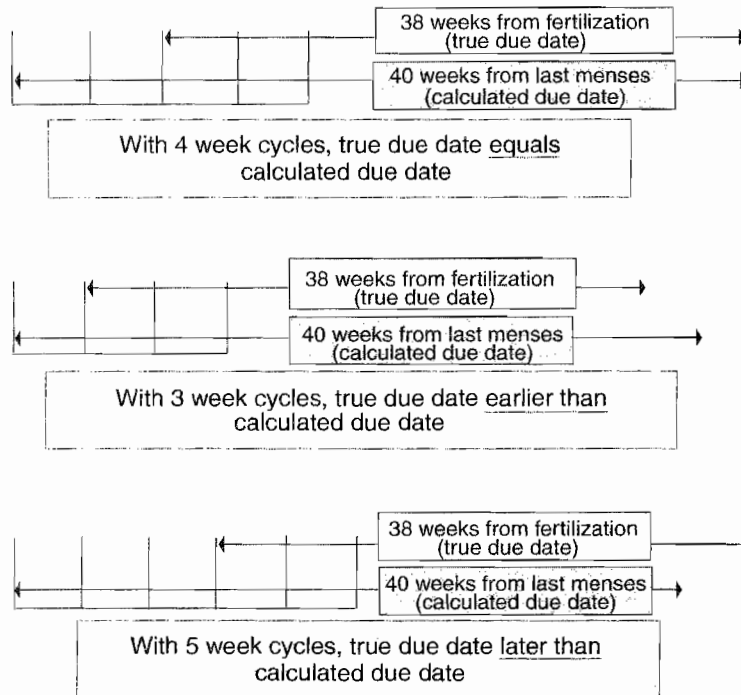


Figure 3-2. Effect of Cycle Length on Calculated Due Date

Clinical Landmarks

Fetal heart tones (FHT) are first heard by *Doppler stethoscope* at 10–12 weeks. FHT are first heard with *fetuscope* auscultation at 18–20 weeks. Maternal report of *quickening* (first perceived fetal movement) is usually at 16–18 weeks in a multipara and 18–20 weeks in a primigravida.

Uterine Fundal Height

Before 12 weeks the diameter of the uterus in centimeters on bimanual pelvic examination approximates the number of weeks' gestation. After 20 weeks, the fundal height in centimeters is assumed to parallel gestational weeks of the pregnancy. Normal variation in fundal height measurement can be ± 3 cm.

Ultrasound Dating

First-trimester sonogram dating uses measurement of the fetal *crown-rump length* (CRL). Second- and third-trimester sonogram dating uses the composite of four measurements: *biparietal diameter* (BPD), *head circumference* (HC), *abdominal circumference* (AC), and *femur length* (FL). Accuracy of sonographic dating varies by gestational age. An early sonogram has a narrower range of normal variation than one performed later in the pregnancy. A *due date based on a precisely obtained early sonogram should not be changed*. Subsequent ultrasound studies indicate the appropriateness of growth, not a change in due date.

Variation in Sonogram Accuracy

<12 weeks	±5 days
12–18 weeks	±1.0 week
18–24 weeks	±1.5 weeks
24–30 weeks	±2.0 weeks
30–36 weeks	±2.5 weeks
36–40 weeks	±3.0 weeks

TERMINOLOGY

Gravidity—the total number of pregnancies irrespective of the pregnancy duration.

Nulligravida—woman who is not currently pregnant and has never been pregnant.

Primigravida—woman who is pregnant currently for the first time.

Multigravida—woman who is pregnant currently for more than the first time.

Parity—the total number of pregnancies achieving ≥20 weeks' gestation.

Nullipara—woman who has never carried a pregnancy achieving ≥20 weeks' gestation.

Primipara—woman who has carried one pregnancy achieving ≥20 weeks' gestation.

Multipara—woman who has carried more than one pregnancy to ≥20 weeks' gestation.

Parturient—woman who is in labor.

Puerpera—woman who has just given birth.

Table 3-1. Terminology for Perinatal Losses

Terminology	Definition
Abortion	Pregnancy loss prior to 20 menstrual weeks.
Antepartum death	Fetal death between 20 menstrual weeks and onset of labor.
Intrapartum death	Fetal death from onset of labor to birth.
Fetal death	Fetal death between 20 menstrual weeks and birth.
Perinatal death	Fetal/neonatal death from 20 menstrual weeks to 28 days after birth.
Neonatal death	Newborn death between birth and the first 28 days of life.
Infant death	Infant death between birth and first year of life.
Maternal death	A woman who died during pregnancy or within 90 days of birth.

Table 3-2. Definitions of Mortality Rates

Terminology	Definition
Birth rate	Number of live births per 1000 total population.
Fertility rate	Number of live births per 1000 women ages 15–45 years.
Fetal mortality rate	Number of fetal deaths per 1000 <i>total</i> births.
Neonatal mortality rate	Number of neonatal deaths per 1000 <i>live</i> births.
Perinatal mortality rate	Number of fetal + neonatal deaths per 1000 <i>total</i> births.
Infant mortality rate	Number of infant deaths per 1000 <i>live</i> births.
Maternal mortality rate	Number of maternal deaths per 100,000 <i>live</i> births.

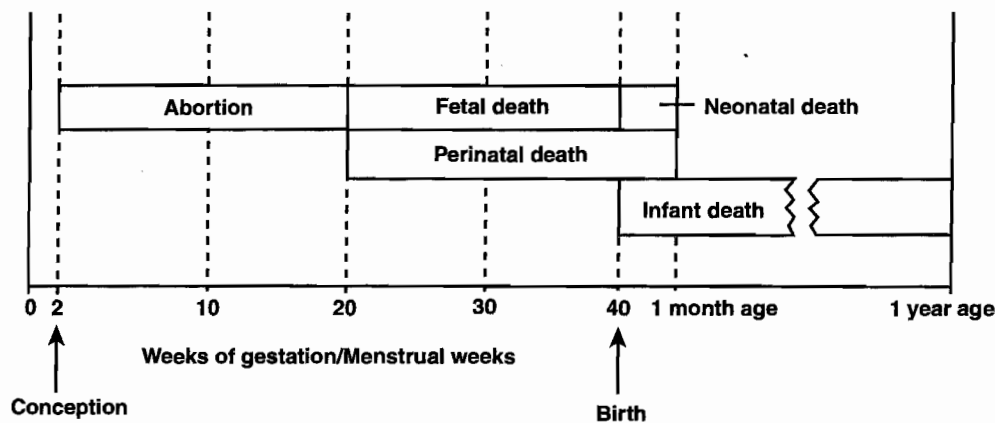


Figure 3-3. Perinatal Mortality Terminology

NORMAL PREGNANCY EVENTS

First Trimester

Assuming a 40 menstrual week pregnancy, the first trimester is assumed to extend from conception through to 13 weeks.

- *Normal symptoms* that are seen in the majority of pregnancies include nausea, vomiting, fatigue, breast tenderness, and frequent urination.
- *Spotting and bleeding*: occur in 20% of pregnancies, 50% of which will continue successfully.
- *Average weight gain is 5–8 pounds.*
- *Complications*—spontaneous abortion.

Second Trimester

Assuming a 40 menstrual week pregnancy, the second trimester is assumed to extend from 13 to 26 weeks.

- *Normal symptoms* are an improved feeling of general well-being. Round ligament pain is common.
- *Braxton-Hicks* contractions are painless, low-intensity, long-duration contractions that can be palpated as early as 14 weeks.
- *Quickening* (maternal awareness of fetal movement) is detected at 18–20 weeks by primigravidas and 16–20 weeks by multigravidas.
- *Average weight gain* is 1 pound per week after 20 weeks.
- *Complications* include incompetent cervix (painless cervical dilation leading to delivery of a nonviable fetus); premature membrane rupture, and premature labor.

Third Trimester

Assuming a 40 menstrual week pregnancy, the third trimester is assumed to extend from 26 to 40 weeks.

- *Normal symptoms* include decreased libido, lower back and leg pain, urinary frequency, and Braxton-Hicks contractions.
- *Lightening* describes descent of the fetal head into the pelvis resulting in easier maternal breathing, pelvic pressure.
- *Bloody show* describes vaginal passage of bloody endocervical mucus, the result of cervical dilation before labor.
- *Average weight gain* is 1 pound per week after 20 weeks.
- *Complications* include premature membrane rupture, premature labor, preeclampsia, urinary tract infection, anemia, and gestational diabetes.

INITIAL PRENATAL LABORATORY TESTS

A 21-year-old primigravida presents for her first prenatal visit at 11 weeks' gestation, which is confirmed by obstetric sonogram. She has no risk factors. What laboratory tests should be ordered on her?

Complete Blood Count

Hemoglobin and hematocrit

Normal pregnancy hemoglobin reference range is 10–12 g/dL. Although nonpregnant female hemoglobin reference range is 12–14 g/dL, normal values in pregnancy will reflect the dilutional effect of greater plasma volume increase than red blood cell (RBC) mass.

Mean corpuscular volume (MCV)

Because hemoglobin and hematocrit reflect pregnancy dilution, MCV may be the *most reliable predictor of true anemia*. A low hemoglobin and low MCV ($<80 \mu\text{m}^3$) most commonly suggests iron deficiency, but may also be caused by thalassemia. A low hemoglobin and high MCV (>100) suggests folate deficiency.

Platelet count

A low platelet count ($<150,000/\text{mm}^3$) is most likely indicative of idiopathic thrombocytopenic purpura or pregnancy-induced thrombocytopenia. Disseminated intravascular coagulation is rare.

Leukocyte count

White blood cell count in pregnancy is normally up to $16,000/\text{mm}^3$. Leukopenia suggests immune suppression or leukemia.

Rubella IgG Antibody

Immunity

The presence of rubella antibodies rules out a primary infection during the pregnancy. Antibodies derived from a natural, wild infection lead to lifelong immunity. Antibodies from a live-attenuated virus are not as durable.

Susceptibility

An absence of antibodies leaves the woman at risk for a primary rubella infection in pregnancy that can have devastating fetal effects, particularly in the first trimester. Rubella immunization is contraindicated in pregnancy because it is made from a live virus but is recommended after delivery.

Hepatitis B Virus (HBV)

Surface antibody

HBV surface antibodies are expected from a successful vaccination.

Surface antigen

The presence of HBV surface antigen represents either a previous or current infection. HBV surface antigen indicates *high risk for vertical transmission* of HBV from the mother to the fetus or neonate. This is the only specific hepatitis test obtained routinely on the prenatal laboratory panel.

E antigen

The presence of HBV E antigen signifies a highly infectious state.

Type, Rh, and Antibody Screen

Direct Coombs test

The patient's blood type and Rh is determined with the *direct Coombs test*. If the patient is Rh negative, she is at risk for anti-D isoimmunization.

Indirect Coombs test or atypical antibody test (AAT)

The presence of atypical RBC antibodies is determined with the indirect Coombs test. Isoimmunization is identified if atypical antibodies are present. Follow-up testing is necessary to identify whether the fetus is at risk.

STD Screening

Cervical cultures

Screening cultures for *chlamydia* and *gonorrhea* will identify whether the fetus is at risk from delivery through an infected birth canal.

Syphilis

Nonspecific screening tests (*veneral disease research laboratory* [VDRL] or *rapid plasma reagin* [RPR]) are performed on all pregnant women. Positive screening tests must be followed up with treponema-specific tests (microhemagglutination assay for antibodies to *T. pallidum* [MHA-TP] or *fluorescent treponema antibody absorption* [FTA]). Treatment of syphilis in pregnancy requires *penicillin* to ensure adequate fetal treatment.

Hepatitis B

Maternal hepatitis-B surface antigen (HBsAg) screening assesses if the mother could have active hepatitis, as well as if she could transmit HBV to her newborn at the time of delivery.

Urine Screening

Urinalysis

Assessment of proteinuria, ketones, glucose, leukocytes, and bacteria is important to screen for *underlying renal disease*, diabetes, and infection.

Culture

Screening for *asymptomatic bacteriuria* (ASB) is essential. Left untreated, 30% of ASB progresses to pyelonephritis, which is associated with septic shock, pulmonary edema, and adult respiratory distress syndrome.

Tuberculosis (TB) Screening

PPD or Tine test

This screening skin test determines *previous exposure to TB*. A positive test is induration, not erythema. If the screening test is negative, no further follow-up is necessary. TB screening is *not done routinely* but only on high-risk populations.

Chest x-ray (CXR)

A CXR is performed to rule out active disease only if the screening skin test is positive. If the CXR is negative, isoniazid (INH) (and vitamin B₆) is given for 6 months. If the CXR is positive, induced sputum is cultured and triple medications begun until cultures define the organisms involved. Antituberculosis drugs are not contraindicated in pregnancy.

HIV Screening

Screening

HIV screening is *recommended for all pregnant women*, but requires a specific consent. The most common risk factor for HIV in women is heterosexual contact with an IV drug abuser.

ELISA test

This *screening test* assesses presence of detectable HIV antibodies. A 3-month lag exists between HIV infection and a positive ELISA test. All babies born to HIV-positive women will be HIV antibody positive from passive maternal antibodies.

Western blot test

This *definitive test* identifies the presence of HIV core and envelope antigens. Zidovudine is recommended for all HIV-positive women starting at 14 weeks and continuing through delivery. Perinatal vertical transmission is reduced from 30% to 8%.

Cervical Pap smear

Cervical cytologic screening is performed to identify if the mother has cervical dysplasia or malignancy.

MID-TRIMESTER PRENATAL LABORATORY TESTS

A 23-year-old woman (G3 P1 Ab1) is seen at 16 weeks' gestation. Her previous pregnancy resulted in an anencephalic fetus that did not survive. She took 4 mg of folate preconception before this pregnancy but wants to know whether this fetus is affected.

Maternal Serum α -Fetoprotein (MS-AFP)

AFP

This is the *major serum glycoprotein* of the embryo. The concentration peaks at 12 weeks in the fetus and amniotic fluid (AF), then rises until 30 weeks in the maternal serum. Fetal structural defects (open neural tube defect [NTD] and ventral wall defects) result in increased spillage into the amniotic fluid and maternal serum. Other causes include twin pregnancy, placental bleeding, fetal renal disease, and sacrococcygeal teratoma.

MS-AFP

MS-AFP is reported in multiples of the median (MoM). Maternal serum testing is performed within a gestational window of 15–20 weeks. Because reference ranges are specific to gestational age, accurate pregnancy dating is imperative.

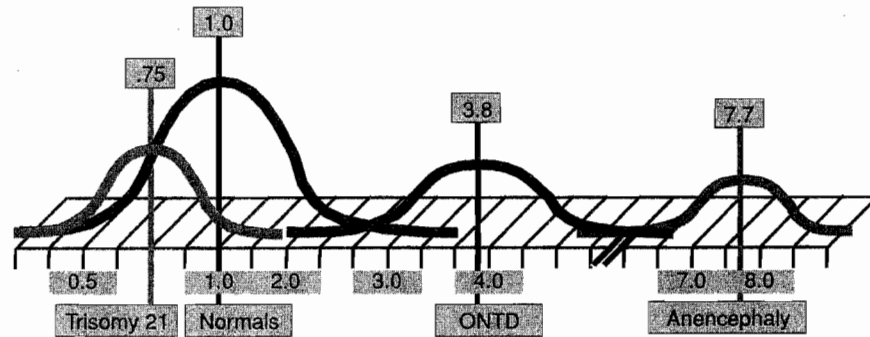


Figure 3-4. Midpoints of MSAFP

Elevated MS-AFP

A positive high value is $>2.5 MoM$. The next step in management is to obtain an obstetric ultrasound to confirm gestational dating. The *most common* cause of an elevated MS-AFP is *dating error*.

- If the true gestational age is more advanced than the assumed gestational age, it would explain the positive high value. In cases of dating error, repeat the MS-AFP if the pregnancy is still within the 15- to 20-week window. A normal MS-AFP will be reassuring.
- If the dates are correct and no explanation is seen on sonogram, perform amniocentesis for *AF-AFP* determination and acetylcholinesterase activity. Elevated levels of *AF acetylcholinesterase* activity are specific to open NTD.
- With unexplained elevated MS-AFP but normal *AF-AFP*, the pregnancy is statistically at risk for intrauterine growth retardation (IUGR), stillbirth, and preeclampsia.

Low MS-AFP

A positive low value is $<0.85 MoM$. The sensitivity of MS-AFP for trisomy 21 is only 20%. If no triple marker screen testing is available, the next step in management is to obtain an obstetric ultrasound to confirm gestational dating. The *most common* cause of a low MS-AFP is *dating error*.

- If the true gestational age is less than the assumed gestational age, it would explain the positive low value. In cases of dating error, repeat the MS-AFP if the pregnancy is still within the window. A normal MS-AFP will be reassuring.
- If the dates are correct and no explanation is seen on sonogram, perform amniocentesis for *karyotype*.

Triple Marker Screen

Trisomy screening

The sensitivity for trisomy 21 detection can be increased to 60% by performing maternal serum screen for not only *MS-AFP*, but also *hCG* and *estriol*. The window for testing is also 15–20 weeks. Because reference values are gestational age specific, accurate dating is important.

Trisomy 21

With Down syndrome, levels for *MS-AFP* and *estriol* are decreased, but *hCG* is increased. Perform an amniocentesis for *karyotype*.

Trisomy 18

With Edward syndrome, levels for *all three markers* (MS-AFP, estriol, and hCG) are decreased. Perform an amniocentesis for *karyotype*.

THIRD-TRIMESTER PRENATAL LABORATORY TESTS

A 33-year-old woman (G4 P3) is at 25 weeks' gestation. Her height is 63 inches and she weighs 250 pounds. She has gained 30 pounds thus far this pregnancy. With her last pregnancy she gained 60 pounds, was diagnosed with gestational diabetes, and delivered a 4,300-g female neonate by cesarean section. She wants to know whether she has diabetes with this pregnancy.

Diabetic Testing

1-h 50-g Oral glucose tolerance test (OGTT)

This *screening test* is administered to all pregnant women between 24 and 28 weeks' gestation. No fasting state is needed. A 50-g glucose load is given, and serum glucose is measured 1 h later. A *normal value* is <140 mg/dL. Fifteen percent of pregnant women will have an abnormal screening test, which is a value of ≥ 140 mg/dL. The next step in management is a 3-h 100-g OGTT.

3-h 100-g OGTT

This is the *definitive test* for glucose intolerance in pregnancy. Fifteen percent of women with an abnormal screening test will be found to have gestational diabetes mellitus. After an overnight fast, a fasting blood sugar (FBS) is drawn. An FBS >125 mg/dL indicates overt diabetes mellitus, and no further testing is performed. If the FBS is <126 mg/dL, administer a 100-g glucose load, followed by glucose levels at 1, 2, and 3 h. Normal values are FBS <95 mg/dL, 1 h <180 mg/dL, 2 h <155 mg/dL, and 3 h <140 mg/dL. *Gestational diabetes is diagnosed if two or more values are abnormal*. Impaired glucose intolerance is diagnosed if only one value is abnormal.

Complete Blood Count (CBC)

Anemia

A CBC should be performed between 24 and 28 weeks' gestation in all women. With the increasing diversion of iron to the fetus in the second and third trimester, iron deficiency, which was not present early in pregnancy, may develop. This is particularly so in the woman who is not taking iron supplementation. A hemoglobin <10 g/dL is considered anemia. *The most common cause is iron deficiency*, which occurs only after bone marrow iron stores are completely depleted.

Platelet count

Reassessment of pregnancy-induced thrombocytopenia can be also be done with the CBC.

Atypical Antibody Screen

Before giving prophylactic RhoGAM to an Rh-negative woman, an indirect Coombs test is performed at 28 weeks. This is obtained to ensure she has not become isoimmunized since her previous negative AAT earlier in pregnancy. Two tenths of a percent of Rh-negative women will become

isoimmunized from spontaneous feto-maternal bleeding before 28 weeks. If it is discovered that the patient already has anti-D antibodies, administration of RhoGAM is futile.

ANTENATAL FETAL TESTING

A 37-year-old multipara with systemic lupus erythematosus is at 31 weeks' gestation. She has chronic hypertension that is being controlled with methyldopa. She comes to the office stating her fetus is not moving as much as it used to.

Overview

Antenatal fetal tests are highly accurate in confirming fetal well-being, but poor predictors of fetal jeopardy.

Most common reasons for fetal testing are *decreased fetal movements*, diabetes, post dates, chronic hypertension, and IUGR.

Nonstress Test (NST)

This test assesses the frequency of fetal movements and uses an external fetal heart rate (FHR) monitoring device to detect the presence or absence of *accelerations*. These are *abrupt* increases in FHR above the baseline lasting <2 min and are unrelated to contractions. The criteria vary by gestational age: <32 weeks, the increase should be ≥ 10 beats/min lasting ≥ 10 s; 32 weeks, the increase should be ≥ 15 beats/min lasting ≥ 15 s. They are mediated by the *sympathetic* nervous system and always occur in response to *fetal movements*. *Interpretation: Accelerations are always reassuring.*

- **Reactive NST**—This requires the presence of *two accelerations in a 20-min* window of time meeting the above criteria. This is *reassuring* and highly predictive for fetal well-being. Fetal death rate is only 3 per 1,000 in the next week. *Management* is to repeat the NST weekly.
- **Nonreactive NST**—This is diagnosed when any criteria for reactivity are not met: either the number of accelerations in 20 min or the amplitude or duration of the acceleration. Eighty percent of nonreactive NSTs are false positives (meaning the fetus is not hypoxemic). Nonhypoxemic causes include fetal sleep, prematurity, drug effects, and CNS anomalies. *Management* is to perform fetal *vibroacoustic stimulation* to see whether this results in reactivity. If the NST is persistently nonreactive, then perform a biophysical profile.

Four-Quadrant Amniotic Fluid Index

This test assesses in centimeters the deepest single vertical amniotic fluid pocket in each of the four quadrants of the uterus. The sum of the pockets is known as the amniotic fluid index, or AFI. Interpretation is as follows:

- <5 cm—oligohydramnios
- 5–8 cm—borderline
- 9–25 cm—normal
- >25 cm—polyhydramnios

Biophysical Profile (BPP)

This test measures *five components of fetal well-being*: NST, amniotic fluid volume, fetal gross body movements, fetal extremity tone, and fetal breathing movements. The last four components are assessed using obstetric ultrasound. Scores given for each component are 0 or 2, with maximum possible score of 10 and minimum score of 0.

- **Score of 8 or 10**—This is highly *reassuring* of fetal well-being. Management is to repeat the test weekly or as indicated.
- **Score of 4 or 6**—This is *worrisome*. Management is delivery if the fetus is ≥ 36 weeks or repeat the biophysical profile in 12–24 h if < 36 weeks. An alternative is to perform a CST.
- **Score of 0 or 2**—This is highly predictive of fetal *hypoxia* with low probability of false positive. Management is prompt delivery regardless of gestational age.

A modified BPP includes only the NST and amniotic fluid volume. Its predictive value is almost as high as a complete BPP.

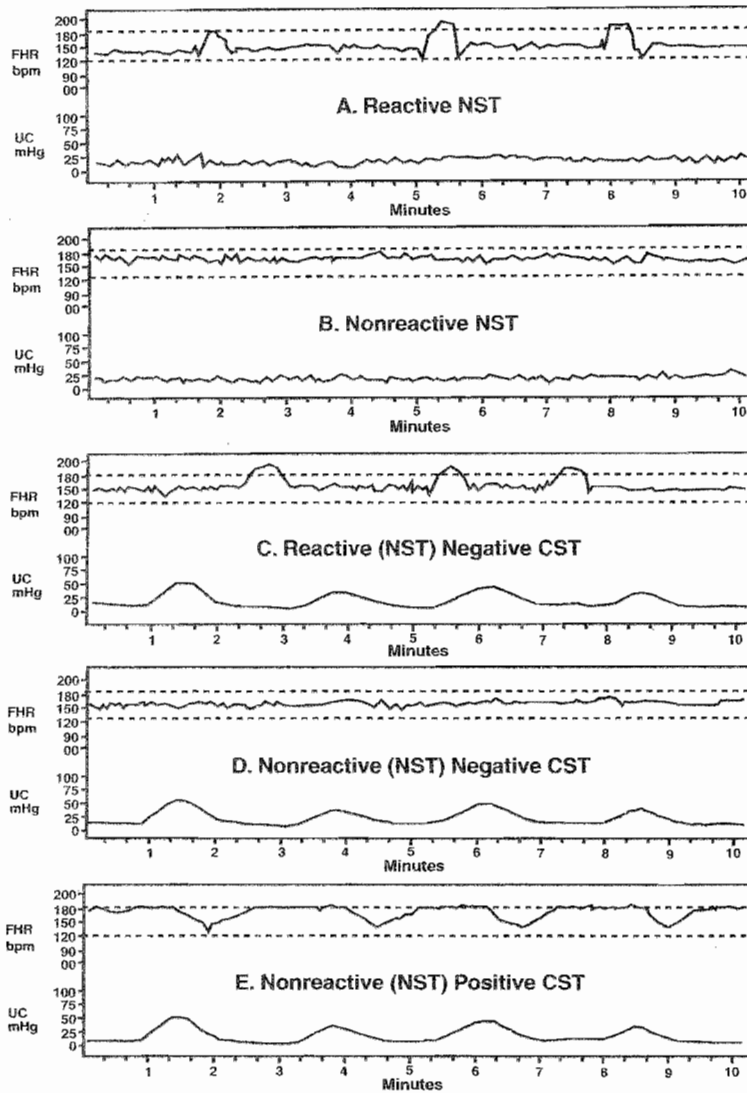


Figure 3-5. Antepartum Electronic Fetal Monitor (EFM) Tracings

All EFM tracings should be evaluated for two components: the nonstress test (NST) and the contraction stress test (CST). If a technically adequate fetal heart rate (FHR) tracing is present, the NST component can be assessed as reactive or nonreactive. If three or more uterine contractions (UCs) are present in 10 minutes, the CST components can be assessed as negative or positive. (A) The EFM tracing shows a normal baseline range, and no UCs are present. Thus, only the NST component can be assessed. Because three accelerations are present, the assessment is reactive NST. **This is a reassuring tracing.** (B) The EFM tracing shows a normal baseline range, and no UCs are present. Thus, only the NST component can be assessed. Because no accelerations are present, the assessment is nonreactive NST. **Because this is not a reassuring tracing, the next step should be a vibroacoustic fetal stimulation.** (C) The EFM tracing shows a normal baseline range, and four UCs are present in 10 minutes. Thus, both the NST and CST components can be assessed. Because three accelerations are present, and no late decelerations are present, the assessment is reactive NST, negative CST. **This is a reassuring tracing.** (D) The EFM tracing shows a normal baseline range, and four UCs are present in 10 minutes. Thus, both the NST and CST components can be assessed. Even though no accelerations can be seen, no late decelerations are present. The assessment is nonreactive NST, negative CST. **This suggests fetal sleep, sedation, or central nervous system (CNS) abnormality.** (E) The EFM tracing shows an elevated baseline range, and four UCs are present in 10 minutes. Thus, both the NST and CST components can be assessed. No accelerations can be seen, but repetitive late decelerations are present. The assessment is nonreactive NST, positive CST. **This is highly suggestive of fetal compromise.**

Contraction Stress Test (CST)

This test assesses the ability of the fetus to tolerate transitory decreases in intervillous blood flow that occur with uterine contractions. It uses both external FHR and contraction monitoring devices and is based on the presence or absence of *late decelerations*. These are *gradual* decreases in FHR below the baseline with onset to nadir of ≥ 30 s. The deceleration onset and end is *delayed* in relation to contractions. If three contractions in 10 min are not spontaneously present, they may be induced with either IV oxytocin infusion or nipple stimulation. *This test is rarely performed because of the cost and the personnel time required.* The *most common* indication is a BPP of 4 or 6.

- **Negative CST**—This requires absence of any late decelerations with contractions. This is *reassuring* and highly reassuring for fetal well-being. Management is to repeat the CST weekly.
- **Positive CST**—This is *worrisome*. This requires the presence of late decelerations associated with at least 50% of contractions. Fifty percent of positive CSTs are false positive (meaning the fetus is not hypoxemic). They are associated with good FHR variability. The 50% of true positives are associated with poor or absent variability. Management is delivery if the fetus is ≥ 36 weeks.
- **Contraindications**—A CST should not be performed whenever contractions would be hazardous to the mother or fetus. Examples include previous classical uterine incision, previous myomectomy, placenta previa, incompetent cervix, preterm membrane rupture, and preterm labor.

Umbilical Artery Doppler

This test measures the ratio of systolic and diastolic blood flow in the umbilical artery. The umbilical circulation normally has low resistance, so diastolic blood flow is expected. The systolic/diastolic (S/D) ratio normally increases throughout pregnancy. This test is predictive of poor perinatal outcome only in IUGR fetuses. Nonreassuring findings, which may indicate need for delivery, are *absent* diastolic flow and *reversed* diastolic flow.

Perinatal Infections

4

GROUP B β -HEMOLYTIC STREPTOCOCCI (GBBS)

A 20-year-old woman G2 P1 is admitted to the birthing unit at 35 weeks' gestation in active labor at 6-cm dilation. Her prenatal course was unremarkable with the exception of a positive first-trimester urine culture that was positive for GBBS. Her first baby was hospitalized for 10 days after delivery for GBBS pneumonia.

Pathophysiology. GBBS is a bacterium commonly found in normal GI tract flora. Thirty percent of women have asymptomatic *vaginal colonization* with GBBS, with the majority having intermittent or transient carrier status. Most neonates delivered to colonized mothers will be culture positive.

Significance. One in 500 neonates will develop serious clinical infections or sepsis.

- *Early onset* infection is the *most common* finding, occurring within a few hours to days of birth, and is characterized by fulminant *pneumonia and sepsis*. This is usually vertical transmission from mother to neonate with a *50% mortality rate*.
- *Late-onset* infection is less common, occurring after the first week of life, and is characterized by meningitis. This is usually hospital acquired, with a *25% mortality rate*.

Prevention. Intrapartum antibiotic prophylaxis of neonatal GBBS sepsis is given with IV penicillin G. If the patient is penicillin allergic, use clindamycin or erythromycin. *Candidates for antibiotic prophylaxis are selected as follows:*

- *No screening*—All women with a positive GBBS urine culture or a previous baby with GBBS sepsis will receive intrapartum prophylaxis. Prophylaxis of other women is based on either of the following two protocols, each of which will prevent 70% of neonatal sepsis.
- *Screening by vaginal culture*—Third-trimester vaginal cultures are obtained, and intrapartum prophylaxis is administered only to those with positive GBBS cultures. Antepartum treatment is not given.
- *Screening by intrapartum risk factors*—No vaginal cultures are obtained. Intrapartum prophylaxis is given on the basis of risk factors being present: preterm gestation, membranes ruptured >18 h, or maternal fever.

TOXOPLASMA GONDII

A 26-year-old primigravida was admitted to the birthing unit at 39 weeks' gestation in active labor at 6-cm dilation. During her second trimester she experienced a mononucleosis-like syndrome. Uterine fundal growth lagged behind that expected on the basis of a first-trimester sonogram. Serial sonograms showed symmetrical intrauterine growth retardation (IUGR). She delivered a 2,250-g male neonate who was diagnosed with microcephaly, intracranial calcifications, and chorioretinitis.

Pathophysiology

- Toxoplasmosis is caused by a *parasite* transmitted *most commonly* in the United States from exposure to an infected *cat's feces*. Infections can also occur from drinking raw goat milk or eating raw or undercooked infected meat.
- *Vertical transmission* from mother to fetus or neonate can only occur during the parasitemia of a *primary infection* because the result is residual *lifelong immunity*.
- Up to 40% of pregnant women are toxoplasmosis IgG seropositive.
- First-trimester infection risk is *low* (15%), but infections are *most serious*, even lethal.
- Third-trimester infection risk is *high* (65%), but infections are *mostly asymptomatic*.

Significance

- *Fetal infection*—Manifestations may include symmetric IUGR, nonimmune fetal hydrops, microcephaly, and *intracranial calcifications*.
- *Neonatal infection*—Manifestations may include *chorioretinitis*, seizures, hepatosplenomegaly, and thrombocytopenia.

Prevention. Avoid infected cat feces, raw goat milk, and undercooked meat.

Treatment. Pyrimethamine and sulfadiazine.

VARICELLA

A 29-year-old woman (G2 P1) is at 34 weeks' gestation. She complains of uterine contractions every 5 min. During the last few days she has developed diffuse pruritic vesicles on her neck that appear to be also developing on her chest and breasts. She has a fever and complains of malaise.

Pathophysiology. Varicella is a DNA virus that is the causative agent of chicken pox and herpes zoster. It is spread by *respiratory droplets*, but is less contagious than rubeola or rubella. More than 90% of women are immune by adulthood.

Significance

- *Fetal infection*—Transplacental infection rate is as high as 25–40%.
- *Neonatal infection*—Congenital varicella syndrome is characterized by “zigzag” skin lesions, microphthalmia, cataracts, chorioretinitis, extremity hypoplasia, and motor and sensory defects. The greatest neonatal risk is if maternal rash appears between 5 days antepartum and 2 days postpartum.

- *Maternal infection*—Ten percent of patients with varicella will develop *varicella pneumonia*, which has a high maternal morbidity and mortality. Communicability begins 1–2 days before vesicles appear and lasts until all vesicles are crusted over. Pruritic vesicles begin on the head and neck, progressing to the trunk. The infection can trigger labor.

Prevention. Administer VZIG (varicella zoster immune globulin) to a susceptible gravida within 96 h of exposure. Live-attenuated varicella virus (Varivax III) can be administered to nonpregnant or postpartum to varicella IgG-antibody–negative women.

Treatment. Administer IV antiviral treatment with *acyclovir* for varicella pneumonia.

RUBELLA

An 18-year-old primigravida is at 30 weeks' gestation and is employed in a childcare center. One of the children had a rash that was diagnosed as rubella. The patient's rubella IgG titer is negative. She is concerned about the possibility of her fetus getting infected with rubella.

Pathophysiology

- Rubella is a highly contagious RNA virus that is spread by *respiratory droplets*. Up to 85% of pregnant women are rubella IgG seropositive.
- *Vertical transmission* from mother to fetus or neonate can only occur during the viremia of a *primary infection* because the result is residual *lifelong immunity*.

Significance

- *Fetal infection*—Transplacental infection rate is >90% in the first 10 weeks of pregnancy, but 5% in the third trimester. Manifestations may include symmetric IUGR, microcephaly, or ventriculoseptal defect (VSD).
- *Neonatal infection*—Congenital rubella syndrome is characterized by *congenital deafness* (most common sequelae), *congenital heart disease*, *cataracts*, mental retardation, hepatosplenomegaly, thrombocytopenia, and “blueberry muffin” rash.
- *Maternal infection*—Rubella infection during pregnancy is generally a mild, low-morbidity condition.

Prevention. All pregnant women should undergo rubella IgG antibody screening. Rubella-susceptible women should avoid known rubella cases, then receive active immunization after delivery. Because rubella vaccine is made using a live attenuated virus, pregnancy should be avoided for 1 month after immunization.

Treatment. No specific treatment.

CYTOMEGALOVIRUS (CMV)

A 31-year-old neonatal intensive care unit nurse has just undergone an uncomplicated term spontaneous vaginal delivery of a 2,300-g female neonate with a diffuse petechial rash. At 12 weeks' gestation she experienced a flulike syndrome with right upper quadrant pain. Obstetric sonograms showed fetal growth was only at the fifth percentile.

Pathophysiology. CMV is a DNA herpes virus that is spread by infected *body secretions*. Up to 50% of pregnant women are CMV IgG seropositive.

Vertical transmission from mother to fetus or neonate occurs mainly during the viremia of a primary infection. However, because the result of primary infection is predisposition to a residual lifelong latency, fetal infection can occur with reactivation.

Significance

- *Fetal infection*—Transplacental infection rate is 50% with maternal primary infections regardless of the pregnancy trimester, but <1% with recurrent infections. Manifestations may include nonimmune hydrops, symmetric IUGR, microcephaly, and cerebral calcifications.
- *Neonatal infection*—From 1 to 2% of newborns have evidence of *in utero* exposure to CMV. Congenital CMV syndrome is the *most common congenital viral syndrome* in the United States. Only 10% of infected infants have clinical disease, which includes *petechiae*, meningoencephalitis, hepatosplenomegaly, thrombocytopenia, and jaundice.
- *Maternal infection*—CMV infection during pregnancy is generally a mild, low-morbidity condition appearing as a mononucleosis-like syndrome with hepatitis.

Prevention. Follow universal precautions with all body fluids. Avoid transfusion with CMV-positive blood.

Treatment. Antiviral therapy with *ganciclovir*.

HERPES SIMPLEX VIRUS (HSV)

A 21-year-old multipara was admitted to the birthing unit at 39 weeks' gestation in active labor at 6-cm dilation. The bag of waters is intact. She has a history of genital herpes before the pregnancy. Her last outbreak was 8 weeks ago. She now complains of vaginal lesions. On examination she had localized, painful, ulcerative lesions on her right vaginal wall.

Pathophysiology

- HSV is a DNA herpes virus that is spread by intimate *mucocutaneous contact*. Up to 50% of pregnant women are HSV IgG seropositive.
- Most genital herpes results from HSV II, but can also occur with HSV I.
- Transplacental transmission from mother to fetus can occur with viremia during the primary infection but is rare. HSV infection predisposes to a residual lifelong latency with periodic recurrent attacks. The *most common route of fetal infection* is contact with *maternal genital lesions* during a recurrent HSV episode.

Diagnosis. The definitive diagnosis is a positive HSV culture from fluid obtained from a ruptured vesicle or debrided ulcer.

Significance

- *Fetal infection*—The transplacental infection rate is 50% with maternal primary infections. Manifestations may include spontaneous abortions, symmetric IUGR, microcephaly, and cerebral calcifications.
- *Neonatal infection*—With passage through an HSV-infected birth canal, the neonatal attack rate is 50% with a primary infection, but <5% with a recurrent infection. Neonatal mortality rate is 50%. Those who survive have severe sequelae: meningoencephalitis, mental retardation, pneumonia, hepatosplenomegaly, jaundice, and petechiae.
- *Maternal infection*—This can be of two types:
 - *Primary herpes* results from a viremia and has systemic manifestations: fever, malaise, adenopathy, and diffuse genital lesions (vagina, cervix, vulva, and urethra). Transplacental fetal infection is possible.
 - *Recurrent herpes* results from migration of the virus from the dorsal root ganglion but is localized and less severe with no systemic manifestations. Fetal infection results only from passing through a birth canal with lesions present.

Prevention. A cesarean section should be performed in the presence of genital HSV lesions at the time of labor. If membranes have been ruptured >8–12 h, the virus may already have infected the fetus.

Treatment. Acyclovir.

HUMAN IMMUNODEFICIENCY VIRUS (HIV)

A 22-year-old multigravida is a former IV drug user. She was diagnosed as HIV positive 12 months ago during her previous pregnancy. She underwent vaginal delivery of an infant who is also HIV positive. She is now pregnant again at 15 weeks' gestation.

Pathophysiology

- *HIV*—This is an RNA retrovirus that is spread by infected *body secretions*. Sharing contaminated needles, having sexual intercourse with an infected partner, and perinatal transmission are the most common ways of transmission.
- *AIDS*—The infected patient develops acquired immunodeficiency syndrome (AIDS). The clinical course from HIV to AIDS is a gradual but relentless immunosuppression during a period of years, resulting in death caused by overwhelming infection from opportunistic diseases.

Significance

- *Fetal infection*—Transplacental infection occurs, but the major route of vertical transmission is contact with infected genital secretions at the time of vaginal delivery. Without maternal azidothymidine (AZT) prophylaxis, the vertical transmission rate is 30%, but with AZT the infection rate is lowered to 10% with vaginal delivery. With elective cesarean section without labor and before membrane rupture, the perinatal infection rate may be <5%. The greatest benefit to the fetus of cesarean delivery is probably in women with low CD4 counts and high RNA viral loads.

- *Neonatal infection*—At birth neonates of HIV-positive women will have positive HIV tests from transplacental passive IgG passage. HIV-infected breast milk can potentially transmit the disease to the newborn. Progression from HIV to AIDS in infants is more rapid than in adults.
- *Maternal infection*—Pregnancy in an HIV-positive woman does not enhance progression to AIDS.

Prevention

- *Antiviral prophylaxis*—All HIV-positive gravidas should be receiving AZT prophylaxis, which is continued from 14 weeks' gestation throughout pregnancy, including delivery.
- *Mode of delivery*—Cesarean section is currently offered to all HIV-positive women. Which mode of delivery is optimal for HIV-positive patients may be clarified by future research. Guidelines for vaginal delivery: avoid amniotomy as long as possible, do not use scalp electrodes in labor, avoid forceps or vacuum extractor operative delivery, and use gentle neonatal resuscitation.
- *Breast feeding*—This is probably best avoided in HIV-positive women.
- *Universal precautions*—Pay careful attention to handling of all body fluids.

Treatment. Women with low CD4 counts and high RNA viral loads should be receiving multidrug antiviral regimens.

SYPHILIS

A 34-year-old multigravida presents for prenatal care in the second trimester. She admits to a past history of substance abuse but states she has been clean for 6 months. With her second pregnancy she experienced a preterm delivery at 34 weeks gestation of a male neonate who died within the first day of life. She states that at delivery the baby was swollen with skin lesions and that the placenta was very large. She was treated with antibiotics but she does not remember the name or other details. On a routine prenatal panel with this current pregnancy she is found to have a positive VDRL test.

Pathophysiology

Syphilis is caused by *Treponema pallidum*, a motile anaerobic spirochete. Syphilis does not result in either a state of immunity or latency. The infection can be eradicated by appropriate treatment, but reinfection can occur over and over again. It is spread as a sexually transmitted disease by intimate contact between moist mucous membranes or congenitally through the placenta to a fetus from an infected mother.

Significance

Fetal infection

Transplacental infection is common with vertical transmission rates of 60% in primary and secondary syphilis. The rate of fetal infection with latent or tertiary syphilis is lower. Without treatment, manifestations of early congenital syphilis include nonimmune hydrops, macerated skin, anemia, thrombocytopenia, and hepatosplenomegaly. Fetal death rates are high, with perinatal mortality rates approaching 50%. The placenta is typically large and edematous.

Neonatal infection

Late congenital syphilis is diagnosed after 2 years of age and includes “Hutchinson” teeth, “mulberry” molars, “saber” shins, “saddle” nose, and 8th nerve deafness.

Maternal infection

This can be of four types:

- *Primary syphilis* is the first stage after infection. Painless ulcers with rolled edges (*chancres*) appear two to three weeks after contact at the site of infection, most commonly the vulva, vagina, or cervix. Darkfield microscopy of lesion exudate is positive for the spirochete, but the nonspecific serologic tests (Venereal Disease Research Laboratory [VDRL] or rapid plasma reagin [RPR] test) are not yet positive. Without treatment the chancre spontaneously disappears.
- *Secondary syphilis* is characterized by systemic spirochetemia. Two to three months after contact, fever, malaise, general adenopathy, and a maculopapular skin rash (“money spots”) are seen. Broad exophytic excrescences (*condyloma lata*) appear on the vulvar. These physical findings also spontaneously disappear without treatment. Darkfield microscopy of condyloma exudate is positive for treponema. The VDRL or RPR test will be positive, but a diagnosis of syphilis must be confirmed with a treponema-specific test, such as the fluorescent titer antibody absorption (FTA-ABS) or microhemagglutination assay for antibodies to *T. pallidum* (MHA-TP).
- *Latent syphilis* is characterized by absence of symptoms or physical findings. One third of cases proceed to tertiary disease. The nonspecific and treponema-specific tests remain positive.
- *Tertiary syphilis* is a symptomatic stage with symptoms dependent on which organ system is affected by the classic necrotic, ulcerative nodules (*gummas*). Lesion location may include the cardiovascular system (aortitis, saccular aneurysms), CNS (meningitis, tabes dorsalis, dementia, ataxia), or bone (osteitis). Not only are the blood tests positive, but the cerebrospinal fluid will be positive with CNS involvement.

Prevention

Mode of delivery

Vaginal delivery is appropriate with cesarean section only for obstetric indications.

STD prevention guidelines

Follow the principles of avoiding multiple sexual partners, and promote use of barrier contraceptives.

Treatment

Benzathine penicillin 2.4 million units IM $\times 1$ is given in pregnancy to ensure adequate antibiotic levels in the fetus. Other antibiotics do not cross the placenta well. Even if the gravida is penicillin allergic, she should still be given a full penicillin dose using an oral desensitization regimen under controlled conditions.

HEPATITIS B (HBV)

A 29-year-old multigravida was found on routine prenatal laboratory testing to be positive for hepatitis B surface antigen. She is an intensive care unit nurse. She received 2 units of packed red blood cells two years ago after experiencing postpartum hemorrhage with her last pregnancy.

Pathophysiology

Hepatitis B is a DNA virus that is spread by infected body secretions. Sharing contaminated needles, having sexual intercourse with an infected partner, and perinatal transmission are the most common ways of transmission. Vertical transmission accounts for 40% of all chronic HBV infections. Most HBV infections are asymptomatic.

Significance

Fetal infection

Transplacental infection is rare, occurring mostly in the third trimester. The main route of fetal or neonatal infection arises from exposure to or ingestion of infected genital secretions at the time of vaginal delivery. There is no perinatal transmission risk if the mother is positive for HBV surface antibodies but negative for HBV surface antigen.

Neonatal infection

Neonatal HBV develops in only 10% of mothers positive for HBsAg but in 80% of those positive for both HBsAg and HBeAg. Of those neonates who get infected, 80% will develop chronic hepatitis, compared with only 10% of infected adults.

Maternal infection.

This can be of three types.

- *Asymptomatic HBV.* The majority of all infected patients fall into this category with no impact on maternal health. Hepatitis B surface antigen (HBsAg) is the screening test used for identifying existing infection and is obtained on all pregnant women. A positive HBsAg test is followed up with a complete hepatitis panel and liver enzymes assessing for active or chronic hepatitis.
- *Acute hepatitis.* Acute and chronic HBV infections can result in right upper quadrant pain and lethargy varying according to the severity of the infection. Laboratory studies show elevated bilirubin and high liver enzymes. The majority of patients with acute hepatitis will recover normal liver function.
- *Chronic hepatitis.* Cirrhosis and hepatocellular carcinoma are the most serious consequences of chronic hepatitis.

Prevention

Mode of delivery

Vaginal delivery is indicated with cesarean section only for obstetric indications.

Vertical transmission

Avoid scalp electrodes in labor as well as scalp needles in the nursery. Neonates of HBsAg-positive mothers should receive passive immunization with hepatitis B immunoglobulin (HBIG) and active immunization with hepatitis B vaccine. Breast-feeding is acceptable after the neonate has received the active immunization and HBIG.

Maternal immunization

HBsAg-negative mothers at high risk for hepatitis B should receive HBIG passive immunization. Active immunization is safe in pregnancy because the agent is a killed virus.

Treatment

There is no specific therapy for acute hepatitis. Interferon is used for life-threatening cases.

Pregnancy Bleeding

5

LATE PREGNANCY BLEEDING

Definition. Vaginal bleeding occurring after 20 weeks' gestation. Prevalence is <5%, but when it does occur, prematurity and perinatal mortality quadruple.

Etiology

- *Cervical* causes include erosion, polyps, and, rarely, carcinoma.
- *Vaginal* causes include varicosities and lacerations.
- *Placental* causes include abruptio placenta, placenta previa, and vasa previa.

Initial Evaluation. What are patient's vital signs? Are fetal heart tones present? What is fetal status? What is the nature and duration of the bleeding? Is there pain or contractions? What is location of placental implantation?

Initial Investigation. Complete blood count, disseminated intravascular coagulation (DIC) workup (platelets, prothrombin time, partial thromboplastin time, fibrinogen, *D-dimer*), type and cross-match, and sonogram for placental location. *Never perform a digital or speculum examination until ultrasound study rules out placenta previa.*

Initial Management. Start an IV line with a large-bore needle; if maternal vital signs are unstable, run isotonic fluids without dextrose wide open and place a urinary catheter to monitor urine output. If fetal jeopardy is present or gestational age is ± 36 weeks, the goal is delivery.

ABRUPTIO PLACENTA

A 32-year-old multigravida at 31 weeks' gestation is admitted to the birthing unit after a motor-vehicle accident. She complains of sudden onset of moderate vaginal bleeding for the past hour. She has intense, constant uterine pain and frequent contractions. Fetal heart tones are regular at 145 beats/min. On inspection her perineum is grossly bloody.

Etiology/Pathophysiology

- A *normally implanted* placenta (not in the lower uterine segment) separates from the uterine wall before delivery of the fetus. Separation can be partial or complete.
- Most commonly bleeding is *overt* and *external*. In this situation blood dissects between placental membranes exiting out the vagina.

- Less commonly, if bleeding remains *concealed* or *internal*, the retroplacental hematoma remains within the uterus, resulting in an increase in fundal height over time.

Diagnosis. This is based on the presence of *painful* late-trimester vaginal bleeding with a *normal* fundal or lateral uterine wall *placental implantation* not over the lower uterine segment.

Clinical Presentation. Abruption placenta is the *most common cause of late-trimester bleeding*, occurring in 1% of pregnancies at term. It is the *most common cause* of painful late-trimester bleeding.

Classification

- With *mild abruption*, vaginal bleeding is moderate with no fetal monitor abnormality. Localized uterine pain and tenderness is noted, with incomplete relaxation between contractions.
- With *moderate abruption*, symptoms of uterine pain and moderate vaginal bleeding can be gradual or abrupt in onset. From 25 to 50% of placental surface is separated. Fetal monitoring may show tachycardia, decreased variability, or mild late decelerations.
- With *severe abruption*, symptoms are usually abrupt with a continuous knifelike uterine pain. Greater than 50% of placental separation occurs. Fetal monitor shows severe late decelerations, bradycardia, or even fetal death. Severe disseminated intravascular coagulation (DIC) may occur.
- Ultrasound visualization of a retroplacental hematoma is rarely seen.

A. Partial separation

B. Marginal separation

C. Complete separation with concealed hemorrhage

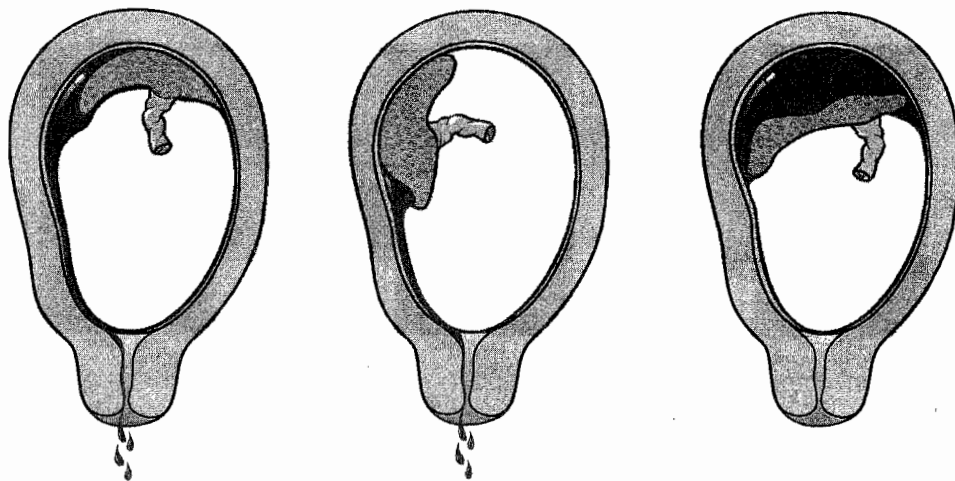


Figure 5-1. Abruption Placenta

Risk Factors. Abruption placenta is seen more commonly with *previous abruption*, *hypertension*, and *maternal trauma*. Other risk factors are maternal *cocaine* abuse and premature membrane rupture.

Management. Management is variable:

- *Emergency cesarean section*—This is performed if maternal or fetal jeopardy is present as soon as the mother is stabilized.
- *Vaginal delivery*—This is performed if bleeding is heavy but controlled or pregnancy is >36 weeks. Perform amniotomy and induce labor. Place external monitors to assess fetal heart rate pattern and contractions. Avoid cesarean delivery if the fetus is dead.
- *Conservative in-hospital observation*—This is performed if mother and fetus are stable and remote from term, bleeding is minimal or decreasing, and contractions are subsiding. Confirm normal placental implantation with sonogram and replace blood loss with crystalloid and blood products as needed.

Complications. Severe abruption can result in hemorrhagic shock with *acute tubular necrosis* from profound hypotension, and *DIC* from release of tissue thromboplastin into the general circulation from the disrupted placenta. *Couvelaire uterus* refers to blood extravasating between the myometrial fibers, appearing like bruises on the serosal surface.

PLACENTA PREVIA

A 34-year-old multigravida at 31 weeks' gestation comes to the birthing unit stating she woke up in the middle of the night in a pool of blood. She denies pain or uterine contractions. Examination of the uterus shows the fetus to be in transverse lie. Fetal heart tones are regular at 145 beats/min. On inspection her perineum is grossly bloody.

Etiology/Pathophysiology

- Placenta previa is present when the placenta is implanted in the *lower uterine segment*. This is common early in the pregnancy, but is most often not associated with bleeding.
- Usually the lower implanted placenta atrophies and the upper placenta hypertrophies, resulting in *migration of the placenta*. At term placenta previa is found in only 0.5% of pregnancies.
- Symptomatic placenta previa occurs when painless vaginal bleeding develops through avulsion of the anchoring villi of an *abnormally implanted* placenta as lower uterine segment stretching occurs in the latter part of pregnancy.

Diagnosis. This is based on the presence of *painless* late-trimester vaginal bleeding with an obstetric ultrasound showing placental implantation over the *lower uterine segment*.

Classification

- *Total, complete, or central previa* is found when the placenta completely covers the internal cervical os. This is the *most dangerous location* because of its potential for hemorrhage.
- *Partial previa* exists when the placenta partially covers the internal os.
- *Marginal or low-lying previa* exists when the placental edge is near but not over the internal os.

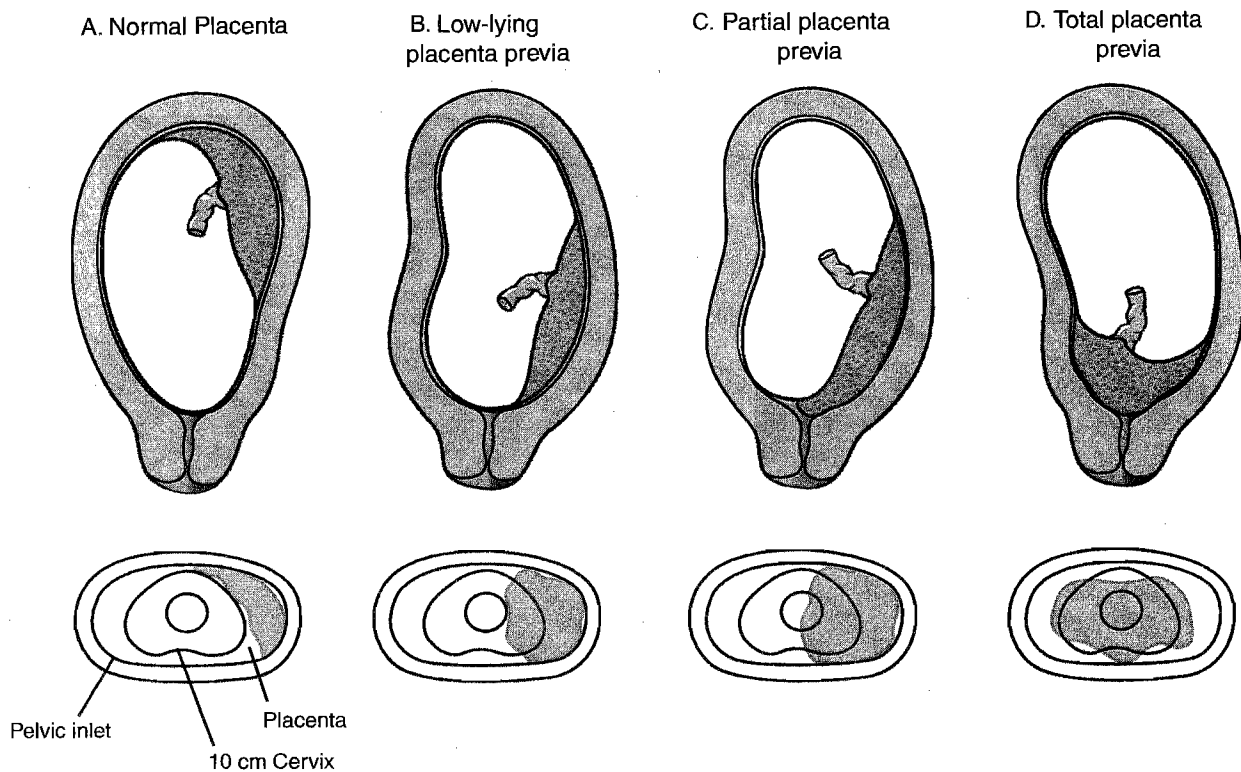


Figure 5-2. Placenta Previa

Clinical Presentation. The classic picture is *painless* late-pregnancy bleeding, which can occur during rest or activity, suddenly and without warning. It may be preceded by trauma, coitus, or pelvic examination. The uterus is nontender and nonirritable.

Risk Factors. Placenta previa is seen more commonly with *previous placenta previa and multiple gestation*. Other risk factors are multiparity and advanced maternal age.

Management. Management is variable:

- *Emergency cesarean section*—This is performed if maternal or fetal jeopardy is present after stabilization of the mother.
- *Conservative in-hospital observation*—Conservative management of bed rest is performed in preterm gestations if mother and fetus are stable and remote from term. The initial bleed is rarely severe. Confirm abnormal placental implantation with sonogram and replace blood loss with crystalloid and blood products as needed.
- *Vaginal delivery*—This may be attempted if the lower placental edge is more than 2 cm from the internal cervical os.
- *Scheduled cesarean delivery*—This is performed if the mother has been stable after fetal lung maturity has been confirmed by amniocentesis, usually at 36 weeks' gestation.

Complications. If placenta previa occurs over a previous uterine scar, the villi may invade into the myometrium, resulting in *placenta accreta*. This can result in intractable bleeding requiring *cesarean hysterectomy*. Profound hypotension can cause anterior pituitary necrosis (*Sheehan syndrome*) or *acute tubular necrosis*.

VASA PREVIA

A 21-year-old primigravida at 38 weeks' gestation is admitted to the birthing unit at 6-cm dilation with contractions occurring every 3 min. Amniotomy (artificial rupture of membranes) is performed, resulting in sudden onset of bright red vaginal bleeding. The electronic fetal monitor tracing, which had showed a baseline fetal heart rate (FHR) of 135 beats/min with accelerations, now shows a bradycardia at 70 beats/min. The mother's vital signs are stable with normal blood pressure and pulse.

Etiology/Pathophysiology. Vasa previa is present when fetal vessels traverse the fetal membranes over the internal cervical os. These vessels may be from either a velamentous insertion of the umbilical cord or may be joining an accessory (succenturiate) placental lobe to the main disk of the placenta. If these fetal vessels rupture the bleeding is from the fetoplacental circulation, and fetal exsanguination will rapidly occur, leading to fetal death.

Diagnosis. This is rarely confirmed before delivery but may be suspected when antenatal sonogram with color-flow Doppler reveals a vessel crossing the membranes over the internal cervical os. The diagnosis is usually confirmed after delivery on examination of the placenta and fetal membranes.

Clinical Presentation. The *classic triad* is rupture of membranes and *painless* vaginal bleeding, followed by fetal bradycardia.

Risk Factors. Vasa previa is seen more commonly with *velamentous insertion* of the umbilical cord, *accessory placental lobes*, and multiple gestation.

Management. *Immediate cesarean delivery* of the fetus is essential or the fetus will die from hypovolemia.

UTERINE RUPTURE

A 27-year-old G2 P1 woman comes to the maternity unit for evaluation for regular uterine contractions at 34 weeks' gestation. Her previous delivery was an emergency cesarean section at 32 weeks because of hemorrhage from placenta previa. A classic uterine incision was used because of lower uterine segment varicosities. Pelvic exam shows the cervix to be closed and long. As she is being evaluated, she experienced sudden abdominal pain, profuse vaginal bleeding, fetal bradycardia, and inability to pick up uterine contractions. The fetal head, which was at -1 station, now is floating.

Definition. Uterine rupture is *complete separation* of the wall of the pregnant uterus with or without expulsion of the fetus that endangers the life of the mother or the fetus, or both. The rupture may be *incomplete* (not including the peritoneum) or *complete* (including the visceral peritoneum).

Clinical Presentation. The most common findings are nonreassuring fetal monitor tracing associated with vaginal bleeding, abdominal pain, and alterations in uterine contractility. Rupture may occur both before labor as well as during labor.

Diagnosis. Confirmation of the diagnosis is made by *surgical exploration* of the uterus and identifying the rent.

Risk Factors. The *most common* risk factors are previous *classic uterine incision*, *myomectomy*, and excessive oxytocin stimulation. Other risk factors are grand multiparity and marked uterine distention.

Significance. A vertical fundal uterine scar is 20 times more likely to rupture than a low segment incision. Maternal and perinatal mortality is also much higher with the vertical incision rupture.

Management. *Treatment is surgical. Immediate cesarean delivery of the fetus is imperative.* Uterine repair is indicated in a stable young woman to conserve fertility. Hysterectomy is performed in the unstable patient or one who does not desire further childbearing.

Obstetrical Complications: Obstetrics

FIRST-TRIMESTER BLEEDING

A 40-year-old woman (G3 P1 Ab1) at 9 weeks' gestation comes to the office complaining of vaginal bleeding. A urine pregnancy test was positive 3 weeks ago. She initially experienced breast tenderness; however, it has now disappeared. She denies passage of any tissue vaginally.

Definition. Bleeding that occurs before 12 weeks' gestation. The *most common* cause of early pregnancy wastage is fetal in origin.

Etiology

- *Cytogenetic etiology.* The majority of early pregnancy losses are caused by gross chromosomal abnormalities of the embryo or fetus. The *most common* aneuploidy is Turner syndrome (45,X).
- *Mendelian etiology.* Other losses may be caused by autosomal or X-linked dominant or recessive diseases.
- *Anticardiolipin antibody.* An uncommon cause of early pregnancy wastage is this autoimmune disease in which the woman makes antibodies against her own vascular system and fetoplacental tissues.

Clinical Presentation

- *Speculum examination* is essential to rule out vaginal or cervical lesions that are causing bleeding.
- *RhoGAM* should be administered to all Rh-negative gravidas who undergo dilatation and curettage (D&C).
- Molar and ectopic pregnancy should be ruled out in all patients with early pregnancy bleeding.

Clinical Entities

The following diagnoses represent findings along a continuum from the beginnings of losing the pregnancy to complete expulsion of the products of conception (POC).

Missed abortion

Sonogram finding of a nonviable pregnancy without vaginal bleeding, uterine cramping, or cervical dilation. *Management:* Scheduled suction D&C or conservative management awaiting a spontaneous completed abortion.

Threatened abortion

Sonogram finding of a viable pregnancy with vaginal bleeding but no cervical dilation. Half of these pregnancies will continue to term successfully. *Management:* Observation. No intervention is generally indicated or effective.

Inevitable abortion

Vaginal bleeding and uterine cramping leading to cervical dilation, but no POC has yet been passed. *Management:* Emergency suction D&C to prevent further blood loss and anemia.

Incomplete abortion

Vaginal bleeding and uterine cramping leading to cervical dilation, with some, but not all, POC having been passed. *Management:* Emergency suction D&C to prevent further blood loss and anemia.

Completed abortion

Vaginal bleeding and uterine cramping have led to all POC being passed. This is confirmed by a sonogram showing no intrauterine contents or debris. *Management:* Conservative if an intrauterine pregnancy had been previously confirmed. Otherwise, serial β -human chorionic gonadotropin (β -hCG) titers should be obtained weekly until negative to ensure an ectopic pregnancy has not been missed.

FETAL DEMISE

A 28-year-old multigravida at 33 weeks' gestation comes to the office stating she has not felt her baby move for 24 h. A previous 18-week sonogram showed a single fetus with grossly normal anatomy. You are unable to find fetal heart tones by auscultation with a Doppler stethoscope.

Definition. In utero death of a fetus *after 20 weeks'* gestation before birth. *Antenatal* demise occurs before labor. *Intrapartum* demise occurs after the onset of labor.

Significance

- *Disseminated intravascular coagulation (DIC)* is the most serious consequence with prolonged fetal demise (>2 weeks) resulting from release of tissue thromboplastin from deteriorating fetal organs.
- *Grief resolution* may be prolonged if psychosocial issues are not appropriately addressed.

Risk Factors. Fetal demise is most commonly *idiopathic*. When a cause is identified, risk factors include antiphospholipid syndrome, overt maternal diabetes, maternal trauma, severe maternal isoimmunization, fetal aneuploidy, and fetal infection.

Presentation

- Before 20 weeks' gestation, the most common finding is uterine *fundus less than dates*.
- After 20 weeks' gestation, the most common symptom is maternal report of *absence of fetal movements*.

Diagnosis. Ultrasound demonstration of lack of fetal cardiac activity.

Management

- *DIC present.* Coagulopathy should be ruled out with appropriate laboratory testing: platelet count, d-dimer, fibrinogen, prothrombin time, partial thromboplastin time. If DIC is identified, *immediate delivery* is necessary with selective blood product transfusion as clinically indicated.
- *No DIC present.* Delivery may best be deferred for a number of days to allow for an appropriate grief response to begin. Or if the patient wishes conservative management, follow weekly serial DIC laboratory tests.
- *Mode of delivery.* A dilatation and evacuation (*D&E*) procedure may be appropriate in pregnancies of <20 weeks' gestation if no fetal autopsy is indicated. *Induction of labor* with vaginal prostaglandin is appropriate in pregnancies of >20 weeks or if a fetal autopsy is indicated. Cesarean delivery is almost never appropriate for dead fetus.
- *Psychosocial issues.* Acceptance of the reality of the loss may be enhanced by allowing the patient and her family to see the fetus, hold the fetus, name the fetus, and have a burial. Encouraging expression of feelings and tears may speed *grief resolution*.
- *Identify cause.* Workup may include cervical and placental cultures for suspected infection, *autopsy* for suspected lethal anatomic syndrome, *karyotype* for suspected aneuploidy, *total body x-ray* for suspected osteochondrodysplasia, maternal blood for *Kleihauer-Betke* (peripheral smear for suspected fetomaternal bleed).

MULTIPLE GESTATION

A 21-year-old primigravida at 15 weeks' gestation is seen for a routine prenatal visit. At her last visit 4 weeks ago, her uterus was appropriate for size and dates. Today, her uterine fundus is palpable at the umbilicus.

Definition. This is a pregnancy in which more than one fetus is present. The fetuses may arise from one or more zygotes and are usually separate, but may be conjoined.

Risk Factors

- *Dizygotic* multiple gestations are most common. *Identifiable risk factors* include by race, geography, family history, or ovulation induction. Risk of twinning is up to 10% with clomiphene citrate and up to 30% with human menopausal gonadotropin.
- *Monozygotic* multiple gestation has *no identifiable risk factors*.

Diagnosis. *Obstetric sonogram* demonstration of more than one intrauterine fetus.

Complications for all twin pregnancies include nutritional anemias (iron and folate), preeclampsia, preterm labor (50%), malpresentation (50%), cesarean section delivery (50%), and postpartum hemorrhage.

Dizygotic Twins. They arise from multiple ovulation with *two zygotes*. They are always dichorionic, diamniotic.

Monozygotic Twins. They arise from *one zygote*. Chorionicity and amnionicity vary according to the duration of time from fertilization to cleavage.

- *Up to 72 h* (separation up to the morula stage), the twins are *dichorionic, diamniotic*. There are two placentas and two sacs. This is the *lowest* risk of all monozygotic twins.
- *Between 4 and 8 days* (separation at the blastocyst stage), the twins are *monochorionic, diamniotic*. There is one placenta and two sacs. A specific additional complication is *twin–twin transfusion*. The twins share a single placenta but do so unequally. The *donor twin* gets less blood supply, resulting in growth restriction, oligohydramnios, and anemia. However, neonatal outcome is usually better. The *recipient twin* gets more blood supply, resulting in excessive growth, polyhydramnios, and polycythemia. Neonatal course is often complicated.
- *Between 9 and 12 days* (splitting of the embryonic disk), the twins are *monochorionic, monoamniotic*. There are only one placenta and one sac. Specific additional risks are twin–twin transfusion but particularly *umbilical cord entanglement*. This is the *highest* risk of all monozygotic twins.
- *After 12 days*, conjoined twins result. Most often this condition is *lethal*.

Clinical Findings. *Hyperemesis gravidarum* is more common from high levels of β -hCG. Uterus is larger than dates. Maternal serum α -fetoprotein is excessively high.

Management

- *Antepartum:* Give mother *iron and folate* supplementation to prevent anemia, *monitor blood pressure* to detect preeclampsia, *educate mother* regarding preterm labor symptoms and signs, and perform *serial ultrasound* examinations looking for twin–twin transfusion ($\geq 25\%$ discordance in fetal weights, amniotic fluid discordance).
- *Intrapartum:* Route of delivery is based on presentation in labor—*vaginal delivery* if both are cephalic presentation (50%); *cesarean delivery* if first twin in noncephalic presentation; route of delivery is *controversial* if first twin is cephalic and second twin is noncephalic.
- *Postpartum:* Watch for *postpartum hemorrhage* from uterine atony owing to an overdistended uterus.

ISOIMMUNIZATION

A 32-year-old woman, G2 P1, was seen for her first prenatal visit at 12 weeks' gestation. Her prenatal laboratory panel reveals a blood type of O negative. Her atypical antibody screen (indirect Coombs test) is positive. She has been married to the same husband for 10 years and states he is the father of both her pregnancies. She did not receive RhoGAM during her last pregnancy.

Definition. A pregnant woman has developed *antibodies to foreign red blood cells (RBCs)*, most commonly against those of her current or previous fetus(es), but also caused by transfusion of mismatched blood.

Pathophysiology

- The most common RBC antigens are of the Rh system (C, c, D, E, e), with the *most common being big D*.

- Antibodies to RBC antigens are detected by *indirect Coombs test* (atypical antibody test [ATT]). The concentration of antibodies is reported in dilutional titers with the lowest level being 1:1, and titers increasing by doubling (e.g., 1:1, 1:2, 1:4, 1:8, 1:16, 1:32...1:1,028, etc.).
- Hemolytic disease of the newborn (HDN) is a continuum ranging from hyperbilirubinemia to erythroblastosis fetalis. HDN is caused by maternal antibodies crossing into the fetal circulation and targeting antigen-positive fetal RBCs, resulting in hemolysis. When severe, this can result in anemia, fetal hydrops, and even death.

Risk Factors. Isoimmunization *most commonly* occurs when fetal RBCs enter the mother's circulation transplacentally at delivery. It can also occur if a woman is transfused with mismatched RBCs. Other pregnancy-related risk factors are amniocentesis, ectopic pregnancy, D&C, abruptio placenta, and placenta previa.

Protective Factors. ABO incompatibility *decreases the risk* of maternal isoimmunization from foreign RBCs. Naturally occurring anti-A and anti-B antibodies rapidly lyse foreign RBCs before maternal lymphocytes are stimulated to produce active antibodies.

Requirements. (All must be present.)

- Mother must be antigen negative.
- Fetus must be antigen positive, which means the father of the pregnancy must also be antigen positive.
- Adequate fetal RBCs must cross over into the maternal circulation to stimulate her lymphocytes to produce antibodies to the fetal RBC antigens.
- Antibodies must be associated with HDN.
- A significant titer of maternal antibodies must be present to cross over into the fetal circulation and lead to fetal RBC hemolysis.

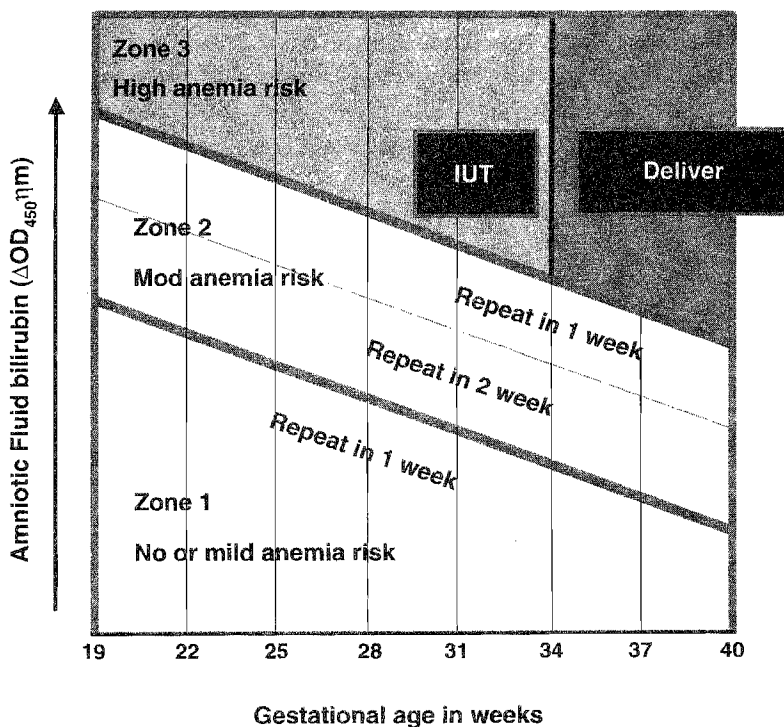


Figure 6-1

Management

1. Determine whether there is any fetal risk.
 - *Fetal risk is present* only if (1) atypical antibodies are detected in the mother's circulation, (2) antibodies are associated with HDN, (3) antibodies are present at a significant titer ($\geq 1:8$), and (4) the father of the baby (FOB) is RBC antigen positive. Fetal blood type may be determined by amniocentesis or percutaneous umbilical blood sampling (PUBS). If the fetus is RBC antigen negative, there is no fetal risk.
 - *No fetal risk is present* if (1) the AAT is negative, (2) antibodies are present but are NOT associated with HDN, (3) antibody titer is $< 1:8$, or (4) the FOB is RBC antigen negative.
 - *If the atypical antibody titer is $< 1:8$* , management is conservative. Repeat the titer monthly as long as it remains $< 1:8$.
2. Assess degree of fetal anemia if the fetus is RBC antigen positive or if fetal blood typing is impossible. This can be done by either serial amniocentesis or PUBS.
 - *Amniotic fluid bilirubin* indirectly indicates fetal hemolysis because bilirubin accumulates as a byproduct of RBC lysis. The bilirubin is plotted on a *Liley graph*.
 - *PUBS* directly measures fetal hematocrit and degree of anemia.
3. Intervene if severe anemia. This is diagnosed when amniotic fluid bilirubin is in Liley zone III or PUBS shows fetal hematocrit to be $\leq 25\%$.
 - *Intrauterine transfusion* is performed if gestational age is < 34 weeks. This may be intravascular or intraperitoneal.
 - *Delivery* is performed if gestational age is ≥ 34 weeks.

Prevention

- *What is RhoGAM?* It is pooled anti-D IgG passive antibodies that are given IM to a pregnant woman when there is significant risk of fetal RBCs passing into her circulation. The passive IgG antibodies attach to the foreign RBC antigens, causing lysis to occur before the maternal lymphocytes become stimulated.
- *When is RhoGAM given?* It is routinely given to Rh(D)-negative mothers at 28 weeks, and within 72 h of chorionic villus sampling (CVS), amniocentesis, or D&C. It is also given within 72 h of delivery of an Rh(D)-positive infant. Three hundred micrograms of RhoGAM will neutralize 15 ml of fetal RBCs or 30 ml of fetal whole blood.
- *Kleihauer-Betke test* quantitates the volume of fetal RBCs in the maternal circulation by differential staining of fetal and maternal RBCs on a peripheral smear. This can assess whether more than one vial of RhoGAM needs to be given when large volumes of fetal-maternal bleed may occur (e.g., abruptio placenta).

PREMATURE RUPTURE OF MEMBRANES (PROM)

A 22-year-old primigravida at 33 weeks' gestation comes to the birthing unit stating that 2 h ago she had a gush of fluid from her vagina. She denies vaginal bleeding or uterine contractions. Her perineum appears moist to gross inspection. On examination her temperature is 102°F.

Definition. Rupture of the fetal membranes before the onset of labor, whether at term or preterm.

Risk Factors. *Ascending infection* from the lower genital tract is the *most common* risk factor for PROM. Other risk factors are local membrane defects and cigarette smoking.

Clinical Presentation. Typical history is a sudden gush of copious vaginal fluid. On external examination, clear fluid is flowing out of the vagina. Oligohydramnios is seen on ultrasound examination.

Diagnosis

- PROM is diagnosed by *sterile speculum examination* meeting the following criteria:
 - *Pooling positive*—clear, watery amniotic fluid is seen in the posterior vaginal fornix
 - *Nitrazine positive*—the fluid turns pH-sensitive paper blue
 - *Fern positive*—the fluid displays a ferning pattern when allowed to air dry on a microscope glass slide
- *Chorioamnionitis* is diagnosed clinically with all the following criteria needed: maternal fever and uterine tenderness in the presence of confirmed PROM in the absence of a URI or UTI.

Management

- *If uterine contractions occur*, tocolysis is contraindicated.
- *If chorioamnionitis is present*, obtain cervical cultures, start broad-spectrum therapeutic IV antibiotics, and initiate prompt delivery.
- *If no infection is present*, management will be based on gestational age as follows:
 - *Before viability* (<24 weeks), outcome is dismal. Either induce labor or manage patient with bed rest at home. Risk of fetal pulmonary hypoplasia is high.
 - *With preterm viability* (24–35 weeks), conservative management. Hospitalize the patient at bed rest, administer IM betamethasone to enhance fetal lung maturity if <32 weeks, obtain cervical cultures, and start a 7-day course of prophylactic ampicillin and erythromycin.
 - *At term* (≥36 weeks), initiate prompt delivery. If vaginal delivery is expected, use oxytocin or prostaglandins as indicated. Otherwise, perform cesarean delivery.

PRETERM LABOR

A 24-year-old woman, G2 P1, at 28 weeks' gestation by dates comes to the birthing unit complaining of regular uterine contractions every 7–10 min. She is a smoker with chronic hypertension. She has had no prenatal care. On examination her fundal height is 35 cm. Her previous pregnancy ended with spontaneous vaginal delivery at 30 weeks' gestation.

Definition. Preterm delivery is the *most common* cause of perinatal morbidity and mortality. Overall, 8–10% of pregnancies deliver prematurely. Many patients will have preterm contractions but not be in preterm labor. *Three criteria* need to be met:

- *Gestational age*—pregnancy duration ≥ 20 weeks, but < 37 weeks.
- *Uterine contractions*—at least three contractions in 30 min.
- *Cervical change*—serial examinations show a change in dilation or effacement, or a single examination shows cervical dilation of ≥ 2 cm.

Risk Factors. *Multiple pregnancy, uterine anomalies, PROM, and previous preterm birth are the most common risk factors for preterm delivery.* Other risk factors are pyelonephritis, chorioamnionitis, maternal smoking, heavy physical labor, polyhydramnios, abdominal-pelvic surgery, periodontal disease, bacterial vaginosis, trichomoniasis vaginitis, and ultrasound cervical length < 25 mm.

Symptoms. Lower abdominal pain or pressure, lower back pain, increased vaginal discharge, or bloody show. Particularly in primigravidas, the symptoms may be present for a number of hours to days but are not recognized as contractions by the patient.

Tocolytic Contraindications. These are conditions under which stopping labor is either *dangerous* for mother and baby or *futile* (makes no difference in outcome). Examples include the following:

- *Obstetric conditions*—severe abruptio placenta, ruptured membranes, chorioamnionitis.
- *Fetal conditions*—lethal anomaly (anencephaly, renal agenesis), fetal demise or jeopardy (repetitive late decelerations).
- *Maternal conditions*—eclampsia, severe preeclampsia, advanced cervical dilation.

Tocolytic Agents. *Parenteral agents* may prolong pregnancy but for no more than 72 h. This does provide a window of time for (1) administration of *maternal IM betamethasone* to enhance fetal pulmonary surfactant and (2) *transportation of mother and fetus in utero* to a facility with neonatal intensive care. *Oral tocolytic agents* are no more effective than placebo.

- *Magnesium sulfate* is a competitive inhibitor of calcium. Clinical monitoring is based on decreasing but maintaining detectable deep tendon reflexes.
 - *Side effects* include muscle weakness, respiratory depression, and pulmonary edema. Magnesium overdose is treated with IV calcium gluconate.
 - *Contraindications* include renal insufficiency and myasthenia gravis.
- *β -Adrenergic agonists* include terbutaline and ritodrine (the only FDA-approved agent). Tocolytic effect depends on the β_2 -adrenergic receptor myometrial activity.
 - *Cardiovascular side effects* (hypotension, tachycardia) are from β_1 receptor cardiovascular activity. Other side effects are hyperglycemia, hypokalemia, and pulmonary edema.

- *Contraindications* include cardiac disease, diabetes mellitus, uncontrolled hyperthyroidism.
- *Calcium-channel blockers* decrease intracellular calcium (e.g., nifedipine).
 - *Side effects* include tachycardia, hypotension, and myocardial depression.
 - *Contraindications* include hypotension.
- *Prostaglandin synthetase inhibitors* decrease smooth muscle contractility by decreasing prostaglandin production (e.g., indomethacin).
 - *Side effects* include oligohydramnios, in utero ductus arteriosus closure, and neonatal necrotizing enterocolitis.
 - *Contraindications* include gestational age >32 weeks.

Management

- *Confirm labor* using the three criteria listed above.
- *Rule out contraindications* to tocolysis using criteria listed above.
- *Initiate IV hydration* with isotonic fluids.
- *Start magnesium sulfate* tocolysis with 5 g IV for 20 min, then 2 g/h.
- *Obtain cervical and urine cultures* before giving IV penicillin G (or erythromycin) for group B β streptococcus sepsis prophylaxis.
- *Administer maternal IM betamethasone* to stimulate fetal type II pneumocyte surfactant production.

Prevention. Weekly intramuscular injections of 17α -OH progesterone caproate starting at 20 weeks' gestation has been shown to decrease preterm deliveries in women with a history of previous idiopathic deliveries.

POSTDATES PREGNANCY

A 21-year-old primigravida at 42 weeks' gestation by dates comes to the outpatient prenatal clinic. She has been seen for prenatal care since 12 weeks' gestation, confirmed by an early sonogram. She states that fetal movements have been decreasing. Fundal height measurement is 42 cm. Her cervix is long, closed, posterior, and firm. Nonstress test (NST) is reactive, but amniotic fluid index (AFI) is 4 cm.

Definition

- *Academic.* The most precise definition is a pregnancy that continues for ≥ 40 weeks or ≥ 280 days postconception.
- *Practical.* Because most of the time the date of conception is not known, a practical definition is a pregnancy that continues ≥ 42 weeks or ≥ 294 days after the first day of the last menstrual period.
- *Statistics.* Generally, 50% of patients deliver by 40 weeks, 75% by 41 weeks, and 90% by 42 weeks. These statistics assume ovulation occurred on day 14 of a 28-day menstrual cycle. These figures probably overstate the actual number because up to half of these patients had cycles longer than 28 days.

Etiology. The most *common cause* of true postdates cases are *idiopathic* (no known cause). It does occur more commonly in young primigravidas and rarely with placental sulfatase deficiency. Pregnancies with anencephalic fetuses are the longest pregnancies reported.

Significance. *Perinatal mortality is increased two- to threefold.* This is a direct result of changes on placental function over time.

- *Macrosomia syndrome.* In most patients, *placental function continues* providing nutritional substrates and gas exchange to the fetus, resulting in a healthy but large fetus. *Cesarean rate is increased* owing to prolonged or arrested labor. Shoulder dystocia is more common with risks of fetal hypoxemia and brachial plexus injury.
- *Dysmaturity syndrome.* In a minority of patients, *placental function declines* as infarction and aging lead to placental scarring and loss of subcutaneous tissue. This reduction of metabolic and respiratory support to the fetus can lead to the asphyxia that is responsible for the increased perinatal morbidity and mortality. *Cesarean rate is increased* owing to nonreassuring fetal heart rate patterns. Oligohydramnios results in umbilical cord compression. Hypoxia results in acidosis and in utero meconium passage.

Management. Management is based on two factors.

- *Confidence in dates.* Identify how much confidence can be placed on the gestational age being truly >42 weeks.
- *Favorableness of the cervix.* Assess the likelihood of successful induction of labor by assessing cervical dilation, effacement, position, consistency, and station.
 - *Favorable cervix* is dilated, effaced, soft, and anterior to mid position.
 - *Unfavorable cervix* is closed, not effaced, long, firm, and posterior.

Patients can be classified into three groups.

- *Dates sure, favorable cervix.* Management is *aggressive.* There is no benefit to the fetus or mother in continuing the pregnancy. Induce labor with IV oxytocin and artificial rupture of membranes.
- *Dates sure, unfavorable cervix.* Management is *controversial.* Management could be *aggressive*, with cervical ripening initiated with vaginal or cervical prostaglandin E₂ followed by IV oxytocin. Or management could be *conservative* with twice weekly NSTs and AFI's awaiting spontaneous labor.
- *Dates unsure.* Management is *conservative.* Perform twice weekly NSTs and AFI's to ensure fetal well-being and await spontaneous labor. If fetal jeopardy is identified, delivery should be expedited.

Management of Meconium

- *In labor,* amnioinfusion (with saline infused through an intrauterine catheter) can dilute the meconium and provide a fluid cushion to prevent umbilical cord compression.
- *After the head is delivered,* suction the fetal nose and pharynx to remove any upper airway meconium.
- *After the body is delivered,* use a laryngoscope and suction to visualize and remove meconium below the vocal cords.

Obstetrical Complications: Hypertension



GESTATIONAL HYPERTENSION

A 19-year-old primigravida is seen in the outpatient prenatal clinic for routine visit. She is at 32 weeks' gestation, confirmed by first trimester sonogram. She has no complaints. She denies headache, epigastric pain, or visual disturbances. She has gained 2 pounds since her last visit 2 weeks ago. On examination her blood pressure (BP) is 155/95, which is persistent on repeat BP check 10 minutes later. She has only trace pedal edema. A spot urine dipstick is negative.

Definition. Gestational hypertension is diagnosed with sustained elevation of BP $\geq 140/90$ after 20 weeks of pregnancy without proteinuria. The BP returns to normal baseline postpartum.

Presenting Symptoms and Physical Examination. No symptoms of preeclampsia are seen, e.g., headache, epigastric pain, visual disturbances. Physical findings are unremarkable for pregnancy.

Laboratory Abnormalities. Laboratory tests are unremarkable for pregnancy. Proteinuria is absent.

Diagnostic Tests. The key findings are sustained elevation of BP $>140/90$ without proteinuria and a rapid return to baseline on repeat measurement.

Management. Conservative outpatient management is appropriate. Close observation is prudent to ensure the patient is not experiencing incipient preeclampsia. Appropriate laboratory testing should be performed to rule out preeclampsia, e.g., urine protein, hemoconcentration assessment.

Differential Diagnosis. Preeclampsia should always be ruled out.

MILD PREECLAMPSIA

A 21-year-old primigravida is seen in the outpatient prenatal clinic for routine visit. She is at 32 weeks' gestation, confirmed by first trimester sonogram. Her only complaint is swelling in her hands and feet. She denies headache, epigastric pain, or visual disturbances. She has gained 10 pounds since her last visit 2 weeks ago. On examination her BP is 155/95, and remains unchanged on repeat BP in 15 min. She has 3+ pedal edema, and her fingers appear swollen. A spot urine dipstick shows 2+ protein.

Definition. Preeclampsia is *sustained* BP elevation in pregnancy *after 20 weeks'* gestation in the absence of preexisting hypertension.

Diagnostic Criteria. There are no pathognomic tests. The *diagnostic dyad* includes the following:

- *Sustained BP elevation* of $\geq 140/90$.
- *Proteinuria* on dipstick of 1--2+ or ≥ 300 mg on a 24-h urine collection.

Risk Factors. Preeclampsia is found 8 times more frequently in *primiparas*. Other risk factors are multiple gestation, hydatidiform mole, diabetes mellitus, age extremes, chronic hypertension, and chronic renal disease.

Etiology/Pathophysiology. Pathophysiology involves *diffuse vasospasm* caused by (1) loss of the normal pregnancy-related refractoriness to vasoactive substances such as angiotensin; and (2) relative or absolute changes in the following *prostaglandin* substances: increases in the vasoconstrictor thromboxane along with decreases in the potent vasodilator *prostacyclin*. This vasospasm contributes to intravascular volume constriction and decreased perfusion of most organs including uteroplacental unit, kidneys, liver, brain, and heart. Decreased renal blood flow leads to decreased clearance of body metabolic wastes. Capillary injury leads to loss of intravascular volume into the interstitial space and subsequent edema.

Presenting Symptoms and Physical Examination. With mild preeclampsia the symptoms and physical findings are generally related to the excess weight gain and fluid retention. Presence of new onset of persistent headache, epigastric pain, or visual disturbances would move the diagnosis from mild to severe preeclampsia.

Laboratory Abnormalities. Evidence of *hemoconcentration* is shown by elevation of hemoglobin, hematocrit, blood urea nitrogen (BUN), serum creatinine, and serum uric acid. *Proteinuria* is described under diagnostic tests. Evidence of disseminated intravascular coagulation (*DIC*) or *liver enzyme* elevation would move the diagnosis from mild to severe preeclampsia.

Management. The only *definitive cure* is *delivery* and removal of all fetal-placental tissue. However, delivery may be deferred in mild preeclampsia to minimize neonatal complications of prematurity. Management is based on gestational age.

- *Conservative inpatient.* Before 36 weeks' gestation as long as mother and fetus are stable, mild preeclampsia is managed in the hospital, watching for possible progression to severe preeclampsia. No antihypertensive agents or MgSO_4 are used.
- *Delivery.* At ≥ 36 weeks' gestation, delivery is indicated with dilute IV oxytocin induction of labor and continuous infusion of IV MgSO_4 to prevent eclamptic seizures.

Complications. Progression from mild to severe preeclampsia may occur.

Differential Diagnosis. Chronic hypertension should always be ruled out.

SEVERE PREECLAMPSIA

A 21-year-old primigravida is seen in the outpatient prenatal clinic for routine visit. She is at 32 weeks' gestation, confirmed by first trimester sonogram. For the past 24 h she had experienced severe, unremitting occipital headache, and mid-epigastric pain not relieved by acetaminophen, and also seen light flashes and spots in her vision. She has gained 10 pounds since her last visit 2 weeks ago. On examination her BP is 165/115. She has 3+ pedal edema, and her fingers appear swollen. Fundal height is 29 cm. Fetal heart tones are regular at 145 beats/min. A spot urine dipstick shows 4+ protein.

Diagnostic Tests. The diagnosis is made on the basis of the finding of at least mild preeclampsia *plus any one* of the following:

- *Sustained BP elevation* of $\geq 160/110$.
- *Proteinuria* on dipstick of 3–4+ or ≥ 5 g on a 24-h urine collection.
- *Evidence of maternal jeopardy.* This may include symptoms (headache, epigastric pain, visual changes), thrombocytopenia (platelet count $< 100,000/\text{ml}$), elevated liver enzymes, pulmonary edema, oliguria (< 750 ml/24 h), or cyanosis.
- *Edema* may or may not be seen.

Risk Factors. These are the same as mild preeclampsia with the addition of diseases with small vessel disease such as systemic lupus and longstanding overt diabetes.

Etiology/Pathophysiology. Pathophysiology is the same as mild preeclampsia but involves *severe diffuse vasospasm* and *more intense capillary injury* to where the ischemia demonstrates itself in overt, usually multiorgan system injury.

Presenting Symptoms. Presence of new onset of persistent headache, epigastric pain, or visual disturbances is characteristic of severe preeclampsia.

Laboratory Abnormalities. Evidence of *hemoconcentration* will be more severe. Proteinuria is described under diagnostic tests. Evidence of DIC and hepatocellular injury is characteristic of severe preeclampsia.

Management

- *Aggressive prompt delivery* is indicated for severe preeclampsia at any gestational age with evidence of maternal jeopardy or fetal jeopardy.
 - *Administer IV MgSO_4* to prevent convulsions. Give a 5-g loading dose, then continue maintenance infusion of 2 g/h.
 - *Lower BP* to diastolic values between 90 and 100 mm Hg with IV hydralazine and labetalol.
 - *Attempt vaginal delivery* with IV oxytocin infusion if mother and fetus are stable.
- *Conservative inpatient management* may rarely be attempted in absence of maternal and fetal jeopardy with gestational age 26–34 weeks if BP can be brought below 160/110 mm Hg. This should take place in an intensive care unit (ICU) tertiary-care setting. Continuous IV MgSO_4 should be administered, and maternal betamethasone should be given to enhance fetal lung maturity.

Complications. Progression from severe preeclampsia to eclampsia may occur.

ECLAMPSIA

A 21-year-old primigravida is brought to the emergency department after suffering generalized tonic-clonic seizure at 32 weeks' gestation. The seizure was preceded by a severe headache. She lost control of her bowels and bladder. She has gained 10 pounds since her last prenatal visit 2 weeks ago. On examination she is unresponsive in a postictal state. Her BP is 185/115, and a spot urine dipstick shows 4+ protein.

Definition. Eclampsia is the presence of *unexplained grand mal seizures* in a hypertensive, proteinuric pregnant woman in the last half of pregnancy.

Risk Factors. These are the same as mild and severe preeclampsia. A primary seizure disorder does not predispose to eclampsia.

Etiology/Pathophysiology. Pathophysiology is *severe diffuse cerebral vasospasm* resulting in cerebral perfusion deficits and cerebral edema.

Presenting Symptoms. In addition to those of mild and severe preeclampsia, the most significant finding is *unexplained tonic-clonic seizures*.

Laboratory Abnormalities. These are the same as found with mild and severe preeclampsia.

Diagnosis. The diagnosis is made clinically with unexplained grand mal seizures occurring in a hypertensive, proteinuric pregnant woman in the last half of pregnancy.

Management

- The first step is to protect the mother's airway and tongue.
- Administer $MgSO_4$ with an IV bolus of 5 g to stop seizures, continuing maintenance infusion rate of 2 g/h.
- Aggressive prompt delivery is indicated for eclampsia at any gestational age after stabilization of the mother and the fetus. Attempt vaginal delivery with IV oxytocin infusion if mother and fetus are stable.
- Lower diastolic BP between 90 and 100 mm Hg with IV hydralazine and labetalol.

Complications. Intracerebral hemorrhage can occur with even death resulting.

CHRONIC HYPERTENSION

A 35-year-old multigravida is seen in the outpatient prenatal clinic for her first prenatal visit. She is at 12 weeks' gestation with a BP of 155/95. Chronic hypertension was diagnosed 5 years ago for which she has been treated with oral nifedipine. A spot urine dipstick protein is 2+. A recent 24-h urine collection showed 1.2 g of protein and a creatinine clearance of 85 ml/min. Serum creatinine is 1.2 mg/dl. She has no complaints of headache or visual changes.

Risk Factors. Most chronic hypertension (HTN) is *idiopathic* without specific antecedents. Risk factors are obesity, advanced maternal age, positive family history, renal disease, diabetes, and systemic lupus erythematosus.

Etiology/Pathophysiology. Pathophysiology is *vasospasm* causing *decreased end-organ perfusion*, resulting in injury and damage. The acute problems arise from excessive systolic pressures, whereas the long-term problems arise from excessive diastolic pressures.

Diagnosis. The diagnosis of chronic HTN is made with the finding of BP $\geq 140/90$ with onset before the pregnancy or before 20 weeks' gestation.

Pregnancy Prognosis With Chronic HTN:

- *Good.* Favorable maternal and neonatal outcome is found in patients with BP values between 140/90 and 179/109 and no evidence of end-organ damage.
- *Poor.* Pregnancy complications are more common in patients with severe HTN with the following end-organ damage: cardiac, renal, and retinal.
 - *Renal disease.* Pregnancy loss rates increase significantly if serum creatinine value are >1.4 mg/dl.
 - *Retinopathy.* Longstanding HTN is associated with retinal vascular changes including hemorrhages, exudates, and narrowing.
 - *Left ventricular hypertrophy.* This is seen mostly in women with prolonged BP values of $>180/110$.
- *Worst.* Tenfold higher fetal loss rate if uncontrolled HTN (before conception or early in pregnancy) and chronic HTN with superimposed preeclampsia.

Chronic HTN With Superimposed Preeclampsia:

- This complication occurs in 25% of patients with chronic HTN. Risk factors include renal insufficiency, HTN for previous 4+ years, and HTN in a previous pregnancy.
- Adverse pregnancy outcomes for both mother and baby are markedly increased. Abruption placenta incidence is markedly increased.
- The diagnosis is made on the basis of established chronic HTN along with any of the following: documented *rising BP* values; demonstrated *worsening proteinuria*; or evidence of *maternal jeopardy* (headache, epigastric pain, visual changes, thrombocytopenia [platelet count $<100,000/\text{ml}$], elevated liver enzymes, pulmonary edema, oliguria [<750 ml/24 h], or cyanosis). Edema may or may not be seen.

Laboratory Abnormalities. Chronic HTN patients have a spectrum of etiologies and disease severity. Those with mild HTN and no end-organ involvement have normal laboratory tests, whereas those with renal disease may have evidence of decreased renal function including proteinuria, lowered creatinine clearance, and elevated BUN, creatinine, and uric acid.

Antihypertensive Drug Therapy Issues

- *Discontinue medications.* This may be done in patients with mild-to-moderate HTN caused by the normal decrease in BP that occurs in pregnancy. Pharmacologic treatment in patients with diastolic BP <100 mm Hg does not improve either maternal or fetal outcome.
- *Maintain medications.* This may be necessary in patients with severe HTN. The drug of choice is *methyl-dopa* because of extensive experience and documented fetal safety. *Labetalol* and *atenolol* are acceptable alternatives. However, β -blocking agents are associated with intrauterine growth retardation (IUGR).

- “Never use” medications. Angiotensin-converting enzyme inhibitors are contraindicated in pregnancy, as they have been associated with fetal hypocalvaria, renal failure, oligohydramnios, and death. *Diuretics* should not be initiated during pregnancy owing to possible adverse fetal effects of associated plasma volume reduction.
- *BP target range.* Reduction of BP to normal levels in pregnancy may jeopardize uteroplacental blood flow. Maintain *diastolic* values between 90 and 100 mm Hg.

Management

- *Conservative outpatient management.* This is appropriate with uncomplicated mild-to-moderate chronic HTN.
 - *Stop drug therapy.* Attempt discontinuation of antihypertensive agents. Follow guideline outlined.
 - *Serial sonograms* and antenatal testing is appropriate after 30 weeks’ gestation to monitor for increased risk of IUGR.
 - *Serial BP and urine protein* assessment is indicated for early identification of superimposed preeclampsia.
 - *Induce labor at term* if the cervix is favorable.
- *Aggressive prompt delivery* is indicated for chronic HTN with superimposed preeclampsia at any gestational age.
 - Administer IV $MgSO_4$ to prevent convulsions.
 - Keep *diastolic BP* between 90 and 100 mm Hg with IV hydralazine and labetalol.
 - Attempt *vaginal delivery* with IV oxytocin infusion if mother and fetus are stable.

Complications. Progression from chronic HTN to superimposed preeclampsia, which can lead to maternal and fetal death.

HELLP SYNDROME

A 32-year-old multigravida is at 32 weeks’ gestation. At a routine prenatal visit her BP was noted to be 160/105. Previous BP readings were normal. Preeclampsia workup was begun and revealed the following: elevated total bilirubin, lactate dehydrogenase, alanine aminotransferase, and aspartate aminotransferase, as well as platelet count of 85,000. She has no complaints of headache or visual changes.

Definition. HELLP syndrome occurs in 5–10% of preeclamptic patients and is characterized by hemolysis (*H*), elevated liver enzymes (*EL*), and low platelets (*LP*).

Risk Factors. HELLP syndrome occurs twice as often in multigravidas as primigravidas.

Differential Diagnosis. It can be confused with thrombotic thrombocytopenic purpura and hemolytic uremic syndrome. HTN, although frequently seen, is not always present.

Management. *Prompt delivery* at any gestational age is appropriate. Use of maternal *corticosteroids* may enhance postpartum recovery.

Complications. Conditions that are associated with HELLP syndrome include DIC, abruptio placenta, fetal demise, ascites, and hepatic rupture.

Obstetrical Complications: Medical

8

CARDIAC DISEASE IN PREGNANCY

A 30-year-old multigravida with a childhood history of rheumatic fever has echocardiography-diagnosed mitral stenosis. She is now at 20 weeks' gestation and has no symptoms at rest but has mild shortness of breath and dyspnea with activity. On examination she has a diastolic murmur.

Definition

General types of heart disease:

- *Coronary heart disease.* This condition is rarely found in women of childbearing age. Adverse consequences of hypoxic heart disease include miscarriage, fetal death, preterm delivery, and increased perinatal morbidity and mortality.
- *Rheumatic heart disease.* The most common acquired lesion in pregnancy is rheumatic heart disease. The most common rheumatic heart disease is *mitral stenosis*. With severe stenosis, the main problem is *inadequate diastolic flow* from the left atrium to the left ventricle. Obstruction to left ventricular filling may lead to left atrial enlargement, pulmonary congestion, atrial fibrillation, and subacute bacterial endocarditis (SBE) with valvular vegetations causing thromboemboli. Tachycardia and increased plasma volume, which are normal changes of pregnancy, will only exacerbate these problems.
- *Congenital heart disease.* The most common congenital lesions are atrial (ASDs) and ventricular septal defects (VSDs). The most common cyanotic congenital heart disease in pregnancy is tetralogy of Fallot. ASDs and VSDs are tolerated well with pregnancy, as are any regurgitation lesions.

Maternal Mortality Risk

- *Low maternal mortality* (<1% risk of death): ASD, VSD, patent ductus arteriosus (PDA), minimal mitral stenosis, porcine heart valve, and corrected tetralogy of Fallot.
- *Intermediate maternal mortality* (5–15% risk of death): mitral stenosis with atrial fibrillation, artificial heart valve, uncorrected tetralogy of Fallot, and Marfan syndrome with normal aortic root diameter.
- *High maternal mortality* (25–50% risk of death): pulmonary hypertension, Eisenmenger's syndrome, Marfan syndrome with aortic root >40 mm diameter, and peripartum cardiomyopathy.

Unique High-Risk Conditions

Eisenmenger syndrome

This condition is characterized by pulmonary hypertension and a bidirectional shunt. The normal decrease in systemic vascular resistance (SVR) in pregnancy places the patient at risk for having the pulmonary vascular resistance (PVR) exceed the SVR. When this develops, the path of least resistance for blood from the right heart is to bypass the pulmonary circulation across the shunt. This results in the left heart pumping unoxygenated blood into the systemic circulation, resulting in a 50% mortality risk. *Management* is by avoiding hypotension.

Marfan syndrome

This is an autosomal dominant connective tissue disorder. In pregnancy, if the aortic root diameter is >40 mm, the risk of aortic dissection is high, placing the patient at a 50% mortality risk.

Peripartum cardiomyopathy

In this condition, the patient has no underlying heart disease, but develops idiopathic biventricular cardiac decompensation between the last few weeks of pregnancy and the first few months postpartum. Risk factors include advanced maternal age, multiparity, hypertension, and multiple pregnancy. Mortality rate is 75% if reversal does not occur within 6 months. *Management* is supportive, intensive care unit (ICU) care.

New York Heart Association Functional Classification of Heart Disease in Pregnancy

- Class I—no sign or symptoms of cardiac decompensation with physical activity.
- Class II—no symptoms at rest, but minor limitations with activity.
- Class III—no symptoms at rest, but marked limitations with activity.
- Class IV—symptoms present at rest, increasing with any physical activity.

Signs of Heart Disease

- Any diastolic or continuous heart murmur.
- Any systolic murmur associated with a thrill.
- Any severe arrhythmias.
- Unequivocal cardiac enlargement.

General Principles in Pregnancy Management of Rheumatic Mitral Heart Disease

- Minimize tachycardia.
- Minimize excessive intravascular volume.

Specific Management

- *Antepartum*. Left lateral rest, 2 g sodium diet, digitalis as indicated, diuretics as indicated, avoid strenuous activity, avoid anemia, fetal echocardiogram (if patient has congenital heart disease).

- *Intrapartum.* Aim for vaginal delivery, left lateral rest, monitor intravascular volume, administer oxygen, reassurance, sedation, SBE prophylaxis, epidural, no pushing, elective forceps to shorten the second stage of labor, possible arterial line and pulmonary artery catheter (if Class III or IV status).
- *Postpartum.* Watch closely for postpartum intravascular overload caused by sudden emptying of uterine venous sinuses after placental delivery.

THYROID DISEASE IN PREGNANCY

A 23-year-old primigravida is at 30 weeks' gestation. She has lost 4 pounds during the past 2 months. She states her heart "feels like it is racing," and her resting pulse is 135 beats/min. There is a noticeable tremor when she holds her arms out straight. Her eyes appear prominent and protruding. She is complaining of frequent uterine contractions.

Physiology. Increased thyroid blood flow leads to thyromegaly. Increased glomerular filtration rate (GFR) in pregnancy enhances iodine excretion, lowering plasma iodine concentrations. Estrogen causes an increase in liver-produced thyroid binding globulin (TBG), thus increasing total T_3 and T_4 . *However, free T_3 and T_4 remain unchanged.* Fetal thyroid function begins as early as 12 weeks with minimal transfer of T_3 or T_4 across the placenta.

Hyperthyroidism

Underlying etiology may be Grave disease, toxic nodular goiter (Plummer disease), hydatidiform mole, or toxic diffuse goiter.

- *If uncontrolled,* it is associated with increased spontaneous abortions, prematurity, intrauterine growth retardation (IUGR), and perinatal morbidity and mortality.
- *If controlled,* pregnancy outcome is not altered. Clinical features include elevated resting pulse, thyromegaly, exophthalmus, inadequate weight gain or even weight loss, and markedly elevated T_4 .
- *Thyroid storm.* This is a life-threatening hypermetabolic state presenting with pyrexia, tachycardia, and severe dehydration. *Management* is propylthiouracil (PTU), β -blocking agents, steroids, and iodine.

Graves disease

This is the most common kind of hyperthyroidism in pregnancy.

Pathophysiology. It is mediated by autoimmune production of long-acting thyroid-stimulating IgG (*LATS*) that drives thyroid hormone production independent of thyrotropin (TSH). LATS can cross the placenta, potentially causing fetal hyperthyroidism.

Diagnosis. The diagnosis is confirmed by elevated T_4 and LATS, as well as low TSH in the presence of clinical features described above.

Management

- *Antithyroid medications* are the first line of therapy in pregnancy, but can cross the placenta leading to fetal hypothyroidism. PTU and methimazole are thioamides that block thyroid hormone synthesis. Both can be used in pregnancy.
- *Subtotal thyroidectomy* is primarily indicated when antithyroid medical therapy fails and is ideally performed in the second trimester.
- *Thyroid ablation with radioactive iodine (I 131)* is *contraindicated* because it can cross the placenta, destroying the fetal thyroid.

Hypothyroidism

This condition is most commonly a primary thyroid defect and often results in *anovulation and infertility*. If uncontrolled it is associated with spontaneous abortion; however, if pregnancy continues, the infant is healthy. If controlled with appropriate thyroid replacement, normal fertility and pregnancy outcomes are noted.

Diagnosis. Demonstration of an elevated TSH.

Management. Supplemental thyroid hormone.

SEIZURE DISORDERS IN PREGNANCY

A 25-year-old primigravida is 19 weeks' gestation. She has a 10 year history of generalized seizures poorly controlled requiring hydantoin and valproic acid. A triple marker screen result showed an elevated maternal serum alpha fetoprotein.

Significance. Prevalence of seizure disorders is 0.5% in women of childbearing age.

Classification of epileptic seizures

- *Partial seizures* do not involve both hemispheres. They can be either *simple*, with no loss of consciousness, or *complex*, in which consciousness may be impaired.
- *Generalized seizures* involve both hemispheres. They can be either *absence* type, with duration <20 s (formerly called "petit mal"), or tonic-clonic, with duration lasting up to several minutes (formerly called "grand mal").

Effect of pregnancy on seizure disorder

- *Seizures worsen.* Up to 25% of these women will experience deterioration of seizure control during pregnancy, with 75% seeing no change. The more severe the disorder, the more likely it will worsen.
- *Anticonvulsant metabolism increased.* Seizure medication clearance may be enhanced by higher hepatic microsomal activity, resulting in lower blood levels.

Effect of seizure disorder on pregnancy

Pregnancy complications are minimal with appropriate prenatal care and compliance with anticonvulsant medications.

Effect of anticonvulsants on fetus and infant

Congenital malformation rate is increased from 3% to >10%. In addition, cerebral palsy, seizure disorders, and mental retardation are increased in offspring of epileptic women. Maternal phenytoin use is associated with neonatal deficiency of vitamin K-dependent clotting factors: II, VII, IX, and X.

Management

- *Folate supplements.* Ensure extra folic acid supplementation before conception and during embryogenesis to minimize neural tube defects.
- *Anomaly screening.* Offer triple-marker screen and second trimester sonography to identify neural tube defects (NTDs) or other anomalies.
- *Drug monotherapy.* Use a single drug if possible, at the lowest possible dose, to ensure freedom from seizures.
- *Medication levels.* Monitor anticonvulsant levels each trimester and adjust dose as needed. Prevent seizures to minimize maternal and fetal hypoxia.

GLUCOSE INTOLERANCE IN PREGNANCY

A 32-year-old Hispanic multigravida is at 29 weeks' gestation. Her 1-h 50-g glucose screen came back at 175 mg/dl. She is 60 inches tall and weighs 200 pounds. Her pregnancy weight gain has been 30 pounds thus far. Her previous babies weighed 3,800 and 4,200 g.

Definition

A pregnant woman is unable to maintain fasting (FBS) or postchallenge glucose values in the normal pregnant range before or after a standard 100-g glucose challenge.

Risk factors

Obesity, age >30 years, and positive family history are the *most common* risk factors for gestational diabetes. Other risk factors are fetal macrosomia, unexplained stillbirth or neonatal death, polyhydramnios, and previous traumatic delivery.

Classification by pathophysiology

Prevalence of glucose intolerance in pregnancy is 2–3%.

- *Gestational diabetes mellitus (GDM)* is *most common type* with onset during pregnancy, usually diagnosed in the last half. Pathophysiology is the diabetogenic effect of *human placental lactogen (hPL)*, placental insulinase, cortisol, and progesterone. Thirty-five percent of women with GDM will develop overt diabetes within 5 to 10 years after delivery.
- *Type 1 DM* is juvenile onset, ketosis prone, insulin-dependent diabetes caused by pancreatic islet cell deficiency.
- *Type 2 DM* is adult onset, ketosis resistant, non-insulin-dependent diabetes caused by insulin resistance.

Table 8-1. White Classification of Diabetes in Pregnancy

Class A1	GDM with normal FBS not requiring insulin
Class A2	GDM with elevated FBS requiring insulin
Class B	Overt DM onset after age 20 years and duration <10 years
Class C	Overt DM onset age 10–19 years or duration 10–19 years
Class D	Overt DM onset before age 10 years or duration \geq 20 years
Class E	Overt DM with calcified pelvic vessels
Class F	Overt DM with nephropathy
Class R	Overt DM with proliferative retinopathy

Screening

- *Who is screened?* This is performed on *all pregnant women* between 24 and 28 weeks' gestation when the anti-insulin effect of hPL is maximal. On patients *with risk factors* it is performed on the first prenatal visit then repeated at 24–28 weeks if initially negative.
- *What is the test?* The screening test is a 1-h 50-g oral glucose challenge test (OGTT) with normal values being <140 mg/dl. This does not need to be in a fasting state.
- *How are values interpreted?* If the screening value is \geq 140 mg/dl, then proceed to a definitive 3-h 100-g OGTT. If the screening value is \geq 200 mg/dl, and an FBS is \geq 95 mg/dl, GDM is diagnosed and no further OGTT testing is needed.

Diagnosis

- *Who is tested?* The 3-h OGTT is performed on all patients with an abnormal screening test.
- *What is the test?* The definitive diagnosis is based on an abnormal 3-h 100-g OGTT performed after an overnight fast. Four glucose values are obtained.
- *How are values interpreted?* The normal pregnant values are FBS <95 mg/dl, 1 h <180 mg/dl, 2 h <155 mg/dl, 3 h <140 mg/dl. *Impaired glucose tolerance* is diagnosed if only one value is abnormal. *GDM* is diagnosed if at least two values are abnormal.

Antepartum General Management

The most significant factor in management of diabetic pregnancies is achieving maternal euglycemia.

- **American Diabetes Association diet.** Educate patient regarding spreading calories evenly throughout the day, encourage complex carbohydrates. 80% of patients with GDM can maintain glucose control with diet therapy.
- **Home blood glucose monitoring.** Patient checks her own blood glucose values at least four times a day with target values of FBS <90 mg/dl and 1 h after meal of <140 mg/dl.
- **Insulin therapy.** Start subcutaneous insulin with type 1 and type 2 DM and with GDM if home glucose values are consistently above the target range. Initial dose is based on pregnancy trimester. Total daily insulin units equal actual body weight in kilograms times 0.8 (first trimester), 1.0 (second trimester), or 1.2 (third trimester). Insulin is divided with two thirds of total daily dose in morning (split into 2/3 NPH and 1/3 regular) and one third of total daily dose in evening (split into 1/2 NPH and

1/2 regular). Insulin is a large molecule and *does not cross the placenta*. Insulin requirements will normally increase through the course of the pregnancy. 15% of patients with GDM will require insulin.

- **Oral hypoglycemic agents.** These are *contraindicated* because they can cross the placental barrier and may induce fetal or neonatal hypoglycemia.

Antepartum Overt Diabetes Management

- **Hemoglobin A_{1C}.** Obtain a level on the first visit to ascertain degree of glycemic control during the previous 60 days. Repeat levels each trimester.
- **Renal status.** Obtain an early pregnancy baseline 24-h urine collection for total protein and creatinine clearance.
- **Retinal status.** Obtain an early pregnancy ophthalmologic fundoscopic evaluation for proliferative retinopathy.
- **Home blood glucose monitoring.** Patient checks her own blood glucose values at least four times a day with target values of FBS 60–90 mg/dl and 1 h after a meal of <140 mg/dl.

Preconception Anomaly Prevention

- **Anomaly risk.** Women with overt diabetes are at increased risk of fetal anomalies. This risk can be minimized by lifestyle modification.
- **Euglycemia.** Maintaining glucose values at normal levels reduces anomaly risk close to that of nondiabetes. This should be started three months prior to discontinuing contraception.
- **Folate supplementation.** Folic acid, 4 mg a day, should be started 3 months prior to conception to prevent both fetal neural tube defects, as well as congenital heart defects.

Antepartum Fetal Assessment

- **Anomaly screening.** Anomalies are mediated through hyperglycemia and are highest with poor glycemic control during embryogenesis. *Anomalies are not increased in GDM* because hyperglycemia is not present in the first half of pregnancy. *Most common* fetal anomalies with overt DM are *NTD* and *congenital heart disease*. An uncommon anomaly, but one highly specific for overt DM, is *caudal regression syndrome*. Obtain a *triple-marker screen* at 16–18 weeks to assess for NTD as well as a *targeted ultrasound* at 18–20 weeks to look for structural anomalies. If the glycosylated hemoglobin is elevated, order a *fetal echocardiogram* at 22–24 weeks to assess for congenital heart disease.
- **Fetal growth.** Monthly sonograms will assess fetal macrosomia (most commonly seen) or IUGR (seen with longstanding DM and vascular disease).
- **Fetal surveillance.** Start weekly NSTs and amniotic fluid index (AFIs) *at 32 weeks* if taking insulin, macrosomia, previous stillbirth, or hypertension. Start NSTs and AFIs *at 26 weeks* if small vessel disease is present or there is poor glycemic control. Biophysical profiles can be performed at the time of monthly sonograms.

Intrapartum Management

- **Timing of delivery.** Fetal maturity is often delayed in fetuses of diabetic mothers. Yet prolonging the pregnancy may increase the risk of stillbirth. Delivery planning is a result of balancing these two factors. The target delivery gestational age is 40 weeks,

but may be necessary earlier in the presence of fetal jeopardy and poor maternal glycemic control. An amniotic fluid *lecithin to sphingomyelin (L/S) ratio* of 2.5 in the presence of *phosphatidyl glycerol* assures fetal lung maturity.

- **Mode of delivery.** The cesarean section rate in diabetic pregnancies approaches 50% because of fetal macrosomia, arrest of labor, and concern regarding shoulder dystocia.
- **Glycemic control.** Maintain maternal blood glucose levels between 80 and 100 mg/dl using 5% dextrose in water and an insulin drip.

Postpartum Management

- **Postpartum hemorrhage.** Watch for uterine atony related to an overdistended uterus.
- **Hypoglycemia.** Turn off any insulin infusion because insulin resistance decreases with rapidly falling levels of hPL after delivery of the placenta. Maintain blood glucose levels with a sliding scale.

Neonatal Problems

- **Hypoglycemia** caused by persistent hyperinsulinemia from excessive prenatal transplacental glucose.
- **Hypocalcemia** caused by failure to increase parathyroid hormone synthesis after birth.
- **Polycythemia** caused by elevated erythropoietin from relative intrauterine hypoxia.
- **Hyperbilirubinemia** caused by liver immaturity and breakdown of excessive neonatal red blood cells (RBCs).
- **Respiratory distress syndrome** caused by delayed pulmonary surfactant production.

ANEMIA IN PREGNANCY

An 18-year-old woman G3 P2 had prenatal laboratory tests drawn when she was seen for her first prenatal visit at 18 weeks' gestation. The complete blood count showed the following: hemoglobin 9.5 g/dl, hematocrit 28%, MCV 75, and RDW 17.0. Her first child was delivered 2 years ago, with her second child born 1 year ago.

Definition. A hemoglobin concentration of <10 g/dl during pregnancy or the puerperium. This is less than the 12 g/dl, which is the lower limits of normal in the nonpregnant woman.

Iron Deficiency Anemia

This is a nutritional anemia resulting in decreased heme production. *It is the most common anemia in women because of menstrual and pregnancy needs.*

Diagnosis. RBCs are microcytic and hypochromic. Hemoglobin ≤ 10 g/dl, MCV <80, RDW >15.

Pathophysiology. Falling hemoglobin values do not occur until complete depletion of iron stores in the liver, spleen, and bone marrow, which is followed by a decrease in serum iron with increase in total iron binding capacity (TIBC).

Pregnancy Requirements. A pregnant woman needs 800 mg of elemental iron, of which 500 mg goes to expand the RBC mass and 300 mg goes to the fetal-placental unit.

Risk Factors. Chronic bleeding, poor nutrition, and frequent pregnancies.

Symptoms. Findings may vary from none to general malaise, palpitations, and ankle edema.

Fetal Effects. There are none as iron is actively transported across the placenta to the fetus.

Treatment. FeSO₄ 325 mg po tid.

Prevention. Elemental iron 30 mg per day.

Folate Deficiency Anemia

This is a nutritional anemia resulting in decreased heme production

Diagnosis. RBCs are macrocytic. Hemoglobin ≤ 10 g/dl, MCV > 100 , RDW > 15 . RBC folate levels are low. Peripheral smear may show hypersegmented neutrophils.

Pathophysiology. Folate stores in the body are usually enough for 90 days. Falling hemoglobin values do not occur until complete depletion of folate stores.

Risk Factors. Chronic hemolytic anemias (e.g., sickle cell disease), anticonvulsant use (phenytoin, phenobarbital), and frequent pregnancies.

Symptoms. Findings may vary from none to general malaise, palpitations, and ankle edema.

Fetal Effects. Low birth-weight infants; NTDs may be increased.

Treatment. Folate 1 mg po daily.

Prevention. Folate 0.4 mg po daily for all women; 4 mg po daily for those at high risk for NTDs.

Sickle Cell Anemia

This is an inherited autosomal recessive disease resulting in normal production of *abnormal globin chains*.

Screening Test. These are peripheral blood tests used to detect the presence or absence of hemoglobin S. They do not differentiate between disease and trait.

Diagnostic Test. A hemoglobin electrophoresis will differentiate between SA trait ($< 40\%$ hemoglobin S) or SS disease ($> 40\%$ hemoglobin S).

Risk Factors. African and Mediterranean descent is the only significant risk factor for sickle cell anemia.

Effects on Pregnancy.

- *With SA*, the patient may have increased urinary tract infections (UTIs), but pregnancy outcome is not changed.
- *With SS*, the pregnancy may be complicated by increased spontaneous abortions, IUGR, fetal deaths, and preterm delivery.

Treatment. *Avoid hypoxia*, take folate supplements, and monitor fetal growth and well-being.

URINARY TRACT INFECTION IN PREGNANCY

A 23-year-old primigravida at 31 weeks' gestation comes to the birthing unit with complaints of flank pain, nausea, vomiting, and shaking chills for the past 12 h. She has been diagnosed with sickle cell trait. On examination her temperature is 103°F, pulse is 125 beats/min, and respirations are 30 breaths/min. Her skin is grossly diaphoretic, and she has exquisite right costovertebral angle tenderness. Electronic fetal monitor shows a baseline heart rate of 170 beats/min with reactivity. Uterine contractions are noted every 10 min.

Definition. UTIs may involve either the *lower tract* (including the bladder or urethra) or the *upper tract* (including the kidney). The *most common organisms* are gram-negative enteric bacteria with *Escherichia coli* the most frequent.

Risk Factors. Pregnancy is a risk factor. Others include mechanical urinary obstructions and systemic diseases (such as sickle cell trait/disease, diabetes mellitus, and gout).

Asymptomatic Bacteriuria

This is the *most common UTI* in pregnancy.

Clinical Findings. No symptoms or signs are present.

Significance. If not treated, 30% of cases will develop acute pyelonephritis.

Diagnosis. Made with a positive urine culture showing >100K colony-forming units (CFU) of a single organism.

Treatment. Single-agent, outpatient oral antibiotics.

Acute Cystitis

This is a UTI localized to the bladder without systemic findings.

Clinical Findings. Urgency, frequency, and burning are common.

Significance. If not treated, 30% of cases will develop acute pyelonephritis.

Diagnosis. Made with a positive urine culture showing >100K CFU of a single organism.

Treatment. Single-agent, outpatient oral antibiotics.

Acute Pyelonephritis

This is a UTI involving the upper urinary tract with systemic findings. This is one of the *most common* serious medical complications of pregnancy.

Symptoms. Include shaking chills, anorexia, nausea, vomiting, and flank pain.

Signs. Include high fever, tachycardia, and costovertebral angle tenderness (R>L).

Significance. Preterm labor and delivery can occur. Severe cases are complicated by sepsis, anemia, and pulmonary dysfunction, sometimes requiring ICU care, including intubation.

Diagnosis. Confirmed with a positive urine culture showing >100K CFU of a single organism.

Treatment. *Hospital admission*, generous IV hydration, parenteral antibiotics, and tocolysis as needed.

Intrapartum Events

9

ANATOMY OF THE BONY PELVIS

Bones

The pelvis is constructed of *four bones*: ileum superior-laterally, ischium inferior-laterally, pubis anteriorly, and the sacrum and coccyx posteriorly.

Joints

It is held together by the following *four joints*: bilateral sacroiliac joints, the symphysis pubis, and the sacrococcygeal joint. The sacrum has five vertebrae joined together. The anterior superior edge of the first sacral vertebra is called the *sacral promontory*.

Landmarks

The pelvis is divided by the *linea terminalis* into the false pelvis above and the true pelvis below. The *false pelvis* is bordered by lumbar vertebrae posteriorly, by the iliac fossa laterally, and by the abdominal wall anteriorly. The *true pelvis* is a bony canal formed by posterior sacrum and coccyx, lateral ischial, and anterior pubis.

TYPES OF PELVIC SHAPES

Gynecoid Shape

This is the *classic female pelvis* and is found in 50% of women. The inlet is a round oval with largest diameter transverse. It has straight side walls, well-curved sacrum, and spacious subpubic arch with a 90° angle. *Assessment*: This pelvis is *spacious* for the fetal head to pass through.

Android Shape

This is the *typical male pelvis* and is found in 30% of women. The inlet is triangular with convergent side walls, shallow sacral curve, and narrow subpubic arch. *Assessment*: This pelvis is *restricted* at all levels. Arrest of descent in labor is common.

Anthropoid Shape

This pelvis resembles that of anthropoid apes and is found in 20% of women. The inlet is larger anterior-posteriorly with side walls that converge. Subpubic arch is narrow. *Assessment*: The fetal head *engages anterior-posteriorly*, often in occiput posterior position, making *delivery difficult*.

Platypelloid Shape

This is like a flattened gynecoid pelvis. The inlet is an elongated transverse oval. It has straight side walls with deep sacral curve and wide subpubic arch. *Assessment:* The fetal head *engages transversely* and *delivers occiput transverse* position.

FETAL ORIENTATION IN UTERUS

Lie

Orientation of the long axis of the fetus to the long axis of the uterus. The *most common* lie is *longitudinal*.

- **Longitudinal:** fetus and mother are in same vertical axis
- **Transverse:** fetus at right angles to mother
- **Oblique:** fetus at 45° angle to mother

Presentation

Portion of the fetus overlying the pelvic inlet. *The most common presentation is cephalic.*

- **Cephalic:** head presents first
- **Breech:** feet or buttocks present first. *Frank* breech means thighs are flexed and legs extended. This is the only kind of breech that potentially could be safely delivered vaginally. *Complete* breech means thighs and legs flexed. *Footling* breech means thighs and legs extended. The major risk of vaginal breech delivery is entrapment of the after-coming head.
- **Compound:** more than one anatomic part is presenting (e.g., head and upper extremity)
- **Shoulder:** presents first

Position

Relationship of a definite fetal part to the maternal bony pelvis. It is expressed in terms stating whether the orientation part is anterior or posterior, left or right. The *most common* position at delivery is *occiput anterior*.

- **Occiput:** with a flexed head (cephalic presentation)
- **Sacrum:** with a breech presentation
- **Mentum (chin):** with an extended head (face presentation)

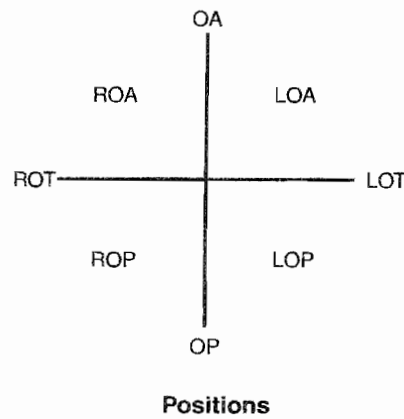
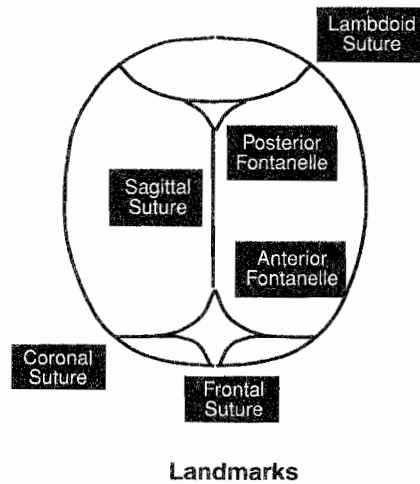


Figure 9-1. Landmarks and Positions

Attitude

Degree of extension-flexion of the fetal head. *The most common attitude is vertex.*

- **Vertex:** head is maximally flexed
- **Military:** head is partially flexed
- **Brow:** head is partially extended
- **Face:** head is maximally extended

Station

Degree of descent of the presenting part through the birth canal; expressed in centimeters above or below the maternal ischial spine.

OVERVIEW OF LABOR

Definition. Labor is a process whereby with time regular uterine contractions bring about progressive effacement and dilation of the cervix, resulting in delivery of the fetus and expulsion of the placenta. Contractions will occur at least every 5 min lasting 30 s.

Physiology. Increasing frequency of contractions is associated with formation of *gap junctions* between uterine myometrial cells. These events are correlated with increasing levels of *oxytocin* and *prostaglandins* along with multiplication of specific *receptors*.

Uterine Changes. The contractile *upper uterine segment*, containing mostly smooth muscle fibers, becomes thicker as labor progresses, exerting forces that expel the fetus down the birth canal. The *lower uterine segment*, containing mostly collagen fibers, passively thins out with contractions of the upper segment.

Cervical Effacement. Cervical softening and thinning occur as increasing levels of oxytocin and prostaglandins lead to breakage of *disulfide linkages* of collagen fibers, resulting in increasing water content. Effacement is often expressed in percentages with the uneffaced (0%) cervix assumed to be 2 cm long and 2 cm wide. Progressive shortening and thinning lead to full effacement (100%) in which the cervix has no length and is paper-thin.

Cervical Dilation. This occurs as the passive lower uterine segment is thinned and pulled up by the contractile upper segment. In early labor (latent phase), the rate of dilation is slow, but at 3–4 cm of dilation, the rate accelerates to a maximum rate in the active phase of labor. Complete dilation is expressed as 10 cm.

Cardinal Movements of Labor. The first three steps occur simultaneously.

1. *Engagement:* movement of the presenting part below the plane of the pelvic inlet.
2. *Descent:* movement of the presenting part down through the curve of the birth canal.
3. *Flexion:* placement of the fetal chin on the thorax.
4. *Internal rotation:* rotation of the position of the fetal head in the mid pelvis from transverse to anterior-posterior.
5. *Extension:* movement of the fetal chin away from the thorax.
6. *External rotation:* rotation of the fetal head outside the mother as the head passes through the pelvic outlet.
7. *Expulsion:* delivery of the fetal shoulders and body.

STAGES OF LABOR

Stage One

This begins with onset of regular uterine contractions and ends with complete cervical dilation at 10 cm. It is divided into a *latent* and an *active* phase.

Latent phase

This begins with onset of regular contractions and ends with the acceleration of cervical dilation. Its *purpose* is to prepare the cervix for rapid dilation through effacement. Essentially no descent of the fetus occurs. *Duration* may be up to 20 h in a primipara and up to 14 h in a multipara. *Abnormalities* include prolonged latent phase.

Active phase

This begins with cervical dilation acceleration, usually at 3–4 cm of dilation, ending with complete cervical dilation. Its *purpose* is rapid cervical dilation. The *cardinal movements of labor* occur, with beginning descent of the fetus in the latter part of the active phase. The *rate of dilation* is at least 1.2 cm/h in a primipara and 1.5 cm/h in a multipara. *Abnormalities* include prolonged active phase or arrest of active phase.

Stage Two

This begins with complete cervical dilation and ends with delivery of the fetus. Its *purpose* is descent of the fetus through the birth canal as maternal pushing efforts augment the uterine contractions. *Duration* may be up to 2 h in a primipara and 1 h in a multipara. *Abnormalities* include prolonged second stage or arrest of descent.

Stage Three

This begins with delivery of the fetus and ends with expulsion of the placenta. Placental separation from the uterine wall occurs as myometrial contractions shear off the anchoring villi. This is often augmented with IV oxytocin infusion. *Signs of the third stage* include gush of blood vaginally, change of the uterus from long to globular, “lengthening” of the umbilical cord. *Duration* may be up to 30 min in all women. *Abnormalities* include prolonged third stage.

Stage “Four”

This is a 1- to 2-h period of close observation of the parturient immediately after delivery when vital signs and vaginal bleeding are monitored for onset of preeclampsia and postpartum hemorrhage.

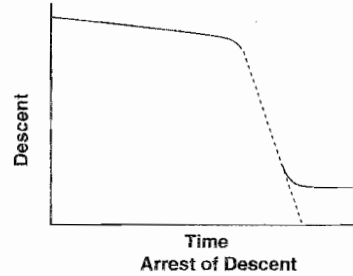
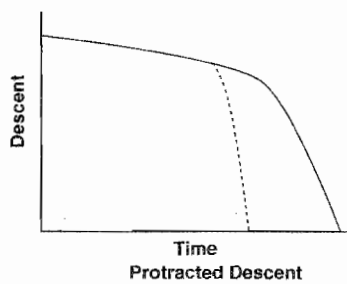
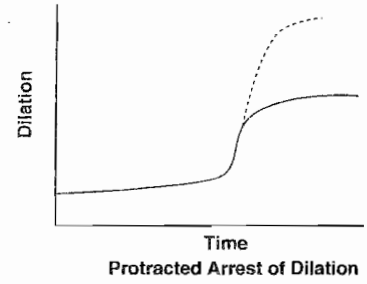
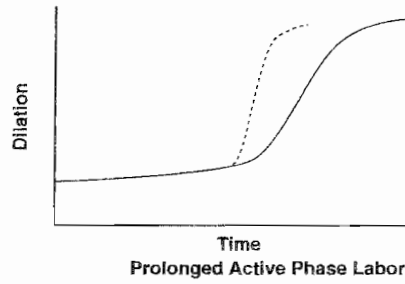
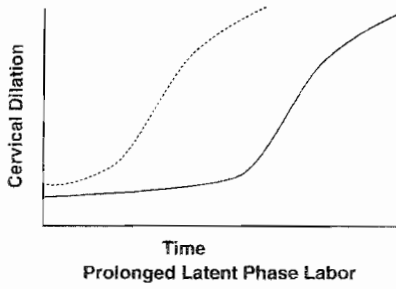
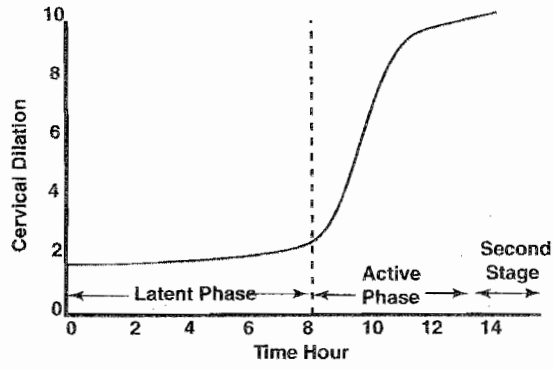


Figure 9-2. Stages of Labor

CONDUCT OF NORMAL SPONTANEOUS LABOR

A 20-year-old primigravida comes to the maternity unit at 39 weeks' gestation complaining of regular uterine contractions every 3 min for the past 6 h. The contractions are becoming more frequent. She denies any vaginal fluid leakage. Her vital signs: blood pressure (BP) is 125/75, pulse 80 beats/min, respirations 17 breaths/min. On pelvic examination the fetus is cephalic presentation at -1 station. Her cervix is 5 cm dilated, 90% effaced, and soft and anterior in position. On the electronic fetal monitor (EFM) the fetal heart rate baseline is 135 beats/min with good variability, frequent accelerations, and no decelerations. How will you manage this patient?

Preadmission

The parturient is not admitted to the maternity unit until cervical dilation is at least 3 cm, unless premature membrane rupture has occurred. Fetal presentation is confirmed to be cephalic.

Admission

On admission intravenous access is established, and oral clear liquid may be ingested. The patient is allowed whatever position is comfortable; however, the lateral recumbent position is encouraged as it optimizes uteroplacental blood flow.

First Stage

The fetal heart rate is assessed, usually with continuous electronic monitoring. Cervical dilation and fetal head descent are followed through appropriately spaced vaginal examinations. Amniotomy is performed in the active phase when the fetal head is well applied to the cervix. Obstetric analgesia is administered at patient request.

Second and Third Stages

Maternal pushing efforts augment uterine contractions in the second stage of labor. An episiotomy is not routine, but is performed as indicated. After delivery of the fetus, the placenta is allowed to spontaneously separate, after which IV oxytocin is administered to prevent uterine atony and bleeding.

Recovery Period

For 1–2 h postpartum the parturient is observed closely for excessive bleeding and development of preeclampsia.

ABNORMAL LABOR

Prolonged Latent Phase

A 20-year-old primigravida at 39 weeks' gestation is being observed in the maternity unit. She states she has been having irregular uterine contractions for 24 h but cervical dilation remains at 1–2 cm. Her vital signs are stable. EFM tracing is reassuring regarding fetal status.

Diagnosis. Cervical dilation is ≤ 3 cm, and the acceleration phase of dilation has not been reached. Duration has extended to >20 h in a primipara or to >14 h in a multipara.

Cause. Latent-phase abnormalities are most commonly caused by injudicious analgesia. Other causes are contractions, which are hypotonic (inadequate frequency, duration, or intensity) or hypertonic (high intensity but inadequate duration or frequency).

Management. This involves therapeutic rest and sedation with narcotics or sedatives.

Prolonged or Arrested Active Phase

A 20-year-old primigravida at 39 weeks' gestation has progressed in labor to 8 cm of cervical dilation but has not changed for 3 h. Her vital signs are stable. EFM tracing is reassuring regarding fetal status.

Diagnosis. Cervical dilation is ≥ 3 cm, or the acceleration phase of dilation has been reached. *Prolongation* is diagnosed if cervical dilation is <1.2 cm/h in a primipara or <1.5 cm/h in a multipara. *Arrest* is diagnosed if cervical dilation has not changed for ≥ 2 h.

Causes. Active-phase abnormalities may be caused by either abnormalities of the *passenger* (excessive fetal size or abnormal fetal orientation in the uterus), abnormalities of the *pelvis* (bony pelvis size), or abnormalities of *powers* (dysfunctional or inadequate uterine contractions).

Management. This is directed at assessment of uterine contraction quality. Contractions should occur every 2–3 min, last 45–60 s with 50 mm Hg intensity. If contractions are hypotonic, IV oxytocin is administered. If contractions are hypertonic, give morphine sedation. If contractions are adequate, proceed to emergency cesarean section.

Prolonged Second Stage

A 20-year-old primigravida at 39 weeks' gestation has progressed in labor to 10 cm of cervical dilation and has been pushing for the past 3 h without descent of the fetal head beyond +2 station. Her vital signs are stable. EFM tracing is reassuring regarding fetal status.

Diagnosis. Failure to deliver the baby in 2 hours (primipara) or 1 hour (multipara). With epidural analgesia add additional 1 hour.

Cause. Same as active-phase abnormalities: *passenger, pelvis, or powers*.

Management. Involves assessment of uterine contractions and maternal pushing efforts. Use IV oxytocin or enhanced coaching as needed. If they are both adequate, assess whether the fetal head is engaged. If the head is not engaged, proceed to emergency cesarean. If the head is engaged, consider a trial of either obstetric forceps or a vacuum extractor delivery.

Prolonged Third Stage

A 20-year-old primigravida at 39 weeks' gestation underwent a spontaneous vaginal delivery 40 min ago of a healthy 3,500-g daughter. However, the placenta has still not delivered. Her vital signs are stable.

Diagnosis. Failure to deliver the placenta within 30 minutes.

Cause. May be inadequate uterine contractions. If the placenta does not separate, in spite of IV oxytocin stimulation of myometrium contractions, think of abnormal placental implantation (e.g., placenta *accreta*, placenta *increta*, and placenta *percreta*).

Management. May require manual placental removal or rarely even hysterectomy.

OBSTETRIC COMPLICATIONS

Prolapsed Umbilical Cord

A 34-year-old multigravida with a known uterine septum comes to the maternity unit at 34 weeks' gestation complaining of regular uterine contractions. She underwent a previous cesarean at 37 weeks' gestation for breech presentation. You perform a pelvic examination. You find the fetus is a footling breech. Her cervix is 6 cm dilated with bulging membranes. As you are examining her, her bag of waters suddenly ruptures, and a loop of umbilical cord protrudes through the cervix between the fetal extremities.

Umbilical cord prolapse is an obstetric emergency because if the cord gets compressed, fetal oxygenation will be jeopardized, with potential fetal death.

Prolapse can be *occult* (the cord has not come through the cervix but is being compressed between the fetal head and the uterine wall), *partial* (the cord is between the head and the dilated cervical os but has not protruded into the vagina), or *complete* (the cord has protruded into the vagina).

Risk Factors. Rupture of membranes with the presenting fetal part not applied firmly to the cervix, malpresentation.

Management. Do not hold the cord or try to push it back into the uterus. Place the patient in knee-chest position, elevate the presenting part, avoid palpating the cord, and perform immediate cesarean delivery.

Shoulder Dystocia

A 20-year-old primigravida at 39 weeks' gestation was pushing in the second stage of labor for 90 min and has just delivered the fetal head. However, in spite of vigorous pushing efforts by the mother, and moderate traction on the fetal head, you are unable to deliver the anterior shoulder. Since delivery of the fetal head, 30 s has passed. The fetal heart rate is now 70 beats/min.

Diagnosis. This diagnosis is made when delivery of the fetal shoulders is delayed after delivery of the head. It is usually associated with fetal shoulders in the anterior-posterior plane, with the anterior shoulder impacted behind the pubic symphysis. It occurs in 1% of deliveries and may result in permanent neonatal neurologic damage in 2% of cases.

Risk Factors. Include *maternal diabetes*, obesity, and postdates pregnancy, which are associated with fetal macrosomia. Even though incidence increases with birth weight, half of shoulder dystocias occur in fetuses <4,000 grams.

Management. Includes suprapubic pressure, maternal thigh flexion (McRobert's maneuver), internal rotation of the fetal shoulders to the oblique plane (Wood's "corkscrew" maneuver), manual delivery of the posterior arm, and Zavanelli maneuver (cephalic replacement).

Lacerations

Vaginal, cervical, vulvar, and perineal lacerations should be identified by careful physical examination after each delivery and repaired. Perineal lacerations are classified according to degree.

- *First degree:* involves only the perineal mucosa and can be managed conservatively if they are not bleeding.
- *Second degree:* involves the muscles of the perineal body but does not extend to the rectal sphincter.
- *Third degree:* involves the rectal sphincter but not the rectal mucosa.
- *Fourth degree:* involves the rectal mucosa. (Careful suturing in layers is required to prevent rectovaginal fistula formation.)

FETAL HEART RATE (FHR) MONITORING

Normal FHR findings are highly reassuring of fetal well-being. Abnormal FHR findings are poor predictors of fetal compromise. Wide usage of electronic FHR monitoring has not lowered the rate of cerebral palsy (CP) because the antecedents of CP appear not to be intrapartum events but rather antenatal events.

Modalities of Labor Monitoring

Both of the following modalities are equivalent in predicting fetal outcome.

- *Intermittent auscultation* of FHR is performed with a fetoscope using auditory FHR counting averaged for 10–15 s.
- *Electronic monitoring* measures the milliseconds between consecutive cardiac cycles giving an instantaneous FHR continuously.

External Devices

These are placed on the uterine fundus and are the *most common* devices used. *Advantages* are utilization before significant cervical dilation and membrane rupture. *Disadvantages* include poor quality tracing with maternal obesity, and maternal discomfort from the device belts.

- **Fetal.** A continuous ultrasound transducer picks up fetal cardiac motion but can also register maternal great vessel movement.
- **Contractions.** A tocographic transducer device senses the change in uterine wall muscle tone. It can measure the beginning and ending of contractions but cannot assess contraction intensity.

Internal Devices

These are placed through the dilated cervix. *Advantages* include optimum signal quality, which is unaffected by maternal obesity. *Disadvantages* include limitation to labor when cervical dilation and membrane rupture have occurred.

- **Fetal.** A direct scalp electrode precisely senses each QRS complex of the fetal cardiac cycle. Complications can include fetal scalp trauma and infection.
- **Contractions.** An intrauterine pressure catheter (IUPC), placed into the uterine cavity, precisely registers intrauterine hydrostatic changes with each contraction.

EVALUATION OF FETAL MONITOR TRACINGS

Baseline Heart Rate

This is the mean FHR during a 10-min segment of time excluding periodic changes: Normal values are between 110 and 160 beats/min.

Bradycardia

This is diagnosed when FHR is <110 beats/min. Nonhypoxic explanations may be maternal or fetal.

- **Maternal medications:** β -adrenergic blockers, local anesthetics.
- **Fetal arrhythmia:** congenital heart block (associated with maternal lupus).
- **Interpretation:** unexplained bradycardia is nonreassuring.

Tachycardia

This is diagnosed when FHR is >160 beats/min. Nonhypoxic explanations may be maternal or fetal.

- **Maternal:** medications (β -adrenergic agonists [terbutaline, ritodrine]), fever, thyrotoxicosis.
- **Fetal:** repetitive accelerations from movements, fetal arrhythmia, prematurity.
- **Interpretation:** unexplained tachycardia is nonreassuring.

Periodic Changes

These are visually apparent *temporary* variations from the baseline FHR, often related to contractions. They include both accelerations and decelerations.

Accelerations

These are *abrupt* increases in FHR above the baseline lasting <2 min and are unrelated to contractions. The criteria vary by gestational age: <32 weeks the increase should be ≥ 10 beats/min lasting ≥ 10 s; ≥ 32 weeks the increase should be ≥ 15 beats/min lasting ≥ 15 s.

- They are mediated by the *sympathetic* nervous system and always occur in response to *fetal movements*.
- **Interpretation:** accelerations are always reassuring.

Early decelerations

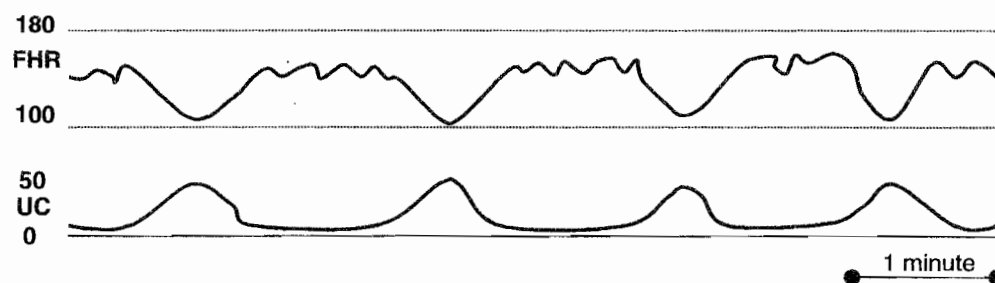
- These are *gradual* decreases in FHR below the baseline beginning and ending *simultaneously* with contractions. They are mediated by *vagal* stimulation and occur in response to *fetal head compression*.
- **Interpretation:** early decelerations have no impact on clinical outcome.

Variable decelerations


- These are *abrupt* decreases in FHR below the baseline of at least 15 beats/min with onset to nadir of <30 s. They are *variable* in relation to contractions.
- They are mediated by *vagal* stimulation and occur in response to *umbilical cord compression*. Mild variables drop 15–40 beats/min. Moderate variables drop 40–60 beats/min. Severe variables drop >60 beats/min or last ≥ 60 s.
- **Interpretation:** mild to moderate variables have no impact on clinical outcome. Severe variables are nonreassuring and may be associated with fetal acidosis.

Late decelerations

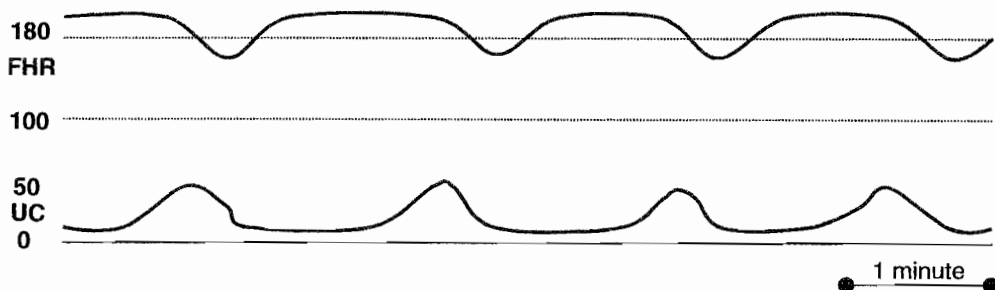
- These are *gradual* decreases in FHR below the baseline with onset to nadir of ≥ 30 s. The deceleration onset and end is *delayed* in relation to contractions. They are mediated by either *vagal stimulation* or *myocardial depression* and occur in response to *uteroplacental insufficiency*.
- *All late decelerations are nonreassuring and may be associated with fetal acidosis.*



Early Decelerations – head compression



Variable Decelerations – umbilical cord compression



Late Decelerations – uteroplacental insufficiency

Figure 9-3

Variability

These describe baseline FHR fluctuations in amplitude and frequency of ≥ 2 cycles/min. Variability is a reflection of normal healthy autonomic interplay between the sympathetic and parasympathetic nervous systems. Classification criteria include the following:

- **Absent:** variability is undetectable. This finding is nonreassuring.
- **Minimal:** ≤ 5 beats/min.
- **Moderate:** 6–25 beats/min. This is considered *normal* variability.
- **Marked:** >25 beats/min.

CRITERIA FOR FETAL MONITOR TRACING

Terminology. The terms *normal tracing* and *fetal distress* are imprecise and nonspecific and should not be used. It is best to use the terms *reassuring fetal status* or *nonreassuring fetal status*, followed by a description of the findings.

Criteria for Reassuring FHR Tracing

- Baseline rate is between 110 and 160 beats/min.
- Accelerations are present.
- Decelerations are absent.
- Variability is present.

Criteria for Nonreassuring FHR Tracing

- Baseline rate shows tachycardia or bradycardia without explanation.
- Accelerations are absent.
- Repetitive variable decelerations, if severe, are seen.
- There are repetitive late decelerations of any magnitude.
- Variability is absent.

INTRAUTERINE RESUSCITATION MEASURES

Decrease uterine contractions: Turn off any IV oxytocin infusion or administer terbutaline 0.25 mg subcutaneously to enhance intervillous placental blood flow.

Augment IV fluid volume: Infuse the parturient with a 500 ml bolus of intravenous normal saline rapidly to enhance uteroplacental perfusion.

Administer high-flow oxygen: Give the parturient 8–10 L of oxygen by facemask to increase delivery of maternal oxygen to the placenta.

Change position: Removing the parturient from the supine position decreases inferior vena cava compression and enhances cardiac return, thus cardiac output to the placenta. Turning the parturient from one lateral position to the other may relieve any umbilical cord compression that may be present.

Vaginal examination: Perform a digital vaginal examination to rule out possible prolapsed umbilical cord.

Scalp stimulation: Perform a digital scalp stimulation observing for accelerations, which would be reassuring of fetal condition.

FETAL pH ASSESSMENT

Intrapartum

This may be used in labor if the EFM strip is equivocal. Prerequisites include cervical dilation, ruptured membranes, and adequate descent of the fetal head. Contraindications are suspected fetal blood dyscrasia. A small, shallow fetal scalp incision is made resulting in capillary bleeding. The blood is collected in a heparinized capillary tube and sent to the laboratory for blood gas analysis. Normal fetal pH is ≥ 7.20 .

Postpartum

This is used to confirm fetal status at delivery and involves obtaining both umbilical cord venous and arterial samples. Arterial pH, PCO_2 , and HCO_3 values are higher than venous, but PO_2 is lower. Normal fetal pH is ≥ 7.20 .

APPROACH TO NONREASSURING EFM PATTERNS

A 20-year-old primigravida at 39 weeks' gestation is in active labor at 7 cm of cervical dilation. The EFM strip shows a baseline heart rate of 175 beats/min, and variability is 7 beats/min, but repetitive late decelerations are seen after each contraction. No accelerations are noted.

Recognize that most "abnormal" tracings are not caused by fetal hypoxia. Ask whether the tracing has biologic plausibility.

- *Examine the EFM strip* carefully looking for baseline heart rate, degree of variability, and presence of periodic changes (accelerations, decelerations).
- *Confirm abnormal findings* using criteria discussed above.
- *Identify nonhypoxic causes* present that could explain the abnormal findings.
- *Initiate the intrauterine resuscitation measures* described previously to enhance placental perfusion and fetal oxygenation.
- *Observe for normalization* of the EFM tracing.
- *Prepare for delivery* promptly if the resuscitation measures do not normalize the EFM tracing.

Specific Interventions If Immediate Delivery Is Indicated

- In stage one of labor, the only option is emergency cesarean section.
- In stage two of labor, an operative vaginal delivery (e.g., vacuum extractor assisted or obstetrical forceps) may be appropriate, or an emergency cesarean section must be performed.

OPERATIVE OBSTETRICS

Definition. This refers to any method used to deliver the fetus other than uterine contractions and maternal pushing efforts. It may include vaginal or cesarean routes.

Obstetric Forceps

Definition. These are metal instruments used to provide traction, rotation, or both to the fetal head.

- *Simpson:* used for traction only.
- *Kjelland:* used for head rotation and traction.
- *Piper:* used for the after-coming head of a vaginal breech baby.
- *Barton:* used to deliver the head in occiput transverse position with a platypelloid pelvis.

Classification

- *Outlet:* fetal head is on the pelvic floor. Most forceps use is in this category.
- *Low:* fetal head is below +2 station, but has not reached the pelvic floor.
- *Mid:* fetal head is below 0 station, but has not reached +2 station. This is seldom used today.
- *High:* fetal head is unengaged, above 0 station. This is never appropriate in modern obstetrics because of the risk to both mother and fetus.

Indications

- *Prolonged second stage.* This may be because of dysfunctional labor or suboptimal fetal head orientation. This is the *most common* indication for forceps.
- *Nonreassuring EFM strip.* The fetal heart rate monitor pattern suggests the fetus is not tolerating labor.
- *Avoid maternal pushing.* These include a variety of conditions in which pushing efforts may be hazardous to the parturient, e.g., cardiac, pulmonary, or neurologic disorders.
- *Breech presentation.* Shorten the time to deliver the head of a vaginal breech fetus.

Prerequisites

- Clinically adequate pelvic dimensions
- Experienced operator
- Full cervical dilation
- Engaged fetal head
- Orientation of fetal head is certain

Complications

- *Maternal:* lacerations to the vagina, cervix, perineum, and uterus.
- *Fetal-neonatal:* soft-tissue compression or cranial injury caused by incorrectly placed forceps blades.

Vacuum Extractor

Definition. These are cuplike instruments that are held against the fetal head with suction. Traction is thus applied to the fetal scalp, which along with maternal pushing efforts, results in descent of the head leading to vaginal delivery. The cups may be metal or plastic, rigid or soft.

Advantages Over Forceps

- *Fetal head orientation.* Precise knowledge of fetal head position and attitude is not essential.
- *Space required.* The vacuum extractor does not occupy space adjacent to the fetal head.
- *Perineal trauma.* Third- and fourth-degree lacerations are fewer.
- *Head rotation.* Fetal head rotation occurs spontaneously at the station best suited to fetal head configuration and maternal pelvis.

Disadvantages Over Forceps

- *Cup pop-offs.* Excessive traction can lead to sudden decompression as the cup suction is released.
- *Scalp trauma.* Scalp skin injury and lacerations are common.
- *Subgaleal hemorrhage and intracranial bleeding* are rare.
- *Neonatal jaundice* arises from scalp bleeding.

Indications Are Similar to Those of Forceps

- *Prolonged second stage.* This may be because of dysfunctional labor or suboptimal fetal head orientation.
- *Nonreassuring EFM strip.* The FHR monitor pattern suggests the fetus is not tolerating labor.
- *Avoid maternal pushing.* These include a variety of conditions in which pushing efforts may be hazardous to the parturient, e.g., cardiac, pulmonary, or neurologic disorders.

Prerequisites

- Clinically adequate pelvic dimension
- Experienced operator
- Full cervical dilation
- Engaged fetal head
- Gestational age is ≥ 34 weeks

Complications

- *Maternal:* vaginal lacerations from entrapment of vaginal mucosa between the suction cup and fetal head.
- *Neonatal:* neonatal *cephalohematoma* and scalp lacerations are common; life-threatening complications of *subgaleal hematoma* or *intracranial hemorrhage*, although uncommon, are associated with vacuum duration >10 min.

CESAREAN SECTION

Definition. This describes a procedure in which the fetus is delivered through incisions in the maternal anterior abdominal and uterine walls. The overall US cesarean section rate is approximately 22%, which includes both primary and repeat procedures.

Risks. Maternal mortality and morbidity is higher than with vaginal delivery, especially with emergency cesareans performed in labor. Maternal mortality is largely anesthetic related with overall mortality rate of 25 per 100,000.

- *Hemorrhage:* Blood loss is twice that of a vaginal delivery with mean of 1,000 ml.
- *Infection:* Sites of infection include endometrium, abdominal wall wound, pelvis, urinary tract, or lungs. Prophylactic antibiotics can decrease infectious morbidity.
- *Visceral injury:* Surrounding structures can be injured (e.g., bowel, bladder, and ureters).
- *Thrombosis:* Deep venous thrombosis is increased in the pelvic and lower extremity veins.

Uterine Incisions

- *Low segment transverse.* This incision is made in the noncontractile portion of the uterus and is the one most commonly used. The bladder must be dissected off the lower uterine segment. It has a low chance of uterine rupture in subsequent labor (0.5%).
 - *Advantages* are trial of labor in a subsequent pregnancy is safe; the risk of bleeding and adhesions is less.
 - *Disadvantages* are the fetus(es) must be in longitudinal lie; the lower segment must be developed.
- *Classical.* This incision is made in the contractile fundus of the uterus and is less commonly performed. Technically it is easy to perform, and no bladder dissection is needed. Risk of uterine rupture both before labor as well as in subsequent labor is significant (5%). Repeat cesarean should be scheduled before labor onset.
 - *Advantages* are any fetus(es) regardless of intrauterine orientation can be delivered; lower segment varicosities or myomas can be bypassed.
 - *Disadvantages* are trial of labor in a subsequent pregnancy is unsafe; the risk of bleeding and adhesions is higher.

Indications for Primary Cesarean Section

- *Cephalopelvic disproportion (CPD).* This is the *most common indication* for cesarean delivery. This term literally means the pelvis is too small for the fetal head. In actual practice, it most commonly indicates failure of the adequate progress in labor, which may be related to dysfunctional labor or suboptimal fetal head orientation.
- *Fetal malpresentation.* This refers most commonly to *breach* presentation, but also means any fetal orientation other than cephalic.
- *Nonreassuring EFM strip.* The FHR monitor pattern suggests the fetus may not be tolerating labor, but commonly this is a false-positive finding.

Vaginal Birth After Cesarean (VBAC).

- Successful vaginal delivery rate is 80% in carefully selected patients.
- Criteria for trial of labor include patient consent, nonrepetitive cesarean indication (e.g., breech, placenta previa), previous low segment transverse uterine incision, clinically adequate pelvis.

External Cephalic Version. This procedure consists of externally manipulating the gravid abdomen without anesthesia to turn the fetus from transverse lie or breech presentation. The optimum time for version is 37 weeks' gestation, and success rates are 60–70%. Potential hazards are umbilical cord compression or placental abruption requiring emergency cesarean section.

CERVICAL CERCLAGE

This procedure is performed on a patient diagnosed with an *incompetent cervix* that is structurally weak. A suture is placed in the cervix encircling the internal os, providing external support. In a *Shirodkar* procedure, the suture is buried beneath the cervical mucosa and is often left in place with delivery by cesarean section. In a *McDonald* procedure, the suture is placed in a simple purse-string fashion and removed at 36 weeks' gestation to allow vaginal delivery. Risks include rupture of membranes, bleeding, and bleeding that could lead to pregnancy loss.

Incompetent Cervix

A 32-year-old primigravida at 18 weeks' gestation comes to the maternity unit complaining of pelvic pressure and increasing vaginal mucus discharge. She denies any uterine contractions. On pelvic examination the fetal membranes are seen bulging into the vagina, and no cervix can be palpated. Fetal feet can be felt through the membranes. Two years ago she underwent a cervical conization for cervical intraepithelial neoplasia.

Diagnosis. This is retrospective based on a history of painless mid-trimester cervical dilation resulting in delivery of a previable, normal-appearing fetus.

Etiology. Causes may include trauma from rapid forceful cervical dilation associated with second-trimester abortion procedures, cervical laceration from rapid delivery, injury from deep cervical conization, or congenital weakness from intrauterine diethylstilbestrol (DES) exposure.

Management. During the next pregnancy, confirm normal fetal anatomy by sonogram. Place the cerclage at 14 weeks' gestation, before cervical dilation and effacement occur. Successful pregnancy rates may be as high as 85%.

OBSTETRIC ANESTHESIA

General Considerations

- Pain relief from uterine contractions and cervical dilation in stage 1 of labor involves thoracic nerve roots, T10 to T12.
- Pain relief from perineal distention in stage 2 of labor involves sacral nerve roots, S2 to S4.
- Pregnancy predisposes to hypoxia because of decreased functional residual capacity.
- Placental transfer of medications exposes the fetus to lipid-soluble anionic substances.
- Antacids should be given prophylactically because of delayed gastric emptying time in pregnancy.
- Uterus should be laterally displaced to avoid inferior vena cava compression in the supine position.

Intravenous Agents

This includes narcotics and sedatives, which are frequently given in the active phase of labor. *Advantages* include ease of administration and inexpensive cost. *Disadvantages* include neonatal depression if given close to delivery. The neonate may need administration of *naloxone* to reverse the effect.

Paracervical Block

This is a mode of conduction anesthesia that involves bilateral transvaginal local anesthetic injection to block *Frankenhauser's ganglion* lateral to the cervix. It is administered in the active phase of labor. *Disadvantages* include temporary high levels of local anesthetic in the uterus that may lead to *transitory fetal bradycardia*, which is managed conservatively.

Pudendal Block

This is a mode of conduction anesthesia that involves bilateral transvaginal local anesthetic injection to block the pudendal nerve as it passes by the ischial spines. It is administered in stage 2 of labor to provide perineal anesthesia.

Epidural Block

This is a mode of conduction anesthesia that involves injection of local anesthetic into the epidural space to block the lumbosacral nerve roots during both stages 1 and 2 of labor. *Advantages* include use for either vaginal delivery or cesarean section. *Disadvantages* include patchy block from nonuniform spread of the local anesthetic around the nerve roots. *Complications* include hypotension from peripheral vascular dilation owing to sympathetic blockade and spinal headache from inadvertent dural puncture, as well as CNS bleeding or infection (rare). Hypotension is treated with IV fluids and IV ephedrine. Spinal headache is treated with IV hydration, caffeine, or blood patch.


Spinal Block

This is a mode of conduction anesthesia that involves injection of local anesthetic into the subarachnoid space to block the lumbosacral nerve roots. It is used as a saddle block for stage 2 of labor and for cesarean delivery. *Advantages* are complete predictable anesthesia. *Complications* include hypotension from peripheral vascular dilation because of sympathetic blockade (common) and spinal headache (rare), as well as CNS bleeding or infection (rare).

General Anesthesia

This is only rarely used for vaginal delivery, but commonly for cesarean section. *Indications* include need for rapid emergency delivery, maternal medical conditions in which conduction anesthesia is unsafe (e.g., blood dyscrasia, thrombocytopenia). *Complications* include aspiration pneumonia, atelectasis, and uterine atony (associated with inhalation agents, e.g., halothane, enflurane).

Postpartum Issues



REPRODUCTIVE TRACT CHANGES

Lochia

These are superficial layers of the endometrial decidua that are shed through the vagina during the first 3 postpartum weeks. For the first few days the color is red (*lochia rubra*), changing during the next week to pinkish (*lochia serosa*), ending with a whitish color (*lochia alba*) by the end of the second week.

Cramping

The myometrial contractions after delivery constrict the uterine venous sinuses, thus preventing hemorrhage. These lower midline cramps may be painful and are managed with mild analgesics.

Perineal Pain

Discomfort from an episiotomy or perineal lacerations can be minimized in the first 24 h with ice packs to decrease the inflammatory response edema. A heat lamp or sitz bath is more helpful after the first day to help mobilize tissue fluids.

URINARY TRACT CHANGES

Hypotonic Bladder

Intrapartum bladder trauma can result in increased postvoid residual volumes. If the residuals exceed 250 ml, the detrusor muscle can be stimulated to contract with bethanechol (Urecholine). Occasionally an indwelling Foley catheter may need to be placed for a few days.

Dysuria

Pain with urination may be seen from urethral irritation from frequent intrapartum catheterizations. Conservative management may be all that is necessary. A urinary analgesic may be required occasionally.

GI TRACT CHANGES

Constipation

Decreased GI tract motility, because of perineal pain and fluid mobilization, can lead to constipation. *Management* is to encourage oral hydration and stool softeners.

Hemorrhoids

Prolonged second-stage pushing efforts can exaggerate preexisting hemorrhoids. *Management* is to encourage oral hydration and stool softeners.

PSYCHOSOCIAL PROBLEMS

Bonding

Impaired maternal-infant bonding is seen in the first few days postdelivery. Lack of interest or emotions for the newborn are noted. Risk is increased if contact with the baby is limited because of neonatal intensive care, as well as poor social support. *Management* is psychosocial evaluation and support.

Blues

Postpartum blues are very common within the first few weeks of delivery. Mood swings and tearfulness occur. Normal physical activity continues and care of self and baby is seen. *Management* is conservative with social support.

Depression

Postpartum depression is common but is frequently delayed up to a month after delivery. Feelings of despair and hopelessness occur. The patient often does not get out of bed with care of self and baby neglected. *Management* includes psychotherapy and antidepressants.

Psychosis

Postpartum psychosis is rare, developing within the first few weeks after delivery. Loss of reality and hallucinations occur. Behavior may be bizarre. *Management* requires hospitalization, antipsychotic medication, and psychotherapy.

CONTRACEPTION PLANNING

Breast-feeding

Lactation is associated with temporary anovulation, so contraceptive use may be deferred for 3 months. A definitive method should be used after that time.

Diaphragm

Fitting for a vaginal diaphragm should be performed after involution of pregnancy changes, usually at the 6-week postpartum visit.

Intrauterine Device (IUD)

Higher IUD retention rates, and decreased expulsions, are seen if IUD placement takes place at 6 weeks postpartum.

Combination Pills

Combined estrogen-progestin oral contraceptive pills should not be used in breast-feeding women because of the estrogen effect of diminishing milk production. In nonlactating women, it should be started after 3 weeks postpartum to allow reversal of the hypercoagulable state of pregnancy and thus decrease the risk of deep venous thrombosis.

Progestin Contraception

Progestin steroids (e.g., mini-pill, Depo-Provera, Norplant) do not diminish milk production so can safely be used during lactation. They can be begun immediately after delivery.

POSTPARTUM IMMUNIZATIONS

RhoGAM

If the mother is Rh(D) negative, and her baby is Rh(D) positive, she should be administered 300 µg of RhoGAM IM within 72 h of delivery.

Rubella

If the mother is rubella IgG antibody negative, she should be administered active immunization with the live-attenuated rubella virus. She should avoid pregnancy for 3 months to avoid potential fetal infection.

POSTPARTUM HEMORRHAGE

Uterine Atony (50%)

This is the *most common* cause of excessive postpartum bleeding. Risk factors include rapid or protracted labor (*most common*), chorioamnionitis, medications (e.g., MgSO₄, β-adrenergic agonists, halothane), and overdistended uterus. Clinical findings are a soft uterus palpable above the umbilicus. *Management* is uterine massage and uterotonic agents (e.g., oxytocin, methylergonovine, or carboprost).

Lacerations (20%)

Risk factors include uncontrolled vaginal delivery (*most common*), difficult delivery, and operative vaginal delivery. Clinical findings are identifiable lacerations in the presence of a contracted uterus. *Management* is surgical repair.

Retained Placenta (10%)

Risk factors include accessory placental lobe (*most common*) and abnormal trophoblastic invasion. Clinical findings are missing placental cotyledons in the presence of a contracted uterus. *Management* is manual removal.

Disseminated Intravascular Coagulation (DIC; rare)

Risk factors include abruption placenta (*most common*), severe preeclampsia, amniotic fluid embolism, and prolonged fetal demise. Clinical findings include generalized bleeding in the presence of a contracted uterus. *Management* is removal of pregnancy tissues from the uterus, intensive care unit (ICU) support, and selective blood product replacement.

Uterine Inversion (rare)

Risk factors include myometrial weakness (*most common*) and previous uterine inversion. Clinical findings are a beefy-appearing bleeding mass in the vagina and failure to palpate the uterus abdominally. *Management* is uterine replacement by elevating the vaginal fornices and lifting the uterus upward, followed by IV oxytocin.

Unexplained

If despite careful searching, no correctible cause of continuing hemorrhage is found, it may be necessary to perform a laparotomy and bilaterally surgically ligate the uterine or internal iliac arteries. Hysterectomy would be a last resort.

POSTPARTUM FEVER

PP Day 0: Atelectasis

Risk factors include general anesthesia with incisional pain (*most common*) and cigarette smoking. Clinical findings include mild fever with mild rales on auscultation. *Management* is pulmonary exercises and ambulation.

PP Day 1–2: Urinary Tract Infection

Risk factors include multiple intrapartum catheterizations and vaginal examinations. Clinical findings are high fever, flank tenderness, and positive urinalysis and culture. *Management* is single-agent IV antibiotics.

PP Day 2–3: Endometritis

This is the *most common* cause of postpartum fever. Risk factors include emergency cesarean section, prolonged membrane rupture, and prolonged labor. Clinical findings are moderate fever with significant uterine tenderness. *Management* is multiple-agent IV antibiotics to cover polymicrobial genital tract flora.

PP Day 4–5: Wound Infection

Risk factors include emergency cesarean section, prolonged membrane rupture, and prolonged labor. Clinical findings are persistent spiking fever despite antibiotics along with wound erythema, fluctuance, or drainage. *Management* is IV antibiotics for cellulitis and wound drainage for an abscess.

PP Day 5–6: Septic Thrombophlebitis

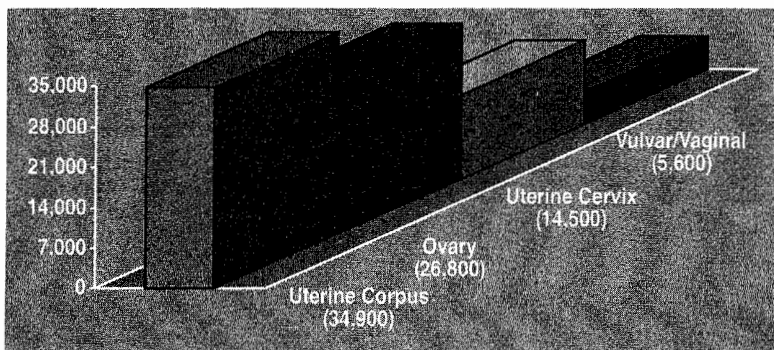
Risk factors include emergency cesarean section, prolonged membrane rupture, and prolonged labor. Clinical findings are persistent wide fever swings despite antibiotics with normal pelvic and physical examination. *Management* is IV heparin for 7–10 days.

PP Day 7–21: Infectious Mastitis

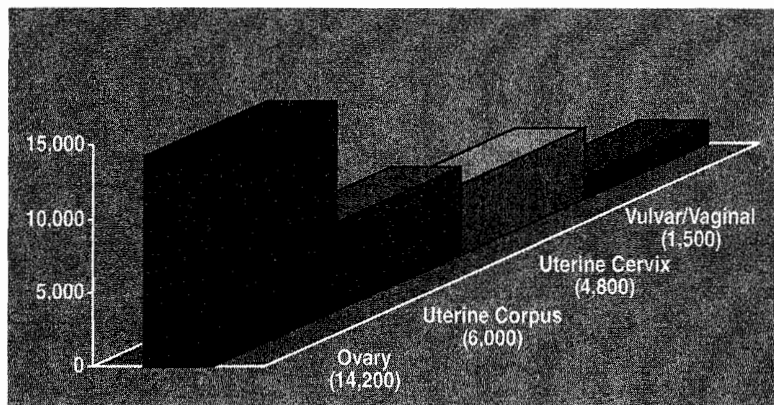
Risk factors include lactational nipple trauma. Clinical findings are variable fever with localized, unilateral breast tenderness, erythema, and edema. *Management* is oral cloxacillin. Breast-feeding can be continued.

Gynecologic Neoplasia and Cancer

11



81,800 New Gyn Cancers



26,500 Gyn Cancer Deaths

Figure 11-1

CERVICAL NEOPLASIA

Cervical Dysplasia

Reproductive years

A 29-year-old woman is referred because of a Pap smear showing LGSIL (low-grade squamous intraepithelial lesion). The patient states that the Pap smear last year was negative. She has been on combination oral contraceptive pills for the past 6 years. The pelvic examination is normal.

Presentation. Premalignant lesions of the cervix are usually *asymptomatic*. The progression from premalignant to invasive cancer has been reported to be approximately 8–10 years. Most lesions will spontaneously regress; others remain static, with only a minority progressing to cancer.

Etiology. The *most common* etiology of cervical cancer is the human papilloma virus (HPV). More than 75 subtypes of HPV have been identified. HPV 16, 18, 31, 33, and 35 are the *most common* HPV types associated with premalignant and cancerous lesions of the cervix. HPV 6 and 11 are the *most common* HPV types associated with benign condyloma acuminata.

Risk Factors. These include early age of intercourse, multiple sexual partners, cigarette smoking, and immunosuppression. The mediating factor for all these conditions is probably HPV.

Screening

- *What is the Pap test?* The best screening test for premalignant lesions is cytology. Cytologic screening uses the Pap test. The *most common* site for cervical dysplasia is the transformation zone (T-zone).
- *How is it performed?* Two specimens are obtained with the Pap smear: an ectocervical sample performed by scraping the T-zone with a spatula, and an endocervical sample obtained with a cytobrush in the nonpregnant woman or a cotton-tip applicator in a pregnant woman.
- *What cytologic screening methods can be used?* With the *conventional method*, the specimens are smeared onto a glass slide, which is placed in fixative and then microscopically examined. With the *thin-layer, liquid-based cytology*, the specimens are rinsed into a preserving solution and are then deposited on a slide as a thin layer of processed cells.
- *When should it be started?* New recommendations are within 3 years after onset of sexual activity or age 21 years, whichever occurs first.
- *When should screening be discontinued?* At age 70, if patient has had ≥ 3 consecutive normal Pap smears, and after total hysterectomy, if the procedure was performed for benign disease.
- *Frequency of screening?* If patient is under 30 years old, screen annually if using conventional methods or every 2 years if using liquid-based methods. If patient is ≥ 30 years, screen every 2 to 3 years if ≥ 3 annual Pap smears.

Classification. The *Bethesda system* is the current classification used in the United States. The squamous cell categories include the following:

- *Negative* for intraepithelial lesion or malignancy—comments may report trichomoniasis, candida, BV, HSV, or atrophy.
- *ASC (atypical squamous cells)*—These can be either ASC-US (undetermined significance) or ASC-H (cannot exclude HSIL).

- *LSIL (low-grade squamous intraepithelial lesion)*—Biopsy will demonstrate histologic findings of HPV, mild dysplasia, or CIN 1.
- *HSIL (high-grade squamous intraepithelial lesion)*—Biopsy will demonstrate histologic findings of moderate dysplasia, severe dysplasia, CIS, CIN 2, or CIN 3.
- *Cancer*—Biopsy will demonstrate histologic findings of invasive cancer.

Diagnostic Approach

- *Accelerated repeat Pap.* This is an option for the findings of ASC-US. Repeat Pap at 4- to 6-month intervals until there are two consecutive, negative Paps. If a repeat Pap is again ASC-US or worse, refer for colposcopy.
- *HPV DNA testing.* This is also an option for findings of ASC-US. If liquid-based cytology was used on the initial Pap smear, this specimen can be used for DNA testing. If conventional methods were used, a second Pap needs to be performed. Colposcopy is performed only if high-risk HPV DNA is identified.
- *Colposcopy.* Once the patient is reported to have an abnormal Pap smear, she should be evaluated by colposcopic examination. Colposcopy is a magnification of the cervix (10–12 times). Colposcopy is aided by acetic acid, which makes the vascular patterns more visible. *Satisfactory* or *adequate* colposcopy is diagnosed if the entire T-zone is visualized and no lesions disappear into the endocervical canal. *Unsatisfactory* or *inadequate* colposcopy is diagnosed if the entire T-zone cannot be fully visualized.
- *Endocervical curettage (ECC).* All nonpregnant patients undergoing colposcopy for an abnormal Pap smear will undergo an ECC to rule out endocervical lesions.
- *Ectocervical biopsy.* Lesions identified on the ectocervix by colposcopy (e.g., mosaicism, punctuation, white lesions, abnormal vessels) are biopsied and sent for histology.
- *Compare Pap smear and biopsy.* When the biopsy histology is complete, it is compared with the level of Pap smear abnormality to ensure the level of severity is comparable.
- *Cone biopsy.* If the Pap smear is worse than the histology (suggesting the site of abnormal Pap smear cells was not biopsied), then a cone biopsy is performed. Other indications for conization of the cervix include abnormal ECC histology, a lesion seen entering the endocervical canal, and a biopsy showing microinvasive carcinoma of the cervix. Deep cone biopsies can result in an *incompetent cervix*. Another risk of cone biopsy is *cervical stenosis*.

Management According to Histology

- *Observation* and follow-up without treatment is appropriate for CIN 1 and includes any of the following: repeat Pap in 6 and 12 months; colposcopy and repeat Pap in 12 months; or HPV DNA testing in 12 months.
- *Ablative modalities* can be used for CIN 1, 2, and 3. These include cryotherapy (freezing), laser vaporization, and electrofulguration.
- *Excisional procedures* can be used for CIN 1, 2, and 3. These include LEEP (loop electrosurgical excision procedure) or cold-knife conization.
- *Hysterectomy* is only acceptable with biopsy-confirmed, *recurrent* CIN 2 or 3.

Follow-Up. Patients treated with either ablative or excisional procedures require follow-up repeat Pap smears, colposcopy and Pap smear, or HPV DNA testing every 4 to 6 months for 2 years.

ASC Pap smear

A 35-year-old woman is referred because of a Pap smear reading of ASC. The patient states that her last Pap smear done approximately 1 year ago was negative. She has been sexually active, using combination oral contraception pills for the last 4 years.

Definition. ASCUS means atypical squamous cell of undetermined significance.

Significance

- *Incidence.* The incidence of ASCUS Pap smears should not be >5% of cytology specimens, but often is up to 20%. A problem with the traditional Pap smear was that the cells would clump up and make it difficult for the cytologist to evaluate. Two new technologies may improve traditional Pap smear sensitivity.
- *Thin prep.* This new technology is liquid based. The sample from the cervix and endocervix is placed on a liquid vial at which time it is dispersed and then placed on the slide for evaluation. The sensitivity of the newer technique is approximately 75–80% compared with approximately 51% of the conventional Pap smear.
- *HPV/DNA testing.* More than 75 subtypes of the HPV have now been identified, of which HPV 16, 18, 31, 33, and 35 are *most commonly* associated with premalignant and invasive cancer lesions. In patients with ASCUS Pap smears, this technique may be helpful as the cells reported to be consistent with ASCUS can be evaluated better for which type of HPV is present. If it is HPV 6 or 11, then the patient should have a repeat Pap smear in 1 year; however, if it is HPV/DNA 16 or 18, then these are the patients that should be evaluated by colposcopy and biopsy.

Etiology

- *Benign.* ASCUS Pap smears can result from inflammatory and atrophic lesions, or may be caused by the initial stages of HPV infection.
- *Neoplasia.* Studies have shown that about 10–15% of patients with ASCUS Pap smears can have a significant premalignant lesion, and a small percentage of these patients can even have invasive carcinoma.

Diagnostic Options. A patient with an ASCUS Pap smear can be evaluated either by repeat cytology in 3–6 months or colposcopic evaluation and biopsy.

- *Follow-up is certain.* With reliable patients, repeat the Pap smear in 3 months. If the result is negative, follow-up is routine. If the repeat Pap smear is again ASCUS, then colposcopy and directed biopsies are performed.
- *Follow-up is uncertain.* With unreliable patients, it is safer to proceed directly to colposcopy and biopsies.

Management. Follow-up is based on the results of the repeat Pap smears or colposcopically directed biopsy findings.

Invasive Cervical Cancer

A 43-year-old woman complains of intermenstrual postcoital bleeding for the past 6 months between regular menstrual cycles that occur every 28 days. On pelvic examination a 3-cm exophytic mass is seen from the anterior lip of the cervix. The rest of the pelvic examination, including a rectovaginal examination, is normal.

Definition. Cervical neoplasia that has penetrated through the basement membrane.

Presentation. Patients with invasive cervical cancer can present with postcoital vaginal bleeding. Other symptoms of cervical cancer include irregular vaginal bleeding and, in advanced stage, lower extremity pain and edema.

Epidemiology. Cervical carcinoma is the *third most common* gynecologic malignancy with a mean age at diagnosis of *45 years*.

Diagnostic Tests/Findings

- *Cervical biopsy.* The initial diagnostic test should be a cervical biopsy, in which the most common diagnosis is squamous cell carcinoma.
- *Metastatic workup.* Once a tissue diagnosis of invasive carcinoma is made, a metastatic workup should be done that includes pelvic examination, chest x-ray, intravenous pyelogram, cystoscopy, and sigmoidoscopy.
- *Imaging studies.* Invasive cervical cancer is the only gynecologic cancer that is staged clinically; an abdominal pelvic computed tomographic (CT) scan or magnetic resonance imaging (MRI) cannot be used for clinical staging.

Staging. Staging is *clinical* based on pelvic examination and may include an intravenous pyelogram (IVP).

- Stage I: Spread *limited* to the cervix. This is the *most common* stage at diagnosis.
 - Ia1. Invasion is ≤ 3 mm deep (minimally invasive)
 - Ia2. Invasion is $>Ia1$ but ≤ 5 mm deep (microinvasion)
 - Ib. Invasion is >5 mm deep (frank invasion)
- Stage II: Spread *adjacent* to the cervix
 - IIa. Involves upper two thirds of vagina
 - IIb. Invasion of the parametria
- Stage III: Spread *further* from the cervix
 - IIIa. Involves lower one third of vagina
 - IIIb. Extends to pelvic side wall or hydronephrosis
- Stage IV: Spread *furthest* from the cervix
 - IVa. Involves bladder or rectum or beyond true pelvis
 - IVb. Distant metastasis

Management

- *General.* Patients treated surgically are evaluated for risk factors for metastatic disease and tumor recurrence. These include metastatic disease to the lymph nodes, tumor size >4 cm, poorly differentiated lesions, or positive margins. Patients with these findings are offered adjuvant therapy (radiation therapy and chemotherapy).

- *Specific by stage:*

Stage Ia1: Treatment is simple hysterectomy, either vaginal or abdominal.

Stage Ia2: Treatment is modified radical hysterectomy.

Stage Ib or IIa: Treatment is either radical hysterectomy with pelvic and para-aortic lymphadenectomy and peritoneal washings or pelvic radiation. In patients who can tolerate surgery, a radical hysterectomy is preferred; however, studies have demonstrated equal cure rates with radiation or surgical treatment.

Stage IIb, III, or IV: Treatment is radiation therapy and chemotherapy.

Follow-Up

- *All patients.* Patients with invasive cervical cancer should be followed up with Pap smears every 3 months for 2 years after treatment and then every 6 months for the subsequent 3 years.
- *Local recurrence.* Patients who have a local recurrence can be treated with radiation therapy and if they had received radiation previously, they might be considered candidates for a pelvic exenteration.
- *Distant metastases.* A patient with distant metastasis should be considered for chemotherapy treatment. The most active chemotherapeutic agent for cervical cancer is cis-platinum.

Cervical Neoplasia in Pregnancy

A 25-year-old woman with intrauterine pregnancy at 14 weeks by dates is referred because of a Pap smear showing as HGSIL (high-grade squamous intraepithelial lesion). On pelvic examination there is a gravid uterus consistent with 14 weeks size, and the cervix is grossly normal to visual inspection.

Diagnostic Tests/Findings

- *Effect of pregnancy.* Pregnancy per se does not predispose to abnormal cytology and does not accelerate precancerous lesion progression into invasive carcinoma.
- *Colposcopy and biopsy.* A patient who is pregnant with an abnormal Pap smear should be evaluated in the same fashion as in a nonpregnant state. An abnormal Pap smear is followed with colposcopy with the aid of acetic acid for better visualization of the cervix. Any abnormal lesions of the ectocervix are biopsied.
- *Perform an ECC?* Owing to increased cervical vascularity, ECC is not performed during pregnancy.

Management

- *CIN.* Patients with intraepithelial neoplasia or dysplasia should be followed with Pap smears and colposcopy every 3 months during the pregnancy. At 6–8 weeks postpartum the patient should be reevaluated with repeat colposcopy and Pap smear. Any persistent lesions can be definitively treated postpartum.
- *Microinvasion.* Patients with microinvasive cervical cancer on biopsy during pregnancy should be evaluated with cone biopsy to ensure no frank invasion. If the cone biopsy specimen shows microinvasive carcinoma during pregnancy, these patients can also be followed conservatively, delivered vaginally, reevaluated, and treated 2 months postpartum.

- *Invasive cancer.* If the punch biopsy of the cervix reveals frankly invasive carcinoma, then treatment is based on the gestational age. In general, if a diagnosis of invasive carcinoma is made *before 24 weeks* of pregnancy, the patient should receive definitive treatment (e.g., radical hysterectomy or radiation therapy). If the diagnosis is made *after 24 weeks* of pregnancy, then conservative management up to about 32–33 weeks can be done to allow for fetal maturity to be achieved, at which time cesarean delivery is performed and definite treatment begun.

UTERINE NEOPLASIA

Postmenopausal Bleeding

A 65-year-old patient complains of vaginal bleeding for 3 months. Her last menstrual period was at the age of 52. She has not taken any hormone replacement. She was diagnosed with type 2 diabetes 20 years ago and was treated with oral hypoglycemic agents. She has chronic hypertension, for which she is treated with oral antihypertensives. Her height is 62 inches, and she weighs 200 lb. Physical examination is normal with a normal-sized uterus and with no vulvar, vaginal, or cervical lesions.

Definition. A patient is considered to be in menopause after 12 continuous months of cessation of menses and elevated gonadotropins. Menopause usually occurs at approximately 52 years of age. Postmenopausal bleeding is any bleeding that occurs after menopause.

Epidemiology. Endometrial carcinoma is the *most common* gynecologic malignancy, occurring in 1% of women. The mean age at diagnosis is 61 years.

Differential Diagnosis. The differential diagnosis of postmenopausal bleeding includes endometrial carcinoma, vaginal or endometrial atrophy, and postmenopausal hormonal replacement therapy. Although the *most common* cause of postmenopausal bleeding is vaginal or endometrial atrophy, the most important diagnosis to rule out is endometrial carcinoma.

Pathophysiology. The mediating factor for most endometrial carcinomas appears to be unopposed estrogen. This results from excessive hyperstimulation of the endometrium without the stabilizing effect of progesterone.

Risk Factors. These include *obesity, hypertension, and diabetes mellitus*. Other risk factors include nulliparity, late menopause, and chronic anovulation conditions, such as polycystic ovarian (PCO) disease.

Diagnostic Tests

- *Endometrial sampling.* Patients with postmenopausal bleeding must be evaluated with an endometrial sampling, which can be done in an office setting. Sometimes in postmenopausal patients cervical stenosis is present, and these patients should be evaluated with a dilatation and curettage.
- *Hysteroscopy and ultrasonography.* These are other diagnostic tools that can be used for evaluation of patients with postmenopausal bleeding. With hysteroscopy, cervical or endometrial polyps can be identified as the cause of the postmenopausal bleeding, and ultrasonography can be used to measure the thickness of the lining of the endometrium. In postmenopausal patients the endometrial lining should measure <5 mm in thickness.

Staging. Staging is surgical. The staging is done after an evaluation of the pathology report.

- Stage I: Spread *limited* to the uterus. This is the *most common* stage at diagnosis.
 - Ia. Limited to the endometrium
 - Ib. Invasion less than half of myometrium
 - Ic. Invasion more than half of myometrium
- Stage II: Extension to the cervix
 - IIa. Involves only endocervical glands
 - IIb. Invasion of cervical stroma
- Stage III: Spread *adjacent* to the uterus
 - IIIa. Invades serosa or adnexa or positive cytology
 - IIIb. Invasion of vagina
 - IIIc. Invasion of pelvic or para-aortic nodes
- Stage IV: Spread *further* from the uterus
 - IVa. Involves bladder or rectum
 - IVb. Distant metastasis

Management

- *Negative histology.* If the endometrial sampling reveals atrophy and no evidence of cancer, then the patient can be assumed to be bleeding from atrophy and can be treated with hormone replacement therapy. With hormone replacement therapy estrogen and progesterone should be given to the patient. If estrogen is given alone the risk of endometrial cancer increases.
- *Positive histology.* If the endometrial sampling reveals adenocarcinoma, the patient should be treated surgically.
 - *Surgical therapy.* The mainstay of treatment of endometrial carcinoma is a total abdominal hysterectomy (TAH) and bilateral salpingo-oophorectomy (BSO), pelvic and para-aortic lymphadenectomy, and peritoneal washings.
 - *Radiation therapy.* An evaluation of the postoperative pathology report will classify patients into poor or good prognosis category. Patients with poor prognosis should be considered for radiation therapy. Poor prognostic factors include metastasis to the lymph nodes, >50% myometrial invasion, positive surgical margins, or poorly differentiated histology.
 - *Chemotherapy.* Medical treatment is used for metastatic disease and involves *progestins* and cytotoxic agents.

Prevention

- *Postmenopausal patients* taking estrogen replacement therapy must be also treated with progestins to prevent unopposed estrogen stimulation, which may lead to endometrial cancer.
- *Reproductive age women* who have chronic anovulation, such as PCO syndrome, should also be treated with progestins to avoid endometrial hyperplasia from unopposed estrogen.

Enlarged Uterus

Differential Diagnosis. The *most common* cause of an enlarged uterus in the reproductive years is pregnancy. Common benign causes of uterine enlargement are leiomyomas and adenomyosis.

Leiomyoma uteri

Location. It is a benign smooth muscle growth of the myometrium. It is the *most common* benign uterine tumor. It is found five times more often in black women compared with white women. It can develop in a number of anatomic locations.

- *Intramural.* The *most common* location of a leiomyoma is within the wall of the uterus. When small it is usually asymptomatic and cannot be felt on examination unless it enlarges to where the normal uterine external contour is altered.
- *Submucous.* These myomas are located beneath the endometrium and can distort the uterine cavity. The distorted overlying endometrium may not respond appropriately to the normal hormonal fluctuations, resulting in unpredictable, often intermenstrual, bleeding. Abnormal vaginal bleeding is the *most common* symptom of a submucous myoma and can result in anemia. Menorrhagia is defined as heavy menses and metrorrhagia is defined as irregular bleeding in between menses. Menometrorrhagia consists of both heavy menses and bleeding in between the menses.
- *Subserosal.* These are located beneath the uterine serosa. As they grow they distort the external contour of the uterus causing the firm, nontender asymmetry. Depending on their location they can put pressure on the bladder, rectum or ureters. If they are pedunculated, attached to the uterus by a stalk, they can become parasitic fibroids. They break away from the uterus and receive their blood supply from another abdominal organ (such as the omentum or the mesentery of the intestine).

Natural History. Changes in size are dependent on the reproductive life stage of the woman.

- *Slow growth.* Most leiomyomas are small, grow slowly, and cause no symptoms. Only when massive in size do they cause pelvic pressure symptoms.
- *Rapid growth.* Estrogen receptors are increased in leiomyomas resulting in rapid enlargement during times of high estrogen levels, such as pregnancy.
- *Degeneration.* During times of rapid growth, myomas may outgrow their blood supply, resulting in ischemic degeneration of a fibroid. Common degenerations that are seen include hyaline, calcific, and red degeneration. The latter, also known as carneous degeneration, can cause such extreme, acute pain that the patient requires hospitalization and narcotics. This is *most common* during pregnancy.
- *Shrinkage.* When estrogen levels fall, with estrogen receptors no longer stimulated, leiomyomas will typically decrease in size. This predictably occurs after menopause but can also occur when estrogen levels are medically reduced through gonadotropin releasing hormone (GnRH) agonist suppression of follicle-stimulating hormone (FSH).

Diagnosis

- *Pelvic examination.* In most cases the diagnosis is made clinically by identifying an enlarged, asymmetric, nontender uterus in the absence of pregnancy. The size of the fibroid is compared with the size of a pregnant uterus. A pregnant uterus that reaches the umbilicus is approximately 20 weeks in gestation; if the pregnant uterus reaches the symphysis pubis, it is approximately 12 weeks in gestation.
- *Sonography.* Traditional abdominal or vaginal ultrasound can image large intramural or subserosal myomas. Saline infusion sonography is helpful for identifying submucous myomas by instilling 5–10 ml of saline into the uterine cavity before visualizing the uterine cavity with an endovaginal sonogram probe.

- *Hysteroscopy.* Submucous myomas may be identified by visualizing them directly with hysteroscopy.
- *Histology.* The only definitive diagnosis is by surgical confirmation of excised tissue.

Management

- *Observation.* Most leiomyomas can be managed conservatively and followed expectantly with regular pelvic examinations.
- *Presurgical shrinkage.* After 3–6 months of GnRH analog therapy, with resultant hypoenstrogonic state, a 60–70% reduction in size of the fibroids can be expected. However, once the leuprolide (Lupron) is terminated, there will be a regrowth of the fibroid within 6 months. Thus, GnRH analogs cannot be used for definitive cure, but they can be used in the adjuvant setting with surgical therapy. If a myomectomy is done, a decrease in size will be associated with a decrease in blood loss, and if a hysterectomy is planned, then perhaps a vaginal instead of an abdominal hysterectomy can be performed.
- *Myomectomy.* This is a surgical procedure performed if the patient desires to maintain fertility. The uterus is incised and the myoma removed through either a laparoscopic or laparotomy approach. If the myomectomy incision entered the endometrial cavity, delivery of any subsequent pregnancy should be by cesarean section because of increased risk of scar rupture in labor.
- *Embolization.* This is an invasive radiology procedure in which a catheter is placed into the vessels supplying the myoma. Microspheres are injected, causing ischemia and necrosis of the myoma.
- *Hysterectomy.* If the patient has completed her childbearing, definitive therapy is an abdominal or vaginal hysterectomy.

Adenomyosis

A 42-year-old woman complains of increasing pain with her menstrual periods for the past 8 months. She also states her periods are getting heavier, leaving her tired and weak. She underwent a postpartum tubal ligation after her last child 10 years ago. She has been treated for chronic hypertension for the past 3 years. On pelvic examination her uterus is 12-week size, globular, soft, and tender. Rectovaginal examination is unremarkable.

Definition. It is ectopic endometrial glands and stroma located within the myometrium of the uterine wall. The *most common* presentation is diffuse involvement of the myometrium. The lesion is known as an *adenomyoma* if the involvement is focal, surrounded by a pseudocapsule.

Diagnosis. In most cases the diagnosis is made clinically by identifying an enlarged, symmetric, tender uterus in the absence of pregnancy. The only definitive diagnosis is by histologic confirmation of the surgically excised tissue.

Symptoms. The majority of women are asymptomatic. The *most common* symptoms are secondary dysmenorrhea and menorrhagia.

Examination. The uterus is globular and diffusely up to 2–3 times the normal size. Tenderness is most common immediately before and during menses.

Imaging. Ultrasound study or MRI imaging shows a diffusely enlarged uterus with cystic areas found within the myometrial wall.

Management. Medical treatment includes the levonorgestrel (LNG) intrauterine system (IUS), which may decrease heavy menstrual bleeding. Surgery, in the form of hysterectomy, is the definitive treatment.

OVARIAN NEOPLASIA

Premenopausal Adnexal Mass

A 22-year-old woman comes for annual examination and requests oral contraceptives pills. On pelvic examination, a 6-cm mobile, smooth, soft, left adnexal mass is palpable. An endovaginal pelvic ultrasound shows a 6-cm, round, fluid-filled, simple ovarian cyst without septations or calcifications. She has no other significant personal or family history.

A 28-year-old woman is in the emergency department complaining of lower abdominal discomfort the last 5 days. She has no history of steroid contraceptive use. A year ago, her pelvic exam and Pap smear were negative. Pelvic exam today shows a 7-cm, mobile, painless right adnexal mass. An endovaginal sonogram in the emergency department confirms a 7-cm, mobile, irregular complex mass with prominent calcifications.

Differential Diagnosis

- *Pregnancy.* The *most common* cause of a pelvic mass in the reproductive years is pregnancy.
- *Simple cyst.* The *most common* cause of a simple cystic mass in the reproductive age years is a physiologic cyst (luteal or follicular cyst). During the reproductive years the ovaries are functionally active, producing a dominant follicle in the first half of the cycle and a corpus luteum after ovulation in the second half of the menstrual cycle. Either of these structures, the follicle or the corpus luteum, can become fluid-filled and enlarged, producing a functional cyst.
- *Complex mass.* The *most common* complex adnexal mass in young women is a dermoid cyst or benign cystic teratoma. Other diagnoses include endometrioma, tubo-ovarian abscess, and ovarian cancer.

Benign Cystic Teratoma. Dermoid cysts are benign tumors. They can contain cellular tissue from all three germ layers. The *most common* histology seen is ectodermal skin appendages (hair, sebaceous glands) and therefore the name “*dermoid*.” Gastrointestinal histology can be identified, and carcinoid syndrome has been described originating from a dermoid cyst. Thyroid tissue can also be identified, and if it comprises more than 50% of the dermoid, then the condition of *struma ovarii* is identified. Rarely a malignancy can originate from a dermoid cyst, in which case the *most common* histology would be squamous cell carcinoma, which can metastasize.

Diagnosis

- *Qualitative β -human chorionic gonadotropin (β -hCG) test.* If negative, this will rule out pregnancy.
- *Sonogram.* A complex mass on ultrasound appearance will rule out a functional cyst.

Management

- *Simple cyst.* Most simple cysts are functional and can be managed expectantly, but surgery is indicated if certain characteristics are present.
 - *Observation.* If the sonogram showed a simple cyst the patient should be advised that it is probably benign but careful follow-up is needed. Follow-up examination should be in 6–8 weeks, at which time the functional cyst should have spontaneously resolved. During this period of observation the patient should be alerted to the possibility of acute onset of pain, which may be indicative of torsion of the adnexal cyst. Oral contraceptive medication can be used to help prevent further functional cysts from forming.
 - *Laparoscopy.* Even if the cyst is simple in appearance, surgical evaluation should be performed if: the cyst is >7 cm or she had been on prior steroid contraception. Physiologic cysts do not usually get larger than 7 cm in diameter. Functional cysts should not form if the patient has been on oral contraception for at least 2 months because gonadotropins should have been suppressed.
- *Complex mass.* Patients in the reproductive age group with a complex adnexal mass should be treated surgically. The surgery can be done by a laparoscopy or a laparotomy according to the experience of the surgeon.
 - *Cystectomy.* At the time of surgery an ovarian cystectomy should be attempted to preserve ovarian function in the reproductive age. Careful evaluation of the opposite adnexa should be performed as dermoid cysts can occur bilaterally in 10–15% of the cases.
 - *Oophorectomy.* If an ovarian cystectomy cannot be done because of the size of the dermoid cyst, then an oophorectomy is performed, but conservative management should always be attempted before an oophorectomy is done.

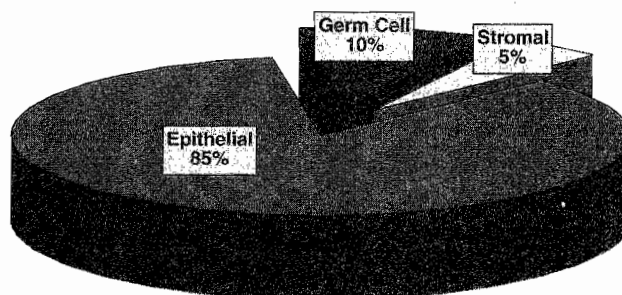


Figure 11-2. Types Of Ovarian Neoplasms

Adnexal Mass With Pain

A 31-year-old woman is taken to the emergency department complaining of severe sudden lower abdominal pain, which started approximately 3 h ago. The patient states that she was at work when she suddenly developed lower abdominal discomfort and pain, which progressively got worse. On examination in the emergency department, the abdomen is tender, although no rebound tenderness is present, and there is a suggestion of an adnexal mass in the cul-de-sac area. An ultrasound evaluation shows an 8-cm left adnexal mass, and there is suggestion of torsion of the ovary.

Diagnosis. Sudden onset of severe lower abdominal pain in the presence of an adnexal mass is presumptive evidence of ovarian torsion.

Management. The management of the torsion should be to untwist the ovary and to observe the ovary for a few minutes in the operating room to assure revitalization. This can be performed with either laparoscopy or laparotomy.

- *Cystectomy.* If revitalization occurs, then an ovarian cystectomy can be performed with preservation of the ovary.
- *Oophorectomy.* If the ovary is necrotic, then a unilateral salpingo-oophorectomy is performed.

Follow-Up. These patients should have routine examination 4 weeks after the operation and then should be seen on a yearly basis. The pathology report should be checked carefully to make sure that it is benign, and if this is the case, then they go to routine follow-up.

Prepubertal Adnexal Mass

An 8-year-old girl is evaluated in the emergency department for sudden onset of severe lower abdominal pain. A general surgery consult was obtained, and appendicitis is ruled out. Pelvic ultrasound reveals a 7-cm solid and irregular right adnexal mass. On examination the pelvic examination is consistent with a 7-cm right adnexal mass, and there is lower abdominal tenderness but no rebound present.

Etiology. An adnexal mass in the prepubertal age group is abnormal. During the prepubertal and the postmenopausal years, functional ovarian cysts are not possible because ovarian follicles are not functioning. Therefore any ovarian enlargement is suspicious for neoplasm.

Differential Diagnosis. If sonography shows a complex adnexal mass in a girl or teenager, the possibility of *germ cell* tumors of the ovary has to be considered. The following serum *tumor markers* should be obtained: lactate dehydrogenase (LDH) for dysgerminoma, β -hCG for choriocarcinoma, and α -fetoprotein for endodermal sinus tumor.

Presentation. Sudden onset of acute abdominal pain is a typical presentation of germ cell tumors of the ovary. These tumors characteristically grow rapidly and give early symptomatology as opposed to the epithelial cancers of the ovary that are diagnosed in advanced stages. Germ cell tumors of the ovary are *most common* in young women and present in early stage disease.

Diagnosis. *Surgical exploration.* In a prepubertal patient who is symptomatic and has ultrasound evidence of an adnexal mass, a surgical evaluation is recommended.

- *Simple mass.* If the ultrasound shows the consistency of the mass to be simple (no septations or solid components), this mass can be evaluated through a laparoscopic approach.
- *Complex mass.* If the mass has septations or solid components, a laparoscopy or laparotomy should be performed, depending on the experience of the surgeon.

Management

- *Benign histology.* A cystectomy should be performed instead of a salpingo-oophorectomy. Because of the patient's age the surgical goal should be toward conservation of both ovaries. If the frozen section pathology analysis is benign, no further surgery is needed. *Follow-up* is on an annual basis.
- *Germ cell tumor.* A unilateral salpingo-oophorectomy and surgical staging (peritoneal and diaphragmatic biopsies, peritoneal cytology, pelvic and para-aortic lymphadenectomy, and omentectomy) should be done. All patients with germ cell tumors require postoperative chemotherapy. The most active regimen used is vinblastine, bleomycin, and cisplatin. *Follow-up* after conservative surgery is every 3 months with pelvic examination and tumor marker measurements.

Prognosis. The current survival is >95% in patients with germ cell tumors managed with conservative management and chemotherapy. Before the chemotherapy age the majority of these patients succumbed to their disease.

Postmenopausal Adnexal Mass

A 70-year-old woman comes for annual examination. She complains of lower abdominal discomfort; however, there is no weight loss or abdominal distention. On pelvic examination you find a nontender, 6-cm, solid, irregular, fixed, left adnexal mass. Her last examination was 1 year ago, which was normal, and it included a normal Pap smear.

Definition. A pelvic mass that is identified after menopause. Ovaries in the postmenopausal age group should be atrophic, and anytime they are enlarged, the suspicion of *ovarian cancer* arises.

Diagnostic Tests

- *GI tract lesions.* The patient should undergo an abdominal pelvic CT scan or a pelvic ultrasound, and GI studies (barium enema) should also be done to rule out any intestinal pathology such as diverticular disease.
- *Urinary tract lesions.* The patient should undergo an IVP to identify any impingement of the urinary tract.

Screening Test. The current screening test for ovarian cancer is the *bimanual pelvic examination*. Pelvic ultrasound is excellent for finding pelvic masses, but is not specific for identifying which are benign and which are malignant. Only 3% of patients undergoing laparotomy for sonographically detected pelvic masses actually have ovarian cancer.

Epidemiology. Ovarian carcinoma is the *second most common* gynecologic malignancy, with a mean age at diagnosis of 69 years. One percent of women die of ovarian cancer. It is the *most common* gynecologic cancer leading to death.

Risk Factors. These include *BRCA1* gene, positive family history, high number of lifetime ovulations, and infertility.

Protective Factors. These are conditions that decrease the total number of lifetime ovulations: oral contraceptive pills (OCPs), chronic anovulation, breast-feeding, and short reproductive life.

Classification of Ovarian Cancer

- *Epithelial tumors*—80%. The *most common* type of histologic ovarian carcinoma is epithelial cancer, which predominantly occurs in postmenopausal women. These include serous, mucinous, Brenner, endometrioid, and clear cell tumors. The *most common* malignant epithelial cell type is *serous*.
- *Germ cell tumors*—15%. Another histologic type of ovarian cancers is the germ cell tumor, which predominantly occurs in teenagers. Examples of germ cell tumors are dysgerminoma, endodermal sinus tumors, teratomas, and choriocarcinoma. The *most common* malignant epithelial cell type is *dysgerminoma*. It is uniquely x-ray sensitive.
- *Stromal tumors*—5%. The third type of ovarian tumors is the stromal tumor, which is functionally active. These include granulosa-theca cell tumors, which secrete estrogen and can cause bleeding from endometrial hyperplasia. They also include Sertoli-Leydig cell tumors, which secrete testosterone and can produce masculinization syndromes. Patients with stromal tumors usually present with early stage disease and are treated either with removal of the involved adnexa (for patients who desire further fertility) or a TAH and BSO (if their family has been completed). They metastasize infrequently, and then they require chemotherapy (vincristine, actinomycin, and Cytosan).
- *Metastatic tumor*. These are cancers from a primary site other than the ovary. The *most common* sources are the endometrium, GI tract, and breast. *Krukenberg tumors* are mucin-producing tumors from the stomach metastatic to the ovary.

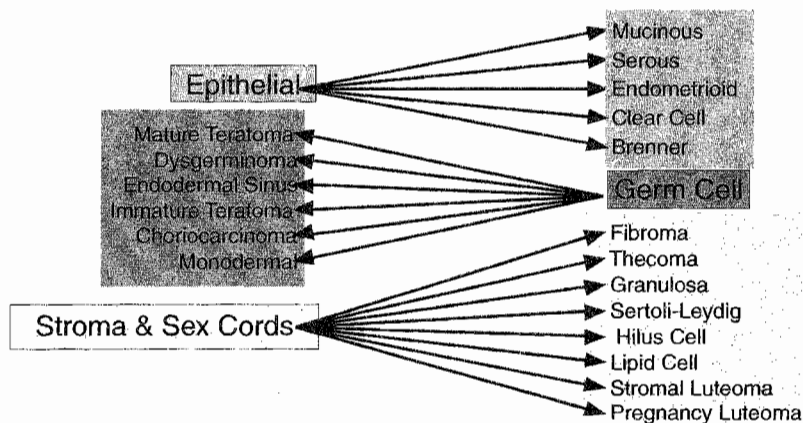


Figure 11-3. Overview of Ovarian Oncology

Tumor Markers

- *CA-125* (cancer antigen 125) and *CEA* (carcinoembryonic antigen) should also be drawn for the possibility of ovarian epithelial cancer.
- *LDH*, *hCG*, and *α-fetoprotein* should be drawn for the possibility of germ cell tumors.
- *Estrogen* and *testosterone* should be drawn for the possibility of stromal tumors.

Staging. Staging is *surgical*.

- Stage I: Spread limited to the *ovaries*
 - Ia. Limited to one ovary, capsule intact, negative cytology
 - Ib. Limited to both ovaries, capsules intact, negative cytology
 - Ic. One or both ovaries but ruptured capsule, positive cytology
- Stage II: Extension to the *pelvis*
 - IIa. Extension to uterus or tubes
 - IIb. Extension to other pelvic structures
 - IIc. Extension to pelvis with positive cytology
- Stage III: *Peritoneal* metastases or positive nodes. This is the *most common* stage at diagnosis.
 - IIIa. Microscopic peritoneal metastases
 - IIIb. Macroscopic peritoneal metastases ≤ 2 cm
 - IIIc. Macroscopic peritoneal metastases > 2 cm
- Stage IV: *Distant* metastases
 - IVa. Involves bladder or rectum
 - IVb. Distant metastasis

Management. After preoperative studies and medical evaluation have been done, the patient should undergo a surgical exploration. If the abdominal or pelvic CT scan does not show evidence of ascites or any spread to the abdominal cavity and if the surgeon is an experienced laparoscopist, then the evaluation could be performed laparoscopically. At the time of surgery, a unilateral salpingo-oophorectomy (USO) is done and sent for a frozen section.

Benign Histology. If the patient is not a good surgical candidate or the patient desires to maintain her uterus and contralateral ovary, a USO is sufficient treatment. If the USO by frozen section is benign and the patient is a good surgical candidate, then a TAH and BSO should be performed even though it is benign disease because the uterus and ovaries are not unusual sites of pathology in a woman.

Malignant Histology. In this case, a debulking procedure (cytoreduction) should be performed. This procedure consists of a TAH and BSO, omentectomy, and bowel resection, if necessary. Postoperative chemotherapy (carboplatin and Taxol) should be administered.

Follow-Up. If the final pathology report of the enlarged adnexa was benign, the patient can be followed up in the office on a yearly basis for regular examination. If the pathology report was carcinoma, then she would be followed up every 3 months for the first 2 years and then every 6 months for the next 2 years with follow-up of the CA-125 tumor marker.

Borderline Cancers. Another entity of ovarian cancer is the borderline tumors also known as tumors of low malignant potential. These are characterized by no invasion of the basement membrane and can also be treated conservatively.

- *Conservative surgery.* A patient who desires further fertility with a unilateral borderline cancer of the ovary can be treated with a USO with preservation of the uterus and the opposite adnexa.
- *Aggressive surgery.* If the patient has completed her family then the most acceptable treatment would be a TAH and BSO.
- *Chemotherapy.* Patients with borderline cancer of the ovary do not require chemotherapy unless they have metastasis, and this is a rare occurrence.

Adnexal Mass and Ascites

A 65-year-old woman is referred for evaluation of abdominal distention and ascites and an adnexal mass. The patient has noted abdominal distention for the past 6 months, and on pelvic examination there is a 7-cm irregular and solid mass in the cul-de-sac, which is palpable by rectovaginal examination.

Definition. Ascites is an abdominal accumulation of fluid in the peritoneal cavity, which usually causes abdominal distention.

Differential Diagnosis. The etiology of ascites can be multifactorial and includes heart, kidney, and liver disease and ovarian cancer. In a female patient with ascites, ovarian carcinoma must always be considered. Although the etiology of ovarian carcinoma is not known, ovulation inhibition, as occurs with OCPs or pregnancy, does decrease the risk of epithelial ovarian cancer.

Laboratory Abnormalities/Diagnostic Criteria. In a patient with an adnexal mass and ascites, an abdominal pelvic CT scan should be ordered for evaluation of the upper abdomen. The *most common* method of ovarian carcinoma spread is by peritoneal dissemination (exfoliation) and is commonly seen metastatic to the omentum and to the GI tract. The cause of death of patients with advanced ovarian carcinoma is bowel obstruction.

Management Steps

- *Surgical staging.* After an abdominal pelvic CT scan confirms the presence of ascites and the adnexal mass, an exploratory laparotomy and surgical staging should be performed. A salpingo-oophorectomy of the enlarged ovary should be done and sent for frozen section evaluation.
- *Debulking surgery.* If ovarian carcinoma is confirmed, then a debulking (cytoreductive) surgical procedure should be performed. This procedure usually includes a TAH, BSO, omentectomy, and, frequently, bowel resection.
- *Chemotherapy.* Postoperatively these patients should be treated with standard chemotherapy regimen, which includes Taxol and carboplatin. Six courses of chemotherapy are given, and the patients are followed with the tumor marker CA-125.

VULVAR NEOPLASIA

Vulvar Lesion With Pruritus

A 70-year-old woman complains of vulvar itching for a year. She has been treated with multiple steroid medications with no relief. On pelvic examination there is a well-defined 1-cm white lesion of the left labia minora. There are no other lesions in the vulva noted; however, there is a clinical enlargement of a left inguinal node.

Clinical Presentation. The *most common* symptom of both benign as well as malignant lesions is vulvar itching resulting in scratching.

Epidemiology. Vulvar carcinoma is an *uncommon* gynecologic malignancy, with a mean age at diagnosis of 65 years.

Differential Diagnosis. This includes sexually transmitted diseases, benign vulvar dystrophies, or malignant cancers.

Vulvar Dystrophies. These are benign lesions *without* malignant predisposition. The most common symptom is vulvar itching.

- *Squamous hyperplasia.* These lesions appear as whitish focal or diffuse areas that are firm and cartilaginous on palpation. Histologically they show thickened keratin and epithelial proliferation. *Management* is fluorinated corticosteroid cream.
- *Lichen sclerosis.* This appears as bluish-white papula that can coalesce into white plaques. On palpation they feel thin and parchment-like. Histologically they show epithelial thinning. *Management* is testosterone cream.

Vulvar Intraepithelial Neoplasia (VIN). These are benign lesions *with* malignant predisposition. The *most common* symptom is vulvar itching, but most lesions are asymptomatic.

- *Squamous dysplasia.* These lesions appear as white, red, or pigmented, often multifocal in location. Histologically they show cellular atypia restricted to the epithelium without breaking through the basement membrane. The appearance is almost identical to cervical dysplasia. *Management* is surgical excision.
- *CIS.* The appearance is indistinguishable from vulvar dysplasia. Histologically, the cellular atypia is full thickness but does not penetrate the basement membrane. *Management* is laser vaporization.

Malignant Tumor Types

- *Squamous cell.* The *most common* type of invasive vulvar cancer is squamous cell carcinoma, which has been associated with HPV. The *most common* stage at diagnosis is Stage I.
- *Melanoma.* The *second most common* histologic type of vulvar cancer is melanoma of the vulva, and the most important prognostic factor for this type of tumor is the depth of invasion. Any *dark or black lesion* in the vulva should be biopsied and melanoma considered.
- *Paget disease.* An uncommon histologic lesion is Paget disease of the vulva. Paget disease is characteristically a *red lesion*, which is *most common* in postmenopausal white women. Any patient with a red vulvar lesion must be considered for the possibility of Paget disease. Most of the time Paget disease is an intraepithelial process; however, in approximately 18–20% of cases invasion of the basement membrane has been identified. Patients with Paget disease of the vulva have a higher association of other cancers mainly from the GI tract, the genitourinary system, and breast.

Diagnosis. Biopsy. All vulvar lesions of uncertain etiology should be biopsied. Patients with vulvar pruritus should be considered for the possibility of preinvasive or invasive vulvar carcinomas if there is a vulvar lesion. A biopsy of this patient's lesion reveals invasive squamous cell carcinoma of the vulva.

Staging. Staging is *surgical*.

- Stage 0: CIS. The basement membrane is intact.
- Stage I: Tumor confined to the vulva with size ≤ 2 cm; nodes not palpable.
 - Ia. Invasion ≤ 1 mm deep.
 - Ib. Invasion > 1 mm deep.
- Stage II: Tumor confined to the vulva with size > 2 cm; nodes not palpable.
- Stage III: Tumor any size with spread to lower urethra, vagina, or anus; unilateral nodes.
- Stage IV: Widespread metastases.
 - IVa. Involves upper urethra, bladder or rectum, pelvic bone, bilateral nodes.
 - IVb. Distant metastasis.

Management

- *Radical vulvectomy.* Once the diagnosis of squamous cell cancer of the vulva is established, the traditional treatment has been radical vulvectomy with bilateral groin lymphadenectomy. A radical vulvectomy has significant morbidity in terms of sexual dysfunction, and the groin lymphadenectomy also has significant morbidity with edema of the lower extremities.
- *Modified radical vulvectomy.* During recent years significant advancements have been made in making the surgery of vulvar carcinoma a more acceptable procedure for the patient. Less radical procedures are now being performed, such as a modified radical vulvectomy with omission of the lymphadenectomy in specific patients.
- *Lymphadenectomy.* Patients with lesions that are clinically < 2 cm and who have invasion of < 1 mm can be treated with a radical local excision and omission of the lymphadenectomy. Any patient with vulvar cancer with invasion > 1 mm should be treated with a lymphadenectomy. The lymphadenectomy can be unilateral if it is a lateralized lesion, which means that the lesion does not infringe in midline structures such as the clitoris, labia minora, or the perineal body.

GESTATIONAL TROPHOBLASTIC NEOPLASIA (GTN)

Molar Pregnancy

A 24-year-old Filipino nurse is 14 weeks pregnant by dates. She complains of vaginal bleeding as well as severe nausea and vomiting. Her uterus extends to her umbilicus but no fetal heart tones can be heard. Her blood pressure is 150/95. A dipstick urine shows 2+ proteinuria.

Definition. GTN is an *abnormal proliferation of placental tissue* involving both cytotrophoblast and/or syncytiotrophoblast. It can be either benign or malignant. Malignant GTN can be characterized as either localized or metastatic as well as classified into either Good Prognosis or Poor Prognosis.

Classification

- **Benign GTN.** This is the classic hydatidiform mole (H-mole). Incidence is 1:1200 in the US, but 1:120 in the Far East.
 - **Complete mole** is the most common benign GTN. It results from fertilization of an empty egg with a single X sperm resulting in paternally derived *normal 46,XX* karyotype. No fetus, umbilical cord or amniotic fluid is seen. The uterus is filled with grape-like vesicles composed of edematous avascular villi. Progression to malignancy is 20%.
 - **Incomplete mole** is the less common benign GTN. It results from fertilization of a normal egg with two sperm resulting in *triploid 69,XXX* karyotype. A fetus, umbilical cord and amniotic fluid is seen which results ultimately in fetal demise. Progression to malignancy is 10%.
- **Malignant GTN.** This is the gestational trophoblastic tumor (GTT) which can develop in three categories.
 - **Non-metastatic** disease is localized only to the uterus.
 - **Good Prognosis metastatic** disease has distant metastasis with most common location to the pelvis or lung. Cure rate is >95%.
 - **Poor Prognosis metastatic** disease has distant metastasis with most common location to the brain or the liver. Other poor prognosis factors are: serum β -hCG levels >40,000, >4 months from the antecedent pregnancy, and following a term pregnancy. Cure rate is 65%.

Risk Factors. Increased prevalence *geographically* is most common in *Taiwan* and the *Philippines*. Other risk factors are maternal age extremes (<20 years old, >35 years old) and folate deficiency.

Clinical Findings

- **Most common symptom** is bleeding prior to 16 weeks' gestation and passage of vesicles from the vagina. Other symptoms of a molar pregnancy include hypertension, hyperthyroidism, and hyperemesis gravidarum, and no fetal heart tones appreciated.
- **Most common sign** is fundus larger than dates, absence of fetal heart tones, bilateral cystic enlargements of the ovary known as *theca-lutein cysts*.
- **Most common site of distant metastasis** is the lungs.

Diagnosis. "Snowstorm" ultrasound. The diagnosis is confirmed with sonogram showing homogenous intrauterine echoes without a gestational sac or fetal parts.

Management

- Obtain a baseline quantitative β -hCG titer.
- Obtain a chest X-ray to rule out lung metastasis.
- Perform a suction D&C to evacuate the uterine contents.
- Place the patient on effective contraception (oral contraceptive pills) for the duration of the follow-up period to ensure no confusion between rising β -hCG titers from recurrent disease and normal pregnancy.

- Treatment is then based on histology and location of metastasis.
 - *Benign GTN*: Follow weekly serial β -hCG titers until negative for three weeks, then monthly titers until negative for 12 months. *Follow-up is for 1 year*. If serial β -hCG titers plateau or rise, the patients are diagnosed with persistent gestational trophoblastic disease. They should undergo a metastatic workup (CT scans of the brain, the thorax, the abdomen and the pelvis) and be managed as below.
 - *Non-metastatic or Good Prognosis metastatic disease*: Administer *single agent* (methotrexate or actinomycin D) until weekly β -hCG titers become negative for three weeks, then monthly titers until negative for 12 months. *Follow-up is for 1 year*.
 - *Poor Prognosis metastatic disease*: Administer *multiple agent* chemotherapy (which include Methotrexate, Actinomycin-D and Cytoxan) until weekly β -hCG titers become negative for three weeks, then monthly titers for 2 years, then every three months for another 3 years. *Follow-up is for 5 years*.

PELVIC RELAXATION

Uterine Prolapse

A 62-year-old woman complains of low back pain and perineal pressure for 18 months. She had been recommended by another physician to wear a pessary, which she is reluctant to do. At the present time she is reluctant to wear a pessary. On pelvic examination a second-degree uterine prolapse with a cystocele and a rectocele is observed.

Anatomy. The pelvic floor is made up of the diaphragm and perineal membrane.

- *Pelvic diaphragm.* The pelvic diaphragm consists of the levator ani and coccygeus muscles. The levator consists of three muscles: puborectalis, pubococcygeus, and ileococcygeus.
- *Perineal membrane.* This is a triangular sheet of dense fibromuscular tissue that spans the anterior half of the pelvic outlet. The vagina and the urethra pass through the perineal membrane (urogenital diaphragm).
- *Uterine support.* The main structures that support the uterus are the cardinal ligaments, the uterosacral ligaments, and the endopelvic fascia.

Etiology. The etiology of pelvic relaxation is *most commonly* related to childbirth. The mechanical trauma of childbirth stresses and tears the supporting ligaments of the pelvic retroperitoneum in the pelvis whose main function is to support the pelvic viscera.

Classification. The components of pelvic relaxation include uterine prolapse, cystocele, rectocele, enterocele, and urinary stress incontinence. Lesser forms of pelvic relaxation include vaginal or vault prolapse.

- *Uterine prolapse.* The severity of prolapse is indicated by increase in grade from I to IV.
 - Grade I: Cervix descends half way to the introitus.
 - Grade II: Cervix descends to the introitus.
 - Grade III: Cervix extends outside the introitus.
 - Grade IV or procidentia: The entire uterus, as well as the anterior and posterior vaginal walls, extends outside the introitus.

- *Cystocele*. This is defined as herniation or bulging of the anterior vaginal wall and overlying bladder base into the vaginal lumen.
- *Rectocele*. This is defined as herniation or bulging of the posterior vaginal wall and underlying rectum into the vaginal lumen.
- *Enterocele*. This is defined as herniation of the pouch of Douglas containing small bowel into the vaginal lumen.

Diagnosis. The diagnosis of pelvic relaxation is mainly made through observation at the time of *pelvic examination*. The prolapsed vagina, rectum, and uterus are easily visualized particularly as the patient increases intraabdominal pressure by straining.

Management. The management of pelvic relaxation includes medical and surgical treatment.

- *Medical*. These are used in patients with minor degree of relaxation. *Kegel* exercises involve voluntary contractions of the pubococcygeus muscle. *Estrogen* replacement may be useful in postmenopausal women. *Pessaries* are objects inserted into the vagina that elevate the pelvic structures into their more normal anatomic relationships.
- *Surgical*. In patients in whom more conservative management has failed, a surgical approach can be entertained consisting of vaginal hysterectomy with an anterior and posterior vaginal repair. The *vaginal hysterectomy* repairs the uterine prolapse, the anterior vaginal repair repairs the cystocele, and the posterior vaginal repair repairs the rectocele. The *anterior and posterior colporrhaphy* uses the endopelvic fascia that supports the bladder and the rectum, and a plication of this fascia restores normal anatomy to the bladder and to the rectum.

Follow-Up. These patients should be motivated to walk in the immediate postoperative period; however, strenuous activity should be limited for about 3 months postoperatively to avoid recurrence of the relaxation.

Urinary Incontinence

A 58-year-old woman complains of urinary leakage after exertion. She loses urine after coughing, sneezing, and playing golf. She underwent menopause 5 years ago and is not on estrogen therapy. On examination there is evidence of urethral detachment with a positive Q-tip test.

Definition. Urinary incontinence is the inability to hold urine, producing involuntary urinary leakage.

Physiology of Continence. Continence and micturition involve a balance between urethral closure and detrusor muscle activity. Urethral pressure normally exceeds bladder pressure, resulting in urine remaining in the bladder. The proximal urethra and bladder are normally both within the pelvis. Intraabdominal pressure increases (from coughing and sneezing) are transmitted to both urethra and bladder equally, leaving the pressure differential unchanged, resulting in continence. Normal voiding is the result of changes in *both* of these pressure factors: urethral pressure falls and bladder pressure rises. Spontaneous bladder muscle (detrusor) contractions are normally easily suppressed voluntarily.

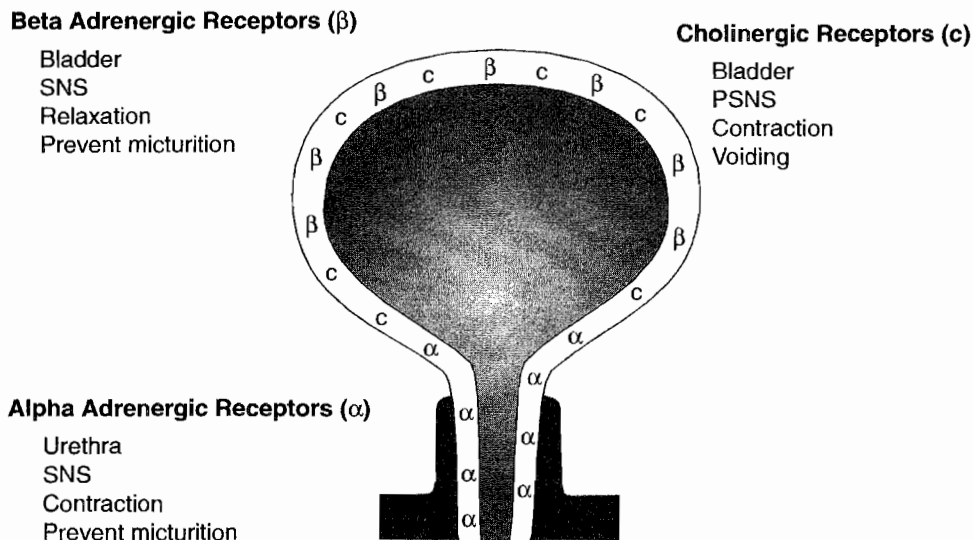


Figure 12-1. Continence and Micturition of Labor

Pharmacology of Incontinence

- *α -Adrenergic receptors.* These are found primarily in the urethra and when stimulated cause contraction of urethral smooth muscle, preventing micturition. *Drugs:* ephedrine, imipramine (Tofranil), and estrogens. *α -Adrenergic blockers or antagonists* relax the urethra, enhancing micturition. *Drugs:* phenoxybenzamine (Dibenzyline).
- *β -Adrenergic receptors.* These are found primarily in the detrusor muscle and when stimulated cause relaxation of the bladder wall, preventing micturition. *Drugs:* flavoxate (Urispas) and progestins.
- *Cholinergic receptors.* These are found primarily in the detrusor muscle and when stimulated cause contraction of the bladder wall, enhancing micturition. *Drugs:* bethanecol (Urecholine) and neostigmine (Prostigmine). Anticholinergic medications block the receptors, inhibiting micturition. *Drugs:* oxybutynin (Ditropan) and propantheline (Pro-Banthine).

Cystometric studies. Basic office cystometry begins with the patient emptying her bladder as much as possible. A urinary catheter is first used to empty the bladder and then left in place to infuse saline by gravity, with a syringe into the bladder retrograde assessing the following:

- *Residual volume.* How much is left in the bladder? Normal is <50 mL.
- *Sensation-of-fullness volume.* How much infusion (in mL) until the patient senses fluid in her bladder? Normal is 200–225 mL.
- *Urge-to-void volume.* How much infusion (in mL) until the patient feels the need to empty her bladder? Normal is 400–500 mL.

Involuntary bladder contractions. By watching the saline level in the syringe rise or fall, involuntary detrusor contractions can be detected. No contractions are normal.

Classification of incontinence

Most of the following types of incontinence result when bladder pressure rises in isolation of increases in urethral pressure.

Irritative Incontinence

- *Etiology.* Involuntary rises in bladder pressure occur owing to detrusor contractions stimulated by irritation from any of the following bladder conditions: infection, stone, tumor, or a foreign body.
- *History.* Loss of urine occurs with urgency, frequency, and dysuria. This can take place day or night.
- *Examination.* Suprapubic tenderness may be elicited, but otherwise the pelvic examination is unremarkable.
- *Investigative studies.* A urinalysis will show the following abnormalities: bacteria and white blood cells (WBCs; suggest an infection) or red blood cells (RBCs; suggest a stone, foreign body, or tumor). A urine culture is positive if an infection is present. Cystometric studies (which are usually unnecessary) would reveal normal residual volume with involuntary detrusor contractions present.
- *Management.* Infections are treated with antibiotics. Cystoscopy is used to diagnose and remove stones, foreign bodies, and tumors.

Genuine Stress Incontinence. This is the *most common* form of true urinary incontinence.

- *Etiology.* Rises in bladder pressure because of intraabdominal pressure increases (e.g., coughing and sneezing) are not transmitted to the proximal urethra because it is no longer a pelvic structure owing to loss of support from pelvic relaxation.
- *History.* Loss of urine occurs in small spurts simultaneously with coughing or sneezing. *It does not take place when the patient is sleeping.*
- *Examination.* Pelvic examination may reveal a cystocele. Neurologic examination is normal. The *Q-tip test* is positive: when a lubricated cotton-tip applicator is placed in the urethra and the patient increases intraabdominal pressure, the Q-tip will rotate >30 degrees.
- *Investigative studies.* Urinalysis and culture are normal. Cystometric studies are normal with no involuntary detrusor contractions seen.
- *Management.* Medical therapy includes Kegel exercises and estrogen replacement in postmenopausal women. Surgical therapy aims to elevate the urethral sphincter so that it is again an intraabdominal location (urethropexy). This is done by attachment of the sphincter to the symphysis pubis, using the Burch procedure as well as the Marshall-Marchetti-Kranz (MMK) procedure. The success rate of both of these procedures is in the 85–90% range. A minimally invasive surgical procedure is the tension-free vaginal tape procedure in which a mesh tape is placed transcutaneously around and under the mid urethra. It does not elevate the urethra but forms a resistant platform against intraabdominal pressure.

Hypertonic, Urge Incontinence

- *Etiology.* Involuntary rises in bladder pressure occur from idiopathic detrusor contractions that cannot be voluntarily suppressed.
- *History.* Loss of urine occurs in large amounts often without warning. This can take place both day and night. The *most common* symptom is *urgency*.
- *Examination.* Pelvic examination shows normal anatomy. Neurologic examination is normal.

- *Investigative studies.* Urinalysis and culture are normal. Cystometric studies show normal residual volume, but *involuntary detrusor contractions are present* even with small volumes of urine in the bladder.
- *Management.* Anticholinergic medications (e.g., oxybutynin [Ditropan]); nonsteroidal antiinflammatory drugs (NSAIDs) to inhibit detrusor contractions; *tricyclic antidepressants*; calcium-channel blockers.

Hypotonic, Overflow Incontinence

- *Etiology.* Rises in bladder pressure occur gradually from an overdistended, hypotonic bladder. When the bladder pressure exceeds the urethral pressure, involuntary urine loss occurs but only until the bladder pressure equals urethral pressure. *The bladder never empties.* Then the process begins all over. This may be caused by denervated bladder (e.g., diabetic neuropathy, multiple sclerosis) or systemic medications (e.g., ganglionic blockers, anticholinergics).
- *History.* Loss of urine occurs intermittently in small amounts. This can take place *both day and night.* The patient may complain of pelvic fullness.
- *Examination.* Pelvic examination may show normal anatomy; however, the neurologic examination will show decreased pudendal nerve sensation.
- *Investigative studies.* Urinalysis and culture are usually normal, but may show an infection. Cystometric studies show *markedly increased residual volume*, but involuntary detrusor contractions do not occur.
- *Management.* Intermittent self-catheterization may be necessary. Discontinue the offending systemic medications. Cholinergic medications to stimulate bladder contractions and α -adrenergic blocker to relax the bladder neck.

Fistula, Bypass Incontinence

- *Etiology.* The normal urethral-bladder mechanism is intact, but is bypassed by urine leaking out through a fistula from the urinary tract.
- *History.* The patient usually has a history of either radical pelvic surgery or pelvic radiation therapy. Loss of urine *occurs continually* in small amounts. This can take place *both day and night.*
- *Examination.* Pelvic examination may show normal anatomy and normal neurologic findings.
- *Investigative studies.* Urinalysis and culture are normal. An intravenous pyelogram (IVP) will demonstrate dye leakage from a urinary tract fistula. With a urinary tract-vaginal fistula, intravenous indigo carmine dye will leak onto a vaginal tampon.
- *Management.* Surgical repair of the fistula.

Table 12-1. Inhibit/Promote Voiding

<u>Inhibit Voiding</u>	<u>Promote Voiding</u>
<u>Bladder relaxants</u>	<u>Bladder contraction</u>
Antispasmodics	
Oxibutinin (Ditropan)	Betanecol (Urocholine)
Flavoxate (Urispas)	Neostigmine (Prostigmine)
Anticholinergics	
Probanthine	
Tricyclics	
Imipramine (Tofranil)	
<u>Vesical neck contraction</u>	<u>Vesical neck relaxants</u>
Alpha adrenergics	Alpha antagonists
Ephedrine	Methyl Dopa
Imipramine	Phenothiazines
Estrogen stimulates alpha receptors	
Progesterone stimulates beta receptors	

PELVIC PAIN AND INFECTIONS

Endometriosis

A 34-year-old woman complains of dysmenorrhea, dyspareunia, and infertility for 2 years. She had used combination oral contraceptive pills from age 25 to 30. Pelvic examination reveals a tender, 5-cm cul-de-sac mass, along with tenderness and nodularity of the uterosacral ligaments.

Definition. Endometriosis is a benign condition in which endometrial glands and stroma are seen outside the uterus. This is not a premalignant condition.

Pathophysiology

- Although the etiology of endometriosis is not known, the most accepted theory of explanation is that of Sampson, which is *retrograde menstruation*.
- The *most common* site of endometriosis is the *ovary*, and because this is functioning endometrium, it bleeds on a monthly basis and can create adnexal enlargements known as *endometriomas*, also known as a *chocolate cyst*.
- The second *most common* site of endometriosis is the *cul-de-sac*, and in this area the endometriotic nodules grow on the uterosacral ligaments, giving the characteristic *uterosacral ligament nodularity* and tenderness appreciated by rectovaginal examination. Menstruation into the cul-de-sac creates fibrosis and adhesions of bowel to the pelvic organs and a rigid cul-de-sac, which accounts for *dyspareunia*.

Clinical Findings

- *Symptoms.* Pelvic-abdominal pain is not necessarily related to the extent of disease. Painful intercourse (*dyspareunia*) is often experienced along with painful bowel movements (*dyschezia*). Infertility of endometriosis is not necessarily related to the extent of disease.
- *Examination.* Pelvic tenderness is common. A fixed, retroverted uterus is often caused by cul-de-sac adhesions. Uterosacral ligament nodularity is characteristic. Enlarged adnexa may be found if an endometrioma is present.
- *Investigative findings.* WBC and erythrocyte sedimentation rate (ESR) are normal. CA-125 may be elevated. Sonogram will show an endometrioma if present.

Diagnosis. The diagnosis of endometriosis is made by laparoscopy. There is a suspicion of the disease based on history and physical examination; however, laparoscopic identification of endometriotic nodules or endometriomas is the definitive way of making the diagnosis.

Medical Therapy of Endometriosis. This seeks to prevent shedding of the ectopic endometrial tissue, thus decreasing adhesion formation.

- *Pregnancy* can be helpful to endometriosis because during pregnancy there is no menstruation and also the dominant hormone throughout pregnancy is progesterone, which causes atrophic changes in the endometrium. However, infertility may make this impossible.
- *Pseudopregnancy* achieves this goal through preventing progesterone withdrawal bleeding. Continuous medroxyprogesterone acetate (MPA [Provera]) or combination oral contraceptive pills (OCPs) can mimic the atrophic changes of pregnancy.
- *Pseudomenopause* achieves this goal by making the ectopic endometrium dormant. The treatment is based on inhibition of the hypothalamic–pituitary–ovarian axis to decrease the estrogen stimulation of the ectopic endometrium. Several medications can be used to achieve inhibition of the axis. These include a testosterone derivative (Danocrine or Danazol) and a gonadotropin-releasing hormone (GnRH) analog (leuprolide or Lupron). The best inhibition of the hypothalamic–pituitary–ovarian axis is achieved by GnRH analogs. GnRH stimulates the pituitary in a pulsatile fashion, and GnRH analogs stimulate by continuous stimulation, which produces a condition known as down-regulation of the pituitary. Although regression of the endometriotic nodules can be achieved, the patient can become symptomatic with menopausal complaints. Patients on Lupron therapy for >3–6 months can complain of menopausal symptoms, such as hot flashes, sweats, vaginal dryness, and personality changes. Lupron medication is continued for 3–6 months' duration, and then a more acceptable medication for the inhibition of the axis can be used, such as birth control pill medication.

Surgical Management of Endometriosis. This approach may be conservative or aggressive.

- *Conservative.* If preservation of fertility is desired, the procedures can be performed in many cases through laparoscopic approach. Lysis of paratubal adhesions may allow adherent fimbria to function and achieve pregnancy. Ovarian cystectomies as well as oophorectomies can be treatment for endometriomas.
- *Aggressive.* If fertility is not desired, particularly if severe pain is present because of diffuse adhesions, definitive surgical therapy may be carried out through a total abdominal hysterectomy (TAH) and bilateral salpingo-oophorectomy (BSO). Estrogen replacement therapy is then necessary.

Follow-Up. Endometriosis is not considered a premalignant condition; however, patients with this disease should be followed up with yearly gynecologic evaluation.

Ectopic Pregnancy

A 28-year-old patient visits the emergency room complaining of unilateral left-sided abdominal pain and vaginal spotting of 3 days' duration. Her last menstrual period was 8 weeks ago, and before this episode she had menses every 28 days. Her only previous pregnancy was an uncomplicated term spontaneous vaginal delivery. She had used intrauterine contraception for 3 years in the past. On pelvic examination, the uterus is slightly enlarged, and there is left adnexal tenderness but no palpable mass. A quantitative serum β -hCG value is 2,600 mIU.

Definition. This is a pregnancy in which implantation has occurred outside of the uterine cavity. The *most common* location of ectopic pregnancies is an oviduct. The *most common* location within the oviduct is the distal ampulla.

Differential Diagnosis. With a positive pregnancy test, the differential diagnosis consists of a threatened abortion, incomplete abortion, ectopic pregnancy, and hydatidiform mole. In a reproductive age woman with abnormal vaginal bleeding, the possibility of pregnancy or complication of pregnancy should always be considered.

Risk Factors. The *most common* predisposing cause is previous pelvic inflammatory disease (PID). Ectopic pregnancy risk is increased from any obstruction of normal zygote migration to the uterine cavity from tubal scarring or adhesions from any origin: infectious (PID, IUD), postsurgical (tubal ligation, tubal surgery), or congenital (diethylstilbestrol [DES] exposure). One percent of pregnancies are ectopic pregnancies, and if the patient has had one ectopic pregnancy, the incidence becomes 15%.

Clinical Findings

- **Symptoms.** The *classic triad* with an unruptured ectopic pregnancy is amenorrhea, vaginal bleeding, and unilateral pelvic-abdominal pain. With a ruptured ectopic pregnancy, the symptoms will vary with the extent of intraperitoneal bleeding and irritation.
- **Signs.** The classic findings with an unruptured ectopic pregnancy are unilateral adnexal and cervical motion tenderness. Uterine enlargement and fever are usually absent. With a ruptured ectopic pregnancy, the findings reflect peritoneal irritation and the degree of hypovolemia. Hypotension and tachycardia indicate significant blood loss. This results in abdominal guarding and rigidity.
- **Investigative findings.** A β -hCG test will be positive. Sonography may or may not reveal an adnexal mass; but most significantly no intrauterine pregnancy (IUP) will be seen.

Diagnosis

- **Background.** The diagnosis of an unruptured ectopic pregnancy rests on the results of a quantitative serum β -hCG titer combined with the results of a vaginal sonogram. It is based on the assumption that when a normal IUP has progressed to where it can be seen on vaginal sonogram at 5 weeks' gestation, the serum β -hCG titer will exceed 1,500 mIU. With the lower resolution of abdominal sonography, an IUP will not consistently be seen until 6 weeks' gestation. The β -hCG discriminatory threshold for an abdominal ultrasound to detect an intrauterine gestation is 6,500 mIU compared with 1,500 mIU for vaginal ultrasound.
- **Specific criteria.** Failure to see a normal intrauterine gestational sac when the serum β -hCG titer is $>1,500$ mIU is presumptive diagnosis of an ectopic pregnancy.

Management

- *Ruptured ectopic.* The diagnosis of ruptured ectopic pregnancy is presumed with a history of amenorrhea, vaginal bleeding, and abdominal pain in the presence of a hemodynamically unstable patient. Immediate surgical intervention to stop the bleeding is vital, usually by laparotomy.
- *Intrauterine pregnancy.* If the sonogram reveals an IUP, management will be based on the findings. If the diagnosis is threatened abortion, the patient should be placed on bed rest. If the diagnosis is hydatidiform mole, the patient should be treated with a suction curettage and followed up on a weekly basis with β -hCG.
- *Possible ectopic.* If the sonogram does not reveal an IUP, but the quantitative β -hCG is $<1,500$ mIU, it is impossible to differentiate a normal IUP from an ectopic pregnancy. Because β -hCG levels in a normal IUP double every 58 h, the appropriate management will be to repeat the quantitative β -hCG and vaginal sonogram every 2–3 days until the β -hCG level exceeds 1,500 mIU. With that information an ectopic pregnancy can be distinguished from an IUP.
- *Unruptured ectopic.* Management can be medical with methotrexate or surgical with laparoscopy. Medical treatment is preferable because of the lower cost, with otherwise similar outcomes.
 - *Methotrexate.* This *folate antagonist* attacks rapidly proliferating tissues including trophoblastic villi. Criteria for methotrexate include pregnancy mass <3.5 cm diameter, absence of fetal heart motion, β -hCG level $<6,000$ mIU, and no history of folic supplementation. Patients with an ectopic pregnancy should be advised of the somewhat increased incidence of recurrent ectopic pregnancies. Follow-up with *serial β -hCG* levels is crucial to ensure pregnancy resolution. Rh-negative women should be administered *RhoGAM*.
 - *Laparoscopy.* If criteria for methotrexate are exceeded, surgical evaluation is performed through a laparoscopy or through a laparotomy incision. The preferred procedure for an unruptured ampullary tubal pregnancy is a *salpingostomy*, in which the trophoblastic villi are dissected free preserving the oviduct. Isthmic tubal pregnancies are managed with a *segmental resection*, in which the tubal segment containing the pregnancy is resected. *Salpingectomy* is reserved for the patient with a ruptured ectopic pregnancy or those with no desire for further fertility. After a salpingostomy β -hCG titers should be obtained on a weekly basis to make sure that there is resolution of the pregnancy. Rh-negative women should be administered *RhoGAM*.

Follow-Up. Patients who are treated with methotrexate or salpingostomy should be followed up with β -hCG titers to assure there has been complete destruction of the ectopic trophoblastic villi.

SEXUALLY TRANSMITTED DISEASES

Spectrum of Organisms

Bacterial. These include chancroid, lymphogranuloma venereum, granuloma inguinale, chlamydia, gonorrhea, syphilis.

Viral. These include condyloma acuminatum, herpes simplex, hepatitis B virus, and human immunodeficiency virus.

Protozoan. This includes trichomoniasis.

Chancroid

Background. This disease is caused by *Haemophilus ducreyi*, a Gram-negative bacterium. It is uncommon in the United States. It is a cofactor for HIV transmission.

Symptoms. This is one of the two STDs that presents with a *painful* ulcer.

Examination. A pustule, usually on the vulva, within 72 hours becomes a painful ulcer with a typically “ragged edge.”

Diagnosis. A positive culture confirms the diagnosis, although a diagnosis is often made clinically after excluding syphilis and genital herpes.

Management. The CDC-recommended treatment includes a single oral dose of Azithromycin, a single IM dose of ceftriaxone, or oral erythromycin base for 7 days.

Lymphogranuloma Venereum (LGV)

Background. This disease is caused by the L serotype of *Chlamydia trachomatis*. It is uncommon in the United States.

Symptoms. The initial lesion is a *painless* ulcer.

Examination. A painless vesiculopustular eruption, usually on the vulva, spontaneously heals. This is replaced within a few weeks by perirectal adenopathy that can lead to abscesses and fistula formation. The classic clinical lesion is a double genitocrural fold, the “groove sign.”

Diagnosis. A positive culture of pus aspirated from a lymph node confirms the diagnosis.

Management. The CDC-recommended treatment includes oral doxycycline or erythromycin base for 3 weeks.

Granuloma Inguinale (Donovanosis)

Background. This disease is caused by *Calymmatobacterium granulomatis*, a Gram-negative intracellular bacterium. It is uncommon in the United States.

Symptoms. The initial lesion is a *painless* ulcer.

Examination. A vulvar nodule breaks down, forming a painless, beefy red, highly vascular ulcer with fresh granulation tissue without regional lymphadenopathy. Lymphatic obstruction can result in marked vulvar enlargement. Chronic scarring can lead to lymphatic obstruction.

Diagnosis. Culture of the organism is difficult but microscopic examination of an ulcer smear will reveal *Donovan bodies*.

Management. The CDC-recommended treatment includes either oral doxycycline or trimethoprim-sulfamethoxazole for 3 weeks.

Chlamydia

Background. This disease is caused by *Chlamydia trachomatis*, an obligatory intracellular bacterium. It is the most common bacterial STD in women, occurring up to five times more frequently than gonorrhea. The long-term sequelae arise from pelvic adhesions, causing chronic pain and infertility. When the active infection ascends to the upper genital tract and becomes symptomatic, it is known as acute pelvic inflammatory disease (acute PID). Transmission from an infected gravida to her newborn may take place at delivery, causing conjunctivitis and otitis media.

Symptoms. Most chlamydial cervical infections, and even salpingo-oophoritis, are asymptomatic.

Examination. The classic cervical finding is *mucopurulent cervical discharge*. Urethral and cervical motion tenderness may or may not be noted.

Diagnosis. Polymerase chain reaction (PCR) and DNA probe assays are used.

Management. The CDC-recommended treatment includes a single oral dose of azithromycin or oral doxycycline for 7 days.

Gonorrhea

Background. This disease is caused by *Neisseria gonorrhoea*, a Gram-negative diplococcus. The long-term sequelae arise from pelvic adhesions, causing chronic pain and infertility. When the active infection becomes symptomatic, it is known as acute pelvic inflammatory disease (acute PID). Systemic infection can occur.

Symptoms. Lower genital tract infection may lead only to vulvovaginal discharge, itching, and burning with dysuria or rectal discomfort. Upper genital tract infection leads to bilateral abdominal-pelvic pain. Disseminated gonorrhea is characterized by dermatitis, polyarthralgia, and tenosynovitis.

Examination. Vulvovaginitis is seen on inspection. Mucopurulent cervical discharge is seen on speculum exam. Cervical motion tenderness is common with bimanual pelvic exam. A Bartholin abscess may be found if the gland duct becomes obstructed due to an acute infection. Petechial skin lesions, septic arthritis, and rarely, endocarditis or meningitis, may demonstrate with disseminated gonorrhea.

Diagnosis. Cervical and rectal swab culture on Thayer-Martin media reveal the organism.

Management. Dual therapy for gonococcus and chlamydia is recommended by the CDC because of the frequency of coinfection. The CDC-treatment recommendations include a single dose of cephalosporin plus a single oral dose of azithromycin. A Bartholin abscess needs to undergo marsupialization.

Condyloma Acuminatum

Background. This disease is caused by the *human papilloma virus* (HPV). It is the *most common* overall STD in women, as well as the most common viral STD. Transmission can occur with subclinical lesions. HPV subtypes 16 and 18 are associated with cervical and vulvar carcinoma. Predisposing factors include immunosuppression, diabetes, and pregnancy.

Symptoms. HPV is subclinical in most infected women. Symptoms of pain, odor, or bleeding occur only when lesions become large or infected.

Examination. Clinical lesions are found in only 30% of infected women. The characteristic appearance of a condyloma is a pedunculated, soft papule that progresses into a cauliflower-like mass. The *most common* site of lesions is the cervix.

Diagnosis. The lesions have an appearance so characteristic that biopsy is seldom necessary.

Management. Treatment is directed only at clinical lesions. Small lesions are treated topically with podophyllin, trichloroacetic acid, or imiquimod. Larger lesions are ablated with cryotherapy, laser vaporization, or surgical excision. No effective systemic therapy is available.

Syphilis

This spirochete STD is discussed in Chapter 4, Perinatal Infections. The CDC-treatment recommendations for nonpregnant penicillin-allergic women include oral doxycycline or tetracycline for 2 weeks.

Herpes Simplex

This viral STD is discussed in Chapter 4, Perinatal Infections.

Hepatitis B Virus (HBV)

This viral STD is discussed in Chapter 4, Perinatal Infections. This is the only STD that can be prevented by immunization. The CDC recommends vaccination of all adolescents.

Human Immunodeficiency Virus (HIV)

This viral STD is discussed in Chapter 4, Perinatal Infections.

Trichomoniasis

This parasitic STD is discussed later in this chapter. It is the *second most common* STD in women.

Pelvic Inflammatory Disease (PID)

A 19-year-old nulligravida presents to the emergency department with bilateral lower abdominal pelvic pain. The onset was 24 hours ago after she had just finished her menstrual period. She is sexually active but using no contraception. Speculum examination reveals mucopurulent cervical discharge. Bimanual pelvic examination shows bilateral adnexal tenderness and cervical motion tenderness. She is afebrile. Her qualitative urinary β -hCG test is negative. Complete blood cell count (CBC) shows a WBC of 14,000. ESR is elevated.

Definition

- *PID spectrum.* PID is a nonspecific term for spectrum of upper genital tract conditions ranging from acute bacterial infection to massive adhesions from old inflammatory scarring.
- *Organisms.* The *most common* initial organisms are *chlamydia* and *gonorrhea*. With persistent infection, secondary bacterial invaders include anaerobes and gram-negative organisms.

Pathophysiology

- *Cervicitis*. The initial infection starts with invasion of endocervical glands with chlamydia and gonorrhea. A mucopurulent cervical discharge may be noted. Cervical cultures will be positive, but symptoms are usually absent.
- *Acute salpingo-oophoritis*. Usually after a menstrual period with breakdown of the cervical mucus barrier, the pathogenic organisms ascend through the uterus, without causing an endometritis, entering the oviduct where acute salpingo-oophoritis develops.
- *Chronic PID*. If the salpingo-oophoritis is not appropriately treated, the body's immune defenses will often overcome the infection but at the expense of persistent adhesions and scarring.
- *Tubo-ovarian abscess (TOA)*. If the body's immune defenses cannot overcome the infection, the process worsens, producing an inflammatory mass involving the oviducts, ovaries, uterus, bowel, and omentum.

Risk Factors. The *most common* risk factor is an adolescent female sexually active with multiple partners. PID is increased in the month after insertion of an IUD, but this is probably exacerbation of preexisting subclinical infection.

Cervicitis

Symptoms. Often there are no symptoms except vaginal discharge.

Examination. The *most common* finding is mucopurulent cervical discharge. No pelvic tenderness is noted. The patient is afebrile.

Investigative Findings. Routine cervical cultures are positive for chlamydia or gonorrhea. WBC and ESR are normal.

Management. Oral tetracycline, doxycycline, erythromycin, or amoxicillin for 7 days.

Acute salpingo-oophoritis

Symptoms. Bilateral lower abdominal-pelvic pain may be variable ranging from minimal to severe. Onset may be gradual to sudden, often after menses. Nausea and vomiting may be found if abdominal involvement is present.

Examination. Mucopurulent cervical discharge, cervical-motion tenderness, and bilateral adnexal tenderness are present. Fever, tachycardia, abdominal tenderness, peritoneal signs, and guarding may be found depending on the extent of infection progression.

Investigative Findings. WBC and ESR are both elevated. Pelvic sonography is usually unremarkable. Laparoscopy will show erythematous, edematous, purulent oviducts. Cervical cultures will come back positive for chlamydia or gonorrhea.

Differential Diagnosis. Adnexal torsion, ectopic pregnancy, endometriosis, appendicitis, diverticulitis, Crohn disease, and ulcerative colitis.

Diagnosis. This is a *clinical diagnosis* based on the finding of: bilateral lower abdominal-pelvic tenderness, mucopurulent cervical discharge, cervical-motion tenderness, and elevated WBC and ESR.

Management. Outpatient or inpatient treatment is indicated, depending on history and clinical findings.

- *Outpatient treatment.* Criteria include a certain diagnosis and no evidence of systemic infection or pelvic abscess. *Medications:* Ofloxacin bid with metronidazole bid, both for 14 days.
- *Inpatient treatment.* Criteria include uncertain diagnosis, nulligravida, adolescent, outpatient treatment failure, IUD in place, evidence of pelvic abscess, and temperature $>39^{\circ}\text{C}$ or 102.2°F . *Medications:* IV cefoxitin or cefotetan plus IV doxycycline or IV clindamycin plus gentamicin.

Chronic PID

Symptoms. Chronic bilateral lower abdominal-pelvic pain is present, varying from minimal to severe. Other symptoms may include history of infertility, dyspareunia, ectopic pregnancy, and abnormal vaginal bleeding. Nausea and vomiting are absent.

Examination. Bilateral adnexal tenderness and cervical-motion tenderness is present, but mucopurulent cervical discharge is absent. Fever and tachycardia are absent.

Investigative Findings. Cervical cultures are negative. WBC and ESR are normal. Sonography may show bilateral cystic pelvic masses consistent with hydrosalpinges.

Diagnosis. This is based on laparoscopic visualization of pelvic adhesions.

Management. Outpatient mild analgesics are used for pain. Lysis of tubal adhesions may be helpful for infertility. Severe unremitting pelvic pain may require a pelvic clean-out (TAH, BSO). If the ovaries are removed, estrogen replacement therapy is indicated.

Tubo-ovarian abscess (TOA)

Symptoms. The patient looks septic. Lower abdominal-pelvic pain is severe. Often the patient has severe back pain, rectal pain, and pain with bowel movements. Nausea and vomiting are present.

Examination. The patient appears gravely sick. She has high fever with tachycardia. She may be in septic shock with hypotension. Abdominal examination shows peritoneal signs, guarding, and rigidity. Pelvic examination may show such severe pain that a rectal examination must be performed. Bilateral adnexal masses may be palpated.

Investigative Findings. Cervical cultures are positive for chlamydia or gonorrhea. Blood cultures may be positive for gram-negative bacteria and anaerobic organisms such as *Bacteroides fragilis*. Culdocentesis may yield pus. WBC and ESR are markedly elevated. Sonography or computed tomographic (CT) scan will show bilateral complex pelvic masses.

Differential Diagnosis. Septic abortion, diverticular abscess, appendiceal abscess, and adnexal torsion.

Management. Inpatient IV clindamycin and gentamicin should result in fever defervescence within 72 h. If patient does not respond, or there is rupture of the abscess exposing free pus into the peritoneal cavity, significant mortality can occur. Exploratory laparotomy with possible TAH and BSO or percutaneous drainage through a colpotomy incision may be required.

Vaginal Discharge

A 25-year-old woman complains of a whitish vaginal discharge. The patient states that this is the first time that she has this complaint, and it is associated with vaginal pruritus. There is no significant medical history, and she is not on oral contraception.

Diagnostic Tests

- *Visual inspection.* The vulva and vagina should be examined for evidence of an inflammatory response as well as the gross characteristics of the vaginal discharge seen on speculum examination.
- *Vaginal pH.* Normal vaginal pH is an acidic <4.5. Identification of the pH is easily performed using pH-dependent Nitrazine paper. Normal vaginal discharge leaves the paper yellow, whereas an elevated pH turns the paper dark.
- *Microscopic examination.* Two drops of the vaginal discharge are placed on a glass slide with a drop of normal saline placed on one, and a drop of KOH placed on the other. The two sites are covered with cover slips, and examined under the microscope for WBC, pseudohyphae, and trichomonads.

Bacterial vaginosis

Background. This is the *most common* (50%) cause of vaginal complaints in the United States. It is not a true infection but rather an alteration in concentrations of normal vaginal bacteria. The normal predominant lactobacilli are replaced by massive increases in concentrations of anaerobic species and facultative aerobes. It is frequently seen postmenopausally because of low levels of estrogen. It is not sexually transmitted, but it is associated with sexual activity.

Symptoms. The *most common* patient complaint is a fishy odor. Itching and burning are not present.

Speculum Examination. The vaginal discharge is typically thin, grayish-white. No vaginal inflammation is noted. The vaginal pH is elevated above 5.0. A positive “*whiff*” test is elicited when KOH is placed on the discharge.

Wet Mount. Microscopic examination reveals “*clue cells*” on a saline preparation. These are normal vaginal epithelial cells with the normally sharp cell borders obscured by increased numbers of anaerobic bacteria. WBCs are rarely seen.

Management. The treatment of choice is metronidazole or clindamycin administered either orally or vaginally. Metronidazole is safe to use during pregnancy, including the first trimester.

Trichomonas vaginitis

Background. This is the *most common* cause of vaginal complaints worldwide and is the third most common *sexually transmitted* disease (STD) in the United States. It is caused by a flagellated pear-shaped protozoan that can reside asymptotically in male seminal fluid.

Symptoms. The *most common* patient complaint is itching, burning, and pain with intercourse.

Speculum Examination. The vaginal discharge is typically frothy and green. The vaginal epithelium is frequently edematous and inflamed. The erythematous cervix may demonstrate the characteristic “*strawberry*” appearance. The vaginal pH is elevated >5.0.

Wet Mount. Microscopic examination reveals actively motile “trichomonads” on a saline preparation. WBCs are seen.

Management. The treatment of choice is oral metronidazole for both the patient and her sexual partner. Vaginal metronidazole gel has a 50% failure rate. Metronidazole is safe to use during pregnancy, including the first trimester.

Yeast vaginitis

Background. This is the second most common of vaginal complaints in the United States. The most common organism is *Candida albicans*. It is not transmitted sexually.

Risk Factors. These include diabetes mellitus, systemic antibiotics, pregnancy, obesity, and decreased immunity.

Symptoms. The most common patient complaint is itching, burning, and pain with intercourse.

Speculum Examination. The vaginal discharge is typically curdy and white. The vaginal epithelium is frequently edematous and inflamed. The vaginal pH is normal <4.5.

Wet Mount. Microscopic examination reveals *pseudohyphae* on a KOH prep. WBCs are frequently seen.

Management. The treatment of choice is either a single oral dose of fluconazole or vaginal “azole” creams. An asymptomatic sexual partner does not need to be treated.

Physiologic discharge

Background. This condition is the result of the thin, watery cervical mucus discharge seen with estrogen dominance. It is a normal phenomenon and becomes a complaint with prolonged anovulation, particularly in patients with wide eversion of columnar epithelium.

Risk factors. These include chronic anovulatory conditions such as polycystic ovarian (PCO) syndrome.

Symptoms. The most common patient complaint is increased watery vaginal discharge. There is no burning or itching.

Speculum Exam. The vaginal discharge is typically thin and watery. The vaginal epithelium is normal appearing with no inflammation. The vaginal pH is normal <4.5.

Wet Mount. Microscopic examination reveals absence of WBCs, “clue cell,” trichomonads, or pseudohyphae.

Management. The treatment of choice is steroid contraception with progestins, which will convert the thin, watery, estrogen-dominant cervical discharge to a thick, sticky progestin-dominant mucus.

CONTRACEPTION

Steroid Contraception

A 44-year-old woman, gravida 4 para 4, presents with questions about oral steroid contraception. She uses a diaphragm but is worried about contraceptive failure. She also expresses concern that her menses have become slightly heavier and more painful. She does not smoke and has no other medical problems.

Mechanisms of Action. These include inhibition of the midcycle luteinizing hormone (LH) surge, thus preventing ovulation; alteration of cervical mucus making it thick and viscid, thus retarding sperm penetration; and alteration of endometrium inhibiting blastocyst implantation.

Estrogen-Mediated Metabolic Effects. These include fluid retention from decreased sodium excretion; accelerated development of cholelithiasis; increase in hepatic protein production (e.g., coagulation factors, carrier proteins, angiotensinogen); healthy lipid profile changes (increase in high-density lipoproteins [HDL]; decrease in low-density lipoproteins [LDL]); and increased venous and arterial thrombosis.

Progestin-Mediated Metabolic Effects. These include mood changes and depression from decreased serotonin levels; androgenic effects (e.g., weight gain, acne); and unhealthy lipid profile changes (decreased HDL, increased LDL).

Absolute Contraindications. These include pregnancy; acute liver disease; history of vascular disease (e.g., thromboembolism, deep venous thrombosis [DVT], cerebrovascular accident [CVA], systemic lupus erythematosus [SLE]); and hormonally dependent cancer (e.g., breast, endometrium).

Relative Contraindications. These include migraine headaches, depression, diabetes mellitus, chronic hypertension, and hyperlipidemia.

Noncontraceptive Benefits. These include decreased ovarian and endometrial cancer; decreased dysmenorrhea and dysfunctional uterine bleeding; and decreased PID and ectopic pregnancy.

Modalities

Combination OCPs. These contain both an estrogen and a progestin. They are administered daily in 4-week cycles with the first 3 weeks on the pills and 1 week off, allowing for withdrawal bleeding to occur. Of all steroid contraceptives, they are the only one to have regular, predictable menses. Failure rate is 2% with ideal use.

Progestin-Only OCPs. They contain only progestins and are sometimes called the "minipill." They need to be taken daily and continuously. A frequent side effect is break-through bleeding. Failure rate is 3% with ideal use.

Progestin-Only injectable. Marketed under the trade name of Depo-Provera, this is an IM injection of depo-medroxyprogesterone acetate (DMPA). The slow release allows administration only every 3 months. A frequent side effect is break-through bleeding. Failure rate is <1%.

Progestin-Only subcutaneous implant. Marketed under the trade name of Norplant, this uses levonorgestrel as the active ingredient. The continuous release continues for 5 years. A frequent side effect is break-through bleeding. Failure rate is <1%.

“Morning-After” Pill. Marketed under the trade name of “Plan B,” it uses levonorgestrel tablets. This postcoital contraception is administered with two tablets taken immediately followed by two additional tablets in 12 h. Nausea is common. Failure rate is 1%.

Case discussion

General. A recent evaluation of women’s views regarding contraceptive health benefits demonstrated that most women are unaware of the protective effects of OCPs against endometrial and ovarian cancer, PID, ectopic pregnancy, benign breast disease, anemia, and dysmenorrhea.

Risks and Benefits. In nonsmoking women older than the age of 40, currently available OCPs are extremely safe. Low-dose contraceptive pills do not significantly increase the risk of cancer, heart disease, or thromboembolic events in women with no associated risk factors (hypertension, diabetes, or smoking). The pill tends to reduce menstrual flow and dysmenorrhea, and it regulates the menses, all of which would be excellent benefits for the patient.

Barrier-Spermicidal Methods

A 16-year-old adolescent comes to the family planning clinic requesting contraception. She has heard about the diaphragm and wonders if it would be appropriate for her.

Mechanisms of Action. These are locally active devices preventing entry of sperm in through the cervix, thus preventing pregnancy.

Advantages. Barrier methods become increasingly effective with advancing age and the associated natural decline in fertility. They do protect against some STDs. They do not have systemic side effects.

Disadvantages. Failure rate approaches 20%. They are coitally dependent, requiring a decision for each use, thus decreasing spontaneity. Barrier methods have no impact on excessive menstrual flow or excessively painful menses.

Specific Types

- **Condoms.** These are penile sheaths that must be placed on the erect penis. No individual fitting is required. They are the *most common* barrier contraceptive method used.
- **Vaginal diaphragm.** This is a dome-shaped device placed in the anterior and posterior vaginal fornices holding spermicidal jelly against the cervix. It can be placed an hour before intercourse. Individual fitting is required. If too large a size is used, it can result in urinary retention.
- **Spermicides.** The active ingredient is nonoxynol-9, a surface-active agent that disrupts cell membranes, thus the possible side effect of genital membrane irritation. These can take the form of jellies or foams placed into the vagina.

Intrauterine System (IUS)

A 30-year-old woman with Crohn disease who periodically requires steroid therapy seeks advice regarding long-term contraception. She has had three pregnancies. A subserosal, fundal fibroid was noted at the time of her previous cesarean section delivery. To her knowledge she is in a mutually monogamous relationship. She was treated for a chlamydia infection 2 months ago but does not like the idea of hormonal contraception and is asking about the risks associated with an IUS.

Mechanisms of Action. These include inhibition of sperm transport; increased tubal motility causing failure of implantation of immature zygote; inhibition of implantation secondary to endometrial inflammation; phagocytic destruction of sperm and blastocyst; and alteration of cervical mucus (only progesterone IUSs).

Absolute Contraindications. Include a confirmed or suspected pregnancy; a known or suspected pelvic malignancy; undiagnosed vaginal bleeding; and known or suspected salpingitis.

Relative Contraindications. Include abnormal uterine size or shape; medical conditions (e.g., corticosteroid therapy, valvular heart disease, or any instance of immune suppression increasing the risk of infection); nulligravidity; abnormal Pap smears; and a history of ectopic pregnancy.

Side Effects. Menstrual bleeding and menstrual pain may be increased with the copper IUS, but not with the progesterone IUSs.

Potential Complications

- *Expulsion* is higher in young, low parity women.
- *Ectopic pregnancy.* The IUS does not increase ectopic pregnancies. However, with pregnancy from failed IUS, the likelihood of it being ectopic is higher because primarily, intrauterine pregnancies are prevented.
- *Septic abortion* occurs in 50% of patients with concurrent pregnancy.
- *Uterine perforation* occurs more likely at time of insertion.
- *PID* may occur within the first 2 months after placement if pathogenic organisms are present in the reproductive tract.

IUS Options

- *“Progestasert.”* This is a progesterone-impregnated IUS that releases the hormone gradually over the period of a year. Annual replacement is necessary. Bleeding and cramping may be decreased. Failure rate is 2%.
- *“Mirena.”* This is a levonorgestrel-impregnated IUS that releases the hormone gradually over the period of 5 years. Bleeding and cramping may be decreased. Failure rate is 2%.
- *Copper T-380A IUS.* Marketed under the trade name “Paraguard,” this copper-banded IUS releases copper gradually over a period of 10 years. Bleeding and cramping may be increased. Failure rate is 1%.

Case Discussion

- **General.** The popularity of the IUS has varied greatly during the past two decades. Despite its excellence as a method of contraception for appropriately selected couples, the IUS has yet to recover from the negative publicity generated by the Dalkon Shield in the late 1970s. Although the hormone-containing IUS is effective for only 1 year, the copper T-380A is effective for 10 years, making it potentially the least expensive contraceptive available.
- **Chlamydia.** The patient's recent chlamydia infection is a significant risk factor for IUS use. Most of the increased risk of infection actually attributable to IUS use is within 20 days after infection; consequently, any vaginal infection should be treated and resolved before insertion of the IUS to prevent introduction of organisms into the upper genital tract. Medical conditions that increase the risk of infection, such as HIV infection and immunosuppressive therapy, are also relative contraindications to IUS use. This patient's periodic need for steroid treatment for Crohn disease is a risk factor.
- **Leiomyomas.** Uterine fibroids could also be a relative contraindication because they alter the shape of the endometrial cavity or cause heavy bleeding. The subserosal fundal fibroids should not interfere with IUS placement.

Sterilization

A 38-year-old multipara has completed her childbearing and is requesting sterilization. All three of her children were delivered vaginally. She has no medical problems and is in good health. General and pelvic examination is unremarkable.

Mechanisms of Action. These are surgical procedures usually involving ligation of either the female oviduct or male vas deferens. After the procedure is performed, there is nothing to forget and nothing to remember. They are to be considered permanent and irreversible.

Tubal Ligation. Destruction or removal of a segment of the oviduct is performed in an operating room through a transabdominal approach usually using a laparoscopy or minilaparotomy. Failure rate is 1 in 200. This is the *most common* modality of pregnancy prevention in the United States. If the procedure fails and pregnancy results, an ectopic pregnancy should be ruled out.

Vasectomy. Destruction or removal of a segment of vas deferens is performed as an outpatient procedure using local anesthesia. Failure rate is 1 in 500. A successful procedure can be confirmed by absence of sperm on a semen specimen obtained 12 ejaculations after the surgery. Sperm antibodies can be found in 50% of vasectomized patients.

SEXUALITY

Sexual Dysfunction

A 31-year-old woman, mother of four children, comes to the office stating she has little interest in sexual intercourse with her husband for the past year. She says sex is painful, but she is able to experience orgasm occasionally. She has had no other sexual partners than her husband. These problems are affecting her marriage. She had a tubal sterilization procedure performed after her last delivery 2 years ago. Medications she is taking include thyroid replacement and fluoxetine.

Human sexual response cycle

Desire. In both women and men the desire for sexual activity is also known as *libido*. Desire is maintained by a balance between *dopamine* stimulation and *serotonin* inhibition. The threshold of response is determined by androgens, especially *testosterone*.

Excitement. This phase is also known as *arousal*. It is mediated by *parasympathetic* connections to the pelvic organs and results in vascular *engorgement*. Arousal in women is generally slower, responds more to *touch* and *psychic* stimuli, and is manifested by vaginal *lubrication*. Arousal in men is generally faster, responds more to *visual* stimuli, and is manifested by penile *erection*.

Plateau. This phase entails progression and intensification of the excitement phase. The length of this phase is variable. The neural pathway and physiologic mechanism is the same as excitement.

Orgasm. This phase is mediated by *sympathetic* connections resulting in reflex tonic-clonic *muscle contractions* of the pelvic floor followed by contractions of the uterus. Women have more individual orgasmic *variability* than men. A unique characteristic of women is the potential for consecutive *multiple orgasms*.

Resolution. This phase is marked by a return to basal physiologic state with reversal of vasocongestion and muscle tension. Resolution tends to be faster for men and slower for women.

Refractory Phase. This is a unique characteristic of men and is the period of inability to be aroused before another orgasm. It frequently varies directly with the age of the man.

Sexual history questions

The following questions should be asked of all new patients in developing a medical data base and problem list.

- *Sexual activity.* Start out with the following initial question: Is the patient currently sexually active? If not now, has she been in past?
- *Current history.* If she is currently sexually active, ask the following: Is the relationship with men or women or both? Is the relationship satisfying? Does she have any difficulty lubricating? Does she have pain with intercourse?
- *Previous history.* What was her age at first intercourse? What is the number of lifetime and current sexual partners? Does she have a history of sexual abuse or rape?

Sexual dysfunctions

Each phase of the sexual response cycle can be dysfunctional.

- *Desire disorders.* Decreased sexual desire is the most common female sexual complaint. It may be organic (e.g., low androgens), medication related (e.g., selective serotonin reuptake inhibitors [SSRIs]), or psychological (e.g., poor partner relationship). *Treatment* can be difficult if it is relational in etiology.
- *Excitement disorders.* This usually results in difficulty in vaginal lubrication. The most common cause is estrogen deficiency. *Treatment* is highly successful.
- *Anorgasmia.* This can be primary or secondary. Inadequate clitoral stimulation is the most common cause. *Treatment* is highly successful using initially self-stimulation then partner education.
- *Dyspareunia.* Since pain with intercourse may arise from both psychological or physical causes, a thorough history and physical examination is essential. *Treatment* is directed at the specific cause found.
- *Vaginismus.* This occurs with painful reflex spasm of the paravaginal thigh adductor muscles. It is the only sexual dysfunction that can be diagnosed on physical examination. *Treatment* is highly successful using vaginal dilators.

SEXUAL ASSAULT

A 21-year-old university student presents to the emergency department stating she was walking home after an evening class when she was assaulted by a male stranger and was raped. She is not crying or upset, but rather looks almost without emotions. She is accompanied by her female roommate.

Definition. Rape is defined as sexual activity without the individual's consent occurring under coercion.

Management

- *Stabilization.* The first step is to determine the patient's vital signs and take whatever is needed to stabilize them. An informed consent needs to be obtained.
- *History-taking.* Record the events that happened in the patient's own words. Also obtain a reproductive, obstetric, sexual, and contraceptive history.
- *Examination.* A thorough general and pelvic examination should be performed with photographic or drawing documentation of any injuries or trauma.
- *Specimens.* A rape kit should be used to obtain biologic specimens (e.g., vaginal, oral, or anal specimens) for DNA or other evidence for use in potential legal proceedings. These must be appropriately labeled and documented, including signatures of receiving authorities. Also obtain baseline laboratory tests: VDRL, HIV screen, pregnancy test, urine drug screen, and blood alcohol level.
- *Prophylaxis.* Antibiotic therapy should be administered prophylactically for gonorrhea (cephalosporin), chlamydia (doxycycline), and trichomoniasis (metronidazole). Active and passive immunization for hepatitis B is appropriate.
- *Pregnancy prevention.* Administer two tablets of high progestin OCPs immediately, repeating two tablets in 12 h. A newly released formulation of levonogestrel tablets (Plan B) are now available specifically for postcoital pregnancy prevention.

Reproductive Endocrinology

13

REVIEW OF MENSTRUAL PHYSIOLOGY

General Considerations

The menstrual cycle is the cyclic pattern of activity of hypothalamus, pituitary, ovary, and uterus that produces a rhythm of bleeding every month for 30 years or more during the active reproductive phase of a woman's life.

Menarche is the first flow that signifies potential reproductivity. Menopause is the termination of the menstrual flow, which signifies diminished ovarian function.

Menstrual cycle occurs with the maturation of the hypothalamic-pituitary-ovarian axis. The hormones produced include gonadotropin-releasing hormone (GnRH) from the hypothalamus, which stimulates follicle-stimulating hormone (FSH) and luteinizing hormone (LH) from the anterior pituitary, which stimulate estrogen and progesterone from the ovarian follicle.

Layers of the Endometrium

Functionalis Zone. This is the superficial layer that undergoes cyclic changes during the menstrual cycle and is sloughed off during menstruation. It contains the spiral arterioles that undergo spasm with progesterone withdrawal.

Basalis Zone. This is the deeper layer that remains relatively unchanged during the menstrual cycle and contains stem cells that function to renew the functionalis. It contains the basal arteries.

Phases of the Endometrium

Menstrual Phase. This is defined as the first 4 days of the menstrual cycle with the first day of menses taken as day 1. It is characterized by disintegration of the endometrial glands and stroma, leukocyte infiltration, and red blood cell (RBC) extravasation. Sloughing of the functionalis and compression of the basalis occurs.

Proliferative Phase. This follows the menstrual phase and is characterized by endometrial growth secondary to estrogen stimulation, including division of stem cells that migrate through the stroma to form new epithelial lining of the endometrium and new endometrial glands. The length of the spiral arteries also increases. *An estrogen-dominant endometrium is unstable and, in the presence of prolonged anovulation, will undergo hyperplasia with irregular shedding over time.*

Secretory Phase. This follows the proliferative phase and is characterized by glandular secretion of glycogen and mucus stimulated by progesterone from the corpus luteum. Endometrial stroma becomes edematous, and spiral arteries become convoluted. *A progesterone-dominant endometrium is stable and will not undergo irregular shedding.* Regression of the corpus luteum

occurs by day 23 if there is no pregnancy, causing decreased levels of progesterone and estradiol and endometrial involution. Constriction of the spiral arteries occurs 1 day before menstruation, causing endometrial ischemia and release of prostaglandins, followed by leukocyte infiltration and RBC extravasation. The resulting necrosis leads to menstruation. When a pregnancy occurs, the serum β -human chorionic gonadotropin (β -hCG) becomes positive at day 22–23 of the cycle. The β -hCG becomes positive when the zygote implants into the endometrium, usually 7–8 days after ovulation. Therefore, the serum β -hCG becomes positive before the missed period.

Menstrual Cycle Hormones

FSH stimulates the growth of granulosa cells and induces the *aromatase* enzyme that converts androgens to estrogens. It raises the concentration of its own receptors on the granulosa cells. It stimulates the secretion of inhibin from the granulosa cells and is suppressed by inhibin.

LH stimulates the production of androgens by the theca cells, which then get converted to estrogens in the granulosa cells by the aromatase enzyme (two-cell theory). It raises the concentration of its own receptors in FSH-primed granulosa cells. The LH surge stimulates synthesis of prostaglandins to enhance follicle rupture and ovulation. The LH surge also promotes luteinization of the granulosa cells in the dominant follicle, resulting in progesterone production as early as the 10th day of the cycle.

Estrogen is produced in the granulosa cells in response to even low FSH concentrations, and stimulates proliferative changes in the endometrium. It has a negative feedback to FSH at the hypothalamic–pituitary level, but has a positive feedback to increase GnRH receptor concentrations. At low estrogen levels there is negative inhibitory feedback for LH release, but as the level of estradiol increase is sustained for 50 h, there is a transition to a positive stimulatory feedback, leading to the LH surge.

Androgens include androstenedione and testosterone. They are precursors of estrogen and are produced in the theca cells. In lower concentrations they stimulate aromatase enzyme activity, whereas at high levels they inhibit it. Androgens inhibit FSH induction of LH receptors.

Progesterone is produced by the corpus luteum and stimulates secretory changes in the endometrium in preparation for blastocyst implantation.

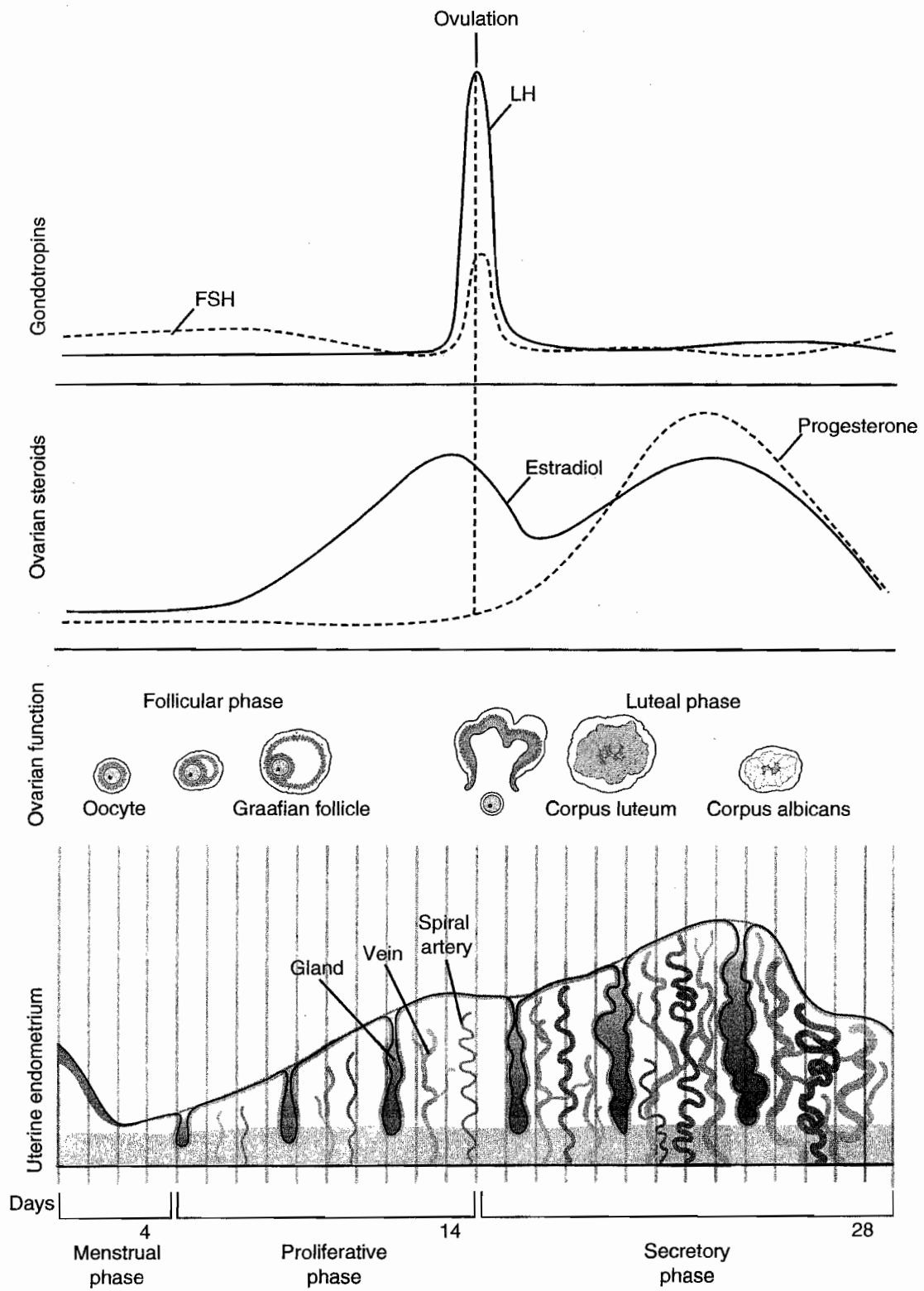


Figure 13-1. The Menstrual Cycle: Pituitary, Ovarian, and Endometrial Correlations

ABNORMAL BLEEDING

Premenarchal Vaginal Bleeding

An 8-year-old girl is brought by her mother to the gynecologist's office because of vaginal bleeding for 2 weeks. The girl states that she has not taken any medication and gives no history suggestive of sexual abuse. She does not complain of headache or visual disturbance and has been doing well in school. On physical examination she is normal for her age without pubertal changes, and pelvic examination under sedation reveals a vaginal foreign body.

Definition. Premenarchal bleeding is bleeding that occurs before menarche. The average age at menarche is 12 years old.

Differential Diagnosis and Etiology. Possible causes include ingestion of estrogen medication, a foreign body that irritates the vaginal lining, a cancer of the vagina or of the cervix (*sarcoma botryoides*), a tumor of the pituitary or adrenal gland, an ovarian tumor, sexual abuse, or idiopathic precocious puberty. The most common cause of premenarchal bleeding is a foreign body.

Diagnosis and Management

- *Pelvic examination.* The patient who complains of premenarchal bleeding should have a pelvic examination under sedation. In this examination, evidence of a foreign body, sexual abuse, or tumor are looked for. Sarcoma botryoides typically looks like grapes arising from the vaginal lining or from the cervix.
- *Imaging study.* A computed tomographic (CT) scan or a magnetic resonance imaging (MRI) scan of the pituitary, abdomen, and pelvis should be done. The scans are looking for evidence of a pituitary, ovarian, or adrenal tumor, which may cause early estrogen production.

Precocious Puberty

A 6-year-old girl is brought to the office by her mother who has noticed breast budding and pubic hair development on her daughter. Her childhood history is unremarkable until 3 months ago when these changes began.

Diagnosis. Criteria for diagnosis include development of female secondary sexual characteristics and accelerated growth before age 8 in girls and age 9 in boys. Precocious puberty is more common in girls than boys.

Normal Pubertal Landmarks. Complete puberty is characterized by the occurrence of all pubertal changes.

- The most common initial change is *thelarche* (breast development at 9–10 years of age).
- This is followed by *adrenarche* (pubic and axillary hair at 10–11 years).
- Maximal growth rate occurs between ages 11 and 12 years.
- Finally, the last change is *menarche* (onset of menses at age 12–13 years).

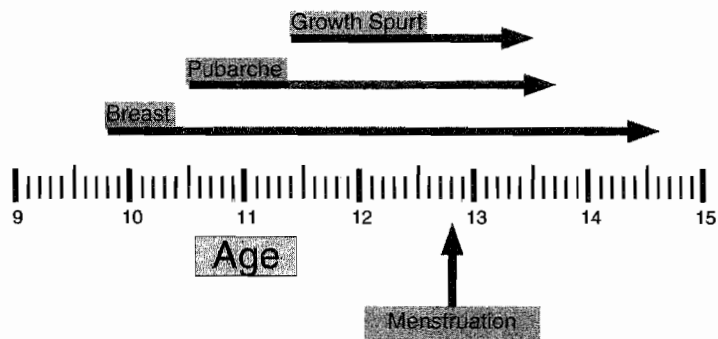


Figure 13-2. Overview of Puberty

Classification of precocious puberty

Incomplete Isosexual Precocious Puberty. This involves only one change—either thelarche, adrenarche, or menarche. This condition is the result of either transient hormone elevation or unusual end-organ sensitivity. Management is conservative.

Complete Isosexual Precocious Puberty. All changes of puberty are seen including breast development, growth spurt, and menstrual bleeding. The primary concern is premature closure of the distal epiphyses of the long bones, resulting in short stature. Fertility and sexual response are not impaired.

- *Gonadotropin-dependent.* This occurs because of increased secretion of estrogens that are dependent on premature release of gonadotropins from the hypothalamus and pituitary.
 - *Idiopathic.* The *most common* explanation is constitutional without a pathologic process present, accounting for 80% of precocious puberty. The age of the patient is usually 6 or 7 years. The diagnosis is usually one of exclusion after CNS imaging is shown to be normal. *Management* is GnRH agonist suppression (leuprolide or Lupron) of gonadotropins until appropriate maturity or height has been reached.
 - *CNS pathology.* This is a rare cause of precocious puberty. A CNS pathologic process stimulates hypothalamic release of GnRH, which leads to FSH release and ovarian follicle stimulation of estrogen production. This may include hydrocephalus, von Recklinghausen disease, meningitis, sarcoid, and encephalitis. CNS imaging is abnormal. The age of the patient is usually <6 years. *Management* is directed at the specific pathologic process.
- *Gonadotropin-independent.* This occurs when estrogen production is independent of gonadotropin secretion from the hypothalamus and pituitary.
 - *McCune-Albright syndrome.* Also known as polyostotic fibrous dysplasia, this disorder is characterized by autonomous stimulation of aromatase enzyme production of estrogen by the ovaries. The syndrome includes multiple cystic bone lesions and *café au lait* skin spots. This accounts for 5% of precocious puberty. *Management* is administration of an aromatase enzyme inhibitor.
 - *Granulosa cell tumor.* A rare cause of precocious puberty is a gonadal-stromal cell ovarian tumor that autonomously produces estrogen. A *pelvic mass* will be identified on examination or pelvic imaging. *Management* is surgical removal of the tumor.

Follow-Up. Patients with idiopathic precocious puberty should be maintained with inhibition of the hypothalamic–pituitary–ovarian axis until the chronologic age catches up with the bone age.

ABNORMAL VAGINAL BLEEDING

A 31-year-old woman complains of 6 months of menometrorrhagia. The patient states that she started having menstruation at age 13 and that she has had regular menses until the past 6 months. The pelvic examination including a Pap smear is normal. She has no other significant personal or family history.

Differential Diagnosis. A patient with irregular bleeding during the reproductive age group should be considered for pregnancy or complications of pregnancy, anatomic causes for the bleeding, or anovulation.

Diagnosis and Management

- **Pregnancy.** In a patient who has abnormal bleeding during the reproductive age group, pregnancy or a complication of pregnancy must first be considered.
 - **Mechanism.** Complications of early pregnancy that are associated with bleeding include incomplete abortion, threatened abortion, ectopic pregnancy, and hydatidiform mole.
 - **Diagnosis.** A β -hCG examination is requested for the confirmation of pregnancy. A pelvic ultrasound will help sort out which pregnancy complication is operative.
 - **Management.** Treatment will vary with the individual diagnosis identified.
- **Anatomic lesions.** If the pregnancy test is negative then anatomic causes of vaginal bleeding should be considered. These are often characterized as unpredictable bleeding occurring between normal, predictable menstrual periods.
 - **Mechanism.** A variety of lower and upper reproductive tract factors can cause bleeding, such as *vaginal* lesions (lacerations, tumors), *cervical* lesions (polyps, cervicitis, tumors), *endometrial* lesions (submucous leiomyomas, polyps, hyperplasia, cancer), or *myometrial* lesions (adenomyosis).
 - **Diagnosis.** Tests that can be performed for anatomic diagnosis include a pelvic examination, saline sonogram, endometrial sampling, and hysteroscopy.
 - **Management.** Treatment will vary with the individual diagnosis identified.
- **Dysfunctional uterine bleeding (DUB).** If the pregnancy test is negative and there are no anatomic causes of abnormal vaginal bleeding, then hormonal imbalance (DUB) should be considered.
 - **Mechanism.** The most common cause of DUB is anovulation, which causes unopposed estrogen. With unopposed estrogen, there is continuous stimulation of the endometrium with no secretory phase. An estrogen-dominant endometrium is structurally *unstable* as it increasingly thickens. With inadequate structural support, it eventually undergoes random, disorderly, and unpredictable breakdown, resulting in estrogen breakthrough bleeding.
 - **Diagnosis.** Anovulatory cycles can usually be diagnosed from a history of *irregular, unpredictable* menstrual bleeding. This bleeding is usually without cramping. Cervical mucus will be *clear, thin, and watery*. A basal-body temperature chart will not show a midcycle temperature rise. An endometrial biopsy will show *proliferative* endometrium.

- **Management.** DUB should be managed either by cyclic progestin therapy from day 14 to 25 of each cycle or by daily combination oral contraceptive pills (OCPs). Progesterone (or progestins) stabilize the endometrium in the latter half of the cycle and prevent random breakdown. When the progestins are discontinued for the last week of the month, spiral arteriolar spasm results in prostaglandin release, necrosis, and orderly shedding of the endometrium. Correctable causes of anovulation, e.g., hypothyroidism or hyperprolactinemia, should be identified by a TSH and prolactin level. Cases that fail hormonal therapy may be managed by either endometrial ablation (using microwave or thermal methods) or hysterectomy.

Postmenopausal Bleeding

(See Chapter 11 under Uterine Neoplasia.)

MENSTRUAL ABNORMALITIES

Primary Amenorrhea

A 16-year-old girl presents with her mother, complaining she has never had a menstrual period. She states that all her daughter's friends in school have menstruated, and she is concerned about her daughter's lack of menstruation. On examination she seems to be well-nourished, with adult breast development and pubic hair present. Pelvic examination reveals a rudimentary vagina. No uterus is palpable on rectal examination.

Definition. Amenorrhea means absence of menstrual bleeding. Primary means that menstrual bleeding has never occurred.

Diagnosis. Primary amenorrhea is diagnosed with absence of menses at age 14 *without* secondary sexual development or age 16 *with* secondary sexual development.

Etiology. The origins of primary amenorrhea can be multiple. The two main categories of etiology are *anatomic* (e.g., vaginal agenesis/septum, imperforate hymen, or Müllerian agenesis) or *hormonal* (e.g., complete androgen insensitivity, gonadal dysgenesis [Turner syndrome], or hypothalamic-pituitary insufficiency).

Clinical Approach—Preliminary Evaluation

- *Are breasts present or absent?* A physical examination will evaluate secondary sexual characteristics (breast development, axillary and pubic hair, growth). *Breasts are an endogenous assay of estrogen.* Presence of breasts indicates adequate estrogen production. Absence of breasts indicates inadequate estrogen exposure.
- *Is a uterus present or absent?* An ultrasound of the pelvis should be performed to assess presence of a normal uterus.

Clinical Approach Based on Findings Regarding Breasts and Uterus

- *Breasts present, uterus present.* Differential diagnosis includes an imperforate hymen, a vaginal septum, anorexia nervosa, excessive exercise, and the possibility of pregnancy before the first menses.
 - History and physical examination will identify the majority of specific diagnoses.
 - Otherwise the workup should proceed as if for secondary amenorrhea.

- *Breasts present, uterus absent.* Differential diagnosis is Müllerian agenesis (Rokitansky-Kuster-Hauser syndrome) and complete androgen insensitivity (testicular feminization). Testosterone levels and karyotype help make the diagnosis.
 - *Müllerian agenesis.* These are genetically normal females (46,XX) with idiopathic absence of the Müllerian duct derivatives: fallopian tubes, uterus, cervix, and upper vagina; the lower vagina originates from the urogenital sinus. Patients with Müllerian agenesis develop secondary sexual characteristics because ovarian function is intact; Müllerian ducts do not give rise to the ovaries. Normal pubic and axillary hair is present. Testosterone levels are normal female. *Management:* These patients should be treated with surgical elongation of the vagina for satisfactory sexual intercourse.
 - *Androgen insensitivity.* In these genetically male (46,XY) individuals, with complete lack of androgen receptor function, their bodies do not respond to the high levels of androgens present. Without androgen stimulation, internal Wolffian duct structures atrophy. With testicular Müllerian inhibitory factor present, the Müllerian duct derivatives involute. Without body recognition of dihydrotestosterone, external genitalia differentiate in a female direction. These patients function psychologically and physically as females and are brought up as girls. At puberty, when primary amenorrhea is noted, the diagnosis is made. Female secondary sexual characteristics are present because the testes do secrete estrogens without competition from androgens. No pubic or axillary hair is noted. Testosterone levels are normal male. *Management:* These women should have their testes removed at the age of 20 because the higher temperatures associated with the intraabdominal position of the testes may lead to testicular cancer. Estrogen replacement is then needed.
- *Breasts absent, uterus present.* Differential diagnosis is gonadal dysgenesis (Turner syndrome) and hypothalamic–pituitary failure. FSH level and karyotype help make the diagnosis.
 - *Gonadal dysgenesis.* Turner syndrome (45,X) is caused by the lack of one X chromosome, which is essential for presence of normal ovarian follicles. Instead of developing ovaries, these patients develop streak gonads. FSH levels are elevated because of lack of estrogen feedback to the hypothalamus and pituitary. No secondary sexual characteristics are noted. *Management:* These patients should be treated with estrogen and progesterone replacement for development of the secondary sexual characteristics.
 - *Hypothalamic–pituitary failure.* In the patient without secondary sexual characteristic but uterus present by ultrasound, another possibility is the hypothalamic causes of amenorrhea (stress, anxiety, anorexia nervosa, excessive exercise). FSH levels will be low. *Kallman syndrome* is the inability of the hypothalamus to produce GnRH and also *anosmia*. The defect is in the area of the brain that produces GnRH, but it's also close to the olfactory center. CNS imaging will rule out a brain tumor. *Management:* These patients should be treated with estrogen and progesterone replacement for development of the secondary sexual characteristics.

Table 13-1. Primary Amenorrhea

BREASTS (Secondary Sex Characteristic)	UTERUS	
	Present (+)	Absent (-)
PRESENT (+)	Breasts + Uterus + <i>Rare</i> Same workup as secondary amenorrhea	Breasts + Uterus - <i>Common</i> Müllerian Agenesis versus Androgen Insensitivity
ABSENT (-)	Breasts - Uterus + <i>Common</i> Gonadal Dysgenesis versus Hypothalamic-Pituitary	Breasts - Uterus - <i>Rare</i> Low yield: not clinically relevant

Secondary Amenorrhea

A 32-year-old woman states that her last menstrual period was 1 year ago. She started menses at the age of 12, and was irregular for the first couple of years. However, since the age of 14 or 15 she recalls having menstruation every 28–29 days. She has not been pregnant and is concerned about the amenorrhea. She has not been sexually active and has not used contraception. She has no other significant personal or family history. Her physical examination, including a pelvic examination, is normal.

Definition. Amenorrhea means absence of menstrual bleeding. Secondary means that previously menstrual bleeding had occurred.

Diagnosis. Secondary amenorrhea is diagnosed with absence of menses for 3 months if previously regular menses or 6 months if previously irregular menses.

Pathophysiology. There are multiple etiologies for secondary amenorrhea, which can be classified by alterations in FSH and LH levels. They include *hypogonadotropic* (suggesting hypothalamic or pituitary dysfunction), *hypergonadotropic* (suggesting ovarian follicular failure), and *eugonadotropic* (suggesting pregnancy, anovulation, or uterine or outflow tract pathology).

Specific etiology

Pregnancy. The first step in the evaluation of a patient with amenorrhea is a β -hCG to diagnose pregnancy. This is the most common cause of secondary amenorrhea.

Anovulation. If no corpus luteum is present to produce progesterone, there can be no progesterone-withdrawal bleeding. Therefore, anovulation is associated with unopposed estrogen stimulation of the endometrium. Initially the anovulatory patient will demonstrate amenorrhea, but as endometrial hyperplasia develops, irregular, unpredictable bleeding will occur. The causes of anovulation are multiple, including polycystic ovary (PCO) syndrome, hypothyroidism, pituitary adenoma, elevated prolactin, and medications (e.g., antipsychotics, antidepressants).

Estrogen Deficiency. Without adequate estrogen priming the endometrium will be atrophic with no proliferative changes taking place. The causes of hypoestrogenic states are multiple, including absence of functional ovarian follicles or hypothalamic–pituitary insufficiency.

Outflow Tract Obstruction. Even with adequate estrogen stimulation and progesterone withdrawal, menstrual flow will not occur if the endometrial cavity is obliterated or stenosis of the lower reproductive tract is present.

Management

Pregnancy Test. The first step in management of secondary amenorrhea is to obtain a qualitative β -hCG test to rule out pregnancy.

Thyrotropin (TSH) Level. If the β -hCG test is negative, hypothyroidism should be ruled out. The elevated thyrotropin-releasing hormone (TRH) in primary hypothyroidism can lead to an elevated prolactin. If hypothyroidism is found, treatment is thyroid replacement with rapid restoration of menstruation.

Prolactin Level

- *Medications.* An elevated prolactin level may be secondary to antipsychotic medications or antidepressants, which have an anti-dopamine side effect (it is known that the hypothalamic prolactin-inhibiting factor is dopamine).
- *Tumor.* A pituitary tumor should be ruled out with a CT scan or MRI of the brain. If a pituitary tumor is found and it is <1 cm in its greatest dimension, the patient can be treated medically with bromocriptine (Parlodel), a dopamine agonist. Whereas if the tumor is >1 cm, the patient is usually treated surgically.
- *Idiopathic.* If the cause of elevated prolactin is idiopathic, treatment is also medical with bromocriptine.

Progesterone Challenge Test (PCT). If the β -hCG is negative, and the TSH and prolactin levels are normal, then administer either a single IM dose of progesterone or 7 days of oral medroxyprogesterone acetate (MPA).

- *Positive PCT.* Any degree of withdrawal bleeding is *diagnostic of anovulation*. Cyclic MPA is required to prevent endometrial hyperplasia. Clomiphene ovulation induction will be required if pregnancy is desired.
- *Negative PCT.* Absence of withdrawal bleeding is caused by either inadequate estrogen priming of the endometrium or outflow tract obstruction.

Estrogen–Progesterone Challenge Test (EPCT). If the PCT is negative, then administer 21 days of oral estrogen followed by 7 days of MPA.

- *Positive EPCT.* Any degree of withdrawal bleeding is *diagnostic of inadequate estrogen*. An FSH level will help identify the etiology.
 - An *elevated FSH* suggests *ovarian failure*. If this occurs before age 25 years, the cause could be Y chromosome mosaicism that is associated with malignancy; so order a karyotype. *Savage syndrome* or resistant ovary syndrome is a condition in which although follicles are seen in the ovary by sonogram, they do not respond to gonadotropins.

- A low FSH suggests *hypothalamic–pituitary insufficiency*. Order a CNS imaging study to rule out a brain tumor. Whatever the result, women with a positive EPCT will need estrogen-replacement therapy to prevent osteoporosis and estrogen-deficiency morbidity. Cyclic progestins are also required to prevent endometrial hyperplasia.
- *Negative EPCT*. Absence of withdrawal bleeding is diagnostic of either an outflow tract obstruction or endometrial scarring (e.g., *Asherman syndrome*). A hysterosalpingogram (HSG) will identify where the lesion is. Asherman syndrome is the result of extensive uterine curettage and infection-produced adhesions. It is treated by hysteroscopic adhesion lysis followed by estrogen stimulation of the endometrium.

Premenstrual Syndrome (PMS)

A 36-year-old patient complains of depression, anxiety, irritability, and breast tenderness, which occur on a monthly basis. On further questioning, this symptomatology most commonly occurs two weeks before her menstruation and disappears with menses.

Definition. PMS includes a wide range of physical and emotional difficulties referred to as PMS, as well as the more severe affective changes included in premenstrual dysphoric disorder (PDD).

Diagnosis

- *Symptom diary*. The basis for diagnosis is a diary of symptoms that the patient keeps throughout three menstrual cycles.
- *Criteria*. All the following must be present: symptoms must be recurrent in at least three consecutive cycles, they must be absent in the preovulatory phase of the menstrual cycle, they must be present in the two postovulatory weeks, they must interfere with normal functioning, and they must resolve with onset of menses.
- *Timing*. The specific symptoms are less important than their temporal relationship to the menstrual cycle.
- *Symptoms*. The symptoms may be of varied descriptions, including fluid retention (bloating, edema, breast tenderness), autonomic changes (insomnia, fatigue, heart pounding), emotional symptoms (crying, anxiety, depression, mood swings), or musculoskeletal complaints (headache, muscle aches, joint aches).

Management. Possible treatments include the following:

- *Selective serotonin reuptake inhibitors (SSRIs)*. Fluoxetine hydrochloride (Prozac); natural progesterone vaginal suppositories; MPA (Depo-Provera), spironolactone, and vitamin B₆ (pyridoxine). All of these options have been proposed for the treatment of PMS, but only fluoxetine, alprazolam (Xanax), and GnRH agonists have been shown in controlled, double-blind trials to be superior to placebo for the more severe symptoms of PDD. Recently reported double-blind trials of fluoxetine have shown reductions of 40–75% in troublesome behavioral and emotional symptoms. Similar outcomes have been reported for buspirone hydrochloride (BuSpar) and meclofenamate sodium in descriptive studies. SSRIs are the *treatment of choice* for emotional symptoms of PMS.
- *Progesterone therapy* has a long history in the treatment of PMS, but neither natural progesterone (vaginal suppositories) nor progestin therapy has been shown to be any more effective than placebo. Because of both a lack of efficacy and the possibility of inducing menstrual irregularities, these agents should not be used.

- *Diuretics.* Because of the common complaint of “bloating” voiced by many patients with PMS, diuretics such as spironolactone have been advocated. Spironolactone has been studied in double-blind, randomized trials, and the results have been mixed. Although spironolactone may relieve some symptoms for some patients, the lack of consistent response across the studies in the literature suggests that other therapy is more effective.
- *Pyridoxine.* Vitamin B₆ in doses of 50-200 mg/d has been suggested as a treatment for PMS. A number of randomized, blinded studies have been performed, but no conclusive findings have emerged. Because of the lack of demonstrated efficacy and the possibility of permanent sensory neuropathy associated with high-dose vitamin B₆ consumptions, the use of vitamin B₆ should be discouraged.

Criteria for premenstrual dysphoric disorder

- A. In most menstrual cycles during the past year, five (or more) of the following symptoms were present for most of the time during the last week of the luteal phase, began to remit within a few days after the onset of the follicular phase, and were absent in the week after menses, with at least one of the symptoms being either (1), (2), (3), or (4):
- (1) Markedly depressed mood, feelings of hopelessness, or self-deprecating thoughts
 - (2) Marked anxiety, tension, or feelings of being “keyed up” or “on edge”
 - (3) Marked affective lability (feeling suddenly sad or tearful or increased sensitivity to rejection)
 - (4) Persistent and marked anger or irritability or increased interpersonal conflicts
 - (5) Decreased interest in usual activities (work, school, friends, hobbies, etc.)
 - (6) Subjective sense of difficulty in concentrating
 - (7) Lethargy, easy fatigability, or marked lack of energy
 - (8) Marked change in appetite, overeating, or specific mood cravings
 - (9) Hypersomnia or insomnia
 - (10) A subjective sense of being overwhelmed or out of control
 - (11) Other physical symptoms such as breast tenderness or swelling, headaches, joint or muscle pain, a sensation of “bloating,” or weight gain
- B. The disturbance markedly interferes with work or school or with usual social activities and relationships with others (e.g., avoidance of social activities, and decreased productivity and efficiency at school or work).
- C. The disturbance is not merely an exacerbation of the symptoms of another disorder, such as major depressive disorder, panic disorder, dysthymic disorder, or a personality disorder, although it may be superimposed on any of these orders.
- D. Criteria A, B, and C must be confirmed by prospective daily ratings during at least two consecutive symptomatic cycles. The diagnosis must be made provisionally before this confirmation.

American Psychiatric Association, Diagnostic and statistical manual of mental disorders, 4th ed. Washington, DC APA, 1994: 717-718.

HORMONAL CONDITIONS

Hirsutism

A 28-year-old woman complains of increased hair growth in the face and on the chest. She states that this has been going on for the past 10 years; however, she is more conscious of it at the present time. Her menses are irregular and unpredictable. Even though she has been married for 8 years and never used contraception, she has never been pregnant. On pelvic examination the ovaries bilaterally are slightly enlarged, but there are no other abnormalities noted.

Definitions

- *Hirsutism.* This is excessive male-pattern hair growth in a woman on the upper lip, chin, chest, abdomen, back, and proximal extremities.
- *Virilization.* This is excessive male-pattern hair growth in a woman *plus other masculinizing signs* such as clitorimegaly, baldness, lowering of voice, increasing muscle mass, and loss of female body contours.

Pathophysiology. Hirsutism involves the conversion of *vellus hair* (fine, nonpigmented hair) to *terminal hair* (coarse, dark hair) within the hair follicle. This conversion is under the influence of androgens. In women, androgens are generally produced in only three body locations: the ovaries, the adrenal glands, and within the hair follicle. The workup of hirsutism will seek to identify which of these body locations is producing the androgens that are responsible for the excess terminal hair.

Clinical Approach

- *History.* Is there a positive family history? What was the age of onset? Was onset gradual or abrupt? Have menstrual periods been irregular or regular? Is medication history positive for androgenic steroids?
- *Examination.* What is body-mass index? Location of excess hair? Evidence of virilization (frontal balding, loss of female body contour, clitorimegaly)? Presence of adnexal masses?

Laboratory Tests. The primary purpose of these tests is to identify elevated free androgens.

- *Dehydroepiandrosterone sulfate (DHEAS).* DHEAS is produced only in the adrenal glands. A markedly elevated DHEAS is consistent with an adrenal tumor.
- *17-OH progesterone.* This is a precursor in the biosynthesis pathway of cortisol. It is elevated in late-onset congenital adrenal hyperplasia (CAH), with 21-hydroxylase deficiency. It is converted peripherally into androgens.
- *Testosterone.* This androgen is produced by both the ovary and the adrenal glands. A mildly elevated level is suggestive of PCO syndrome. A markedly elevated level is consistent with an ovarian tumor.

Clinical entities

Adrenal Tumor

- *History.* Typically the onset has been *rapid* without positive family history.
- *Examination.* Physical examination will show evidence of *virilization*. Pelvic examination is unremarkable.
- *Laboratory tests.* DHEAS level is markedly elevated.
- *Imaging.* CT or MRI scan will show an abdominal-flank mass.
- *Management.* Treatment involves surgical removal of tumor.

Ovarian Tumor

- *History.* Typically the onset has been *rapid* without positive family history.
- *Examination.* Physical examination will show evidence of *virilization*. An adnexal mass will be palpated on pelvic examination.
- *Laboratory tests.* Testosterone level is markedly elevated.
- *Imaging.* Pelvic ultrasound will show an adnexal mass.
- *Management.* Surgical removal of the mass, usually either a Sertoli-Leydig cell tumor or hilus cell tumor.

Congenital Adrenal Hyperplasia (21-Hydroxylase Deficiency)

- *History.* Typically the onset has been *gradual* in the second or early third decade of life and is associated with menstrual irregularities and anovulation. Precocious puberty with short stature is common. Family history may be positive. Late-onset CAH is one of the most common autosomal recessive genetic disorders.
- *Examination.* Physical examination will show evidence of *hirsutism* without virilization. Pelvic examination is unremarkable.
- *Laboratory tests.* Serum 17-OH progesterone level is markedly elevated.
- *Management.* Treatment is medical with continuous corticosteroid replacement, which will arrest the signs of androgenicity and restore ovulatory cycles.

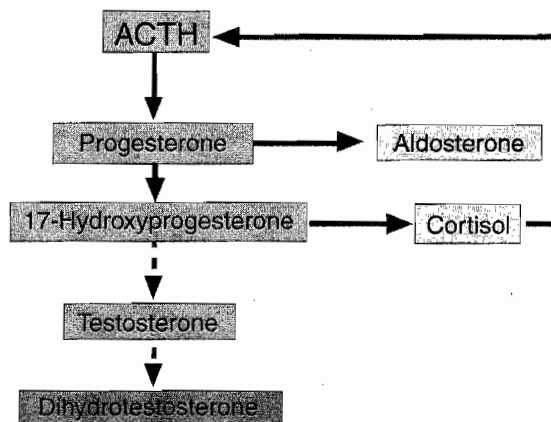


Figure 13-3. Normal Adrenal Function

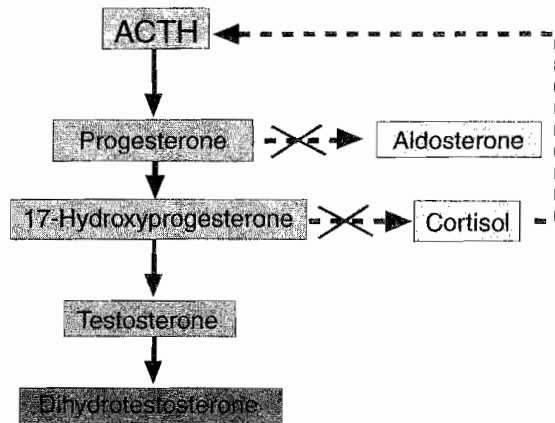


Figure 13-4. Adrenal Hyperplasia

Polycystic Ovarian Syndrome (PCO)

- *History.* Typically the onset has been *gradual*, frequently with a positive family history. In addition, the history is positive for irregular bleeding and infertility.
- *Examination.* Physical examination usually reveals *hirsutism* often with obesity and increased acne. Bilaterally enlarged, smooth, mobile ovaries will be palpated on pelvic examination. *Acanthosis nigricans* may be seen.
- *Laboratory tests.* Testosterone level is mildly elevated. LH to FSH ratio is elevated (3:1). Sex hormone binding globulin (SHBG) is decreased.
- *Imaging.* Pelvic ultrasound will show bilaterally enlarged ovaries with multiple subcapsular small follicles and increased stromal echogenicity.
- *Management.* The treatment of choice is combination OCPs. They will lower free testosterone levels in two ways. First, OCPs will lower testosterone production by suppressing LH stimulation of the ovarian follicle theca cells. Second, OCPs will also increase SHBG, thus decreasing free testosterone level. Metformin can decrease insulin resistance and lower testosterone levels.

Idiopathic

- *History.* Typically the onset has been *gradual*, frequently with a positive family history. Menses and fertility are normal. This is the *most common* cause of androgen excess in women.
- *Examination.* Physical examination reveals *hirsutism* without virilization. Pelvic examination is normal.
- *Laboratory tests.* Normal levels of testosterone, DHEAS, and 17-OH progesterone are identified.
- *Management.* The treatment of choice is *spironolactone*, a potassium-sparing diuretic. Its mechanism of action as an antiandrogen is twofold. First, it is an androgen-receptor blocker. It also suppresses hair follicle 5- α reductase enzyme conversion of androstenedione and testosterone to the more potent dihydrotestosterone.

Polycystic Ovarian Disease

A 32-year-old woman visits the gynecologist's office complaining of vaginal bleeding, facial hair growth, and obesity. She states that she has noted the facial hair growth for many years and the irregular bleeding has been progressively getting worse during the past 6 months. She has no other significant personal or family history, and on pelvic examination she has slightly enlarged bilateral ovaries. A rectovaginal examination is confirmatory.

Definition. Polycystic ovarian syndrome (PCO), historically called Stein-Leventhal syndrome, is a condition of chronic anovulation with resultant infertility. The patient presents typically with irregular vaginal bleeding. Other symptoms include obesity and hirsutism.

Pathophysiology

- *Chronic anovulation.* Instead of showing the characteristic hormone fluctuation of the normal menstrual cycle, PCO syndrome gonadotropins and sex steroids are in a steady state, resulting in anovulation and *infertility*. Without ovulation, there is no corpus luteum to produce progesterone. Without progesterone there is unopposed estrogen. Endometrium, which is chronically stimulated by estrogen, without progesterone ripening and cyclic shedding, becomes hyperplastic with *irregular bleeding*. With time *endometrial hyperplasia* can result, which could progress to endometrial cancer.
- *Increased testosterone.* Increased LH levels cause increased ovarian follicular theca cell production of androgens. The increased levels of androstenedione and testosterone suppress hepatic production of SHBG by 50%. The combined effect of increased total testosterone and decreased SHBG leads to mildly elevated levels of free testosterone. This results in *hirsutism*. PCO is one of the *most common* causes of hirsutism in women.
- *Ovarian enlargement.* On ultrasound the ovaries demonstrate the presence of the necklace-like pattern of multiple peripheral cysts (20–100 cystic follicles in each ovary). The increased androgens prevent normal follicular development, inducing premature follicle atresia. These multiple follicles, in various stages of development and atresia, along with stromal hyperplasia and a thickened ovarian capsule, result in ovaries that are bilaterally enlarged.

Diagnosis

- The diagnosis is suspected in the presence of irregular menstrual bleeding, obesity, hirsutism, and infertility.
- It is confirmed with an LH to FSH ratio, which is in the range of 3:1. The normal LH to FSH ratio in ovulatory patients is 1.5:1.

Management. Treatment is directed toward the primary problem and the patient's desires.

- *Irregular bleeding.* OCPs will normalize her bleeding. The progestin component will prevent endometrial hyperplasia.
- *Hirsutism.* Excess male-pattern hair growth can be suppressed two ways. OCPs will lower testosterone production by suppressing LH stimulation of the ovarian follicle theca cells. OCPs will also increase SHBG, thus decreasing free testosterone levels. Spironolactone suppresses hair follicle 5- α reductase enzyme conversion of androstenedione and testosterone to the more potent dihydrotestosterone.

- *Infertility.* If she desires pregnancy, ovulation induction can be achieved through clomiphene citrate (Clomid) or human menopausal gonadotropin (HMG; Pergonal). Metformin, a hypoglycemic agent that increases insulin sensitivity, can enhance the likelihood of ovulation both with and without clomiphene.

Infertility

A 35-year-old woman comes to the gynecologist's office complaining of infertility for 1 year. She and her husband have been trying to achieve pregnancy for >1 year and have been unsuccessful. There is no previous history of pelvic inflammatory disease and she used oral contraception medication for 6 years. The pelvic examination is normal, and a Pap smear is done.

Definition. Infertility is defined as inability to achieve pregnancy after 12 months of unprotected and frequent intercourse. Both male and female factors have to be evaluated in the patient with infertility. Fifteen percent of American couples suffer infertility.

Fecundability. This is the likelihood of conception occurring with one cycle of appropriately timed midcycle intercourse. With the female partner age of 20 years, the fecundity rate is 20%. By age 35 years, the rate drops to 10%.

Initial noninvasive tests

Semen Analysis

- *Normal values.* Expected findings are volume >2 ml; pH 7.2–7.8; sperm density >20 million/ml; sperm motility >50%; and sperm morphology >50% normal. If values are abnormal, repeat the semen analysis in 4–6 weeks because semen quality varies with time.
- *Timing.* The first step in the infertility evaluation is a semen analysis, which should be obtained after 2–3 days of abstinence and examined within 2 h.
- *Minimally abnormal.* If sperm density is mild to moderately lower than normal, intrauterine insemination (IUI) may be used. Washed sperm are directly injected into the uterine cavity. Idiopathic oligozoospermia is the most common male infertility factor.
- *Severely abnormal.* If semen analysis shows severe abnormalities, intracytoplasmic sperm injection (ICSI) may be used in conjunction with in vitro fertilization (IVF) and embryo transfer.
- *No viable sperm.* With azoospermia or failed ICSI, artificial insemination by donor (AID) may be used.

Anovulation. Of all causes of infertility, treatment of anovulation results in the greatest success.

- *History.* The patient typically gives a history of irregular, unpredictable menstrual bleeding, most often associated with minimal or no uterine cramping.
- *Objective data.* A basal body temperature (BBT) chart will not show the typical midcycle temperature elevation. A serum progesterone level will be low. An endometrial biopsy shows proliferative histology.
- *Correctible causes.* Hypothyroidism or hyperprolactinemia are causes of anovulation that can be treated.

- Ovulation induction.** The agent of choice is *clomiphene* citrate administered orally for 5 days beginning on day 5 of the menstrual cycle. The biochemical structure of clomiphene is very similar to estrogen, and clomiphene fits into the estrogen receptors at the level of the pituitary. The pituitary does not interpret clomiphene as estrogen and perceives a low estrogen state, therefore producing high levels of gonadotropins. *HMG* is administered parenterally and is used to induce ovulation if clomiphene fails. Careful monitoring of ovarian size is important because ovarian hyperstimulation is the *most common* major side effect of ovulation induction. When a patient is given clomiphene, her own pituitary is being stimulated to secrete her own gonadotropins, whereas when a patient is administered HMG, the patient is being stimulated by exogenous gonadotropins.

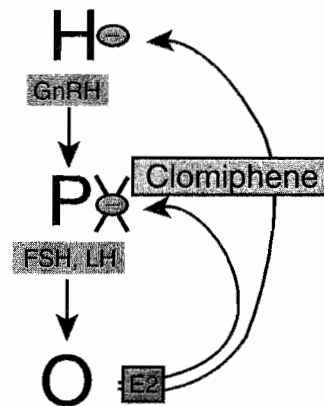


Figure 13-5. Clomiphene Citrate

Follow-up invasive tests

Tubal Disease. Assessment of fallopian tube abnormalities is the next step if the semen analysis is normal and ovulation is confirmed.

- Hysterosalpingogram (HSG).** In this imaging procedure, a catheter is placed inside the uterine cavity, and contrast material is injected. The contrast material should be seen on x-ray images spilling bilaterally into the peritoneal cavity. It should be scheduled during the week after the end of menses after prophylactic antibiotics to prevent causing a recurrent acute salpingitis. No further testing is performed if the HSG shows normal anatomy. If abnormal findings are seen, the extent and site of the pathology is noted and laparoscopy considered.
- Laparoscopy.** If potentially correctible tubal disease is suggested by the HSG, the next step in management is to visualize the oviducts and attempt reconstruction if possible (tuboplasty). If tubal damage is so severe surgical therapy is futile, then IVF should be planned.

Approach if still no pregnancy

Unexplained Infertility

- Definition.** This diagnosis is reserved for couples in which the semen analysis is normal, ovulation is confirmed, and patent oviducts are noted.
- Outcome.** Approximately 60% of patients with unexplained infertility will achieve a spontaneous pregnancy within the next 3 years.

- **Management.** Treatment consists of controlled ovarian hyperstimulation (COH) with clomiphene, and appropriately timed preovulatory intrauterine insemination (IUI). The fecundity rates for 6 months are comparable with IVF with a significantly lower cost and risk.

IVF. With IVF, eggs are aspirated from the ovarian follicles using a transvaginal approach with the aid of an ultrasound. They are fertilized with sperm in the laboratory, resulting in the formation of embryos. Multiple embryos are transferred into the uterine cavity with a cumulative pregnancy rate of 60% after six IVF cycles.

Menopause

A 53-year-old woman visits the gynecologist's office complaining of hot flashes, vaginal dryness, and irritability. She states that her symptoms started 1 year ago and have progressively been getting worse. Her last gynecologic examination was 2 years ago, at which time her mammogram was normal.

Definition

- *Menopause* is defined as 3 months of amenorrhea with elevation of gonadotropins (FSH and LH). The mean age of 51 years is genetically determined and unaffected by pregnancies or use of steroid contraception. Smokers experience menopause up to 2 years earlier.
- *Premature menopause* occurs between ages 30 and 40 years and is mostly idiopathic, but can also occur after radiation therapy or surgical oophorectomy.
- *Ovarian failure* occurs before age 30 years and may be associated with autoimmune disease or Y chromosome mosaicism.

Diagnosis. The diagnosis of menopause is made through serial identification of elevated gonadotropins.

Etiology. The etiology of menopausal symptoms is lack of estrogen.

Clinical Findings. The lack of estrogen is responsible for the majority of menopausal symptoms and signs.

- *Amenorrhea.* The *most common* symptom is secondary amenorrhea. Menses typically become anovulatory and decrease during a period of 3–5 years known as perimenopause.
- *Hot flashes.* Unpredictable profuse sweating and sensation of heat is experienced by 75% of menopausal women. This is probably mediated through the hypothalamic thermoregulatory center. Obese women are less likely to undergo hot flashes owing to peripheral conversion of androgens to estrone in their peripheral adipose tissues.
- *Reproductive tract.* Low estrogen leads to decreased vaginal lubrication, decreased vaginal pH, and increased vaginal infections.
- *Urinary tract.* Low estrogen leads to increased urgency, frequency, nocturia, and urge incontinence.

- *Psychic.* Low estrogen leads to mood alteration, emotional lability, sleep disorders, and depression.
- *Cardiovascular disease.* This is the *most common* cause of mortality (50%) in postmenopausal women, with prevalence rising rapidly after menopause.
- *Osteoporosis.* This is a disorder of decreased bone density leading to pathologic fractures when density falls below the fracture threshold.

Osteoporosis

- *Anatomy.* The most common bone type of osteoporosis is trabecular bone. The *most common* anatomic site is in the vertebral bodies, leading to crush fractures, kyphosis, and decreased height. Hip and wrist fractures are the next most frequent sites.
- *Diagnosis.* The *most common* method of assessing bone density is with a DEXA scan (dual-energy x-ray absorptiometry). The *most common* method of assessing calcium loss is 24-h urine hydroxyproline or NTX (*N*-telopeptide, a bone breakdown product).
- *Risk factors.* The *most common* risk factor is positive family history in a thin, white female. Other risk factors are steroid use, low calcium intake, sedentary lifestyle, smoking, and alcohol.
- *Prevention.* Maximum bone density is found in the mid-20s. Maintenance of bone density is assisted by both lifestyle and medications.
- *Lifestyle.* Calcium and vitamin D intake, weight-bearing exercise, and elimination of cigarettes and alcohol.
- *Medications.* Bisphosphates (e.g., alendronate, risedronate) inhibit osteoclastic activity. Selective estrogen receptor modulators (SERMs; e.g., raloxifene) increase bone density. Bisphosphonates and SERMs are the first choices for osteoporosis treatment. Calcitonin and fluoride have also been used. While estrogen is a highly effective therapy, it should not be primarily used for the treatment of osteoporosis because of concerns detailed in the next paragraph.

Hormone and estrogen therapy

Benefits and Risks

- Estrogen therapy continues to be the most effective and FDA-approved method for relief of menopausal vasomotor symptoms (hot flashes), as well as genitourinary atrophy and dyspareunia.
- The Women's Health Initiative (WHI) study of the National Institutes of Health (NIH) studied 27,000 postmenopausal women with a mean age of 63 years. These included women with a uterus on hormone therapy (HT), both estrogen and progestin, and hysterectomized women on estrogen therapy (ET) only.
- *Benefits:* Both HT and ET groups in WHI had decreased osteoporotic fractures and lower rates of colorectal cancer.
- *Risks:* Both HT and ET groups in WHI were found to have small increases in deep vein thrombosis (DVT). The HT group also had increased heart attacks and breast cancer, but these were not increased in the ET group.
- *Limitations of WHI:* Women with prominent vasomotor symptoms, the most common reason for initiating HT, were excluded from the study. The mean age of 63 years is 10 years past the age that most women begin HT, thus missing the "window of opportunity" immediately after menopause. The same hormone dose was used in both older and younger women.

Contraindications. A personal history of an estrogen-sensitive cancer (breast or endometrium), active liver disease, active thrombosis, unexplained vaginal bleeding.

Modalities. Estrogen can be administered by oral, transdermal, vaginal, or parenteral routes. All routes will yield the benefits described. Women without a uterus can be given continuous estrogen. All women with a uterus should also be given progestin therapy to prevent endometrial hyperplasia. The *most common* current regimen is oral estrogen and progestin given continuously.

Recommendations. Current guidelines for postmenopausal hormone therapy include the following:

- The *only indication* for HT is vasomotor symptoms. It should not be given for prevention of cardiovascular disease. Although HT is effective for prevention of postmenopausal osteoporosis, consider nonestrogen medications first if osteoporosis prevention is the sole reason for using HT.
- The *lowest dose* of HT that will treat the symptoms should be used. This should be re-evaluated on an annual basis.
- The *shortest duration* of HT that will treat the symptoms should be used. This should be re-evaluated on an annual basis.
- *Optimally, do not exceed 4 years.* The increase in breast cancer risk with HT was not found prior to 4 years.

Estrogen alternatives

SERMs. In patients with contraindications to estrogen-replacement therapy, SERMs can be used. These are medications with estrogen agonist effects in some tissues, and estrogen antagonist effects on others. Although protective against the heart as well as bone, these medications do not have much effect on hot flashes and sweats.

- *Tamoxifen* (Nolvadex) is an SERM with endometrial and bone agonist effects, but breast antagonist effects.
- *Raloxifene* (Evista) has bone agonist effects, but endometrial antagonist effects.

BENIGN BREAST LESIONS

Cystic Breast Mass

A 40-year-old menstruating woman had a 2-cm cystic breast mass confirmed by breast ultrasonography.

Diagnosis. Cyst aspiration and fine-needle aspiration are important components in the preliminary diagnosis of breast disorders. Fine-needle aspiration of a palpable macrocyst, the appropriate procedure for this patient, can be performed in an office setting. Interpretation of fine-needle aspiration requires the availability of a trained cytopathologist.

Management. Preaspiration mammography should be obtained. If the cyst disappears and the cytology is benign, no further workup is required.

Fibrocystic Breast Changes

A 30-year-old woman experiences bilateral breast enlargement and tenderness, which fluctuates with her menstrual cycle. On physical examination the breast feels lumpy, and the patient indicates a sensitive area with a discrete 1.5-cm nodule, which she says is consistently painful. A fine-needle aspiration is performed, and clear fluid is withdrawn. Clinically the cysts resolved.

Diagnosis. Cyclic premenstrual mastalgia is often associated with fibrocystic changes of the breast; a condition that is no longer considered a disease but a heterogeneous group of disorders. Breast discomfort may be accompanied by a palpable mass. Fine-needle aspiration can easily distinguish whether a mass is solid or cystic. The procedure requires no special skill other than stabilizing the mass so that needle aspiration can be done with precision. The goal of cyst aspiration is complete drainage of the cyst with collapse of the cyst wall.

Management

- *Mass disappears.* If the cyst fluid is clear, it may be discarded. If the cyst fluid is grossly bloody, it should be sent for cytologic examination to rule out the possibility of intracystic carcinoma. After aspiration, the affected area must be palpated to determine whether there is a residual mass. If there is no residual mass, the patient may be reexamined in 4–6 weeks for the reaccumulation of fluid. If fluid reaccumulates, it may be aspirated again.

- *Mass persists.* A mass that persists requires further workup. A persistent accumulation is managed by mammography and excision. Because changes such as hematoma related to aspiration may affect mammographic appearances, it is recommended that mammography not be performed until 2 weeks after aspiration. Definitive evaluation of a persistent mass requires excisional biopsy.
- *Conservative.* Ultrasonography is useful in distinguishing cysts from solid masses. If ultrasonography has been performed before aspiration and had shown a cyst with distinct smooth contours, an alternative management plan would be conservative follow-up with serial ultrasound scans. If the cyst disappears on aspiration and the fluid is clear, no further workup is required.

Breast Fibroadenoma

A 25-year-old woman visits the gynecologist for routine annual examination. During the examination she has a palpable, rubbery breast mass, which has been present and stable for the past 2 years. The pathology report of fine-needle aspiration was consistent with fibroadenoma.

Diagnosis. Fibroadenomas are the *most common* breast tumors found in adolescence and young women. In approximately 15% of patients they occur as multiple lesions. Clinically, fibroadenomas are discrete, smoothly contoured, rubbery, nontender, freely moveable masses. The most distinctive gross feature of fibroadenomas that allows them to be distinguished from other breast lumps is their mobility. Fibroadenomas arise from the epithelium and stroma of the terminal duct lobular unit, most frequently in the upper outer quadrant of the breast. An association of fibroadenomas with the development of breast cancer has not been well established. Any associated increases in breast cancer risk depends on the presence of proliferative changes in the fibroadenoma itself or in the surrounding breast, and on a family history of breast carcinoma.

Although cysts and fibroadenomas may be indistinguishable on palpation, ultrasound examination easily distinguishes cystic from solid lesions. On fine-needle aspiration, cysts typically collapse, whereas samples from a fibroadenoma present a characteristic combination of epithelial and stromal elements.

Management

- *Conservative.* Some clinicians advocate conservative management of fibroadenomas, especially in young women, because they can be diagnosed by ultrasonography and core-needle biopsy or fine-needle aspiration with a high degree of confidence, and in some cases they will resolve. A survey of patient preferences, however, has revealed that many women choose excisional biopsy even when they are assured that the lesion is benign by fine-needle aspiration.
- *Excision.* Typically, the lesion is “shelled out” with a surrounding thin rim of breast tissue to avoid the necessity of reexcision in the rare instances when the tumor proves to be a *phylloides tumor*. This is a mixed epithelial and stromal tumor that has benign, borderline, and malignant variants. The biology of the phylloides tumor is determined by its stromal elements; in its fully malignant form, it behaves as a sarcoma.

BREAST BIOPSY

Mammography Microcalcifications

A 45-year-old woman visits her gynecologist after having her yearly mammogram done. The mammogram reveals a “cluster” of microcalcifications.

Diagnosis. A geographic cluster of microcalcifications is nonpalpable. Although most of these lesions are benign, approximately 15–20% represent early cancer. An occult lesion requires stereotactic needle localization and biopsy under mammographic guidance. The coordinates of the lesion are calculated by the computer according to the basic principles of stereotaxis. The radiologist selects the length of the biopsy needle, and a core biopsy is obtained. The procedure is performed in an outpatient setting.

Management. Treatment is based on the established histologic diagnosis.

Persistent Breast Mass

A 35-year-old woman has a persistent breast mass after a fine-needle aspiration has been performed. The breast mass is confirmed by ultrasonography.

Diagnosis. With the combination of physical examination, fine-needle aspiration or core biopsy, and mammography, open biopsies are being performed less frequently. Excisional biopsy has the advantage of a complete evaluation of the size and histologic characteristics of the tumor before definitive therapy is selected. An excisional biopsy is usually recommended in the following circumstances:

- Cellular bloody cyst fluid on aspiration
- Failure of a suspicious mass to disappear completely upon fluid aspiration
- Bloody nipple discharge, with or without a palpable mass
- Skin edema and erythema suggestive of inflammatory breast carcinoma, and a needle core biopsy cannot be performed

In the past, recurrent or persistent simple breast cysts were routinely excised. Because of improvement in ultrasonographic technology, these cysts may now be followed conservatively. This patient, who has had a fine-needle aspiration before, is a candidate for an excisional biopsy.

Management. Treatment is based on the established histologic diagnosis.

Bloody Nipple Discharge

A 60-year-old woman comes to the gynecologist's office complaining of a left breast bloody nipple discharge.

Diagnosis. A bloody nipple discharge usually results from an intraductal papilloma. The treatment is total excision of the duct and papilloma through a circumareolar incision. Modern ductography does not reliably exclude intraductal pathology and is not a substitute for surgery in

patients with pathologic discharge. Its utility is in identifying multiple lesions or lesions in the periphery of the breast.

Management. Treatment is based on the established histologic diagnosis.

BREAST CANCER

Breast Cancer Prognosis

A 65-year-old woman visits the gynecologist with a solid 2-cm mass in the upper outer quadrant of the left breast. A biopsy of the lesion is done, which is consistent with "infiltrating ductal breast cancer."

Epidemiology. Breast cancer continues to be the *most common* cancer diagnosed in women of western industrialized countries. An estimated 182,000 new cases of invasive breast cancer were expected to occur among women in the United States during 2000. After increasing by approximately 4% per year in the 1980s, breast cancer incidence rates in women have leveled off in the 1990s to approximately 110 cases per 100,000 women.

Management. The preferred treatment for most patients with stage I or II breast cancer is considered to be breast-conserving therapy with a wide excision, axillary lymph node dissection or sentinel lymph node biopsy, and radiotherapy. Lymphatic mapping and sentinel lymph node biopsy are new procedures that offer the ability to avoid axillary lymph node dissection and its associated morbidity in patients with small primary tumors who are at low risk of axillary node involvement, while still offering nodal staging information.

Prognostic Factors. Some of the key decisions in the current management of primary breast cancer involve the need for prognostication. Prognostic factors serve to identify those patients who might benefit from adjuvant therapy.

- *Lymph node status.* This is important in determining cancer staging and treatment options. Axillary lymph node status is the most important factor in the prognosis of patients with breast cancer. As the number of positive axillary lymph nodes increases, survival rate decreases and relapse rate increases. An adequate dissection usually contains at least 10 lymph nodes; however, because these tumors in 25–30% of patients with negative nodes eventually recur, other biologic prognostic factors also are needed.
- *Tumor size.* This correlates with the number of histologically involved lymph nodes; however, it is also an independent prognostic factor, particularly in node-negative women. The use of size of the tumor, as the most significant prognostic factor, is problematic because 15% of patients with small tumors have positive nodal involvement.
- *Receptor status.* It is standard practice to determine both estrogen and progesterone receptor status at the time of diagnosis for definitive surgical therapy. Although hormone receptor status correlates with the prognosis, it does so to a lesser degree than nodal status. Hormone receptor determination is, however, of critical importance as a predictive factor. A predictive factor is any measurement associated with response or lack of response of a particular therapy.

Estrogen receptor status has clearly shown to be a predictive factor for hormone therapy, either in the adjuvant therapy or the metastatic disease setting. HER-2 (also known as HER-2.neu and c-erbB-2) is an epidermal growth factor receptor on the surface of a cell that transmits growth signals to the cell nucleus. Approximately 25–30% of breast cancers overexpress HER-2, and overexpression of the receptor is associated with poor prognosis. This may be more of a reflection of the biologic correlates of HER-2 overexpression, e.g., rapid tumor cell proliferation, larger tumor size, and loss of hormone receptors, than an independent prognostic indicator.

- *DNA ploidy status.* DNA ploidy status of tumors is determined by flow cytometry. It measures the average DNA per cell. Tumors can be classified as diploid with normal DNA content or aneuploid. Disease-free survival rates are significantly worse in patients with aneuploid tumors than in those with diploid tumors; however, it is unclear whether ploidy has an independent prognostic value.

Node-Positive Early Breast Cancer

A healthy 55-year-old woman had a lumpectomy (negative margins) and axillary node dissection for a 2.5-cm tumor in the upper outer quadrant of the left breast, with three positive lymph nodes. The tumor was positive for both estrogen and progesterone receptors. She comes to the gynecologist's office wanting an opinion about further therapy.

Management. Breast-conserving therapy with a wide excision (lumpectomy), axillary dissection (or sentinel node biopsy), and radiation therapy is considered the preferred treatment for most patients with stage I or II breast cancer.

In patients at moderate or high risk of developing systemic metastasis, it is preferable to give adjuvant therapy, beginning with chemotherapy followed with radiation therapy. This patient has a high risk of recurrence because of the presence of lymph node metastasis, and it would be inappropriate to withhold further therapy.

Another high risk factor that this patient has is that the tumor is larger than 1 cm. Recommended adjuvant treatment for patients with node-positive breast cancer is explained in the table below.

A large number of prospective randomized trials, as well as recent overviews and meta-analysis of adjuvant systemic therapy, have determined that both chemotherapy and tamoxifen therapy reduce the odds of recurrence in breast cancer patients. A few randomized clinical trials and the overview of meta-analysis of randomized clinical trials have suggested that the combination of chemotherapy and tamoxifen is superior to chemotherapy alone or tamoxifen alone in postmenopausal patients with node-positive breast cancer. Women with estrogen receptor-negative breast cancer appear to have no improvement in recurrence or survival from tamoxifen use.

It has been established that combination chemotherapy is superior to single-agent therapy, and that four to six cycles of combination therapy are as effective as more than six cycles of treatment.

Table 14-1. Recommended Adjuvant Treatment for Node-Positive Breast Cancer

Patient Group	Treatment
Premenopausal, ER- or PR-positive	Chemotherapy + tamoxifen Ovarian ablation (or GnRH analog) ± tamoxifen Chemotherapy ± ovarian ablation (or GnRH analog) ± tamoxifen
Premenopausal, ER- and PR-negative	Chemotherapy
Postmenopausal, ER- or PR-positive	Tamoxifen + chemotherapy
Postmenopausal, ER- and PR-negative	Chemotherapy
Elderly	Tamoxifen If no ER and PR expression: chemotherapy

Abbreviations: ER, estrogen receptor; PR, progesterone receptor; GnRH, gonadotropin-releasing hormone. Goldhirsch A, Glick JH, Gelber RD, Senn H-J. Meeting highlights: International Consensus Panel on the Treatment of Primary Breast Cancer. *J Natl. Cancer Inst* 1998;90:1604. By permission of the National Cancer Institute.



BL4018C Printed in USA ©2005 Kaplan, Inc.

KAPLAN[®]
medical

kaplanmedical.com