
Denture and Overdenture Complications

Elena Preoteasa, Cristina Teodora Preoteasa,
Laura Iosif, Catalina Murariu Magureanu and
Marina Imre

Additional information is available at the end of the chapter

<http://dx.doi.org/10.5772/59250>

1. Introduction

Dentures and overdentures, the most frequently used treatment options for the complete edentulism, can have local and systemic complications. For their prevention, treatment and reduction of their negative impact, it is necessary to understand their etiological context and to know their particularities of manifestation. Considering the relatively high rate of some complications of denture and overdenture treatment, knowing them is essential for ensuring a treatment that corresponds to the medical standards of care and patients' needs and expectations.

2. Context of denture and overdenture complications

All medical treatments should be approached with a holistic perspective in mind, due to the fact that there are numerous factors which, through interacting each other, have an impact on the final medical outcome. Understanding the problem and its realistic possible approaches, but also considering its treatment limitations and performing an analysis that evaluates the medium and long-term prognosis ensures the highest premises for obtaining a good result.

The previous also applies to the treatment of edentulism using dentures or overdentures. Some of the key aspects that might help understand better the denture and overdenture complications, as they define the etiological context, are mentioned in Table 1.

Context	General medical and social factors	Medical and social perception of edentulism Demographics of edentulism
	Denture and overdenture treatment factors	Treatment difficulty
		Treatment options overview
		Maintenance therapy
Edentulous patient factors	Technical and biomechanical considerations	
	Previous dental treatments	
	Oral health status	
Context	Edentulous patient factors	Systemic health status and medication use
		Age
		Health risk factors
		Patient need and preferences

Table 1. Context of denture and overdenture complications – key factors

2.1. Medical and social perception of edentulism

Edentulism is defined as the loss of all permanent teeth. Tooth loss is an outcome of a complex interaction between disease entities (e.g., caries and periodontal disease) and non-disease entities (e.g. economy, oral healthcare system, access to dental services, dental awareness, cultural tradition, education) [1]. Continuing exposure to risk factors after onset of edentulism (e.g., poor oral hygiene, smoking, deficient dental treatment) can have an etiological role in the occurrence of complication.

Edentulism is a chronic, severe, irreversible medical condition and is described as the final marker of disease burden for oral health [2,3]. It is common for elderly people, but it is not regarded any more as an inevitable phenomenon that comes with age [4].

Edentulism has several deleterious consequences on oral health (e.g., residual ridge resorption, impaired masticatory function, trouble speaking), general health (deficient nutritional status, increased risk for certain systemic diseases), mental and social well-being (dissatisfaction with appearance, avoidance of social contacts) and on quality of life [1,2,4]. The previous have impact on prosthetic treatment to be performed.

Thus, the current perception on edentulism is as non-fatal sequelae of diseases and injuries, which still represents a tremendous global health care burden [5,6]. It can be considered a physical impairment, because important body parts have been lost, a disability, because it associates functional limitations or a handicap, as it sometimes limits or prevents normal life or work activities [1,2,7-9].

Considering the impact and demographics of the edentulism, the health care barriers that older people face, the Active Ageing approach of the World Health Organization (keeping older people socially engaged and productive), intensive measures and new regulations regarding caring for the elderly population are needed. Consequently, implementation of gerodontology, as a new dental specialty, may be appropriate [10].

2.2. Demographics of edentulism

According to the current reports and predictions, edentulism is and will continue to represent a common disease for the elderly people segment.

There is a tendency for reduction of the edentulism prevalence, through the reduction of tooth loss. Thus, in the United States in the period of 1999-2004, the prevalence of tooth retention in seniors (65 years and older) significantly increased from 17.9 teeth to 18.9 teeth and the prevalence of edentulism significantly decreased from approximately 34% to 27% [11]. This phenomenon can be justified through the progress made in the dental field, the emphasis on prevention measures, improved access to dental care services and mass education for approaching a healthy behavior [4]. But, despite these efforts, complete edentulism continues to have a high prevalence, aspect associated mainly to the aging population phenomenon through growth of the life expectancy and thus the number of elderly people and the number of edentulous patients [12,13].

Estimates show that edentulism is found in 2.3% of the world's population regardless of age, respectively in 7-69% of adult populations internationally [5,14]. Considerably high disparities are noted between different countries, different regions, due to the important impact of the socio-economical and behavioral factors.

The prognoses show that edentulism is decreasing, but most probably will continue to be a condition with a significant prevalence, especially in elderly's people, which is estimated to be a growing category in the global population [15]. Douglas estimates that in the United States the population with one or two edentulous jaws will increase from 34 million in 1991 to 38 million in 2020 [1,12]. Felton considers that most probably the necessity for complete denture therapy will not disappear over the next 4 or 5 decades, and the economic conditions may even lead to a growing need [1,6].

2.3. Treatment difficulty

Edentulism is generally regarded as a clinical condition with a high degree of treatment difficulty, often being hard to achieve optimal functional parameters. The complexity of the edentulous condition derives from the extensive oral changes, both anatomical and functional, that sometimes require preprosthetic surgical intervention in order to optimize the biomechanical conditions, which are superimposed on general alterations (related to age, systemic disease, and psychosocial status). In order to support the differentiation of cases according to their treatment difficulty degree, the ACP (American College of Prosthodontists) has put together the Prosthodontic Diagnostic Index (PDI) Classification System for the complete edentulism [16]. Higher complexity of edentulism condition increase the risk of treatment complication (e.g., in cases with severe ridge resorption ill-fitting dentures are more frequently noticed), and complications can also contribute to increasing the degree of treatment difficulty (e.g., wearing unstable dentures accelerate the ridge resorption rate).

2.4. Treatment options overview

Complete denture used to be the only treatment option for the complete edentulism. Nowadays, this is still the most frequently used treatment option, but there can be seen a growing

trend towards using implant prosthetic restorations fixed or removable. Each treatment option has the risk of specific complications, dependent on their manufacturing particularities and bio-mechanical features.

Dentures can have both local and systemic complications, such as gingival hyperplasia, denture stomatitis, loss of denture retention, fracture of the denture and functional impairment, mastication deficiencies having a negative impact on the nutritional status. Some patients cannot tolerate the dentures, aspect that can be connected to psychological factors, to patients' needs and expectations, but also to age, oral conditions, denture deficiencies and doctor-patient relationship.

Root supported overdentures, with or without attachment systems, have the advantage of improved retention and stability, with a positive impact on the oral functions and the accommodation with the future dentures. Their possible complications include the ones of the conventional dentures and, additionally, some modifications of the supporting teeth or the attachment system used.

Prosthetic implant restorations, either fixed or a removable, are alternatives that provide an improved functional integration and better treatment outcome, but are more complex and require preprosthetic interventions, with additional biological, financial and time costs. Using these treatment options involves the risk for additional complications, with regards to the higher complexity of the treatment –e.g., treatment plan related, surgical complications, technical complications.

2.5. Maintenance therapy

Maintenance is very important for the longevity of the treatment, having a positive impact in reducing the frequency and severity of its complications. Both type of procedures, those performed in the dental office, by the dentist and at home, by the patient, are relevant in this respect.

Periodical check-ups are essential, considering that there are some complications with a high prevalence rate both for dentures and implant overdentures (e.g., loss of denture stability due to progressive ridge resorption, denture adjustments and relinings, clip activations) [17]. Additionally, the edentulous patients are often elderly patients, and face access barriers to dental care services, in relation to aspects like lack of finances or transportation difficulties [18,19]. Due to this, it is recommended to keep in mind the possible complications and to take the appropriate preventive measures to limit them at the time the treatment is being planned and performed.

Informing and instructing the patient on how to take proper care of the oral care and prosthetic restorations are important aspects, since complications can be tightly related to this (e.g., the lack of appropriate cleaning of the denture, teeth or implants is associated with a higher risk for denture stomatitis, tooth or implant loss). Since we are frequently dealing with elderly people, who have less manual dexterity, it is recommended to choose simpler treatment option (e.g., if applicable, 2-implant overdentures are more appropriate than 4-implant overdenture [20]).

2.6. Technical and biomechanical considerations

According to the current level of knowledge, treatment with dentures or implant/root overdentures must consider the risk for developing complications in relation to the technical and biomechanical features (e.g., design, attachment components, materials).

There are different types of design for dentures and overdentures, with different possible complications. Thus, using narrow-diameter implants associates a higher risk of implant fracture. Considering the occlusal scheme, there is evidence that patients prefer dentures with lingualized occlusion [21]. Metal or non-metal (glass and polyethylene fibers) inserts are recommended for denture base reinforcement when there is a high risk of denture fracture or when there are more than 2 teeth or implants supporting the denture [22].

Material used for denture/overdenture fabrication associates the risk of developing complications in relation to their physico-chemical properties and their biocompatibility. For example, polymethylmethacrylate (PMMA), the material mostly used for manufacturing of dentures or overdentures, through its features (porosity, increased wettability, low mechanical strength, monomer release after curing) facilitates the occurrence of complications such as microbial or contact denture stomatitis, fracture of the dentures, artificial teeth discoloration and wear [23].

2.7. Previous dental treatments

A key element in order to achieve a predictable outcome is the analysis of the previous dental and prosthetic treatments, by connecting patient's subjective complaints with prosthetic restoration's objective deficiencies. This gives important information that could be used for decision making in establishing the particularities of the future prosthetic treatment. For example, complete denture intolerance can be linked to personality traits, to objective patient's features that enhance the occurrence of functional deficiencies, or to some objective faults of the dentures. Differentiating between these three situations is the basis for selecting the optimal treatment option, with the possibility to prevent the complications that occurred in the past.

2.8. Oral health status

The complete edentulism cannot be regarded simply as the loss of teeth. It is accompanied by massive, progressive changes of the oral structures and functional alterations, which associates a high degree of treatment difficulty and the occurrence of specific complications. Impact of edentulism on oral health is mainly manifested in 3 directions: modifier of normal physiology; risk factor for impaired mastication; determinant of oral health [2]. Amongst the sequelae of treatment with complete dentures, as the most commonly used treatment option, there can be mentioned residual ridge resorption, mucosal reactions, burning mouth syndrome, denture stomatitis [24].

Considering the severe changes of the oral status in edentulous patients, the increasing elderly population and the relatively frequent barriers to oral health care of older people (e.g., financial hardship, transportation difficulties), Petersen et al. makes a series of recommendations among

which are the incorporation of age related oral health concerns into the promotion of general health, that could ease the development of oral health care for older people [25].

2.9. Systemic health status and medication use

Between oral health and general health there are numerous interactions, that sometimes materializes as local or systemic complications.

The impact of complete edentulism on the general health status is manifested as an increased risk of conditions, such as nutritional deficiencies, inflammatory changes of the gastric mucosa, peptic or duodenal ulcers, obesity, noninsulin-dependent diabetes mellitus, hypertension, heart failure, ischemic heart disease, stroke, aortic valve sclerosis, chronic kidney disease, sleep-disordered breathing, including obstructive sleep apnea [2]. Additionally, functional limitations, mental and social well-being alterations that negatively impact the quality of life are more common in edentulous patients.

The impact of general health status and the medication used on the oral health of the edentulous patient is partially manifested through the occurrence of complications. Nutritional deficiencies increase the risk of occurrence of denture stomatitis, traumatic ulcer and burning mouth syndrome [25]. Patient's personality and psychological well-being influences treatment satisfaction and tolerance [10]. Decreased manual dexterity has a negative impact on care and maintenance of dentures/overdentures, which leads to negative effects on oral and systemic health [14].

2.10. Age

Patient's age is an important aspect to consider when planning the prosthetic treatment, being linked to particularities of oral and general health status, to specific needs and expectation towards the prosthetic rehabilitation, to particular medical approaches in order to ensure a good long-term prognosis. Prosthetic treatment of the edentulous patient should take into account the current situation, but also the most probable evolution and, if present, the inherent complications (e.g., preventive measures to reduce alveolar ridge resorption are recommended).

Young-elderly edentulous patients generally have more favorable clinical conditions for prosthetic rehabilitation, a better general health status, a faster adaptation to removable prosthesis if chosen and the ability to perform most accurately the necessary the maintenance procedures. They have higher expectations regarding the esthetics and functionality of the prosthetic rehabilitation and don't easily accept the removable treatment options.

Old-elderly edentulous patients generally register an increased treatment difficulty, as a consequence of numerous factors interacting. In previous ill-fitting complete denture wearers there is a severe ridge resorption [26,27]. The prevalence of co-morbidities is increased, such as physical or mental health problems that have a negative impact on oral health, systemic health, functioning and behavior. Most of the times the elderly people are not regular users of dental services since they overcome physical and psychological access treatment barriers (e.g.,

the cost of dental care services, transportation problems, doctor's attitudes-lack of responsiveness to patient's concerns, the lack of perceived need for care, fear), which are more significant for the functionally dependent elderly than for the independent elderly [28-30]. They have treatment expectations that target first the rehabilitation of the masticatory function, and second the esthetics. They usually prefer more simple medical procedures, that include limited surgical interventions and that demand easy maintenance procedures. The older completely edentulous patients show a more frequent rate of denture intolerance, probably due to less adaptability to new situations.

Demographic changes, namely population ageing and decreasing prevalence of tooth loss, have impact on the edentulous patient profile. There is an increasing of the age when edentulism occurs, aspects that associates an increased treatment difficulty. Considering the latter, additional measures are necessary to ensure adequate oral health for older edentulous patients e.g., access to and financing for dental services, an adequately trained workforce to provide dental care and appropriate education to edentulous individuals [30].

2.11. Health risk factors

Health risk factors should be assessed since they can explain some of the case particularities and may have a negative impact on the treatment outcome. Among them, there can be mentioned behavioral risk factors (e.g. tobacco and alcohol consumption, obesity related to physical activity and diet), social risk factors (e.g., socio-economical status, social networks and social support, occupational factors, social inequalities), inadequate disease screening practices, exposure to increased stress [31]. Their role is proven both as a cause of complete edentulism and also as a factor that impacts the treatment outcome, being risk factors for some complications.

2.12. Patient need and preferences

Health care decisions require integrating the patient's individual preferences and values, according to the ethical principle of respecting the patient's autonomy [32]. A good relation and communication between doctor and patient offers the best premises for reaching a consensus regarding the medical decision, with a positive effect on the treatment outcome.

Patient preferences are related to numerous variables, e.g., age, social status, personality type, education. Acknowledging them may be difficult, especially in elderly patients, sometimes in relation to objective reasons, as physical changes that affect the communication (e.g., loss of hearing or visual acuity). Additional efforts should be made in order to understand the patient's health needs and preferences, since they can have important consequences, such as rejection of the prosthetic treatment or even avoiding addressing for medical treatment.

3. Classification of denture and overdenture complications

The classification of denture and overdenture complications can enhance practitioner's understanding of them, with a positive effect on their management and prognosis.

Denture and overdenture complications can be classified considering their etiology, according to risk factor's nature and mechanism of action, as described in table 2, or in regarded to some descriptive criteria, as presented in table 3.

Classification of denture and overdenture complications, considering their etiology

A. According to the nature of the risk factor

Host or patient related factors

- *edentulism-related*, e.g., ridge resorption, impaired mastication;
- *oral health-related*, excluding the conditions linked to edentulism, e.g., reduced salivary flow increases the risk for denture stomatitis and denture intolerance;
- *systemic health-related*, including medication use, e.g., diabetes mellitus is a risk factor for denture stomatitis; the bisphosphonate treatment is a risk factor for osteonecrosis;
- *patient's behavior and other characteristics-related*, like income and social status, education, physical environment, e.g., poor financial status limits the access to dental treatment;

Dental treatment related factors

- *removable dental prosthesis-related*, considering the manufacturing accuracy, technical features and materials used, e.g., overextended dentures causes traumatic ulcers or hyperplasia; artificial teeth wear is linked to mastication deficiencies; allergic reactions to polymethylmethacrylate (PMMA);
- *teeth or dental implants-related*, e.g., periodontal disease of supporting roots causes denture instability; implant overdentures have additional surgical complications like nerve injury; treatment failure may appear consequently to tooth or dental implant loss;
- *attachment system-related*, e.g., ill-fitting overdenture due to loosening or loss of the matrix;

Dentist's intervention related factors [33]

- *inherent complications*, in which dentist's role is irrelevant, e.g., allergic reaction to polymethylmethacrylate (PMMA), when patients' history is inconclusive;
- *passive intervention*, as improper conduct regarding early signs of disease, e.g., implant loss due to excessive denture pressure or due to ignored early signs of peri-implantitis;
- *wrongful judgment*, as errors in conceiving and conducting the treatment, e.g., improper implant location or number; incorrect registration of maxillomandibular relationship, as an increased vertical dimension of occlusion.

B. According to the mechanism of action of the risk factor

Susceptibility factors increase the chance of complications occurrence, e.g., implant failure is frequenter in smokers and diseases like diabetes;

Initiation factors directly initiate the complication, e.g., overextended dentures cause traumatic lesions of the oral mucosa;

Progression factors cause worsening of a preexistent condition, e.g., ill-fitting dentures increase the rate of alveolar ridge resorption.

Table 2. Classifications of denture and overdenture complications, considering their etiology

Descriptive classification of denture and overdenture complications

A. According to localization

Host

- *oral*, e.g., oral soft and hard tissue complications, functional alterations; remaining teeth complications in case of root overdentures as caries, periodontal disease, root fracture;
- *facial*, e.g., aged prognathic appearance;
- *systemic*, e.g., malnutrition, gastro-intestinal disorders;

Dental restoration

- *removable dental prosthesis*, e.g., denture/overdenture fracture; retention loss; aging of the material, teeth wear
- *dental implants*, that are classified according to Berglundh et al. [34] as biological complications (functional disturbances that affect the tissues supporting the implant, e.g., peri-implantitis) or technical complications (mechanical damage of the implant, implant components and suprastructures)
- *attachment system*, e.g., loosening, loss, damage

B. According to modification type

Anatomical changes, e.g., alveolar ridge resorption; decrease of the muscular mass;

Functional changes, e.g., mastication or phonation deficiencies, protruded mandibular position;

Pathological changes, e.g., traumatic ulcers, atrophic stomatitis, candidiasis.

C. According to severity

Light – few clinical signs, whose treatment is simple, requires reduced costs in terms of biological, financial and clinical time and has a good prognosis, e.g., loosening of attachment system; ulcerations or irritations related to surplus material on denture's base;

Moderate – functional alterations are associated and treatment requires medium costs, e.g., denture base fracture; loss of stability and need for relining; artificial tooth wear;

Severe – associates important functional alterations, can lead to treatment failure, addressing them imply high costs, e.g., damage of inferior alveolar nerve, denture intolerance.

D. According to the moment of occurrence

During the preprosthetic procedures, e.g., pain during the surgical procedures for frenum plastia or reshaping of exostosis;

While manufacturing the removable prostheses, e.g., discomfort due to vomiting reflex;

During the surgical phase of implant placement, according to Misch & Wang [35] being encountered treatment plan-related complications (e.g., wrong angulation or improper implant location), anatomy-related complications (e.g., nerve injury, bleeding, cortical plate perforation, sinus membrane complication), procedure-related complications (e.g., mechanical complications, lack of primary stability, ingestion and aspiration) and others (e.g., iatrogenic damage and human error);

Immediately after inserting the denture/overdenture, e.g., traumatic ulcers;

During maintenance, e.g., root or implant complications, retention loss

Table 3. Classifications of denture and overdenture complications, considering descriptive criteria

4. Main complications of denture and overdenture

Some of the most common complications of the completely edentulous patient, treated by dentures or implant/root overdentures will be presented. Aspects related to their etiology, clinical features and management will be covered.

4.1. Alveolar ridge resorption

The residual ridge derives from the alveolar process after tooth loss. It registers the most significant changes and it supports the highest pressures during the worn of dentures or implant-retained overdentures. The ridge resorption is manifested as a continuous, cumulative and irreversible process, visible as the decrease of the quantity and quality of the bone [36].

Etiology. The ridge resorption is inherent after tooth loss and during denture wearing. It is a cronic plurifactorial condition as a joint result of physical, physiological and pathological factors.

The process of postextractive bone restructuring, after tooth loss, has variable rate and pattern, in relation to general physiological and pathological factors (age, menopause, systemic alterations), local factors (the edentulism and its cause, features of the jaws – volume, density). Also, the rate of bone resorption (the quantity of bone lost in a time period) varies in relation to the moment of tooth loss-it is maximum immediately after it in the first month, high in the first year after the tooth loss and decreases consequently. The pattern of bone resorption registers topographic differences – as for the maxilla and the mandible, for the anterior and posterior regions and in relation to anatomical features. The resorption is maximum at the top of the ridge and is lower at the base of the ridge, in the biostatistical areas (maxillary tuberosity, retromolar pad), at the ligaments' insertion site (frenum) and in the region of the hard palate. The ridge resorption occurs from the top to the basis, and is centripetal in the maxilla and centrifugal in the mandible. The pattern of ridge resorption varies according to the anatomical features and the size of the jaws, e.g., in class II skeletal patients, brachicephals, with mandibular micrognathism the resorption is more severe in the mandible, and in class III skeletal patients, dolicocephals, with mandibular macrognathism the resorption is more severe in the maxilla. Also, ridge resorption is more pronounced in women (probably linked to smaller jaws and lower bone density, related to postmenopause osteoporosis), in patients who lost their teeth due to periodontal disease and in those with high occlusal forces (natural teeth as antagonists, bruxism). Systemic conditions, particularly diabetes mellitus and other metabolic disorders, can accelerate the rhythm of ridge resorption.

The dentures accelerate the rate of ridge resorption, mainly through the pressure exercised by them on the support structures during oral functions. The severity of ridge resorption is connected to the parameters of functional and parafunctional forces of occlusion and to biomechanical aspects related to the prosthesis-the support and stability of the denture, the positioning of artificial teeth, type of occlusion, antagonists (teeth, implants, edentulous), and correctness of the registration of maxillomandibular relationship. The support surface for occlusal forces is reduced in edentulous patients, compared to the dentulous ones, and through progressive ridge resorption, both in high and width, consequently the support surface

decreases even more. The magnitude of occlusal forces are generally lower in the edentulous patients, but there are variations related to age, sex, parafunctions as bruxism, stress level, food consistency preferences, and also the correctness of prosthetic rehabilitation. Increased duration of occlusion contacts, as a risk factor for ridge resorption, is related to bruxism, ill-fitting dentures, unstable occlusion and increased vertical dimension of occlusion. Compared to maxillary edentulism, mandibular edentulism has greater risk of registering more severe ridge resorption, due to the decreased denture support surface and related higher magnitude of pressure beared. Also, denture wearing associates the risk of specific complications that favor the occurrence of an accelerated rate of ridge resorption, such as inflammatory lesions of the oral mucosa (e.g., denture stomatitis). Due to these factors, it is considered that ridge resorption is in tight relation with the period of wearing the dentures, but is also influenced by the quality of the treatment.

Clinical features. Ridge resorption is characterized by changes of the morphology of the alveolar ridges and of maxillomandibular relationship, with consequences on the prosthetic treatment and its outcome with time.

Ridge resorption implies a decrease in bone volume, as ridges' height (assessed as reduced, medium and severe resorption), ridge's width (assessed as wide, medium or thin "knife edge ridge") and ridge's surface layout (normal or abnormal morphology, with exostosis). The characteristics of the alveolar ridge influence treatment conduct and have impact on its outcome, e.g., severe ridge resorption (Figure 1) is more frequently associated with denture instability and reduced denture tolerance, difficulties in mounting the artificial teeth and esthetic deficiencies.

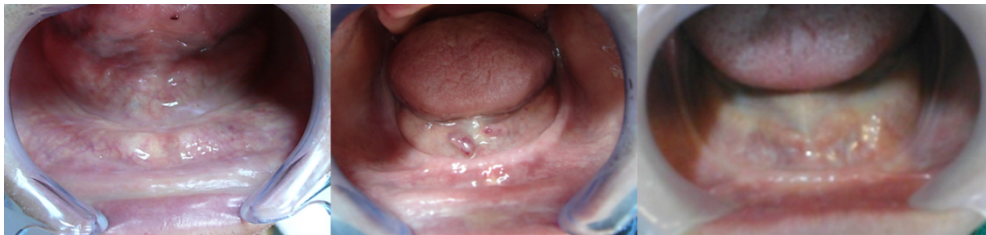

Figure 1. Severe ridge resorption, in long-term denture wearers

Associated to ridge resorption particular aspects of the maxillomandibular relationship can be noticed, as lack of parallelism between the ridges direction and anterior or/and posterior inverse ridge relationship (Figure 2). According to their skeletal jaw relations and in relation with the different patterns of jaws resorption, class III skeletal patients have the tendency to register an inverse ridge relationship, and class II skeletal patients an apparently normal relationship.

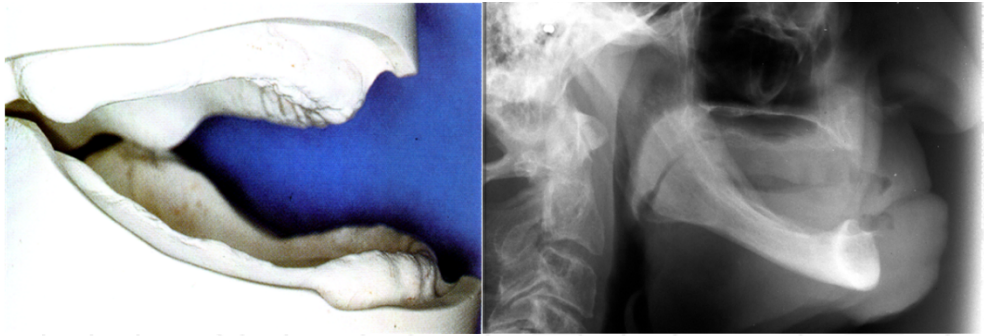


Figure 2. Inverse ridge relationship, related to skeletal class III and the pattern of bone resorption (centripetal in the maxilla and centrifugal in the mandible)

Through resorption and replacement of the bone with fibrous tissue, a floating ridge, usually named “flabby ridge” is noticed. This aspect is most commonly observed in the edentulous anterior maxilla, being related to the excessive pressure of the mandibular anterior teeth (Combination Syndrome). Flabby ridge can also be seen in other places, like maxillary tuberosity or retromolar pad, being linked to instability of the denture or excessive occlusal trauma.

Severe mandibular ridge resorption is accompanied by reduction of the area of the fixed mucosa, difficulties in acknowledgement of the extension of the denture base (due to the sublingual gland herniation through the mylohyoid muscle and modifications of the muscle and ligaments’ insertion sites, which can get close to the ridge crest) and pain as a result of dental pressure in the mental foramen area and nerve exposure.

Denture wearing associates inherent ridge resorption, manifested as the occurrence of denture instability. Consequently, clinical procedures as relining or rebasing are required for readjustment of the dentures, in order to correspond to patient’s need and to prevent worsening of the edentulous condition.

Management. The ridge resorption, due to its impact on the prosthetic treatment, is the first criteria for the classification of treatment difficulty level according to the Prosthodontic Diagnostic Index (PDI) for complete edentulism of ACP [16]. Thereby, a detailed analysis of the severity of ridge resorption and associated clinical signs is essential in the treatment planning. Useful data can be gained through clinical examination, analysis of the old dentures (when available, they are essential) and evaluation on panoramic and cephalometric radiographs. Computed tomography provides information that are most valuable when implant prosthetic restorations are used, as implant overdentures, especially in complex cases as those with severe ridge resorption or flabby ridge.

In edentulous patients, considering the irreversible and progressive character of bone resorption, preventive interventions should be taken towards reduction of resorption rate and its complications. In this respect, addressing the risk factors and correct management of the supporting tissue should be a priority. In order to limit the bone resorption it is recommended

to preserve the tooth roots, to use dental implants, to realize immediate prosthetic rehabilitation, especially in cases with tooth lost due to periodontal disease since this conduct favors a more reduced guided bone resorption. Correctness of dentures manufacturing is essential and it should rely on the principles of retention, stability and support, with proper maintenance and on time replacement. Implant overdentures can be used both as a preventive solution, in order to reduce the bone resorption, and as a curative solution, for solving the cases with severe ridge resorption where conventional dentures did not succeed or were not tolerated.

Severe ridge resorption associates decreased denture stability, which is associated with complications such as pain, lesions of the mucosa, reduced denture tolerance, that need to be addressed. The surgical preprosthetic interventions (bone augmentation, frenectomy, excision of hyperplastic lesions, as in figure 3) and non-surgical interventions (tissue conditioning, antifungal medication, improvement of the nutrition) are preparative treatments that aim achieving better conditions for prosthetic rehabilitation. Taking into account edentulous patient's profile (aged, with systemic co-morbidities), stress related to the fear of surgical interventions and healing parameters (as time needed or remaining scar tissues), the non-surgical or less invasive surgical interventions are preferred. Soft lining materials are indicated since they facilitate the uniformly distribution of the functional stress and can reposition the abused tissues.

The prosthetic treatment of the edentulous patient can be performed using conventional or implant restorations, fixed or removable, with or without preprosthetic interventions, according to the clinical case's particularities and patient's needs. Treatment requirements include accurate physiological impression of the oral structures, correct registration of maxillomandibular relationship and teeth mounting and selection of appropriate occlusal scheme, in order to ensure dentures' stability and esthetic and functional rehabilitation.

Accurate establishment of the peripheral extension of the denture base, considering also the pressures supported by the denture-bearing area, is extremely important, being directly relate to denture's retention, stability and tolerance. In this respect, the correct 2-phase impression technique (primary and custom tray impression) is essential. In edentulous patients with severe ridge resorption, additional adjunctive procedures may be required as tissue conditioning, supplementary functional impressions or usage of neutral zone impression technique. In displaceable or "flabby ridges", the selective pressure impression technique (e.g., using a custom tray with a window opening over the mobile tissue) is more recommended, being at equal importance to other aspects as stable posterior occlusion. Thin mandibular "knife edge ridges", that are accompanied by pain related to denture pressure, needs special treatment conduct, with usage of soft liners, a selective pressure impression technique, preprosthetic surgery (some disagree because ridge reduction implies loss of potential stabilizing zone) and dental implants.

Registration of maxillomandibular relationship is essential for the treatment success. It implies establishing the functional vertical dimension of occlusion, in accordance with minimum speaking space and the freeway space, and respecting the coincidence of maximal intercuspal position and centric relation. The most recommended occlusal schemes for removable prosthesis are the lingualized occlusion, for the bimaxillary complete edentulous patient, in

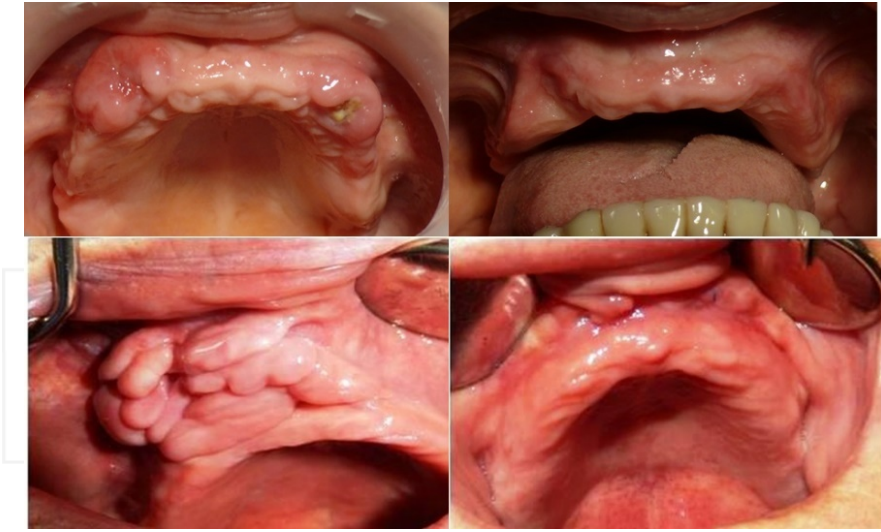


Figure 3. Preprosthetic surgical interventions for excision of hyperplastic lesions

skeletal class II patients or in severe mandibular ridge resorption or the linear occlusion, for mandibular overdentures, in patients with combination syndrome or skeletal class III pattern and severe maxillary ridge resorption.

Mandibular conventional dentures register frequently retention and stability deficiencies, mainly related to ridge resorption. These can be addressed through usage of implant prosthetic restorations, fixed or removable. There are multiple treatment options when considering usage of dental implants, as removable prosthesis (conventional or narrow dental implant overdenture, with different attachment systems as bars, ball, Locator) or fixed restorations (All an four, Fast & Fixed, conventional fixed implant restorations). Current perspective identifies 2 implant overdentures as the minimum standard for mandibular edentulism taking into account performance, patient satisfaction, cost and clinical time [37]. Selecting between them require acknowledgement of case futures and patient's need and preferences. For example, fixed restorations have better treatment outcome, but have limited usage due to aspects like cost and higher complexity of the interventions required (e.g., sometimes surgical procedures as bone augmentation or sinus lift cannot be avoided).

4.2. Traumatic ulcers

Traumatic ulcers are small, painful mucosal lesions that most commonly develop in the first days after insertion of a new denture [38].

Etiology. Traumatic ulcers are caused by dentures with overextended margins, unbalanced occlusion, small excess of material or related to some conditions of the denture bearing area, like exostosis or tori. Ill-fitting dentures can lead to soft tissue irritation or ulceration due to

excessive movement of denture. Additional to the mechanical trauma, ulcers can appear due to chemical or thermal insults.

Clinical features. The painful mucosal ulcerations are tender, have a yellowish floor and red margins, with no hardening or thickening of mouth tissues. The irregularly shaped lesions are usually localized in the buccal and lingual sulcus, are covered by a grey necrotic membrane and surrounded by an inflammatory halo. It looks as a hyperemic area, covered or not with fibrin deposits.

Management. Traumatic ulcers usually heal fast, in about a week, after removal of the cause. Usually, denture base and occlusion adjustments are made. Additionally, benzamine hydrochloride 0.15% mouthwash or spray, to provide symptomatic relief, and chlorhexidine gluconate 0.2% mouthwash for oral rinses and soaking the dentures overnight, to prevent and treat infection, can be recommended [39]. Traumatic ulcer decreased in frequency as the length of denture use increased and occurred more frequently during the first 5 years of denture use [40]. Traumatic ulcers must be differentiated from squamous carcinoma, bacterial, fungal and viral diseases, and other oral mucosal diseases, through their clinical aspect, evolution, lack of response to treatment [39]. Patients with an ulcer of over three weeks' duration should be referred for biopsy or other investigations to exclude malignancy or other serious conditions such as chronic infections.

4.3. Denture related hyperplasia

Denture related hyperplasia is an enlargement of the oral mucosa, appeared in relation to the denture base. There are two main types of denture related hyperplasia, namely denture-related fibrous hyperplasia (epulis fissuratum) and inflammatory papillary hyperplasia.

Etiology. Denture-related fibrous hyperplasia occurs as a reaction to low-grade continuous chronic trauma induced by denture flanges, which have thin sharp edges. Other risk factors are ill-fitting unstable dentures, increased vertical dimension of occlusion and parafunctional habits [41]. Inflammatory papillary hyperplasia occurs in relation to wearing the denture continuously, poor oral and denture hygiene, severe ridge resorption, unstable dentures, smoking, age-related changes and some systemic conditions [42]. Denture related hyperplasia is more common in elderly due to oral mucosa changes and their decreased immune response to infection.

Clinical features. Denture-related fibrous hyperplasia appears as a reactive mucosal enlargement, corresponding to the denture flange, which is more common in the maxillary buccal sulcus. The pedunculated, sessile or nodular formations, single or multiple can be red, hyperemic or light pink, usually being asymptomatic. Microbial colonization can occur, most common being *Candida* species.

In inflammatory papillary hyperplasia the hard palatal mucosa has an erythematous aspect, with a pebbly or papillary surface [42]. According to its severity, we can see forms with limited localization or that cover the entire hard palatal mucosa. The previously described two types of denture related hyperplasia can be observed in figure 4.

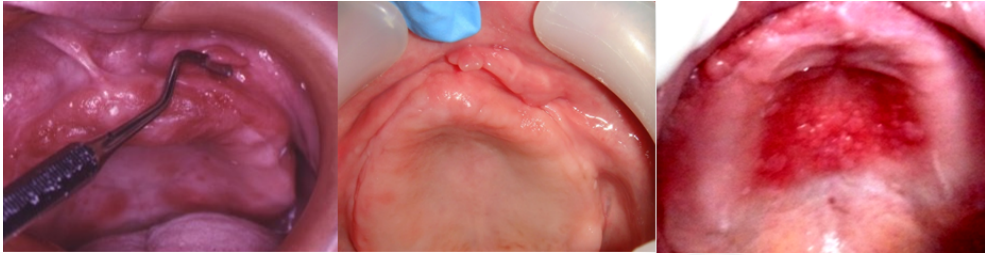


Figure 4. Denture related hyperplasia

Management. Denture-related fibrous hyperplasia usually diminishes considerably, almost entirely, after removal of the cause, correcting the denture flanges. Sometimes minor surgery is required.

The treatment of inflammatory papillary hyperplasia requires removal of the denture at night, improvement of the oral hygiene and denture hygiene. Antifungal therapy, surgical excision of the hyperplastic tissues and renewal of the denture can be recommended in some cases [42].

4.4. Denture stomatitis

Denture stomatitis is a chronic infectious inflammatory disease of the oral mucosa that is in direct contact with the base of the removable prosthesis, either conventional or implant-supported.

Etiology. It has a multifactorial etiology, it is primary related to denture wearing, but the dominant etiological factor is the microbial one—frequently fungal infection with *Candida albicans* and other sub-strains, but also bacteria such as *Staphylococcus* and *Streptococcus* species being identified [43]. Additionally, there are local and systemic and behavioral risk factors.

Acrylic dentures produce ecological changes that facilitate the accumulation of bacteria and yeasts and thus commensal organism may become pathogenic, denture stomatitis being considered an opportunistic infection [44]. A higher prevalence is noticed in cases with poor denture hygiene with denture plaque accumulation, continuous wear of the dentures (including at night) and in ill-fitting dentures. Other risk factors for denture stomatitis are related to the material characteristics, as their changes in time that favor plaque accumulation and microbial colonization (soft linings materials through their fast deterioration and difficulties of achieving proper hygiene; hard acrylic materials through their increased porosity that occurs in time) or as determining hypersensitivity reactions.

Host related risk factors for denture stomatitis include local factors (reduced salivary flow rate, low salivary pH, poor oral hygiene), general factors (physiological such as age, sex, nutritional status and associated medication) which act towards decreasing the resistance and defense mechanisms of the oral mucosa. The prevalence of denture stomatitis is higher among elderly denture users, women, smokers, alcohol consumers, vitamin A deficiency, diabetes and

immune deficiency [44-47]. Changes in the salivary flow rate may be signs of a systemic disease, as in Sjögren or Mikulicz syndromes, or associated to medication use, as diuretics, antihypertensive, antipsychotic, anxiolytic, analgesic, anti-inflammatory, antihistaminic drugs. Also, incorrect antibiotic therapy, without fungal protection and broad spectrum antibiotics are seen as risk factors.

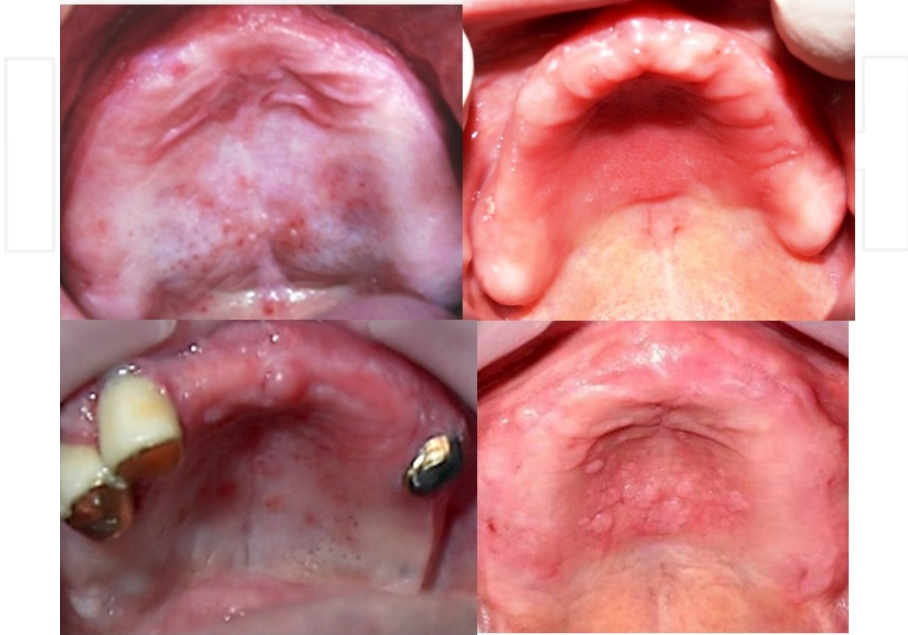

Figure 5. Denture stomatitis – clinical aspect

Clinical features. Denture stomatitis (Figure 5) is characterized by usually asymptomatic inflammatory lesions, with erythema and edema that are found in the denture bearing area, more frequently in the maxilla [44]. The reference classification for denture stomatitis is the one suggested by Newton in 1962, based exclusively on clinical criteria, including 3 types, namely type I (pin-point hyperemic lesions, as a localized simple inflammation), type II (diffuse erythema of the mucosa contacting the denture, as a generalized simple inflammation), and type III: (granular surface, as an inflammatory papillary hyperplasia) [43]. Denture stomatitis can be accompanied by other soft tissue lesions as angular cheilitis, median rhomboid glossitis or candidal leukoplakia.

Management. Considering the relatively high prevalence of denture stomatitis and its relapses, a preventive approach is recommended, by making the patient aware of this disease in order to motivate them to adopt the proper oral and denture hygiene methods, to remove the denture over nighttime and adopt a healthy life-style (quitting smoking, proper nutrition). Since most of the times the condition has no clinical signs, it is recommended to perform a

routine basis screening for denture stomatitis. Additional tests may be useful, such as microbiological exam and thermography –Figure 6 [14,43,48].

Treatment of denture stomatitis consists mainly in adopting strict methods for oral and denture hygiene, with removal of the denture overnight and soaking it in an antiseptic solution, such as chlorhexidine mouthwash. Considering the frequent *Candida* colonization, antifungal agents, usually as topical application, are recommended either when the yeasts have been isolated or in the absence of a favorable response to the previous interventions [14,44]. Additionally, denture deficiencies and other risk factors should be identified and addressed.

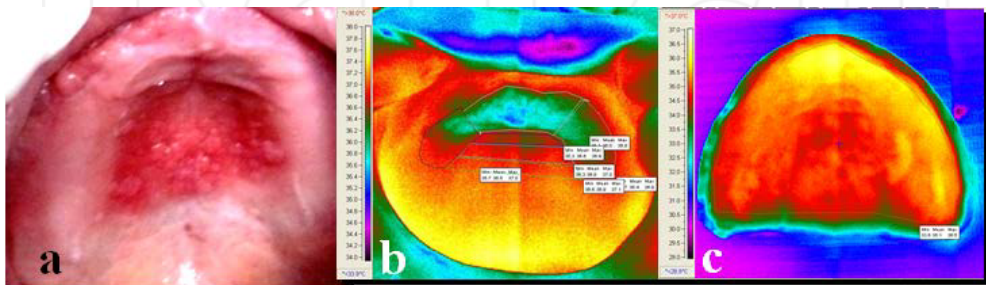


Figure 6. Denture stomatitis – clinical aspect (a); thermography of the oral mucosa (b); thermography of the maxillary denture (c)

4.5. Muscles changes

Edentulousness and dentures can lead to muscle changes, which are mainly an adaptation to the anatomical and functional changes. These can be encountered to the muscle that define the extension of the denture base and the neutral zone and play a role in the denture stability and retention (lips, cheeks and tongue), to masticatory muscles and to the muscles of facial expression.

Etiology. The muscle changes are linked to multiple interrelated factors. Aging associates loss of muscle tone and skin elasticity, decrease of the muscular mass and the force of contraction. The edentulism and the alveolar bone resorption induce major anatomical changes, with muscular consequences. Changing the support for the soft tissues causes the retraction of the lips and cheeks, and the muscular attachment changes in relation to the bone resorption. In severe forms of bone resorption, the muscles are inserted up to the ridge crest and the tongue, due to loss of the guiding offered by the teeth, changes gradually its shape, position and tonicity [49]. The patient's skeletal pattern associates muscular particularities also in the edentulous patient. In skeletal class II patients the tongue is hyperkinetic and has an elevated position that negatively influences the denture stability. In skeletal class III patients the tongue is less active and has a low position. An excessively large tongue, with a retracted position can be observed in edentulous patients that had not been treated for a long period of time. Patients with combination syndrome and skeletal class II with a retrognathic mandible show a tendency towards a protruded mandibular position. Certain systemic alterations, as degenerative and

autoimmune conditions, vascular accidents, paresis, burns, traumatism, nutritional status alterations as protein deficiencies, associate muscular changes.

Prosthetic treatment deficiencies favor abnormal muscular changes. Increased vertical dimension of occlusion and ill-fitting dentures cause muscle spasms, habitual and involuntary movements. Oversized anterior buccal flange of the maxillary denture associates the overextension of the upper lip, with possible anatomical and functional consequences. Association of posterior artificial tooth wear with over jet or lack of coincidence of maximal intercusp pal position and centric relation leads to an abnormal protruded mandibular position, which makes difficult the registration of maxillomandibular relationship (centric relation).

Clinical features. Generally, the clinical aspects are the result of complex muscular changes, such as regarding the tone, volume and attachment of the muscle, combined with neuromuscular coordination and control deficiencies.

The changes in muscle tonus can be seen as hypertonia or hypotonia. Muscle hypertonia (Figure 7) is more obvious in lower lip orbicularis oris muscle and in tongue muscles, and causes instability of the mandibular denture. It occurs in the edentulous patients in relation to prosthetic factors as ill-fitting dentures, to patient's individual characteristics as hypodivergent skeletal class II pattern, to parafunctions as bruxism or some systemic conditions. Muscle hypotonia is more frequent for upper lip orbicularis oris muscle and the buccinator muscle, and it occurs related to ageing, to deficient nutritional status and various systemic conditions. Less favorable condition for denture retention and stability, decrease of the efficiency of self-cleaning and reduced visibility of the anterior maxillary teeth in phonation or smiling are some of the effects of muscle hypotonia.

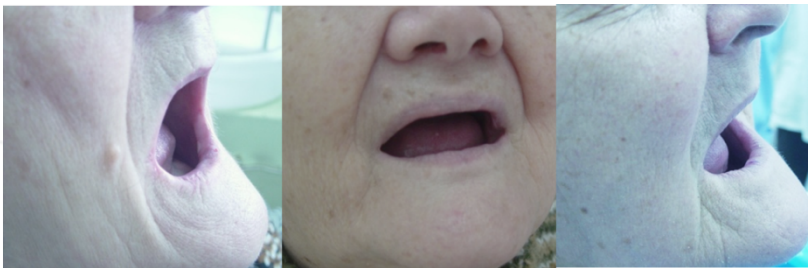

Figure 7. Lower lip orbicularis oris muscle hypertonia, that affects mandibular denture stability\

The changes in volume of the muscles is usually represented by muscular atrophy, which combined with muscular hypotonia, lead to the characteristic facial aspect of old people, with masseter muscle thickness and loose or sagging skin.

Buccinators, orbicularis oris and tongue muscles define the neutral zone, whose accurate limitation is difficult to identify in severe ridge resorption. Changes in the position of the

muscle insertions occur, such as high muscle insertions, even on the ridge top (genioglossus and mentalis muscle), with detached oral mucosa. Considering that position of muscle attachments has a major impact to denture base stability and retention, through changes of the denture bearing area, severe ridge resorption with consecutive muscles changes increase the treatment difficulty degree, especially in the mandible.

Muscle force decreasing leads to decrease in the capacity of performing a voluntary act (such as mastication). This occurs in relation to ageing, paresis, depression, denture instability or pain caused by the dentures. Alterations in jaw movements can occur in relation to deficiencies of the prosthetic restorations, as unstable occlusion, denture instability, increased vertical dimension of occlusion or in bruxism. Muscular spasms are encountered in particular situations as in the jaw-closing muscles, related to an increased vertical dimension of occlusion or for jaw-opening muscles related to a decreased vertical dimension of occlusion.

Neuromuscular coordination and control deficiencies, which occur in relation to age and systemic alterations, can increase treatment difficulty and negatively influence the accommodation with the prosthesis. For example, in Parkinson disease a lack of neuromuscular coordination occurs, which leads to difficulties in registration of maxillomandibular relationship and in the insertion and removal of the denture or the overdenture. Abnormal, involuntary, patterned or stereotyped and purposeless orofacial movements (oral dyskinesia) can occur linked to ill-fitting unstable dentures, oral discomfort, and lack of sensory contacts [2]. Facial nerve paresis includes affected unilateral facial musculature movement with asymmetry of facial expression and functional disorders, taste alterations and salivary changes, all having impact on the prosthetic treatment – difficulties in impression taking and in registration of maxillomandibular relationship, reduced masticatory efficiency with unilateral mastication, increased risk of unstable dentures, aesthetic alterations and denture intolerance.

Management. Considering the importance of the muscle factor for the oral functioning, an accurate evaluation should be performed. In some cases, besides the clinical evaluation, additional tests are recommended, such as electromyography or kinesiography, and sometimes special treatment conduct is required [50].

If muscle changes have been identified, these should be taken into account in planning and performing the prosthodontic treatment. In muscle hypertonia, aspects like positioning the artificial teeth in the neutral zone, correct placement of the occlusal plane and correct occlusal relations are essential. In muscle hypotonia, it is recommended to design the buccal flange of the denture with a convex shape and usage of medium viscosity impression materials, in order to have a correct registration of the extension of the denture base and to use the muscle contractions for denture stabilization. Impression taking technique varies according to case's particularities – in patients with protruded tongue at rest, wider movement are required during impression taking, comparing to a retracted tongue, in order to adequately register functional movements (Figure 8).

Extension of denture or overdenture base is limited by the muscle insertions, their encroachment causing, during muscle contraction, movement of the prosthesis. In severe ridge

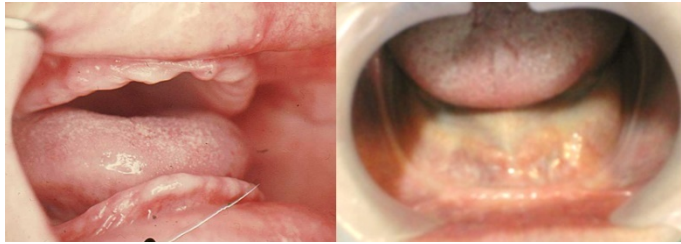


Figure 8. Tongue position at rest – anterior vs. posterior

resorption cases, as for those with muscle insertions on the ridge top, preprosthetic surgery for repositioning of muscle and mucosal attachments is indicated [51].

In neuromuscular coordination and control deficiencies, considering the severe functional alterations, conventional dentures usually don't respond to patient's need and implant overdenture should be chosen instead. Compared to conventional dentures, implant overdentures provides better functional parameters – exertion of higher masticatory forces promotes better nutrition through the ability to chew harder foods.

Last but not least, manufacturing of a new prosthesis requires an adjustment period for the establishment of the new memory patterns for the masticatory muscles, of about 6 to 8 weeks, aspect that should be mentioned to the patient [52].

4.6. Facial alterations, including esthetic complications

The complete edentulism contributes greatly to the facial aspect known as the aged appearance. Prosthetic treatment needs to adequately address this consequence of edentulism, considering the fact that patients' complaints are frequently related to aesthetic reasons.

Etiology. The facial appearance of the edentulous patient is the result of factors related to complete edentulism and prosthetic treatment, combined with others such as ageing, local and general particularities and medical conditions.

Edentulism associates significant anatomical and functional changes that impact the facial appearance. Lip and cheek support is severely altered by tooth loss and bone resorption. A tendency of increasing the facial concavity occurs in relation to the different pattern of bone resorption of the jaws (centripetal in the maxilla and centrifugal in the mandible). In association with the loss of the occlusal contacts, a counter-clockwise rotation of the mandible, with a decreasing height of the lower third of the face, and sometimes a tendency to a more advanced protruded mandibular position occurs. Facial alterations that are directly linked to edentulism can be considered worsening factors of the esthetic appearance, since there are also preexistent changes in relation to other factors.

As a consequence of aging, there are changes related to the evolution of bones and soft tissues (muscles, fat and skin), in addition to noticeable effects of gravity, with effect on facial esthetics [53]. Systemic health, medication use and behavior (e.g., alcohol and tobacco use) can

influence the facial appearance. For example, smoking causes changes particularly in the lower and middle third of the face, like hyperpigmentation and accentuated wrinkles-deeper nasolabial folds, upper lip wrinkles, lower lip vermilion wrinkles, lower lid hyperpigmentation [54]. Premature aged appearance occurs in some diseases like Cutis laxa or glomerulonephritis [55,56].

The prosthetic treatment of the edentulous patient addresses positively some of the previous mentioned facial alteration, but can also contribute to an aged appearance through its deficiencies, as in cases with a decreased vertical dimension of occlusion, a reverse smile line or darker, yellow artificial teeth.

Clinical features. Facial appearance of the edentulous patient registers changes compared to the dentate period, which are mostly found in the lower third of the face (Figure 9).

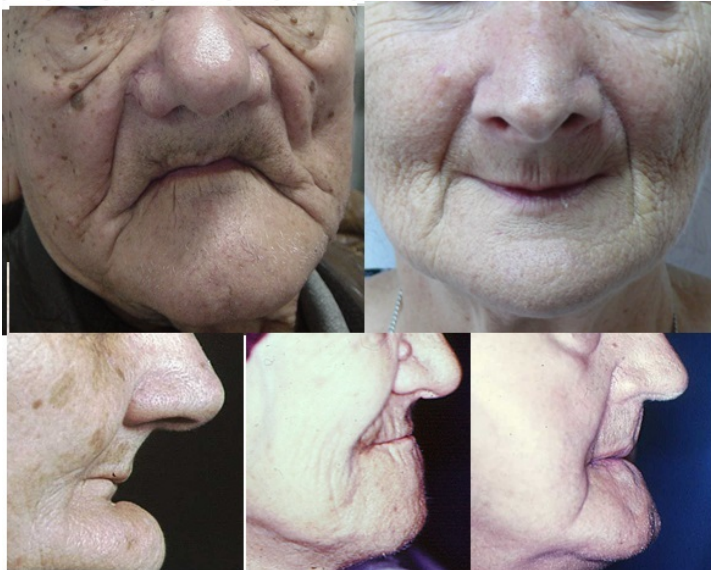

Figure 9. Facial appearance of edentulous patient, with severe bone resorption, without dentures

In edentulous patient, shape and vertical proportions of the face are modified compared to the dentate period. Frequently, edentulous patients have a short face morphotype, appeared in relation to the decrease in the facial lower and total height and the counter-clockwise rotation of the mandible.

Profile changes occur as decreasing its convexity compared to the dentate period. This aspect is due to the different pattern of bone resorption of the jaws and sometimes an advanced protruded mandibular position in the absence of stable occlusion. These changes are more obvious in the skeletal class III patients and are termed as pseudo-class III relation or the old

man's prognathism. Profile changes include also modification of nasolabial angle related to nose tip lowering and loss of upper lip support.

Lips register great changes, as reduction of vermilion height and their volume, color modifications, retraction due to support loss, elongation (upper lip) and shortening (lower lip), straight or reversed lip line and low smile line, and reduced lips dynamics that contribute to a decreased teeth exposure during speaking and smiling, which associated a reduction of emotional display, as happiness or sadness [57].

Facial changes related to ageing mark the facial appearance. Lips and cheeks become less prominent and there can be noticed marked folds and wrinkles, loose or sagging skin, changes in the skin texture and hyperpigmentation. These are mainly connected to muscle changes, as hypotonia, and skin changes, as loss of skin elastic recoil.

The prosthetic treatment has a positive impact on the facial esthetics (Figure 10). Generally, it provides a support for the soft tissue, tries to compensate the tooth loss and bone resorption (through the artificial teeth and anterior buccal maxillary flange), ensures a functional vertical dimension of occlusion and give a natural look through exposure of the teeth during smiling or speaking. Some faulty prosthesis or some changes that occurs in time can have a negative impact on facial esthetic. Unpleasant facial appearance can be linked to errors in anterior artificial tooth mounting (too forward, too backward), shade selection (chosen incorrectly, too light, not matching the patient's age), to changes of the artificial teeth over time (through teeth wear the smile line can become reversed, or through aging of the material discolorations can appear). A decreased vertical dimension of occlusion leads to an aged appearance, with deeper perioral folds, and an increased vertical dimension of occlusion associate an unnatural, tensioned look. An overextended buccal flange, encountered more often in the maxillary dentures, leads to an over-supported lip with a tensioned unnatural look. Unstable dentures negatively influence facial appearance through movement while speaking and the facial changes related to protruded mandibular position that many times is associated.

Management. Facial esthetic evaluation must consider changes' severity and causes, in order to properly address them and respond to patients' need and expectations. In order to make an accurate analysis, regular clinical examination (from frontal and lateral view, with and without dentures, in rest and in maximal intercuspal position, during speech and smiling) can be supplemented by radiological examination (cephalometric radiographs) and records from the dentate period, as photos, dental casts, radiographs. The prosthetic rehabilitation of the completely edentulous patient must consider, from an aesthetic point of view, beside the general esthetic principles, also patient's features that are relatively obvious in the dentate period and rather difficult to assess in the edentulous one. The previous should be related to other patient's characteristics (e.g., age, sex, functional particularities, health status) and to prosthodontic biomechanical requirements in order to obtain a good treatment outcome.

4.7. Denture and overdenture biomechanical and technical complications

Removable dental prosthesis are described as having a series of complications in relation to the correctness and accuracy of their planning and execution (extension of the denture base,

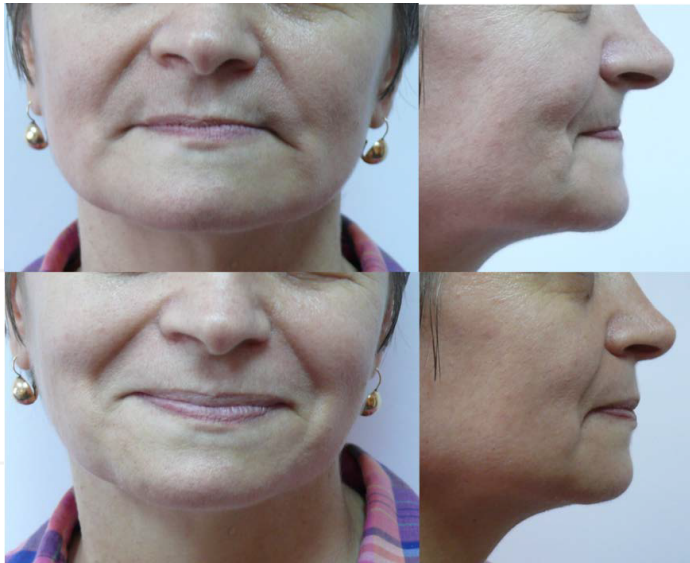

Figure 10. Facial appearance of a recently edentulous patient with and without the dentures

registration of maxillomandibular relationship, mounting of the artificial teeth, occlusal scheme), the technical and biomechanical features of the devices, the properties of the materials used, in conjunction with their evolution in time.

Considering the aims of medical treatments, not properly achieving the prosthodontic treatment goals (denture retention and stability, patient's satisfaction that is linked to aspects like the degree of esthetic and functional rehabilitations and absence of pain) may be considered treatment complications. Removable prosthesis instability can be caused by incorrect denture execution (e.g., overextended flanges, incorrect mounting of the artificial teeth, unstable occlusion), or can occur in time, as a consequence of bone resorption. This issue must be promptly addressed since it can lead to serious complications, such as the fracture of the prosthesis, abutment loss (teeth, implants) and intolerance of the prosthesis. In order to ensure good removable prosthesis stability, the primary aspect that should be considered is its correct execution, mainly regarding the extension of the denture base and artificial teeth mounting. Secondary, usage of denture adhesives, relinings and placement of dental implants should be considered.

The fracture of the removable prosthesis (Figure 11) is a relatively common complication, having numerous risk factors, such as poor denture design, denture instability, teeth or fixed restorations in the opposite jaw, increased mucosal resiliency, previous fractures, accidents (dropping the denture, associated to reduced dexterity), material properties and changes in time, flexural fatigue or other impact factors. Its management includes identifying the cause and the treatment can range from conventionally repairing procedures to reinforcement of the

denture base with metal or non-metal products (as glass and polyethylene fibers or net), to changing the previous denture or even the treatment option [58].

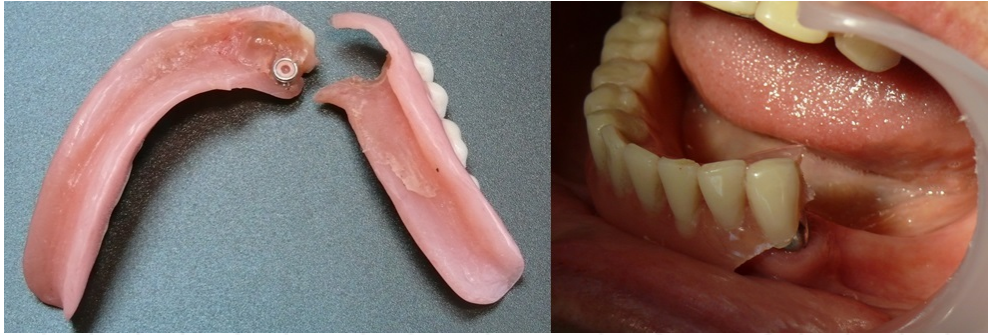

Figure 11. Overdenture fracture at the attachment site

The complications associated to the properties of the material used, mainly polymethylmethacrylate (PMMA), are linked to changes that appears during their evolution in time, as discolorations, artificial teeth wear, increased porosity and decrease flexural strength. Considering their functional and aesthetic impact, denture and overdenture treatment should be renewed at approximately every 5 years.

Additionally, signs of combination syndrome can appear when mandibular overdentures (supported or retained by roots or dental implants) are opposed by an edentulous maxilla. In this situation the masticatory field moves anteriorly, favoring the instability of the maxillary denture and the increased bone resorption rate in the anterior maxilla. This iatrogenic effect can be managed by using implants also in the maxilla, aiming to address or prevent this functional consequence and the destructive process of the oral structures [59].

4.8. Teeth complications, with root overdentures

The root overdentures can have teeth related complications, mainly due to primary or recurrent caries, periradicular lesions developed by vital teeth, endodontically lesions developed by endodontically treated teeth due to loss of the restoration sealing the root canal, periodontitis or root fracture [60]. Their management is dependent of the problem type, in most severe forms tooth loss and recurrent failure of prosthodontic treatment occurring. It is important to preserve the roots as a prevention factor for bone resorption and due their positive impact on the oral functioning [61]. Patients' awareness, instruction and motivation regarding maintaining a proper oral hygiene are essential considering that is the main factor for periodontal disease and caries control. When caries occur, it is important to identify them quickly in order to have high a high success rate for the treatment. Topical fluoridation or coverage with metallic caps can be performed preventively for patients with a high caries risk. For the periodontal disease it is recommended to use Chlorhexidine 0.12% mouthwash twice daily. Also, the removal of the denture overnight and maintenance of proper denture hygiene are

recommended. If tooth mobility appears, it can be addressed by reducing the tooth height, which leads to an increase in the crown to root ratio. The risk of root fracture is higher in endodontically treated teeth and when the magnitude of occlusal forces is higher, as in denture instability, bruxism, increased vertical dimension of occlusion, when teeth or fixed prosthesis in the opposite jaw. Preventively, thimble crowns can be used.

4.9. Implants complications, with implant overdentures

For the implant overdenture, the implants complications can be related to the treatment planning (insufficient implant number), implant positioning (surgical complications can appear, such as nerve or blood vessel injuries, penetration of the maxillary sinus or the nasal cavity, hemorrhages or pain) and their evolution (post-insertion infections, compromised survival or implant loss associated deficient osseointegration, peri-implantitis, implant fracture) [62].

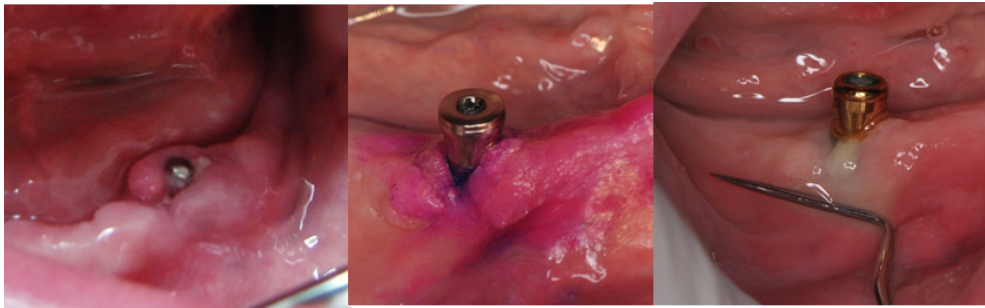


Figure 12. Peri-implant soft tissue lesions-clinical aspect

Therefore, treatment planning considering the fundamental principles of removable implant prosthodontics, overdenture design and execution, maintenance procedures, regular check-ups are all essential for prevention or adequate management of treatment complications. Implant problems are differently addressed according to their type and severity, ranging from simple denture adjustments and enhancing the oral hygiene, to denture relinings or replacement of the denture, to inserting new implants. An important aspect to consider is that implant failure is more common in the maxilla than the mandible, consequently being favorable to place more implants in the upper jaw.

Mandibular implant overdenture is generally considered as being a good predictable treatment, its major implant complication, namely implant loss usually occurring in the first year of function [63,64]. Therefore, regular check-ups are absolutely necessary in this period, for an early intervention that ensures the best prognosis. It is recommended that the dentists performs periodically an accurate evaluation of the implants and surrounding soft tissue regarding the peri-implant marginal bone loss, implant mobility, peri-implant soft tissue, peri-implant bleeding, implant sensitivity during function, result of implant percussion test, plaque

accumulation. The overdentures must be verified regarding the overdenture base that is in direct contact with the implant, as risk factor for peri-implant soft tissue complications, regarding the occlusion and maxillomandibular relationship whose faults may be related to exerting increased pressure on implants, as risk factor for implant failure, as its stability and hygiene. Other aspects, like the prosthetic treatment on the opposite jaw (an unstable denture as antagonist can produce excessive forces on the implants) and parafunctions should be checked.

4.10. Attachment system complication, with overdentures

Attachment system complications can occur as a consequence of an incorrect treatment planning, improper treatment conduct (e.g., errors during placement of the retentive housing in the overdenture base) or related to their changes that occur in time, during functioning (e.g., loosening or damage). These vary according to the type of attachment system, e.g., bar, ball, Locator. Most frequent attachment system complications, with overdentures, are: decreased prosthesis retention due to deactivation, detachment, damage or loss of the retentive housing; abutment screw loosening or fracture; fracture of the attachment system components (e.g., bar or clip fracture); soft tissue lesions as hyperplasia under the bar or peri-implant mucositis.

The management of attachment system complications varies according to the attachment system used and the complication type. Technical complications are more common for bar than ball attachments, and both of them are more common compared to locator system [65,66]. Usually low severity complications occurs, such as loss of rubber ring and matrix deactivation, which need to be promptly addressed since they cause overdenture instability with possible negative impact on the dental implants. A more severe complication is bar fracture, that requires increased clinical time and expenses to be resolved, considering that usually the overdenture must be replaced. In elderly edentulous patients simpler prosthetic reconstructions, with complications that require decreased time and money are preferred. Thus, if the option of implant overdenture has been selected, the ball attachment system can be more appropriate than the bar attachment system, due to the more simple maintenance procedures and easier replacement of the implant if necessary.

4.11. Patient satisfaction and quality of life

The conventional dentures are the most common treatment option for the edentulous patients, and usually register good results in terms of patient's satisfaction. Dissatisfaction reasons most claimed by patients are related to denture instability, improper mastication, esthetic deficiency and phonation problems [67]. Denture intolerance is usually connected to subjective factors (the patient's needs and expectations, psychological type, misconceptions) or objective factors (denture instability, pain, functional deficiencies).

The root or implant overdenture have improved retention that contributes to physical and psychological comfort. According to the current evidence, mandibular implant overdentures provide a higher satisfaction and oral health related quality of life compared to conventional denture, but there is uncertainty about the true magnitude of difference between the two [68].

5. Conclusions

Dentures and overdentures, the most frequently used treatment options for the complete edentulism, have complications that are related to patient and prostheses features. Patient's general and local conditions and behavior must be acknowledged as their manifestations, interactions and impact on the prosthetic treatment. Removable implant prosthodontics principles should be well-known and respected during prosthesis execution. The previous, additional to regular check-ups, represent the basis of the prevention removable prosthesis complications.

Denture and overdenture complications are partially similar, differences being related to design particularities, biomechanical aspects and execution procedures. Addressing them depends on their nature and severity, requiring a specific medical conduct. Often simple clinical interventions are needed, but sometimes complex procedures with increased clinical, biological and financial costs must be considered in order to achieve a medical result that corresponds to the current medical standards and patient needs and expectations.

Author details

Elena Preoteasa^{1*}, Cristina Teodora Preoteasa², Laura Iosif¹, Catalina Murariu Magureanu¹ and Marina Imre¹

*Address all correspondence to: dr_elena_preoteasa@yahoo.com

1 Department of Prosthodontics, Faculty of Dental Medicine, Carol Davila University of Medicine and Pharmacy, Bucharest, Romania

2 Department of Oral Diagnosis, Ergonomics, Scientific Research Methodology, Faculty of Dental Medicine, Carol Davila University of Medicine and Pharmacy, Bucharest, Romania

References

- [1] Carlsson GE, Omar R. The Future of Complete Dentures in Oral Rehabilitation. A Critical Review. *Journal of Oral Rehabilitation* 2010;37(2): 143-156.
- [2] Emami E, de Souza RF, Kabawat M, Feine JS. The Impact of Edentulism on Oral and General Health. *International Journal of Dentistry* 2013; 2013. DOI: 10.1155/2013/498305 (accessed 1 September 2014).
- [3] Cunha-Cruz J, Hujoel PP, Nadanovsky P. Secular Trends in Socio-Economic Disparities in Edentulism: USA, 1972–2001. *Journal of Dental Research* 2007;86(2): 131–13.

- [4] Beltrán-Aguilar ED, Barker LK, Canto MT, Dye BA, Gooch BF, Griffin SO, Hyman J, Jaramillo F, Kingman A, Nowjack-Raymer R, Selwitz RH, Wu T. Surveillance for Dental Caries, Dental Sealants, Tooth Retention, Edentulism, and Enamel Fluorosis--United States, 1988-1994 and 1999-2002. *Morbidity and Mortality Weekly Report. Surveillance Summaries* 2005;54(3): 1-43.
- [5] Vos T, Flaxman AD, Naghavi M, Lozano R, Michaud C, Ezzati M, Shibuya K, et al. Years Lived with Disability (YLDs) for 1160 Sequelae of 289 Diseases and Injuries 1990-2010: A Systematic Analysis for the Global Burden of Disease Study 2010. *Lancet* 2012; 380(9859): 2163-96. DOI: 10.1016/S0140-6736(12)61729-2 (accessed 1 September 2014).
- [6] Felton DA. Edentulism and Comorbid Factors. *Journal of Prosthodontics* 2009;18(2): 88-96.
- [7] World Health Organization. *International Classification of Functioning, Disability and Health*. Geneva, Switzerland. World Health Organization; 2001.
- [8] O' Reilly E. Treatment Options for Our Edentulous Patients. <http://www.burlington-dentalclinic.ie/wp-content/uploads/2012/10/Dr-Eddie-OReilly-Edentulous-Patients.pdf> (accessed 1 September 2014).
- [9] Suarez-Sanchez OR. Evaluating Epidemiological Properties of the American College of Prosthodontists (ACP) Prosthodontic Diagnostic Index for Complete Edentulism (PDI-CE)(PDI-Study). Harvard School of Dental Medicine; 2007.
- [10] Papadaki E, Anastassiadou V. Elderly Complete Denture Wearers: A Social Approach to Tooth Loss. *Gerodontology* 2012; 29(2):e721-7. DOI: 10.1111/j.1741-2358.2011.00550.x. (accessed 14 September 2014).
- [11] Dye BA, Tan S, Smith V, Lewis BG, Barker LK, Thornton-Evans G, Eke PI, Beltrán-Aguilar ED, Horowitz AM, Li CH. Trends in Oral Health Status: United States, 1988-1994 and 1999-2004. *Vital Health Stat* 11. 2007;Apr. (248): 1-92.
- [12] Douglass CW, Shih A, Ostry L. Will There Be a Need for Complete Dentures in the United States in 2020? *Journal of Prosthetic Dentistry* 2002;87(1): 5-8.
- [13] Osterberg T, Carlsson GE. Dental State, Prosthodontic Treatment and Chewing Ability-a Study of Five cohorts of 70-Year-Old Subjects. *Journal of Oral Rehabilitation* 2007;34(8): 553-9.
- [14] Felton D, Cooper L, Duqum I, Minsley G, Guckes A, Haug S, Meredith P et al. Evidence-Based Guidelines for the Care and Maintenance of Complete Dentures: a Publication of the American College of Prosthodontists. *Journal of the American Dental Association* 2011;142(Suppl 1): 1S-20S.
- [15] Thompson GW, Kreisel PS. The Impact of the Demographics of Aging and the Edentulous Condition on Dental Care Services. *Journal of Prosthetic Dentistry* 1998;79(1): 56-9.

- [16] American College of Prosthodontists (ACP). The Prosthodontic Diagnostic Index for Complete Edentulism (PDI-CE). http://www-w.gotoapro.org/assets/1/7/Complete_Edentulism_Checklist.pdf (accessed 1 September 2014).
- [17] Al-Zubeidi MI, Payne AG. Mandibular Overdentures: A Review of Treatment Philosophy and Prosthodontic Maintenance. *New Zealand Dental Journal* 2007;103(4): 88-97.
- [18] Kiyak HA, Reichmuth M. Barriers to and Enablers of Older Adults' Use of Dental Services. *Journal of Dental Education* 2005; 69(9): 975-6.
- [19] [19]. Montini T, Tseng TY, Patel H, Shelley D. Barriers to Dental Services for Older Adults. *American Journal of Health Behaviour* 2014;38(5): 781-8.
- [20] Wismeijer D, Ten BC, Schulten EA. Notes Concerning an Overdenture on 2 Implants as the Standard for Treating an Edentulous Mandible. *Nederlands Tijdschrift Voor Tandheelkunde* 2011;118(12): 633-9.
- [21] Sutton AF, Glenny AM, McCord JF. Interventions for Replacing Missing Teeth: Denture Chewing Surface Designs in Edentulous People. *The Cochrane Database of Systematic Reviews* 2005;25(1). DOI: 10.1002/14651858.CD004941.pub2 (accessed 1 September 2014).
- [22] Preoteasa CT, Nabil Sultan A, Popa L, Ionescu E, Iosif, L, Ghica, MV, Preoteasa E. Wettability of Some Dental Materials. *Optoelectronics and Advanced Materials – Rapid Communications* 2011; 5(8): 874-8.
- [23] Preoteasa E, Imre M, Preoteasa CT. A 3-Year Follow-up Study of Overdentures Retained by Mini-Dental Implants. *The International Journal of Oral & Maxillofacial Implants* 2014; 29(5). 1034-41.
- [24] Carlsson GE. Clinical Morbidity and Sequelae of Treatment with Complete Dentures. *Journal of Prosthetic Dentistry* 1998;79(1): 17-23.
- [25] Petersen PE, Kandelman D, Arpin S, Ogawa H. Global Oral Health of Older People- Call for Public Health Action. *Community Dental Health* 2010;27(4 Suppl 2): 257-67.
- [26] Hummel SK, Wilson MA, Marker VA, Nunn ME. Quality of Removable Partial Dentures Worn by the Adult U.S. Population. *Journal of Prosthetic Dentistry* 2002;88(1): 37-43.
- [27] Pietrokovski J, Harfin J, Levy F. The Influence of Age and Denture Wear on the Size of Edentulous Structures. *Gerodontology* 2003;20(2): 100-5.
- [28] Fitzpatrick AL, Powe NR, Cooper LS, Ives DG, Robbins JA. Barriers to Health Care Access Among the Elderly and Who Perceives Them. *American Journal of Public Health* 2004; 94(10):1788-94.

- [29] Dolan TA, Atchison KA. Implications of Access, Utilization and Need for Oral Health Care by the Non-Institutionalized and Institutionalized Elderly on the Dental Delivery System. *Journal of Dental Education* 1993;57(12): 876-87.
- [30] Dolan TA, Atchison K, Huynh TN. Access to Dental Care Among Older Adults in the United States. *Journal of dental Education* 2005; 69(9): 961-74.
- [31] Health and Behavior. The Interplay of Biological, Behavioral, and Societal Influences. Institute of Medicine (US) Committee on Health and Behavior: Research, Practice, and Policy. Washington DC. National Academies Press (US); 2001. <http://www.ncbi.nlm.nih.gov/books/NBK43743/> (accessed 1 September 2014).
- [32] Barratt A. Evidence Based Medicine and Shared Decision Making: The Challenge of Getting Both Evidence and Preferences Into Health Care. *Patient Education and Counseling* 2008;73(3): 407-12.
- [33] Graber T, Eliades T, Athanasiou AE. Risk Management in Orthodontics: Experts' Guide to Malpractice. Chicago: Quintessence Publishing Co; 2004.
- [34] Berglundh T, Persson L, Klinge B. A Systematic Review of the Incidence of Biological and Technical Complications in Implant Dentistry Reported in Prospective Longitudinal Studies of at least 5 Years. *Journal of Clinical Periodontology* 2002;29 (Suppl 3): 197-212.
- [35] Misch K, Wang H. Implant Surgery Complications: Etiology and Treatment. *Implant Dentistry* 2008; 17(2): 159-68.
- [36] Atwood DA. Reduction of Residual Ridges: A Major Disease Entity. *Journal of Prosthetic Dentistry* 1971;26(3): 266-79.
- [37] Thomason JM, Kelly SA, Bendkowski A, Ellis JS. Two implant retained overdentures--a review of the literature supporting the McGill and York consensus statements. *Journal of Dentistry* 2012;40(1):22-34.
- [38] Budtz-Jørgensen E. Oral Mucosal Lesions Associated with the Wearing of Removable Dentures. *Journal of Oral Pathology* 1981; 10(2): 65-80.
- [39] Dunlap CL, Barker CF. A Guide to Common Oral Lesions. http://dentistry.umkc.edu/Practicing_Communities/asset/OralLesions (accessed 23 July 2014).
- [40] Coelho CM, Sousa YT, Daré AM. Denture-Related Oral Mucosal Lesions in a Brazilian School of Dentistry. *Journal of Oral Rehabilitation* 2004;31(2): 135-9.
- [41] Sudarshan R, Sree Vijayabala G, Prem Kumar KS. Inflammatory Hyperplasia of the Oral Cavity. *Archives Medical Review Journal*. 2012; 21(4): 299-307.
- [42] Canger EM, Celenk P, Kayipmaz S. Denture-Related Hyperplasia: A Clinical Study of a Turkish Population Group. *Brazilian Dental Journal* 2009; 20(3): 243-8.

- [43] European Association of Oral Medicine (EAOM). Denture Related Stomatitis. http://www.eaom.eu/empty_24.html (accessed 1 September 2014).
- [44] Gendreau L, Loewy ZG. Epidemiology and Etiology of Denture Stomatitis. *Journal of Prosthodontics* 2011; 20(4): 251-60.
- [45] Petersen PE, Yamamoto T. Improving the Oral Health of Older People: The Approach of the WHO Global Oral Health Programme. *Community Dentistry and Oral Epidemiology* 2005;33(2): 81-92.
- [46] Shulman JD, Rivera-Hidalgo F, Beach MM. Risk Factors Associated with Denture Stomatitis in the United States. *Journal of Oral Pathology and Medicine* 2005 34(6): 340-6.
- [47] Lylajam S, Prasanath V. Denture Stomatitis-Etiological Factors and Management. *Journal of Clinical Dentistry* 2011;2(1): 9-11.
- [48] Preoteasa E, Iosif L, Amza O, Preoteasa CT, Dumitrascu C. Thermography, an Imagistic Method in Investigation of the Oral Mucosa Status in Complete Denture Wearers. *Journal of Optoelectronics and Advanced Materials* 2010;12(11): 2333-4.
- [49] Pietrokovski J, Kaffe I, Arensburg B. Retromolar Ridge in Edentulous Patients: Clinical Considerations. *Journal of Prosthodontics* 2007;16(6): 502-6.
- [50] Melescanu Imre M, Preoteasa E, Tancu A, Preoteasa CT. Imaging Technique for the Complete Edentulous Patient Treated Conventionally or With Mini Implant Overdenture. *Journal of Medicine and Life* 2013;6(1): 86-92.
- [51] Cawood JI, Stoelinga PJ. International Research Group on Reconstructive Preprosthodontic Surgery. Consensus Report. *International Journal of Oral Maxillofacial Surgery* 2000;29(3): 159-62.
- [52] Goiato MC, Filho HG, Dos Santos DM, Barão VA, Júnior AC. Insertion and Follow-Up of Complete Dentures: A Literature Review. *Gerodontology* 2011;28(3): 197-204.
- [53] Nkengne A, Bertin C. Aging and Facial Changes--Documenting Clinical Signs, Part 1: Clinical Changes of the Aging Face. *Skinmed* 2012;10(5): 284-289.
- [54] Okada HC, Alleyne B, Varghai K, Kinder K, Guyuron B. Facial Changes Caused by Smoking: A Comparison Between Smoking and Nonsmoking Identical Twins. *Plastic and Reconstructive Surgery* 2013;132(5): 1085-92.
- [55] Mataix J, Bañuls J, Lucas A, Pastor N, Betlloch I. Prematurely Aged Appearance. *Clinical and Experimental Dermatology* 2006;31(6): 833-4.
- [56] Joss N, Boulton-Jones JM, More I. Premature Ageing and Glomerulonephritis. *Nephrology Dialysis Transplantation* 2001;16(3): 615-8.

- [57] Tupac R, et al. Parameters of Care for the Speciality of Prosthodontics. *Jornal of prosthodontics. Implant, Esthetic, and Reconstructive Dentistry. Official Journal of The American College of Prosthodontists* 2005;14(4)Suppl: 1-103.
- [58] Preoteasa E, Murariu CM, Ionescu E, Preoteasa CT. Acrylic Resin Reinforcement With Metallic and Nonmetallic Inserts. *Revista Medico-Chirurgicala a Societatii de Medici si Naturalisti din Iasi* 2007; 111(2): 487-93.
- [59] Kreisler M, Behneke N, Behneke A, d'Hoedt B. Residual Ridge Resorption in the Edentulous Maxila in Patients With Implant-Supported Mandibular Overdentures: An 8-Years Retrospective Study. *International Journal of Prosthodontics* 2003;16(3): 265-300.
- [60] Ettinger RL, Qian F. Postprocedural Problems in An Overdenture Population: A Longitudinal Study. *Journal of Endodontics* 2004; 30(5): 310-4.
- [61] Crum RJ, Rooney GE Jr. Alveolar Bone loss in Overdentures: A 5-Years Study. *Journal of Prosthetic Dentistry* 1978; 40(6): 610-3.
- [62] Preoteasa E, Meleşcanu-Imre M, Preoteasa CT, Marin M, Lerner H. Aspects of Oral Morphology as decision factors in mini-implant supported overdenture. *Romanian Journal of Morphoogy and Embryology* 2010;51(2): 309-14.
- [63] Burns DR. Mandibular Implant Overdenture Treatment: Consensus and Controversy. *Journal of Prosthodontics* 2000;9(1): 37-46.
- [64] Eckert SE, Choi YG, Sánchez AR, Koka S. Comparison of Dental Implant Systems: Quality of Clinical Evidence and Prediction of 5-Year Survival. *The International Journal of Oral & Maxillofacial Implants* 2005; 20(3):406-15.
- [65] Gotfredsen K1, Holm B. Implant-Supported Mandibular Overdentures Retained With Ball Or Bar Attachments: A Randomized Prospective 5-Year Study. *International Journal of Prosthodontics* 2000;13(2): 125-30.
- [66] Cakarar S, Can T, Yaltirik M, Keskin C. Complications Associated with the Ball, Bar And Locator Attachments for Implant-Supported Overdentures. *Medicina Oral, Patologia Oral Y Cirurgia Bucal* 2011;16(7): e953-9.
- [67] Preoteasa E, Marin M, Imre M, Lerner H, Preoteasa CT. Patients' Satisfaction With Conventional Dentures and Mini Implant Anchored Overdentures. *Revista Medico-Chirurgicala a Societatii de Medici si Naturisti din Iasi* 2012;116(1): 310-16.
- [68] Emami E, Heydecke G, Rompré PH, de Grandmont P, Feine JS. Impact of Implant Support for Mandibular Dentures on Satisfaction, Oral and General Health-Related Quality of Life: A Meta-Analysis of Randomized-Controlled Trials. *Clinical Oral Implants Research* 2009; 20(6): 533-44.

