
Interceptive Orthodontics – Current Evidence

Maen H. Zreagat

Additional information is available at the end of the chapter

<http://dx.doi.org/10.5772/59256>

1. Introduction

From evidence found in human skulls, crooked teeth have been around since the time of Neanderthal man (about 50,000 BC), but it was not until about 3000 years ago that we had the first written record of attempts to correct crowded or protruding teeth. Long before braces, long before the word orthodontics” was coined, it was known that teeth moved in response to pressure. Primitive (and surprisingly well-designed) orthodontic appliances have been found with Greek and Etruscan artifacts. Archaeologists have discovered Egyptian mummies with crude metal bands wrapped around individual teeth. It is speculated that catgut was used to close the gaps [1]. The earliest description of irregularities of the teeth was given about 400 BC by Hippocrates (460-377 BC). The first treatment of an irregular tooth was recorded by Celsus (25 BC-50 AD), a Roman writer, who said, “If a second tooth should happen to grow in children before the first has fallen out, that which ought to be shed is to be drawn out and the new one daily pushed toward its place by means of the finger until it arrives at its just proportion.” A clear mechanical treatment was advocated by Pliny the Elder (23-79 AD), who suggested filing elongated teeth to bring them into proper alignment. This method remained in practice until the 1800s [2].

Dentistry entered a period of marked decline during middle ages (5th to 15th centuries), as did all sciences. After the 16th century, considerable progress was made. Matthaeus Gottfried Purmann (1692) was the first to report taking wax impressions. In 1756, Phillip Pfaff used plaster of Paris impressions. Malocclusions were called “irregularities” of the teeth, and their correction was termed “regulating.” It remained for the Enlightenment to reawaken the spirit of scientific thought necessary to advance dentistry and other disciplines. Beginning in the 18th century, Pierre Fauchard (1678-1761) was leading efforts in the field of dentistry. He has been called the “Father of Orthodontia.” He was the first to remove dentistry from the bonds of empiricism and put it on a scientific foundation. In 1728, he published the first general work on dentistry, a 2-volume opus entitled “The Surgeon Dentist: A Treatise on the Teeth”.

Fauchard described for first time the bandeau, an expansion arch consisting of a horseshoe-shaped strip of precious metal to which the teeth were ligated (Fig 1). This became the basis for Angle's E-arch, and even today its principles are used in unraveling a crowded dentition. He also "repositioned" teeth with a forceps, called a "pelican" because of its resemblance to the beak of that bird, and ligated the tooth to its neighbors until healing took place. At that time, little attention was paid to anything other than the alignment of teeth and then almost exclusively to the maxilla. moreover, he was the first to recommend serial extraction by extracting premolars to relieve crowding [3].

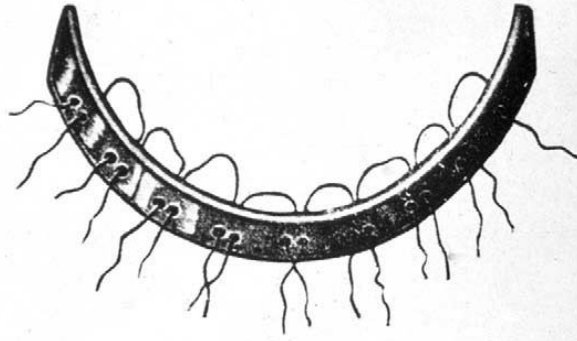


Figure 1. Fauchard's bandeau

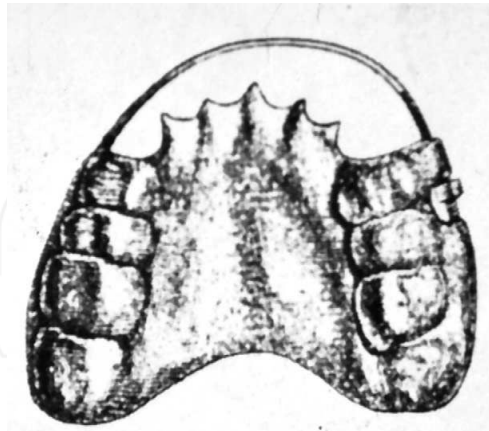


Figure 2. Removable "plate" used by Friedrich Christoph

Friedrich Christoph Kneisel (1797-1847), a German dentist, was the first to use plaster models to record malocclusion and removable appliance to fit prognathic teeth with a chin strap (Fig.

2). However, before the time of Edward Angle, the treatment of malocclusions was chaotic, with little understanding of normal occlusion and even less understanding of the development of the dentition. Appliances were primitive, not only in design but also in the metals and materials used. There was no rational basis for diagnosis and case analysis. It was Edward Hartley Angle (1855 –1930), early in the 20th century, who dominated the emergence of "orthodontia as a science and a specialty". He also created the first educational program to train specialists in orthodontics and he developed the first prefabricated orthodontic appliance system. Angle is considered the father of modern orthodontics [4].

2. The development of the occlusion of the teeth

The primary dentition begins to erupt at the age of about 6 months, and is normally completely in occlusion by about 3 years of age. Details of mean age of eruption and the range of variation have been reported by Van der Linden (1983) for Swedish children and by Sato and Ogiwara (1971) for Japanese children. There appear to be no significant differences between the sexes for the age of primary tooth eruption. The first teeth to erupt and to form occlusal contacts are the incisors, which ideally take up occlusal positions that are more vertical than the permanent incisors, with a deeper incisal overbite. The lower incisors in this condition will contact the cingulum area of the upper incisors in centric occlusion. Spaces are present between the primary incisor teeth. Following eruption of the incisors, the first primary molars erupt into occlusion. These teeth take up occlusal contacts so that the lower molars are slightly forward in relation to the upper molar. The last teeth to erupt into occlusion in the primary dentition are the second molars. These teeth erupt slightly spaced from the first molars, but the space quickly closes by forward movement of the second molars which take up a position so that the distal surfaces of the upper and lower second molars are in the same vertical plane in occlusion. Thus certain features of the 'ideal' occlusion of the primary dentition when fully erupted can be described as following:

1. Spacing of incisor teeth.
2. Anthropoid spaces mesial to upper canine and distal to lower canine, into which the opposing canine interdigitates.
3. Vertical position of incisor teeth, with lower incisor touching the cingulum of upper incisor.
4. The distal surfaces of the upper and lower second primary molars in the same vertical plane.

From the age of about 6 years onwards the primary dentition is replaced by the permanent dentition. The primary incisors, canines and molars are replaced by the permanent incisors, canines and premolars, and the permanent molars erupt as additional teeth. There is some difference in size between the primary teeth and the permanent teeth which directly replace them. The permanent incisors and canines are usually larger than the corresponding primary teeth, and the premolars are usually smaller than the corresponding primary molars. Studies

reported by Van der Linden (1983), have shown that the overall difference in size between the two dentitions is not large, amounting on average to about 3 mm in the upper teeth and less than 1 mm in the lower teeth. There is, however, not a strong correlation between the sizes of the primary dentition and the permanent teeth. The relationship of the jaws to each other will have a large influence on the relationship of the dental arches. The relationship of the jaws to each other can also vary in all three planes of space, and variation in any plane can affect the occlusion of the teeth. The antero-posterior positional relationship of the basal parts of the upper and lower jaws to each other, with the teeth in occlusion, is known as the skeletal relationship. This is sometimes called the dental base relationship, or the skeletal pattern. A classification of the skeletal relationship is in common use, namely:

1. Skeletal Class 1—in which the jaws are in their ideal antero-posterior relationship in occlusion.
2. Skeletal Class 2—in which the lower jaw in occlusion is positioned further back in relation to the upper jaw than in skeletal Class 1.
3. Skeletal Class 3—in which the lower jaw in occlusion is positioned further forward than in skeletal Class 1.

In addition, the teeth erupt into an environment of functional activity governed by the muscles of mastication, of the tongue and of the face. The muscles of the tongue, lips and cheeks are of particular importance in guiding the teeth into their final position, and variation in muscle form and function can affect the position and occlusion of the teeth. Moreover, some dental and local factors can affect the development of occlusion. These include: alterations in size of the dentition in relation to jaw size, crossbite, aberrant developmental position of individual teeth, presence of supernumerary teeth, developmental hypodontia, labial frenum, thumb or finger sucking. Early interference and modification of these basic etiological features can help to avoid malocclusion or reduce the need for treatment in some cases. Consequently interceptive orthodontic treatment has been set as an important aspect of orthodontic care [5].

3. Interceptive orthodontics: Definition of the concept

The concept and the necessity of interceptive orthodontic treatment, so called early, have been controversial. Some define it as removable or fixed appliance intervention in the deciduous, early mixed, or midmixed dentition. Others place it in the late mixed dentition stage of development (before emergence of the second premolars and the permanent maxillary canines). The American Association of Orthodontists' Council of Orthodontic Education defines interceptive orthodontics as "that phase of the science and art of orthodontics employed to recognize and eliminate potential irregularities and malpositions in the developing dentofacial complex." [6]. While some profession's leaders advocate that early treatment is always desirable because tissue tolerance and their power of adjustment are at or near their maximum, others warn that there is no assurance that the results of early treatment will be sustained, and that several-phased treatment will always lengthen overall treatment time.

Early treatment not only may do some damage or prolong therapy, it may exhaust the child's spirit of cooperation and compliance [7]. Joseph Fox (1776-1816, English), in his "Natural History of the Human Teeth" (London, 1803), recommended that treatment be started "before 13 or 14 years of age, and as much earlier as possible." Angle advocated the institution of orthodontic treatment "as near the beginning of the variation from the normal in the process of the development of the dental apparatus as possible". Although Nance advocated that "active treatment in the mixed dentition period is desirable only in Class III cases, crossbites, and Class II cases wherein facial appearance is markedly affected," he freed orthodontists from their hesitancy to treat patients before the development of the adult dentition [8].

4. Orthodontic interceptive measures during primary and mixed dentition

4.1. Space maintainers

The primary dentition plays a very important role in the child's growth and development, not only in terms of speech, chewing, appearance and the prevention of bad habits but also in the guidance and eruption of permanent teeth. Exfoliation of primary teeth and eruption of permanent teeth is a normal physiological process. When this normal process is disrupted, due to factors like premature loss of primary teeth, proximal carious lesions etc, it may lead to mesial migration of teeth resulting in loss of the arch length which may manifest as malocclusion in permanent dentition in the form of crowding, impaction of permanent teeth, supraeruption of opposing teeth etc. The best way to avoid these problems is to preserve the primary teeth in the arch till their normal time of exfoliation is attained. Hence it is rightly quoted that primary teeth serve as best space maintainers for permanent dentition. However, if premature extraction or loss of tooth is unavoidable due to extensive caries or other reasons, the safest option to maintain arch space is by placing a space maintainer. The fixed space maintainers are usually indicated to maintain the space created by unilateral/bilateral premature loss of primary teeth in either of the arches. Of the various fixed space maintainers, Band and Loop type of space maintainers are one of the most frequently used appliances with good high success rates [9]. Cemented lower lingual bars, transpalatal arches, crowns with distal extensions are other forms of space maintainers utilizing similar mechanisms (Fig. 3) Nevertheless, disintegration of cement, solder failure, caries formation along the margins of the band and long construction time are some of the disadvantages associated with them [10].

Considering this, there has been many pilot studies that explain the use of newer adhesive directly bonded splints. They are glass fiber reinforced composite resins (e.g. Ribbond, Everstick) as fixed space maintainers [11, 12]. Ribbond is a biocompatible esthetic material made from high strength polyethylene fibers (Fig. 4). The various advantages of this material includes its ease of adhesion to the dental contours, fast technique of application and good strength, well tolerated by the patient [13]. However there is limited literature is available in terms of efficacy and longevity [14].

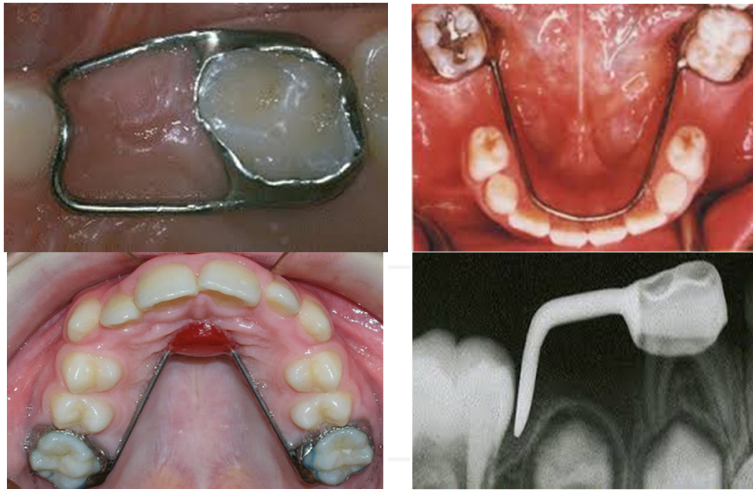


Figure 3. Various space maintainers

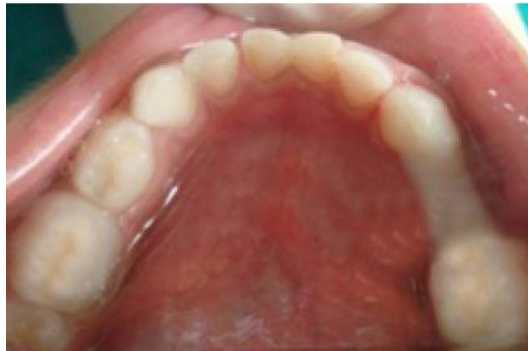

Figure 4. Ribbond space maintainer

5. Elimination of oral habits

Oral habits are learned patterns of muscle contraction and have a very complex nature. They are associated with anger, hunger, sleep, tooth eruption and fear. Some children even display oral habits for release of mental tension. These habits might be non-nutritive sucking (thumb, finger, pacifier and/or tongue), lip biting and bruxism events. These habits can result in damage to dentoalveolar structure; hence, dentists play a crucial role in giving necessary information to parents. This information includes relevant changes in the dentoalveolar structure and the method to stop oral habits. Also, a dentist is required to treat the ensuing malocclusion. The

prevalence of oral habits in high school girls and primary school students has been reported to be 87.9 and 30%, respectively [15].

Oral habits could be divided into 2 main groups:

1. **Acquired oral habits:** Include those behaviors which are learned and could be stopped easily and when the child grows up, he or she can give up that behavior and start another one.
2. **Compulsive oral habits:** Consist of those behaviors which are fixed in child and when emotional pressures are intolerable for the child, he or she can feel safety with this habit, and preventing the child from these habits make him or her anxious and worried.

5.1. Thumb sucking

Thumb sucking is the most common oral habit and it is reported that its prevalence is between 13 to 60% in some societies [16]. Basically, sucking is one of an infant's natural reflexes. They begin to suck on their thumbs or other fingers while they are in the womb. Infants and young children may suck on thumbs, other fingers, pacifiers or other objects. It makes them feel secure and happy, and it helps them learn about their world. The prevalence of this habit is decreased as age increases, and mostly, it is stopped by 4 years of age. There is a relationship between the level of education in parents, the child nutrition and the sucking habit [17]. If the child chooses this habit in the first year of his or her life, the parents should move away his or her thumb smoothly and attract the child's attention to other things such as toys. After the second years of age, thumb sucking will decrease and will be appear just in child's bed or when he/she is tired. Some of children who do not stop this habit, will give it up when their permanent teeth erupt, but there is a tendency for continuing the sucking habit even until adult life. According to a study in 1973, millions of kids do not give up this habit before the eruption of teeth [18]. Nowadays, the level of stress is higher than the time of that study, and as stress is a powerful stimulus in sucking habit, it is probable to find more kids with long-term sucking habit if we do a research exactly like the one which was done in 1973.

Thumb sucking has 2 types:

1. **Active:** In this type, there is a heavy force by the muscles during the sucking and if this habit continues for a long period, the position of permanent teeth and the shape of mandible will be affected.
2. **Passive:** In this type, the child puts his/her finger in mouth, but because there is no force on teeth and mandible, so this habit is not associated with skeletal changes.

In the case of active thumb sucking habit, it is better for a child not to be blamed, teased, offended, humiliated and punished, because these methods will increase the anxiety and consequently increase the incidence of the habit. Long-term finger sucking habit has harmful effects on dentition and speech. In 1870s decade, Camble and Jander reported for the first time that long-term finger sucking has harmful effects on dentition [19].

The side effects of finger sucking are: Anterior open bite, increased overjet, lingual inclination lower incisor and labial inclination upper incisor, posterior cross bite, compensatory tongue thrust, deep palate, speech defect, and finger defects (Eczema of the finger due to alternate dryness and moisture that occurs and even angulations of the finger). The severity of changes in dentition due to finger sucking is related to the duration and times of doing the habit. Also, the position of finger in mouth, dental arches relation and child's health affect the severity of changes [20].

Dental changes due to finger sucking do not need any treatment if the habit stopped before the 5 years of age and as soon as giving up the habit, dental changes will be corrected spontaneously [21]. At the time of permanent anterior teeth eruption and if the child is motivated to stop the sucking habit, it is time to start the treatment as follows:

1. Direct interview with child if he/she is mature enough to understand
2. Encouragement: This can give the child more pride and self-confidence
3. Reward system
4. Reminder therapy
5. Orthodontic appliance: The final stage in treatment is the use of orthodontic appliance whether fixed or removable, which can play the role of reminder and can reduce the willing of finger sucking. For long-term habits or unwilling patient, the fixed intra oral appliance is the most effective inhibitor. In the case of using fixed or removable appliance, we should alarm the parents about potential problems in speaking or eating during the first 24 to 48 h, which are usual and self correcting. After active phase of treatment, the appliance should remain in place for more 3 to 6 month to minimize the relapse potential [22, 23].

5.2. Use of pacifier

The use of pacifier is common in most countries and it will not cause permanent changes in dentition if it is stopped at the age of 2 or 3 years. After that, the use of pacifier has harmful effects on dentition development, and if it is used more than 5 years old, these effects would be more severe [24]. The children who use pacifier are not willing to suck their fingers. pacifier has the following negative effects:

1. Anterior open bite
2. Shallow palate
3. Increased width of lower arch
4. Posterior cross bite.
5. Median otitis

It is suggested that pacifier should be replaced in children who have the habit of finger sucking, because the harmful effects of sucking pacifier are less than finger. In comparison between

different pacifiers, despite the claims, it has been shown that there is no significant advantage for physiologic pacifiers over conventional ones [25].

5.3. Nail biting or onychophagia

Nail biting is a common and untreated medical problem among children. This habit starts after 3 to 4 years of age and is in its peak in 10 years of age. Its rate increases in adolescence, while it declines later. This problem is not gender dependent in children less than 10 years of age, but its incidence in boys is more than girls among adolescents [26]. This problem is a reaction in response to psychological disorders and some children will shift their habits from thumb sucking to nail biting. Complications caused by nail biting include malocclusion of the anterior teeth, teeth root resorption, bacterial infection and alveolar destruction. Moreover, about one fourth of patients with temporo-mandibular joint pain and dysfunction have been shown to suffer from nail biting habit [27]. It is seen in clinic that boys with nail biting have a kind of psychological disorder especially attention deficient hyperactivity disorder (ADHD) more than girls. This habit in higher ages will be replaced with some habits such as lip chewing, gum chewing or smoking (Finn, 1998). Children with nail biting should be evaluated for emotional problems. In addition, putting nail polish or distasteful liquids on nails may be a therapeutic choice.

5.4. Tongue thrust

Tongue Thrust refers to a swallowing pattern in which the tongue is placed in the front of the mouth to begin the swallow (Fig. 5). Forward position of the tongue may also be seen at rest (mouth breathers). Normal swallowing patterns after infancy involve a coordinated smooth movement of the tongue toward the back of the mouth. This consistent forward movement of the tongue may cause speech errors and misaligned teeth. Forward positioning of the tongue during rest has the most influence on misaligning the teeth due to duration of the pressure. The speech disorder most commonly associated with tongue thrust is a frontal lisp, in which the tongue is placed between the teeth for the sounds s and z, and sometimes for sh, ch, j, and soft g.

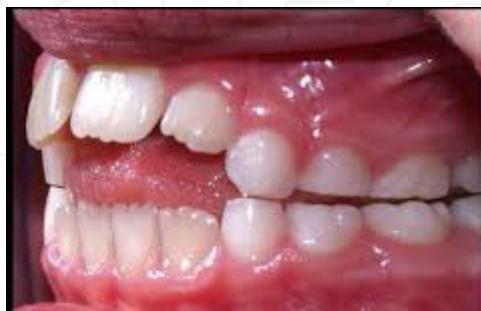

Figure 5. Tongue thrust

The line of treatment for these habits includes removal of the etiology, retraining exercises, and use of mechanical restraining appliances. Tongue bead appliances are commonly used as retraining exercise devices. In severe tongue thrusting cases and in cases with anterior open bite, a bead appliance alone may not be effective in restricting the habit. Tongue crib appliances (Fig. 6) are extremely effective in breaking the tongue thrust habit [28]. They create a mechanical barrier and prevent the tongue from thrusting between the incisors. In most of the cases with severe thumb/digit sucking habit, an anterior open bite develops. This will result in the development of a secondary tongue thrust habit. Hence, in cases with severe prolonged thumb or digit sucking, an appliance which can eliminate both of these habits. The Hybrid Habit Correcting Appliance (HHCA) can be used to effectively restrain and correct tongue thrusting as well as thumb sucking habit (Fig.7). HHCA incorporates a tongue bead, a palatal crib and a U-loop which is attached to the molar bands on either sides. The tongue bead consists of a spinnable acrylic bead of 3mm diameter. The appliance is designed to position the acrylic bead over the posterior one-third of the incisive papilla. The bead acts as a tongue retractor. The patient is asked to constantly pull the bead towards the posterior region of the mouth. The palatal crib and the U-loop are made of 0.9mm stainless steel wire. Three to four spurs are bent on either sides of the bead, starting from the canine region on one side, running anteriorly as a smooth curve (in conventional crib appliances, the cribs run obliquely from one canine to the other side canine) and lying 1mm lingual to the cervical margin of the maxillary anterior teeth. In the region of the incisive papilla, the acrylic bead is incorporated in such a way that it lies over the posterior one-third of the incisive papilla. The tip of the crib should be almost in line with the incisor tip of the maxillary central incisor or 2 mm longer without interfering with the lower incisors when in occlusion. In cases with anterior open bite, the crib should be longer and can be up to 3/4th of the interincisal distance between the upper and lower central incisors. This is to avoid the tongue from thrusting over the tip of the crib. The palatal crib acts as a barrier against the thrusting tongue and works as a mechanical restrainer. The U-loop is incorporated in the second premolar region and it helps to reposition the appliance posteriorly during the retraction phase, when it is used along with fixed orthodontic appliances.

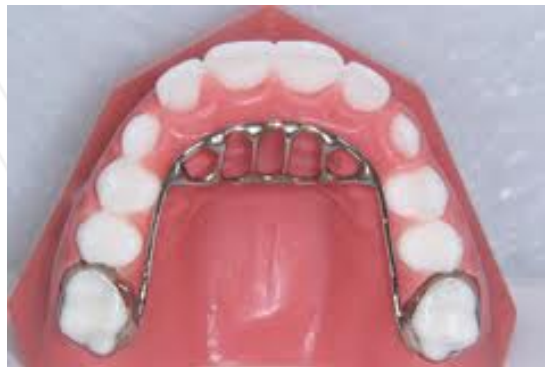

Figure 6. Tongue crib appliances

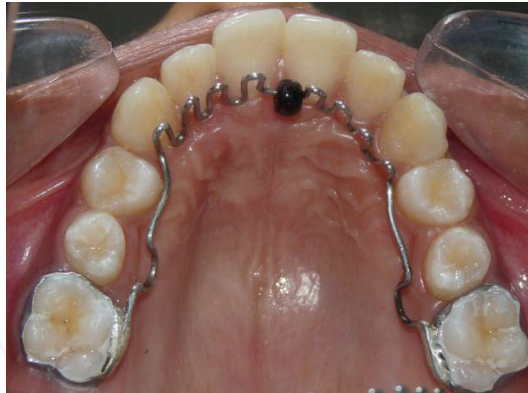

Figure 7. Hybrid Habit Correcting Appliance (HHCA).

5.5. Bruxism

The actions of masticatory system are divided into 2 groups. Functional actions such as mastication, speaking and swallowing, and parafunctional actions such as teeth impacting (clenching) and bruxism.

Functional activities are controllable and occurred daily. Parafunctional actions may be conscious or unconscious and are normally without sound. However, bruxism in nights is unconscious and mostly it is with sound production. Sleep bruxism occurs during stages first and second of non rapid eye movement (REM) sleep and REM sleep. These people do not have any complaint about bruxism, and it would not affect their quality of sleep. But in the old and people with sleep apnea, bruxism can reduce the quality of sleep [29]. Sleep bruxism has 2 types: Primary or idiopathic and secondary or iatrogenic. The first type is without any medical reason and the secondary type is whether with use of drug or without the use of drug. Risk factors are as follows: Genetics: 20 to 50% of patients with sleep bruxism have positive family history [30]; age: The prevalence of this habit decrease with age; cigarette smoking: The prevalence of sleep bruxism in smokers is 1.9 times more than non-smokers; use of alcohol and caffeine [31]; tension and stresses. Clinical findings of sleep bruxism include; report of grinding or impacting sounds of teeth; erosion of the teeth occlusal surfaces and breakdown of repairs; hypertrophy of masticatory muscles; hypersensitivity of teeth to cold air, and joint sounds. The treatment includes no special recommended regimen, but increasing awareness of the patient, intra oral appliances, behavioral treatment and drugs like diazepam and clonazepam have been reported to be effective [32,33].

6. Anterior cross bite correction

Anterior crossbite is defined as a malocclusion resulting from the lingual positioning of the maxillary anterior teeth in relationship to the mandibular anterior teeth. An anterior crossbite

is present when one or more of the upper incisors are in linguo-occlusion (reverse over jet). This may involve just a single tooth or could include all four upper incisors. Anterior dental crossbite has a reported incidence of 4-5% and usually becomes evident during the early mixed-dentition phase [34]. Anterior crossbite correction in early mixed dentition is highly recommended as this kind of malocclusion does not diminish with age. Uncorrected anterior crossbite may lead to abnormal wear of the lower incisors, dental compensation of mandibular incisors leading to thinning of labial alveolar plate and/or gingival recession. However early treatment does not always eliminates orthodontic treatment need in permanent occlusion. The aim of early treatment of this type of malocclusion is to correct anterior crossbite, as otherwise often can lead to very serious Class III malocclusion which would be possible to treat only with combined orthodontic and orthognatic method.

A variety of factors has been reported to cause anterior dental crossbite, including a palatal eruption path of the maxillary anterior incisors; trauma to the primary incisor resulting in lingual displacement of the permanent tooth germ; supernumerary anterior teeth; an over-retained necrotic or pulpless deciduous tooth or root; odontomas; crowding in the incisor region; inadequate arch length; and a habit of biting the upper lip. Various treatment methods have been proposed to correct anterior dental crossbite, such as tongue blades, reversed stainless steel crowns, fixed acrylic planes, bonded resin-composite slopes, and removable acrylic appliances with finger springs.

Bayraka and Tunca, 2008, described the use of bonded resin-composite slopes for the management of anterior crossbite in children in early mixed dentition. Dental crossbite was corrected by applying a 3-4 mm bonded resin-composite slope to the incisal edge of the mandibular incisor with an angle 45° to the longitudinal axis of the tooth (Fig. 8). Correction was achieved within 1-2 weeks with no damage to either the tooth or the marginal periodontal tissue. The procedure was a simple and effective method for treating anterior dental crossbite [35].

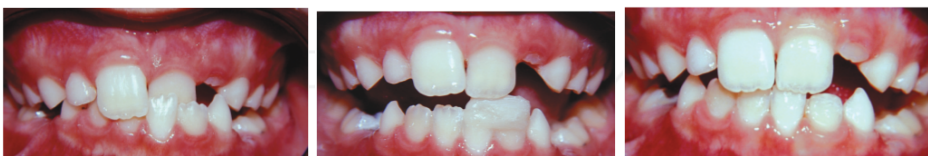

Figure 8. Anterior crossbite correction with bonded resin-composite slope

Some authors believe that removable appliances are not preferred in anterior crossbite correction as they tend to get displaced as the turning frequency decreases following activation. Moreover, poor patient compliance with removable appliance can cause relapse of the case and poor success rate. Therefore, a fixed appliance was proposed as a more sound therapy. Yaseen and Acharya, 2012, described the use of hexa helix, a modified version of quad helix for the management of anterior crossbite and bilateral posterior crossbite in early mixed dentition (Fig. 9). Correction was achieved within 15 weeks with

no damage to the tooth or the marginal periodontal tissue. The procedure is a simple and effective method for treating anterior and bilateral posterior crossbite simultaneously. It provides advantages such as minimal discomfort, reduces need for patient cooperation, and better control of tooth movements [36].

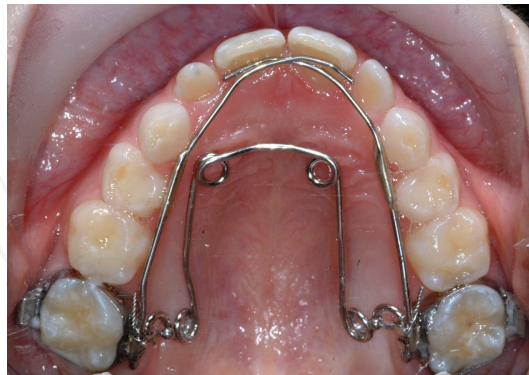

Figure 9. Hexa helix appliance.

In a recent study, Wiedel and Bondemark, 2014, evaluated and compared the stability of correction of anterior crossbite in the mixed dentition by fixed or removable appliance therapy. The study comprised 64 consecutive patients who met the following inclusion criteria: early to late mixed dentition, anterior crossbite affecting one or more incisors, no inherent skeletal Class III discrepancy, moderate space deficiency, a nonextraction treatment plan, and no previous orthodontic treatment. The study was designed as a randomized controlled trial with two parallel arms. The patients were randomized for treatment with a removable appliance with protruding springs or with a fixed appliance with multi-brackets. The outcome measures were success rates for crossbite correction, overjet, overbite, and arch length. Measurements were made on study casts before treatment (T0), at the end of the retention period (T1), and 2 years after retention (T2). Results showed that at T1 the anterior crossbite had been corrected in all patients in the fixed appliance group and all except one in the removable appliance group. At T2, almost all treatment results remained stable and equal in both groups. From T0 to T1, minor differences were observed between the fixed and removable appliance groups with respect to changes in overjet, overbite, and arch length measurements. These changes had no clinical implications and remained unaltered at T2. It was concluded that in the mixed dentition, anterior crossbite affecting one or more incisors can be successfully corrected by either fixed or removable appliances with similar long-term stability [37].

7. Anterior diastema and abnormal labial fraenum

Angle described the midline diastema as a common form of incomplete occlusion characterized by a space between the maxillary and, less frequently, mandibular central incisors. In his

classical article, Andrews stated that interdental diastemas should not exist and all contacts should be tight so that the patient has 'straight and attractive teeth as well as a correct overall dental occlusion'.

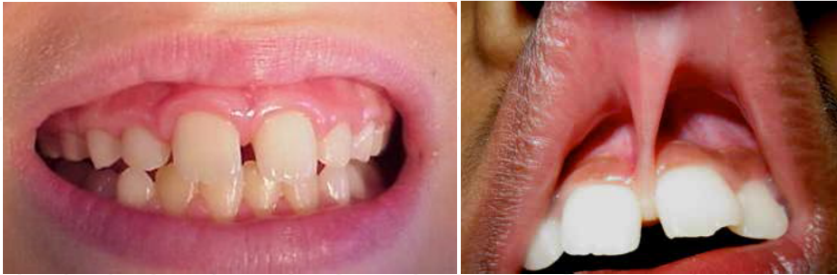

Figure 10. Midline diastema

Sanin et al., developed a method that could predict whether the space would close spontaneously in the developing dentition. This method is based on millimeter measurements in the early mixed dentition and is claimed to have an accuracy of 88%. As the size of the diastema increases the possibility of space closure without treatment reduces. Sanin's prediction is as follows:

- For a 1 mm space in the early mixed dentition the possibility of spontaneous space closure is 99%.
- For a 1.5 mm space the possibility is 85%.
- For a 1.85 mm diastema it is 50%.
- For a 2.7 mm space the possibility of closure without treatment is only 1%.

The measurement should be made after the eruption of the lateral incisors. Hence it is advisable to intervene early if the midline diastema is more than 1.85 mm after the eruption of the permanent lateral incisors [38].

To treat the midline diastema effectively, an accurate diagnosis of the etiology and an intervention relevant to the specific etiology is necessary. Timing of the treatment is important to achieve satisfactory results. Most of the researchers do not recommend tooth movement until the eruption of the permanent canines, but in certain cases, where very large diastemas exist, treatment can be initiated early [39].

Nainar and Gnanasundaram noted in their study of midline diastemas on 9774 Southern Indian individuals, that there was a relatively increased frequency of familial occurrence and hence proposed the presence of a genetic factor in the expression of midline diastema. Treatment methods include orthodontic correction with a fixed or removable appliance and prosthetic correction with composites and crowns. If the diastema is large, it is advisable to

close the space using orthodontic appliances. In most cases, simple removable appliances incorporating finger springs or a split labial bow can give good results [40].

A hypertrophic labial frenum may be considered as a major etiological factor for midline diastema. In a thick and fleshy labial frenum, the fibro-elastic band crosses the alveolus and inserts into the incisive papilli, preventing the approximation of the maxillary central incisors. The blanching test is a simple diagnostic test to predict whether a normal tight contact between the central incisors. Most of the researchers, like Angle, Sicher, and Edwards, [41-43] are of the opinion that superior labial frenum causes midline diastema. Some researchers, like Popovich et al, believe that there is an inverse relationship between high frenal attachment and midline diastema. According to them, labial frenum persists owing to the existing diastema and, as the dentition applies little or no pressure on the tissues, there is little or no atrophy of the frenum [44]. However, most of the researchers agree that removal of the high bulbous labial frenum is important for the stability after the closure of the midline diastema.

Excessive anterior overbite is another major contributing factor for midline diastema. As a result of trauma to the maxillary anterior teeth from the mandibular incisors, the maxillary incisors procline. This results in an increase of the upper arch circumference, leading to a diastema. Practitioners should not fail to identify deep bite as an aetiology for the diastema. Any attempt to close the midline spacing without correcting the deep bite and anterior traumatic bite will lead to a speedy relapse of the condition.

Oral habits such as tongue thrusting and finger sucking can be other etiological factors for the appearance of the midline diastema. According to Proffit and Fields, tongue position at rest may have a greater impact on tooth position than tongue pressure, as the tongue only briefly contacts the lingual surface of the anterior teeth during thrusting [45]. The tongue pushes the anterior teeth to a forward position, increasing the circumference which results in spacing. An abnormal habit of the tongue can be detected by the tip of the tongue popping out through the anterior spacing when the patient is asked to swallow. In cases of anterior open bite, the tongue may be seen thrusting between incisal edges of the maxillary and mandibular incisors. Patients with tongue thrust often produce a snap sound on swallowing and also have hyperactivity of the orbicularis oris muscle. Deleterious habits have to be corrected by using habit-breaking appliances and by psychological approaches. The use of fixed tongue cribs are found to be effective in breaking the tongue-thrusting habit.

Peg-shaped laterals Supernumerary teeth/mesiodens, missing teeth, pathologic migration of teeth Tooth size, arch size discrepancy, angulation of teeth, odontomas occurring in the maxillary midline, developmental cysts in the orofacial midline, and flaccid lips are other proposed etiological factors leading to midline diastema. Relapse is a major concern in the correction of midline diastema. However, exact diagnosis and removal of the etiology is the key to obtaining a stable result. Long-term use of retainers or even permanent bonded lingual retainers are advocated, especially in cases with large diastema. Large pre-treatment diastema presence of at least one family member with a similar condition increases the risk of relapse [46,47].

8. Serial extraction

The term serial extraction describes an orthodontic treatment procedure that involves the orderly removal of selected deciduous and permanent teeth in a predetermined sequence (Dewel, 1969). Serial extraction can be defined as the correctly timed, planned removal of certain deciduous and permanent teeth in mixed dentition cases with dento-alveolar disproportion in order to: Alleviate crowding of incisor teeth and to allow unerupted teeth to guide themselves into improved positions (canines in particular), and to lessen (or eliminate) the period of active appliance therapy. Thus, it is one of the positive interceptive orthodontic procedure generally applied in most discrepancy cases where supporting bone is less than the total tooth material [48].

Serial extraction has been of interest to dentist for many years. Throughout the history of dentistry it has been recognized that the removal of one or more irregular teeth would improve the appearance of the remainder. Nance presented clinics on his technique of progressive extraction in 1940 and has been called as the father of serial extraction philosophy in the United States. Kjellgren in 1940 termed this extraction procedure as planned or progressive extraction procedure of teeth. Hotz, 1970, named the same procedure on "Guidance of eruption". According to him the term guidance of eruption is comprehensive and encompasses all measures available for influencing tooth eruption [49]. Widespread adoption of serial extraction as a corrective treatment procedure continues to be a source of concern to all pedodontists who are aware of its limitations as well as of its possibilities. The principle reason is that its application involves growth prediction. Every serial extraction diagnosis is based on the promise that future growth will be inadequate to accommodate all of the teeth in a normal alignment.

If primary teeth are extracted prematurely, this will influence the eruption rate and position of the permanent successors. In general, the eruption will be delayed if the primary tooth overlying the permanent tooth is extracted 1 ½ years or more from the time the primary tooth would normally exfoliate. Conversely, the eruption rate can be accelerated if the primary tooth overlying the permanent tooth is extracted less than a year before the primary tooth would normally exfoliate. Biologic variation in eruption rates will affect these time tables, as will periapical inflammation of the primary tooth. Another useful principle is that crowded teeth adjacent to an extraction site tend to align themselves [50].

Normal dental, skeletal and profile development – influences the rationale for serial extraction. The work of Moorrees et al on arch dimensions and serial extractions indicates that there is minimal increase in mandibular intercanine width between 8 and 18 years, occurring usually around the time the permanent mandibular canines erupt. The maxillary intercanine width increases slightly more and over a longer time. The dental arch perimeter from the distal of the mandibular primary second molar to its antimere is less in the permanent dentition than in the primary. Also the principles of leeway space, interrelationship of overjet, overbite, axial inclinations, and mesial shift, and arch-length analysis must be considered in determining whether to institute a serial extraction procedure. The skeletal and profile factors that influence serial extractions are the another-posterior, vertical, and transverse relationships as well as the

developmental pattern. Specifically the relation of the maxilla to the mandible and of the both to the cranial base must be determined to identify protrusions, retrusions, hyperdivergences, hypodivergences, crossbites, and asymmetries. Also rotational, vertical, and transverse growth patterns need to be integrated into the decision-making process [51].

The idea of serial extraction started when Pedodontist sees a child 5 or 6 years of age with all the deciduous teeth present in a slightly crowded state or with no spaces between them, he can predict, with a fair degree of certainty, that there will not be enough space in the jaws to accommodate all the permanent teeth in their proper alignment. As Nance (1940), Dewel (1954), and others have pointed out, after the eruption of the first permanent molars at 6 years of age, there is probably no increase in the distance from the mesial aspect of the first molar on one side around the arch to the mesial aspect of the first molar on the opposite side. If there is any change, it may be an actual reduction of the molar-to-molar arch length, as the "leeway" space is lost through the mesial migration of the first permanent molars during the tooth-exchange process and correction of the flush terminal plane relationship. At that time, a list of possible clinical clues for serial extraction were proposed: Premature loss of deciduous teeth, arch-length deficiency and tooth size discrepancies, lingual eruption of lateral incisors, unilateral deciduous canine loss and shift to the same side, mesial eruption of canines overlateral incisors, mesial drift of buccal segments, abnormal eruption direction and eruption sequence, flaring of incisors, ectopic eruption of mandibular first deciduous molar, abnormal resorption of II deciduous molar, ankylosis, labial stripping, and gingival recession, usually of lower incisor. However, a number of contraindications for serial extractions were addressed: Congenital absence of teeth providing space, mild to moderate crowding, deep or open bites, severe Class II, III of dental/skeletal origin, cleft lip and palate, spaced dentition, anodontia / oligodontia, Midline diastemia, dilacerations extensive caries, disproportion between arc length and tooth material.

9. Considerations in serial extraction

1. Extracting primary canines will produce maximum amounts of self improvement in crowding with greatest inter-ception of lingual cross bite.
2. Extracting primary first molars produces earliest eruption of first premolars but reduces speed and amount of improvement in permanent central and lateral incisors crowding and position due to retention of C that it has limited application.
3. Extracting primary canines and first molars is a compromise between rapid improvement in and desired early eruption of permanent central and lateral incisors due to simultaneous eruption of first premolars with this extraction sequence.

There is no single technique for Serial Extraction. It is a long-range guidance program and it may be necessary to reevaluate and change tentative decisions several times. Usually the child is 7-8 years of age when he/she brought to the pedodontist. At this time the maxillary and mandibular central incisors are usually erupted, but there is inadequate space in anterior

segments to allow normal eruption and positioning of lateral incisors. In some cases, mandibular lateral incisors have already erupted but they are usually lingually positioned and rotated. The same is with the maxillary lateral incisors.

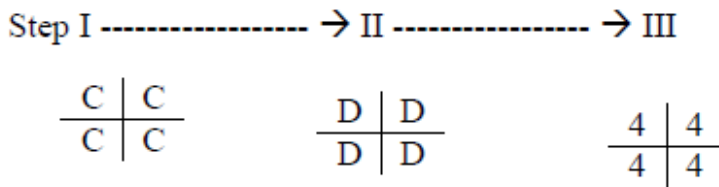
9.1. Dewel's method

There are 3 stages in Serial Extraction Therapy:

First: Removal of deciduous canines : to permit eruption and optimal alignment of lateral incisors. There is some amount of improvement in position of central incisors also.

Second: Removal of first deciduous molars: to accelerate eruption of first premolars ahead of canine if possible.

Third: Removal of erupting first premolars: Before the first premolars are extracted, all the diagnostic criteria must again be evaluated. The status of developing third molars must be evaluated, because if the third molars are congenitally missing then extraction of 1st premolars would be unnecessary because there would be enough space. So in short, Dewel's method is:



9.2. Tweed's method

According to Tweed, if diagnosis shows the discrepancy exists between teeth and basal bone structures and if patient is between 7 ½ to 8 ½ years, Serial Extraction program is should be carried out. Sequence is:

First: At approximately 8 years all deciduous molars are extracted. It is preferable to maintain in deciduous canines to retard eruption of permanent canines.

Second: extract of first premolar and deciduous canines should he done 4-6 months prior to eruption of permanent canines when they erupt they migrate posteriorly into good position. Any irregularities in mandibular incisors if not too severe, get corrected themselves and they are also tipped lingually due to normal muscular forces.

9.3. Moyers method

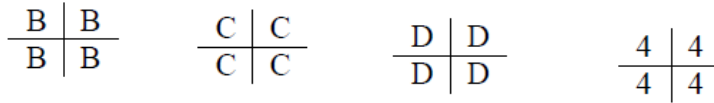
Proposed when crowding seen in central incisor region. Fairly eruption of lateral incisors.

Stage I (Extraction of all deciduous lateral incisors). It helps in alignment of central incisors.

Stage II (Extraction of all deciduous canines after 7-8 months). It helps in alignment of lateral incisors and provides space for lateral incisors.

Stage III (Extraction of all deciduous first molars). It stimulates eruption of all first premolars.
 Stage IV (Extraction of all first premolars after 7-8 months). It provides space for canines and stimulates eruption of canines.

Step I ----- → II ----- → III ----- → IV



The technique of serial extraction was biologically sound proven, and was not considered a compromise. with continuous observation and study, the sight has changed. conventional orthodontic therapy is required to complete the alignment of teeth, to parallel the roots on either side, of the extraction space, to eliminate overbite, and to effect residual space closure. With advances in fixed orthodontics, less damage and more stable results are obtained. Moreover, it must be remembered that, once teeth have been extracted, they cannot be replaced if an error in judgment must be made, it is more expedient to error in a conservative manner without extraction as teeth can always be extracted at a later date. To summarize the limitations and side effects of serial extraction:

First: Tendency of bite to close following loss of posterior teeth. A normal overbite depends on adequate vertical growth and Serial Extraction involves removal of strategically located deciduous and permanent teeth. Vertical and horizontal growth depends great part on normal proximal and occlusal function in maintaining arch length and normal overjet and overbite.

Second: Failure of premolars that fail to reach their normal occlusal level. In normally developing dentition, the premolars are ready to emerge soon after the loss of the deciduous molars and then proceed occlusally with no delay. But in Serial Extraction cases the premolars have to travel a long way before penetrating the gingival tissues. Prolonged absence of teeth in the posterior segment of arches permits the tongue to flow into remaining spaces and this may remain as a tongue thrusting habit. This in turn prevents premolars from attaining full eruption.

Third: Effect of serial extraction on facial esthetics. Most of us over emphasize on straight profile which has led to extraction of teeth in mixed dentition because the lips appear to be prominent. Its normal for lip line to have greater convexity during early transitional stages than it will have in mature dentition. Lip fullness is not a reliable criterion for extraction in early mixed dentition. The straight profile must be viewed with greater concern because early removal of premolars is likely to cause a concave profile.

Fourth: Nasal development is another unpredictable hazard. The nose is one structure that continues to grow long after other facial parts have reached maturity. Unrestrained extraction will accentuate its prominence by reducing skeletal development in dental area. Moreover growth of chin is unpredictable. If growth in nose and chin exceeds normal range a concave profile is obtained.

In conclusion, one team of clinicians and practitioners demonstrate that undertaking a serial extraction protocol can afford an improvement of the patient's self-esteem, resulting in a positive social impact due to esthetic enhancement. Furthermore, the low cost of this protocol permits the use of this therapy in underprivileged communities provided the diagnosis is certain and the post extraction movement of teeth is controlled by mechanical means. The other team suggest that serial extraction is counter-productive. The early extraction of primary cuspids will invariably result in crowding of the permanent cuspids region. In reality, they adopt the idea that the problem is maintained and the crowding shifts to involve the permanent cuspids. They remind us with the most basic canon of the health profession which is "first do no harm" [52].

10. Interceptive functional therapy

There is little doubt that functional appliances produce tooth movement and in many cases can correct occlusal discrepancies. The controversy over their use relates mainly to their mode of action, and in particular to two aspects. The first is the question of modification of growth of the basal parts of the jaws. Many authorities believe that basal jaw growth can be altered by functional means. The temporo-mandibular joint area has been thought to be a reactive growth site, i.e. any prolonged change in the position of the mandible during the growth period, such as is induced by wearing the appliance, results in bone apposition on the mandibular and temporal surfaces of the enlarged joint cavity. Baume, (1969) quotes histological evidence to support this concept, and ample clinical evidence has been produced in attempts to show that the use of functional appliances can alter the skeletal relationship of the jaws [53]. On the other hand, this clinical evidence does not always take into account the effects of normal growth. As functional appliances are normally used during the mixed dentition stage a considerable amount of normal growth must occur which could alter jaw size and relationships. Several investigators have failed to find evidence of altered growth with functional appliances, but instead have found the main effects to be tipping of the incisors and an opening rotation of the mandible [54,55].

The first practitioner to use functional jaw orthopedics to treat a malocclusion was Pierre Robin (1902).

His appliance influenced muscular activity by changing the spatial relationship of the jaws. Robin's monoloc was actually a modification of Kingsley's maxillary plate. It extended all along the lingual surfaces of the mandibular teeth, but it had sharp lingual imprints of the crown surfaces of both maxillary and mandibular teeth. It incorporated an expansion screw in the palate to expand the dental arches. In 1909, Viggo Andresen, a Danish dentist, used lingual horseshoe flange that guides the mandible forward to eliminate Class II malocclusion cases. The original Andresen activator was a tooth-borne, loosely fitting passive appliance consisting of a block of plastic covering the palate and the teeth of both arches, designed to advance the mandible several millimeters for Class II correction and open the bite 3 to 4 mm. The original design had facets incorporated into the body of the appliance to direct erupting

posterior teeth mesially or distally, so, despite the simple design, dental relationships in all 3 planes of space could be changed.

The Herbst appliance (Dentaurum, Newtown, Pa) is suitable for slightly older children whose cooperation might not be dependable, because it is a fixed appliance worn 24 hours a day. The Herbst was introduced in 1905 by Emil Herbst, but his findings were not published until 1935. Little more was published on the appliance until the late 1970s, when Hans Pancherz, recognizing its possibilities for mandibular growth stimulation, revived interest. The typical Herbst consists of a telescoping mechanism connected to the maxillary first molars at one end and a cantilevered arm attached to the mandibular first molars at the other end; it forces the mandible forward (Fig. 11).

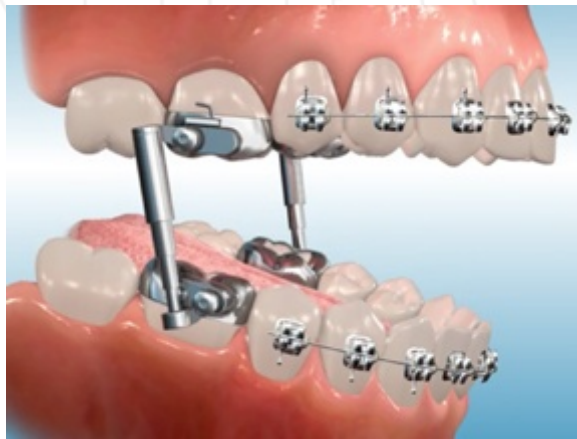

Figure 11. Herbst Appliance

In 1950, Wilhelm Balters (1893-1973), in an effort to treat Class II malocclusions characterized by deficient mandibles, began to modify Andresen's activator. He gave it the name bionator. It is indicated for patients with favorable facial growth patterns and is designed to produce forward positioning of the mandible. As with the function regulator, the bionator is available in 3 designs. Consisting of 2 halves connected by a Coffin spring, it is less restrictive of speech than Andresen's appliance. However, the treatment also highly depends on patient compliance, especially with regard to exercising

The Clark twin-block (Clark 1988) consists of separate upper and lower removable appliances, each with a 45° posterior bite plane designed to induce a mandibular posture of the desired amount and direction (Fig. 12) One or both sections may incorporate a mid-line screw to effect arch expansion(Fig. 13), and there is provision for the addition of extraoral traction.

Many clinical studies have been done on skeletal and dentoalveolar changes associated with functional appliances therapy in Class II malocclusions, but the scientific data are still controversial. Concerning skeletal effects induced by the functional appliances some authors

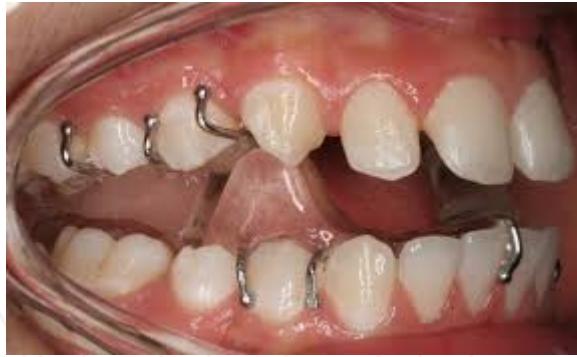

Figure 12. Twin-block appliance



Figure 13. Expansion screw within Twin block appliance

demonstrate significant influences on mandibular growth [56], the others claim that it may be induced only small skeletal changes by this type of treatment [57]. The latter group of researchers found that the main changes occurred with functional appliance therapy were dentoalveolar distalization of the buccal and retroclination of the frontal upper teeth, along with mesial movement of the lower buccal segments and proclination of the lower labial segments[58]. Such diversity of results on skeletal changes might be related first of all to difficulties in applying treatment at the maximum growth spurt time. Another reason for the inconsistency in assessment of treatment results might be the use of not reliable reference lines and/or structures for cephalometric analysis before and after treatment. This makes difficult to assess real contribution of skeletal and dental components to occlusal changes [59]. A new paradigm for successful treatment presents a philosophical challenge to combine the benefits of orthodontic and orthopedic techniques to extend our horizons in the treatment of malocclusion that requires dental and skeletal correction.

The prefabricated myofunctional appliances are a series of prefabricated appliances produced by myoresearch company, Queensland, Australia. These appliances were also called "Trainers™" which include T4K™ and T4F™ appliances (Fig.14,15). The idea of prefabricated

functional appliances was recently introduced to the orthodontic field and it becomes more practical with the new customizable functional appliance T4F™. The T4F™ appliance is a prefabricated re-mouldable appliance when immersed in very hot water so it can be customized to accommodate the patient's dentition in the mouth and increase the retention. This new functional appliance has the advantage of the immediate issuing and the direct fitting of the appliance in the patient's mouth and it is also a better choice in terms of the cost for the private practitioners. The prefabricated appliances were claimed to be effective for class II Div.1 management but there was no evidence except for T4K™ type which is designed for young children.

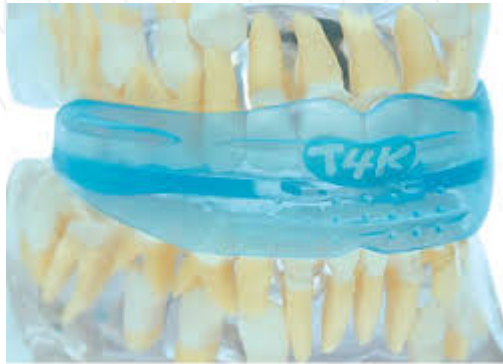

Figure 14. T4K™ The Pre-Orthodontic Trainer

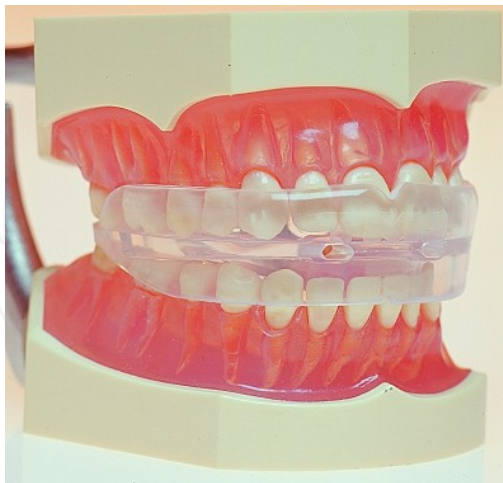

Figure 15. T4F™ The Pre-Orthodontic Trainer

Uysal et al., 2012, evaluated the effects of Pre-Orthodontic Trainer (T4F™) appliance on the anterior temporal, mental, orbicularis oris, and masseter muscles through electromyography (EMG) evaluations in subjects with Class II division 1 malocclusion and incompetent lips. Twenty patients (mean age: 9.8 ± 2.2 years) with a Class II division 1 malocclusion were treated with T4F™ (Myofunctional Research Co., Queensland, Australia). A group of 15 subjects (mean age: 9.2 ± 0.9 years) with untreated Class II division 1 malocclusions was used as a control. EMG recordings of treatment group were taken at the beginning and at the end of the T4F™ therapy (mean treatment period: 7.43 ± 1.06 months). Follow-up records of the control group were taken after 8 months of the first records. Recordings were taken during different oral functions: clenching, sucking, and swallowing. Statistical analyses were undertaken with Wilcoxon and Mann-Whitney U-tests. During the T4F™ treatment, activity of anterior temporal, mental, and masseter muscles was decreased and orbicularis oris activity was increased during clenching and these differences were found statistically significant when compared to control. Orbicularis oris activity during sucking was increased in the treatment group ($P < 0.05$). In the control group, significant changes were determined for anterior temporal ($P < 0.05$) and masseter ($P < 0.01$) muscle at clenching and orbicularis oris muscle at swallowing during observation period ($P < 0.05$). Findings indicated that treatment with T4F™ appliance showed a positive influence on the masticatory and perioral musculature [60].

Usumeze et al., 2004, evaluated the dentoskeletal treatment effects induced by a preorthodontic trainer appliance (T4K™) treatment on Class II, division 1 cases. Twenty patients (10 girls and 10 boys, mean age 9.6 ± 1.3 years) with a Class II, division 1 malocclusion were treated with T4K™ (Myofunctional Research Co., Queensland, Australia). The patients were instructed to use the trainer every day for one hour and overnight while they slept. A control group of 20 patients (mean age 10.2 ± 0.8 years) with untreated Class II, division 1 malocclusions was used to eliminate possible growth effects. Lateral cephalograms were taken at the start and end of treatment. Final cephalograms were taken 13.1 ± 1.8 months after trainer application, compared with a mean of 11.2 ± 2.4 months later for the control group. The mean and standard deviations for cephalometric measurements were analyzed by paired-samples t-test and independent-samples t-tests. At the end of the study period, the trainer group subjects showed significant changes including anterior rotation and sagittal growth of the mandible, increased SNB and facial height, reduced ANB, increased lower incisor proclination, retroclination of upper incisors, and overjet reduction. However, only total facial height increase, lower incisor proclination, and overjet reduction were significantly higher when compared with the changes observed in the control group. This study was the first that demonstrated that the preorthodontic trainer application induces basically dentoalveolar changes that result in significant reduction of overjet and can be used with appropriate patient selection [61].

In a very recent study, Dr. Hanoun and his colleagues evaluated the effectiveness of the prefabricated myofunctional appliance T4F™ (compared to Twin Block appliance) in the treatment of Class II Div.1 malocclusion. The study was a prospective randomized clinical trial. All subjects were growing patients aged 11 -14 years old with Class II Div.1 malocclusion based on Class II skeletal relationship with overjet of 7 mm or more. Those subjects who had anterior open bite or previous orthodontic therapy or craniofacial anomalies or history of fa-

cial trauma were all excluded from the trial. The overjet was reduced more favourably in the Twin Block group than in the T4F™ group with a mean difference between the two groups of 2.14 mm ($p < 0.01$). Moreover, there was a significant difference between both groups in terms of horizontal skeletal linear dimensions of the mandible with more favourable increase in the Twin Block group ($p < 0.05$).

11. Conclusion

Interceptive orthodontics is employed to recognize and eliminate potential irregularities and malposition in the developing dentofacial complex. These procedures are directed to lessen or to eliminate the severity of developing malocclusion. The early assessment of the child, followed by regular review, and treatment at the appropriate time if necessary, will do much to reduce malocclusion to the basic non-preventable level. The key to prevention of this kind is awareness. This part examines the key areas relating to interceptive orthodontics with the available evidence to support the clinical management of common problems presenting in the mixed dentition.

Acknowledgements

I offer my sincerest gratitude to my wife, Mrs. Huda Zurigat who has supported me throughout my project with a lot of patience and enthusiasm. Her assistance in typing and organizing words and figures in this article was indispensable.

Author details

Maen H. Zreagat*

Address all correspondence to: maenzreagat@yahoo.com

Al-Ogaly Medical Group, Saudi Arabia

References

- [1] Weinberger BW. Historical résumé of the evolution and growth of orthodontia. J Am Dent Assoc 1934;21:201-221.
- [2] Asbell MB. A brief history of orthodontics. Am J Orthod Dentofacial Orthop 1990;98:176-83.

- [3] Casto FM. A historical sketch of orthodontia. *Dent Cosmos* 1934;76:111-35.
- [4] Brodie AG. Orthodontic history and what it teaches. *Angle Orthod* 1934;4:85-97.
- [5] Irurita J, Alemán I, López-Lázaro S, Viciano J, Botella MC. Chronology of the development of the deciduous dentition in Mediterranean population. *Forensic Sci Int*. 2014;240:95-103.
- [6] Borrie F, Bonetti D, Bearn D. What influences the implementation of interceptive orthodontics in primary care? *Br Dent J*. 2014;216(12):687-91.
- [7] Kerosuo H1, Väkiparta M, Nyström M, Heikinheimo K. The seven-year outcome of an early orthodontic treatment strategy. *J Dent Res*. 2008;87(6):584-8.
- [8] Norman W. Orthodontics in 3 millennia. Chapter 12: Two controversies: Early treatment and occlusion *Am J Orthod Dentofacial Orthop*. 2006;130(6):799-804.
- [9] Baroni C; Franchini A; Rimondini L: Survival of different types of space maintainers. *Pediatr Dent*. 1994;16:360-61.
- [10] Kirzioglu Z, Ozay MS Z, Ozay MS. Success of reinforced fibre material space maintainers. *J Dent Child*. 2004;71;2:158-62.
- [11] Kargul B, Çağlar E, Kabalay U. Glass fibre reinforced composite resin as fixed space maintainer in children 12 month clinical follow up. *J Dent Child*. 2005; 72(3):109-12
- [12] Kargul B, Çağlar E, Kabalay U. Glass fiber-reinforced composite resin space maintainer: case reports. *J Dent Child*. 2003;71:258-61.
- [13] Goldberg AJ, Frelich MA. Tooth splinting and stabilisation *Dent Clin North Am*. 1999; 43 (1) :127-33.
- [14] Setia V, Pandit IK, Srivastava N, Gugnani N, Sekhon HK. Space maintainers in dentistry: past to present. *J Clin Diagn Res*. 2013;7(10):2402-5.
- [15] Kharbanda O. P, Sidhu S. S, Sundaram K, Shukla D. K, "Oral habits in school going children of Delhi: a prevalence study," *Journal of the Indian Society of Pedodontics and Preventive Dentistry*. 2003; 21 (3): 120–124.
- [16] Larson EF. The prevalence and etiology of prolonged dummy and finger sucking habit. *Am. J. Orthod.*, 1985; 87(5):172-174.
- [17] Farsi NM, Salama FS.. Sucking habits in Saudi children: prevalence, contributing factors and effects on the primary dentition. *Pediatr. Dent*. 1997; 19(1):28-33.
- [18] N. L. Villa, "Changes in the dentition secondary to palatal crib therapy in digit-suckers: a preliminary study," *Pediatric Dentistry*, vol. 19, no. 5, pp. 323–326, 1997.
- [19] B. S. Haskell and J. R. Mink, "An aid to stop thumb sucking: the "Bluegrass" appliance," *Pediatric Dentistry*. 1991; 13 (2): 83– 85.

- [20] Van Norman RA (1997). Digit-sucking: A review of the literature, clinical observations and treatment recommendations. *Int. J. Orofacial Myol.*, 23: 14-34
- [21] Warren JJ, Bishara SE (2002). Duration of nutritive and nonnutritive sucking behavior and their effects on the dental arches in the primary dentition. *Am. J. Orthod.*, 121: 347-356.
- [22] Moimaz SA, Garbin AJ, Lima AM, Lolli LF, Saliba O, Garbin CA. Longitudinal study of habits leading to malocclusion development in childhood. *BMC Oral Health*. 2014; (4):14-96.
- [23] Maia-Nader M, Silva de Araujo Figueiredo C, Pinheiro de Figueiredo F, Moura da Silva AA, Thomaz EB, Saraiva MC, Barbieri MA, Bettiol H. Factors associated with prolonged non-nutritive sucking habits in two cohorts of Brazilian children. *BMC Public Health*. 2014;14:14-17.
- [24] Fleming PJ, Blaive PS Pacifier use an sudden infant death syndrome. *Arch. Dis. Children*. 1999; 81(2): 112-116.
- [25] Lopes TS, Moura Lde F, Lima MC. Breastfeeding and sucking habits in children enrolled in a mother-child health program. *BMC Res Notes*. 2014;14(7): 23-38.
- [26] Tanaka OM, Vitral RW, Tanaka GY, Guerrero AP, Camargo ES. (. Nailbiting, or onychophagia: A special habit. *Am. J. Orthod. Dentofacial Orthop*. 2008;134(2): 305-308.
- [27] Saheeb D. Prevalence of oral and parafunctional habits in Nigerian patients suffering temporomandibular joint pain and dysfunction. *J. Med. Biomed. Res.*, (2005; 4(1): 59-64
- [28] Feu D1, Menezes LM, Quintão AP, Quintão CC. A customized method for palatal crib fabrication. *J Clin Orthod*. 2013 Jul;47(7):406-12.
- [29] Kato T, Thein NMR, Montplaisir JY, Lavigne GJ. Bruxism and orofacial movements during sleep. *Dent. Clin. North Am*. 2001;45(4):651-676.
- [30] Hublin C, Kaprio J, Partinen M, Koskenvuo M. Sleep bruxism based on self – report in a nationwide twin cohort. *Sleep Res*. 1998;7(1): 61-68
- [31] Dahan JS, Lelong BA, Celant S, Leysen V. Oral perception in tongue thrust and other oral habits. *Am. J. Orthod. Dentofacial Orthop.*, 2000;118:385-91.
- [32] Pierce CJ, Gale EN. A comparison of different treatments for nocturnal bruxism. *J. Dent. Res.*, 1988;67: 597-601.
- [33] Ferreira NM, Dos Santos JF, Dos Santos MB, Marchini L. Sleep bruxism associated with obstructive sleep apnea syndrome in children. *Cranio*. 2014 Sep [Epub ahead of print].
- [34] Major PW, Glover K. Treatment of anterior cross-bites in the early mixed dentition. *Journal of the Canadian Dental Association*. 1992;58(7):574–578.

- [35] Bayrak S1, Tunc ES. Treatment of anterior dental crossbite using bonded resin-composite slopes: case reports. *Eur J Dent.* 2008;2(4):303-6.
- [36] Yaseen SM, Acharya R. Hexa Helix:Modified Quad Helix Appliance to Correct Anterior and Posterior Crossbites in Mixed Dentition. *Case Reports in Dentistry.* 2012: 1-5.
- [37] Wiedel AP1, Bondemark L. Stability of anterior crossbite correction: A randomized controlled trial with a 2-year follow-up. *Angle Orthod.* 2014 Jul 8. [Epub ahead of print]
- [38] Sanin C, Sekiguchi T, Savara BS. A clinical method for the prediction of closure of the central diastema. *ASDC J Dent Child* 1969; 36: 415-418.
- [39] Baum AT. The midline diastema. *J Oral Med* 1966; 21: 30-39.
- [40] Nainar SM, Gnanasundaram N. Incidence and etiology of midlinediastema in a population in southIndia (Madras). *Angle Orthod* 1989; 59: 277-282.
- [41] Angle EH. *Treatment of Malocclusion of the Teeth* 7th edn. Philadelphia: SS White Dental Manufacturing Company, 1907: p167.
- [42] Sicher H. *Oral Anatomy* 2nd edn. St Louis: CV Mosby Co, 1952: pp272-273.
- [43] Edwards JG. The diastema, the frenum, the frenectomy: a clinical study. *Am J Orthod* 1977; 71:489-508.
- [44] Popovich F, Thompson GW, Main PA. Persisting maxillary diastema: indications for treatment. *Am JOrthod* 1979; 75(4): 399-404.
- [45] Proffit WR, Fields HW. *Contemporary Orthodontics* 2nd edn. St Louis: Mosby Yearbook, 1993: p467
- [46] Shashua D, Artun J. Relapse afterorthodontic correction of maxillarymedian diastema: a follow-up evaluation of consecutive cases. *Angle Orthod* 1999; 69: 257-263.
- [47] Nagalakshmi S, Sathish R, Priya K, Dhayanithi D. Changes in quality of life during orthodontic correction of midline diastema. *J Pharm Bioallied Sci.* 2014 (Suppl 1): 162-4
- [48] Almeida RR, Almeida MR, Oltramari-Navarro PV, Conti AC, Navarro Rde L, Souza KR. Serial extraction: 20 years of follow-up. *J Appl Oral Sci.* 2012; 20(4):486-92.
- [49] Hotz P.R. Guidance of eruption versus serial extraction. *Am. J. Orthod,* 1970; 58(1): 1-20.
- [50] Nagalakshmi S, Sathish R, Priya K, Dhayanithi D. Changes in quality of life during orthodontic correction of midline diastema. *J Pharm Bioallied Sci.* 2014; 6 (Suppl 1):. [Epub ahead of print]
- [51] Lee KP. The fallacy of serial extractions. *Aust Orthod J.* 2013;29(2):217-21.

- [52] Almeida RR, Almeida MR, Oltramari-Navarro PV, Conti AC, Navarro Rde L, Souza KR. Serial extraction: 20 years of follow-up. *J Appl Oral Sci.* 2012 Jul-Aug;20(4): 486-92.
- [53] Baume, L. J. Cephalo-facial growth patterns and the functional adaptation of the temporo-mandibular joint structures. *Eur Orthod Soc Trans*, 1969: 79–98.
- [54] Calvert, F. J. () An assessment of Andresen therapy on Class II Division I malocclusion. *Br J Orthodk* 1982; 9: 149-153.
- [55] Hamilton, S. D., Sinclair, P. M. & Hamilton, R. H. A cephalometric, tomographic and dental cast evaluation of Frankei therapy. *Am J Orthod.* 1987; 92: 427-434.
- [56] Pancherz H. A cephalometric analysis of skeletal and dental changes contributing to Class II correction in activator treatment. *Am J Orthod* 1984;85:125-134
- [57] Mills C, McCulloch K. Treatment effects of the Twin-block appliance: a cephalometric study. *Am J Orthod* 1998;114:15-24.
- [58] Windmiller EC. Acrylic splint Herbst appliance: cephalometric evaluation. *Am J Orthod Dentofac Orthop* 1993;104:73-84.
- [59] Baccetti T. et al. Treatment timing for Twin-block therapy. *Am J Orthod dentofacial Orhop* 2000;118:159-70.
- [60] Usumez S, Uysal T, Sari Z, Basciftci FA, Karaman AI, Guray E. The effects of early preorthodontic trainer treatment on Class II, division 1 patients. *Angle Orthod.* 2004 Oct;74(5):605-9.
- [61] Uysal T1, Yagci A, Kara S, Okkesim S. Influence of pre-orthodontic trainer treatment on the perioral and masticatory muscles in patients with Class II division 1 malocclusion. *Eur J Orthod.* 2012 34(1):96-101
- [62] Hanoun AB, Khamis MF Mokhtar N. The effectiveness of the prefabricated myofunctional appliance T4FTM in comparison with Twin Block (TB) appliance in the treatment of Class II Div.1 malocclusion. A randomized clinical trial. Master thesis. School of Dental Sciences, University Science Malaysia, 2014.

