

---

# Narrow Diameter and Mini Dental Implant Overdentures

---

Elena Preoteasa, Marina Imre, Henriette Lerner,  
Ana Maria Tancu and Cristina Teodora Preoteasa

Additional information is available at the end of the chapter

<http://dx.doi.org/10.5772/59514>

---

## 1. Introduction

Complete dentures are most frequently a challenge for practitioners. The complexity of this disease is often associated with general health problems, but also with the physiological ageing phenomenon, that increases the treatment difficulty. Completely edentulous patients, usually elderly, often complain about the functionality of conventional dentures, especially the mandibular ones, claiming their instability, poor retention and discomfort during wear.

Following the development of public health programs, a beneficial effect was found in terms of percentage decrease in the number of completely edentulous patients, but this was partially offset by the increased life expectancy. Consequently, complete edentulism remains a frequent medical condition that needs to be addressed through treatment alternatives that meet the needs of modern man. This aspect is integrated in the current medical perception that highlights the importance of an active aging process, with preservation of elderly participation in social and economic activities [1]. Additionally to population aging as a demographic trend, changes in the dental field have also occurred, related to the use of dental implants and implant prosthesis, but also to patients' perception and expectations regarding the prosthetic rehabilitation, demanding more stable, functional and aesthetic prosthesis.

Complete maxillary and mandibular dentures have been for over 100 years the standard treatment of complete edentulism. If complete maxillary denture wearers tolerate better the complete dentures, given the better conditions for support, retention and stability, the tolerance of mandibular prosthesis is generally lower. The relatively frequent instability of the mandibular denture, poor retention and associated discomfort were the starting point for the

idea of setting the overdenture on 2 implants as first treatment alternative for the mandibular complete edentulism (according to McGill and York consensus) [2, 3, 4].

## 2. Concept of implant overdentures

Implant overdentures are inspired, as treatment concept, from the of the overdentures, the dental implants being used instead of tooth roots. If for teeth overdentures the attachment systems are optional, for the implant-supported ones they become mandatory. Therefore, the structural components of implant overdentures are the prosthesis (partial or complete overdenture), the dental implants and the attachment system. Using dental implants mainly aims to increase retention and/or to provide support for the prosthesis.

Considering the relation between the structural components of the implant overdentures, their interaction with the oral structures and functions, the biomechanical aspects, all with impact on implants survival and treatment success, numerous treatment options and concepts have been developed. These differ in various aspects, such as the design of the dental implants used (as diameter - conventional, narrow or mini dental implants, as length), as implant number, as technique of implant placement and loading, as attachment system, as prosthesis design and as their effect on the prosthesis balance, retention and patients satisfaction [5]. Regardless of their type, implant-supported overdentures bring a number of benefits compared to the conventional dentures, by increasing their stability and retention, improving the mastication and phonation, and ensuring a physical and psychological comfort.

Dental implants that are used for implant overdentures are made of high-strength alloy (Ti-Al-V), with good biocompatibility, with different designs and sizes that aim to address the prosthetic needs according to the oral particularities and clinical limitations of its execution. The first implants that were introduced in the dental practice were the ones with standard diameter, around 3.75mm. Later on, their diameter was increased and decreased (narrow), ranging between 3 and 6mm. Afterwards, the mini implants with one-piece design for implant overdentures appeared (IMTEC, later 3MESPE), with diameters of 1.8mm, 2.1mm and 2.4mm.

Using dental implants with a diameter under the conventional one has increased, aspect related to the extension of their clinical indications. These were firstly used for temporary retention of the interim prosthesis and for orthodontic anchorage. Nowadays there is an increased use of them for prosthesis stabilization.

Dental implants with a diameter below the conventional one, are classified mainly on their diameter, or design (i.e. one piece/two piece). Thus, implants with a diameter below the conventional one have been classified by some authors as narrow-diameter implants (3.0 to 3.5 mm) with smaller implants (3.0 to 3.25 mm), and mini-implants (<3.0mm) [6]. The mini-implants are sometimes divided in hybrid implants (2.7 to 2.9 mm) and mini implants (1.8 to 2.7mm).

**Conventional Diameter Implant Overdentures (CDIO)** use two-piece implants, with usually two-stage placement protocol, with larger diameters (over 3.5mm) and variable lengths

(8-16mm), in a number of minimum two for the mandibular overdenture. Its implementation requires wide ridges (over 5-6mm), condition that rather often is not met in the aged edentulous patients, therefore bone augmentation, supplemented sometimes by sinus lift being required. The protocol of conventional implant placement is with or without a flap, usually involves two phase surgery (one for implant placement and one for removal of the cover screw and abutment placement), with delayed implant loading, after the implants osseointegration (after 3-6 months). As prosthetic parameters and attachment selection, conventional implants have a wider spectrum of indications and treatment options. Implants can be splinted with bars as attachment systems, or be used unsplinted, with ball, locator, magnets and telescopes. When selecting the attachments, one must take into account the prosthetic space, as well as patient's manual dexterity and the degree of oral hygiene.

**Narrow Diameter Implant Overdenture (NDIO)** represents a category of implants that combines features from conventional implants and mini implants, with diameters between 3 and 3.5mm and variable lengths (10-18mm), comprising two distinctive subgroups, namely two-piece design (e.g. Seven Narrow Line implants, MIS Implants Technologies Inc. 18-00 Fair Lawn Ave. Fair Lawn, NJ 07410, UNITED STATES, mini Sky 2, Bredent Medical GmbH & Co, Germany, Straumann implant, Straumann Group SIX: STMN, Basel Switzerland) and one-piece design (e.g. uno line, MIS implants). Two-piece narrow implants can be used as the conventional implants (with delayed loading), or as one-piece mini implants (with immediate loading protocol). In relation to anatomical, functional and prosthetic case particularities, the number of dental implants used can be reduced, similar to that of the conventional implants (e.g., two narrow implants for the mandibular overdenture).

**Mini Dental Implant Overdentures (MDIO)** use mostly-one piece dental implants (miniSky1, Bredent, MDI 3MESPE) with diameters between 1,8mm and 3mm and variable lengths (10mm-18mm), that require one-stage surgery for implant placement, followed by prosthesis application in the same appointment, with soft material in the housing area (progressive loading) or fixation of the matrices in the denture base (immediate loading). Within the mini implants, those with a diameter between 2.7 and 3mm are classified as hybrid implants, these having sometimes a two-piece design and can be used as narrow dental implants (e.g., two narrow implants for the mandibular overdenture).

The main features of the overdentures on dental implants with a diameter below the conventional one, considering their three main categories according to their diameter, are synthesized in table 1.

The decision to use either a CDIO, NDIO or MDIO as treatment for complete edentulism, starts from the acknowledgment of patient's preferences and expectations, within the limitations of the systemic and oral health-status. In systemic alterations with indications of limited surgery or that negatively affects the healing process, NDIO and MDIO are more indicated than CDIO, due to their reduced invasiveness. Oral particularities, such as the anatomical conditions (bone quality and quantity, the shape of the alveolar ridge, skeletal class), thickness and health of the oral mucosa (e.g., denture stomatitis, candidiasis), available prosthetic restorative space (especially as vertical dimension, given the necessary space for abutment, attachments and

prosthesis thickness, in order to prevent its fracture) should all be considered when choosing between the implant prosthesis alternatives.

	<b>Conventional implant overdenture(CDIO)</b>	<b>Narrow diameter implant overdenture (NDIO)</b>	<b>Mini dental implant overdenture (MDIO)</b>
Implant's diameter	>3.5mm	3.5 – 3.0 mm 3.0- 3.25 mm (smaller)	2.9-2.7mm (hybrid) 1.8mm – 2.7mm
Implant's length	> 8mm	> 10mm	> 10mm
Design	Two-piece implants	One- and two-piece implants	One-piece implants and two-piece (hybrid)
Number			
Maxilla	Minimum 4	Minimum 4	Minim 6 (minimum 4 for hybrid implants)
Mandible	Minimum 2	Minimum 2	Minimum 4 (minimum 2 for hybrid implants)
Surgery	Usually two-stage implant placement protocol	One- or two-stage implant placement protocol	One-stage implant placement protocol
Loading	Usually delayed loading	Immediate or delayed loading	Immediate loading
Overdenture support	Soft tissue and implant support	Soft tissue-support	Soft tissue-support
Overdenture design	Open palate maxillary denture	As a conventional complete denture	As a conventional complete denture
Attachment system	Splinted implants (bar) and unsplinted (ball, locator, magnets, telescope)	Unsplinted (ball, locator, magnets, telescope)	Unsplinted (Ball with O- ring)
Aim	improve overdenture retention, stability and support	improve overdenture retention and stability	improve overdenture retention and stability

**Table 1.** Main features of the overdentures on dental implants, in regard to their diameter

Patients with a high risk of developing implant or overdenture-related complications should be identified, and treatment personalized according to their nature. There are conditions with absolute contraindications of surgical procedures (e.g., recent myocardial infarction, stroke, cardiovascular surgery, and transplant; profound immunosuppression; bisphosphonate use, diabetes), but even in these cases the degree of disease-control is far more important than the nature of the systemic disorder itself [7, 8]. Behavioral aspects may increase some complication rates (e.g., implants are not indicated in heavy drinkers or smokers, more than 10 cigarettes per day). In patients with decreased manual dexterity or coordination deficiencies alternatives

that promote simpler plaque control and easier overdenture placement and removal should be chosen (e.g. ball attachments are preferred to bars). Bruxism or other parafunctions with occlusal overloads associates high occlusal loading that increases the risk of implant failure, in this cases more frequent check-ups and sometimes the increase of the implant number are required. When more than two implants are used, there is a higher risk of overdenture fracture, and the reinforcement of the overdenture base is recommended [9].

The patient's expectations towards the prosthetic outcomes must be assessed in terms of functional restorations, esthetics and prosthesis retention. It is recommended to acknowledge the patient's perception and reasons of dissatisfaction toward the previous prosthesis, in order to correctly evaluate and inform him about the benefits of each particular type of implant overdenture. Additionally, financial aspects need to be explained to the patient, as comparative analysis of the additional costs of each treatment alternative, putting them in balance with the treatment benefits.

### **2.1. Concept of Mini Dental Implant Overdentures (MDIO)**

Based on similar principles of overdentures with roots or conventional implants, using mini implants for overdenture has been suggested, as an alternative with advantages such as the less invasive surgical interventions with lower risks and lower costs, but with similar results [10, 11].

Implant overdentures are nowadays increasingly preferred to conventional dentures. Patients are more informed about the benefits of implant prosthesis, more frequently request and accept these treatment alternatives. The significant improvement in denture retention, with rapid regaining of functionality after implant placement, is an important motivating factor. The surgical and prosthetic techniques are significantly simplified, being more widely used one-stage implant placement protocol, with immediate loading, becoming a less invasive treatment that promotes rapid healing and has good treatment outcomes. MDIO fits this prosthetic treatment trend, and is seen as an appropriate option for the elderly edentulous, implants having a survival rate between 88.5% and 96%, higher in the mandible than in the maxilla [12, 6, 13]. Their use is increasing in relation to the relatively frequently reduced ridge width in the edentulous patient, that often limit using conventional implants without extensive surgical procedures for augmentation, that are usually not easily accepted, especially by the elderly patients [14].

Biomechanical studies support the use of narrow and mini implants, but draw attention to their increased risk of fracture, which should be considered. The decrease of implant diameter does not affect the implant osseointegration. Block et al. analyzed the effect of implant diameter on the pullout force required to extract the implant and proved that, after 15 weeks for osseointegration, no correlation was found to its diameter, but only with its length [15]. Clinical studies confirm that short implants were often accompanied by failure, but narrow implants have a good prognosis [16]. Therefore the narrow and mini implants used for overdenture should have at least 10mm length, in relation to their diameter, but also to the bone's height.

Given the good results obtained in vivo and in vitro, narrow and mini implants, seem to be the successors of conventional diameter implants in overdentures. Mini dental implants were originally designed by Victor Sendax [17]. At first they had diameters between 1.8- 2.4 mm, and were used for stabilization of interim prosthesis during implant osseointegration, stabilization of occlusion rims and for orthodontic anchorage. Afterwards, histological studies confirmed that these implants osseointegrate and clinical studies acknowledge a high survival rate, of about 83,9 to 97.5% [18]. Consequently, their usage expanded for definitive prosthesis both fixed (for single narrow edentulous spaces) and removable (for partial and complete denture stabilization). Mini implants, as endosseous implants, are indicated to complete edentulous patients with narrow ridges, where the prosthetic treatment on implants is chosen, but reduced surgical invasiveness is beneficial, for example for those with general systemic risk factors [6]. It is particularly suitable for elderly patients, with multiple comorbidities and a low income, and who often do not accept complex and expensive dental interventions.

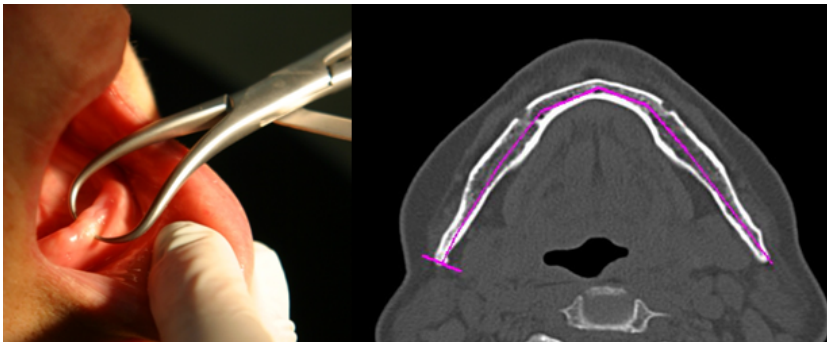
The mini implants have a number of features that have to be known and considered, both when it comes to selecting the implants, as well as during the treatment phases. Thus the mini dental implants are most commonly one-piece implants, with reduced diameter, conventional length, tapered, self-threading, made of biocompatible titan-based materials, with rough sandblasted surface treated by acid. IMTEC (currently part of 3M ESPE) developed mini dental implants with a diameter of 1.8mm to 2.4mm, supplemented recently by those with a diameter of 2.9mm (indicated especially in the maxilla), and with lengths of 10, 13, 15 and 18 mm. These implants have been designed differently, with 2.5mm transgingival collar (for thick gingiva) or without it (for thin gingiva). The upper surface of the endosteal dental implant may be polished and remain outside the bone within the mucosa, but the rough surface must be placed within the bone. Regarding the implant thread, it may be standard for D1 and D2 Misch bone densities (usually encountered in the mandible), or Max Thread, for D2 and D3 bone density (most frequently encountered in the maxilla) [19]. The implant prosthetic element, the abutment, has a spherical design like the ball attachment system, with an overall height of 4mm or 6 mm. Its gingival part has a square-profile section, with or without transgingival collar, which must remain outside the mucosa for at least half of its length. The attachment system is O-ring type, a resilient retention device composed of a metal matrix and a rubber ring, available in the following three options:

- standard: provides strong retention and tolerate a divergence of implants up to 30°;
- micro: has a 30% lower height than the standard matrix, offers an advantage for reduced prosthetic restorative spaces, provides a higher retention and compensates less for the implant divergence;
- O-Cap: provides extra-firm retention, mini-implants should be placed almost parallel, being used with delayed implant loading.

Therefore, the main coordinates of mini implant selection, according to the case particularities, are the following:

- Implant number: at least 4 in the mandible and at least 6 in the maxilla;

- Implant size, as diameter and length, is chosen according to ridge width, bone height and bone density. Usually, smaller diameter implants, of 1.8-2.1mm are used in the mandible, in bone with D1 and D2 Misch density, and mini implants with diameter of at least 2,4mm are recommended in D3 bone density in the maxilla. Implants should have a diameter with at least 2 mm less than the width of the ridge, which can be assessed using a clinical compass, or subtracting from the clinically measured width minimum 2mm corresponding to the mucosa thickness (Figure 1). The implants' length is chosen according to the bone height (at least 2 mm less than the bone height), which can be approximated by overlaying the specially designed grid on the panoramic radiography;
- Choosing between mini implants according to thread design is related to bone density (standard in the mandible and Max Thread in the maxilla);
- Choosing between mini implants with or without transgingival collar is related to the mucosa thickness.



**Figure 1.** Clinical and radiological assessment of bone width

In case of MDIO, implants are placed without extensive augmentation procedure, through a less invasive surgical procedure, considering the anatomical limitation. In the mandible, mini implants are placed in the interforaminal region (7mm anterior to the mental foramen, to prevent damaging the inferior alveolar neurovascular bundle), and in the maxilla, anterior to the maxillary sinuses (protecting both the maxillary sinus and the nasal fosses). Within the mandible, when the mandibular canal is making a loop and the bone height allows it, implants can be placed behind the mental foramen. When placing the implants, it is recommended to keep a distance of at least 4.5 mm between them.

Most of the companies that produce implants are usually making available a line of implants with different diameters, and, for the same diameter, different corresponding implants lengths. Some of them, as mini Sky1 (Bredent Medical, Germany), that are hybrid implants, ensure a simpler implant selection and implant placement related to the implant options that differ only by implant length (10mm, 12mm and 14mm, and have the same diameter of 2.8mm, are identical as endosteal and abutment design) and have all the same simple implant placement

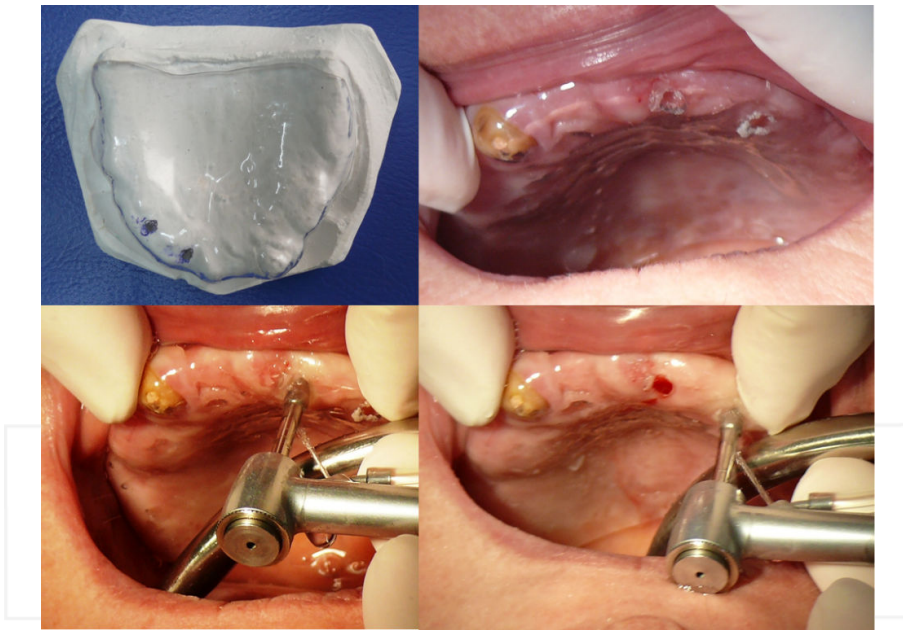


protocol (only two drills are needed). Using hybrid implants allows, according to the bone quality and prosthetic needs, the reduction of the implant number (e.g., in the mandible only 2 mini Sky1 hybrid implants can be used instead of 4 mini implants with a diameter of 1,8-2,5 mm). Compared to the surgical implant kit of conventional denture, the one for mini implants is usually considerably simpler, containing fewer components (basically 1 or 2 drills for implant osteotomy and 2 ratchets), promoting a reduced time of the surgical phase, beneficial when considering this is a major stress for the patient.

Treatment with MDIO includes a surgical phase (implants placement) and a prosthetic phase (transformation of the denture in overdenture), both conducted in one clinical appointment.

Before implant placement some simple preoperative interventions are required, such as instruction and motivation on maintaining proper oral hygiene (antibacterial mouthwash as Chlorhexidine may be recommended), with prophylactic antibiotherapy and sedation.

For mini implant placement local anesthesia is sufficient, and a flap or flapless technique can be used, with or without a surgical guide (Figure 2).



**Figure 2.** Implant placement using a surgical guide

For the flapless technique, the implant site is marked and the cortical bone is pierced with the same small size drill. Flap technique (Figure 3) is recommended in cases with thick mucosa or flabby ridge in order to properly assess bone offer, or in cases where 1.8 mm implants are to be placed into 3 mm narrow ridges. Initial implant osteotomy should be performed with a pilot



drill with a diameter smaller than the one of the implant, in order to obtain bone condensation. Considering the positive effect of bone tapping on osseointegration, osteotomy depth varies according to bone density, about 2/3 of implant length for D1 bone density, about 1/2 of implant length for D2 bone density and about 1/3 of implant length for D3 bone density. Also, abundant irrigations with refrigerated sterile saline solution are mandatory. Implant placement should be done using slow movements, especially in high density bone, in order to avoid the heat trauma created by friction that may cause harmful effects in the bone (necrosis by heating) and also the implant fracture, which is more frequent in mini implants due to their decreased diameter. The self-tapped implant is placed and advanced into the bone by hand ratchet or headpiece and must be operated slowly, without extreme pressures. When screwing with the ratchet, the left hand finger is onto the ratchet in the mini implant's axis and the pressure is created with the right hand only on the ratchet arm, in the direction pointed by the arrow. The optimum value for the insertion torque is 35Ncm and should not exceed 45Ncm. If during the mini implant placement the torque exceeds 45Ncm it is recommended to unscrew the implant and expand the osteotomy, as depth or diameter. The implant body should be fully inserted into the bone.

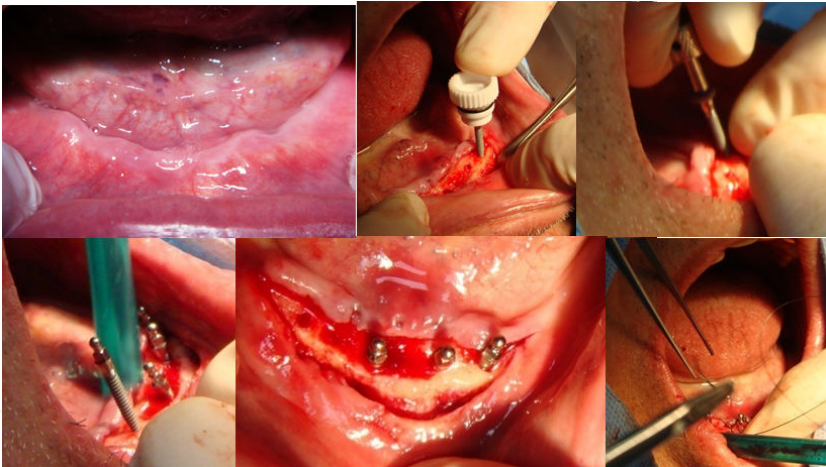


Figure 3. Mini implant placement, using a flap technique

In case of MDIO, for immediate loading, a good primary stability of the implants is required, which is related to the implant insertion torque (minimum 30 to 35 Ncm; in this respect, unfavorable situations are more frequently encountered in the maxilla, and are very rare in the mandible), bone compression and anchorage in the cortical bone. For immediate loading of the implants it is necessary to have a complete denture before the implants insertion that will be transformed into the overdenture, either as the old or newly manufactured prosthesis.

For immediate loading, the attachment caps, which contain rubber O-rings, are placed on the implants. The first clinical step is to remove the acrylic material from the inner part of the

overdenture base, in the area corresponding to the implant site, quantitatively until the overdenture passive fits on the overdenture-bearing area. Fixing the housings can be done directly (by the dentist in the clinic) or indirectly (by the dental technician, in the laboratory). For housing fixing in the clinic, isolation of the gingival part of the implant abutment is done with latex materials (as piece of rubber dam or medical gloves), in order to prevent the acrylic material penetration under the O-ball head. Metal housings are placed combining rotational movements and pressure, until they fit passively. Preparing the prosthesis consists of repeatedly marking each matrix site accompanied by acrylic material removal from the corresponding denture base area. It is recommended to verify passive fit using soft silicone materials as Fit checker (GC Corporation). Afterwards, definitive metal housing fixation is done intraorally with acrylic materials, in centric occlusion. For a more accurate reproduction, before implant placement an occlusal registration can be taken and can be used during this treatment phase. Finally it is recommended to perform an accurate polishing of the denture around the metal matrices, in order to prevent plaque accumulation that favors occurrence of peri-implant mucositis and peri-implantitis.

If the insertion torque is less than 35Ncm, the primary stability is not sufficient for immediate loading. Therefore, it is recommended to use progressive loading through the usage as soft lining material such as matrices during the osseointegration phase, and also to ensure weaker occlusal load in the area corresponding to the implant site. Metal housing fixation is recommended to be done after 3 to 6 months after implant placement.

A very important aspect is to verify, during the osseointegration period, the occlusion, the overdenture stability and the prosthesis of the antagonist jaw, as key elements for ensuring a good treatment prognosis.

Rubber O-rings are a part of the attachment system that wear-out over time and must be checked and periodically replaced in relation to loss of retention. Associated to the unavoidable alveolar bone resorption, denture relining or renewal are necessary over time. If overdenture renewal is desired, abutment analogues are used during impression.

MDIO has many advantages for older patients, often complete denture wearers that are dissatisfied with its retention and stability. Thus, through a reduced invasiveness surgical procedure, which requires less clinical time, with average costs, in a single session, a removable prosthesis with a good stability and with immediate functional integration can be achieved, providing the mental and physical comfort in order to carry out current social activities. At the same time, this treatment option has the advantage of an easy maintenance of oral and denture hygiene, through the unsplinted implants, an important aspect especially for elderly people, with frequent deficiencies when it comes to manual dexterity.

## **2.2. Concept of Narrow Diameter Implant Overdentures (NDIO)**

The growing popularity of MDIO associated a general increase in the usage of implant overdentures among elderly completely edentulous patients. This is due to the clinical success of MDIO, the increase of its acceptability among edentulous patients, and the possibility for dentists to use it without extensive training in oral implantology (implant placement require

one surgical intervention, relatively easy to perform. Within completely edentulous patients, narrow alveolar ridges are very common, mini and narrow implants being advantageous considering that they can be used without bone augmentations or other extensive surgical procedures, such as ridge splitting technique, being more easily accepted by elderly patients. At the same time, it is undeniable that the use of conventional diameter implants has numerous advantages, such as a reduced risk of implant fracture, reduced stress peaks at the implant-bone interface, the possibility to reduce the number of implants and the use of attachments according to the prosthetic needs, with different retention degrees [6]. Subsequently, the concept called NDIO has developed, which uses implants with a diameter between the conventional and the mini dental implants, and is partially similar to both MDIO and CDIO. Narrow diameter implants with diameters between 3 and 3.5 mm, designed initially for fixed restorations of narrow edentulous spaces, expanded their use for implant overdentures. These can be found in different options, as size (implants with diameter between 3.0 and 3.25 are named sometimes small implants) and design (one- or two-piece implants, with different attachment systems).

NDIO, as treatment alternative has particularities common to both CDIO and MDIO, such as:

- Like the MDIO, it is mainly indicated in cases with narrow ridges (1.5-2 mm more than implant diameter) and resorbed ridges;
- Surgery is usually minimally invasive, similar to MDIO (without bone augmentation, possibility to use flapless implant insertion technique);
- The implant number can be reduced compared to MDIO, being similar to that of CDIO, due to the increased implant diameter;
- Narrow implants can be loaded immediately or delayed, depending on bone density, insertion torque, primary implant stability, being possible to use previous dentures or the ones manufactured after implant placement;
- Two-piece narrow implants allow insertion into bone with a lower density with delayed loading after 3 to 6 months, similar to CDIO;
- Two-piece narrow implants usually can be used with different attachment systems, with different retention degree, resiliency and possibility to compensate implant divergence (e.g., Locator can compensate up to 40° implant divergence);
- When compared to mini dental implants, narrow dental implants have a lower fracture risk, due to the larger diameter;
- NDIO, like MDIO, compared to CDIO, require reduced clinical time, reduced surgery (as number of appointments and complexity of the procedures), which favors a faster healing process and patient's comfort, reducing the biological and financial costs and overall being a more suitable treatment alternative for the elderly.

Narrow dental implants have diameters of 3 to 3.5 mm and are available in one- or two-piece design. Using the two-piece implants has the advantage of choosing to use either immediate or delayed loading, and for the latter either subgingival or transgingival healing. They may be

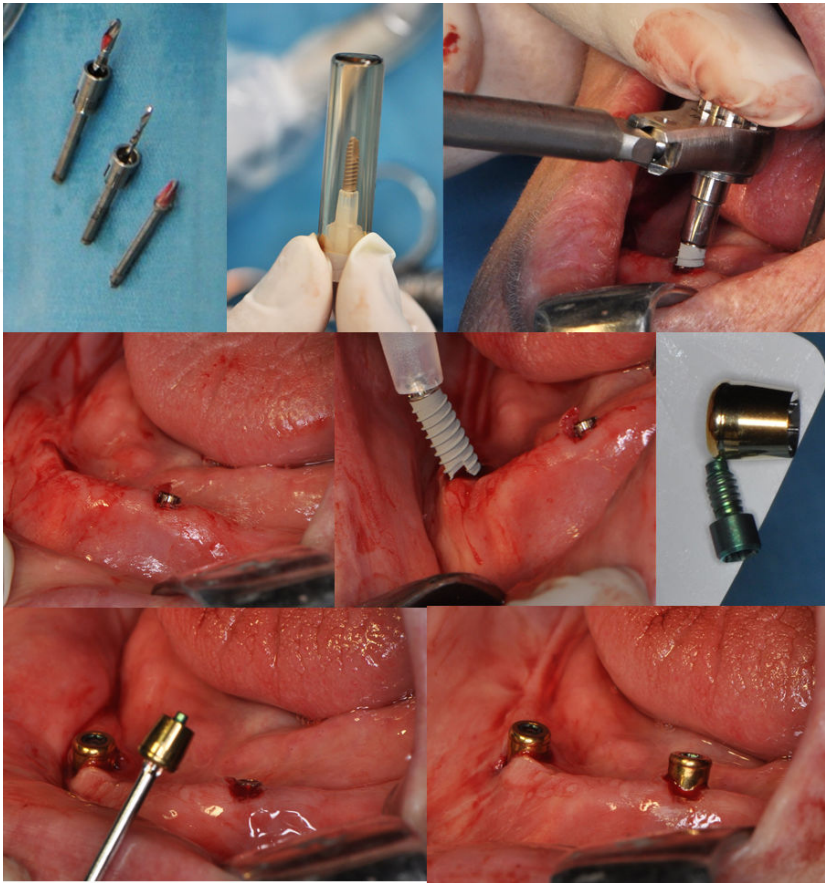
placed flap or flapless, the latter the disadvantage of a less reliable assessment of the bone offer, but the advantage of promoting a faster healing. Usually, using a two-piece implant associates the possibility to choose from several attachment systems, and therefore a better treatment individualization, according to biomechanical and functional features, is available.

The increased interest towards implants designed for stabilization of the removable prosthesis is justified by the high prevalence of edentulism, which is usually treated by conventional complete dentures, alternatives that rather often have stability and retention deficiencies, problems that are more and more perceived as being unacceptable. In addition to this, more often cases with a high degree of treatment difficulty (mainly related to changes related to previous removable prosthetic treatment, as severe ridge resorption) are encountered and concerns are related to the increase of the age when edentulism occurs, that associates difficulties in generally adapting to new, and particularly to new prosthesis. Therefore, the increased use of narrow and mini implants is related to the reduced treatment invasiveness correlated to the functional benefits, which is a very important aspect for the elderly, population category in which most of the edentulous patients are encountered.

Treatment of edentulism with implant prosthesis is frequently accompanied by difficulties related to the limited bone offer – as a result of buccal or lingual bone resorption (narrow ridges) or as apical bone resorption (resorbed ridges). Narrow ridges are more often encountered in skeletal class II patients with a hypodivergent pattern. Conventional removable prostheses are barely tolerated by patients with sharp ridges (sometimes associated with irregularities such as exostosis, with thin covering mucosa, sensitive to pressures) or with severe ridge resorption and imprecise peripheral boundaries, situations which are encountered mainly in the mandible. Most of the completely edentulous patients that are denture wearers have severe ridge resorption, which associates difficulties both for conventional denture (through decreased support area) and CDIO (bone offer is insufficient for placement of conventional implants). Between these two treatment alternatives there are MDIO and NDIO, and when appropriate, the latter is preferred due to preserving the benefits of the first and having other important advantages (e.g., as stated before, a lower risk of implant fracture, possibility to use a reduced number of implants).

NDIO is found as a treatment option with indications similar to MDIO, in cases with narrow alveolar ridge, but it is a suitable treatment alternative also in cases of increased ridge resorption, associated with denture intolerance. Similar to MDIO, for NDIO implant diameter should be chosen according to ridge width (the ridge width should be at least 2 mm larger than the implant's diameter). NDIO are more indicated than MDIO in the maxilla, as a preventive mean, considering that the survival rate of implants is lower in the maxilla than in the mandible. NDIO versus MDIO has the advantage of the possibility to use a smaller number of implants, for example for the mandibular prosthesis 2 narrow implants can be used instead of 4 mini implants (Figure 4).

Implant placement is similar for the one-piece narrow implants to that of mini implants, and for the two-piece narrow implants to conventional implants. The surgical kit includes a reduced number of drills and ranches, which should be used according to the manufacturer's instructions. In two-piece implants a one- or two-stage protocol can be used, that depends



**Figure 4.** Narrow implant and Locator placement

mostly on the implant's primary stability. Therefore NDIO, compared to CDIO has the advantages of less surgical invasiveness and its associated benefits, overcoming some deficiencies of MDI, while preserving its advantages (good retention and stability of the overdenture, easy maintenance) [20].

Prosthesis execution differs according to the type of narrow implant used and coordination of treatment planning. Thus, when using one-piece narrow implants with one-stage surgery the process is similar to the one used for MDIO. When an attachment system with increased retention is used, like the Locator, it is recommended to use soft acrylic or silicone material as matrices during osseointegration. In this regard, silicone materials with different retention levels were developed, such as Retention.Sil (Bredent) that has 3 options according to the detachment force desired (200, 400, 600 gf). When using two-piece narrow implant with two-stage surgery, after osseointegration, the healing abutment is uncovered by a new surgical



procedure, and replaced with the attachment, followed by the procedures needed in order to transform the denture into the overdenture.

### 3. Clinical phases of MDIO and NDIO

NDIO and MDIO are treatment options for complete edentulism, usually aiming the stabilization of the removable prosthesis. Alveolar ridge resorption, modifications of the muscle insertions and muscle tonus, neuromuscular coordination and control deficiencies increase treatment difficulties and favor occurrence of ill-fitting dentures, its retention and balance deficiencies being possible to be addressed through an implant overdenture. NDIO or MDIO have usually a mucosal support, not an implant one, the attachments only aiming to increase overdenture retention and stability. As clinical phases MDIO and NDIO are mostly similar, differences being encountered especially between one- and two-piece implants, when used with one or two-stage surgery.

**Patient evaluation.** Before implant placement, an accurate analysis of oral and systemic status is required. Although mini or narrow implant placement is done through surgical procedures with reduced invasiveness, the absolute contraindication should be accounted (e.g., recent myocardial infarction or stroke, profound immunosuppression, radiotherapy or bisphosphonate use) [7, 8]. Oral particularities should be accurately acknowledged through clinical and radiological examination, as anatomical and functional aspects. Considering the implant placement, ridge width should be evaluate by computed tomography or by clinical means (as using a clinical compass), the latter being sometimes confirmed by direct assessment during the surgical phase, after flap elevation. Bone height is best established using also computed tomography, but usually in the mandible only a panoramic radiography is used. Mucosa thickness is assessed by probing it with a periodontal probe.

The most commonly used radiological investigation is the panoramic radiography, which provides information on bone size and anatomical limitations (mandibular canal, mental foramen, maxillary sinus, nasal fossae). Computed tomography is indicated especially in cases with severe bone resorption, for an accurate bone offer evaluation and the establishment of implant site. Lateral cephalography can offer important data especially on skeletal relations, which associate anatomical and functional features relevant for treatment planning and prognosis.

**Implants number and size.** Implants are chosen according to the bone offer, the option with higher diameter and length being preferred. The higher the implant's diameter, the better it will resist to lateral forces, the longer it is, the better it will resist to vertical forces. Therefore, in order to compensate the decreased diameter of mini implants and to increase the resistance to lateral forces, a higher number of implants are placed. Usually, for mini implants 4 MDI in the mandible are placed between the mental foramens and 6 in the maxilla, anterior to the maxillary sinus. For hybrid and narrow implants their number may be reduced (2 in the mandible, 4 in the maxilla), related to the higher diameter. Bone density influences implant



size selection. Therefore, 1.8 mm diameter implants can be placed in bone with D1 and D2 density, but an increased diameter, of 2.4 mm, is recommended for D3 bone density.

**Implant placement.** Mini- and narrow-implants are placed through a surgical procedure that is usually considered as having decreased invasiveness, and can be performed by a general dentist.

MDI and NDI insertion can be done with or without a surgical guide. The last option has the advantage of a more accurate positioning of the implants, in accordance with prosthetic aspects. Using a surgical radiological guide, manufactured based on the existing prosthesis, allows an accurate establishment of the most distal implant site, preventing the damage to anatomical proximity structures [21].

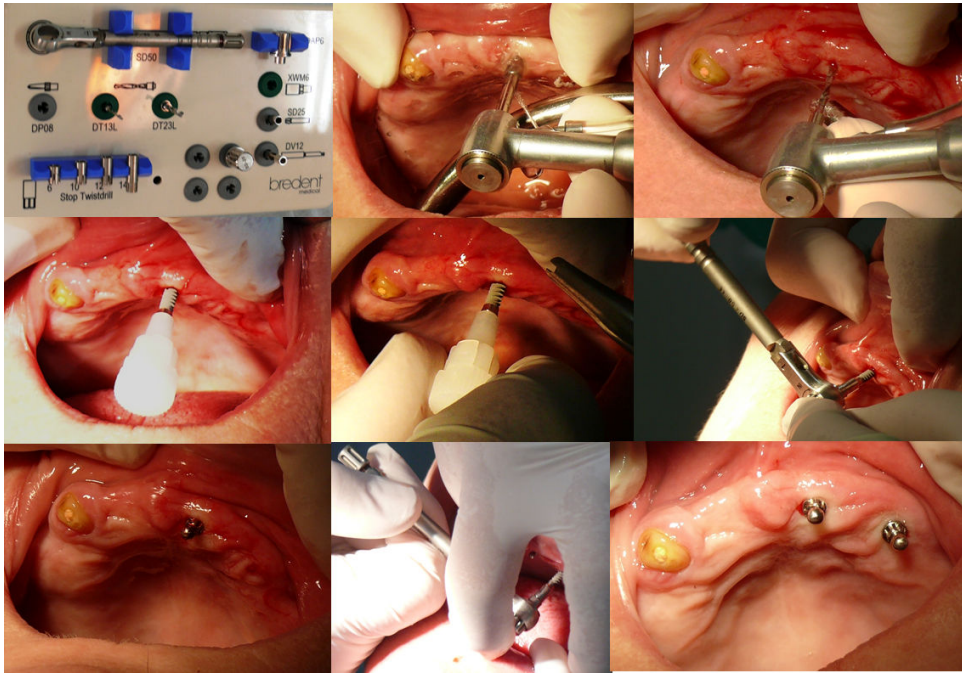
Mini and narrow diameter implants, by their design, associate bone condensation during implant placement, which favors a good primary stability. Screwing of the implant should be done slowly, with the ratchet, while performing manual control, in order to feel "the saturation point" and to avoid implant fracture.

Flap or a flapless technique may be used for mini and narrow implant placement. The flap technique, the most commonly used, has the advantage of directly visualizing the alveolar bone volume before the osteotomy, the possibility to reshape the bone and soft tissue. As a disadvantage, it is more invasive and prolongs the duration of the surgical phase, recovery and healing phase. Flapless technique is mostly done transmucosally, being a less invasive intervention, ensuring a more rapid healing, with a lower degree of patient discomfort (Figure 5). By not disturbing the periosteum layer, there is a higher chance, compared to the flap one, to maintain the alveolar bone levels [22, 23].

Last but not least, the decision to either use a flap or not is up to the practitioner, according to patient's particularities, but also to the clinician's surgical and prosthetic skills [24]. The flap technique is recommended especially when interventions are needed in order to remodel the bone support (e.g., irregular alveolar bone; reduction of bone height needed due to insufficient prosthetic space) and when direct visual access is required (e.g. flabby ridge). The flapless technique is indicated when the bone width is adequate, the ridge shows no exostosis or alterations that require surgical correction, it is preferred when using immediate loading and in patients with systemic diseases that limit the extent of surgery or interfere in the healing process [24].

**Implant loading protocol.** Placement of mini- or narrow-dental implants can be followed by immediate-, progressive- or delayed-loading protocol, depending mainly on the implant primary stability

Immediate implant loading protocol is used when insertion torque is above 40Ncm, for D1 or D2 bone density, being a more commonly encountered in implants placed in the mandible, in the interforaminal area, especially when a flapless technique was used. In this regard previously made prosthesis are used, which are adjusted to the new situation, followed by the fixation of the matrix in the overdenture base. Occlusion analysis should be performed, considering these alterations can have a negative impact especially in the vulnerable period of osseointegration.



**Figure 5.** Hybrid implants placement, using a flapless technique

Progressive implant loading is recommended for D2 bone density and in cases with slower healing process after surgery, such as in flap techniques. Basically, for a period of 30 days postinsertion soft resilient acrylic or silicone materials are used as matrices, followed afterwards by the fixation of the matrices into the denture base.

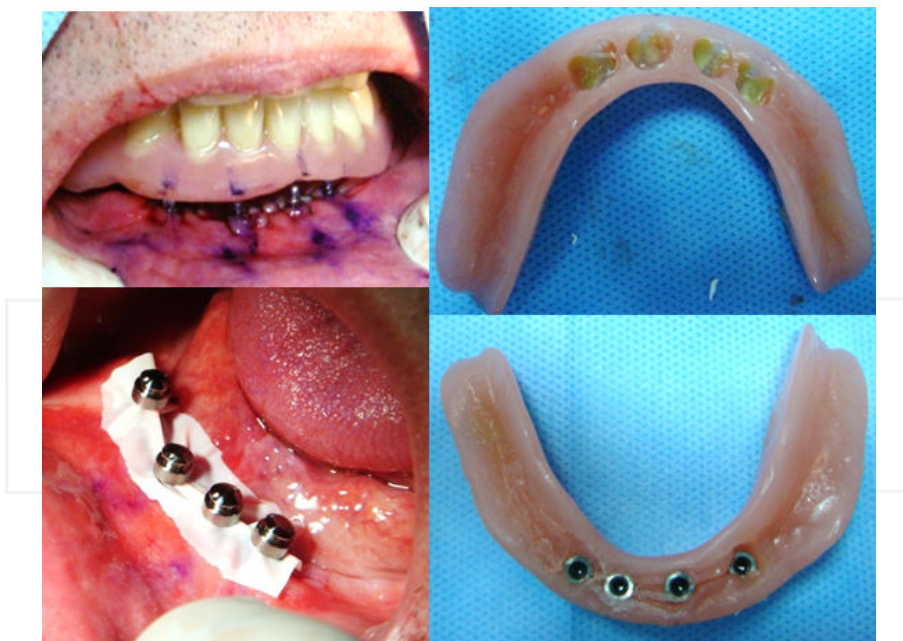In case of immediate and progressive loading, regular check-ups are at most importance during the osseointegration period. The overdenture must be verified in order not to exert direct pressure on the implants (only mucosal support should be noticed), as occlusal relations, as its stability and, if applicable, as the stability of the antagonist denture, as factors that may negatively influence the prognosis of the implant.

Delayed implant loading, performed at about 3 months, is indicated when the insertion torque is under 40Ncm and in patients with D3 bone density. In this case there is an additional surgical step in order to uncover the healing abutments.

**Fixation of the matrices into the overdenture base.** Fixing the prosthetic component of the attachment can be done in the dental office or in the dental laboratory, after verifying the denture correctness (e.g., as teeth mounting, occlusal relations, denture base extension, aesthetic and functional outcome, material status). One of the main advantages of NDIO and MDIO is related to the possibility of preserving the previous prostheses, this being related mainly to the denture correctness and patient preferences. Usually the dentures need to be

renewal, most often due their deficiencies, occurred related to the improper execution or as changes in time. Even so, during the osseointegration period it is best to preserve the old denture, relined with resilient material, so that the patient can easily perceive modifications that may have a negative impact, such as the pressure on the implant.

Direct fixation of the prosthetic part of the attachment system, in the dental office, varies according to implant design, i.e. one- or two-piece implant. The clinical procedure for one-piece implants, which usually have O-ring as attachment system, is similar to that used for MDIO, previously described. For two-piece implants, applying the retention systems is different upon the implant placement protocol, i.e. one- or two-stage protocol. For one-stage protocol the procedures used are similar to those applied for one-piece implants, namely in the same clinical appointment with implant placement, the attachment abutment is applied (ball, locator, ferromagnetic metal keeper) and, depending on implant and prosthetic parameters (e.g., implant primary stability, insertion torque, bone density, occlusal loading) either a progressive implant loading (with soft material as matrices), or immediate implant loading (definitive fixation of the prosthetic attachment component, such as metal housing or ring, denture cap, magnet, in the denture base with self- or light-cured acrylic materials) is done. For two-stage protocol, after the osseointegration period, the endosseous implants are surgically uncovered, the healing abutment are replaced by the attachment abutment, and followed by the fixation of the prosthetic attachment in the overdenture base (Figure 6).



**Figure 6.** Direct metal housing fixing, in the dental office

Indirect fixation of the prosthetic part of the attachment system, in the dental laboratory, is mainly used when the overdenture renewal is desired. Correspondent, either impression transfer procedures after attaching the analogue, either impression taken with the prosthetic attachment component placed on the attachment abutment, can be used.

In all situations previously mentioned, overdenture adjustments and verifications are needed in order to achieve only mucosal support, passive fit on the implants and correct registrations of maxillomandibular relationship, without excessive occlusal loading. In the first 72 hours it is recommended to remove the denture only during oral and denture hygiene procedures, being highlighted to the patients the importance of a good plaque control in preventing treatment complications.

Considering that in case of MDIO and NDIO dental implants are applied in order to increase denture's retention and balance, overdenture execution should be done similar to that of conventional denture with a complete coverage of the support area, for ensuring proper retention, support and balance. Furthermore, choosing the occlusal scheme may be an important factor for treatment success, linear and lingualized occlusion being preferred for ensuring a more uniform distribution of the occlusal pressures over the bearing area, recommended especially for the mandibular overdenture. Key factors that ensure a good prognosis of conventional dentures should not be neglected in the case of MDIO and NDIO, such as the correct registration of maxillomandibular relations, at a correct vertical dimension of occlusion and centric relation.

**Frequently used attachment systems for MDIO and NDIO.** These types of implant prosthesis are usually retained by unsplinted implants, with attachment systems that only provide better denture retention and balance, while the prosthesis has only mucosal support. The most frequently used attachment systems are O-ring type, but also other alternatives are encountered, such as Locator, magnets, telescopes (especially double conical crowns, which are less rigid).

O-ring attachment system is used for both one- and two-piece narrow and mini dental implants. O-ring system is encountered in different designs, as the one of mini dental implant manufactured by 3M ESPE (spherical abutment with a metal matrix and rubber ring) or the one of miniSky 1 hybrid implants from Bredent Medical (spherical abutment with a metal ring and rubber ring). The metal matrix are made of Au or Ti, and can be activated, ensuring a different retention level. This attachment system has a resiliency degree, being a semi-rigid type, with positive effect on stress distribution. The system compensates for an implants divergence of about 20°-30°. Due to wearing over time, the rubber rings must be replaced periodically, when not ensuring the proper overdenture retention. This is encountered most frequently in cases with denture deficiencies that contribute to denture instability (e.g., overextended denture flanges, incorrect mounting of artificial teeth, unstable occlusal contacts).

Locator attachment systems, developed later, brought a number of advantages for NDIO. They can be used in cases with decreased vertical prosthetic space (at about 10 mm from the ridge crest to the height of the denture), generally having below 5 mm height with the denture cap in place, value that is below of that of O-ring attachment system. Also, it compensates for a



higher angle of implant divergence, up to 40°. Even so, they are designed for ensuring an internal and external retention, but in order to use both, implants must be placed nearly parallel. If implants are placed under a divergent angle, only internal retention is preserved. Depending on the manufacturer, different alternatives are available according to the level of retention and gingiva thickness.

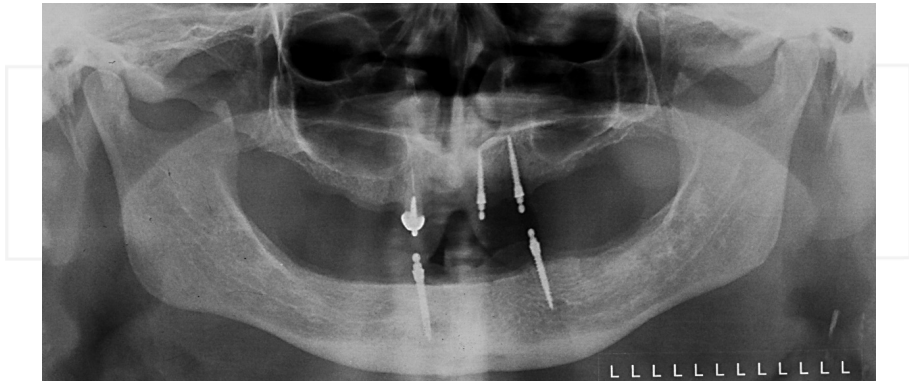


Figure 7. miniSky 1 implant overdentures – radiological examination 2 years after implant placement

#### 4. Advantages and disadvantages of MDIO and NDIO

Implant overdentures, and especially MDIO and NDIO have registered an increased usage, which is probably related to its better treatment outcome, when compared to conventional complete denture. Among others, there can be mentioned beneficial aspects as the increased prosthesis balance and retention (especially for the mandibular denture), the improvement of oral functions (mastication, phonation) and self-confidence, with positive implications on the patient's physical and psychological comfort and on the quality of life.

MDIO and NDIO are particularly indicated in edentulous patients with an increased degree of treatment difficulty, unsatisfied by their conventional dentures (e.g., complaining about denture instability, pain and discomfort during wearing), with systemic alterations that limits the extent of the surgery or that refuse complex, prolonged, expensive medical interventions [25].

When compared to the fixed implant prosthesis, or even CDIO, MDIO and NDIO are simplified implant prosthetic treatment alternatives that have a satisfactory clinical success and are implemented through less invasive surgery, with reduced pain and trauma. These alternatives are well fitted to aged edentulous patients, who frequently have systemic comorbidities that associate a higher risk of complications, and generally have difficulties in accepting complex medical interventions in general, and implant treatment in particular. For these patients, aspects like the reduced invasiveness of surgical procedures, of the

clinical time needed, of postoperative discomfort, additionally to the relatively reduced costs required, are arguments that may convince them to accept the implant restoration. Overall costs are generally rated as being lower for MDIO and NDIO than for CDIO, due to the price differences of mini and narrow implants, the reduced clinical time with avoidance of some procedures (e.g., bone augmentation), the possibility to use the previous complete denture, when it corresponds qualitatively, through complications that are in general relatively easy and cheaper to resolve (e.g., loss of an implant can be solved by applying another one, followed by adjusting procedures to the existing denture; at CDIO using bars, implant loss is usually accompanied by extensive interventions, which almost covers the whole implant-prosthetic treatment).

By improving the denture stability, mastication efficiency increases, promoting a better nutritional status, and the denture detachment during mastication and phonation is reduced, offering the patient a psychological comfort [26]. MDIO and NDIO may be considered preventive treatments for reducing the side effects of ill-fitting conventional dentures, as an accelerated ridge resorption rate [27]. Additionally, one-piece mini implants associate a decreased peri-implant bone resorption compared to two-piece conventional implants, that was linked to the absence of the microgap between the endosseous implant and the abutment, as well as the less physical displacement [28].

MDIO and NDIO require usage of a reduced number of implants, starting with 2 narrow or hybrid implants in the mandible and 4 in the maxilla, placed in most predictable anatomic area (interforaminal area), by simple surgical techniques, which ensures, in case of immediate loading, rapid regaining of functionality. Mini and narrow diameter implants minimize, through their design, the soft tissue and bone damaging, compared to conventional implants, favoring a shorter and better healing and osseointegration [29]. Placing the implants in the anterior maxillary area is beneficial, considering the occlusal load is decreased when compared to the posterior maxillary area, and also the possibility to use bicortical implant stabilization. The survival rate of implants placed in the anterior area of the mandible is high, above 90%, similar to that of conventional implants [30, 31, 32].

Increased use of MDIO and NDIO may be related also to the extended usage of implants the dental field. Also, in the general dental practice an increased surgical placement of implants is observed, probably related to patient's demands. However, the cost for dental practitioners for conventional implants remains high, both in terms of education and equipment needs, but are affordable for mini- and narrow-dental implants.

Although the use of either MDIO or NDIO is accompanied by many advantages, it must be considered that the treatment and maintenance is more complex than the one for conventional prosthesis, that may be regarded as a disadvantage, when considering the barriers that elderly face (e.g., financial hardship, transportation difficulties). Therefore, simpler solutions must be chosen, with complications that can be easily resolved (e.g., in elderly, unsplinted implants with O-ball attachments are preferred to bars). Also, there are behavioral aspects or systemic conditions that associate a higher complication rate (e.g., smokers are at greater risk of implant failure compared to nonsmokers).

Specifically linked to the MDIO and NDIO is the disadvantage of not being recommended to be insert mini and narrow dental implant immediately after tooth extraction.



Also, when using mandibular MDIO or NDIO, opposed by an edentulous maxilla treated by conventional denture, signs similar to those of Combination Syndrome may appear, as instability of the conventional denture and increase bone resorption rate in the anterior maxilla. These are managed usually through using implant prosthesis also in the maxilla.

## 5. Conclusions

Stabilization of conventional denture with mini- or narrow-dental implants is beneficial especially for the elderly, considering the improvement achieved through a relatively easy surgical intervention, with moderate treatment costs. In this regard, for mandibular denture stabilization either 4 mini implants or 2 hybrid/narrow implants can be used. Treatment success is strongly related to acknowledgement of patient anatomical and functional particularities, rigorous planning and execution of prosthetic and surgical phase, as well as ensuring an adequate maintenance.

Considering that edentulism is and most probably will continue to remain a frequent medical condition mostly found in the elderly, MDIO and NDIO overdentures, through their specific parameters, may replace in time complete dentures and may be the most used treatment alternative.

## Author details

Elena Preoteasa<sup>1\*</sup>, Marina Imre<sup>1</sup>, Henriette Lerner<sup>2</sup>, Ana Maria Tancu<sup>1</sup> and Cristina Teodora Preoteasa<sup>3</sup>

\*Address all correspondence to: [dr\\_elena\\_preoteasa@yahoo.com](mailto:dr_elena_preoteasa@yahoo.com)

1 Department of Prosthodontics, Faculty of Dental Medicine, Carol Davila University of Medicine and Pharmacy, Bucharest, Romania

2 Private Practice, Baden-Baden, Germany

3 Department of Oral Diagnosis, Ergonomics, Scientific Research Methodology, Faculty of Dental Medicine, Carol Davila University of Medicine and Pharmacy, Bucharest, Romania

## References

- [1] WHO. Active Aging. A Policy Framework. Madrid; 2002. [http://whqlibdoc.who.int/hq/2002/WHO\\_NMH\\_NPH\\_02.8.pdf?ua=1](http://whqlibdoc.who.int/hq/2002/WHO_NMH_NPH_02.8.pdf?ua=1) (accessed 3 October 2014).

- [2] Thomason JM, Kelly SA, Bendkowski A, Ellis JS. Two implant retained overdentures--a review of the literature supporting the McGill and York consensus statements. *Journal of Dentistry* 2012;40(1) 22-34.
- [3] Feine JS, Carlsson GE, Awad MA, Chehade A, Duncan WJ, Gizani S, Head T et al. The McGill Consensus Statement on Overdentures. Montreal, Quebec, Canada. May 24-25, 2002. *International Journal of Prosthodont* 2002;15(4) 413-4.
- [4] Melescanu Imre M, Marin M, Preoteasa E, Tancu AM, Preoteasa CT. Two implant overdenture--the first alternative treatment for patients with complete edentulous mandible. *Journal of Medicine and Life* 2011;4(2) 207-9.
- [5] Preoteasa E, Marin M, Imre M, Lerner H, Preoteasa CT. Patients' Satisfaction With Conventional Dentures and Mini Implant Anchored Overdentures. *Revista Medico-Chirurgicala a Societatii de Medici si Naturisti din Iasi* 2012;116(1) 310-16.
- [6] Klein MO, Schiegnitz E, Al-Nawas B. Systematic review on success of narrow-diameter dental implants. *The International Journal of Oral & Maxillofacial Implants* 2014;29 Supplement 43-54.
- [7] Diz P, Scully C, Sanz M. Dental Implants in the Medically Compromised Patient. *Journal of Dentistry* 2013;41(3) 195-206.
- [8] Gomez-de Diego R, Mang-de la Rosa M, Romero-Pérez MJ, Cutando-Soriano A, Lopez-Valverde-Centeno A. Indications and Contraindications of Dental Implants in Medically Compromised Patients: Update. *Medicina Oral Patologia Oral y Cirugia Bucal* 2014;19(5):e438, -9.
- [9] Preoteasa E, Murariu CM, Ionescu E, Preoteasa CT. Acrylic Resin Reinforcement With Metallic and Nonmetallic Inserts. *Revista Medico-Chirurgicala a Societatii de Medici si Naturalisti din Iasi* 2007; 111(2) 487-93.
- [10] Lerner H. Minimal invasive implantology with small diameter implants. *Implant Practice* 2009, 2(1) 30-5.
- [11] Preoteasa E, Meleşcanu-Imre M, Preoteasa CT, Marin M, Lerner H. Aspects of oral morphology as decision factors in mini-implant supported overdenture. *Romanian Journal of Morphology and Embryology* 2010;51(2) 309-14.
- [12] Shatkin TE, Shatkin S, Oppenheimer AJ, et al. A simplified approach to implant dentistry with mini dental implants. *Alpha Omega*. 2003; 96(3) 7-15.
- [13] Preoteasa E, Imre M, Preoteasa CT. A 3-Year Follow-up Study of Overdentures Retained by Mini-Dental Implants. *The International Journal of Oral & Maxillofacial Implants* 2014; 29(5) 1034-41.
- [14] Sohrabi K, Mushantat A, Esfandiari S, Feine J. How successful are small-diameter implants? A literature review. *Clinical Oral Implants Research* 2012;23 (5) 515–525.

- [15] Block MS1, Delgado A, Fontenot MG. The effect of diameter and length of hydroxylapatite - coated dental implants on ultimate pullout force in dog alveolar bone. *Journal of Oral and Maxillofacial Surgery* 1990;48(2) 174-8.
- [16] Renouard F, Nisand D. Impact of implant length and diameter on survival rates. *Clinical Oral Implants Research* 2006;17 (2) Supplement 35-51.
- [17] Singh RD, Ramashanker, Chand P. Management of atrophic mandibular ridge with mini dental implant system. *National Journal of Maxillofacial Surgery* 2010;1(2) 176-8.
- [18] Griffiths TC, Collins CP, Collins PC. Mini dental implants: an adjunct for retention, stability, and comfort for the edentulous patient. *Oral Surgery, Oral Medicine, Oral Pathology, Oral Radiology, and Endodontology* 2005;100 (5) 81-4.
- [19] Misch CE. *Contemporary Implant Dentistry* 2nd edition. St. Louis: Mosby Inc; 1999.
- [20] Rossein KD. Alternative treatment plans: implant supported mandibular dentures. *Inside Dentistry* 2006; 2(6) 42-43.
- [21] Melescanu Imre M, Preoteasa E, Tancu A, Preoteasa CT. Imaging Technique for the Complete Edentulous Patient Treated Conventionally or With Mini Implant Overdenture. *Journal of Medicine and Life* 2013;6(1) 86-92.
- [22] Campelo LD, Camara JR. Flapless implant surgery: A 10-year clinical retrospective analysis. *International Journal Oral Maxillofacial Implants* 2002;(17) 271-276.
- [23] Sunitha RV, Saphthagiri E. Flapless implant surgery: A 2-year follow-up study of 40 implants. *Oral Surgery, Oral Medicine, Oral Pathology and Oral Radiology* 2013;116 (4) 237-243.
- [24] Scherer MD, Ingel AP, Rathi N. Flapped or Flapless Surgery for Narrow-Diameter Implant Placement for Overdentures: Advantages, Disadvantages, Indications, and Clinical Rationale. *The International Journal of Periodontics & Restorative Dentistry* 2014;34(3) Supplement 89-95.
- [25] Christensen GJ. The 'mini'-implant has arrived. *The Journal of the American Dental Association* 2006;137(3) 387-90.
- [26] Preoteasa E, Iosif L, Amza O, Preoteasa CT, Dumitrascu C. Thermography, an Imagistic Method in Investigation of the Oral Mucosa Status in Complete Denture Wearers. *Journal of Optoelectronics and Advanced Materials* 2010;12(11) 2333-4.
- [27] Awad MA, Lund JP, Dufresne E, Feine JS. Comparing the efficacy of mandibular implant-retained overdentures and conventional dentures among middle-aged edentulous patients: satisfaction and functional assessment. *The International Journal of Prosthodontics* 2003;16, 117-22.
- [28] Flanagan D, Mascolo A. The Mini Dental Implant in Fixed and Removable Prosthetics: A Review. *Journal of Oral Implantology* 2011;37 (1) 123-132

- [29] Bulard RA. Mini implants. Part I. A solution for loose dentures. *The Oklahoma Dental Association Journal*. 2002;93:42-46.
- [30] Dantas Ide S, Souza MB, Morais MH, Carreiro Ada F, Barbosa GA. Success and survival rates of mandibular overdentures supported by two or four implants: a systematic review, *Brazilian Oral Research* 2014;28(1) 74-80.
- [31] Bergendal T, Engquist B. Implant-supported overdentures: a longitudinal prospective study. *The International Journal of Oral & Maxillofacial Implants* 1998;13 (2) 253-62.
- [32] Klein MO, Schiegnitz E, Al-Nawas B. Systematic review on success of narrow-diameter dental implants. *The International Journal of Oral & Maxillofacial Implants*. 20

INTECH

INTECH