

Neurologic Emergencies

How to Do a Fast,
Focused Evaluation
of Any Neurologic
Complaint

Latha Ganti
Joshua N. Goldstein
Editors

Neurologic Emergencies

Latha Ganti • Joshua N. Goldstein
Editors

Neurologic Emergencies

How to Do a Fast, Focused Evaluation
of Any Neurologic Complaint

Editors

Latha Ganti
Orlando, Florida
USA

Joshua N. Goldstein
Boston, Massachusetts
USA

Disclaimer: The American College of Emergency Physicians (ACEP) makes every effort to ensure that contributors to its publications are knowledgeable subject matter experts. Readers are nevertheless advised that the statements and opinions expressed in this publication are provided as the contributors' recommendations at the time of publication and should not be construed as official College policy. ACEP recognizes the complexity of emergency medicine and makes no representation that this publication serves as an authoritative resource for the prevention, diagnosis, treatment, or intervention for any medical condition, nor should it be the basis for the definition of, or standard of care that should be practiced by all health care providers at any particular time or place. To the fullest extent permitted by law, and without limitation, ACEP expressly disclaims all liability for errors or omissions contained within this publication, and for damages of any kind or nature, arising out of use, reference to, reliance on, or performance of such information.

ISBN 978-3-319-64521-6 ISBN 978-3-319-64523-0 (eBook)
<https://doi.org/10.1007/978-3-319-64523-0>

© Springer International Publishing AG 2018

This work is subject to copyright. All rights are reserved by the Publisher, whether the whole or part of the material is concerned, specifically the rights of translation, reprinting, reuse of illustrations, recitation, broadcasting, reproduction on microfilms or in any other physical way, and transmission or information storage and retrieval, electronic adaptation, computer software, or by similar or dissimilar methodology now known or hereafter developed.

The use of general descriptive names, registered names, trademarks, service marks, etc. in this publication does not imply, even in the absence of a specific statement, that such names are exempt from the relevant protective laws and regulations and therefore free for general use.

The publisher, the authors and the editors are safe to assume that the advice and information in this book are believed to be true and accurate at the date of publication. Neither the publisher nor the authors or the editors give a warranty, express or implied, with respect to the material contained herein or for any errors or omissions that may have been made. The publisher remains neutral with regard to jurisdictional claims in published maps and institutional affiliations.

Printed on acid-free paper

This Springer imprint is published by Springer Nature
The registered company is Springer International Publishing AG
The registered company address is: Gewerbestrasse 11, 6330 Cham, Switzerland

My co-faculty, residents, nurses, and paramedics at UCF/Osceola Regional Medical Center who lead by example, and make my job super fun.

My dad Dr. Ganti L. Rao and late mother Prabha Ganti for always pushing me to pursue my dream of being a doctor and a writer. I wouldn't have the amazing career I do without you.

My children Thor, Tej, Trilok, Karthik & Vaishnavi for their patience, resilience and grace – I may have taught you to read and ace algebra, but you taught me how to live life.

—LG

My teachers, mentors, and colleagues at Massachusetts General Hospital for helping me build an academic career that is interesting, fulfilling, and fun.

My parents, brother, sisters, friends, and so many family members that are immediate, extended, and “other” – they taught me, raised me, and gave my life meaning.

My wife Erica for her love and support all these years (22 years so far!) even though I spent too many hours over the laptop.

My children, Alexa and Lindsey, for filling my life with joy, love, and (of course) dance. And for just being awesome.

—JNG

This book was only possible thanks to the hard work of so many people.

Our authors who put their time and effort into these chapters, and their families who helped them do it!

Our team at Springer- Margaret, Gayathri & Rajeshwari for keeping us on track and seeing us through seamless production.

Marta Foster at the American College of Emergency Physicians for encouraging us to co-publish this text with ACEP.

—Latha Ganti & Joshua Goldstein

Foreword

Neurologic emergencies are not only some of the most common conditions seen in the emergency department, but are also among the most devastating conditions that we treat. The toll of severe neurological conditions not only involves life or death but also impacts the lives of its victims even more profoundly. The long-term sequelae from neurological emergencies include paralysis, loss of sensation, loss of intellectual capacity, and personality change, all of which can be often life changing.

Between 5 and 8% of all patients seen in emergency departments across the United States will have neurological issues. These conditions range from neurotrauma such as traumatic brain and spinal cord injury to ischemic and hemorrhagic stroke, status epilepticus, central nervous system infections, anoxic brain injury, headache, and others. These conditions have a very high burden of disease. Acute ischemic stroke affects about 200/100,000 people in the United States and has a mortality of 15–17% at 30 days. Intracerebral hemorrhage affects about 15/100,000 people but has a mortality rate as high as 50% at 30 days. Status epilepticus affects 40/100,000 people in the United States with a mortality rate of 22% at 30 days and subarachnoid hemorrhage affects 6/100,000 people with a mortality of 50% at 30 days. Not only are these diseases devastating in terms of death and disability, but the healthcare costs from these conditions are enormous.

For many neurological emergencies, patient outcomes can be significantly affected by rapid recognition and appropriate treatment. Ischemic stroke outcomes have been profoundly affected by the use of intravenous thrombolytic agents and recently by the effective use of endovascular treatment for large vessel occlusions. Outcomes from status epilepticus are improved by rapid cessation of seizures with appropriate antiepileptic drugs. We also know that prompt recognition and effective treatment of hypoxia and hypotension can have profound impacts on the outcome of patients with traumatic brain and spinal cord injury.

For these reasons, it is implicit that all emergency physicians have appropriate knowledge and training in recognition and treatment of neurological emergencies. Latha Ganti, M.D., M.S., M.B.A., and Josh Goldstein, M.D., Ph.D., have put together this outstanding book on Neurological Emergencies to address this need. The book has been structured to cover the broad landscape of neurological emergencies and provide the essential keys to rapid recognition and diagnosis. Drs. Ganti

and Goldstein are notable experts in neurological emergencies and they have recruited an outstanding list of authors to put this book together.

I am hopeful that this text will help emergency physicians to better recognize and treat neurological emergencies and lead to better patient outcomes.

William Barsan MD,
Professor of Emergency Medicine
University of Michigan
Ann Arbor, MI, USA

Disclaimer

The American College of Emergency Physicians (ACEP) makes every effort to ensure that contributors to its publications are knowledgeable subject matter experts. Readers are nevertheless advised that the statements and opinions expressed in this publication are provided as the contributors' recommendations at the time of publication and should not be construed as official College policy. ACEP recognizes the complexity of emergency medicine and makes no representation that this publication serves as an authoritative resource for the prevention, diagnosis, treatment, or intervention for any medical condition, nor should it be the basis for the definition of, or standard of care that should be practiced by all health care providers at any particular time or place. To the fullest extent permitted by law, and without limitation, ACEP expressly disclaims all liability for errors or omissions contained within this publication, and for damages of any kind or nature, arising out of use, reference to, reliance on, or performance of such information.

Contents

1	The Fast and Focused Neurological Examination	1
	Matthew S. Siket	
2	Rule Out Acute Stroke	17
	Aunali S. Khaku and Sayed K. Ali	
3	Acute Head Injury: When to Image and When to Observe?	39
	Tracy MacIntosh and Adam Benzing	
4	Seizure Activity	59
	Claire S. Jacobs and Imoigele P. Aisiku	
5	Syncope: Who Needs Imaging? Who Needs Admission?	85
	Ellen Vollmers and Sean Kivlehan	
6	Dizziness: An Evidence-Based Approach (Better than MRI?)	103
	Jonathan A. Edlow	
7	Acute Vision Loss and Diplopia	127
	David C. Lebowitz, Amninder Singh, and Amanda Webb	
8	Headache: When to Image, When to Tap	143
	Perrin T. Considine, Levi Filler, and Murtaza Akhter	
9	Atraumatic Acute Neck and Back Pain	175
	John W. Martel and J. Brooks Motley	
10	The Nonanatomic Exam: Psychogenic Syndromes and Malingering	195
	Michael Hoffmann	
11	Altered Mental Status in the Emergency Department	209
	Austin T. Smith and Jin H. Han	
12	Acute Generalized Weakness	233
	Latha Ganti and Vaibhav Rastogi	

13 Infections of the Central Nervous System	251
Ogonna Felton and Charles R. Wira III	
14 Movement Disorder Emergencies	271
Latha Ganti and Javier Rosario	
15 Basic Emergent Computed Tomography	289
Christopher Horn	
Index	313

Contributors

Imoigele P. Aisiku Brigham and Women's Hospital, Boston, MA, USA

Murtaza Akhter Department of Emergency Medicine, University of Arizona College of Medicine–Phoenix, Maricopa Integrated Health System, Phoenix, AZ, USA

Sayed K. Ali Aga Khan University Hospital, Nairobi, Kenya

University of Central Florida, College of Medicine, Orlando, FL, USA

Adam Benzing University of Central Florida College of Medicine, Orlando, FL, USA

Perrin T. Considine Department of Emergency Medicine, Maricopa Integrated Health System, Phoenix, AZ, USA

Jonathan A. Edlow Professor of Medicine and Emergency Medicine, Harvard Medical School, Vice-chair, Department of Emergency Medicine, Beth Israel Deaconess Medical Center, Boston, MA, USA

Ogonna Felton Department of Emergency Medicine, Yale School of Medicine, New Haven, CT, USA

Levi Filler Department of Emergency Medicine, Maricopa Integrated Health System, Phoenix, AZ, USA

Latha Ganti University of Central Florida College of Medicine, Orlando, FL, USA

Jin H. Han Department of Emergency Medicine, Vanderbilt University School of Medicine, Nashville, TN, USA

Michael Hoffmann University of Central Florida, Orlando, FL, USA

Christopher Horn Director of Neurocritical Care, Department of Neurosciences, Wellstar Kennestone Hospital, Marietta, GA, USA

Claire S. Jacobs Brigham and Women's Hospital, Boston, MA, USA

Aunali S. Khaku University of Central Florida College of Medicine (UCF), Orlando, FL, USA

Sean Kivlehan Department of Emergency Medicine, Brigham and Women's Hospital, Harvard Medical School, Boston, MA, USA

David C. Lebowitz University of Central Florida College of Medicine, Orlando, FL, USA

Tracy Macintosh University of Central Florida, Osceola Regional Medical Center, Kissimmee, FL, USA

John W. Martel Tufts University School of Medicine, Boston, MA, USA

J. Brooks Motley Maine Medical Center, Portland, Maine, USA

Vaibhav Rastogi University of Central Florida College of Medicine, Orlando, FL, USA

Javier Rosario University of Central Florida College of Medicine, Orlando, FL, USA

Matthew S. Siket Department of Emergency Medicine, The Warren Alpert Medical School, Brown University, Providence, RI, USA

Amninder Singh University of Central Florida College of Medicine, Orlando, FL, USA

Austin T. Smith Department of Emergency Medicine, Vanderbilt University Medical Center, Nashville, TN, USA

Ellen Vollmers Harvard Affiliated Emergency Medicine Residency, Boston, MA, USA

Amanda Webb University of Central Florida College of Medicine, Orlando, FL, USA

Charles R. Wira Department of Emergency Medicine, Yale School of Medicine, New Haven, CT, USA

The Fast and Focused Neurological Examination

1

Matthew S. Siket

Introduction

The neurological examination in the emergency department (ED) should be targeted and focused yet thorough and sensitive enough to detect subtle but meaningful abnormalities. Ideally, the components of the neurological exam for any given ED patient should be structured after an interview to gather historical information including the history of present illness, review of systems, as well as past medical, family, and social histories. Realistically, however, in today's world of acute stroke metrics including door-to-CT and door-to-TPA times, with many institutions (including my own) embracing a "direct-to-CT" clinical pathway, the time that an ED provider spends with his/her hands on a patient with an acute neurologic complaint may be very limited before important and time-sensitive decisions must be made. This chapter will focus on structuring a proper encompassing yet efficient neurological exam to be used and relied on by the ED provider when minutes and seconds count for the patient with an acute and undifferentiated neurologic emergency.

Basic Principles

All ED providers should be comfortable performing a neurological examination, as invariably it will be performed several times each shift. According to the National Hospital Ambulatory Medical Care Survey, 9.4 million CT scans of the brain were obtained in US EDs in 2013, which is approximately 7% of all ED visits [1]. Moreover, there were 4 million ED visits each for headache and head/neck trauma,

M.S. Siket, M.D., M.S., F.A.C.E.P.
Department of Emergency Medicine, The Warren Alpert Medical School of Brown University, 55 Claverick Street 2nd Floor, Providence 02903, RI, USA
e-mail: Matthew_Siket@brown.edu

Table 1.1 Common chief complaints of neurological emergencies

Chief complaint
Weakness (focal or generalized)
Headache
Dizziness/vertigo
Seizure
Confusion/altered mental status
Numbness/paresthesias
Neck/back pain
Vision change
Slurred speech
Head injury

1.3 million visits for vertebral/spinal trauma, and over 400,000 visits for dizziness in patients aged 65 and over. Despite the need for careful neurological assessment in these patients, a complete and encompassing neurological examination (as would be performed in a neurologist’s office) would be inefficient and practically impossible given competing time-sensitive demands in the ED setting. Therefore, it is best for the ED clinician to divide the emergent neurological exam into two components: the *focused* component, which is built around the patient’s complaint and historical data, and the *screening* component, which assesses for additional focal and localizing neurologic deficits in the remaining parts of the nervous system [2]. The focused component should be largely individualized and built on a foundation of basic understanding of neuroanatomy. The screening component can be more standardized but should be more comprehensive in patients with potentially neurological causes of acute illness than for those with clearly non-neurologic complaints. For example, one should not be expected to detect a homonymous quadrantanopia in an otherwise healthy patient presenting with dysuria, whereas it would similarly be inappropriate to document the extent of a neurological exam as “no gross abnormalities” in a patient presenting with headache, dizziness, or weakness. A list of the most common neurologic complaints encountered in the ED is found in Table 1.1.

Initial Assessment

In certain instances when time-critical decisions must be made, the initial neurological exam may consist of a brief screen to inform downstream processes, such as the activation of a stroke team, the acquisition of emergent neuroimaging, and of course in securing an airway in patients who have lost protective reflexes. In these cases, review of vital signs and a very brief assessment of neurological function are initiated prior to a comprehensive patient interview. For example, in patients with suspected head injury and/or decreased level of consciousness, the initial patient evaluation should assess the airway, breathing, and circulation (ABCs) followed by level of consciousness, typically using the Glasgow Coma Scale (Table 1.2). In patients suspected of experiencing an acute ischemic stroke, the Face, Arm, Speech,

Table 1.2 The Glasgow Coma Scale [13]

Activity	Score
Eye opening	1–4
None	1
To pain	2
To speech	3
Spontaneous	4
Motor response	(1–6)
None	1
Extension	2
Flexor response	3
Withdrawal	4
Localizes pain	5
Obeys commands	6
Verbal response	(1–5)
None	1
Incomprehensible	2
Inappropriate	3
Confused	4
Oriented	5
Total	(3–15)

Table 1.3 List of stroke recognition and severity assessment tools

<i>Stroke recognition tools</i>	
FAST	Face Arm Speech Test
CPSS	Cincinnati Prehospital Stroke Scale
LAPSS	Los Angeles Prehospital Stroke Scale
ROSIER	Recognition of Stroke in the Emergency Room
<i>Stroke severity assessment tools</i>	
RACE	Rapid Arterial Occlusion Evaluation Scale
LAMS	Los Angeles Motor Scale
CPSSS	Cincinnati Prehospital Stroke Severity Scale
VAN	Vision, aphasia, neglect
3I-SS	3-item stroke scale
sNIHSS-8	Shortened NIHSS (eight items)
sNIHSS-5	Shortened NIHSS (five items)

Time (FAST) assessment or severity scale such as the Los Angeles Motor Scale (LAMS) may be performed in the prehospital environment or upon initial contact with emergency personnel. A more encompassing list of prehospital stroke scales is listed in Table 1.3. The National Institutes of Health Stroke Scale (NIHSS) is a widely used tool for measuring neurologic deficits in a reproducible way, and in the United States, documentation of an NIHSS from the initial provider assessment in all ischemic stroke patients is expected in all certified stroke centers. This 11-item scale (Table 1.4) was designed to take 7 min to complete but in reality can be performed in a fraction of that time. Certification is encouraged but not mandated per

Table 1.4 The National Institutes of Health Stroke Scale (NIHSS)

Item	Description	Scoring
1a. Level of consciousness	State of arousal	0 = Alert, keenly responsive 1 = Not alert, but arousable by minor stimuli and able to answer 2 = Not alert, requires repeated stimulation, obtunded 3 = Only reflex motor response or unresponsive, flaccid, areflexic
1b. LOC questions	Ask the month and patient's age	0 = Answers both correctly 1 = Answers one correctly 2 = Answers neither correctly
1c. LOC commands	Ask to open/close eyes and grip/release hand	0 = Both tasks performed correctly 1 = One task performed correctly 2 = Neither task performed correctly
2. Best gaze	Assess horizontal eye movements	0 = Normal 1 = Partial gaze palsy 2 = Forced deviation or total gaze paresis
3. Visual	Test visual fields	0 = No visual loss 1 = Partial hemianopia 2 = Complete hemianopia 3 = Bilateral hemianopia, blind, cortical blindness
4. Facial palsy	Test facial movements	0 = Normal symmetrical movement 1 = Minor paralysis 2 = Partial paralysis 3 = Complete paralysis
5a/b. Motor arm	Test for pronator drift with arm extended and held up for 10 s	0 = No drift 1 = Slight drift (limb does not lower completely)
6a/b. Motor leg	Test for pronator drift with leg extended and held up for 5 s	2 = Drift, but some effort against gravity (limb lowers completely) 3 = No effort against gravity, limb falls 4 = No movement
7. Limb ataxia	Test finger to nose and heel to shin	0 = Absent 1 = Present in one limb 2 = Present in two limbs
8. Sensory	Test pinprick sensation in the arms, legs, trunk, and face, and assess for symmetry	0 = Normal 1 = Mild/moderate sensory loss 2 = Severe/total sensory loss
9. Best language	Describe a picture, name items, read words and sentences	0 = No aphasia 1 = Mild/moderate aphasia 2 = Severe aphasia 3 = Mute or global aphasia
10. Dysarthria	Assess for clarity/slurring of read words and sentences	0 = Normal 1 = Mild/moderate slurring 2 = Severe; unintelligible speech or mute
11. Extinction and inattention	Visual double simultaneous stimulation, tactile, spatial, personal inattention should be assessed	0 = No abnormality 1 = Inattention in one sensory modality 2 = Profound or multimodality hemi-inattention
	Total	0–42

The Joint Commission and is freely available online (<https://secure.trainingcampus.net/uas/modules/trees/windex.aspx?rx5nihss-english.trainingcampus.net>). It is important to remember that the NIHSS is not a replacement for a complete neurological examination and is not encompassing. It is preferentially skewed toward the anterior circulation, and a NIHSS of 0 does not exclude serious and debilitating neurologic injury.

The History and Focused Neurological Examination

Under most circumstances, the components of a focused neurological examination in the ED should be individualized and constructed around relevant information gathered from the patient's history. The experienced clinician formulates a differential diagnosis in real time during the patient interview and then caters the exam that follows to be hypothesis driven. The examiner should be looking to differentiate whether the patient has a neurologic or non-neurologic cause of illness and whether a neurologic cause can be traced to the central nervous system (brain and spinal cord) or peripheral nervous system. Simply put, the examiner should focus on addressing the following three questions: (1) Is there a lesion? (2) Where is the lesion? (3) What is the lesion?

Reported neurologic symptoms can generally be characterized as either “positive” or “negative.” Positive symptoms include the addition of clinical phenomena, such as certain visual aura preceding a migraine, tonic-clonic activity in a motor seizure, and “pins and needles” paresthesias such as in radicular back pain. Positive symptoms typically describe irritative phenomena, wherein there is an overabundance or abnormal neuronal discharge [3]. The examiner may note repetitive motor movements, such as automatisms or heightened sensation (aka hyperesthesia). Negative symptoms, on the other hand, describe ablative phenomena, where there is a loss of normal neurological function. Symptoms include motor weakness, sensory loss (numbness as opposed to tingling), and loss of normal coordination, vision, speech fluency, and articulation. Since motor, sensory, and visuospatial ablative phenomena are most often unilateral, it is best to directly compare the two sides of the body directly at each step of the examination [4].

Two other types of clinical phenomena are observed in patients with debilitating neurological disease: release and compensation syndromes, which typically follow ablative phenomena. Release syndromes include spasticity and hyperreflexia in upper motor neuron disease and motor rebound findings in patients with cerebellar dysfunction. Compensation syndromes occur as the brain adjusts for deficits, such as in patients with a notable head tilt to compensate for an ocular nerve palsy or a broad-based gait to compensate for imbalance and loss of coordination.

The pace and manner of onset of symptoms are important historical components that should be carefully elucidated during the encounter. For example, acute and sustained ablative-type symptoms should lead one to expect a vascular emergency

such as stroke, whereas episodic, fluctuating, or triggered symptoms often point to a nonvascular cause (except in cases of transient ischemic attacks). Careful attention to the timing and triggers of the described symptoms is imperative, particularly in dizziness (which is discussed in depth in Chap. 6), as it serves as the foundation on which the remaining components of the exam, including provocative tests, are structured. Degenerative processes typically have a slow-to-variable course over months to years, whereas demyelinating diseases such as multiple sclerosis may have a variable course. Diffuse and non-localizing symptoms should clue the clinician into pursuing causes of encephalopathy, such as toxic/metabolic and infectious processes.

Once enough historical data has been collected to form a reasonable differential diagnosis with attention given to the most dangerous and treatable potential causes first, the focused examination that follows should confirm or refute those considerations and modify the list accordingly. The examiner should target the suspected affected portions of the nervous system first, compare to the contralateral side, and then expand to adjacent anatomical areas. For example, a patient with apparent right hemiparesis should have careful attention paid to speech and language function, knowing that Broca's and Wernicke's areas are generally located in the left hemisphere (approximately 95% of right-handed individuals and 60% of left-handed individuals). Similarly, if in the aforementioned example language is preserved but a right-homonymous hemianopia is noted, one can be nearly certain that the lesion is in the left cerebral hemisphere, not in the cervical spinal cord. When such deficits are present, they are described as *focal localizing signs*, which should always trigger further investigation, usually in the form of neuroimaging. *False localizing signs* describe phenomena such as limb weakness observed in hypoglycemia or cranial nerve deficits produced by mass effect from a space-occupying lesion. When formulating and narrowing the differential diagnosis, the ED provider should be mindful of the law of parsimony (Occam's razor), which is the principle that most likely there is a single lesion and unifying diagnosis to explain a constellation of symptoms. Table 1.5 provides a list of general principles to aid in localization of CNS lesions.

Table 1.5 General principles regarding lesion localization

General principles regarding lesion localization
Symptoms of brain or spinal cord ischemia are usually "negative" involving loss of normal function
Irritative or "positive" symptoms are rarely due to ischemia
A lesion in the brainstem reticular activating system or bilateral cerebral hemispheres may result in impaired consciousness
Motor deficits can be due to contralateral lesions above the medulla and ipsilateral lesions below the medulla
Deficits in memory, thought process, and executive functions suggest a cortical lesion
Paralysis with areflexia, muscle wasting, and fasciculations all suggest a lower motor neuron lesion
Paralysis with hyperreflexia and spasticity suggests an upper motor neuron lesion

The Screening Neurological Examination

Following a focused exam, a screening exam should be performed to briefly interrogate the remaining parts of the nervous system. Though the history and physical examination are distinguished for purposes of organization, in reality, the objective assessment of neurological function begins at the commencement of the encounter. Is the patient fully alert and seemingly aware of his/her surroundings? Is there obvious hemispheric inattention or neglect? Does the patient exhibit a normal and fluent speech pattern? Is the patient able to recall historical events and appropriately communicate a history of present illness? Does he/she exhibit normal facial expressions? The interviewer inherently gains a sense of these functions in the first few moments of the interview. For purposes of convenience, the screening neurological exam can be divided into an organizational framework of six distinct components, (1) mental status and higher cortical function, (2) cranial nerves, (3) sensory function, (4) motor function, (5) gait and coordination, and (6) reflexes, which can be performed in any order.

Mental Status and Higher Cortical Function

Assessment of mental status includes both neurological and psychiatric components. Neurologic mental status includes level of consciousness (*alertness*), orientation (*person, place, time, and situation*), attention (*ability to concentrate*), and memory (*immediate, short, and long term*). Psychiatric components include mood, affect, thought process and content, judgment, and insight.

Interrogating language function is also an integral part of assessing a patient's mental status. In order for language function to be intact, patients need to be able to hear and comprehend what was said, find the appropriate words to initiate a reply, and respond fluently with normal cadence and rhythm (*prosody*). Repetition, naming, reading, and writing are also components of a thorough assessment of language function. When speech comprehension, processing, or production is impaired, the patient is said to exhibit *aphasia*. Aphasia can be receptive (*Wernicke's aphasia*), expressive (*Broca's aphasia*), global, or limited to just repetitive (*conductive aphasia*) or naming dysfunction (*nominal aphasia*). Aphasia typically localizes to cortical or subcortical damage. The ED provider need not dwell on the specifics of aphasia subtype discrimination, but for purposes of identification and communication with consultants, one should describe whether the aphasia is fluent (receptive), nonfluent (expressive), or mixed [5]. Speech that is slurred or difficult to understand is considered *dysarthric* which suggests a mechanical disorder from facial muscle weakness or incoordination. This may be reflective of a motor hemispheric or cerebellar lesion or point to a problem in the brainstem, cranial nerves, or chemical effect, such as alcohol intoxication.

Other tests of higher cortical function include right-left discrimination, geographical orientation, recognition (*gnosia*), constructional ability, and carrying out learned tasks (*praxis*). A three-step command is a quick way to assess executive

function in the ED. Though not encompassing, it does test multiple mental processes simultaneously when performed correctly. The key is to eliminate visual input and to ensure that the patient waits to perform the three-step task until after all the steps are described. An example is to ask the patient to close the eyes, make a fist with the right hand with the thumb out, and then use that thumb to touch the left ear while sticking out the tongue [3].

Cranial Nerves

A cranial nerve exam is fundamental when examining patients with neurologic complaints. Though the olfactory nerve (CN I) rarely needs emergent assessment, the remaining cranial nerves may be adequately interrogated in a matter of seconds and provide important clinical data. The ED provider should spend a minute or two assessing the patient's eyes, preferably paying attention to pupillary response, presence of nystagmus, extraocular movements, visual fields, and fundoscopy in addition to assessing facial movements and sensation. This is particularly important in patients presenting with headache when the focus of the encounter is to exclude potentially dangerous causes such as aneurysmal subarachnoid hemorrhage, vasculitis, a space-occupying lesion, meningitis, encephalitis, and other causes of increased intracranial pressure. The remaining cranial nerves (II–XII) and how to test them are described below. Note, significant attention is paid to CN II, III, IV, and VI as the examination of the eyes is often one of the most valuable parts of the neurological exam.

Optic Nerve (CN II): Assess visual acuity, visual fields, pupillary response, and fundoscopy. Not every patient needs formal Snellen chart testing unless visual disturbance is reported. However, a patient may be unaware of a hemianopia or quadrantopia unless specifically tested. Face the patient directly and cover the eye of the patient which is not being tested, and then have the patient focus on your corresponding eye (patient's left eye looks at your right eye). Place your hand halfway between your eye and the patient's eye and find your corresponding visual fields, and then hold up 1–5 fingers and ask the patient to tell you how many. Patients sometimes need to be reminded to not look at your fingers but rather to focus on your eye and see the fingers with their peripheral vision. Do this for each quadrant of each eye. Alternatively, you may combine visual field testing with accessing for visuospatial inattention and some executive function by holding up two fingers in one hand and one finger in the other hand held over the lateral visual fields of each eye and ask the patient to tell you how many fingers are seen in total. For the patient to say "three" requires bihemispheric awareness, intact visual fields where tested, and the ability to add $1 + 2$ (absence of acalculia), typically a parietal lobe function.

The pupils should be near symmetric in size (~1 mm of anisocoria can be physiologic) and round in shape and constrict equally to light. Illumination of one eye should cause an equal pupillary response in both eyes. In the swinging flashlight test, a seemingly paradoxical dilation of one pupil suggests an afferent pupillary

defect (Marcus Gunn pupil) suggestive of unilateral optic nerve dysfunction. Note that slow, subtle (~1 mm) pupillary oscillations may be seen in a normal pupillary light reflex, called a hippus.

A fundoscopic exam should be performed to assess for papilledema whenever increased intracranial pressure is considered on the differential diagnosis. While many trainees in emergency medicine may skip this part of the exam due to difficulty visualizing the optic disk without the aid of a mydriatic agent or a lack of confidence in interpreting the presence of optic disk abnormalities, the exam can provide valuable clinical information and should always be considered. Technological advances in ophthalmoscopy have made fundus visualization and photography easier than ever before, and several portable products exist that can be attached to the examiner's smartphone. Measurement of optic nerve sheath diameter 3 mm behind the eye over closed eyelids on bedside ocular ultrasound may be a useful adjunct to ophthalmoscopy, as a diameter ≥ 5.7 mm achieved 100% sensitivity and specificity for intracranial pressure > 20 mmHg among patients with intracerebral hemorrhage [6–9].

Oculomotor (CN III), Trochlear (CN IV), and Abducens (CN VI) Nerves: Assess the eyelids, extraocular movements, and for the presence and type of nystagmus. The oculomotor nerve innervates all the extraocular muscles except the superior oblique (which is innervated by CN IV) and the lateral rectus (CN VI). A lesion to CN III will lead to the affected eye deviated “down and out.” Additionally, because CN III innervates parasympathetic pupilloconstrictors as well as the levator palpebrae muscle, a third nerve palsy produces a dilated pupil and ptosis as well. Fourth nerve palsy usually manifests as vertical diplopia and is compensated by a head tilt away from the affected side. A sixth nerve palsy produces an inability to abduct the ipsilateral eye. These syndromes along with other causes of diplopia are discussed in more depth in Chap. 7.

Rhythmic oscillation of the eyes is called nystagmus and can be both physiologic and pathologic. Typically, there is a jerking movement with both a fast phase and a slow phase. It is best to assess whether nystagmus is present with the eyes in a neutral position and then with looking to the left and right. At extremes of lateral gaze, some horizontal nystagmus is normal; thus, it is best to assess for pathological nystagmus in acutely dizzy patients when looking ~45 degrees laterally. Pathological nystagmus can be overcome by fixation, producing a false-negative finding, which can be prevented by placing a piece of white paper in the field of view. Frenzel goggles also help prevent this while magnifying the eyes and making nystagmus much easier to visualize. Peripheral causes of acute vestibular syndrome typically produce a horizontal, unidirectional nystagmus, whereas benign paroxysmal, positional vertigo (s) more classically causes a torsional, horizontal-rotatory nystagmus. Vertical nystagmus can be seen in phenytoin toxicity but should be considered a central pathological lesion until proven otherwise.

Most commonly, nystagmus will be observed to be horizontal and unidirectional and will be from a peripheral cause. The fast phase typically beats in the direction of the unaffected ear. In patients with acute-onset and sustained vertigo, testing of the oculocephalic reflex (aka head impulse test) and for vertical skew deviation on

alternating cover test can reliably exclude a central lesion such as a brainstem stroke as the cause of vertigo. This battery of tests is called the HINTS exam and when performed correctly may be more sensitive than diffusion-weighted MRI in the detection of stroke among high-risk acutely dizzy patients [10]. The head impulse test is performed by rapidly rotating the head from either center to lateral or lateral to center approximately 10° and assessing whether the patient is able to maintain his/her gaze on a fixed object (such as the examiner's nose) without catch-up saccade-like movements being observed. The presence of saccades in one direction and failure to maintain a fixed gaze are abnormal findings and suggest a peripheral lesion, such as vestibular neuronitis or labyrinthitis. The alternating cover test assesses whether the patient can maintain gaze on a fixed object while one eye is covered in an alternating fashion. Refixation up and down suggests hypertropia/hypotropia and is a rare but abnormal finding. Horizontal refixation, on the other hand, is most often a normal finding associated with amblyopia.

Trigeminal Nerve (CN V): Assess for sensation on the face and strength in the muscles of mastication. The trigeminal nerve has ophthalmic, maxillary, and mandibular branches and controls touch and temperature sensation throughout the face. The corneal reflex can be tested when patients are unable to communicate sensory findings. Having the patient clench his/her teeth and open/close the mouth tests the muscles of mastication. The jaw jerk reflex tests both sensory afferents and motor efferents.

Facial Nerve (CN VII): Assess the muscles of facial expression. While the facial nerve contains motor, autonomic, and sensory fibers, testing the sense of taste on the anterior two-thirds of the tongue is beyond the scope of most ED neurological exams. Instead, having the patient smile, grimace, wrinkle the forehead, close eyes tightly, show teeth, and wiggle the nose is sufficient. When facial muscles are weak, a flattening of the nasolabial fold may be the first sign. A peripheral lesion (such as Bell's palsy) will typically involve the forehead, whereas a central lesion (such as stroke) spares the forehead and predominantly affects the lower face.

Acoustic Nerve (CN VIII): Assess the hearing component briefly by making a soft sound in each ear individually. Examples include clicking a disposable otoscope specula with one's fingernail or rubbing two fingers together. The use of a tuning fork in the ED is seldom necessary. The vestibular component can be interrogated in patients suspected of having positional vertigo with provocative testing followed by canalith repositioning techniques. Since most (85–90%) of BPPV involve the posterior semicircular canal, the Dix-Hallpike test should be performed first, leading into the Epley maneuver if posterior BPPV is confirmed. If unsuccessful, then assessing the horizontal semicircular canal with the spine roll test is reasonable, followed by the Lempert roll if horizontal BPPV is confirmed.

Glossopharyngeal (CN IX) and Vagus (CN X) Nerves: Simply ask the patient to open his/her mouth and say "ah" while looking for symmetry of the palate and midline position of the uvula. Weakness of the palate may lead to dysarthric speech and impairment of saying words with the letter "k" [11]. Swallowing function may be

impaired in patients with lesions to CN IX and X. If swallowing is impaired or the patient has a decreased level of consciousness or suspected brainstem pathology, consider also assessing the gag reflex.

Accessory Nerve (CN XI): Since this innervates the trapezius and sternocleidomastoid muscles, having the patient shrug the shoulders against resistance and turn the head from lateral to center against resistance should be sufficient.

Hypoglossal Nerve (CN XII): Look for symmetric protruding of the tongue, or have the patient push his/her tongue against the wall of the mouth while the examiner pushes back against the cheek. Having the patient say “La La La” rapidly is also reasonable [12].

Sensory Function

Sensation is divided into light touch, pinprick, position, vibration, and temperature modalities. While it would be impractical to test each modality in every patient, those with acute abnormalities in touch sensation should prompt further interrogation of the additional sensation subtypes. Adequate position sense assesses the spinal posterior column, making vibration testing redundant. Hence, a tuning fork is seldom needed in the ED setting. Altered sensation may either be heightened (hyperesthesia), reduced (hypoesthesia), or absent (anesthesia). When a sensory level is identified, a skin marker can be used for labeling. The examiner should then decide whether the lesion follows a specific dermatome or is more indicative of a polyneuropathy, myelopathy, or central lesion. Cortical sensory modalities include two-point discrimination, graphesthesia (recognizing letters written on the skin), stereognosis (tactile recognition of an object), and tactile extinction during double simultaneous stimulation.

Motor Function

Pronator drift is assessed in each limb individually with the eyes closed. The arms are held outstretched with palms facing up for 10 s. Subtle weakness may initially manifest with abduction of the pinky finger followed by hand pronation and then arm drift downward. The legs are assessed in a supine patient by active hip flexion upward a few inches off the bed for 5 s. Muscle strength can be further assessed by testing both sides simultaneously. Interossei muscles, grip, wrist flexion and extension, elbow flexion and extension, shoulder flexion and extension, and abduction and adduction should all be assessed when upper extremity weakness is reported or when a cervical spinal lesion is suspected. Similarly, plantar and dorsiflexion, knee flexion and extension, hip flexion and extension, and abduction and adduction should be assessed when lower extremity weakness is reported or a lumbar lesion is suspected. Table 1.6 outlines the grading of muscle strength using the Oxford scale.

Table 1.6 The Oxford scale of muscle strength

Muscle strength grading scale (Oxford scale)	
0/5	No contraction
1/5	Visible/palpable muscle contraction but no movement
2/5	Movement with gravity eliminated
3/5	Movement against gravity only
4/5	Movement against gravity with some resistance
5/5	Movement against gravity with full resistance

The presence of abnormal motor movements should be assessed for tremor, fasciculations, and repetitive movements including automatisms. This is best done while the limb is at rest and during movement. Muscle tone can be assessed by passive movements of the patient's joints. Note should be made of rigidity, spasticity, hypotonia, and flaccidity. Muscle groups can be assessed for asymmetric wasting and atrophy. In general, upper motor neuron lesions cause increased muscle tone and hyperreflexia, whereas lower motor neuron lesions cause decreased muscle tone, hyporeflexive reflexes, and atrophy.

Reflexes

Proprioceptive muscle stretch reflexes such as the biceps, triceps, brachioradialis, quadriceps, and Achilles are performed to confirm the integrity of a reflex arc. Though they are of little use in isolation, taken together with strength, tone, and sensation, reflexes are a helpful and often necessary component of the neurological exam. Deep tendon reflexes are graded on a scale from 0 to 4, with 0 denoting areflexia and 4 being significantly hyperreflexic with clonus. Polysynaptic nociceptive reflexes include the Babinski, cremasteric, bulbocavernosus, and anal wink, which are generally reserved for cases when acute spinal cord damage is suspected.

Coordination and Gait

The cerebellum is responsible for orchestrating oppositional muscle function to form fluid and smooth body movements. The central cerebellum (vermis) controls posture and truncal movements and is best tested by assessing for truncal and gait ataxia. The lateral cerebellum (cortex) oversees oppositional muscle coordination and is best tested with rapid alternating movements, dysmetria (finger to nose, heel to shin), and cerebellar rebound testing. Loss of smooth pursuit of eye movements across the visual fields and impaired articulation of speech can be signs of cerebellar dysfunction and will have likely been tested in other parts of the neurological exam.

Putting It All Together

In clinical practice, a thoughtful neurological examination in the ED should take far less time to perform than to read about. One strategy for purposes of efficiency is to incorporate multiple components of the exam simultaneously starting at the patient's head and working toward the toes. The following sequence is one example that incorporates most of what has been discussed and should be sufficient for nearly any neurologic complaint.

1. Start with mental status if not already elucidated during the patient interview. Is the patient awake and alert, easily arousable, drowsy, lethargic, obtunded, or comatose? Is he/she communicative, oriented, and aware of surroundings and situation? Is speech fluent and appropriate and thought content normal? Can the patient repeat words and appropriately identify and recall objects? **Questions:** *What is your full name? Where were you born? Where are you right now? What month is it? Who is the current President of the United States? What is this in my hand that I might use to write my name? Please repeat after me: no ifs, ands, or butts....what was it I was holding in my hand?*
2. Next examine the eyes. Note pupillary response to light and perform the swinging flashlight test. Check extraocular movements, assess for presence and type of nystagmus, and check the visual fields. Perform a fundoscopic exam to exclude papilledema.
3. Proceed to assess facial movements and symmetry. Have the patient smile, grimace, puff out the cheeks, and protrude the tongue and move it side to side. Have the patient close his/her eyes forcefully against resistance from opening by your hands. While touching the face, now assess for symmetry in facial sensation. Then have the patient shrug the shoulders against resistance and turn his/her head from lateral to center against resistance. Palpate the face and skull for abnormalities including for tenderness over the temporal arteries. Visualize the tympanic membranes and, in cases of trauma, exclude Battle sign, raccoon eyes, and hemotympanum. Use the otoscope speculum to assess CN VIII.
4. Proceed caudally to the upper extremities. Assess for pronator drift, then grip strength, and then strength of the shoulders, elbows, wrists, hands, and fingers. With fingers apart, have the patient mimic playing the piano (a test for coordination) and then finger-to-nose test and rapid alternating movements. Place the arms at the side and test sensation in a spiraling fashion distally, so as to not follow a single dermatome. Perform double simultaneous tactile stimulation to assess for inattention, and then do the same in the lower extremities.
5. Having moved on to the legs, test again for sensation, paying special attention to the saddle distribution in patients with back pain or leg weakness. Assess for pronator drift in the legs and then strength in the toes, feet, ankles, knees, and hips. Check heel-to-shin coordination and then patellar and Achilles reflexes.

6. While holding your reflex hammer, move back to the biceps, triceps, and brachioradialis; then, while holding the patient's arm, help him/her up if able to assess for ataxia and gait.
7. Lastly, complete the neurological exam with visual acuity if needed or with the visual items of the NIHSS if one is being scored.

Special Circumstances

Patients who are unable to participate may make parts of the aforementioned exam more difficult to interpret. Pupillary and corneal reflexes, as well as deep tendon and superficial reflexes, should be preserved. Visual field testing can be performed by assessing visual response to threat, and sensation can be assessed by response to painful stimuli.

Pearls and Pitfalls

- Many components of a neurological examination can be observed in the initial moments of a patient's interview.
- Some components of a neurological examination can be assessed simultaneously, and moving from head to toe is one way to streamline the exam in the emergency setting.
- Dizzy patients should always have gait assessed. If the patient is unable to ambulate, assessing for truncal ataxia can be a substitute.
- Fundoscopy is part of an optic nerve exam and should be considered in patients complaining of headache or visual disturbance.

References

1. National Hospital Ambulatory Medical Care Survey: 2013 Emergency Department Summary Tables. *Natl Hosp Ambul Med Care Surv 2013 Emerg Dep Summ Tables*. 2013. https://www.cdc.gov/nchs/data/ahcd/nhamcs_emergency/2013_ed_web_tables.pdf. Accessed 3 Mar 2017.
2. Daroff RB, Jankovic J, Mazziotta JC, Pomeroy SL. Diagnosis of neurological disease. In: *Bradley's neurology in clinical practice*. 7th ed. Philadelphia: Elsevier; 2016. p. 1–7.
3. Henry GL, Little N, Andrew J, Pellegrino TR, Quint DJ. Initial evaluation of a neurologic complaint. In: *Neurologic emergencies*. 3rd ed. New York: McGraw-Hill; 2010. p. 67–88.
4. Gelb DJ. The neurological examination. In: *Introduction to clinical neurology*. 3rd ed. Philadelphia: Elsevier; 2005. p. 43–92.
5. Huff JS, Perron AD. The neurologic examination in the emergency setting. In: *Tintinalli's emergency medicine: a comprehensive study guide*, 8th ed. New York: McGraw-Hill; 2016:1125–1130.
6. Kreitzer N, Adeoye O. Intracerebral hemorrhage in anticoagulated patients: evidence-based emergency department management. *Emerg Med Pract*. 2015;17(12):1–24.

7. Blaivas M, Theodoro D, Sierzenski P. Elevated intracranial pressure detected by bedside emergency ultrasonography of the optic nerve sheath. *Acad Emerg Med*. 2003;10(4):376–81.
8. Hassen G, Bruck I, Donahue J, et al. Accuracy of optic nerve sheath diameter measurement by emergency physicians using bedside ultrasound. *J Emerg Med* 2015;48(4):450–457.
9. Geeraerts T, Launey Y, Martin L, et al. Ultrasonography of the optic nerve sheath may be useful for detecting raised intracranial pressure after severe brain injury. *Intensive Care Med*. 2007;33(10):1704–11.
10. Kattah JC, Talkad AV, Wang DZ, Hsieh YH, Newman-Toker DE. HINTS to diagnose stroke in the acute vestibular syndrome: three-step bedside oculomotor examination more sensitive than early MRI diffusion-weighted imaging. *Stroke*. 2009;40(11):3504–10. doi:[10.1161/STROKEAHA.109.551234](https://doi.org/10.1161/STROKEAHA.109.551234).
11. Aminoff MJ, Greenberg DA, Simon RP. Neurologic history & examination. In: *Clinical neurology*. 9th ed. New York: McGraw-Hill; 2015. p. 1–34.
12. LeBlond RF, Brown DD, Suneja M, Szot JF. The neurologic examination. In: *DeGowin's diagnostic examination*. New York: McGraw-Hill; 2015. p. 600–27.
13. Teasdale G, Jennett B. Assessment of coma and impaired consciousness. A practical scale. *Lancet*. 1974;2:81–4.

Aunali S. Khaku and Sayed K. Ali

Case Presentation

A 70-year-old retired male with a history of hypertension, hyperlipidemia, and type II diabetes mellitus presented to the emergency department (ED) at the insistence of his wife. His wife had noticed that “he was not talking right.” In addition, he had spilt his coffee that morning, acting clumsier than normal. On further questioning, he endorsed difficulty getting words out and that his right hand seemed weaker than usual. The symptoms started abruptly at breakfast, waxing and waning for the last 2 h. He denied any pain, fever, or chills. His medications included lisinopril, metformin, and simvastatin. He denied current tobacco use (quit about 10 years ago) and drank a few beers socially on the weekends. He had a brother who had a brain tumor. He denied allergies, recent surgical procedures, or using any over-the-counter medications.

His vital signs on presentation were normal except for a blood pressure of 160/70 mm Hg. He was alert and oriented but had difficulty naming objects and repeating phrases and had a paucity of words (nonfluent). His smile was asymmetric, with a subtle right lower facial droop. Strength testing bilaterally appeared grossly normal, but he had a subtle right pronator drift. Visual field testing suggested a right upper quadrant visual deficit. NIH Stroke Scale (NIHSS) was calculated as a 6. A non-contrast computed tomography (CT) scan of the head did not show any major abnormalities or bleeds.

The patient had no contraindications for intravenous (IV) recombinant tissue plasminogen activator (rtPA), and after an informed consent was obtained, rtPA was

A.S. Khaku, M.D. (✉)

University of Central Florida College of Medicine (UCF), Orlando, FL, USA

e-mail: aunalikhaku@gmail.com

S.K. Ali, M.D.

Aga Khan University Hospital, Nairobi, Kenya

University of Central Florida, College of Medicine, Orlando, FL, USA

e-mail: Sayed.Ali@va.gov

administered without any issues. The patient was subsequently admitted to the ICU for monitoring. A magnetic resonance image (MRI) of the brain, 24 h later, showed a left middle cerebral artery (MCA) infarction. A bilateral carotid ultrasound did not reveal any significant stenosis or plaques. A transthoracic echocardiogram showed a normal left ventricular ejection fraction with mild valvular abnormalities but no thrombus. No patent foramen ovale was identified. His presenting electrocardiogram and subsequent telemetry monitoring did not identify any causative rhythm such as atrial fibrillation. The patient was started on an antiplatelet agent (clopidogrel). His deficits improved mildly over the course of his hospital stay. He was subsequently discharged with home physical and speech therapy after a full stroke workup.

Differential Diagnosis

- Ischemic stroke (including thrombotic, embolic, and lacunar strokes)
- Hemorrhagic stroke (including hypertensive hemorrhage, aneurysm or AVM rupture, amyloid angiopathy, etc.)
- Transient ischemic attack (TIA)
- Subarachnoid hemorrhage
- Cerebral tumor or mass lesion
- Seizure or postictal state
- Metabolic perturbations: hypoglycemia, hyponatremia, hyperglycemia
- Complicated migraine
- Alcohol or drug ingestion or intoxication
- Infectious: meningitis, encephalitis, abscess, or empyema
- Hypertensive encephalopathy
- Wernicke's encephalopathy
- Psychiatric: psychogenic, conversion disorder, malingering or fugue states

Definition

Stroke can be defined as an acute focal neurologic deficit caused by a compromise of the cerebral perfusion or vasculature. That is why strokes are often also referred to as cerebrovascular accidents (CVA). In general, strokes can be divided into ischemic or hemorrhagic, with ischemic strokes being more common. This chapter will focus primarily on ischemic stroke.

The most common cause of an acute focal neurologic deficit is ischemic stroke. Although the incidence of stroke is increasing globally, the mortality has decreased. Stroke is now the fifth leading cause of mortality in the United States [1]. While mortality has decreased, stroke is still the leading cause of adult disability worldwide. It is critical to recognize stroke early and treat it rapidly in order to prevent or minimize morbidity and mortality. Emergency department (ED) patients with suspected acute stroke should be triaged with the same priority as patients with acute myocardial infarction or serious trauma.

With acute imaging readily available, the diagnosis of ischemic stroke is less cryptic than before. However, if no obvious lesion is visualized on neuroimaging, as is often the case in early strokes and TIAs, one must carefully revisit the differential diagnosis. The most important action remains deciding whether the event is ischemic in nature (i.e., an ischemic stroke or TIA) or not. If it is an ischemic event, the most urgent question for the emergency physician is whether or not the patient qualifies for thrombolysis with IV rtPA, intra-arterial (IA) rtPA, or an interventional endovascular clot retrieval/lysis procedure. The flow chart below summarizes the triaging process in a suspected stroke patient (Fig. 2.1).

The neurological literature refers to “stroke mimics” and “stroke chameleons.” Stroke mimics are manifestations of a nonvascular disease where a stroke-like clinical picture is produced. Stroke chameleons are actual strokes with an atypical presentation resembling other disease processes [2]. For the ED physician, it is paramount to recognize both but critical not to miss the stroke chameleons as strokes in general are considered more injurious and potentially treatable, whereas several of the mimics are not. Furthermore, the administration of rtPA to entities that are not stroke is generally considered safer than not giving rtPA to an ischemic stroke patient based on several studies that have documented a very low risk of hemorrhage when rtPA is administered to stroke mimics (1–2%) as compared to the benefit in acute ischemic stroke [3].

Finally, in several medicolegal analyses, it was clearly demonstrated that the potential for a lawsuit is much higher for failure to administer rtPA than for administering rtPA with adverse outcomes [4, 5].

A TIA generally refers to an ischemic event that lasts momentarily, with full resolution of symptoms. While the prior definition of TIA involved time (24 h), with MRI now widely available, the definition of TIA is evolving, and a presumed ischemic event with no MRI evidence of ischemia (a negative diffusion-weighted image) may be considered a true TIA by imaging [6]. There is robust evidence to suggest

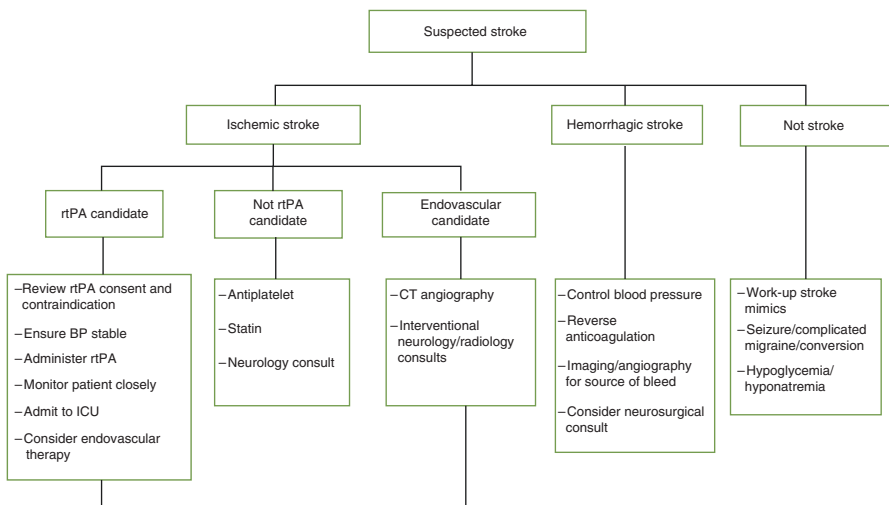


Fig. 2.1 Suspected stroke algorithm

that the risk of an ischemic stroke is highest in the first 48 h following a TIA [7]. A score sometimes used in the primary care setting known as the ABCD or ABCD2 score can be used to forecast the likelihood of a TIA progressing to a stroke. However, the score is based solely on historical factors and has poor sensitivity and specificity [8]. Given the seriousness of a TIA, urgent evaluation including imaging, laboratory, and ECG is necessary [9] and allows more effective triage. Most TIA patients are thus admitted to have a full ischemic workup. In some institutions, TIA is worked up in an emergency department observation unit, where the bulk of the workup is completed without full hospital admission, and there is close neurology follow-up [10].

If the event was determined not to be ischemic in nature, it is important to ensure a cause for the symptoms is elucidated. Foregoing this could result in the patient's neurovascular evaluation most likely ending with the current ED visit, and the patient would probably not have subsequent evaluations to detect possible underlying cerebrovascular pathology. Among the entities mentioned above in the differential diagnosis for acute ischemic stroke, several may be identified by neuroimaging. For instance, hemorrhagic strokes will likely show up as obvious hyperdensities on a non-contrasted CT scan of the head. A hyperacute intracranial bleed may present with a negative CT, but if suspicion remains, the image may be repeated, or an MRI with special attention to the gradient echo sequence (GRE) or the susceptibility-weighted image (SWI) may be done, and this will identify bleeds with high accuracy [11, 12].

The most common stroke mimics are seizures and postictal states, followed by conversion disorder [13]. Conversion disorders are a diagnosis of exclusion, but a history of psychiatric illness or prior hospital visits with vague broad symptoms and negative workups may clue the physician to the possibility of conversion.

Subtle clues in the history and exam may point to a diagnosis of seizures. A history of shaking or "tremor" prior to the event, incontinence, or a known history of epilepsy should clue the physician to consider seizure. On exam, facial trauma, tongue biting, blood from the mouth, or subtle nystagmus may suggest seizure. An EEG would also be helpful in this situation.

Cerebral tumors or mass lesions may be visualized on a CT scan, although a contrasted MRI is more sensitive. While strokes generally follow classic vascular territories and are often wedge shaped, tumors generally do not exhibit this pattern. On exam, patients with cerebral tumors often have "upper motor neuron" signs such as spasticity, hyperreflexia, and a positive Babinski sign suggesting a long-standing lesion. In acute strokes, such signs are absent.

Metabolic perturbations such as hypoglycemia, hyponatremia, and hyperglycemia may produce transient acute focal neurologic deficits that may mimic stroke. These tend to be apparent after screening labs are available and generally resolve with correction of the electrolyte abnormalities. Risk factors such as diabetes in the case of glucose abnormalities, or use of certain medications, may key the ED

physician in the direction of an electrolyte abnormality. It is important to remember that thiamine should always be given prior to glucose when correcting hypoglycemia. Hyponatremia should always be worked up as it may be caused by other underlying, sometimes serious, medical conditions.

Complicated migraines are also a diagnosis of exclusion. Negative imaging, in the presence of a classical history of migraines, without cerebrovascular risk factors may clue the physician to this diagnosis.

Alcohol or drug ingestion or intoxication may sometimes mimic a stroke. Often the presence of alcohol on the breath or track marks in the case of IV drug use is a useful clue that points to a drug-related etiology. In cases where the index of suspicion is high, a urine drug screen and serum alcohol level may be helpful. Certain drugs such as cocaine, amphetamines, and synthetic cannabinoids have been shown to increase the risk of stroke.

If there is prominent fever, leukocytosis, a history of travel, or insect bite, one must consider infectious etiologies such as meningitis, encephalitis, abscess, and empyema. Imaging, labs, and spinal fluid analysis are often helpful in clinching the diagnosis.

Acute and sudden headaches, with the classic “worst headache of my life,” suggest subarachnoid hemorrhage. A non-contrasted head CT is sensitive for detecting this, but a negative head CT in the right clinical setting should not rule out a subarachnoid. The physician may consider a spinal tap or an MRI with the GRE and SWI sequences or a repeat CT scan some time later to confirm clinical suspicion.

In patients with untreated or suboptimally treated hypertension, acute focal neurologic deficits may occur when the blood pressure rises too high, secondary to failed autoregulation of the cerebral perfusion mechanisms. Often the posterior circulation is more involved, and confusion or encephalopathy is commonly seen, hence the diagnosis posterior reversible encephalopathy syndrome (PRES). A history of certain immunologic therapies also has been associated with cases of PRES in the literature. CT perfusion and diffusion-weighted MRI are useful in the diagnosis [14].

The following table from the AHA/ASA guidelines on acute ischemic stroke summarizes the differential diagnosis of stroke (Fig. 2.2).

History

The single most important piece of historical information that the ED physician should ascertain is the time of symptom onset or time last seen normal [15]. It is important to accurately obtain this information, as it determines the eligibility to receive rtPA or endovascular intervention for stroke. If the patient awoke with the symptoms (wake-up stroke), then the time last normal is presumed to be the time they were last awake and normal. Often patients awake in the night to use the

Fig. 2.2 Differential diagnosis of stroke [15]

Psychogenic	Lack of objective cranial nerve findings, neurological findings in a nonvascular distribution, inconsistent examination
Seizures	History of seizures, witnessed seizure activity, postictal period
Hypoglycemia	History of diabetes, low serum glucose, decreased level of consciousness
Migraine with aura (complicated migraine)	History of similar events, preceding aura, headache
Hypertensive encephalopathy	Headache, delirium, significant hypertension, cortical blindness, cerebral edema, seizure
Wernicke's encephalopathy	History of alcohol abuse, ataxia, ophthalmoplegia, confusion
CNS abscess	History of drug abuse, endocarditis, medical device implant with fever
CNS tumor	Gradual progression of symptoms, other primary malignancy, seizure at onset
Drug toxicity	Lithium, phenytoin, carbamazepine

bathroom or get a drink of water. If the patient or their family endorses that they were normal at this time, this may be used as the time last normal. Often patients report symptoms that occurred and then resolved completely. In this case the time of onset is reset to the time the symptoms recurred.

It is important to inquire about risk factors for arteriosclerosis and cardiovascular disease, drug abuse, migraine, seizures, infection, trauma, or pregnancy. Emergency medical personnel, bystanders, and family witnesses play a critical role in providing this information especially when the patients are unable to.

The above case illustrates several key points in the history that suggest ischemic stroke as a cause of the symptoms:

- Acuity of event (strokes tend to be acute or acute in onset).
- Focal neurologic deficit (arm weakness, aphasia, hemianopia, etc. are focal neurologic deficits that are common in stroke). Global deficits such as confusion are not common presenting signs of stroke and suggest other etiologies such as seizure or metabolic perturbations.
- Absence of pain: in general, barring arterial dissections, and the rare thalamic pain syndrome, strokes are painless. Hence, pain as a prominent complaint should prompt the physician to search for alternative causes. A thunderclap headache or “worst headache of my life” suggests subarachnoid or intracranial hemorrhage. Prominent neck pain or a history of possible neck injury (from chiropractic manipulation, motor vehicle collision, or martial arts) points to arterial dissection.
- Risk factors: older age, presence of cardiovascular risk factors such as hypertension, hyperlipidemia, and diabetes all increase the likelihood of stroke on the differential. Other risk factors increasing the likelihood of stroke include a history of smoking, coronary artery disease, a family history of stroke, obesity, atrial fibrillation, etc.

Table 2.1 Key points in the history to differentiate stroke from stroke mimics

History	Stroke	Stroke mimic
Acuity	Sudden or acute	Gradual or subacute
Neurologic deficit	Focal	Global
Pain	Absent	Possibly present
Symptoms	Negative	Positive
Risk factors	Hypertension, hyperlipidemia, atrial fibrillation, diabetes, smoking, obesity	Variable

- Positive versus negative symptoms: in general strokes present with negative symptoms, i.e., numbness as opposed to paresthesia and weakness as opposed to tremor or seizure (Table 2.1).

Physical Examination

The stroke exam is a multi-person coordinated rapid exam. While ancillary staff obtain vitals, connect the patient to telemetry, and obtain IV access, the physician performs the rapid neurological evaluation. It is quintessential to do a thorough exam in order not to miss subtle lesions, yet it is also necessary to do a very rapid evaluation as the adage “time is brain” is literally true in ischemic stroke. It is estimated that every minute, two million brain cells die [16]. Ideally one must at the bare minimum examine the following key elements:

- Level of consciousness (alert and responsive, arouses to noxious stimuli, comatose)
- Language (fluency, naming, comprehension, repetition)
- Dysarthria (slurring) which may be picked up in the history
- Motor (subtle arm weakness can be picked up by performing a pronator drift)
- Visual field deficits
- Eye movement abnormalities (in general if a gaze preference is present, the eyes are deviated toward the side of the lesion)
- Facial paralysis (asking patient to smile)
- Ataxia (finger to nose)

Probably the best neurological exam for an acute stroke is the NIH Stroke Scale (NIHSS). While it was initially developed for research purposes, it has fast become the exam of choice for acute stroke and provides a convenient, reliable, and validated quantitative measure, which correlates well with the size of stroke and with prognosis after stroke [17]. It also provides valuable information that can help stratify patients for various interventions [18]. The American Heart Association (AHA) and American Stroke Association (ASA) recommend using the NIHSS as a standard exam for all stroke patients [15]. The NIH Stroke Scale is as below (Fig. 2.3).

The sentences, images, and word lists that follow are often used as part of the NIHSS in the evaluation of speech and language [20].

Fig. 2.3 NIH Stroke Scale from the National Institute of Neurological Disorders and Stroke and AHA/ASA guidelines on acute stroke [15, 19]

Tested item	Title	Responses and scores
1A	Level of consciousness	0—Alert 1—Drowsy 2—Obtunded 3—Coma/unresponsive
1B	Orientation questions (2)	0—Answers both correctly 1—Answers 1 correctly 2—Answers neither correctly
1C	Response to commands (2)	0—Performs both tasks correctly 1—Performs 1 task correctly 2—Performs neither
2	Gaze	0—Normal horizontal movements 1—Partial gaze palsy 2—Complete gaze palsy
3	Visual fields	0—No visual field defect 1—Partial hemianopia 2—Complete hemianopia 3—Bilateral hemianopia
4	Facial movement	0—Normal 1—Minor facial weakness 2—Partial facial weakness 3—Complete unilateral palsy
5	Motor function (arm) a. Left b. Right	0—No drift 1—Drift before 5 s 2—Falls before 10 s 3—No effort against gravity 4—No movement
6	Motor function (leg) a. Left b. Right	0—No drift 1—Drift before 5 s 2—Falls before 5 s 3—No effort against gravity 4—No movement
7	Limb ataxia	0—No ataxia 1—Ataxia in 1 limb 2—Ataxia in 2 limb
8	Sensory	0—No sensory loss 1—Mild sensory loss 2—Severe sensory loss
9	Language	0—Normal 1—Mild aphasia 2—Severe aphasia 3—Mute or global aphasia
10	Articulation	0—Normal 1—Mild dysarthria 2—Severe dysarthria
11	Extinction or inattention	0—Absent 1—Mild (loss 1 sensory modality lost) 2—Severe (loss 2 modalities lost)

Sentences for 9. Best Language (Fig. 2.4)

You know how.
Down to earth.
I got home from work.
Near the table in the dining room.
They heard him speak on the radio last night.

Picture for 9. Best Language (Fig. 2.5)

Word List for 10. Dysarthria [20]

Mama
Tip-Top
Fifty-Fifty
Thanks
Huckleberry
Baseball player

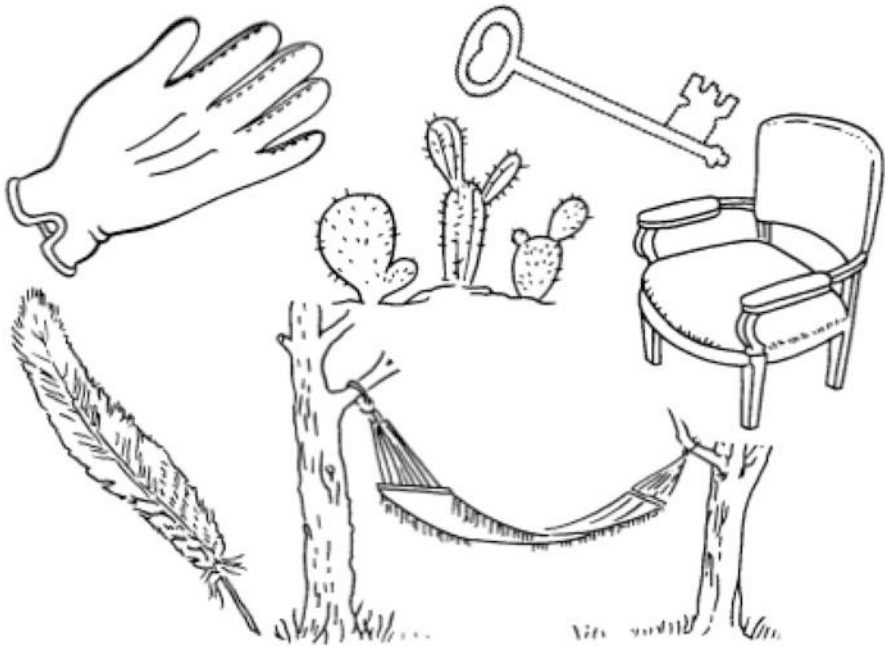


Fig. 2.4 Naming sheet for NIH Stroke Scale question 9 from NINDS (Adapted from Harold Goodglass. *The Assessment of Aphasia and Related Disorders*. Philadelphia, Pa: Lea & Febiger; 1972) [20]

Emergency Department Workup

The initial ED workup of a stroke patient involves stabilizing the airway, breathing, and circulation (ABC). This is followed by a rapid, concise, history and exam such as the NIHSS which is administered simultaneously as the patient gets IV access, telemetry, and stat labs drawn. The patient should then be immediately transported to the CT scanner where, depending on protocol, either a non-contrasted brain CT or a combination of brain CT, CT angiography, and perfusion imaging is obtained. Ideally, rtPA should be prepared as imaging is occurring, and as soon as the non-contrasted head CT can be visualized and a bleed is excluded, rtPA should be administered after discussing the risks and benefits and excluding rtPA contraindications. Time is critical, as only patients who get all the required studies within 4.5 h qualify for potentially lifesaving thrombolysis. The 2013 AHA/ASA guidelines suggest having a systematic stroke protocol in the ED [15]. Although evidence for specific time goals for various activities vis-à-vis stroke in the emergency department is lacking, the guidelines provide the following as a suggestion (Table 2.2).

It is important to note that after administration of IV rtPA, the CT angiography should be reviewed in order to determine if the patient qualifies for endovascular therapy as well. Patients ineligible for IV rtPA may still qualify for endovascular

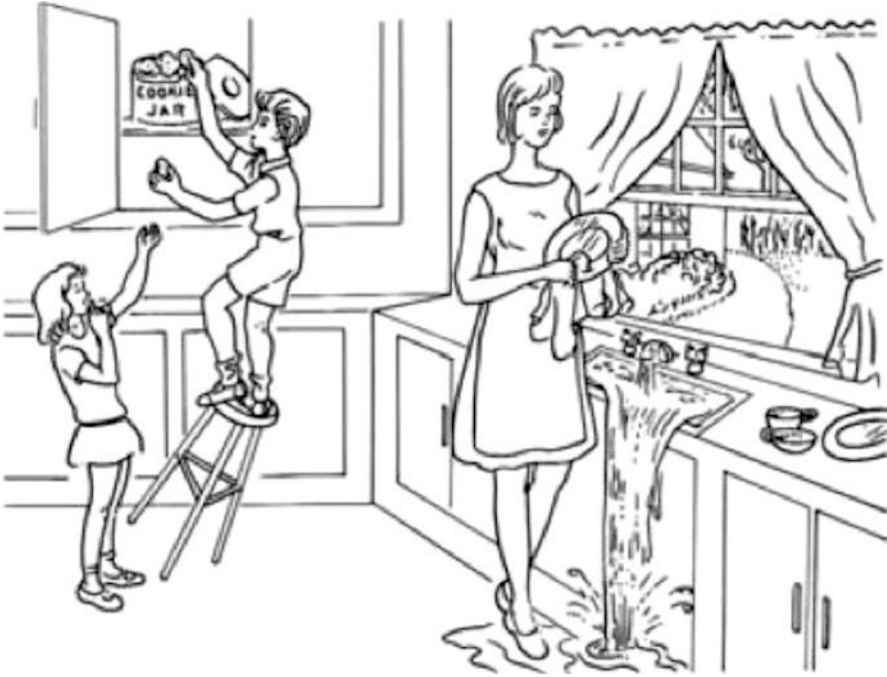

Fig. 2.5 Receptive aphasia evaluation: from NINDS (Adapted from Harold Goodglass. *The Assessment of Aphasia and Related Disorders*. Philadelphia, Pa: Lea & Febiger; 1972) [20]

Table 2.2 Suggested time frames for various ED activities in relation to acute stroke (Adapted from the 2013 AHA/ASA guidelines on acute stroke [15])

Action	Time
Door to physician	≤10 min
Door to stroke team	≤15 min
Door to CT initiation	≤25 min
Door to CT interpretation	≤45 min
Door to drug	≤60 min
Door to stroke unit admission	≤3 h

therapy alone if they meet certain criteria. Currently the criteria include a maximum time to groin puncture of 6 h, along with significant deficits (NIH Stroke Scale greater than 6) and imaging suggestive of a large-vessel occlusion [18]. Patients who do not qualify for rtPA or intervention should be treated with an anti-platelet agent and a statin and be admitted for a full stroke evaluation and secondary stroke prevention.

Vital Signs

Hypertension is often seen in acute stroke. This should not be aggressively treated as it is felt to be compensatory to help increase blood flow to ischemic brain tissue. The AHA/ASA guidelines suggest not to lower the blood pressure (BP) for the first

Table 2.3 Blood pressure parameters in stroke (Adapted from the 2013 AHA/ASA guidelines on acute stroke [15])

Situation	24 h blood pressure goal
Ischemic stroke, no rtPA	<220/120
Before administering rtPA	<185/110
After administering rtPA	<180/105

Patient otherwise eligible for acute reperfusion therapy except that BP is >185/110 mm Hg:

- Labetalol 10–20 mg IV over 1–2 min, may repeat 1 time; or
- Nicardipine 5 mg/h IV, titrate by 2.5 mg/h every 5–15 min, maximum 15 mg/h; when desired BP reached, adjust to maintain proper BP limits; or other agents (hydralazine, enalaprilat, etc.) may be considered when appropriate
- If BP is not maintained at or below 185/110 mm Hg, do not administer rtPA

Management of BP during and after rtPA or other acute reperfusion therapy to maintain BP at or below 180/105 mm Hg:

- Monitor BP every 15 min for 2 h from the start of rtPA therapy, then every 30 min for 6h and then every hour for 16 h

If systolic BP >180–230 mmHg or diastolic BP >105–120 mm Hg:

- Labetalol 10 mg IV followed by continuous IV infusion 2–8 mg/min; or
- Nicardipine 5 mg/h IV, titrate up to desired effect by 2.5 mg/h every 5–15 min, maximum 15 mg/h
- If BP not controlled or diastolic BP >140 mm Hg, consider IV sodium nitroprusside

Fig. 2.6 Blood pressure lowering protocol for acute stroke before, during, and after rtPA administration [15]

24 h of acute ischemic stroke unless it exceeds 220/120 mm Hg or there is a definite medical reason to lower the BP. If the patient is a candidate for thrombolysis, cautious lowering of very high blood pressures would be indicated with labetalol being the first choice of drug for this. The AHA/ASA guidelines suggest that blood pressures above 185/110 should be cautiously lowered if rtPA is to be administered. After rtPA administration, it is also essential to ensure the blood pressure remains below 180/105 for the first 24 h [12]. The table below summarizes the blood pressure parameters recommended in stroke (Table 2.3).

The figure above summarizes the recommended therapy for lowering blood pressure in patients with hypertension who qualify for IV rtPA (Fig. 2.6).

Clinical Investigations

Laboratory Studies

At the bare minimum, the following labs would be indicated when a diagnosis of stroke is entertained:

1. Basic metabolic panel (BMP)
2. Complete blood count (CBC)
3. Cardiac markers
4. Coagulation profile: prothrombin time (PT), international normalized ratio (INR), and activated partial thromboplastin time (PTT)

If the patient is on anticoagulant medications like warfarin or a bleeding diathesis is suspected, then waiting for the coagulation profile is suggested. Elevated cardiac markers are not a contraindication for thrombolysis, and, in fact, serum cardiac markers are frequently elevated following strokes.

However, one should not wait for all laboratory results to initiate rtPA. The only laboratory indicated before rtPA is administered is the serum glucose, and a finger-stick evaluation suffices. This is because hypoglycemia may mimic a stroke and extreme hyperglycemia may increase the likelihood of a bleed after rtPA administration. A urine drug screen, arterial blood gas, pregnancy test, serum alcohol level, or liver function tests may be indicated in certain circumstances, depending on the clinical scenario.

Neuroimaging

At the bare minimum, a non-contrasted head CT is essential whenever stroke is suspected. The primary purpose of the CT is to rule out a hemorrhage, as this is an absolute contraindication for rtPA.

The head CT is often normal in acute stroke, although subtle signs on the CT may suggest an early stroke. These signs include:

1. Subtle loss of the gray matter/white matter distinction on the affected side (Fig. 2.7)
2. Edema: a more dense (dark)-looking area usually in a wedge shape following vascular territories
3. Hyperdense middle cerebral artery (MCA) sign (Fig. 2.8)
4. MCA dot sign (Fig. 2.9)

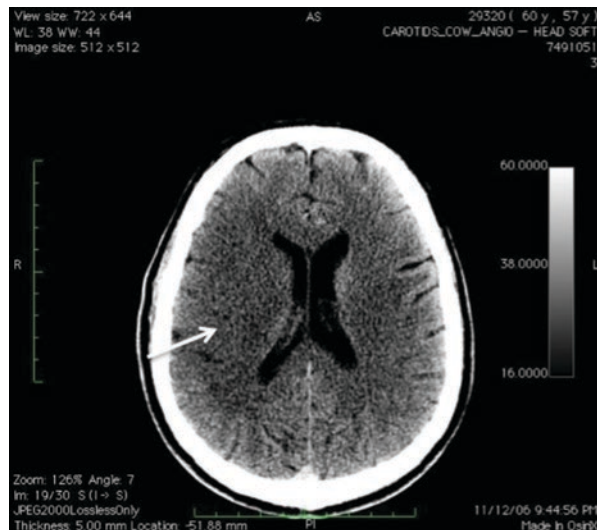

Fig. 2.7 Early signs of acute stroke: loss of gray-white differentiation and sulcal effacement in the right hemisphere (Reproduced with permission from the Alberta Stroke Program [22])

Fig. 2.8 Early signs of acute stroke on head CT: hyperdense MCA sign in right hemisphere (Reproduced with permission: case courtesy of Dr. Jones, <http://radiopaedia.org>. radiopaedia.org [23])

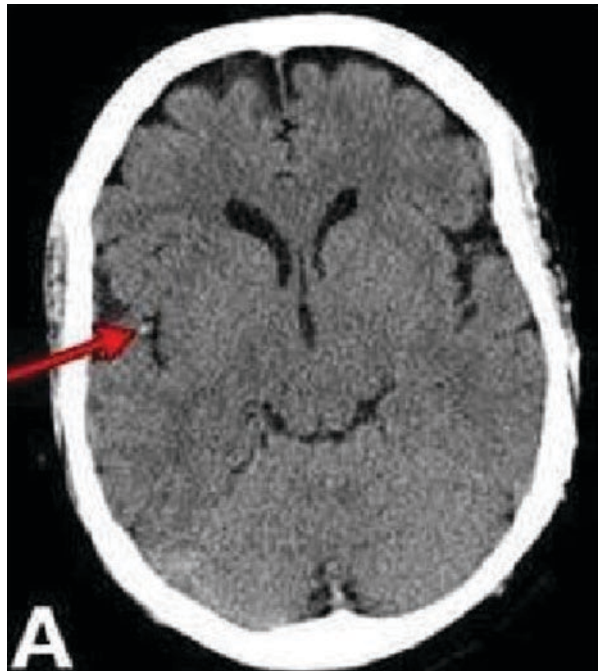
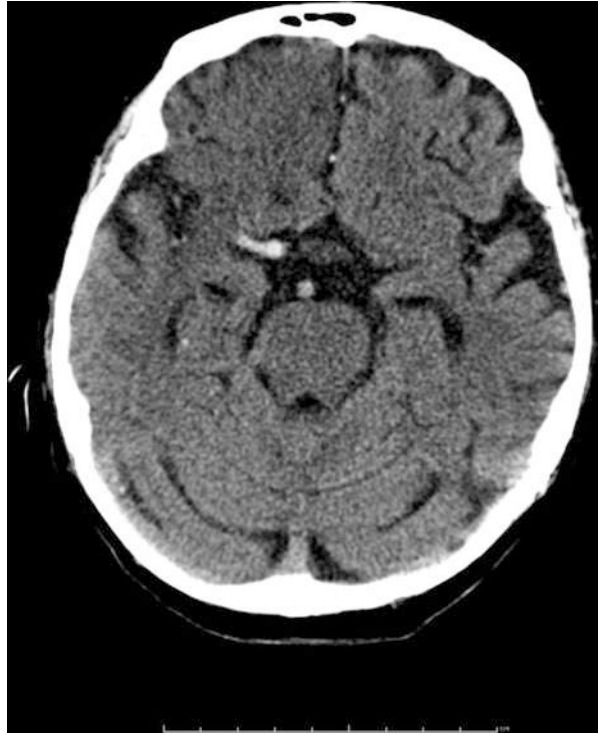

Fig. 2.9 Early signs of acute stroke on CT: MCA dot sign (*arrow*) in right hemisphere (Reproduced with permission from Stanley Medical College [24])

Many stroke centers now routinely do a combination of:

1. Non-contrasted head CT
2. CT angiogram of the head and neck
3. CT perfusion of the head

The rationale is that these additional studies do not add much in terms of time but often provide critical information that may aid the clinician in taking appropriate care of the patient. The CT angiogram is also necessary for determining if the patient qualifies for endovascular clot retrieval or thrombolysis. The CT angiogram may demonstrate a clot in a major blood vessel amenable to interventional clot retrieval.

The 2015 AHA/ASA supplemental guidelines for endovascular therapy of acute ischemic stroke suggested that patients should receive endovascular therapy if they meet all certain criteria (Table 2.4) [18]. However, for the ED physician, it is impractical to spend time calculating a modified Rankin Scale (mRS) and an Alberta Stroke Program Early CT Score (ASPECTS). Hence, we suggest that all patients should receive CT angiography (CTA), providing no contraindication to contrast. If angiography suggests a major blood vessel occlusion, the ED physician should consult interventional neurology or radiology for potential intervention. If CTA is contraindicated, then a magnetic resonance angiography (MRA) using gadolinium-based contrast may be done. The time-of-flight technique minimizes contrast exposure in this study. However, a caveat with MRA is that it can sometimes overcall stenosis and is thus most useful for ruling out major vessel occlusion. Conventional angiography, while being the gold standard to detect vessel occlusion, is invasive and is reserved for cases where neither CTA nor MRA is possible.

The gold standard study to definitively detect an ischemic stroke remains magnetic resonance imaging (MRI) of the brain. The diffusion-weighted image (DWI) sequence is very sensitive and can detect subtle ischemia—depicted as a hyperintensity—within minutes of clinical symptoms. However, obtaining an MRI in the acute stroke setting has its limitations including cost, limited availability of urgent MRI, length of study, susceptibility to motion artifact, claustrophobia, incompatibility with cardiac pacemakers, and metallic implants. The DWI image is compared to the corresponding apparent diffusion coefficient (ADC) map, which typically demonstrates a dropout (hypointensity) in the area of the infarct.

Table 2.4 Criteria for endovascular therapy for acute stroke (Adapted from the 2015 AHA/ASA guidelines on endovascular management of acute stroke [18])

Criteria for endovascular therapy for acute stroke
Prestroke mRS score 0–1
Acute ischemic stroke receiving intravenous rtPA within 4.5 h of onset according to guidelines from professional medical societies
Causative occlusion of the internal carotid artery or proximal MCA (M1)
Age \geq 18 years
NIHSS score of \geq 6
ASPECTS of \geq 6
Treatment can be initiated (groin puncture) within 6 h of symptom onset

Perfusion imaging is now routinely being used in addition to the non-contrast head CT and CTA. Perfusion imaging can be obtained with both MRI and CT, but most centers utilize CT perfusion. In brief, a bolus of contrast is injected, and several parameters are measured, generating beautiful, color-coded maps of the brain's perfusion status. Generally, red signifies an increase, while blue signifies a decrease in a parameter. The parameters measured include:

1. Time to peak (TTP)
2. Mean transit time (MTT)
3. Cerebral blood volume (CBV)
4. Cerebral blood flow (CBF)

For the ED physician, it is adequate to know that generally in acute stroke, the TTP and MTT on the side of a lesion would be increased; hence, the color-coded map would likely show a wedge-shaped red area on that side when compared to the contralateral side which would be blue. The cerebral blood flow may be decreased. The cerebral blood volume may either be increased in cases of compensated ischemia or decreased in cases of core infarct. The true utility of a perfusion image however is in providing evidence for the presence of an ischemic penumbra, i.e., potentially salvageable brain tissue. To do this, the TTP or MTT is compared to the CBV and the area of overlap/penumbra is determined. While this is theoretically very useful, there are some studies questioning its accuracy [21].

The key take-home point is that one must not wait for results of all these imaging studies to decide whether or not to give rtPA but, rather, rule out a hemorrhage and give rtPA as quickly as possible (Figs. 2.10 and 2.11).

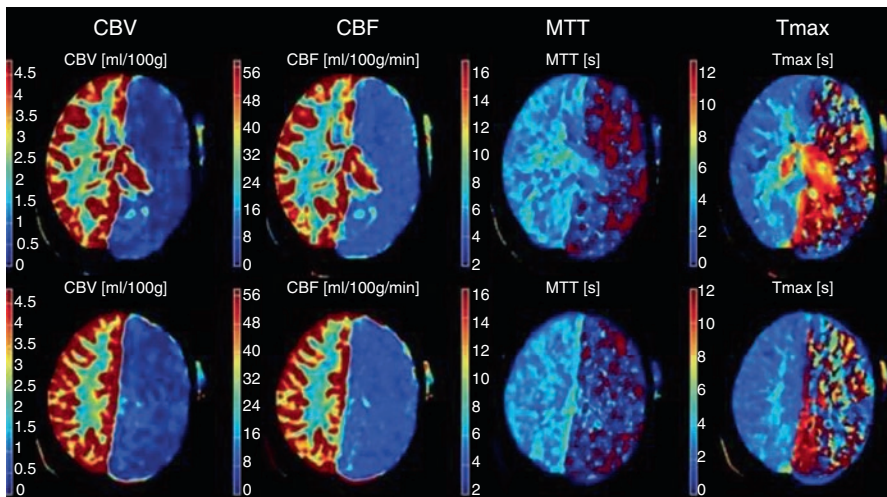
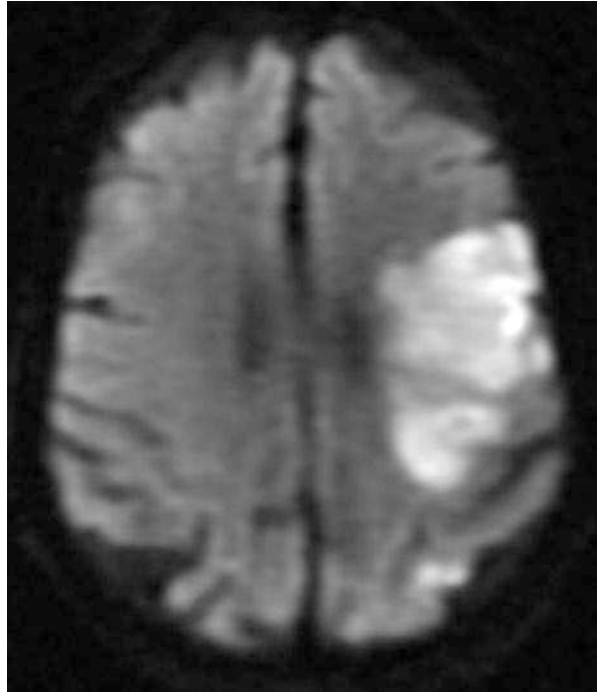


Fig. 2.10 CT perfusion in acute stroke: left hemisphere demonstrating increased MTT with decreased CBV and CBF suggesting large core infarct (Case courtesy of Dr. Gaillard, <http://radiopaedia.org>; reproduced with permission from radiopaedia.org) [25]

Fig. 2.11 DWI MRI imaging in acute stroke: left hemisphere increased signal on DWI suggesting acute stroke (Case courtesy of Dr. Gaillard, <http://radiopaedia.org>; reproduced with permission from radiopaedia.org) [26]



Other Studies

A baseline electrocardiogram is recommended but should not delay the initiation of intravenous rtPA. The role of a chest x-ray especially in the absence of acute cardiopulmonary disease remains unclear and debated at this time [15] (Table 2.5).

Management of Acute Ischemic Stroke

The US FDA approved the use of IV rtPA in 1996 [27], for acute ischemic stroke within 3 h of symptom onset, based on the results of the NINDS rtPA stroke trial. The studies suggested that treatment with IV rtPA was associated with better functional outcomes at 3 months and 1 year. Although the risk of hemorrhage was higher in the rtPA treated arm (6.4% vs. 0.6% for placebo with 3% having a fatal ICH), there was no overall difference in mortality between the treated and untreated groups. Several subsequent trials replicated the results, and subgroup analysis then prompted the increasing of the period of treatment to include those presenting within 3–4.5 h of symptoms, with a different criteria for rtPA use. It is important to note that most experts recommend holding antiplatelet for 24 h following rtPA administration, along with controlling blood pressure to below 180/15.

Below are the rtPA inclusion and exclusion criteria (Fig. 2.12; Tables 2.6 and 2.7):

Table 2.5 Immediate diagnostic studies: evaluation of a patient with suspected acute ischemic stroke (Courtesy of AHA/ASA [15])

<i>All patients</i>
Non-contrast brain CT or MRI
Blood glucose
Oxygen saturation
Serum electrolytes/renal function tests
Complete blood count, including platelets
Markers of cardiac ischemia
Prothrombin time/INR ^a
Activated partial thromboplastin time ^a
ECG ^a
<i>Selected patients</i>
TT and/or ECT if suspected that the patient is taking direct thrombin inhibitors or Factor Xa inhibitors
Hepatic function tests
Toxicology screen
Blood alcohol level
Pregnancy test
Arterial blood gas tests (if hypoxia is suspected)
Chest radiography (if lung disease is suspected)
Lumbar puncture (if SAH is suspected and the CT scan is negative for blood)
Electroencephalogram (if seizures are suspected)

CT computed tomography, *ECG* electrocardiogram, *ECT* ecarin clotting time, *INR* international normalized ratio, *MRI* magnetic resonance imaging, *TT* thrombin time

^aAlthough it is desirable to know the results of these tests before giving intravenous recombinant tissue-type plasminogen activator, fibrinolytic therapy should not be delayed while awaiting the results unless (1) there is clinical suspicion of a bleeding abnormality or thrombocytopenia, (2) the patient has received heparin or warfarin, or (3) the patient has received other anticoagulants (direct thrombin inhibitors or direct factor Xa inhibitors)

- Infuse 0.9 mg/kg (max. dose 90 mg) over 60 min, with 10% of the dose given as a bolus over 1 minute.
- Admit the patient to an intensive care or stroke unit for monitoring.
- If the patient develops severe headache, acute hypertension, nausea, or vomiting or has a worsening neurological examination, discontinue the infusion (if IV rtPA is being administered) and obtain emergent CT scan.
- Measure blood pressure and perform neurological assessments every 15 min during and after IV rtPA infusion for 2 h, then every 30 min for 6 h, then hourly until 24 h after IV rtPA treatment.
- Increase the frequency of blood pressure measurements if systolic blood pressure is >180 mmHg or if diastolic blood pressure is >105 mmHg; administer anti hypertensive medications to maintain blood pressure at or below these levels (Table 2.7)
- Delay placement of nasogastric tubes, indwelling bladder catheters, or intra-arterial pressure catheters if the patient can be safely managed without them.
- Obtain a follow-up CT or MRI scan at 24 h after IV rtPA before starting anticoagulants or antiplatelet agents.

Fig. 2.12 rtPA administration courtesy of the AHA/ASA [15]

Table 2.6 rtPA eligibility criteria for patients within 3 h of onset of symptoms courtesy of the AHA/ASA [15]

<i>Inclusion criteria</i>
<ul style="list-style-type: none"> • Diagnosis of ischemic stroke causing measurable neuro deficit • Clear onset (last witnessed well) <3 h (see below for extension to <4.5 h) • Age > 18 year
<i>Exclusion criteria</i>
<ul style="list-style-type: none"> • Historical <ul style="list-style-type: none"> – Stroke or head trauma in previous 3 months – Any history of intracranial hemorrhage – Major surgery in the previous 14 days – GI or urinary tract bleeding in previous 21 days – Myocardial infarction in previous 3 months – Arterial puncture at noncompressible site in previous 7 days • Clinical <ul style="list-style-type: none"> – Spontaneously clearing stroke symptoms – Only minor and isolated neurologic signs – Seizure at stroke onset • Persistent SBP >185 or DBP >110 despite treatment • Use of direct thrombin inhibitors or direct factor Xa inhibitors with elevated aPTT, INR, or factor Xa assay • Active bleeding or acute trauma (fracture) on exam • Labs <ul style="list-style-type: none"> – Platelets <100 K – Serum glucose <50, >400 – INR >1.7 or PT >15 sec if on warfarin – Elevated PTT if on heparin • Head CT <ul style="list-style-type: none"> – Evidence of hemorrhage – Evidence of multilobar infarction with hypodensity involving >33% of cerebral hemisphere – Intracranial neoplasm, AVM, or aneurysm • Use of dabigatran within 48 h is relative contraindication
<i>Relative exclusion criteria</i>
<ul style="list-style-type: none"> • Minor or rapidly improving stroke symptoms • Pregnancy • Seizure at onset with postictal residual neuro impairments

Table 2.7 rtPA eligibility criteria for patients within 3–4.5 h of onset of symptoms courtesy of the AHA/ASA [15]

Additional criteria for tPA administration between 3 and 4.5 h
<i>Inclusion criteria</i>
Same as for <3 h
<i>Exclusion criteria</i>
All of the above plus
Age > 80 year
Combination of both previous stroke and DM
NIHSS score >25
Oral anticoagulant use regardless of INR

It is imperative to note that the risk of ICH when treating a stroke mimic with IV rtPA is low (less than 1%); hence, one should not inadvertently delay rtPA in the right clinical setting. Similarly, the studies show that the earlier rtPA is administered, the better the outcome; hence, rtPA should not be delayed just because there is a 4.5 h window [15].

For patients who do not qualify for rtPA, an antiplatelet agent and statin should be administered. There are some studies suggesting dual antiplatelet therapy with aspirin and Plavix may be beneficial in the short term (approximately 90 days); however, the long-term benefit remains unclear [28].

The latest focus in acute stroke care has been on expanding the therapeutic time window for intervention. To date, the therapeutic window for treatment with intravenous tPA is 3 h from stroke onset or 4.5 h from stroke onset in patients who do not have the additional exclusion criteria (Table 2.7). This window is solely time based. It excludes wake-up strokes and those strokes with unknown time of onset. It also does not account for an individual brain's collaterals; the time-based definition for therapeutic window treats all patients the same, regardless of their overall and brain health. Someone with good collaterals to the occluded vessel would likely have a penumbra that is salvageable for a longer period. Given this, the latest clinical trials have focused on developing a neuroimaging or tissue-based definition for the therapeutic window. The DAWN trial [29] (DWI or CTP Assessment with Clinical Mismatch in the Triage of Wake-Up and Late Presenting Strokes Undergoing Neurointervention) was actually terminated early due to clear benefit demonstrated in patients with large-vessel occlusions (internal carotid or M1 branch of middle cerebral artery) undergoing mechanical thrombectomy up to 6–24 h since last seen well plus medical management, when compared to medical management alone. The NNT was 2.8. The median NIHSS was 17, with 65% of the cohort comprising wake-up strokes.

Disposition

In general, all patients suspected of having acute ischemic stroke should be admitted for a full neurological workup. Neurology consultation should be obtained. The workup of acute ischemic stroke includes a search for a source of thrombus, which includes carotid evaluation by ultrasound, CTA, MRA, or conventional angiography. Transthoracic echocardiogram is obtained to ascertain for low ejection fraction, cardiac source of clot, or patent foramen ovale. EKG and telemetry are obtained to ascertain for rhythms predisposing to stroke such as atrial fibrillation. Labs such as a fasting lipid panel and hemoglobin A1C are obtained to ascertain for modifiable risk factors for stroke. Other labs such as a hypercoagulable panel in young patients or B12 and syphilis testing in selected patients are also obtained. Antiplatelet and statins remain the mainstay of medical management of stroke. For patients with significant disabilities, physical therapy and occupational therapy consults should be obtained. Similarly, if swallowing and speech are of concern, then speech/swallow consults should be obtained. All patients should have follow-ups arranged with

their primary care providers and with neurology at appropriate times post-discharge. For symptomatic and significant carotid artery stenosis, referrals to vascular or neurological surgery should be sought promptly.

Pearls and Pitfalls

- Stroke generally presents with an acute focal neurologic deficit with no pain.
- The most important part of the history is the time of onset of symptoms.
- Rapid evaluation and treatment are paramount for the best outcomes.
- IV rtPA is approved for use up to 4.5 h following symptom onset, but the earlier the rtPA is administered, the better the outcomes.
- At minimum, a non-contrasted head CT should be obtained to rule out hemorrhage before administering IV rtPA.
- The only lab needed prior to administering rtPA is a fingerstick serum glucose unless a bleeding diathesis or clinical situation warrants more labs.
- Endovascular or interventional therapy should be considered in patients who have significant deficits (NIHSS >6) up to 6 h following symptom onset if treatment can be initiated within 6 h.
- The risk of intracranial hemorrhage in stroke mimics treated with IV rtPA is extremely low (~1%).
- For patients who do not qualify for rtPA, permissive hypertension is indicated for at least the first 24 h, and blood pressure should not be lowered unless it exceeds 220/120.
- Prior to initiating rtPA, blood pressure should be gently lowered to a value below 185/110.
- After rtPA, blood pressure should be kept below 180/105 for 24 h.
- Patients with large-vessel occlusions may benefit from mechanical thrombectomy up to 6–24 h after last seen well.

References

1. Center for Disease Control and Prevention—Stroke. www.dcd.gov/stroke.
2. Fernandes PM, Whiteley WN, Hart SR, Al-Shahi SR. Strokes: mimics and chameleons. *Pract Neurol*. 2013;13(1):21–8.
3. Chernyshev O, Martin-Schild S, Albright K, Barreto A, Misra V, Acosta I, et al. Safety of tPA in stroke mimics and neuroimaging-negative cerebral ischemia. *Neurology*. 2010;74(17):1340–5.
4. Liang BA, Zivin JA. Empirical characteristic of litigation involving tissue plasminogen activator and ischemic stroke. *Ann Emerg Med*. 2008;52(2):160–4.
5. Bruce NT, Neil WP, Zivin JA. Medico-legal aspects of using tissue plasminogen activator in acute ischemic stroke. *Curr Treat Options Cardiovasc Med*. 2011;13(3):233–9.
6. Restrepo L, Jacobs MA, Barker PB, Wityk RJ. Assessment of transient ischemic attack with diffusion-and perfusion weighted imaging. *AJNR Am J Neuroradiol*. 2004;25(10):1645–52.
7. Sehatzadeh S. Is transient ischemic attack a medical emergency? An evidence-based analysis. *Ont Health Technol Ser*. 2015;15(3):1–45.

8. Cucchiara BL, Messe SR, Taylor RA, Pacelli J, Maus D, Shah Q, Kasner SE. Is the ABCD score useful for risk stratification of patients with acute transient ischemic attack? *Stroke*. 2006;37(7):1710–4.
9. Stead LG, Suravaram S, Bellolio MF, Enduri S, Rabinstein A, Gilmore RM, Bhagra A, Manivannan V, Decker WW. An assessment of the incremental value of the ABCD2 score in the emergency department evaluation of transient ischemic attack. *Ann Emerg Med*. 2011;57(1):46–51. doi:10.1016/j.annemergmed.2010.07.001. Epub 2010 Sep 19. PMID: 20855130.
10. Stead LG, Bellolio MF, Suravaram S, Brown RD Jr, Bhagra A, Gilmore RM, Boie ET, Decker WW. Evaluation of transient ischemic attack in an emergency department observation unit. *Neurocrit Care*. 2009;10(2):204–8. doi:10.1007/s12028-008-9146-z. Epub 2008 Oct 11. PMID: 18850077.
11. Kidwell CS, Chalela JA, Saver JL, et al. Comparison of MRI and CT for detection of acute intracerebral hemorrhage. *JAMA*. 2004;292(15):1823–30.
12. Fiebach JB, Schellinger PD, Gass A, et al. Stroke magnetic resonance imaging is accurate in hyperacute intracerebral hemorrhage: a multicenter study on the validity of stroke imaging. *Stroke*. 2004;35(2):502–6.
13. Winkler DT, Fluri F, Fuhr P, Wetzel SG, Lyrer PA, Ruegg S, Engelter ST. Thrombolysis in stroke mimics: frequency, clinical characteristics, and outcome. *Stroke*. 2009;40:1522–5.
14. Hedna VS, Stead LG, Bidari S, Patel A, Gottipati A, Favilla CG, Salardini A, Khaku A, Mora D, Pandey A, Patel H, Waters MF. Posterior reversible encephalopathy syndrome (PRES) and CT perfusion changes. *Int J Emerg Med*. 2012;5:12. doi:10.1186/1865-1380-5-12.
15. Jauch E, Saver J, Adams H, Bruno A, Connors J, Demaerschalk B, et al. Guidelines for the early management of patients with acute ischemic stroke: a guideline for healthcare professionals from the American Heart Association/American Stroke Association. *Stroke*. 2013;44(3):870–947.
16. Saver J. Time is brain—quantified. *Stroke*. 2005;37(1):263–6.
17. Adams H, Davis P, Leira E, Chang K, Bendixen B, Clarke W, et al. Baseline NIH stroke scale score strongly predicts outcome after stroke: a report of the trial of org 10172 in acute stroke treatment (TOAST). *Neurology*. 1999;53(1):126.
18. Power WJ, Derdeyn CP, Biller J, et al. 2015 American Heart Association/American Stroke Association focused update of 2013 guidelines for the early management of patients with acute ischemic stroke regarding endovascular treatment: a guideline for healthcare professional from the American Heart Association/American Stroke Association. *Stroke*. 2015;46(10):3020–35.
19. NIH Stroke Scale [Internet]. National Institute of Neurological Disorders and Stroke. 2016 [cited 1 May 2016]. https://www.ninds.nih.gov/doctors/NIH_Stroke_Scale.pdf.
20. NINDS (Adapted from Harold Goodglass). The assessment of aphasia and related disorders. Philadelphia, PA: Lea & Febiger; 1972.
21. Kurz K, Ringstad G, Odland A, Advani R, Farbu E, Kurz M. Radiological imaging in acute ischaemic stroke. *Eur J Neurol*. 2015;23:8–17.
22. Alberta Stroke Program Early CT score (ASPECTS)—Role of NCCT [Internet]. Aspectsinstroke.com. 2016 [cited 1 May 2016]. <http://www.aspectsinstroke.com/imaging-in-acute-stroke/role-of-ncct/>.
23. Jones J. Hyperdense MCA sign, Radiology Reference Article, Radiopaedia.org [Internet]. Radiopaedia.org. 2016 [cited 2 May 2016]. <http://radiopaedia.org/articles/hyperdense-mca-sign>.
24. CT Scan—Basics [Internet]. Slideshare.net. 2016 [cited 2 May 2016]. <http://www.slideshare.net/smcmedicinedept/ct-scan-basics> Image courtesy of Stanley Medical College.
25. Gaillard F. CT perfusion in ischaemic stroke, Radiology Reference Article, Radiopaedia.org [Internet]. Radiopaedia.org. 2016 [cited 2 May 2016]. <http://radiopaedia.org/articles/ct-perfusion-in-ischaemic-stroke>.
26. Gaillard F. Diffusion weighted MRI in acute stroke, Radiology Reference Article, Radiopaedia.org [Internet]. Radiopaedia.org. 2016 [cited 2 May 2016]. <http://radiopaedia.org/articles/diffusion-weighted-mri-in-acute-stroke-1>.

27. The National Institute of Neurological Disorders and Stroke rt-PA Stroke Study Group. Tissue plasminogen activator for acute ischemic stroke. *N Engl J Med.* 1995;333:1581–8. doi:[10.1056/NEJM199512143332401](https://doi.org/10.1056/NEJM199512143332401).
28. Ge F, Lin H, Liu Y, Li M, Guo R, Ruan Z, Chang T. Dual antiplatelet therapy after stroke or transient ischaemic attack—how long to treat? The duration of aspirin plus clopidogrel in stroke or transient ischaemic attack: a systematic review and meta-analysis. *Eur J Neurol.* 2016;23:1051–7. doi:[10.1111/ene.12982](https://doi.org/10.1111/ene.12982).
29. <https://clinicaltrials.gov/ct2/show/NCT02142283>. Accessed 19 May 2017.

Acute Head Injury: When to Image and When to Observe?

3

Tracy MacIntosh and Adam Benzing

Case Presentation

A 21-year-old male presents to the emergency department (ED) via ambulance after being struck by a car while riding a scooter without a helmet. Per the paramedic, patient had LOC on scene. He was complaining of right ear and right-sided head pain but denied neck, back, extremity, or abdominal pain. Though he could answer some questions, others were answered inappropriately, and he was unreliable in following commands. The paramedics placed him in a C-collar and on a backboard and noted fluid draining from the patient's right ear. His initial GCS was 13 for confusion and localizing pain. His arrival vital signs were: blood pressure 138/82, HR 112, RR 18, 96% on 2 L, and temperature 37.8 C. He had symmetric breath sounds and 2+ femoral and DP pulses. Pupils were equal and reactive; he had right hemotympanum and abrasions to the head and face. His abdomen was soft and non-tender, and he had multiple abrasions on the extremities and a contusion to his right flank.

Introduction

Acute head injury does not always lead to traumatic brain injury (TBI), and the clinician will make the diagnosis of TBI based on clinical symptoms and thorough ED evaluation. TBI is “an alteration in brain function, or other evidence of brain pathology, caused by an external force” [1]. The CDC reported that TBI accounted

T. MacIntosh, M.D., M.P.H. (✉)

University of Central Florida, Osceola Regional Medical Center, Kissimmee, FL., USA

e-mail: tracystmac@gmail.com

A. Benzing, M.D., M.P.H.

University of Central Florida College of Medicine, Orlando, FL, USA

e-mail: Adam.Benzing@ucf.edu

for 2.5 million ED visits and over 50,000 deaths in 2010 [2]. According to the American College of Surgeons' 2015 National Trauma Data Bank of hospital admissions, there were over 300,000 head injuries reported to their trauma registry in 2014, representing 35% of all injuries [3].

The severity of traumatic brain injuries is most commonly categorized using the Glasgow Coma Score (GCS). The GCS is the most widely used coma scale and was introduced in 1974 to characterize changes in consciousness, particularly for the TBI patient, for the purpose of objectively comparing patients and treatment modalities [4]. The score is obtained by assessing eye opening and verbal and motor responses. A severe TBI is often defined as $GCS \leq 8$, moderate as 9–13, and mild as 14–15 [5].

Differential Diagnosis

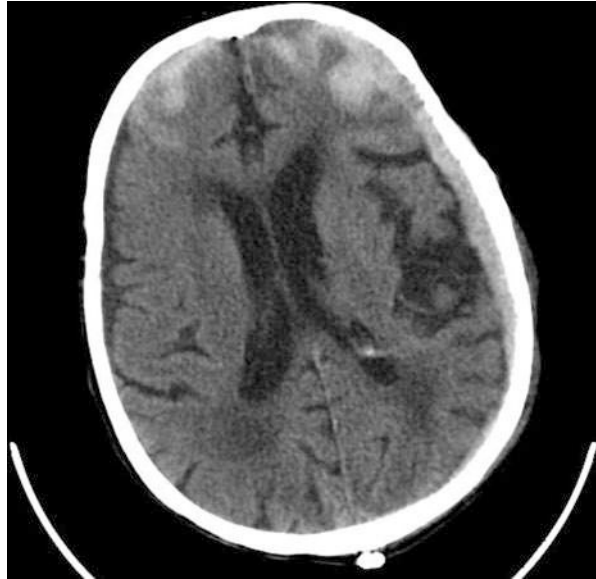
- Intracranial hemorrhage: subdural hematoma, epidural hematoma, and subarachnoid hemorrhage
- Cerebral contusion
- Concussion
- Diffuse axonal injury
- Delayed intracranial bleed
- Skull fracture

Traumatic Intracranial Hemorrhage

Traumatic intracranial hemorrhage and hematomas result from injuries to the vasculature of the brain due to forces of angulation, acceleration, rotation, and direct laceration. This can result in extra-axial lesions, subdural hematoma, epidural hematoma, and subarachnoid hemorrhage [6]. These represent the most important complications from TBI and often require immediate surgical intervention in order to avoid permanent neurological deficits or death, with an estimated 100,000 patients annually in the United States undergoing surgical interventions for traumatic intracranial hemorrhage [7].

Subdural hematomas (SDH) occur in approximately 12–29% of patients admitted with TBI [8]. These appear as a concave collection of blood in the subdural space, following the contour of the brain. The mechanism of injury varies by age but is most frequently caused by motor vehicle collisions, falls, and assault. Elderly and alcoholic patients are at increased risk for SDH because they are more likely to have brain atrophy leading to stretching of the bridging veins, making these vessels more vulnerable to damage with even minor head trauma [8]. Mortality rates for patients requiring surgical intervention range from 40 to 60%, with even higher mortality rates for patients who present to the emergency department in a coma. The majority of patients who require surgical intervention for their subdural hematoma also have additional intracranial and extracranial injuries [9] (Fig. 3.1).

Fig. 3.1 Subdural and intraparenchymal hemorrhage. Subdural hemorrhage up to 1 cm over the left cerebral hemisphere and right frontal and temporal lobes. Two centimeters intraparenchymal hemorrhage in the left frontal lobe surrounded by vasogenic edema. Mass effect and 6 mm midline shift to the right



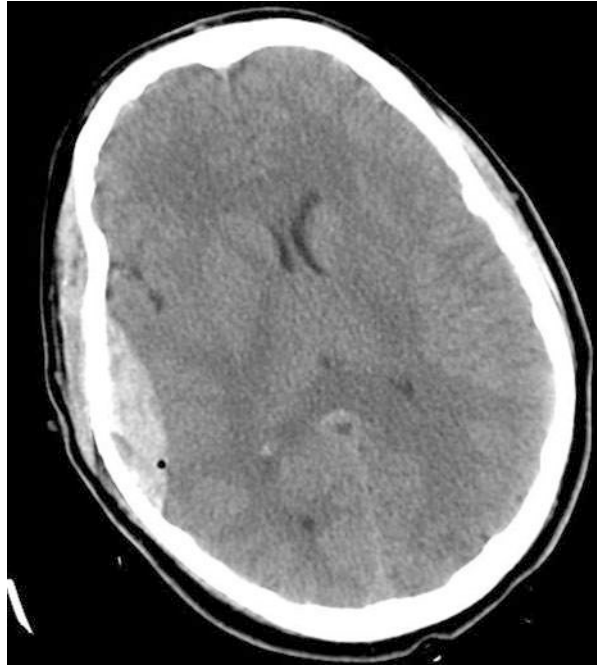
Epidural hematomas (EPH) can result from injury to the middle meningeal artery or vein, or the venous sinuses, and occur in approximately 3–4% of patients admitted with TBI [10]. They appear as a convex collection of blood on CT imaging due to the accumulation of blood between the dura and skull. The classically described “lucid interval,” where patients initially lose consciousness following the injury and then awaken and subsequently deteriorate, occurs in almost half of all patients, while 12–42% of patients remain conscious throughout their entire preoperative course [9]. Patients may also present with pupillary abnormalities, neurological deficits, hemiparesis, decerebration, and/or seizures [10] (Fig. 3.2).

Traumatic subarachnoid hemorrhage occurs in 26–52% of TBI patients and is hypothesized to be due to rotation or acceleration of the brain, vertebrobasilar artery stretch, sudden increase in intra-arterial pressure from trauma to the cervical carotid artery, or damage to bridging veins and pial vessels. They most commonly appear in a mixed pattern on non-contrast CT involving the cerebral hemispheres, basal cisterns, cortical sulci, and interhemispheric space [11]. Although many patients will have concomitant cerebral contusions and SDH or EPH, those patients who present with mild TBI with isolated subarachnoid hemorrhage rarely have progression of pathological findings on subsequent imaging and, even if they do, will generally not require surgical intervention or suffer from neurological decline [12, 13].

Cerebral Contusion

Cerebral contusions are bruises that occur in the parenchyma due to impact of the brain against the skull, falx cerebri, or tentorium, most commonly resulting from blunt, closed head injury. The most common locations for this injury are the inferior

Fig. 3.2 Epidural hematoma. Right-sided epidural hematoma with a gas bubble, consistent with open fracture. Significant mass effect with 6 mm of midline shift



frontal and anterior temporal lobes because the adjacent skull base has a sharp and irregular contour. A contusion at the site of impact is called a coup contusion, and a contrecoup contusion occurs opposite to the site of impact [14].

Concussion

According to the consensus statement on Concussion in Sports, though used interchangeably, concussion and mild TBI are defined as two separate entities [15]. Concussion represents a low-velocity injury caused by “shaking” of the brain leading to clinical symptoms but may not correspond to pathological injury, and patients typically have normal neuroimaging. Concussions generally cause rapid, short-term impairment in neurological function with spontaneous resolution but may occasionally develop over minutes to hours. Patients may present with headache, dizziness, blurry vision, cognitive, emotional or behavioral changes, or sleep disturbance [15, 16]. On the other hand, mild TBI is classified by more severe clinical symptoms and will often have abnormalities apparent on conventional imaging.

Diffuse Axonal Injury

Diffuse axonal injury (DAI) is the process of generalized axonal damage resulting from inertial or rotational forces leading to TBI, resulting in abnormal cerebral connectivity with variable subsequent reversibility [17]. Contemporary theories of mechanism of injury suggest that damage to the axolemma leads to abnormal influx

of extracellular ions with resulting destruction of the cytoskeleton and cellular transport. Axonal swelling then leads to axonal dysfunction and ultimately disruption of connections, a process that can take hours to days following the injury [18].

White matter axonal disruption occurs in more than half of severely head injured patients and approximately 30% of mild head injuries [19]. The diagnosis of DAI remains essentially a “diagnosis of exclusion” in patients with coma or cognitive dysfunction without any abnormalities on CT brain imaging because microscopic degrees of DAI are essentially undetectable on initial CT imaging [20]. The most common immediate impairment from DAI is coma [21].

Delayed Intracranial Bleed

With increasing use of antiplatelet and anticoagulant agents for vascular disease and stroke prevention, more patients are at risk for traumatic intracranial bleeding. For example, head injury patients taking warfarin who may be completely asymptomatic or are otherwise deemed low risk have a 7% risk of intracranial bleed [22], and supra-therapeutic INR is associated with lower initial GCS score [23]. The risk of delayed bleed for patients with minor head injury (GCS \geq 13) on warfarin has been found to be between 0.3 and 6% [24, 25], with higher risk associated at INR $>$ 3.0 [25].

Skull Fractures

Skull fractures are associated with intracranial bleeding [26] and have higher mortality rates among isolated TBI patients, suggesting that these fractures resulted from higher forces of impact [27]. The vast majority of depressed skull fractures are open, or compound fractures, and may lead to infections, neurological morbidity, seizures, and death. These are generally treated operatively with debridement and elevation in order to reduce the risk of infection [9].

The skull base is composed of the frontal, temporal, ethmoid, sphenoid, and occipital bones. Skull base fractures often result from high-velocity injuries and may be linear or comminuted and can have associated intracranial, vascular, or orbital injuries and CSF leak. Surgical management of skull base fractures with cranial decompression is indicated based on associated cranial injuries, prolonged CSF leak, or profound cranial nerve or vascular injury [28] (Fig. 3.3).

History and physical exam

History red flags	Physical exam red flags
Amnesia	Altered mental status
New-onset seizure	GCS $<$ 15
Age $>$ 60	Evidence of skull fracture
Drug/alcohol intoxication	Trauma above the clavicles
Headache	Neurological deficits
Vomiting	
Anticoagulant or antiplatelet agent	
Dangerous mechanism	

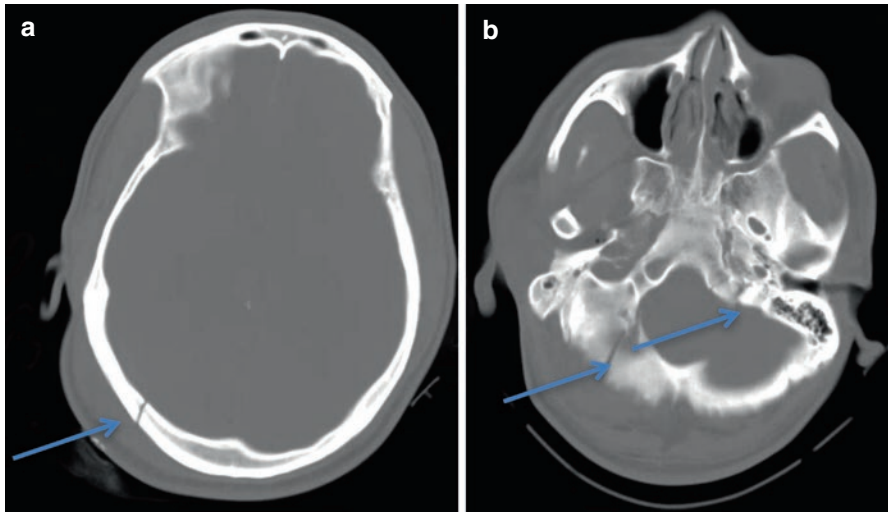


Fig. 3.3 (a, b) Skull fractures. (a) Demonstrates a linear right occipital skull fracture. (b) Demonstrates fractures of the occipital bone to the foramen magnum and left base of the skull

When evaluating a patient with potential TBI, elements of the history and physical exam can provide key information to inform the clinician about the severity of injury and potential worsening of the clinical condition and guide decision-making. An accurate history should be obtained from the patient (if possible) witnesses, and available EMS personnel for details on mechanism of injury, loss of consciousness, confusion, and vomiting, along with the standard elements of a thorough patient history. The initial ED trauma evaluation starts with an assessment of the ABCDEs: airway, breathing, circulation, disability, and exposure. Following the initial assessment and efforts to stabilize vital signs as needed, the physical exam should include a thorough neurological assessment, including physical exam findings for increased intracranial pressure and GCS [29], and a thorough evaluation for extracranial trauma.

The spectrum of injury encompassed within the category of traumatic brain injury is broad, but the clinician responsible for the acute evaluation of such patients will be most challenged by those who are neurologically intact and appear well but may have a significant underlying or evolving intracranial injury. Patients falling into the category of mild TBI are the most difficult to evaluate for proper treatment and disposition as their unimpressive presentation may obfuscate the need for further diagnostic studies, intervention, and follow-up.

The New Orleans Criteria (NOC) and Canadian CT Head Rule (CCHR) have identified key historical and physical exam factors associated with predicting clinically significant TBI after acute head injury with loss of consciousness. Haydel et al. derived the NOC from the history and physical findings of a cohort of 520 patients presenting with head trauma and normal GCS evaluated by head CT and

subsequently validated on 909 patients. A history of short-term memory deficit had the highest positive predictive value of clinically significant TBI, followed by new-onset seizure, age over 60 years, drug or alcohol intoxication, headache, visible trauma, and vomiting. Any evidence of trauma above the clavicles is also associated with clinically significant TBI [30].

Stiell et al. derived and validated the CCHR on over 3000 patients with GCS of 13–15 across 10 large Canadian hospitals and derived 5 high-risk and 2 medium-risk factors associated with requirement for neurosurgical intervention or clinically important brain injury on CT. Vomiting 2 or more times or age 65 and over were 2 high-risk elements from the history that were highly predictive of clinically significant TBI, and retrograde amnesia >30 min prior to impact and dangerous mechanism (pedestrian struck by motor vehicle, occupant ejected from motor vehicle, fall from >3 ft or 5 stairs, heavy object fell onto head/axial load) were both medium-risk historical elements. Suspected open skull fracture or basilar skull fracture on exam is high-risk physical findings [31].

Pediatrics

The pediatric population requires special consideration in the evaluation of acute TBI. In addition to the high incidence of head trauma, clinical assessment is complicated by their inability to follow commands, potential noncompliance with imaging, and increased concerns for ionizing radiation exposure [32, 33]. There are three primary clinical decision rules (CDR) for the evaluation of pediatric head injuries described in the literature: the Canadian Assessment of Tomography for Childhood Injury (CATCH), Children's Head Injury Algorithm for the Prediction of Important Clinical Events (CHALICE), and Pediatric Emergency Care Applied Research Network (PECARN).

The CATCH decision rule is based on a multicenter cohort study of 3866 pediatric patients 0–16 years of age who presented with GCS of 13–15 and signs of TBI [34]. The study identified history of worsening headache and dangerous mechanism (motor vehicle collision, fall >3 ft, fall from bicycle with no helmet) as key historical elements, while signs of basilar skull fracture, irritability on exam, and large boggy hematomas on exam are all predictive of clinically significant TBI [34].

The CHALICE study evaluated 22,772 pediatric patients [35]. Clinically significant head injury was defined as any head-related injury resulting in death, neurosurgical intervention, or acute abnormality on head CT scan, all of which also comprised the study's primary outcome measure with secondary outcomes defined as skull fractures and hospital admissions [35]. The authors identified 14 criteria categorized by history, examination findings, and mechanism of injury, where any single positive criterion resulted in a sensitivity of 98% and specificity of 87% to predict clinically significant head injuries. Witnessed LOC >5 min, amnesia >5 min, abnormal/excessive drowsiness, three or more episodes of emesis since head injury, suspicion

of non-accidental trauma, new-onset seizure, and severe mechanism (high-speed traffic accident as occupant or pedestrian, fall >9.8 m, high-speed projectile injury) were most predictive of clinically significant head injuries. On exam, GCS <15 in an infant <1 year or GCS <14, suspicion of penetrating or depressed skull fracture or tense fontanelle, signs of basilar skull fracture, neurological deficit or ecchymosis, and swelling or laceration of the head >5 cm in an infant were associated with clinically significant TBI [35].

Kuppermann et al. developed the PECARN head injury decision rule in order to identify children with very low risk of clinically important TBI for whom CT imaging may not be necessary [36]. 42,412 pediatric patients younger than 18 years old who presented within 24 h of head trauma with GCS of 14 or 15 were enrolled in this multicenter cohort study. Patients were divided into two age groups, younger than 2 years and 2 years and older. The study assessed for neurosurgical intervention and positive findings for clinically important TBI on CT scan. The validation criteria had a sensitivity of 100% and specificity of 53.6% for identifying clinically important TBI in the <2year age group and a sensitivity of 96.8% and specificity of 58.2% in the ≥2year age group. The decision algorithm identified 100% of patients requiring neurosurgical intervention in both age categories. For children under 2, concerning factors were a history of loss of consciousness ≥5 s, child not acting normally, or severe mechanism (motor vehicle crash with patient ejection, death of another passenger, rollover, pedestrian or bicyclist without helmet struck by motorized vehicle, fall >3 ft, head struck by high-impact object). For children 2 years and older, history of LOC, severe headache, severe mechanism, and history of vomiting were associated with clinically important TBI. On physical exam, altered mental status, GCS <15, palpable skull fracture or non-frontal hematoma for children <2years, or signs of basilar skull fracture for older children were indications for CT [36].

Comparing the diagnostic accuracy of these three pediatric clinical decision rules, Easter et al. found that the PECARN rule identified all of the clinically significant TBIs and had the highest sensitivity at 100%, compared to 91% for CATCH and 84% for CHALICE. CHALICE had the highest specificity at 85% vs. 62% for PECARN and 44% for CATCH (see Fig. 3.4 for PECARN) [37].

Emergency Department Workup

For those patients severely injured, with clearly abnormal neurologic exams on arrival, most will require neuroimaging after stabilization, and diagnostic dilemmas will be rare. This section will focus on how best to diagnose those with mild head injury, and the optimal initial evaluation and treatment.

In order to help guide the clinical evaluation of adult head trauma patients presenting acutely with mild signs and symptoms, the clinician should rely on evidence-based algorithms. As described above, the two best studied and most widely employed for adults are the New Orleans Criteria (NOC) and Canadian CT Head Rule (CCHR).

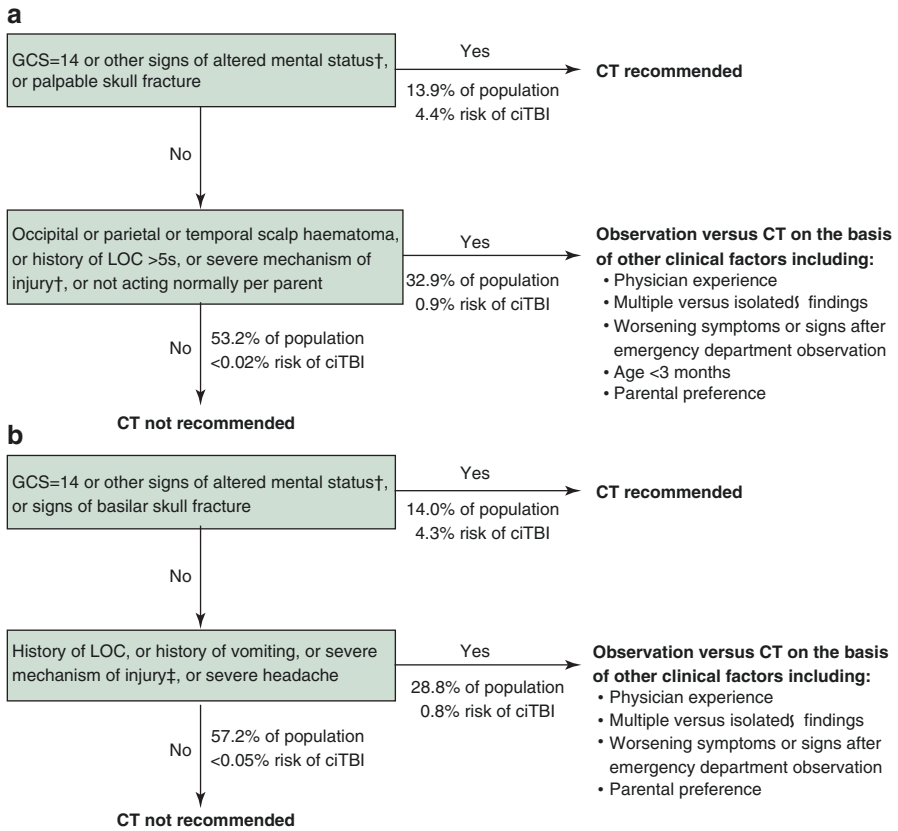


Fig. 3.4 From p. 1168: PECARN decision rule for (a) children <2 years of age and (b) children 2 years and older (with Elsevier permission for this table) [36]

New Orleans Criteria (NOR)

Non-contrast head CT required for patients with minor head injury, GCS 15, and any one of the following

1. Headache
 2. Vomiting
 3. 60 years of age or older
 4. Drug or alcohol intoxication
 5. Persistent anterograde amnesia
 6. Visible trauma above the clavicle
 7. New-onset seizure
-

Adapted from Haydel et al. [30]

 Canadian CT Head Rule (CCHR)

Non-contrast head CT required for patients with minor head injury (GCS 13–15 after witnessed loss of consciousness, amnesia, or confusion) and any one of the following

 High-risk factors for neurosurgical intervention

1. Glasgow coma score lower than 15 at 2 h post-injury
 2. Suspected open or depressed skull fracture
 3. Any indication of basal skull fracture
 4. Two or more episodes of vomiting
 5. 65 years of age or older
-

 Medium risk for brain injury detection by CT scan

6. Amnesia before impact of 30 min or more
 7. Dangerous mechanism
-

Adapted from Stiell et al [31]

Since the establishment of these two decision rules, there have been numerous attempts at their evaluation and comparison. However, the lack of consensus in defining mild TBI, the international variation in clinical settings, and disparate inclusion criteria and study design complicate the comparison of the data.

Stiell et al. conducted a prospective cohort study of 2707 patients in order to compare the clinical performance of the CCHR and NOC for detecting the need for neurosurgical intervention (primary outcome) and clinically important brain injury (secondary outcome). For patients with a GCS of 15, the CCHR and NOC had equivalent sensitivities of 100% for predicting neurosurgical intervention, but the CCHR had better specificity at 76.3% compared to 12.1% for NOC. Likewise, both the CCHR and NOC had excellent sensitivity of 100%, but the CCHR had superior specificity 50.6% versus 12.7% for clinically important brain injury [38].

An observational cohort study by Bouida et al. of 1582 patients demonstrated that CCHR had both higher sensitivity (100% vs. 82%) and specificity (60% vs. 26%) for both primary and secondary outcomes of neurosurgical intervention and clinically significant findings on head CT than NOR [39].

Overall, therefore, there is data that the CCHR has better sensitivity and specificity than NOR and should be used to identify adult patients with mild TBI who require a CT scan. However, practice management guidelines from the Eastern Association for the Surgery of Trauma (EAST) recommend brain CT for any adult patient strongly suspected of brain injury, such as “loss of consciousness or other clinical sign of MTBI.” [40] They define MTBI as the acute alteration in brain function caused by blunt force trauma, with GCS 13–15 with LOC less than 30 min and less than 24 h of post-traumatic amnesia. These guidelines suggest therefore that selecting only high-risk patients for CT should be reserved for resource-limited settings [40].

Due to the high incidence of TBI in the elderly, an additional complicating factor is anticoagulation therapy [41]. Coagulopathy is such a significant confounding factor in the evaluation of TBI that the American College of Emergency Physicians recommends that it be a deciding factor in favor of CT imaging for anyone presenting with head trauma, even in the absence of loss of consciousness or post-traumatic amnesia [42]. Comparing outcomes of head trauma patients on different anticoagulant therapies, aspirin, clopidogrel, and warfarin, warfarin was found to be an independent risk factor for mortality, while all medications were associated

with increased risk of intracranial hemorrhage [43]. Comparing the risk of immediate versus delayed intracranial hemorrhage for clopidogrel and warfarin where the majority of patients (71%) had a GCS of 15, clopidogrel was associated with immediate findings, while warfarin was more likely to result in delayed hemorrhage [44]. While further research is required, particularly related to non-vitamin K oral anticoagulant therapy, current evidence supports routine head CT imaging in those presenting with blunt head injury and anti-platelet or anticoagulant therapy, regardless of injury severity.

Pediatrics

Given the superior sensitivity of the PECARN rule, 100%, compared to 91% for CATCH and 84% for CHALICE, clinicians should use the PECARN guidelines to engage families in medical decision-making and determine which children require neuroimaging.

Acute ED Interventions

Treatment strategies for TBI are determined by the degree and type of injury present. Initial assessment involves evaluating and stabilizing the patient's airway, breathing, and circulation, most often guided by standardized trauma protocols. Hypotension must be avoided in order to preserve cerebral perfusion pressures >50–60 mmHg, and ventilation must be preserved in order to maintain oxygen saturation to avoid ischemic injury [45].

For patients presenting with moderate (GCS 9–13) or severe TBI (GCS ≤ 8), the initial priority is to stabilize the patient and obtain neuroimaging. After the diagnosis is made, the patient should be evaluated for prompt neurosurgical intervention. Stabilization efforts include the assessment and management of increased intracranial pressure and prompt neurosurgical consultation.

During the initial assessment of the patient with suspected severe TBI, the head of the bed should be elevated to $\geq 30^\circ$ to facilitate cerebral venous drainage in the absence of contraindications [46]. Temperature should be controlled to avoid hyperthermia, iso- or hyperosmotic fluids should be prioritized for resuscitation, and excessive stimulation, such as tracheal suctioning, should be minimized in order to avoid any further increases in ICP [45]. Hyperventilation to a PaCO₂ of 30–35 mmHg is an effective temporizing measure for those patients destined for emergency operative intervention and can be maintained for up to 2 h [47].

Interventions for the acute elevation of ICP involve hyperosmolar therapy with either hypertonic saline or mannitol, which are likely equivalent in their efficacy [48, 49]. Dosing of mannitol is 0.5–1 g/kg IV bolus and may be administered through a peripheral line and repeated as often as every 4–6 h with monitoring of serum osmolality [49]. Hypertonic saline and mannitol therapies can be combined, but hypertonic saline concentrations greater than 7.5% are best administered through a central venous catheter [45].

Propofol is also effective in reducing ICP by reducing cerebral metabolic oxygen rate and cerebral blood flow volume [50], which makes it an advantageous choice for the intubation and continued sedation of patients with TBI. A bolus of 1–3 mg/kg may be administered and then converted to an infusion titrated to a maximum of 200 µg/kg/min. The most frequent, anticipated adverse effect of propofol is circulatory depression, which may require correction with IV fluids or vasopressors in order to prevent cerebral hypoperfusion. Additionally, propofol infusion syndrome is a rare side effect that can develop at doses >100 µg/kg/min maintained for >48 h [45]. Onset of metabolic acidosis, cardiac dysfunction, rhabdomyolysis, and hypertriglyceridemia should alert the clinician to this potentially fatal condition [45, 51]. If these initial medical therapies fail to improve the patient's clinical status, rescue decompressive neurosurgery should be considered.

If the patient's clinical condition remains poor despite the aforementioned efforts and the patient is not deemed appropriate for surgery, additional interventions may provide some benefit but with additional risks. Moderate hypothermia with a target core temperature of 32–34 °C has been shown to lower ICP but can also result in cardiac arrhythmias, electrolyte disturbances [45], and coagulopathy. Hyperventilation to mild or moderate hypocapnia of PaCO₂ of 25–35 mmHg can result in further cerebrovascular constriction but is unlikely to provide benefit beyond 6 h while potentially exacerbating ischemic injury [45, 52]. Finally, the use of barbiturates is controversial with limited rigorous evidence to support its use [45], [53].

Clinical Investigations

Biomarkers

Brain injury can result in axonal shear and resulting neuronal axon injury and the release of proteins that can cross the blood-brain barrier. One of the most studied of these proteins is S-100B. According to the 2008 American College of Emergency Physicians Clinical Policy, there are limited data to support its use in identifying patients with TBI who may not require a CT scan and that this test may be used in the future in addition to clinical variables to identify low-risk patients in selected populations [54]. A number of other markers have been studied and were shown to be associated with mortality in TBI patients. These represent ongoing, active areas of research in the management of these injuries [55] but do not yet have an established role.

Neuroimaging

CT

CT scanning is the imaging modality of choice in the acutely head injured patient in order to identify clinically significant intracranial bleeding and/or swelling which requires emergency neurosurgical interventions [56]. Plain films have no role in the

evaluation of patients with TBI [54] when CT is available at the facility given CT's superior sensitivity for skull fractures [57].

Cerebral contusions may not always be evident on initial CT but tend to increase and become more visible on follow-up imaging [14]. Contusions may range in appearance on CT from small petechial hemorrhages to large parenchymal hematomas with mass effect and shift. Contusions can be distinguished from DAI by the fact that contusions involve the cortical surface, whereas DAI is subcortical [14]. New evidence suggests that CT may have some role in detecting DAI. For example, the presence of intraventricular hemorrhage on initial CT was found to be a marker for DAI on subsequent MRI [58].

Clinicians must maintain a high index of clinical suspicion for cerebrovascular injury. Though relatively rare, these patients are often asymptomatic initially, but untreated vascular injury can have high morbidity and mortality. CT angiography is the initial imaging modality of choice [59] and should be considered in patients with neurological deficits not explained by initial CT.

MRI

MRI does not yet serve a broad role in the immediate emergency department (ED) evaluation of the acutely head injured patient and has instead been used to prognosticate in patients with persistent neurological deficits [60], to explain neurological deficits without apparent abnormalities on CT or to better delineate abnormalities seen on initial CT [56]. However, there has been growing success in performing rapid acquisition MRIs in pediatric populations, and recent studies may suggest transferring this technology to traumatic brain injury, with particular attention to the pediatric population. MRI has been shown to be as sensitive as CT scan for detecting traumatic brain injury and intracranial hemorrhage but less sensitive for skull fractures [61]. Seventy-five percent of mild TBI patients with GCS of 14–15 with a post-event LOC had intraparenchymal lesions on MRI, half of which were missed on initial CT [62].

MRI is more sensitive than CT for detecting cerebral contusions, and fluid-attenuated inversion recovery is better than T1- and T2-weighted sequences for identifying cerebral edema due to contusion [14] (Fig. 3.5).

Post-concussion Syndrome

Post-concussion syndrome (PCS) is a constellation of symptoms noted in persons who have sustained a head injury in the recent past. These symptoms are classified into physical, cognitive, emotional, and sleep problems [63]. Physical problems include headache, nausea, vomiting, balance and visual problems, dizziness, fatigue, sensitivity to light or noise, numbness or tingling, and feeling dazed or stunned. Cognitive problems include feeling mentally “foggy,” speaking slowly, and having difficulty attending, concentrating, executing, judging, processing, remembering, tracking, or understanding. Emotional problems include irritability, sadness, and nervousness. Sleep problems include drowsiness, sleeping more or

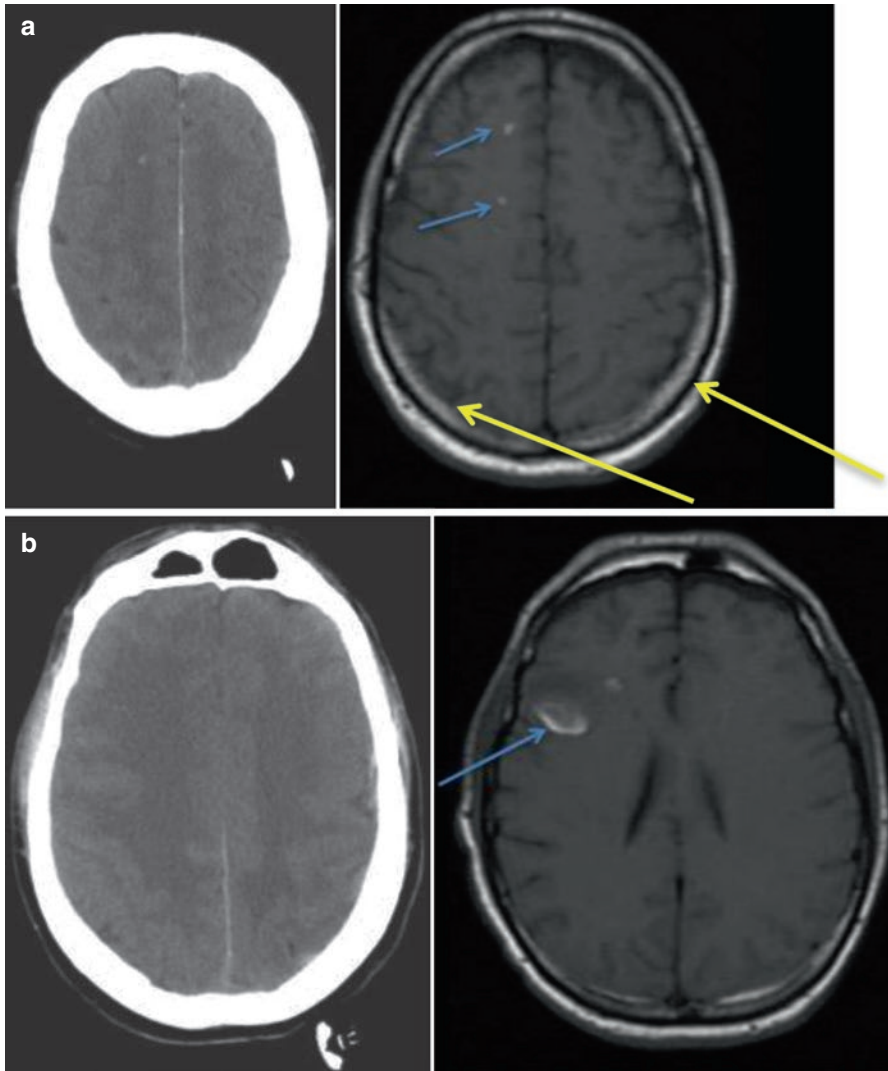


Fig. 3.5 (a, b) Diffuse axonal injury. Comparisons of non-contrast CT with MRI on the same patient. (a) Scattered foci of edema, consistent with DAI (*blue arrows*). Bilateral subdural hematomas (*yellow arrows*). (b) Subacute parenchymal hematoma on MRI

less than usual, and having trouble falling asleep. Studies have reported that between 15 and 30% of mTBI patients meet the criteria for PCS at 1 month [64] and 3 months [65, 66]. Other studies have estimated that up to 50–80% [67, 68] of mTBI patients meet the criteria for PCS after 3 months. One study [69] demonstrated 43% of mTBI patients meet the criteria for PCS around 5 days post-injury. Due to this high prevalence, it is important to caution acute head injury patients being discharged from the emergency department that they may experience

symptoms of PCS [70]. Treatment is supportive and includes brain rest, which means no to minimal screen time (computer, phone, tablet, etc.), and symptomatic treatment with antiemetics and non-opiate analgesics.

Disposition

All patients with severe head injury should be admitted or transferred to a neurosurgical care center as patients managed at non-neurosurgical centers have been shown to have 26% higher mortality rates [71].

Even though approximately one-third of patients with moderate TBI will have negative initial CT scans, these patients are still at high risk for long-term morbidity and neuropsychological deficits; given the potential for reversibility of brain injury, these patients should be admitted or transferred to a hospital with specialty expertise in head injury [72, 73].

There is significant data that both children and adults with mild TBI, GCS 14–15, those with negative CT head, and in the absence of other body system injuries or neurological deficits can be safely discharged [40, 54, 74, 75], though some authors caution that these early discharge guidelines should only be applied to patients with GCS 15 [76] due to significant clinical heterogeneity and poorer clinical outcomes of patients with GCS of 14 [77]. However, given the risk of delayed intracranial bleed in patients on anticoagulant therapy with mild TBI, particularly those on warfarin with an INR >3.0, a period of observation is warranted, followed by repeat CT scan for any new symptoms in order to identify delayed intracranial bleeding [23, 25, 78].

Pearls

- Use clinical decision rules to identify patients at low risk for clinically significant intracranial lesions.
- Patients with a negative initial CT scan, GCS of 15, and no coagulopathy can be safely discharged.
- Patients with moderate TBI with negative initial CT scan should be admitted to a facility with neurosurgical expertise.
- Patients on anticoagulant therapy, particularly with an elevated INR, have higher risk of delayed bleed.

Pitfalls

- GCS of 13 and 14 tend to be different from GCS 15 and can have poorer clinical outcomes even with a negative initial head CT
- Patients with GCS 9–13 and negative initial CT have a relatively high rate of morbidity and should be admitted to a center with specialty expertise

References

1. Menon DK, Schwab K, Wright DW, Maas AI, Demographics and Clinical Assessment Working Group of the International and Interagency Initiative toward Common Data Elements for Research on Traumatic Brain Injury and Psychological Health. Position statement: definition of traumatic brain injury. *Arch Phys Med Rehabil.* 2010;91(11):1637–40.
2. Centers for Disease Control and Prevention. Report to congress on traumatic brain injury in the United States: Epidemiology and Rehabilitation. Atlanta, GA: National Center for Injury Prevention and Control; Division of Unintentional Injury Prevention; 2015.
3. Surgeons ACo. National Trauma Data Bank 2015 Annual Report. 2015.
4. Bordini AL, Luiz TF, Fernandes M, Fernandes M, Arruda WO, Teive HA. Coma scales: a historical review. *Arq Neuropsiquiatr.* 2010;68(6):930–7.
5. Maas AI, Stocchetti N, Bullock R. Moderate and severe traumatic brain injury in adults. *Lancet Neurol.* 2008;7:728–41.
6. Besenki N. Traumatic injuries: imaging of head injuries. *Eur Radiol.* 2002;12:1237–52.
7. Bullock MR, Chesnut R, Ghajar J, Gordon D, Hartl R, Newell DW, Servadei F, Walters BC, Wilberger JE. Guidelines for the surgical management of traumatic brain injury—introduction. *Neurosurgery.* 2006;58(Supplement 2):1–3.
8. Holmes JFC, C.H. Harwood-Nuss' clinical practice of emergency medicine. 5th ed. Philadelphia, PA: Lippincott Williams & Wilkins; 2010.
9. Bullock MR, Chesnut R, Ghajar J, et al. Surgical management of depressed cranial fractures. *Neurosurgery.* 2006;58(3 suppl):S56–60.
10. Bullock MR, Chesnut R, Ghajar J, Gordon D, Hartl R, Newell DW, Servadei F, Walters BC, Wilberger JE. Surgical Management of Acute Epidural Hematomas. *Neurosurgery.* 2006;58(3 Supplement):S7–15.
11. Modi NJ, Agrawal M, Sinha VD. Post-traumatic subarachnoid hemorrhage: a review. *Neuro India.* 2016;64(7):8–13.
12. Quigley MR, Chew BG, Swartz CE, Wilberger JE. The clinical significance of isolated traumatic subarachnoid hemorrhage. *J Trauma Acute Care Surg.* 2013;74(2):581–4.
13. Borczuk P, Penn J, Peak D, Chang Y. Patients with traumatic subarachnoid hemorrhage are at low risk for deterioration or neurosurgical intervention. *J Trauma Acute Care Surg.* 2013;74(6):1504–9.
14. Altmeyer W, Steven A, Gutierrez J. Use of magnetic resonance in the evaluation of cranial trauma. *Magn Reson Imaging Clin N Am.* 2016;24:305–23.
15. McCrory P, Meeuwisse W, Aubry M, Cantu B, Dvorak J, Echemendia R, Engebretsen L, et al. Consensus statement on concussion in sport—the 4th international conference on concussion in sport held in Zurich, November 2012. *Phys Ther Sport.* 2013;14(5):e1–e13.
16. Honce JM, Nyberg E, Jones I, Nagae L. Neuroimaging of concussion. *Phys Med Rehabil Clin N Am.* 2016;27(2):411–28.
17. Su E, Bell M. Diffuse axonal injury. In: Laskowitz D, Grant G, editors. *Translational research in traumatic brain injury.* Boca Raton, FL: CRC Press/Taylor and Francis Group CTI—Frontiers in Neuroscience; 2016.
18. Povlishock JT, Katz DI. Update of neuropathology and neurological recovery after traumatic brain injury. *J Head Trauma Rehabil.* 2005;20(1):76–94.
19. Mittl RL, Grossman RI, Hiehle JF, Hurst RW, Kauder DR, Gennarelli TA, Alburger GW, et al. Prevalence of MR evidence of diffuse axonal injury in patients with mild head injury and normal head CT findings. *Am J Neuroradiol.* 1994;15:1583–9.
20. Cecil KM, Hills EC, Sandel ME, Smith DH, McIntosh TK, Mannon LJ, Sinson GP, et al. Proton magnetic resonance spectroscopy for detection of axonal injury in the splenium of the corpus callosum of brain-injured patients. *J Neurosurg.* 1998;88:795–801.
21. Smith DH, Meaney DF, Shull WH. Diffuse axonal injury in head trauma. *J Head Trauma Rehabil.* 2003;18(4):307–16.
22. Li J, Brown J, Levine M. Mild head injury, anticoagulants, and risk of intracranial injury. *Lancet.* 2001;357:771–2.

23. Cohen DB, Rinker C, Wilberger JE. Traumatic brain injury in anticoagulated patients. *J Trauma*. 2006;60(3):553–7.
24. Lim BL, Manauis C, Asinas-Tan ML. Outcomes of warfarinized patients with minor head injury and normal initial CT scan. *Am J Emerg Med*. 2016;34:75–8.
25. Menditto VG, Lucci M, Polonara S, Pomponio G, Gabrielli A. Management of minor head injury in patients receiving oral anticoagulant therapy: a prospective study of a 24-hour observation protocol. *Ann Emerg Med*. 2012;59(6):451–5.
26. Chan KH, Mann KS, Yue CP, Fan YW, Cheung M. The significance of skull fracture in acute traumatic intracranial hematomas in adolescents: a prospective study. *J Neurosurg*. 1990;72:189–94.
27. Tseng WC, Shih HM, Su Y-C, Chen H-W, Hsiao K-Y, Chen IC. The association between skull bone fractures and outcomes in patients with severe traumatic brain injury. *J Trauma*. 2011;71:1611–4.
28. Baugnon KL, Hudgins PA. Skull base fractures and their complications. *Neuroimaging Clin N Am*. 2014;24:439–65.
29. Tintinalli JE. *Tintinalli's emergency medicine: a comprehensive study guide*. 8th ed. New York: McGraw-Hill Education; 2016. 2128p.
30. Haydel MJ, Preston CA, Mills TJ, Luber S, Blaudeau E, DeBlieux PM. Indications for computed tomography in patients with minor head injury. *N Engl J Med*. 2000;343(2):100–5.
31. Stiell IG, Wells GA, Vandemheen K, Clement C, Lesiuk H, Laupacis A, et al. The Canadian CT head rule for patients with minor head injury. *Lancet*. 2001;357(9266):1391–6.
32. Lyttle MD, Crowe L, Oakley E, Dunning J, Babl FE. Comparing CATCH, CHALICE and PECARN clinical decision rules for paediatric head injuries. *Emerg Med J*. 2012;29(10):785–94.
33. Brenner DJ, Hall EJ. Computed tomography—an increasing source of radiation exposure. *N Engl J Med*. 2007;357(22):2277–84.
34. Osmond MH, Klassen TP, Wells GA, Correll R, Jarvis A, Joubert G, et al. CATCH: a clinical decision rule for the use of computed tomography in children with minor head injury. *CMAJ*. 2010;182(4):341–8.
35. Dunning J, Daly JP, Lomas JP, Lecky F, Batchelor J, Mackway-Jones K. Derivation of the children's head injury algorithm for the prediction of important clinical events decision rule for head injury in children. *Arch Dis Child*. 2006;91(11):885–91.
36. Kuppermann N, Holmes JF, Dayan PS, Hoyle JD Jr, Atabaki SM, Holubkov R, et al. Identification of children at very low risk of clinically-important brain injuries after head trauma: a prospective cohort study. *Lancet*. 2009;374(9696):1160–70.
37. Easter JS, Bakes K, Dhaliwal J, Miller M, Caruso E, Haukoos JS. Comparison of PECARN, CATCH, and CHALICE rules for children with minor head injury: a prospective cohort study. *Ann Emerg Med*. 2014;64(2):145–52. e1–5.
38. Stiell IG, Clement CM, Rowe BH, Schull MJ, Brison R, Cass D, et al. Comparison of the Canadian CT head rule and the New Orleans criteria in patients with minor head injury. *JAMA*. 2005;294(12):1511–8.
39. Bouida W, Marghli S, Souissi S, Ksibi H, Methammem M, Haguiga H, et al. Prediction value of the Canadian CT head rule and the New Orleans criteria for positive head CT scan and acute neurosurgical procedures in minor head trauma: a multicenter external validation study. *Ann Emerg Med*. 2013;61(5):521–7.
40. Barbosa RR, Jawa R, Watters JM, Knight JC, Kerwin AJ, Winston ES, et al. Evaluation and management of mild traumatic brain injury: an Eastern Association for the Surgery of Trauma practice management guideline. *J Trauma Acute Care Surg*. 2012;73(5 Suppl 4):S307–14.
41. Stein SC, Young GS, Talucci RC, Greenbaum BH, Ross SE. Delayed brain injury after head trauma: significance of coagulopathy. *Neurosurgery*. 1992;30(2):160–5.
42. Jagoda AS, Bazarian JJ, Bruns JJ Jr, Cantrill SV, Gean AD, Howard PK, et al. Clinical policy: neuroimaging and decisionmaking in adult mild traumatic brain injury in the acute setting. *Ann Emerg Med*. 2008;52(6):714–48.
43. Bonville DJ, Ata A, Jahraus CB, Arnold-Lloyd T, Salem L, Rosati C, et al. Impact of preinjury warfarin and antiplatelet agents on outcomes of trauma patients. *Surgery*. 2011;150(4):861–8.

44. Nishijima DK, Offerman SR, Ballard DW, Vinson DR, Chettipally UK, Rauchwerger AS, et al. Immediate and delayed traumatic intracranial hemorrhage in patients with head trauma and preinjury warfarin or clopidogrel use. *Ann Emerg Med.* 2012;59(6):460–8.e1–7.
45. Stevens RD, Shoykhet M, Cadena R. Emergency neurological life support: intracranial hypertension and herniation. *Neurocrit Care.* 2015;23(Suppl 2):S76–82.
46. Ng I, Lim J, Wong HB. Effects of head posture on cerebral hemodynamics: its influences on intracranial pressure, cerebral perfusion pressure, and cerebral oxygenation. *Neurosurgery.* 2004;54(3):593–7; discussion 8.
47. Coles JP, Minhas PS, Fryer TD, Smielewski P, Aigbirihio F, Donovan T, et al. Effect of hyperventilation on cerebral blood flow in traumatic head injury: clinical relevance and monitoring correlates. *Crit Care Med.* 2002;30(9):1950–9.
48. Ichai C, Armando G, Orban JC, Berthier F, Rami L, Samat-Long C, et al. Sodium lactate versus mannitol in the treatment of intracranial hypertensive episodes in severe traumatic brain-injured patients. *Intensive Care Med.* 2009;35(3):471–9.
49. Francony G, Fauvage B, Falcon D, Canet C, Dilou H, Lavagne P, et al. Equimolar doses of mannitol and hypertonic saline in the treatment of increased intracranial pressure. *Crit Care Med.* 2008;36(3):795–800.
50. Kelly DF, Goodale DB, Williams J, Herr DL, Chappell ET, Rosner MJ, et al. Propofol in the treatment of moderate and severe head injury: a randomized, prospective double-blinded pilot trial. *J Neurosurg.* 1999;90(6):1042–52.
51. Fong JJ, Sylvia L, Ruthazer R, Schumaker G, Kcomt M, Devlin JW. Predictors of mortality in patients with suspected propofol infusion syndrome. *Crit Care Med.* 2008;36(8):2281–7.
52. Muizelaar JP, Marmarou A, Ward JD, Kontos HA, Choi SC, Becker DP, et al. Adverse effects of prolonged hyperventilation in patients with severe head injury: a randomized clinical trial. *J Neurosurg.* 1991;75(5):731–9.
53. Roberts I, Sydenham E. Barbiturates for acute traumatic brain injury. *Cochrane Database Syst Rev.* 2012;12:CD000033.
54. Policy C. Neuroimaging and decisionmaking in adult mild traumatic brain injury in the acute setting. *Ann Emerg Med.* 2008;52:714–48.
55. Lorente L. New prognostic biomarkers in patients with traumatic brain injury. *Arch Trauma Res.* 2015;4(4):e30165.
56. Provenzale JM. Imaging of traumatic brain injury: a review of the recent medical literature. *AJR.* 2010;194:16–9.
57. Chawla H, Malhotra R, Yadav RK, Griwan MS, Paliwal PK, Aggarwal AD. Diagnostic utility of conventional radiography in head injury. *J Clin Diagn Res.* 2015;9(6):13–5.
58. Mata-Mbemba D, Mugikura S, Nakagawa A, Murata T, Kato Y, Tatewaki Y, et al. Intraventricular hemorrhage on initial computed tomography as marker of diffuse axonal injury after traumatic brain injury. *J Neurotrauma.* 2015;32:359–65.
59. Nace SR, Gentry LR. Cerebrovascular trauma. *Neuroimaging Clin N Am.* 2014;24(3):487–511.
60. Beauchamp MH, Ditchfield M, Babl FE, Kean M, Catroppa C, Yeates KO, Anderson V, et al. Detecting traumatic brain lesions in children: CT versus MRI versus susceptibility weighted imaging (SWI). *J Neurotrauma.* 2011;28(6):915–27.
61. Roguski M, Morel B, Sweeney M, Talan J, Rideout L, Riesenburger RI, Madan N, et al. Magnetic resonance imaging as an alternative to computed tomography in select patients with traumatic brain injury: a retrospective comparison. *J Neurosurg Pediatr.* 2015;15:529–34.
62. Lee H, Wintermark M, Gean AD, Ghajar J, Manley GT, Mukherjee P. Focal lesions in acute mild traumatic brain injury and neurocognitive outcome: CT versus 3T MRI. *J Neurotrauma.* 2008;25:1049–56.
63. http://www.cdc.gov/concussion/headsup/pdf/facts_for_Physicians_booklet-a.pdf Heads up. Facts for physicians about mild traumatic brain injury (MTBI).
64. Savola O, Hillbom M. Early predictors of post-concussion symptoms in patients with mild head injury. *Eur J Neurol.* 2003;10(2):175–81. doi:10.1046/j.1468-1331.2003.00552.x.
65. Hou R, Moss-Morris R, Peveler R, Mogg K, Bradley BP, Belli A. When a minor head injury results in enduring symptoms: a prospective investigation of risk factors for postconcussional

- syndrome after mild traumatic brain injury. *J Neurol Neurosurg Psychiatry*. 2012;83(2):217–23. doi:10.1136/jnnp-2011-300767.
66. Ponsford J, Cameron P, Fitzgerald M, Grant M, Mikocka-Walus A, Schönberger M. Predictors of postconcussive symptoms 3 months after mild traumatic brain injury. *Neuropsychology*. 2012;26(3):304–13. doi:10.1037/a0027888.
 67. Faux S, Sheedy J, Delaney R, Riopelle R. Emergency department prediction of post-concussive syndrome following mild traumatic brain injury—an international cross-validation study. *Brain Inj*. 2011;25(1):14–22. doi:10.3109/02699052.2010.531686.
 68. De Kruijk JR, Leffers P, Menheere PP, Meerhoff S, Rutten J, Twijnstra A. Prediction of post-traumatic complaints after mild traumatic brain injury: early symptoms and biochemical markers. *J Neurol Neurosurg Psychiatry*. 2002;73(6):727–32. doi:10.1136/jnnp.73.6.727.
 69. Meares S, Shores EA, Taylor AJ, Batchelor J, Bryant RA, Baguley JJ, Chapman J, Gurka J, Dawson K, Capon L, Marosszeky JE. Mild traumatic brain injury does not predict acute post concussion syndrome. *J Neurol Neurosurg Psychiatry*. 2008;79(3):300–6. doi:10.1136/jnnp.2007.126565.
 70. Ganti L, Khalid H, Patel P, Daneshvar Y, Bodhit AN, Paters KR. *Int J Emerg Med*. 2014;7:31. doi:10.1186/s12245-014-0031-6. eCollection 2014.
 71. Patel HC, Bouamra O, Woodford M, King AT, Yates DW, Lecky FE. Trends in head injury outcome from 1989 to 2003 and the effect of neurosurgical care: an observational study. *Lancet*. 2005;366:1538–44.
 72. Rimel RW, Giordani B, Barth JT, Jane JA. Moderate head injury: completing the clinical spectrum of brain trauma. *Neurosurgery*. 1982;11(3):344–51.
 73. Surgeons ACo. Best Practices in the Management of Traumatic Brain Injury. ACS Trauma Quality Improvement Program [Internet]. 2015. <https://www.facs.org/~media/files/quality-programs/trauma/tqip/traumatic-brain-injury-guidelines.ashx>.
 74. Holmes JF, Borgialli DA, Nadel FM, Quayle KS, Schambam N, Cooper A, Schunk JE, et al. Do children with blunt head trauma and normal cranial computed tomography scan results require hospitalization for neurologic observation? *Ann Emerg Med*. 2011;58(4):315–22.
 75. Livingston DH, Lavery RF, Passannante MR, Skurnick JH, Baker S, Fabian TC, Fry DE, et al. Emergency department discharge of patients with a negative cranial computed tomography scan after minimal head injury. *Ann Surg*. 2000;232(1):126–32.
 76. af Geijerstam JL, Britton M. Mild head injury: reliability of early computed tomographic findings in triage for admission. *Emerg Med J*. 2005;22(2):103–7.
 77. Culotta VP, Sementilli ME, Gerold K, Watts CC. Clinicopathological heterogeneity in the classification of mild head injury. *Neurosurgery*. 1996;38(2):245–50.
 78. Kaen A, Jimenez-Roldan L, Arrese I, Delgado MA, Lopez PG, Alday R, Alen JF, et al. The value of sequential computed tomography scanning in anticoagulated patients suffering from minor head injury. *J Trauma*. 2010;68:895–8.

Claire S. Jacobs and Imoigele P. Aisiku

Case Presentation

A 66-year-old man with a history of small bowel adenocarcinoma s/p distant resection and chemotherapy, hypertension, hyperlipidemia, diabetes, neuropathy, and chronic pain managed by his primary care physician with oral narcotics was brought in by ambulance after being found unresponsive by his wife, 3 h after last seen well. Vital signs are BP 138/79, HR 87, RR 20, and SaO₂ 95% on room air. On exam, he was drowsy, looking around the room but aphasic with no speech production, not following commands, and diffuse weakness possibly more marked on the right. The family was not at the bedside.

A Code Stroke was activated. The NIH stroke scale score was 10. The following labs were sent: finger-stick glucose; basic metabolic panel with calcium, magnesium, and phosphorus; complete blood count (CBC); liver studies; PT/INR; and urine and serum toxicology. Emergent CT and CT angiogram of the head and neck were obtained and were negative. An MRI brain was incomplete because he was unable to stay still or follow commands, but the DWI and ADC sequences did not show acute infarct. A bedside EEG was negative for seizure but did show diffuse, bilateral theta/delta slowing. His wife arrived and said he had started using “marijuana” for pain relief, as he was worried about opioid addiction if he used the prescribed narcotics. Per phone, the patient’s son stated that his father had started using synthetic cannabinoids purchased on the Internet. Over 2 h following his arrival, the patient’s motor deficits resolved, and there was interval improvement in language (following commands, spontaneous, fluent speech), though he remained inattentive and perseverative. He was transferred to the ED observation unit and monitored

C.S. Jacobs, M.D., Ph.D. • I.P. Aisiku, M.D., M.B.A. (✉)
Brigham and Women’s Hospital, Boston, MA, USA
e-mail: iaisiku@bwh.harvard.edu

until he returned to his cognitive baseline. He was diagnosed with acute toxic encephalopathy due to synthetic cannabinoid use, advised to avoid these substances, and referred to a pain specialist.

This case highlights many of the challenges presented by workup and management of patients presenting with paroxysmal changes in mental status, sensory, or motor function. The differential for these cases is broad, and the acuity of intervention demanded depends on the suspected etiology. This patient was initially assessed for emergency conditions such as intracranial hemorrhage, ischemic infarct, cardiac emergencies, and seizure and the working diagnosis adjusted in response to his evolving clinical picture and available data.

This chapter will discuss seizures and seizure mimics and the evaluation of patients presenting with possible seizure and address important points in the history, exam and evaluation that may distinguish seizures from seizure mimics, and finally the management of status epilepticus.

Seizures and Epilepsy

A seizure is an involuntary change in behavior or neurological function due to abnormal cortical neuronal activity. Epilepsy is a chronic disorder characterized by repeated unprovoked seizures. In the United States, up to 10% of the population will experience seizure during their life, and seizure accounts for 1–2% of annual emergency room visits [1, 2]. In 2010, the International League Against Epilepsy (ILAE) published a revised seizure and epilepsy classification scheme based on clinical seizure appearance and EEG findings (Table 4.1) and is expected to publish an updated version in 2017 [3] (updates will be available at http://www.ilae.org/Visitors/Centre/Definition_Class.cfm). The **clinical symptoms and presentation of a seizure** (i.e., the **semiology**) are related to the area of cortex and networks involved [4–6]. Patients with epilepsy experience stereotyped events, i.e., aura and semiology do not vary substantially from seizure to seizure. Auras may present as nausea, anxiety/fear,

Table 4.1 Seizure classification [3]

Focal seizures without dyscognitive features (simple partial)	Focal seizures with dyscognitive features (complex partial)	Primary generalized seizures
Focal motor	Evolved from focal seizure without dyscognitive features	Absence
Focal sensory	Dyscognitive features at onset	Myoclonic
Psychic symptoms	Focal without dyscognitive features evolving to generalized	Clonic
Somatosensory	Focal with dyscognitive features evolving to generalized	Tonic
Autonomic symptoms	Focal without dyscognitive features evolving to focal with dyscognitive features evolving to generalized	Tonic-clonic
		Atonic

“epigastric rising” sensation, déjà vu, visual distortions, or auditory or olfactory hallucinations (typically an unpleasant smell, e.g., rotten eggs). Witnesses may report stereotypic motor activity and/or dyscognitive features or impaired awareness, like cessation of activity, staring, aimless walking, or purposeless automatisms (picking at clothes or bedsheets, lip smacking). **Focal seizures** (previously *partial seizures*) refer to seizures “originating within networks limited to one hemisphere”; the seizure may remain limited to that hemisphere or can *secondarily generalize* [3]. Focal seizures are further classified depending on whether they occur *without* (**focal seizure without dyscognitive features**, i.e., without impaired awareness, previously called *simple partial seizure*) or *with* (**focal seizure with dyscognitive features**, i.e., with impaired awareness, previously called *complex partial seizure*) associated changes in mental status or awareness. The term “dyscognitive features” refers to impaired awareness or any change in consciousness or level of arousal, such as staring or decreased responsiveness. Loss of consciousness (LOC) occurs only if the seizure secondarily generalizes. Focal seizures are usually limited to 3 min or less, with rapid return to baseline following a focal seizure *without* dyscognitive features. Patients may experience headache, confusion, fatigue, or somnolence for an hour after a focal seizure *with* dyscognitive features.

Generalized seizures result from abnormal neuronal electrical discharges “originating at some point within, and rapidly engaging, bilaterally distributed networks” [3]. They often have an underlying genetic etiology. Generalized seizure types are **absence**, **myoclonic**, **tonic**, **tonic-clonic**, and **atonic** seizures.

Absence seizures: characterized by brief suspension (5–15 s) of motor activity and may present clinically as subtle staring episodes or a pause in conversation with subsequent return to normal activity with no memory of the event. They almost always start in childhood and typically remit by adolescence but may persist into adulthood.

Myoclonic epilepsy: quick, jerking movements (typically upper extremity flexors), often shortly after waking from sleep. Patients may be undiagnosed until they suffer a GTC and undergo EEG.

Generalized tonic-clonic seizures (GTC): tonic extension, sometimes with a “startled cry” at onset (involuntary respiratory muscle contraction) that progresses to rhythmic, synchronized clonic jerking of extremities before gradually slowing to a stop, followed by a postictal period. Patients may have generalized seizures that are primarily *clonic* or primarily *tonic* in nature.

Atonic seizures: sudden loss of tone, often result in falls and injuries.

Provoked seizures: provoked seizures occur in the presence of one or more factors that lower the seizure threshold and make a patient more susceptible to seizure. This can occur in patients with or without underlying epilepsy. Provoked seizures generally present as GTCs, though focal onset can occur in the setting of preexisting neurological injury. Diagnosing provoked seizures is critical, as treatment primarily involves addressing and correcting (when possible) the underlying provoking factor. Patients may require symptomatic, short-term treatment with an AED but do not typically require long-term AED therapy. Common provoking factors are listed in Table 4.3.

Status epilepticus (SE): traditionally defined as prolonged seizure or seizure cluster without return to baseline for at least 30 min. Mortality ranges from 7 to 40%, with worse outcomes predicted by generalized SE, longer duration, older patient age, and concomitant conditions such as stroke, CNS infection or malignancy, or anoxic brain injury [7]. Complications include hypoxia, hypotension, acidosis, hyperthermia, rhabdomyolysis, and neuronal injury. Early and aggressive pharmacological intervention and a collaborative approach involving the emergency room team, the neurologist, and the admitting service promote a successful outcome.

A **revised operational definition of SE**, aimed at lowering morbidity and mortality rates, is **seizure lasting longer than 5 min or two or more seizures without return to baseline** [7, 8]. SE can present with focal seizures with or without dyscognitive features, generalized tonic-clonic seizures, absence seizures, or nonconvulsive subclinical seizures. Most cases in patients with epilepsy are due to medication changes or missed medication doses and due to stroke or other acquired brain injury in patients without underlying epilepsy. **Refractory SE (RSE)** is a serious potential complication for all patients with SE and is **operationally defined as ongoing clinical or electrographic seizures despite adequate initial benzodiazepine doses followed by a second acceptable AED**.

Differential Diagnosis

The differential for paroxysmal change in mental status extends beyond seizures, and a partial list is shown below [9–12]:

- Epileptic seizure
 - Provoked
 - Unprovoked
- Cardiovascular event
 - Stroke or transient ischemic attack (TIA)
 - Syncope/presyncope, convulsive syncope
 - Arrhythmia
- Psychiatric etiology
 - Psychogenic non-epileptic spell
 - Panic attack
 - Dissociative fugue
- Transient global amnesia (TGA)
- Migraine headache +/- migraine aura
- Cortical spreading depression from SAH/CAA
- Metabolic disturbances (drugs, pharmaceuticals)
- Movement disorders
 - Tic
 - Essential myoclonus
- Sleep disorders

Stroke and transient ischemic attack (TIA) are neurological emergencies that can present with paroxysmal-altered mental status or new focal neurological complaints or deficits. They can present with sensory or motor deficits, complaints of feeling vertiginous or “off,” or change in level of awareness. Stroke and TIA more commonly cause neurological *deficit* (*negative* symptoms such as weakness, numbness), while seizures are more often associated with *positive* motor or sensory symptoms (twitching, paresthesias).

Syncope and presyncope are common seizure mimics, particularly in older patients, that result from decreased cerebral perfusion often due to volume status, cardiac etiologies, or dysautonomia (e.g., vasovagal or orthostatic hypotension) [11]. *Suggestive features on history* include hypertension, coronary artery disease, chest pain, anemia, neuropathy, Parkinson disease, multisystem atrophy (MSA) or postural orthostatic hypotension, or family history of sudden death. Events may be presaged by a *prodrome* including light-headedness, dimming or “tunnel” vision, hearing decrease, nausea, or diaphoresis, and witnesses may notice diaphoresis and pallor at onset. *Triggers* include sudden postural changes (e.g., sitting to standing), prolonged standing, exercise, particularly in hot weather, fits of coughing, straining with a bowel movement, micturition, or exposure to a painful stimulus. Syncopal events are brief in duration once cerebral perfusion is restored, and patients regain consciousness within seconds and do not experience persistent somnolence, confusion, or focal deficits. Patients lose postural tone during the event, though in the case of “convulsive syncope,” witnesses may describe ~15 s of small amplitude, multifocal “shaking” or “jerking” *after* LOC; these movements are *not* epileptic in origin [13, 14].

Psychogenic non-epileptic seizures (PNES, previously “pseudoseizures”) are spells clinically resembling seizures but without underlying abnormal electrical activity [15]. There is a female predominance, and patients may have a history of post-traumatic stress disorder, depression, or abuse [16, 17]. It is critical to note that PNES is not malingering but is a functional neurological disorder more akin to conversion disorder or a dissociative spell [18]. Differentiating PNES from epileptic seizures can be difficult, and diagnosis often requires referral to a neurologist for routine and video EEG monitoring [15, 19]. Patients may report persistent or increasing spell frequency or duration despite uptitration of AEDs. PNES spells may differ from epileptic seizures in that they may last longer, have waxing/waning severity, result in bite on the tip of the tongue, and involve unsynchronized or bilateral convulsions with preserved consciousness and often closed eyes (rather than open, as with epileptic events). Involving a neurologist is instrumental in the diagnostic process, and care of these patients often involves a multidisciplinary approach, including neurology, psychiatry, social work, etc.

Transient global amnesia (TGA): an acute-onset, self-limited amnesia (anterograde with a small recent retrograde component) clinically characterized by normal exam and behavior except for a state of “bewilderment” with repetitive questioning (e.g., “what happened?” and “why am I here?”). Patients are oriented to self only, and the symptoms resolve over 24 h or less with patients regaining the ability to form new memories. Though the period to which they are amnesic shrinks, it does not entirely

resolve. Triggers include physical exertion or an intense emotional experience, such as a heated quarrel with a spouse. MRI imaging within 24–48 h after onset may show a punctate hippocampal lesion on DWI, but the diagnosis is clinical and not based on laboratory or MRI results [20]. Management involves frequent reorientation and observation over time until they have returned to baseline. Patients with significant vascular risk factors or atypical presentation merit stroke workup.

Migraine can present as headache alone, aura alone (acephalgic migraine), or “classic migraine” with aura preceding headache. The exam and laboratory studies are normal, though patients with hemiplegic migraine can experience unilateral sensory or motor symptoms involving the face and extremities, visual symptoms, aphasia, dysarthria, or mild confusion. Headache can precede or follow other symptoms or may be absent, and complete resolution can take up to 24 h [21]. **Cortical spreading depression** due to cortical irritation by subarachnoid blood due, e.g., to subarachnoid hemorrhage (SAH) from cerebral venous sinus thrombosis or fragile vessels as in cerebral amyloid angiopathy (CAA) can present with abnormal motor or sensory phenomena [22, 23]. Diagnosis is based on clinical history and imaging studies showing subarachnoid blood.

Movement disorders: tics, dystonia, or essential myoclonus present with preserved consciousness and stereotyped, repetitive movements.

Sleep disorders: drop attacks (narcolepsy-cataplexy), REM behavior disorders involving complex motor movements related to acting out a dream that cease when the patient is woken up, or hypnagogic jerks.

History

Separating epileptic seizure from seizure mimics can be challenging. The patient’s medical history, medication list, and a firsthand description from a witness to the event are crucial [10]. Accurate diagnosis is critical to providing appropriate management, and diagnosis relies on information obtained by frontline providers (Table 4.2).

Key points in the history:

- *Clinical prodrome?* Seizure: patients may experience an antecedent, short-lived aura or focal neurological symptoms, though patients may not recall the event itself. Syncope: prodrome of several minutes to hours and witnesses may notice the patient becoming pale or diaphoretic. Migraine auras: stereotyped, last several minutes to an hour, and may or may not be accompanied by headache.
- *Paroxysmal onset?* What was the patient doing at time of onset? What was the pace of symptom evolution? Seizure is characterized by rapid onset of aura or clinical signs. Presyncope/syncope is typically characterized by rapid clinical change with the event. With cerebrovascular events (TIA, stroke, SAH), the pace is typically acute as well.
- *Is this the first such event?* Patients and families may not be aware of prior episodes or recognize their significance. Ask about a history of febrile seizures in

Table 4.2 (Adapted from [12]) Distinguishing Seizure from Seizure Mimics

	Seizure	Syncope	Psychogenic non-epileptic seizures (PNES)
Prodrome	Brief	Minutes to hours light-headedness, nausea, chest pain, palpitations, diaphoresis, or feeling warm	Variable
Onset	Paroxysmal, +/- aura	Paroxysmal over seconds	Variable
Prior episodes?	+/-	+/-	+/-
Event description	Seconds to 3 min Eyes open +/- head deviation +/- gaze deviation +/- lateral tongue bite +/- urinary incontinence Synchronized body movements	Diaphoretic, pale at start Sudden loss of postural tone +/- brief jerking with LOC	Variable, often prolonged (>3 min) +/-crescendo/decrecendo periods Head side-to-side movements Eyes closed +/- tongue bite on tongue tip Asynchronous body movements Unusual movements, e.g., pelvic thrusting Interactive/responsive during episode
Triggers?	Sleep deprivation Systemic illness/fever Menses Excess alcohol Recreational drug use Increased stress AED nonadherence Recent med changes	Dehydration Prolonged exercise in warm weather Prolonged standing Sudden postural change Micturition, straining with bowel movement Dramatic fluid or electrolyte shifts (e.g., hemodialysis)	+/- acute stressor in history
Return to baseline	Delayed Postictal somnolence and confusion Limited recall of event and moments before clinically apparent +/- postictal headache +/- postictal paralysis	Rapid once trigger removed Preserved recall up to LOC	Variable, may be prolonged
Relevant past history		FHx sudden cardiac death Cardiac history Hypertension Chronic kidney disease - Hemodialysis - Recent/missed HD sessions Diabetes Infection Drug/alcohol use	Mood disorder Psychiatric history

childhood, episodes of myoclonic jerking as a teenager or young adult, odd “episodes” during sleep, nocturnal urinary incontinence, finding a new tongue or cheek bite on waking, unusual fatigue and grogginess on waking, bedsheets in disarray in the morning, staring episodes as a child or difficulties “paying attention” in school, or sensitivity to flickering lights or shadows. Patients presenting with syncope who have a prior history of similar events merit cardiovascular evaluation.

- *What did the event look like?* Patients with epilepsy and/or their family members are often able to describe the event in detail and identify whether it differs significantly from prior seizures. Patients with PNES may have several different spell types, and some but not all patients have insight into whether they are experiencing a PNES spell. A thorough description of the event is critical for patients presenting with a first-time event. Descriptions such as “they had a seizure” or “her eyes rolled back” are not particularly helpful. Key points include focal onset versus generalized onset, sudden LOC accompanied by abnormal motor movements, laterality of symptoms, head deviation, gaze deviation, and how the motor symptoms evolved over time (i.e., a period of stiffening followed by jerking movements that slowed down suggests a GTC). LOC with a few jerking movements after standing up too quickly is likely convulsive syncope.
- *Triggers for the event?* Common seizure triggers are listed in Table 4.3. Patients with epilepsy are often well versed in their seizure triggers but may not be aware that some medications, such as antibiotics, can lower their seizure threshold even in the setting of AED compliance. Commonly prescribed medications may trigger seizures with use or discontinuance. Benzodiazepine withdrawal, as an example, can provoke seizures, even in the absence of an underlying seizure disorder. Seizures related to ethanol are more likely during withdrawal rather than intoxication, so blood alcohol level (BAL) may be normal. Intoxication with alcohols such as ethylene glycol and methanol can precipitate seizures; these agents are not typically included on standard toxicology screens, so an elevated serum osmolality gap or abnormal arterial blood gas may be the only clue. Carbon monoxide poisoning can cause seizures generally only with carboxyhemoglobin levels >50%. Other common offenders include stimulants, such as cocaine, methamphetamine, and MDMA (3,4-methylenedioxymethamphetamine, aka ecstasy), but also newer, more heterogeneous substances such as “bath salts” (which may contain compounds structurally similar to MDMA) or synthetic cannabinoids (aka “K2” or “Spice,” among other names). The newer “synthetic” drugs are more commonly associated with acute intoxication and due to ever-changing formulations and potencies that often evade detection on routine toxicology tests. Recognition of intoxication or drug abuse offers an opportunity to provide counseling on substance abuse in addition to guiding long-term seizure management. The clinician should be aware of regional and national recreational substances that may be en vogue. Presyncope/syncope event triggers include postural change, micturition, dehydration, or other fluid and electrolyte shifts (e.g., during hemodialysis).

Table 4.3 Common factors associated with provoked seizure (adapted from Table 2 [25])

Primary neurological triggers	Systemic factors	Drugs that can cause seizure or lower seizure threshold
Head trauma	Sleep deprivation	Analgesics (meperidine, tramadol)
SAH/SDH/epidural hematoma	Fever/systemic illness	Anesthetics (bupivacaine, lidocaine, procaine, etidocaine, enflurane, sevoflurane)
Neurosurgical intervention	Excess stress	Antibiotics (fluoroquinolones, TMP/SMX, penicillins)
Mass lesion	Drug or alcohol intoxication/withdrawal	Anticholinesterases (physostigmine, organophosphates)
Venous sinus/cortical vein thrombus	Metabolic derangements:	Antidepressants (bupropion)
Vascular malformation	– Hypo- or hyperglycemia	Antihistamines
Meningoencephalitis	– Hyponatremia	Antipsychotics (phenothiazines, butyrophenones, clozapine)
CNS abscess	– Hypocalcemia	Beta-blockers (propranolol, oxprenolol)
HIV encephalopathy	– Hypomagnesemia	Chemotherapeutics (etoposides, ifosfamide, cis-platinum)
Hypertensive encephalopathy/PRES	– Hyperosmolar state	Cyclosporine, FK506
Eclampsia	– Hepatic encephalopathy	Glucose-lowering agents
	– Uremia	Isoniazid
	– Hyperthyroidism	Methylxanthines (e.g., theophylline)
	– Porphyrria	Narcotics (fentanyl, meperidine, pentazocine, propoxyphene, tramadol)
		Phencyclidine
		Sedatives (EtOH, benzodiazepines)
		Stimulants (amphetamines, cocaine, ephedrine, ecstasy, terbutaline, phenylpropanolamine)
		Synthetic marijuana, “bath salts”

- *Did the patient return to baseline after the event? How long did that recovery take?* Generalized seizures and focal seizures with dyscognitive features are followed by a prolonged postictal state, and patients may report muscle soreness. More dramatic postictal states can also occur, such as postictal motor paresis (“Todd paralysis”) mimicking a stroke or postictal psychosis. The most vulnerable patients are those who have transitioned from clinically apparent seizures, such as generalized tonic-clonic seizure, to more subtle seizures or nonconvulsive status. Look for clues like ongoing, minimal face or body movements without any sign of return to alertness. Post-syncope recovery is generally rapid (seconds to 1 minute). PNES spells often last longer than an epileptic convulsive seizure and may have several crescendo/decrescendo periods.

- *Past medical history?* Inquire about a personal or family history of developmental delay (delay in meeting milestones, social or school difficulties), history of seizure, or other neurological or psychiatric disorders. Also ask about factors associated with increased risk of acquired seizures, such as head trauma (penetrating or closed, including traumatic brain injury), brain surgery and/or hardware in place, systemic or CNS malignancy, prior stroke, subarachnoid or subdural hemorrhages, meningoencephalitis, and autoimmune/inflammatory or paraneoplastic encephalitis [24]. A past medical history significant for cardiovascular issues: chronic kidney disease, especially with recent hemodialysis treatment or missed dialysis treatments: diabetes: infection: drug or alcohol use; or recent medication changes can help narrow the differential.

Physical Examination

- Vital signs
 - Tachycardia, bradycardia, or asystole
 - Blood pressure
 - Orthostatic hypotension
 - Hypertension
 - Temperature
 - Fever, rigors, rash, diarrhea, or other indications of infection
 - SaO₂ and respiratory rate
 - Hypoxia or airway compromise
- Ongoing motor movements?
 - Generalized convulsions
 - Patient unresponsive; ongoing, subtle, or intermittent convulsions
 - Mentation
 - Focal movements
 - Subtle ongoing movements
 - Mentation abnormal vs. at baseline
- Focal neurological changes
 - Ongoing movements or weakness. Focal vs. unilateral
 - Sensory changes
 - Hemisensory, focal, or bilateral and symmetric
 - Positive (pain, paresthesias) or negative (numbness) symptoms
- Evidence of trauma related to event
 - Head trauma
 - Assess also for neck/spine trauma
 - Bruising, abrasions, lacerations, or burns
 - Assess for accompanying fractures or dislocations
- Overt evidence of pregnancy
 - Consider eclampsia or AED dosing issues
- Evidence of drug use

The exam is most informative during or shortly after the event. Tachycardia and/or hypertension may precede and accompany focal or convulsive seizures [26]. Less commonly, patients may experience bradycardia and even asystole [27]. Arrhythmia is more consistent with cardiogenic etiologies. Airway and oxygenation must be monitored, but intubation should be done judiciously. Patients who are postictal and somnolent may require oral suctioning and supplemental oxygen transiently but generally retain control of their airway. Consideration of intubation is recommended if there is clinical evidence of respiratory distress, hypoxia, altered mental status with respiratory depression, and escalating doses of benzodiazepines and is discussed further below [8, 28, 29]. Persistent focal neurological deficits, such as hemiparesis or hemisensory changes, suggest ischemic or hemorrhagic stroke, TIA, hemiplegic migraine, or postictal Todd paralysis. Patients experience powerful, sustained muscle contractions with seizures and are at risk of injuries, such as vertebral or long bone fractures, dislocations, lacerations or burns, periorbital hematomas, subdural hemorrhages, or rhabdomyolysis.

Emergency Department Workup

The following section presents recommendations from guidelines published by the American College of Emergency Physicians (ACEP) [30, 31], American Academy of Neurology (AAN) [32, 33], American Epilepsy Society (AES) [7], and the Neurocritical Care Society (NCS) [8]. The recommendation level (A, B, C, or U) is indicated where appropriate. The guidelines are periodically reviewed and updated, with the updated versions accessible through the websites of the above associations.

Laboratory studies: recommendations vary depending on the clinical situation, but laboratory studies can help evaluate for provoked seizure and guide treatment. The ACEP guidelines address evaluation of an otherwise *healthy adult with new-onset seizure* with return to normal neurological baseline, and they recommend serum glucose and serum sodium, as well as pregnancy test in a woman of child-bearing age (as pregnancy may affect testing, disposition, and decisions in regard to antiepileptic medications) (**Level B**). AAN guidelines cite insufficient evidence to make recommendations for routine laboratory testing but do state that, in patients presenting with *initial apparent unprovoked seizure*, blood glucose, blood counts and electrolyte panels, and toxicology testing may be helpful (**Level U**). NCS guidelines for evaluation of *patients presenting in status* support finger-stick glucose followed by blood glucose, CBC, basic metabolic panel with calcium (total and ionized) and magnesium, and AED levels (if appropriate), while additional studies, such as comprehensive toxicology testing (including toxins frequently associated with seizures), liver function tests, serial troponins, type and screen, coagulation studies, ABG, and testing for inborn errors of metabolism, should be considered based on the clinical presentation. The AES' suggested treatment algorithm for *patients presenting with status epilepticus* includes similar laboratory studies as the NCS, including finger-stick glucose, serum electrolytes, CBC,

toxicology screening, and AED levels. In practice, laboratory testing should be informed by published guidelines but tailored to each individual patient.

Convulsive seizures may cause a mild leukocytosis and modestly elevated lactate and creatine kinase (CK). These values normalize rapidly, so significantly or persistently abnormal values or concerning features on exam, such as a focal neurological deficit, should prompt additional investigation. Serum prolactin level is normal following a non-epileptic event but may be elevated following a focal seizure with dyscognitive changes or GTC if measured within 20 min of the event. Of note, serum prolactin has low sensitivity and low negative predictive value for seizure, so the AAN warns against using serum prolactin to distinguish PNES from epileptic seizure. Additional labs should be guided by the clinical presentation.

Antiepileptic levels: for patients with known seizure disorder, decisions about AED adjustment are partially dependent on whether a seizure trigger is identified. A serum AED level should be checked (if applicable) in epilepsy patients presenting with seizure, but the clinically effective level varies for each patient; a nominally “low” level does not necessarily indicate nonadherence, and toxicity is diagnosed based on clinical evidence of toxicity rather than the serum level. Some AED levels do not result quickly enough to be useful in the acute setting but will be helpful during outpatient follow-up. Table 4.4 lists common AED side effects and relevant lab studies [34].

Neuroimaging

Neuroimaging studies should be guided by the clinical presentation, and the imaging modality depends on the question one would like to answer. Abnormal imaging findings are more likely in patients with altered mentation and focal deficits on exam or in patients who have experienced a focal seizure. CT imaging is more appropriate for unstable patients or to evaluate rapidly for potential intracranial catastrophes. MRI is more sensitive and can detect subtle structural abnormalities, such as a focal developmental lesion or mesial temporal sclerosis, but is dependent on patient’s ability to follow commands and tolerate a longer study. Many centers have MRI protocols for first-time seizure workup that include coronal thin cuts through the medial temporal lobes to assess for hippocampal sclerosis; discussion with a neuroradiologist and/or a neurologist can facilitate selection of the most appropriate imaging study or sequences for a particular patient.

For a *patient with new-onset seizure who has now returned to baseline*, ACEP recommends a CT head in the ED whenever an acute intracranial process is suspected, if there is a history of acute head trauma, history of malignancy, immunocompromised, fever, persistent headache, history of anticoagulation or a new focal neurological finding on exam, age above 40 years, or focal onset before generalization (based on a 1996 multidisciplinary clinical policy for neuroimaging in first-time seizure patients) [30]. Neuroimaging may be deferred to the outpatient setting after a first-time seizure in patients who are alert and have returned to baseline and if reliable follow-up is available (**Level B**). AAN guidelines state that brain imaging

Table 4.4 Side effects and indicated labs for common AEDs [34]

AED	Common SEs	Serious SEs	Goal serum levels (mg/L) and/or contraindications (CI)
Benzodiazepine	Drowsiness Nystagmus Ataxia Dysarthria	Withdrawal seizure Respiratory depression	
Phenytoin/ fosphenytoin	Ataxia Encephalopathy Gingival hyperplasia Coarsening of facial features Osteoporosis	Hepatic failure Serum sickness Lupus syndrome Dermatitis Neuropathy Hirsutism	15–25 mg/L total or 1.5–2.5 mg/L (free)
Phenobarbital	Somnolence Dizziness Mood changes N/V	Agranulocytosis SJS/TEN Hepatic failure Thrombophlebitis Thrombocytopenia Osteopenia	15–50 mg/L CI: Porphyria Hepatic disease Respiratory distress or obstructive disease
Valproate	Weight gain Alopecia Peripheral edema N/V/constipation Ataxia, tremor, nystagmus, diplopia	Agranulocytosis Thrombocytopenia Aplastic anemia SJS/TEN Hepatic failure Hyperammonemia Pancreatitis Ototoxicity	50–100 mg/L
Levetiracetam	Somnolence, irritability/mood changes, N/V	Pancytopenia Hepatic failure SJS/TEN Suicidality	25–60 mg/L
Lamotrigine	Ataxia, dizziness, diplopia, tremor, N/V	SJS/TEN Renal or hepatic failure DIC Aseptic meningitis	2–20 mg/L
Carbamazepine	Hyper/hypotension N/V, dizziness, diplopia, nystagmus	AV block, CHF SJS/TEN Aplastic anemia Agranulocytosis Angioedema Hepatitis Acute renal failure Acute intermittent porphyria Hypocalcemia Hyponatremia	4–12 mg/L CI: Hx bone marrow suppression MAOI in last 14 days Hypersensitivity to TCAs Consider test for HLA-B*1502 prior to initial dose
Oxcarbazepine	Ataxia, diplopia, nystagmus, vertigo	Hyponatremia SJS/TEN Angioedema Pancytopenia	15–35 mg/L

(continued)

Table 4.4 (continued)

AED	Common SEs	Serious SEs	Goal serum levels (mg/L) and/or contraindications (CI)
Topiramate	Anorexia Weight loss Paresthesias Somnolence Cognitive dulling	Renal calculi Oligohidrosis Hyperthermia Metabolic acidosis Acute myopia and secondary angle-closure glaucoma	
Gabapentin	Somnolence Dizziness, nystagmus Peripheral edema Myalgias Rarely myoclonus	SJS Seizure Coma	
Clobazam	Somnolence or insomnia Hypersalivation Ataxia or dizziness Seizures	Respiratory depression SJS/TEN	CI: Significant hepatic failure Acute narrow-angle glaucoma
Lacosamide	Diplopia Dizziness Headache	Prolonged PR interval AV block Syncope Hypersensitivity reactions Suicidal behavior	CI: Severe hepatic impairment or cardiac disease AV block

Of note, this table does not include several newer AEDs

with either CT or MRI should be considered in *adults presenting with apparent unprovoked first seizure (Level B)*. Acute CT head is indicated in *epilepsy patients* if the presenting seizure (1) has a different semiology than their typical seizures, (2) is prolonged (longer than 5 min), and (3) is followed by an unusually prolonged postictal period or for new findings on neurological exam [32].

A follow-up MRI brain should be performed for suspected but incompletely characterized lesions on CT, cases of focal onset or focal exam findings and negative CT, or for epilepsy patients presenting with a new seizure semiology and negative CT head. For medically stable patients who are at their baseline, MRI brain may be performed instead of a CT head (if an MRI can be performed in a timely fashion prior to discharge from the ED). Immunocompromised patients who present with seizure should undergo MRI brain to evaluate for opportunistic infections, such as toxoplasmosis, cytomegalovirus (CMV), tuberculosis, *Cryptococcus*, or progressive multifocal leukoencephalopathy (PML), or for primary CNS lymphoma.

Lumbar puncture: lumbar puncture (LP) is a helpful test to evaluate for SAH, inflammatory processes, or CNS infections, which can present in an atypical fashion in neonates, the elderly, or those who are immunocompromised. The AAN guidelines state there is insufficient evidence to recommend or refute routine LP in patients presenting with first seizure but that it may be helpful in specific clinical circumstances, such as fever. ACEP guidelines point to the lack of evidence

supporting LP in patients who are alert, oriented, afebrile, and not immunocompromised but do recommend (**Level B**) LP (after CT head) in patients with immunocompromised and first-time seizure, even if they are afebrile. LP often causes leptomeningeal signal change on MRI, and so if emergent MRI is planned, consider delaying LP until after MRI.

EEG

The AAN recommends routine EEG in *adults with apparent unprovoked first seizure* for both diagnostic and prognostic yield (**Level B**): the timing of this is not specified in the practice parameters, though there is evidence in children to suggest that EEG within 24 h of presenting seizure gives higher yield of significant abnormalities [32, 35]. Tracing of varying types of seizures is shown in Fig. 4.1. The guidelines reviewed 11 articles that assessed the yield of routine EEG and found that EEGs were read as abnormal in 12–73% (average 51%) due to epileptiform activity (sharp or spike waves). It should be noted that a normal EEG does *not* exclude seizure or epilepsy, so a single routine EEG is part of the diagnostic workup but must be interpreted in the clinical context of the patient. EEG also has prognostic value. Meta-analysis of data on 1799 patients is included in the AAN guidelines, and an estimated posttest probability of seizure recurrence was 49.5% in patients with epileptiform EEG abnormalities, compared to 27.4% for those with a normal EEG. There was no increased risk of seizure recurrence with nonspecific abnormalities commonly seen on EEG, such as focal or diffuse slowing. The ACEP guidelines provide a **Level C** recommendation for *emergent EEG in patients suspected of being in nonconvulsive SE or subtle convulsive SE, who have received a long-acting paralytic or are in a drug-induced coma* [30]. This recommendation is based on the utility of EEG in assessing for acute confusional state/delirium, behavioral changes, or encephalopathy due to ongoing seizures, as well as the increased mortality associated with duration of and delay in diagnosis of nonconvulsive SE. These guidelines should be interpreted in the clinical context of each patient and with the understanding that EEG is only a component of the evaluation of patients with persistent altered mental status.

First-Time Seizure

The AAN/AES issued guidelines on evaluation of unprovoked first seizure in adults in 2007 and management of unprovoked first seizure in adults in 2015 [32, 33]. For patients presenting with an apparent unprovoked first seizure, the goals of evaluation are to determine how likely it is that the event was a seizure and the cause (if any). The conclusion and recommendations are to consider routine EEG for diagnostic and prognostic purposes (**Level B**) and to consider brain imaging with CT or MRI (**Level B**). Decisions about laboratory studies (electrolytes, CBC, LP, toxicology studies) should be driven by each individual case, as there are insufficient data

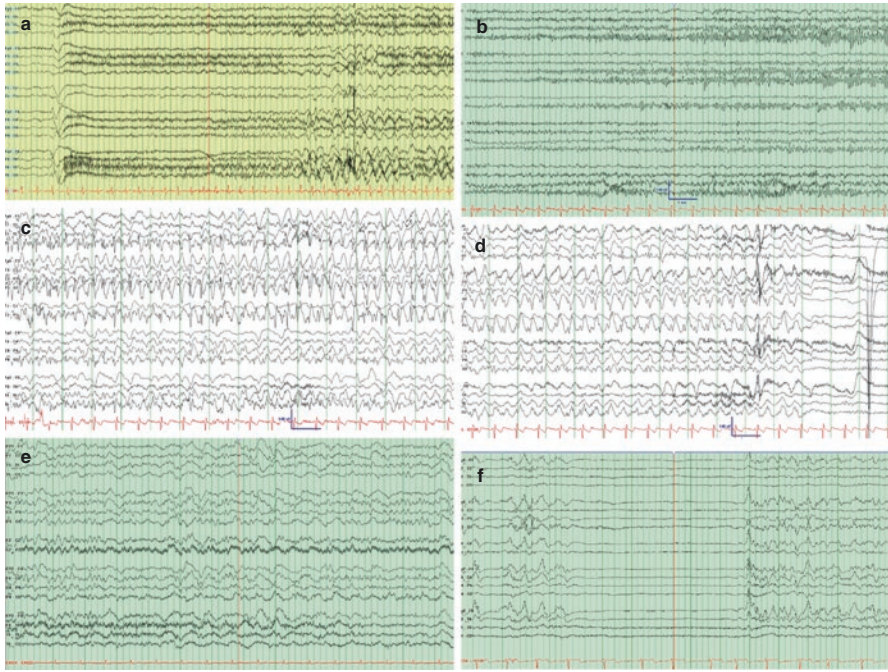


Fig. 4.1 A sample of EEG records. (a) Seizure with generalized onset that is initially best seen over the left hemisphere before switching to the right hemisphere. The single-lead EKG (tracing in red at the bottom) shows rapid transition over a few seconds of seizure onset from a normal sinus rhythm to tachycardia at 150 bpm. (b) Focal seizure onset best seen in leads over the left occipital lobe with evolution over the course of this clip. (c) Ongoing seizure most prominent in the left parasagittal leads with evolution to involve the entire left hemisphere by the end of the clip. (d) At a later point, the seizure shows evolution to slower rhythmic discharges that are more obvious in the left hemisphere but with synchronous slow discharges on the right. At the right-hand side of this clip, the seizure abruptly ends with postictal suppression. (e) This patient presented with confusion and hypertension and was diagnosed with hypertensive encephalopathy. The record shows bursts of irregularly shaped delta slowing on an abnormally slow background and is consistent with an encephalopathic patient. (f) Burst suppression: this record from a patient in the ICU shows brief bursts with several seconds of suppression

to support or refute their routine use (**Level U**). The guidelines support careful history, physical and neurological exam for their diagnostic and prognostic value, and potential impact on treatment decisions.

EEG is helpful for treatment and prognosis. For adults with unprovoked first seizure, the greatest risk of recurrence is within the first 2 years (21–45%) but particularly the first year, with increased risk associated with prior brain lesion or insult causing the seizure (**Level A**), an EEG with epileptiform abnormalities (spike or sharp waves) (**Level A**), significant abnormality on brain imaging (**Level B**), or nocturnal seizure (**Level B**) [33]. The risk of recurrence is likely reduced in the first 2 years in those treated with an AED, but treatment is unlikely to improve chance of sustained remission over the longer term (beyond 3 years). Thus, the decision about

whether to start an AED must be made in the context of the history, data such as imaging and EEG, clinical suspicion, the patient’s social circumstances, and availability of outpatient neurology follow-up.

Pharmacological Management of Status

SE management depends on dual supportive treatment and pharmacological treatment aimed at ending seizure activity. The Neurocritical Care Society (NCS) 2012 guidelines for evaluation and management of status epilepticus includes data on SE patient outcomes and outlines a treatment protocol that includes supportive care and pharmacologic steps [8]. The AES issued updated guidelines in 2016 for treatment of convulsive status epilepticus [7]. Figure 4.2 provides a schematic representation of the treatment discussed in the NCS and AES guidelines but schematically represented as the three treatment phases presented in the NCS guidelines: “emergent initial therapy,” “urgent control therapy,” and “refractory therapy.” The NCS and AES guidelines employ the revised operational definitions of status (SE) and refractory status epilepticus (RSE) (see below).

Revised operational definition of SE: seizure lasting longer than 5 min or two or more seizures without return to baseline.

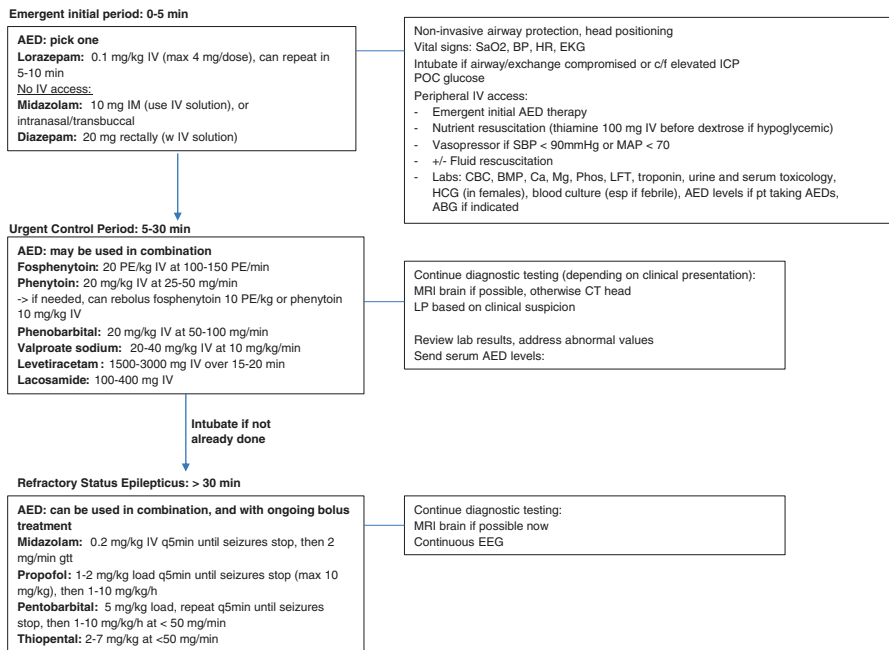


Fig. 4.2 Schematic for evaluation and management of SE. Suggested management strategy for patients presenting with SE (adapted from [7, 8, 25])

Revised operational definition of refractory SE (RSE): ongoing clinical or electrographic seizures despite adequate initial benzodiazepine doses followed by a second acceptable AED.

Pharmacological Treatment of SE

The below recommendations, tables, and graphic are adapted from the NCS 2012 and AES 2016 guidelines [7, 8]. Trial data to determine the optimal doses are lacking and prospective studies limited by ethical concerns, so recommendations are based on observational data and expert opinion (please see guidelines cited above and references therein, including [36, 37]) (Table 4.5).

Emergent Initial Therapy

Both evidence and expert opinion support **benzodiazepines** as first-line agents for emergent initial therapy. **Lorazepam IV** or **diazepam IV** are preferred, but if there is no IV access, **IM midazolam** is equivalent as a first-line agent. The Rapid Anticonvulsant Medication Prior to Arrival Trial (RAMPART) sets out to investigate whether results of prehospital treatment with IM midazolam would be non-inferior to IV lorazepam, as determined by proportion of patients with termination of clinically evident seizure on arrival to the ER after a single dose of study medication and without the use of rescue medication; the study showed that IM midazolam

Table 4.5 Pharmacologic options by phase of treatment based on NCS and AES guidelines for SE [7, 8]

NCS guidelines phases of therapy	AED options by phase	2016 AES guideline phases of therapy	AED options by phase
Emergent initial	Lorazepam IV Midazolam IM Diazepam IV or PR	Initial therapy phase, 5–10 min after presentation	Lorazepam IV Midazolam IM Diazepam IV (Phenobarbital IV ^a , Diazepam PR ^a , midazolam nasal ^a)
Urgent control	Phenytoin/fosphenytoin IV Phenobarbital IV Valproate sodium IV Levetiracetam IV Midazolam gtt	Second therapy phase, 20–40 min after presentation	Fosphenytoin IV Valproic acid IV Levetiracetam IV (phenobarbital IV ^a)
Status epilepticus	Midazolam IV and gtt Propofol IV and gtt Pentobarbital IV	Third therapy phase, 40–60 min after presentation	Repeat dose of second-line therapy or anesthetic dose of: Thiopental, midazolam, pentobarbital, or propofol

^aIndicates alternatives if preferred agents are not available

was superior to IV lorazepam for prehospital treatment of SE by paramedics [38, 39]. The 2016 AES guidelines found that IV PHB, IV lorazepam, IV diazepam, or IM midazolam is efficacious in seizures lasting at least 5 min but that IV lorazepam is more effective than IV PHB in seizures lasting at least 10 min. There was no difference in efficacy between IV lorazepam followed by IV phenytoin, IV diazepam with phenytoin followed by IV lorazepam, and IV PHB followed by IV phenytoin. The NCS recommends that, if the abovementioned benzodiazepines are not available, additional initial therapy options are **diazepam PR**, **midazolam intranasal**, **midazolam buccal**, or **phenobarbital (PHB) IV**. Benzodiazepines and PHB carry the risk of respiratory depression and/or hypotension, and patients must be adequately monitored.

Urgent Control Therapy

Urgent control therapy is required in SE following benzodiazepine administration, with the exception of cases where the immediate cause of SE is identified and corrected with resolution of seizures, e.g., hypoglycemia. The **goals of urgent control therapy** are (1) rapidly to attain and maintain therapeutic AED levels and (2) to stop SE in cases of failed emergent initial therapy. This phase is typically 5–10 min (NCS guidelines) or 20–40 min (second therapy phase in AES 2016 guidelines) after initial presentation.

Urgent control therapies are those available in IV formulations and include **IV phenytoin/fosphenytoin**, **phenobarbital**, **valproate sodium**, **levetiracetam**, or continuous **midazolam infusion**. The AES 2016 guidelines suggest a single dose of one of the following: valproic acid IV (Level B), fosphenytoin (Level U), or levetiracetam IV (Level U) but if none of those are available, phenobarbital IV (Level B). If seizures continue at this point (40–60 min after presentation), the AES guidelines cite insufficient evidence to guide therapy, but choices (Level U) include repeating second-line therapy or anesthetic doses of thiopental, midazolam, pentobarbital, or propofol, all in conjunction with starting continuous EEG monitoring. The ACEP guidelines include IV administration of phenytoin, fosphenytoin, or valproate (all Level B) or levetiracetam, barbiturates, or propofol (all Level C) for SE patients following benzodiazepine and up to 30 mg/kg phenytoin.

Although levetiracetam is FDA indicated for use as an adjunctive therapy, but not for monotherapy in partial seizures or primary generalized epilepsy, it finds frequent and first-line use, often as monotherapy, in emergent or urgent situations because of its low risk of drug-drug interactions, low adverse effect profile, and availability in IV formulation. **Lacosamide** is not included in the AAN, AES, or ACEP guidelines and is reserved for refractory phase in the NCS guidelines; in practice, however, it may find frequent use as second- or third-line therapy due to its relatively safe profile, minimal effect on mental status, and availability for IV administration, and some data show that its 1-h seizure remission efficacy is comparable to valproic acid and that the two have comparable safety [40]. Epilepsy patients presenting with seizure or SE should receive an IV bolus of their home AED (if available IV) before

administering an additional agent. Serum AED levels should be monitored in all patients and additional boluses administered to maintain levels near the high end of the therapeutic range.

Treatment of refractory SE (RSE): **RSE** is a potential complication for all patients presenting in SE, but it can be difficult to detect clinically and to treat. Patients with RSE due to significant toxic or metabolic derangements or anoxia were least likely to achieve control, as compared to those with RSE due to chronic epilepsy, infection, stroke, tumor, or trauma in one series of RSE cases treated with pentobarbital [41]. The NCS guidelines recommend immediately starting an additional agent if there is evidence or concern for ongoing seizure activity after benzodiazepine and one AED, as there is no evidence to support a period of watchful waiting. Consulting with neurology and working to obtain EEG monitoring should be part of patient care at this stage.

Treatment may involve intermittent bolus therapy with an additional AED from what the NCS guidelines term the “urgent control list,” particularly in hemodynamically stable patients who are not intubated. Treatment of patients already intubated may be escalated to continuous infusion of AEDs, and treatment efficacy should be monitored using continuous EEG (cEEG). AEDs most commonly utilized for continuous infusion include **midazolam**, **propofol**, and **pentobarbital** (thiopental in some countries), which require intensive care and monitoring. Pentobarbital was most effective in stopping seizure activity but carries higher risk of hypotension and increased length of stay. No mortality difference was found in patients treated with each of these agents [42]. The duration of therapy is not standardized and depends on EEG findings. If cEEG shows ongoing electrographic seizures, the AED regimen is titrated to “burst suppression,” typically for 24–48 h, followed by attempts to lighten sedation with cEEG to monitor for recurrence [8]. The 2012 NCS and 2016 AES guidelines recommend initiating EEG monitoring within 1 h if there is suspicion for ongoing seizures; if cEEG is not available, strongly consider transfer to a facility with the recommended resources and expertise.

Partial status epilepticus (focal seizure with dyscognitive features) and **focal motor status** (aka *epilepsia partialis continua*, which usually has minimal or no dyscognitive features) present with varying degrees of altered awareness. The clinical presentation is less dramatic than for GTC SE and may be mistaken for a psychiatric condition. These entities can be difficult to treat and will likely require involvement of a neurologist. In hemodynamically stable, alert patients with focal status, the risks and benefits of aggressive therapeutic intervention should be carefully weighed (Table 4.6).

Endotracheal Intubation (ETI)

Respiratory failure is an important potential complication of SE due to ongoing seizures or pharmacological intervention, as many antiepileptics can cause sedation [43, 44]. Endotracheal intubation (ETI) is appropriate for patients unable to maintain their airway but is not without risks. The evidence-based guidelines for

Table 4.6 NCS and AES guidelines: intermittent drug dosing in status epilepticus (adapted from Tables 6 and 7 in NCS 2012 and Table 2 in AES 2016 guidelines [7, 8])

Drug	Initial dosing	Administration rates and alternative dosing recommendations	Serious adverse effects	Considerations
Diazepam AES Level A NCS Level A	0.15–0.2 mg/kg IV up to 10 mg per dose, may repeat in 5 min	Up to 5 mg/min (IVP)	Hypotension Respiratory depression	Rapid redistribution (short duration), active metabolite, IV contains propylene glycol
Lorazepam AES Level A NCS Level A	0.1 mg/kg IV up to 4 mg per dose, may repeat in 5–10 min	Up to 2 mg/min (IVP)	Hypotension Respiratory depression	Dilute 1:1 with saline IV contains propylene glycol
Midazolam AES Level A NCS Level A	NCS: 0.2 mg/kg IM to max 10 mg AES: 10 mg for >40 kg, 5 mg for 13–40 kg		Respiratory depression Hypotension	Active metabolite, renal elimination, rapid redistribution (short duration)
Fosphenytoin AES Level U NCS Level B	20 mg PE/kg IV AES: max 1500 mg PE/dose NCS: can give further 5 mg/kg	Up to 150 mg PE/min; may give additional dose 10 min after loading infusion	Hypotension Arrhythmias	Compatible in saline, dextrose, and lactated ringers solution
Lacosamide NCS Level C in RSE Not in AES 2016	200–400 mg IV	200 mg IV over 15 min	PR prolongation Hypotension	Minimal drug interactions Limited experience in treatment of SE
Levetiracetam AES Level U NCS Level C	AES: 60 mg/kg IV, max 4500 mg single dose NCS: 1000–3000 mg IV	2–5 mg/kg/min IV		Minimal drug interactions Not hepatically metabolized
Phenobarbital AES Level A NCS Level A	AES: 15 mg/kg max dose NCS: 20 mg/kg IV, may give an additional 5–10 mg/kg	50–100 mg/min IV, may give additional dose 10 min after loading infusion	Hypotension Respiratory depression	IV contains propylene glycol

(continued)

Table 4.6 (continued)

Drug	Initial dosing	Administration rates and alternative dosing recommendations	Serious adverse effects	Considerations
Phenytoin NCS Level C AES Level B	NCS: 20 mg/kg IV, may give an additional 5–10 mg/kg	Up to 50 mg/min IV; may give additional dose 10 min after loading infusion	Arrhythmias Hypotension Purple glove syndrome	Only compatible in saline IV contains propylene glycol
Propofol NCS Level B	NCS: 1–2 mg/kg IV load dose, then 20 mcg/kg/min infusion	Maintenance: 30–200 mcg/kg/min	Hypotension respiratory depression Cardiac failure rhabdomyolysis, metabolic acidosis Renal failure	Half-life changes with treatment duration Hypotension risk with loading dose higher in critically ill patients
Topiramate NCS Level C for RSE	200–400 mg NG/PO	300–1600 mg/day orally (divided 2–4 times daily)	Metabolic acidosis	Not available IV
Valproate AES Level B NCS Level A	AES: 40 mg/kg to max 3000 mg single dose NCS: 20–40 mg/kg IV, may give an additional 20 mg/kg	3–6 mg/kg/min, may give additional dose 10 min after loading infusion	Hyperammonemia Pancreatitis Thrombocytopenia Hepatotoxicity	Use with caution in patients with traumatic head injury; may be a preferred agent in patients with glioblastoma multiforme

airway management and ETI in cases of SE are limited. Secondary analysis of the Rapid Anticonvulsant Medication Prior to Arrival Trial (RAMPART) data was performed with the primary outcome of ETI for respiratory depression and depressed mental status (with or without persistent convulsions) and secondary outcomes of ETI timing, mortality, and length of hospital stay [28]. For the 893 subjects included (adults and children with a weight of 13 kg or above who received benzodiazepines in the prehospital setting for SE), ETI frequency was 21% overall. Intubation as compared to non-intubation and late intubation versus early intubation were found to be markers for higher rates of mortality and more severe pathology. This is thought to be related to later intubation occurring in patients with comorbidities that were not initially evident and that early intubation may have protected some patients at high risk of experiencing complications of an unprotected airway. ETI occurred more often in patients older than 50 years, men, those presenting without a known seizure disorder, and SE due to toxic or metabolic etiologies, CNS tumor, or stroke, while lower intubation rates were documented in patients presenting in SE with prior seizure history, anticonvulsant withdrawal, or non-compliance as SE etiology. Of note, 93.6% of the 218

intubations were performed in the hospital, and 42% of intubated patients were intubated for less than 24 h and 11% for fewer than 12 h. The study does not provide guidelines for ETI in SE patients but does suggest that “more selective and appropriately timed” ETI may be warranted.

Disposition: Suggestions for when to admit, observe, or discharge a patient with seizure

Admit	Observation unit (if available, otherwise consider admission)	Discharge
Intubated, hemodynamically unstable -> neuro-ICU if available	Known seizure disorder Patient with persistent focal deficits, normal labs, and imaging	First-time seizure patients after workup complete and unrevealing
SE at presentation		Known epilepsy with provoking factor identified and addressed, patient returned to baseline
New-onset seizures, provoking factor identified		Known epilepsy with seizures due to nonadherence, treated and patient at baseline
New-onset seizure with abnormal imaging		
Focal status		
Recent neurosurgical procedure with new seizure or increased frequency		

Safety Counseling for Seizure Patients

Prior to discharge home, patients who presented with seizure and their family members must be advised of the following:

Driving laws and restrictions in their state for patients who have experienced a seizure: State-by-state driving regulations are available at the state Department of Motor Vehicle website or the Epilepsy Foundation website: www.epilepsyfoundation.org/resources/drivingandtravel.cfm

Avoid unsupervised participation in activities that may result in injury or death to the patient or others if the patient were to experience a seizure while participating in that activity.

Examples include (but are not limited to):

- Driving
- Swimming, bathing in a tub
- Climbing on ladders, scaffolds, etc.

Lifestyle modifications to minimize exposure to seizure triggers. Triggers include systemic illness, sleep deprivation, excess alcohol consumption, recreational drug use, medication nonadherence, and excess stress

Family members should be educated on appropriate safety measures in the event of a seizure, such as turning the patient on their side and cushioning the head and body, but **avoid** forcibly restraining the patient or placing anything in the mouth

<http://www.epilepsyfoundation.org/aboutepilepsy/firstaid/index.cfm>

Follow-Up

- Patient’s neurologist/epileptologist if known seizure disorder
 - Neurologist/epileptologist for patients with first-time seizure disorder and initial evaluation completed or in process
-

Referrals

- Consider referral to therapist or psychiatrist for patients diagnosed with epilepsy to provide assistance with adjusting to their new diagnosis and also because mood disorders are a common comorbidity of epilepsy
 - Referral to therapist or psychiatrist for patients with high suspicion of PNES
 - Consider social work referral for patients with epilepsy and unstable psychosocial situation (employment or housing difficulties, etc.)
 - Epileptologist for patients with recurrent seizures or if unclear if patient has seizure disorder or PNES
-

Pearls and Pitfalls

- If loss of consciousness occurred, then the patient had a generalized seizure.
 - Focal seizures are classified based on the presence or absence of dyscognitive features (previously termed simple partial and complex partial seizures)
 - Status epilepticus (SE) is a seizure lasting more than 5 min (revised from the old 30 min definition) or two or more seizures without return to baseline in between.
 - SE is an emergency where every minute of delay to treatment can result in hypoxia, hypotension, acidosis, hyperthermia, rhabdomyolysis, and neuronal injury. First-line treatment is with a benzodiazepine.
 - Refractory SE (RSE) is a serious potential complication for all patients with SE and is operationally defined as ongoing clinical or electrographic seizures despite adequate initial benzodiazepine doses followed by a second acceptable AED.
-

References

1. Hauser WA, Annegers JF, Rocca WA. Descriptive epidemiology of epilepsy: contributions of population-based studies from Rochester. *Minnesota Mayo Clin Proc.* 1996;71(6):576–86.
2. Pallin DJ, Goldstein JN, Moussally JS, Pelletier AJ, Green AR, Camargo CA Jr. Seizure visits in US emergency departments: epidemiology and potential disparities in care. *Int J Emerg Med.* 2008;1(2):97–105.
3. Berg AT, Berkovic SF, Brodie MG, Buchhalter J, Cross JH, van Emde BW, Engel J, French J, Glauser TA, Mathern GW, Moshe SL, Nordli D, Plouin P, Scheffer IE. Revised terminology and concepts for organization of seizures and epilepsies: report of the ILAE Commission on Classification and Terminology, 2005–2009. *Epilepsia.* 2010;51(4):676–85.

4. Tufenkijian K, Lüders HO. Seizure semiology: its value and limitations in localizing the epileptogenic zone. *J Clin Neurol*. 2012;8(4):243–50.
5. Foldvary-Schaefer N, Unnwongse K. Localizing and lateralizing features of auras and seizures. *Epilepsy Behav*. 2011;20(2):160–6.
6. Loddenkemper T, Kotagal P. Lateralizing signs during seizures in focal epilepsy. *Epilepsy Behav*. 2005;7(1):1–17.
7. Glauser T, Shinnar S, Gloss D, Alldredge B, Arya R, Bainbridge J, Bare M, Bleck T, Dodson WE, Garrity L, Jagoda A, Lowenstein D, Pellock J, Riviello J, Sloan E, Traiman DM. Evidence-based guideline: treatment of convulsive status epilepticus in children and adults: report of the guideline committee of the American Epilepsy Society. *Epilepsy Curr*. 2016;16(1):48–61.
8. Brophy MG, Bell R, Claassen J, Alldredge B, Bleck TP, Glauser T, SM LR, Riviello JJ Jr, Shutter L, Sperling MR, Treiman DM, Vespa PM, Neurocritical Care Society Status Epilepticus Guideline Writing Committee. Guidelines for the evaluation and management of status epilepticus. *Neurocrit Care*. 2012;17:3–23.
9. St. Louis EK, Cascino GD. Diagnosis of epilepsy and related episodic disorders. *Continuum*. 2016;22(1):15–37.
10. Nowacki TA, Jirsch JD. Evaluation of the first seizure patient: key points in the history and physical examination. *Seizure*. 2017;49:54–63.
11. Webb J, Long B, Koyfman A. An emergency medicine-focused review of seizure mimics. *J Emerg Med*. 2017;52(5):645–53.
12. Jacobs CS, Milligan T. Seizures. In: McKean S, Ross J, Dressler DD, Scheurer D, editors. *Principles and practice of hospital medicine*. 2nd ed. New York: McGraw-Hill Education; 2016.
13. Lempert T. Recognizing syncope: pitfalls and surprises. *J R Soc Med*. 1996;89(7):372–5.
14. van Dijk JG, Thijs RD, van Zwet E, Tannemaat MR, van Niekerk J, Benditt DG, Wieling W. The semiology of tilt-induced reflex syncope in relation to electroencephalographic changes. *Brain*. 2014;137(2):576–85.
15. Avbersek A, Sisodiya S. Does the primary literature provide support for clinical signs used to distinguish psychogenic nonepileptic seizures from epileptic seizures? *J Neurol Neurosurg Psychiatry*. 2010, Jul;81(7):719–25.
16. Asadi-Pooya AA. Psychogenic nonepileptic seizures are predominantly seen in women: potential neurobiological reasons. *Neuro Sci*. 2016;37(6):851–5.
17. Perez DL, Dworetzky BA, Dickerson BC, Leung L, Cohn R, Baslet G, Silbersweig DA. An integrative neurocircuit perspective on psychogenic non-epileptic seizures and functional movement disorders: neural functional unawareness. *Clin EEG Neurosci*. 2015;46(1):4–15.
18. Reuber M, Brown RJ. Understanding psychogenic nonepileptic seizures—phenomenology, semiology and the integrative cognitive model. *Seizure*. 2017;44:199–205.
19. Duncan R. Psychogenic nonepileptic seizures: EEG and investigation. *Handb Clin Neurol*. 2016;139:305–11.
20. Arena JE, Rabinstein AA. Transient global amnesia. *Mayo Clin Proc*. 2015;90(2):264–72.
21. Goadsby PJ, Holland PR, Martins-Oliveira M, Hoffmann J, Schankin C, Akerman S. Pathophysiology of migraine: a disorder of sensory processing. *Physiol Rev*. 2017;97(2):553–622.
22. Greenberg SM, Vonsattel JP, Stakes JW, Gruber M, Finklestein SP. The clinical spectrum of cerebral amyloid angiopathy: presentations without lobar hemorrhage. *Neurology*. 1993;43(1):2073–9.
23. Shah NH, Adams D. Episodic aphasia associated with cortical spreading depression after subdural hemorrhage evacuation. *Neurohospitalist*. 2016;6(1):NP1–4.
24. Spatola M, Dalmau J. Seizures and risk of epilepsy in autoimmune and other inflammatory encephalitis. *Curr Opin Neurol*. 2017. doi: [10.1097/WCO.0000000000000449](https://doi.org/10.1097/WCO.0000000000000449).
25. Lam AD, Zepeda R, Westover MB, Shafi MM. Seizures, epilepsy and EEG. In: Westover MB, Choi DeCroos E, Awad K, Bianchi MT, editors. *Pocket neurology*. 2nd ed. Philadelphia: Lippincott Williams & Wilkins; 2016.

26. Sevcencu C, Struijk JJ. Autonomic alterations and cardiac changes in epilepsy. *Epilepsia*. 2010;51(5):725–37.
27. Tényi D, Gyimesi C, Kupó P, Horváth R, Bóné B, Barsi P, Kovács N, Simor T, Siegler Z, Környei L, Fogarasi A, Janszky J. Ictal asystole: a systematic review. *Epilepsia*. 2016. doi:[10.1111/epi.13644](https://doi.org/10.1111/epi.13644), epub ahead of print.
28. Vohra TT, Miller JB, Nicholas KS, Varelas PN, Harsh DM, Durkalski V, Silbergleit R, Wang HE, Neurological Emergencies Treatment Trials (NETT) Investigators. Endotracheal intubation in patients treated for prehospital status epilepticus. *Neurocrit Care*. 2015;23(1):33–43.
29. Billington M, Kandalaf OR, Aisiku IP. Adult status epilepticus: a review of the prehospital and emergency department management. *J Clin Med*. 2016;5(9):74–92.
30. ACEP Clinical Policies Committee, Clinical Policies Subcommittee on Seizures. Clinical policy: critical issues in the evaluation and management of adult patients presenting to the emergency department with seizures. *Ann Emerg Med*. 2004;43(5):605–25.
31. Huff JS, Melnick ER, Tomaszewski CA, Thiessen MEW, Jagoda AS, Fesmire FM. Clinical policy: critical issues in the evaluation and management of adult patients presenting to the emergency department with seizures. *Ann Emerg Med*. 2014;63(4):437–46.
32. Krumholz A, Wiebe S, Gronseth G, Shinnar S, Levisohn P, Ting T, Hopp J, Shafer P, Morris H, Seiden L, Barkley G, French J. Practice parameter: evaluating an apparent unprovoked first seizure in adults (an evidence-based review): report of the quality standards subcommittee of the American Academy of Neurology and the American Epilepsy Society. *Neurology*. 2007;69:1996–2007.
33. Krumholz A, Wiebe S, Gronseth GS, Gloss DS, Sanchez AM, Kabir AA, Liferidge AT, Martello JP, Kanner AM, Shinnar S, Hopp JL, French JA. Evidence-based guideline: management of an unprovoked first seizure in adults: report of the guideline development subcommittee of the American Academy of Neurology and the American Epilepsy Society. *Neurology*. 2015;84:1705–13.
34. Abou-Khalil B. Antiepileptic drugs. *Continuum*. 2016;22(1):132–56.
35. Hirtz D, Ashwal S, Berg A, Bettis D, Camfield C, Camfield P, Crumrine P, Elterman R, Schneider S, Shinnar S. Practice parameter: evaluating a first nonfebrile seizure in children: report of the quality standards subcommittee of the American Academy of Neurology, the Child Neurology Society, and the American Epilepsy Society. *Neurology*. 2000;55(5):616–23.
36. Meierkord H, Boon P, Engelsen B, Göcke K, Shorvon S, Tinuper P, Holtkamp M, European Federation of Neurological Societies. EFNS guideline on the management of status epilepticus in adults. *Eur J Neurol*. 2010;17(3):348–55.
37. Shorvon S, Ferlisi M. The treatment of super-refractory status epilepticus: a critical review of available therapies and a clinical treatment protocol. *Brain*. 2011;134(Pt 10):2802–18.
38. Silbergleit R, Durkalski V, Lowenstein D, Conwit R, Pancioli A, Palesch Y, Barsan W, NETT Investigators. Intramuscular versus intravenous therapy for prehospital status epilepticus. *N Engl J Med*. 2012;366(7):591–600.
39. Silbergleit R, Lowenstein D, Durkalski V, Conwit R, NETT Investigators, et al. *Epilepsia*. 2013;54(6):74–7.
40. Misra UK, Dubey D, Kalita J. A randomized controlled trial of lacosamide versus sodium valproate in status epilepticus. *Epilepsia*. 2017. doi:[10.1111/epi.13706](https://doi.org/10.1111/epi.13706).
41. Krishnamurthy KB, Drislane FW. Relapse and survival after barbiturate anesthetic treatment of refractory status epilepticus. *Epilepsia*. 1996;37(9):863–7.
42. Claassen J, Hirsch LJ, Emerson RG, Mayer SA. Treatment of refractory status epilepticus with pentobarbital, propofol or midazolam: a systematic review. *Epilepsia*. 2002;43(2):146–53.
43. Roppolo LP, Walters K. Airway management in neurological emergencies. *Neurocrit Care*. 2004;1(4):403–14.
44. Michael GE, O'Connor RE. The diagnosis and management of seizures and status epilepticus in the prehospital setting. *Emerg Med Clin North Am*. 2011;29(1):29–39.

Syncope: Who Needs Imaging? Who Needs Admission?

5

Ellen Vollmers and Sean Kivlehan

Abbreviations

AMI	Acute myocardial infarction
BNP	Brain natriuretic peptide
CAD	Coronary artery disease
CBC	Complete blood count
CHF	Congestive heart failure
CNS	Central nervous system
CT	Computerized tomography
DBP	Diastolic blood pressure
ECG	Electrocardiogram
ED	Emergency department
EEG	Electroencephalogram
EMS	Emergency medical services
GI	Gastrointestinal
Hct	Hematocrit
Hgb	Hemoglobin
IV	Intravenous
LOC	Loss of consciousness
OESIL	Osservatorio Epidemiologico sulla Sincope nel Lazio risk score
PE	Pulmonary embolism
RA	Room air

E. Vollmers, M.D., Ph.D.

Harvard Affiliated Emergency Medicine Residency, Boston, MA, USA
e-mail: EVollmers@partners.org

S. Kivlehan, M.D., M.P.H. (✉)

Department of Emergency Medicine, Brigham and Women's Hospital,
Harvard Medical School, Boston, MA, USA
e-mail: SMKivlehan@bwh.harvard.edu

ROSE	Risk stratification of Syncope in the ED
SBP	Systolic blood pressure
SFSR	San Francisco Syncope Rule
TCA	Tricyclic antidepressants
TIA	Transient ischemic attack
VS	Vital signs
WPW	Wolff-Parkinson-White

Case Presentation

A 60-year-old man presents to the emergency department (ED) by EMS with a report of sudden collapse while running a road race. It is a hot summer day, and he was at mile 5 of a 10 K race when he suddenly collapsed. He was helped up by bystanders after a report of roughly 1 min of unconsciousness. He has scrapes on his knees and elbows from the fall to pavement but is only complaining of fatigue. He is awake and alert, with mild tachycardia, a normal blood pressure, and a normal neurological exam. His respiratory rate is normal and he is afebrile. His skin is pale and warm, with some mild sweat. He reports that he has a history of hypertension and non-insulin-dependent diabetes. He takes metformin for the latter, but cannot recall his antihypertensive medication name. EMS has started a peripheral IV en route and given him 500 cm³ of normal saline. They report that a 12 lead ECG showed sinus tachycardia without any features concerning for arrhythmia or ischemia.

Introduction

Syncope is a common occurrence that can be the result of diverse conditions, many benign but others life-threatening. It accounts for 1–3% of ED visits, up to a third of which may result in hospital admission [1]. Being by definition a transient loss of consciousness, syncope poses the diagnostic challenge of the patient/doctor interaction occurring after resolution of symptoms. A detailed history and focused physical exam can alone uncover the cause around 50% of the time, while the addition of extensive inpatient testing will still leave 29% without a definitive discharge diagnosis [2]. The role of the provider is to identify those patients at risk for life-threatening causes of syncope and let the clinical picture guide diagnostic testing, all while avoiding over-testing and unnecessary admissions. Controversy exists regarding the usefulness of various screening tests and the extent to which the asymptomatic patient should be worked up in the ED as this can be a major driver healthcare costs, as much as \$2.6 billion annually by one estimate [3]. This chapter will discuss the differential for the patient with syncope, key history and physical exam findings, investigative options, and disposition planning within the context of the ED.

Differential Diagnosis

Broadly, the causes of syncope can be divided into four categories: neurocardiogenic mediated, cardiac, orthostatic, and neurogenic [4]. A fifth category contains the common syncope imitators of seizure and metabolic disorders.

- Neurocardiogenic mediated:
 - Carotid sinus syndrome
 - Situational
 - Vasovagal

Neurocardiogenic-mediated cases of syncope are the most common and are largely self-limiting [5]. These patients will frequently present asymptomatic and often lack any objective exam findings. While this can make diagnostics difficult, a good history can support these more benign diagnoses. Patients with carotid sinus syndrome may report tight collars or occurrence with neck pressure. In particular, these symptoms are frequently reproducible with a carotid sinus massage. Situational syncope includes peri-micturition and postprandial syncope, both increasingly common in the older population. Additionally, severe coughing bouts can lead to syncope secondary to vagal stimulation as can strong physiological responses to fear-inducing stimuli, such as an IV stick or blood. These causes are frequently classified as “vasovagal.”

- Cardiac:
 - Arrhythmia:
 - Bradycardia and heart blocks
 - Ventricular tachycardia
 - Atrial tachyarrhythmias
 - Pacemaker malfunction
 - Long QT syndrome
 - Wolff-Parkinson-White Syndrome (WPW)
 - Brugada syndrome
 - Structural:
 - Obstructive cardiomyopathy
 - Aortic or pulmonic stenosis
 - Pulmonary hypertension
 - Congestive heart failure (CHF)
 - Subclavian steal
 - Acute myocardial infarction (AMI)
 - Pulmonary embolus (PE)
 - Aortic dissection

Evaluation for cardiac causes of syncope is often criticized for its low yield and can drive significant healthcare costs [6]. That said, this category contains several concerning conditions for which syncope may be the presenting symptom. History preceding the syncope is particularly important here, as patients may have experienced dizziness, palpitations, chest pain, or shortness of breath. Both brady- and tachyarrhythmias can lead to syncope, and while an ECG can easily identify these in the moment, they can be transient and temporally correlated to the syncopal event. Other features predisposing to arrhythmia such as Brugada pattern, long QT syndromes, and WPW can generally be identified, as can any significant ischemia suggestive of an AMI. Structural diseases of the heart can be suggested by the presence of murmurs and confirmed with echocardiography. Laboratory testing and radiography can provide evidence for or against other conditions such as CHF, PE, or aortic dissection.

- Orthostatic:
 - Medications
 - Autonomic dysfunction:
 - Primary: Parkinson disease, multiple sclerosis
 - Secondary: Diabetes, spinal cord injury, uremia
 - Hypovolemia:
 - Dehydration
 - Hemorrhage

Orthostatic syncope encompasses situations in which blood supply is inadequate to meet the needs of the body. In some cases this is transient and related to blood vessel tone, such as with autonomic dysfunction, and in others it is related to an absolute volume depletion, such as in cases of hypovolemic shock. It is important to consider occult causes of bleeding, such as gastrointestinal or vaginal as well as overt ones. Polypharmacy is a growing cause of syncope particularly in the elderly.

- Neurogenic or psychiatric:
 - Vertebrobasilar insufficiency
 - Somatization
 - Panic attack
 - Cataplexy
 - Drop attacks

Truly neurologic causes of syncope are uncommon. Strokes and TIAs generally do not cause syncope, but certain vascular diseases such as basilar artery insufficiency may [5]. Psychiatric causes such as somatization and panic attacks can cause syncope; however, these are diagnoses of exclusion and are largely based on history and context.

- Imitators:
 - Seizure
 - Metabolic disorders:

Hypoglycemia
Hypercapnia
Hypocapnia (e.g., from hyperventilation)

Whether a patient who suffered collapse experienced a seizure or syncope is a common diagnostic dilemma. As both conditions will have frequently resolved by presentation in the ED, and the patient generally will not recall the event, bystander history becomes critically important. Although not always available, EMS and family members can provide key information. Seizure patients more commonly have postictal confusion and a report of convulsive movements and present with oral trauma or urinary incontinence. In contrast, syncope patients more commonly have a prodrome of palpitations, diaphoresis, nausea, or vertigo, as well as situational triggers such as needle sticks, a hot environment, or prolonged sitting or standing [7]. Metabolic conditions such as hypoglycemia and hypercarbia can lead to loss of consciousness; however, these will typically not self-correct.

Critical Features of the History

As above, a range of historical features can help narrow the diagnosis. However, a few specific features have been shown to differentiate emergency from non-emergent causes of syncope [4].

Things in the “breakout box” for separating badness from non-badness:

High risk for emergent condition:

- Age over 70
- Personal history of CAD or structural heart disease
- Family history of sudden death
- Exertional syncope
- Palpitations prior to syncope
- Chest pain related to syncope

Low risk for emergent condition:

- Age under 40
- No personal history of cardiac disease
- HPI strongly suggestive of orthostatic or vasovagal etiology:
 - Abrupt change to an upright position or prolonged standing
 - Preceding lightheadedness/flushing
 - History of volume depletion
 - Warm environment
 - Emotional situation
 - Vagal situation: straining, urinating, coughing, laughing

Additional valuable focused history:

- Position:
 - Standing >15 min: Increased concern for vasovagal
 - Moving to standing: Increased concern for orthostasis
 - Sitting/laying: Increased concern for arrhythmia
- Onset: Were there prodromal symptoms?
 - Lack of prodromal symptoms is associated with arrhythmia.
- Associated chest pain? Associated shortness of breath?
 - These symptoms are associated with cardiac or pulmonary etiology.
- Duration: If witnessed, longer LOC (>4 min) more suggestive of seizure.
 - If witnessed, were there tonic/clonic movements, head deviation, and urinary incontinence?
- Situation:
 - Exertional: Increased concern for arrhythmia and structural cardiac etiology.
 - Vagal activity: Straining, urinating, and coughing all suggest vasovagal syncope.
- Injury: Raises concern for primary or concomitant traumatic injury. Does the patient require a trauma workup? Don't forget about the possibility for trauma secondary to syncope.
- Aftermath: Did they rapidly return to baseline mental status, or was there a post-ictal period? Prolonged recovery can raise the concern for seizure.
- Recent medication changes? Changes to antihypertensives, diuretics, rate controlling meds, antipsychotics, TCAs, nitrates.

Critical Features of the Physical Exam

- Vital signs: When the syncopal event was caused by transient hypotension or a cardiac arrhythmia, this vital sign abnormality will often have normalized by the time you evaluate the patient, but any abnormal vital signs must be explained. Persistent tachycardia may suggest hypovolemia as may hypotension. Sinus tachycardia associated with hypoxia may suggest pulmonary embolism:
 - Orthostatic vital signs can be checked (at least 5 min supine followed by 3 min standing):
 - Drop in SBP >20 mmHg or DBP > 10 mmHg
 - Increase in HR >20
 - Presyncopal sensation even without changes in vital signs
 - There are no strong data in the literature to support or refute using orthostatic vital signs as a decision-making tool. At this time they are simply an inexpensive additional data point that can be gathered, while keeping in mind that the absence of documented orthostatic hypotension in the ED should not be used to definitively rule it out as the offending etiology.
- Cardiac: Listen for murmurs of aortic or mitral stenosis. Listen for extra heart sounds (S3, S4) sounds to suggest heart failure. Bedside echocardiography can be useful: if there are signs of decreased ejection fraction, obvious wall motion

abnormalities, ventricular hypertrophy, or other abnormalities that are new, strongly consider further cardiac workup.

- Carotid sinus exam: Sequentially massage the left and right carotid sinus for 10 s each both supine and erect while monitoring heart rate and blood pressure. A drop of more than 50 mmHg in SBP or at least 3 s pause in heartbeat defines carotid sinus hypersensitivity. This test is both highly sensitive and specific for carotid sinus hypersensitivity, particularly when performed in the upright position [8]:
 - Contraindications: Carotid bruit, CVA or MI within 3 months, history of ventricular arrhythmia
- Abdominal: Rectal exam for occult bleeding if signs of anemia or report of dark stools.
- Trauma: Oral trauma suggests seizure. Head trauma may suggest diffuse axonal injury. Always evaluate for trauma secondary to the collapse.
- Urinary or bowel incontinence: Suggests seizure.
- Vascular: Listen for carotid bruits. If syncope occurred in the setting of activity with arms reaching overhead, consider subclavian steal and compare bilateral arm blood pressures. A pressure differential >15 mmHg is highly specific for subclavian steal [9].
- Neurologic: Perform a focused neurologic exam – new neurologic deficits should be explained.

Emergency Department Workup

Every syncopal patient should at minimum have a workup including vital signs, an ECG, and, for females of childbearing age, a urine pregnancy test. For many patients, particularly young, healthy patients who on history describe an episode suggestive of a reactive or orthostatic syncope (prodromal symptoms, prolonged standing, straining, etc.), the emergency department workup may end there. Otherwise healthy patients under the age of 40 are more likely to have experienced a benign cause of syncope (such as reflex and orthostatic), while the elderly population demonstrates an increased incidence of potentially life-threatening causes [10].

In order to risk-stratify patients for high-risk causes of syncope, multiple decision rules are available (Table 5.1).

Of these risk stratification tools, only SFSR and OESIL have been externally studied for validation, and neither held up as well as their initial study in catching all patients at risk for adverse events [13–16]. For the purposes of the ED physician who is deciding between admission and discharge with close follow-up, the SFSR study design may be more appropriate as the outcome was adverse events within 7 days after presentation, versus 3–6 months with OESIL. When comparing the SFSR to gestalt, physicians proved to be as reliable at predicting and admitting patients at risk for adverse events. However, where the SFSR outperformed physician gestalt was in reducing admission rates of low-risk

Table 5.1 Decision rules: evidence-based risk stratification

ROSE [11]	SFSR [12]	OESIL [13]	Boston [14]
BNP >300	CHF	Any cardiac history	Any cardiac history
Bradycardia <50			Abnormal vital signs
Rectal blood positive			
Hgb <9 g/dL	Hct <30%		Volume depletion
Associated chest pain			
ECG with Q waves (excluding lead III)	Abnormal ECG	Abnormal ECG	ECG with abnormal conduction, CAD history
Oxygen saturation <94% on room air	Shortness of breath		Abnormal vital signs
	Any SBP <90 mmHg (including triage)		
		No prodrome	
		Age >65	
			Valvular heart disease Family history of sudden cardiac death CNS etiology
Sn: 87.2% NPV: 98.5%	Sn: 96% NPV: 99.2%	Sn: 98% NPV: 97.8%	Sn: 97% NPV: 99%

ROSE risk stratification of syncope in the ED, *SFSR* San Francisco Syncope Rule, *OESIL* Osservatorio Epidemiologico Sulla Sincope nel Lazio risk score

patients, as physicians admitted 28% of low-risk patients for further workup, whereas utilization of the SFSR in this study would have decreased the admission rate by 10% without missing any patients who went on to have adverse events [17].

A retrospective analysis of patients over 65 with syncope revealed that the sensitivity of the SFSR for predicting adverse events fell from 90 to 76.5% as compared to the original study of all-comers, with a mean age of 62 [12, 18]. Of the decision rules, only OESIL includes an age cutoff as an independent predictor of adverse outcomes. It appears clear that regardless of the risk stratification tool being used, one should maintain a lower threshold to admit an elderly patient following a syncope event.

Clinical Investigations

The use of diagnostic testing should be driven by the history and physical and supported by decision rules when appropriate. Two commonly cited guidelines are the 2009 European Society of Cardiology guidelines and the 2006 American Heart Association/American College of Cardiology Foundation Scientific Statement on the Evaluation of Syncope. Both follow an algorithmic approach based on historical and physical exam findings. Their recommendations for immediate evaluation are summarized in Table 5.2 [19, 20].

Table 5.2 Guidelines

European Society of Cardiology	American Heart Association/American College of Cardiology Foundation
Carotid sinus massage testing in patients <40 years old	ECG
Echocardiogram if history of heart disease or high suspicion for structural cause of syncope	Echocardiogram if syncope unexplained by exam
ECG monitoring	Exercise test and ischemia evaluation if syncope unexplained by exam
Orthostatic testing	

The European Society of Cardiology proposed a conceptual model in 2016 designed specifically toward the evaluation of syncope in the emergency department that relies on characterization of the patient into low-, high-, and intermediate-risk categories:

- Low-risk patients are young (<40) and must have at least one of the following features that strongly supports neurocardiogenic syncope and no high-risk features:
 - Erect position
 - Preceding nausea or warmth
 - Low-risk triggers such as emotional events, micturition, coughing
 - History of similar low-risk events in the past
- High-risk patients must have at least one of the following features:
 - Exertional syncope
 - Preceding chest discomfort or palpitations
 - Syncope while supine
 - History of functional heart disease or ventricular arrhythmias
 - Sudden cardiac death in the family
 - Hypotension, bradycardia, or anemia
 - Concerning EKG abnormalities during the visit, including new block patterns, ischemia, Brugada, new arrhythmias, or a prolonged QT interval
- Intermediate-risk patients have one of the following:
 - Meet no low- or high-risk criteria
 - Have concerning features in their history or physical exam
 - Meet low-risk criteria but carry other comorbidities

In general, high-risk patients benefit from hospitalization and extensive further workup, whereas low-risk patients do not. The difficulty lies in intermediate-risk patients where there is no clear evidence to help guide the level of evaluation; however, the group gives a recommendation for an additional 3 h period of continuous cardiac monitoring, with the plan to admit patients for any ventricular tachycardia, pause >3 s, symptomatic bradycardia less than 50 BPM or tachycardia greater than 120 BPM, or any bradycardia less than 30 BPM [21].

ECG: Every patient presenting with syncope or presyncope should undergo an ECG. The ECG is a low-cost low-risk evidence-based tool in screening syncopal patients for high-risk features suggestive of adverse events:

- Tachyarrhythmias
- WPW delta wave, short PR interval (Figure 5.1)

- Bradyarrhythmias
- Ischemia/infarction, Q waves (Figures 5.5 and 5.6)
- S1Q3T3 pattern suggestive of PE
- Brugada syndrome (Figure 5.4)
- Hypertrophy suggesting left ventricular outflow obstruction (Figure 5.2):
 - Hypertrophic cardiomyopathy
 - Aortic stenosis
- Prolonged QTc: risk for torsades de pointes (Figure 5.3)

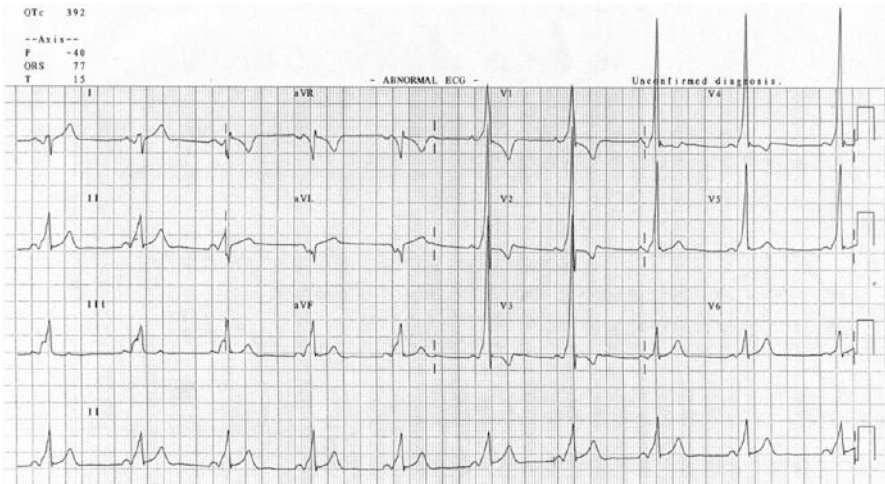


Figure 5.1 ECG with WPW

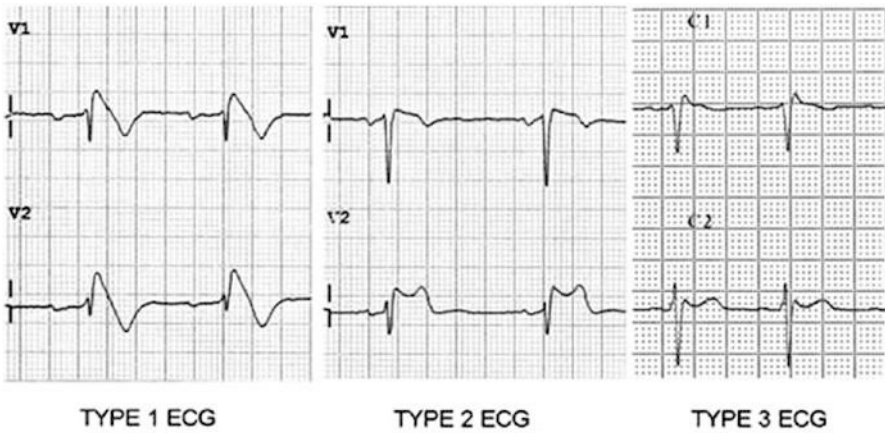


Figure 5.2 ECG with Brugada

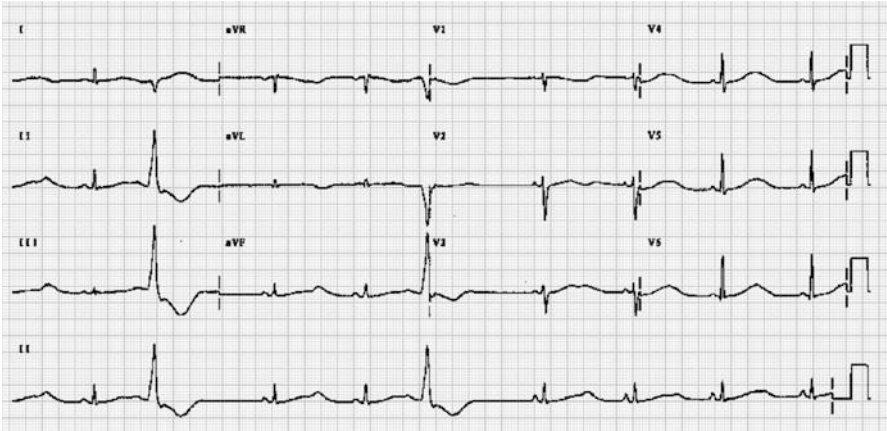


Figure 5.3 ECG with long QT

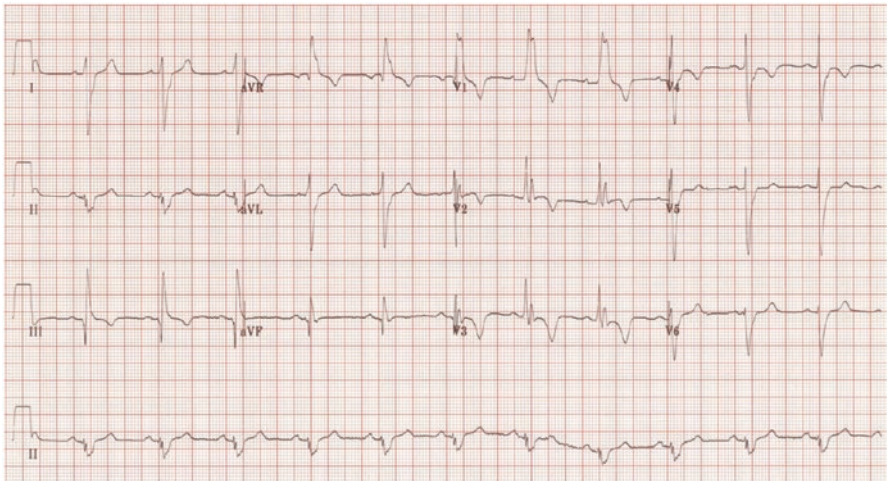


Figure 5.4 ECG with S1Q3T3

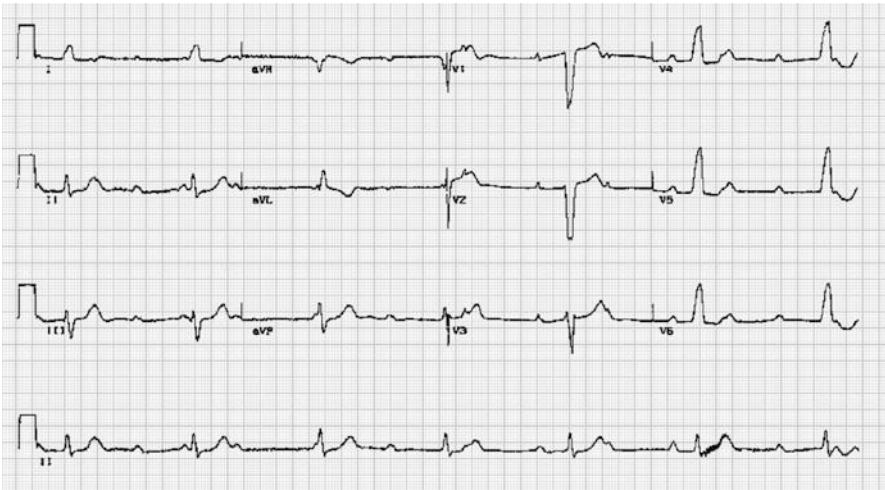

Figure 5.5 ECG with complete heart block

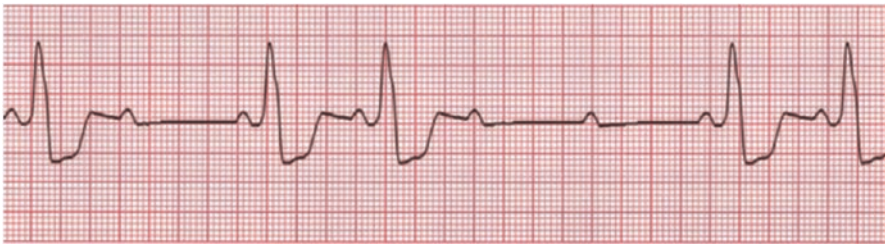

Figure 5.6 ECG with Mobitz II heart block

Telemetry: While the evaluation is ongoing, cardiac monitoring is useful to catch arrhythmias that may not have been present during the initial ECG. Patients with histories concerning for cardiac syncope should undergo continued cardiac monitoring. The duration of telemetry required is controversial, and its diagnostic yield has been as low as 3% [22]. It does retain importance though: in a validation study of the San Francisco Syncope Rule, five patients at high risk for adverse events were discovered only with telemetry [23]. High-risk patients should be considered for Holter monitors or other loop recorders for longer-term cardiac monitoring.

Laboratory analysis: A young, healthy patient with a strong story for neurocardiogenic-mediated, non-exertional syncope, a normal ECG, and no family history of sudden death often requires no laboratory testing. However, for patients without an etiology suggested by history, physical, or ECG, laboratory testing can be helpful in identifying patients at risk for adverse events:

- All females of childbearing age: pregnancy test. There is limited data on syncope in pregnancy; however, ectopic pregnancy can present with syncope [24]. Later in pregnancy, the pressure of the gravid uterus on the inferior vena cava causing impaired venous return to the heart can also lead to syncope.
- Patients with a cardiac history, abnormal ECG, exertional syncope, or associated chest pain should have cardiac ischemia ruled out with cardiac enzymes.
- The ROSE decision tool requires a BNP for risk stratification, with a value >300 pg/mL associated with adverse events. An elevated BNP is a useful tool in differentiating cardiac from non-cardiac syncope in admitted patients [25–28].
- Blood glucose: rule out hypoglycemia.
- Basic metabolic panel to evaluate for metabolic derangement.
- CBC: Check the hemoglobin and hematocrit for anemia and evidence of blood loss. New anemia should be further investigated, starting with occult fecal blood. Two syncope risk stratification studies found anemia (SFSRL Hct <30% [12], ROSE: Hgb <9 g/dL [11]) to be an independent risk factor for adverse events.
- Troponin testing is frequently performed on syncope patients, and one observational study reported that 3% of patients had levels above their institution's threshold [22]. However, it is unclear how many patients had other reasons for an elevated troponin.

Echocardiogram: Any patient with exertional syncope, associated chest pain, lack of prodromal symptoms, a known cardiac history, a family history of sudden death, or abnormal sounds on cardiac auscultation will benefit from a cardiac echo to identify potentially fatal causes of cardiac syncope. A formal exam is useful for identifying structural abnormalities such as myocardial hypertrophy, aortic outlet obstructions, and valvular stenosis, in addition to wall motion abnormalities and the ejection fraction. However, overuse of echocardiography has been identified as a potential area of over-testing. One retrospective study of 468 syncope patients found that only 5.7% of patients with normal ECGs had an abnormal echo. Alternatively, 29% of patients with an abnormal ECG had an abnormal echo [29].

Neuroimaging

Head CT: A non-contrast head CT is an overutilized, low-yield study in the evaluation of syncope for all-comers and should not be used as a screening tool for all patients with syncope [30]. The factors most strongly associated with abnormalities on head CT directly related to the syncopal event include focal neurological findings on physical exam, a history of recent head trauma, and age over 60 [31].

Table 5.3 Seizure

Question	Points
Tongue biting?	2
Preceding déjà vu/jamais vu?	1
In emotional stress?	1
Report of head turning?	1
Ever told you had an (1) unresponsive period? (2) unresponsive posturing/jerking? (3) no memory of unresponsive spell?	1 for any yes
Confusion after regained consciousness?	1
Ever have lightheadedness?	-2
Ever sweat before unconscious spell?	-2
Associated prolonged sitting/standing?	-2

Total score ≥ 1 strongly associated with seizure

EEG: Ruling out seizure as the cause of syncope can be quite difficult. Many of the sequelae associated with seizures can occur in syncope, and witnesses frequently describe shaking or jerking movements. Myoclonic jerks occur in the response to cerebral anoxia, which is likewise the driver of neurocardiogenic syncope. In fact, in a study of healthy patients who underwent induced syncope using a combination of hyperventilation, orthostasis, and Valsalva maneuvers, 90% of the syncopal patients experienced myoclonic jerks [32]. A study of 671 syncopal patients demonstrated that the most strongly predictive features of syncope include tongue biting (likelihood ratio 16.5) and head turning or posturing (likelihood ratios 13.5 and 12.8, respectively), while the historical features making seizure unlikely include any presyncopal symptoms prior to loss of consciousness, preceding diaphoresis, and prolonged sitting or standing prior to syncope. Using these data they developed a question-based scoring system for distinguishing seizure from syncope, with diagnostic accuracy ranging between 85 and 95% (Table 5.3) [7]. EEG is useful in ruling out seizure as the etiology of syncope but is only indicated when clinical concern for seizure is high.

Disposition

After the initial evaluation, the next question will be to determine who requires inpatient hospitalization and observation or who can safely follow up in the outpatient setting. Some patients will have a clear cause of syncope leading to admission, such as a complete heart block or a hemodynamically significant GI bleed. However, the majority of patients will not have the cause of their syncope definitively identified in the first hours, and they can pose a disposition dilemma.

The decision rules discussed above are useful tools for risk stratification, and any patient with the presence of one of these risk factors should strongly be considered for observation or admission. Patients under 40 with a strong story for neurocardiogenic syncope, normal vital signs, no cardiac history, and reliable outpatient follow-up are safe to be discharged home. Using a syncope decision rule to

identify low-risk patients has been shown to further reduce unnecessary admission rates, although none have been prospectively validated well enough to become a clear standard of care. Elderly patients pose the strongest dilemma as they are at higher risk for cardiac and neurologic causes of syncope, have more comorbidities, and are not as reliably captured by the aforementioned syncope decision rules when at risk for adverse events. Thus, one should have a much lower threshold for admission to the hospital or a short-stay unit for continuous cardiac monitoring and consideration for echocardiogram when structural disease is suspected. A short-stay or ED observation unit is a lower-cost alternative to admission for patients with an anticipated length of stay under 24–48 h. In the observation unit, patients can remain on continuous cardiac monitoring, undergo additional testing, and be evaluated by consulting services. A randomized clinical trial involving syncopal patients over the age of 50 at intermediate risk for adverse events demonstrated significant decreased length of stay, decreased rates of hospital admission, decreased healthcare costs, and no difference in adverse outcomes within 30 days or patient satisfaction scores when admitted to ED observation as compared to inpatient admission [33].

All discharged patients should be given strong return precautions for any palpitations, chest pain, or recurrent syncope. If the patient may have had a seizure, they should be instructed not to drive until follow-up and further testing is obtained. Patients with presumed orthostasis should be educated on careful, slow changes in position.

Pearls and Pitfalls

- Arrhythmias will often have completely resolved prior to your evaluation. Any patients with exertional or non-prodromal syncope are always concerning for cardiac causes, and one should have a low threshold for additional evaluation for arrhythmia (typically some period of telemetry).
- Myoclonic jerks, caused by cerebral ischemia, are common in syncope and often exacerbated by the well-meaning witness who aids a syncopal patient by catching their fall and keeping them upright, thus slowing the return of cerebral perfusion.
- Documented abnormal vital signs, even when they self-resolve, should be explained.
- Always check a pregnancy test in the female of childbearing age with syncope.
- Look carefully at the ECG – although abnormal findings are rare, when present they usually reflect an actionable cause of syncope.

References

1. Probst MA, Kanzaria HK, Gbedemah M, Richardson LD, Sun BC. National trends in resource utilization associated with ED visits for syncope. *The American Journal of Emergency Medicine*. 2015;33(8):998–1001.

2. Farwell DJ, Sulke AN. Does the use of a syncope diagnostic protocol improve the investigation and management of syncope? *Heart. BMJ.* 2004;90(1):52–8.
3. Sun BC. Quality-of-life, health service use, and costs associated with syncope. *Progress in Cardiovascular Diseases.* 2013;55(4):370–5.
4. Gauer RL. Evaluation of syncope. *Am Fam Physician.* 2011;84(6):640–50.
5. Shukla GJ, Zimetbaum PJ. Cardiology patient page. Syncope. *Circulation.* 2006;113(16):e715–7.
6. Cook OG, Mukarram MA, Rahman OM, et al. Reasons for hospitalization among emergency department patients with syncope. *Academy Emergency Medicine.* 2016;23(11):1210–7.
7. Sheldon R, Rose S, Ritchie D, Connolly SJ, Koshman M-L, Lee MA, et al. Historical criteria that distinguish syncope from seizures. *Journal of the American College of Cardiology.* 2002;40(1):142–8.
8. Parry SW, Richardson DA, O’Shea D, Sen B, Kenny RA. Diagnosis of carotid sinus hypersensitivity in older adults: carotid sinus massage in the upright position is essential. *Heart.* 2000;83(1):22–3.
9. English JA, Carell ES, Guidera SA, Tripp HF. Angiographic prevalence and clinical predictors of left subclavian stenosis in patients undergoing diagnostic cardiac catheterization. *Catheter Cardiovascular Intervention.* 2001;54(1):8–11.
10. Daniel McDermott MD, James Quinn MM. Approach to the adult patient with syncope in the emergency department [Internet]. Jonathan Grayzel MF, Robert S Hockberger MF, editors. uptodate.com. [cited 2016 Jun 19]. <http://www.uptodate.com/contents/approach-to-the-adult-patient-with-syncope-in-the-emergency-department>.
11. Reed MJ, Newby DE, Coull AJ, Prescott RJ, Jacques KG, Gray AJ. The ROSE (Risk Stratification of Syncope in the Emergency Department) study. *Journal of the American College of Cardiology.* 2010;55(8):713–21.
12. Quinn JV, Stiell IG, McDermott DA, Sellers KL, Kohn MA, Wells GA. Derivation of the San Francisco Syncope Rule to predict patients with short-term serious outcomes. *Annals of Emergency Medicine.* 2004;43(2):224–32.
13. Colivicchi F, Ammirati F, Melina D, Guido V, Imperoli G, Santini M, et al. Development and prospective validation of a risk stratification system for patients with syncope in the emergency department: the OESIL risk score. *Eur Heart J.* 2003;24(9):811–9.
14. Grossman SA, Bar J, Fischer C, Lipsitz LA, Mottley L, Sands K, et al. Reducing admissions utilizing the Boston Syncope Criteria. *The Journal of Emergency Medicine.* Elsevier. 2012;42(3):345–52.
15. Snead GR, Wilbur LG. Can the San Francisco Syncope Rule predict short-term serious outcomes in patients presenting with syncope? *Annals of Emergency Medicine.* 2013;62(3):267–8.
16. Quinn JV. Prospective validation of the San Francisco Syncope Rule (SFSR) to predict patients with serious outcomes. *Academic Emergency Medicine.* 2004;11(5):529–30.
17. Quinn JV, Stiell IG, McDermott DA, Kohn MA, Wells GA. The San Francisco Syncope Rule vs physician judgment and decision making. *The American Journal of Emergency Medicine.* 2005;23(6):782–6.
18. Schladenhaufen RJ. Can the San Francisco Syncope Rule be safely applied to patients aged 65 years and older who present to the emergency department with syncope or near-syncope? *Academic Emergency Medicine.* 2006;13(5 Supplement 1):S69.
19. Developed in collaboration with, European Heart Rhythm Association (EHRA), Heart Failure Association (HFA), and Heart Rhythm Society (HRS), Endorsed by the following societies, European Society of Emergency Medicine (EuSEM), et al. Guidelines for the diagnosis and management of syncope (version 2009): The Task Force for the Diagnosis and Management of Syncope of the European Society of Cardiology (ESC). *Eur Heart J.* 2009;30(21):2631–71.
20. Strickberger SA. AHA/ACCF Scientific Statement on the Evaluation of Syncope: from the American Heart Association Councils on Clinical Cardiology, Cardiovascular Nursing, Cardiovascular Disease in the Young, and Stroke, and the Quality of Care and Outcomes Research Interdisciplinary Working Group; and the American College of Cardiology Foundation: In Collaboration With the Heart Rhythm Society: endorsed by the American Autonomic Society. *Circulation.* 2006;113(2):316–27.

21. Constantino G, Sun BC, Barbic F, Bossi I, Casazza G, Dipaola F, McDermott D, et al. Syncope clinical management in the emergency department: a consensus from the first international workshop on syncope risk stratification in the emergency department. *European Heart Journal*. 2016;37(19):1493–8.
22. Chiu DT, Shapiro NI, Sun BC, Mottley JL, Grossman SA. Are echocardiography, telemetry, ambulatory electrocardiography monitoring, and cardiac enzymes in emergency department patients presenting with syncope useful tests? A preliminary investigation. *The Journal of Emergency Medicine*. 2014;47(1):113–8.
23. Thiruganasambandamoorthy V, Hess EP, Alreesi A, Perry JJ, Wells GA, Stiell IG. External validation of the San Francisco Syncope Rule in the Canadian setting. *Annals of Emergency Medicine*. 2010;55(5):464–72.
24. Barnhart KT. Ectopic Pregnancy. *New England Journal of Medicine*. 2009;361(4):379–87.
25. Pfister R, Hagemeister J, Esser S, Hellmich M, Erdmann E, Schneider CA. NT-pro-BNP for diagnostic and prognostic evaluation in patients hospitalized for syncope. *International Journal of Cardiology*. 2012;155(2):268–72.
26. Reed MJ, Newby DE, Coull AJ, Jacques KG, Prescott RJ, Gray AJ. Role of brain natriuretic peptide (BNP) in risk stratification of adult syncope. *Emergency Medicine Journal*. 2007;24(11):769–73.
27. Isbitan A, Hawatmeh A, Elnahar Y, Patel K, Altheeb Z, Debari V, et al. Utility of brain natriuretic peptide assay as a predictor of short term outcomes in patients presenting with syncope to the emergency department. *Cardiovasc Diagn Ther*. 2016;6(3):234–40.
28. Bader R, Sartini S. Risk stratification of syncope in the Emergency Department, Clinical Decision Rules or Clinical Judgement? *Emergency Medicine*. 2016;6:2.
29. Chang N, Shah P, Bajaj S, et al. Diagnostic yield of echocardiography in syncope patients with normal ECG. *Cardiology Research and Practice*. 2016;2016:1251637.
30. Goyal N, Donnino MW, Vachhani R, Bajwa R, Ahmad T, Otero R. The utility of head computed tomography in the emergency department evaluation of syncope. *Int Emergency Med*. 2006;1(2):148–50.
31. Mitsunaga MM, Yoon H-C JOURNALCLUB. Head CT scans in the emergency department for syncope and dizziness. *American Journal of Roentgenology*. 2014;204(1):24–8.
32. Lempert T, Bauer M, Schmidt D. Syncope: a videometric analysis of 56 episodes of transient cerebral hypoxia. *Annals of Neurology*. 1994;36(2):233–7.
33. Sun BC, McCreath H, Liang LJ, Bohan S, Baugh C, Ragsdale L, Henderson SO, Clark C, Bastani A, Keeler E, An R, Mangione CM. Randomized clinical trial of an emergency department observation syncope protocol versus routine inpatient admission. *Annals of Emergency Medicine*. 2014;64(2):167–75.

Dizziness: An Evidence-Based Approach (Better than MRI?)

6

Jonathan A. Edlow

Case Presentation

A 45-year-old patient with a history of well-controlled hypertension and mildly elevated cholesterol comes to the emergency department (ED) for 8 h of continuous dizziness that began rapidly. The patient describes severe light-headedness. There is no headache or neck pain. Vital signs and general physical examination are normal. On examining the eyes, horizontal nystagmus that beats toward the left is present. Skew deviation is absent. On head impulse testing, there is a corrective saccade when moving toward the right. The remainder of the neurological examination is normal.

Introduction

Approximately 3.5% of emergency department (ED) visits are for dizziness [1, 2]. Numerous conditions, some benign and self-limiting and others extremely serious, can present with dizziness. This is a classic emergency medicine—sorting out the large majority of patients with a given chief complaint who have a self-limiting or easily treatable condition from the smaller number that have life-, limb-, or brain-threatening problems. As of 2013, the direct ED-related costs of care for patients with dizziness in the USA were estimated to approach \$4 billion [3]. In addition to economic, there is additional “cost” both in terms of patient-experienced anxiety and falls, attributed to dizziness, with their resultant morbidity.

The existing paradigm for diagnosing dizziness is based on “symptom quality” (i.e., asking the question “what do you mean ‘dizzy’?”). This approach is taught in

J.A. Edlow, M.D., F.A.C.E.P

Professor of Medicine and Emergency Medicine, Harvard Medical School, Vice-chair,
Department of Emergency Medicine, Beth Israel Deaconess Medical Center, Boston MA, USA
e-mail: jedlow@bidmc.harvard.edu

nearly all review articles and textbooks across specialties; however, newer research has shown that its scientific basis and its internal logic lack foundation.

Currently, misdiagnosis in patients with dizziness is a problem in an environment that is paying increasing attention to diagnostic errors [4]. Misdiagnosis of patients with cerebellar stroke can have disastrous consequences [5]. This article will review the differential diagnosis of acute dizziness in adult patients, discuss newer research about the diagnosis of dizziness, and suggest a modern evidence-based approach.

The new approach emphasizes history and physical examination that will hopefully lead to emergency physicians more frequently and confidently making a specific diagnosis. When a confident diagnosis is made of a peripheral problem, time-consuming consultation, expensive imaging, and hospitalization become unnecessary. When the evaluation suggests a central problem, especially stroke, steps can be taken to diagnose and treat the offending vascular lesion and institute secondary prevention measures.

This new approach to the ED patients with dizziness should improve diagnostic accuracy and reduce length of stay and resource utilization and would be expected to improve overall patient outcomes.

Differential Diagnosis of Acute Dizziness

Numerous disorders and conditions that span multiple organ systems can present with acute dizziness. Many of these diagnoses are benign; others are life-threatening. A study from the national NHAMCS patient database over a 13-year period identified 9472 patients with dizziness [2]. These data suggest that most patients have general medical (including cardiovascular) diagnoses (~50%), oto-vestibular diagnoses (~33%), and neurologic (including stroke) diagnoses (~11%) [2, 6].

Studies of large administrative databases have the limitation that the accuracy of the charted diagnosis is unknown. In the NHAMCS study, 22% of patients received a “symptom only” diagnosis (e.g., dizziness, not otherwise specified). Although assigning a diagnosis of the presenting symptom is common in emergency medicine practice, a “symptom only” diagnosis was three times more common in dizzy patients than in all other patients. In addition, even if a specific vestibular diagnosis is made, such as benign paroxysmal positional vertigo (BPPV), the use of imaging and treatment with medications is not in accordance with best evidence [7].

In the NHAMCS study, prospectively defined “dangerous” diagnoses (various cardiovascular, cerebrovascular, toxic, metabolic, and infectious conditions in which the possibility of a poor outcome without treatment was likely) were found in 15% of patients, and this proportion increased with age [2]. The most common dangerous causes found were fluid and electrolyte disturbances (5.6%), cerebrovascular diseases (4.0%), cardiac arrhythmias (3.2%), acute coronary syndromes (1.7%), anemia (1.6%), and hypoglycemia (1.4%) [2]. Some rare causes of dizziness such as adrenal insufficiency [8], aortic dissection [9], carbon monoxide intoxication [10], pulmonary embolus [11], and thiamine deficiency [12] are treatable.

How does this study compare to others? One older single-institution study analyzed 125 patients prospectively identified over a 16-month period [13]. Forty-three

percent had a diagnosis of a peripheral vestibular problem, and 30% had a “serious” diagnosis. Another larger prospective single-institution Chinese study of adult ED patients with dizziness reported results of 413 patients recruited over just 1 month [1]. A central nervous system (CNS) cause was found in 23 patients (6%).

Two retrospective studies also provide relevant data. One was done in a German ED of 475 consecutive dizzy patients who were seen by a neurologist during the index ED visit [14]. The initial diagnoses assigned by the neurologists were benign in 73% of cases and serious (mostly cerebrovascular and inflammatory CNS disease) in 27% of cases. Overall, the two most common diagnoses were BPPV (22%) and stroke (20%). In follow-up by a neurologist blinded to the ED diagnosis, 44% of diagnoses (previously made by a neurologist in the ED) were changed. Over half of these diagnostic changes were from a serious to a benign diagnosis, which errs toward patient safety but is more resource intensive than necessary. In about one patient in seven, the error was from benign to serious (five patients diagnosed with vestibular neuritis and one with vestibular migraine, all reassigned to stroke), a dangerous misdiagnosis.

The other study analyzed patients who had an ED triage diagnosis of dizziness, vertigo, or imbalance as a primary symptom, collected over a 3-year period, and identified 907 patients (only 0.8% of all ED patients over that period of time), suggesting a very targeted selection (compared to other large studies) [15]. Of the 907 patients, one in five was admitted (68% to an intensive care unit—ICU). The most common admitting services were medicine (41% of admissions), cardiology (32%), and neurology (24%). Of the 907 patients, most had benign conditions either peripheral vestibular problems, 32%, orthostatic hypotension (13%), or migraine (4%). A full 22% could not be diagnosed. Serious neurological disease was found in 49 patients (5%) of which 37 were cerebrovascular. Finally, only two patients with serious neurological disease presented with isolated dizziness.

The incidence of important CNS disease in adult ED patients with dizziness is approximately 5%. The high-end outlier is the Royle study that reported that 27% of patients have serious CNS causes which may be skewed by the fact that the study was conducted in a neurological ED [14]. Various studies have tried to identify risk factors for ED dizzy patients with CNS causes [1, 15–19]. One ED study of dizzy patients found that abnormal gait and subtle neurological deficits on neurological examination were associated with a CNS cause [16]. Overall, the risk factors include increasing age, vascular risk factors and history of previous stroke, complaint of “instability,” and focal neurological findings (Table 6.1).

Taken as a whole, these data suggest the following conclusions:

1. Most adult patients who present to the ED with acute dizziness have general medical or cardiovascular conditions.
2. Although benign vestibular diseases are much more common than CNS causes of dizziness, when emergency physicians make these (benign) diagnoses, their use of imaging and meclizine is not in accordance with the best available evidence.
3. Of the CNS causes, acute cerebrovascular disease (ischemic stroke or transient ischemic attack—TIA) is the most common cause, and misdiagnosis in the ED is not uncommon in these patients.

Table 6.1 Risk factors for a central nervous system cause in emergency department patients with dizziness

Risk factor	Cheung et al. [1]	Navi et al. [15]	Chase et al. [16]	Kerber et al. [19]
Age in years	6.15 for age > 65	5.7 for age > 60		
Symptom of imbalance or ataxia	11.39 for “ataxia”	5.9 for “imbalance”	9.3 for “gait instability”	
Focal neurological symptoms	11.78	5.9		
History of previous stroke	3.89			
Vascular risk factors	3.57 for diabetes			0.48 (CI crossed 1)
ABCD2 score				1.74 (scored as a continuous variable)
HINTS testing				2.82
Other neurological deficits			8.7 for “subtle” neurological finding	2.54

Not every study reported on every variable; blank cells were not reported in that study. Numbers are odds ratios (when reported)

HINTS head impulse, nystagmus, test of skew; *CI* confidence intervals

Origin of the “Symptom Quality” Approach to Diagnosing Dizziness and Its Lack of Scientific Validity

A publication in 1972 led to the “symptom quality” approach to the acutely dizzy patient [20]. Over a 2-year period, the authors enrolled 125 patients. The study suffers from several shortcomings that include a low number of patients, the fact that most patients were not evaluated during the acute phase of their illness, no verification of diagnosis, no long-term follow-up, and others (Table 6.2). This study was the basis for the traditional approach to dizziness that starts by asking the patient, “What do you mean by ‘dizzy’?”

For this “symptom quality” approach to work, two facts must be true. First, patients should be able to reliably and consistently choose one (and only one) dizziness type. Secondly, each symptom type should be tightly linked with a given differential diagnosis. Both facts are demonstrably false [21].

Patients do not choose a single dizziness type. Sensory symptoms are difficult for many patients to describe. Patients with dizziness may use words like, “dizzy,” “light-headed,” “spinning,” “rocking,” “vertigo,” “giddy,” “like I’m going to faint,” “off-balance,” “spacey,” and others to describe what they feel. For this paper, I will use the word “dizziness” in a general way (incorporating all of these descriptors).

In a study published in 2007, research assistants asked a series of ED patients with dizziness a battery of questions aimed at determining “symptom quality” and timing and triggers of the dizziness [22]. Over 60% of the patients chose more than one dizziness type. The questions were then re-asked in a different sequence an average of 6 min later; more than 50% of the patients changed their primary

Table 6.2 Shortcomings of the original paper on the “symptom quality” approach

Methodological issues	
<i>Tautological hypothesis</i>	
	Their methods placed patients into one of four categories of dizziness by design
	Related “appropriate” questions were only asked once the dizziness category was assigned
	A diagnosis of a “peripheral vestibular disorder was typically applied to a patient who complained of unmistakable rotational vertigo”
<i>Lack of independent verification and blinding</i>	
	A single individual assigned the final diagnosis; there was no independent verification of the diagnoses
	The individual assigning the diagnoses was not blinded to the data or the categories of symptom quality
<i>Small number of subjects with 25% drop-out rate after enrollment</i>	
	125 total patients were enrolled (but 25.6% were excluded)
	12 (16.8%) were excluded due to “inadequate data” obtained
	9 (7.2%) were excluded because of “uncertain diagnosis”
	2 (1.6%) were excluded because they were “inappropriate referrals”
<i>Selection bias</i>	
	Only 125 patients were enrolled over a 2-year period
	They had to be available to return on four different days for testing
	They had to be fluent in English
<i>Lack of long-term follow-up of patients</i>	
	There was no long-term follow-up to verify accuracy of diagnosis
Unavoidable issues related to era in which study was performed	
<i>Lack of modern imaging</i>	
	When the study was done, neither CT nor MRI was available
<i>Lack of some diagnoses being established</i>	
	Vestibular migraine (a common cause of s-EVS) had not yet been described
	Posterior circulation TIA presenting as isolated dizziness was not recognized

dizziness type. The responses to timing and triggers of dizziness were much more consistent and reliable between the first and second responses.

Thus, the history should be taken just as one does with a patient with chest pain or dyspnea. One does not evaluate a patient with chest pain differently if the pain is described as “sharp” or “dull” or “discomfort” or “pressure” [21]. One does not use the descriptor of the pain in a binary way; the timing and triggers are more important in rank-ordering a differential diagnosis. We take histories of virtually all chief complaints using the concept of timing and triggers.

Another concept that physicians use regularly to construct a differential diagnosis is that of context and presence or absence of associated symptoms. One thinks very differently about a patient with chest pain associated with (a) leg swelling and dyspnea, (b) productive cough and fever, or (c) hypotension, unilaterally diminished breath sounds, and distended neck veins. It is not simply the word that the patient uses that informs the differential diagnosis but also the timing, triggers, associated symptoms, and epidemiologic context. It should be no different with dizziness.

Finally, the differential diagnosis is not tightly linked with a given use of the descriptors. The use of the word “vertigo” was not associated with a higher

incidence of stroke in a large series of ED patients with dizziness [23]. Patients with a cardiovascular cause of dizziness do endorse “vertigo” in almost 40% of cases [24]. Patients with BPPV often say they feel light-headed and not vertiginous, especially elderly patients [25]. The reality is that the differential diagnosis should *not* be based on the word but rather on the timing, triggers, associated symptoms, and the epidemiologic context.

Despite the fact that the “symptom quality” approach to dizziness is not based on strong science, it is the predominant paradigm used across specialties.

Misdiagnosis of Patients with Dizziness and Resource Utilization

Misdiagnosis of patients with dizziness is common. In the German ED study, neurologists seeing patients made diagnostic errors in 44% of patients. The authors of that study found three factors that contributed to misdiagnosis [14]. First, subsequent clinical course evolved, making the ultimate diagnosis more clear. This factor played a role in 70% of misdiagnoses. This is a regular event in emergency medicine, in which we see patients whose symptoms evolve in a variable way even over hours. The other two factors were insufficient brain imaging (mostly MRI, found to be a factor in half of cases) and failure to screen for vascular risk factors using advanced testing such as echocardiography, telemetry, or ultrasound of cervical arteries (24% of cases). There has never been a head-to-head comparison of emergency physicians versus neurologists diagnosing patients with dizziness at the same phase of care (and likely never will), but this German study clearly shows that dizziness is complicated, even to those with specialized training and focus.

In another study of 1091 dizzy patients in US EDs, emergency physicians documented some comment about nystagmus in 887 (80%) of whom nystagmus was documented to be present in 185 (21%) [26]. No other information beyond the presence or absence was recorded in 26% of the 185 patients, and sufficient information to be diagnostically useful was only recorded in ten patients (5.4%). Of patients given a peripheral vestibular diagnosis, the description of the nystagmus conflicted with that diagnosis. This illustrates a knowledge gap in emergency physicians’ understanding of nystagmus: what to look for, how to report it, and, most importantly, how to use the findings to their advantage.

Reporting the presence or absence of nystagmus in a dizzy patient is not the key finding. In a patient with an AVS the findings of direction-fixed horizontal nystagmus versus direction-fixed vertical nystagmus versus direction-changing nystagmus have different significances (see below). A recent review illustrates how to use the physical examination in dizzy patients [27].

Multiple studies find that patients with an AVS that superficially appears to be a peripheral process in fact have posterior circulation strokes [28–30]. In one, almost 3% of patients referred to the ENT clinic for vertigo had a missed cerebellar stroke [29]. There are two major reasons that missed stroke is an important misdiagnosis. The first is that the underlying vascular mechanism goes untreated, leaving the patient vulnerable to another stroke, and the second is that some patients will develop posterior fossa edema that can be fatal [5]. Although lost opportunity for

thrombolysis is often suggested as a third negative consequence of missing a posterior circulation stroke, many of these patients have minor deficits and are not necessarily thrombolysis candidates. Some have an NIHSS of zero [31].

Younger age and dissection as a cause were found to be risk factors for missed cerebellar stroke [32]. Posterior circulation location is a risk factor for stroke misdiagnosis in general [33–35]. To put these data into some context, only a very small proportion (0.18–0.63%) of patients who are seen in the ED diagnosed with a benign or peripheral vestibular diagnosis return to the ED within 30 days and are hospitalized with a cerebrovascular diagnosis [36–38]. However, because dizziness is so common, this small fraction of a large number would suggest that many thousands of patients have a missed diagnosis of an acute cerebrovascular syndrome (stroke or transient ischemic attack—TIA) each year.

The other side of the coin is that a lack of recognition of common peripheral vestibular problems (such as BPPV and vestibular neuritis) can result in undertreatment, incorrect treatment, and resource overutilization.

A recent review of misdiagnosis of patients with dizziness suggested five common pitfalls [39]. These are overreliance on a symptom quality approach to diagnosis, underuse of timing and triggers approach, lack of familiarity with key physical examination findings, overweighting traditional factors such as age and vascular risk factors to screen patients, and overreliance on CT. Although stroke is more common in older individuals, young patients do have strokes, a fact that may contribute to misdiagnosis [5, 40, 41].

A New Paradigm to Diagnose Patients with Acute Dizziness: ATTEST

A new diagnostic paradigm which is based on the timing, triggers, and context of the dizzy symptoms might reduce misdiagnosis and decrease unnecessary resource utilization. My personal experience is that it allows one to confidently make a specific diagnosis more frequently than the traditional paradigm. The basic idea is that it is the timing, triggers, evolution, and context of symptoms that should drive the workup rather than the specific words that a patient uses to describe their dizziness [6, 21]. I favor the mnemonic: ATTEST—which stands for A (*associated symptoms*), TT (*timing and triggers*), ES (*bedside exam signs*), and T (*additional testing as needed*).

This new paradigm may seem like a radically new way of approaching the dizzy patient, but this is only because the traditional “symptom quality” approach is so deeply engrained in how this subject has been taught [21]. In fact, using a timing and triggers approach is no different than taking a history in any other patient.

Using this paradigm, there are four timing and triggers categories that are important for emergency physicians (Table 6.3). In the traditional paradigm, a patient who endorsed “vertigo” would get an evaluation to try to diagnose peripheral vestibular versus central nervous system (CNS) causes of dizziness. This has led to confusion. Physicians tend to treat all patients with peripheral vertigo the same, whereas the two most common by far being BPPV and vestibular neuritis should be treated very differently [7]. The following sections will review the presentation, differential diagnosis, and appropriate testing to make a specific diagnosis for each of the timing and triggers categories.

Table 6.3 Timing- and-trigger-based “vestibular^a syndromes” in acute dizziness^b

Syndrome	Description	Common causes
AVS	Rapid onset of acute dizziness that lasts days, often associated with nausea, vomiting, and head-motion intolerance	Benign: vestibular neuritis and labyrinthitis Serious: cerebellar stroke
t-EVS ^c	Episodic dizzy episodes triggered by some specific obligate event, usually head movement or standing up and usually last less than 1 min	Benign: BPPV Serious: orthostatic hypotension and CPPV
s-EVS	Episodic dizzy episodes that occur spontaneously are not triggered and usually last minutes to hours	Benign: vestibular migraine, Meniere’s disease Serious: TIA
CVS	Chronic dizziness lasting weeks to months (or longer)	Benign: medication side effects, anxiety, and depression Serious: posterior fossa mass

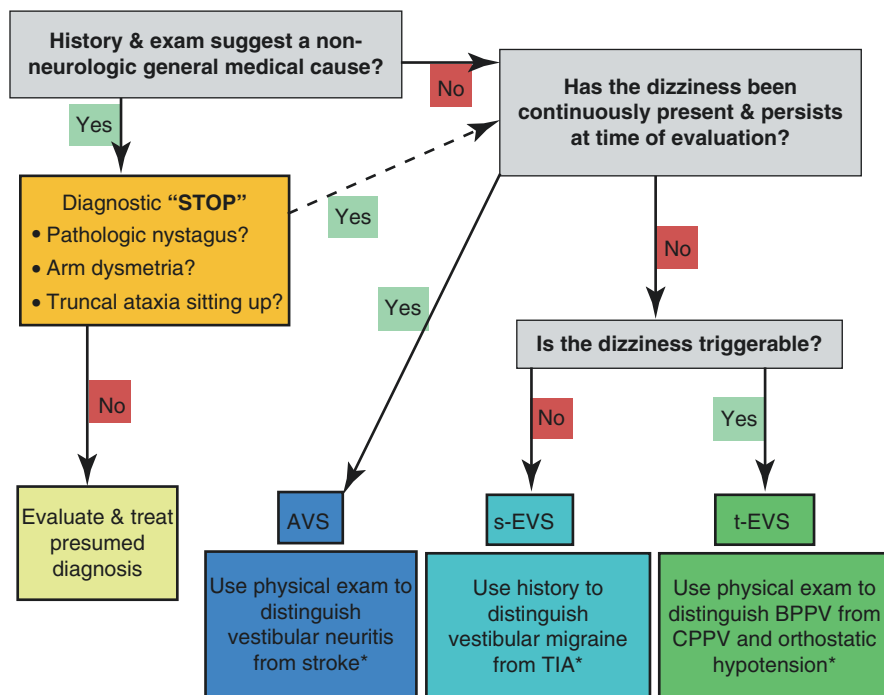
AVS acute vestibular syndrome, *t-EVS* triggered vestibular syndrome, *s-EVS* spontaneous vestibular syndrome, *BPPV* benign paroxysmal positional vertigo, *CPPV* central paroxysmal positional vertigo, *TIA* transient ischemic attack, *CVS* chronic vestibular syndrome

^aNote that the use of the word “vestibular” here connotes vestibular symptoms (dizziness or vertigo or imbalance or light-headedness), rather than that the underlying causes is necessarily vestibular

^bThis table lists the more common causes of these presenting syndromes and is not intended to be encyclopedic

^cDizziness is “triggered” when it is brought on from a baseline of no symptoms, as in positional vertigo due to BPPV. This must be distinguished from dizziness that is “exacerbated” from a milder baseline state; such exacerbations are common in AVS, whether peripheral (neuritis) or central (stroke)

ATTEST: Diagnostic Approach to the Acutely Dizzy Patient



*For each vestibular syndrome, only the most common benign and dangerous diagnoses are listed

Acute Vestibular Syndrome (AVS)

Spontaneous AVS is defined as the acute onset of persistent dizziness in association with nausea or vomiting, gait instability, nystagmus, and head-motion intolerance that lasts days or weeks and gradually resolves [6, 21, 42]. Patients are usually symptomatic at the time of assessment, and focused physical examination is often diagnostic. The most common cause is vestibular neuritis (dizziness only) or labyrinthitis (dizziness plus hearing loss or tinnitus) [42]. The most frequent dangerous cause is posterior circulation ischemic stroke, generally in the cerebellum or lateral brainstem [42]. A distant third most common cause is multiple sclerosis [43, 44]. Uncommon causes of an isolated AVS include cerebellar hemorrhage and a number of rare, but often treatable, autoimmune, infectious, or metabolic conditions [43, 45]. The spontaneous AVS is to be distinguished from a triggered AVS, which we will not further discuss in this paper because the cause is usually obvious, such as post-traumatic dizziness or diphenylhydantoin toxicity.

An important concept is that patients with an AVS generally experience worsening of their symptoms with head movement. These *exacerbating* features should not be mistaken for head movement *triggers* that facilitate diagnosis in EVS patients. Confusion on this point probably contributes to difficulty differentiating BPPV from vestibular neuritis [6, 7, 46]. Acute BPPV patients occasionally complain of more persistent symptoms that may be due to repeated triggering symptoms with small, inadvertent head movements or anticipatory anxiety about moving. This can usually be teased out by careful history taking. When such patients lack obvious features of vestibular neuritis or stroke, the Dix-Hallpike and supine roll test can be performed to assess for an atypical, AVS-like presentation of BPPV [47].

Vestibular neuritis is a benign, self-limited, presumed viral, or post-viral inflammatory condition affecting the vestibular nerve and causing spontaneous AVS, similar to Bell's palsy (seventh nerve) but involving the vestibular portion of the eighth nerve. Some cases are associated with inflammatory disorders (e.g., multiple sclerosis or sarcoidosis), but most are idiopathic and possibly linked to herpes simplex infections [48]. The idiopathic form is generally monophasic and resolves over days to weeks. Routine MRI with contrast is generally negative [49]. The diagnosis is usually clinical. A related condition, herpes zoster oticus (Ramsay Hunt syndrome type 2), may present with AVS, usually in conjunction with hearing loss, facial palsy, and a vesicular eruption in the ear or palate [50].

Posterior fossa strokes may present with AVS mimicking vestibular neuritis (or labyrinthitis if auditory symptoms are present) [51]. The prevalence of cerebrovascular disease in patients presenting to the ED with dizziness is 3–6% [1, 2, 13, 23], but among AVS presentations, it is estimated at ~25% [42]. Almost all (96%) are ischemic strokes, rather than hemorrhages [42, 45]. CT sensitivity for acute ischemic stroke is low and probably worse in the posterior fossa [52–54]. Therefore, CT cannot “rule out” ischemic stroke in AVS, a fact often contributing to misdiagnosis [5, 39, 46]. Importantly, even MRI with diffusion-weighted imaging (DWI) misses 10–20% of strokes in AVS during the first 24–48 h after symptom onset, and repeat delayed imaging (3–7 days post symptom onset) may be required to confirm the presence of a new infarct [42, 55, 56].

Fortunately, the physical examination can help make the distinction between vestibular neuritis and posterior circulation stroke with greater sensitivity than early MRI [55, 56]. These two studies were done by neuro-otologists performing a targeted ocular motor exam consisting of three components—the head impulse test (HIT), testing for nystagmus, and skew deviation (HINTS—head impulse, nystagmus, test of skew). One other study showed similar accuracy when performed by stroke neurologists [57]. Preliminary evidence suggests that “specially trained” emergency physicians can learn to use nystagmus and head impulse testing [58, 59]. My own anecdotal experience also suggests that with some training, emergency physicians can perform and interpret this examination. However, because this approach has not been fully validated when used by nonspecialists, I have added two additional components that should be a part of the basic evaluation of the acutely dizzy patient anyway—the general neurological examination and testing of gait.

I do not perform these tests in the order of the HINTS mnemonic but rather in the following order:

1. Nystagmus testing
2. Skew deviation
3. Head impulse testing (HIT)
4. General neurological exam, focusing on cranial nerves including hearing, cerebellar testing, and long-tract signs
5. Gait testing

There are two reasons for this sequence. Firstly, I like to start with the least “intrusive” parts of the examination, and, secondly, nystagmus testing is the component that helps the most, in part by its presence or absence and in part by its quality. Once any one component tests “positive” for a central cause, then the patient’s disposition (admission for further neurological evaluation) is clear. Although all five components mentioned above are part of a complete examination for a patient with an AVS, causing the patient to feel worse with further intrusive testing (e.g., testing gait that provokes vomiting) after a less intrusive test is positive will not change the disposition and just result in the patient feeling worse.

Furthermore, nystagmus helps to anchor and inform the rest of the process. Essentially all patients with an AVS due to vestibular neuritis will have nystagmus if examined within the first days, so its absence should make one question the diagnosis. To be sure that nystagmus is truly absent, it should be tested with visual fixation removed. Experts state that the absence of nystagmus in a patient examined with their visual fixation removed essentially rules out a vestibular cause for the dizziness [60]. Subspecialists typically use Frenzel lenses to remove visual fixation, neither available nor common practice in emergency medicine practice. A simple solution is to take a large piece of white paper, place it close to the patient’s eyes (telling them to “look through the paper”), and examine the nystagmus from the side. This technique is only needed if there is no nystagmus with the basic exam.

If nystagmus is truly absent, then this is unlikely to be a vestibular process, and therefore head impulse test is not useful and may yield false information. It is still important to perform a complete neurological exam with special attention to

Table 6.4 Acute vestibular syndrome oculomotor physical findings

Oculomotor exam component	Peripheral (usually vestibular neuritis)	Central (usually posterior circulation stroke)
Nystagmus (neutral gaze and gaze to the right and left)	Dominantly horizontal and direction-fixed, beating away from the affected side	Direction-changing horizontal or dominantly vertical and/or torsional and then central ^b (often mimics peripheral)
Test of skew (alternate cover test)	Normal vertical eye alignment (i.e., no skew deviation)	Often mimics peripheral; if skew deviation is present, then central ^c
Head impulse test (HIT)	Unilaterally abnormal toward the affected side (presence of a corrective saccade) ^a	Usually bilaterally normal (no corrective saccade)

^aStrokes in the anterior inferior cerebellar artery (AICA) territory may produce a unilaterally abnormal head impulse test that mimics vestibular neuritis, but hearing loss is usually present as a clue. If a patient has bilaterally abnormal HIT, this is also suspicious for a central lesion if nystagmus is present (AICA stroke or Wernicke's syndrome)

^bInferior branch vestibular neuritis will present with downbeat-torsional nystagmus, but this is a rare disorder. From the emergency medicine perspective, vertical nystagmus in a patient with an AVS patient should be considered to be central (a stroke)

^cSkew deviation, demonstrated by the bedside alternate cover testing, is very rare in peripheral vestibular cases; its presence should be considered to be central (a stroke, often in the brainstem)

brainstem and cerebellar function and gait since patients with cerebellar stroke often do not have nystagmus.

The degree (or amplitude) of nystagmus can fluctuate markedly even over hours. This may represent the natural history of the underlying pathology as the CNS accommodates to the abnormal physiology from vestibular neuritis or from medications (e.g., ondansetron or a benzodiazepine) that are often appropriately used in the ED to reduce symptoms but may accelerate the rate at which the nystagmus dampens.

Nevertheless, clinical testing for nystagmus is quite simple. Have the patient look straight ahead in “neutral” or “primary” gaze and observe for eye movements. By convention, the direction of nystagmus is named by the direction of the fast component. With minimal practice this is easy to see and describe. Importantly, it is the details of the nystagmus, not simply its presence that is most diagnostically important. After observing for nystagmus in primary gaze, test for “gaze-evoked” nystagmus by having the patient look to the right and then to the left, each for several seconds, and observe for the presence of nystagmus and the direction of its fast-beating component. The patient only needs to move their eyes 20–30° off-center when testing for gaze-evoked nystagmus because many normal individuals will have a few beats of horizontal nystagmus on full end gaze. This physiologic nystagmus is generally very low amplitude and extinguishes quickly. Table 6.4 shows the typical findings for patients with the ocular motor examination for patients with the AVS. Direction-changing gaze-evoked nystagmus or nystagmus that is pure torsional or vertical is central in origin (in the setting of an AVS, a stroke).

Skew deviation (a vertical misalignment of the eyes due to imbalance in the gravity-sensing pathways) is not very sensitive (30%) but is very specific (98%) for a brainstem lesion [42]. For this examination, the examiner uses the “alternate cover” test. With the patient looking directly at the examiner’s nose, the physician

alternately covers the right eye and then the left eye and continues alternating back and forth, approximately every 2 s. In patients with skew deviation, each time the covered eye is uncovered, there will be a slight vertical correction (one side corrects upward and the other corrects downward). The amplitude of correction is small, 1–2 mm; therefore, it is key for the examiner to focus on one eye (either one), rather than following the uncovered eye. A normal response is no vertical correction, and an abnormal response should be considered a stroke in patients with an AVS.

The next component is the HIT, a test of the vestibulo-ocular reflex (VOR), only described in 1988 [61]. Standing in front of the patient, the examiner holds the patient's head by each side and instructs the patient to maintain their focus on the examiner's nose and to keep their head and neck loose. Then the examiner very quickly turns the patient's head about 10–20°, using a lateral to center motion. The normal (individuals with normal vestibular function) response is that the patient's focus will stay locked on the examiner's nose. The presence of a corrective saccade (the eyes move with the head and then snap back in a fast corrective movement to the examiner's nose) is a “positive” test (abnormal VOR), which generally indicates a peripheral process, usually vestibular neuritis. The absence of a corrective saccade in AVS is consistent with a stroke.

It may seem counterintuitive that a normal finding predicts a dangerous disease. This is why the HIT is only useful in patients with the AVS and nystagmus. If an acutely dizzy patient with an AVS does not have nystagmus, it's very unlikely to be vestibular, and therefore the HIT (which is meant to distinguish neuritis from stroke) becomes far less useful and usually misleading. Similarly, if the HIT were done in a patient with dizziness from urosepsis or dehydration, the test will be negative, i.e., worrisome for a stroke.

Patients with cerebellar stroke have a negative (normal) HIT [30, 62]. This is because the circuit of the VOR does not loop through the cerebellum. On the other hand, occasional patients with posterior circulation stroke will have a falsely “positive” (abnormal) HIT, usually from a lateral brainstem infarct involving the location where the vestibular nerve enters the brainstem. These strokes are uncommon and involve the anterior inferior cerebellar artery stroke (AICA) territory or an infarction directly involving the inner ear (labyrinthine stroke) itself. In both situations, acute hearing loss usually occurs. Adding a bedside test of hearing (“HINTS plus”) will help to pick up the occasional AICA stroke [63]. This last point is important because traditional teaching is that if both hearing and dizziness coexist, the problem is peripheral (in the labyrinth). However, the blood supply to the labyrinth is due to ischemia of branches of the AICA, so this co-involvement of hearing and dizziness can occur from a stroke [64–66]. The relative frequency of this occurring from a peripheral cause (true labyrinthitis) as opposed to stroke (AICA territory) is unknown.

A recent article with attached video clips reviews these physical examination findings [27]. Because HINTS testing has not been fully validated when done by nonspecialists, I recommend adding two additional components of the HINTS testing—brainstem and cerebellar testing and gait testing. Key elements include testing for pupillary function, facial motor and sensory symmetry, and dysarthria. Lateral medullary stroke (Wallenberg's syndrome), an important cause of the AVS, merits special attention. These patients have dysarthria, dysphagia, or hoarseness due to

lower cranial neuropathy and may have Horner's syndrome with mild ptosis and anisocoria that may only be evident in dim light (so that the normal larger pupil fully dilates, making the difference in pupil size more apparent) [67]. Common physical examination findings are hemifacial decreased pain and temperature sensation. Routine testing of only light touch can miss this finding.

Finally, if all four initial components of the exam (nystagmus, skew deviation, HIT, and general neurological exam) are nondiagnostic, gait testing must be performed. Ideally have the patient walk unassisted, but for patients too symptomatic to walk, test for truncal ataxia by asking the patient to sit upright in the stretcher without holding onto the side rails. A patient who cannot walk or sit up unassisted is unsafe for discharge, and an AVS patient who is unable to walk is more likely to have had a stroke than vestibular neuritis [30].

Imaging is not very useful in patients with the AVS. CT is a poor test for posterior circulation stroke [52–54]. MRI, even with DWI, misses 10–20% of strokes in AVS during the first 24–48 h [42, 55, 56]. In small brainstem strokes, MRI, with DWI, can still miss upward of 50% when tested within 48 h [56]. Importantly, half of those small strokes were not due to small vessel disease, but due to vertebral artery atherosclerosis or dissection. Therefore, in patients with the AVS, the physical examination is more sensitive than MRI.

An Italian ED study (in which the emergency physicians used Frenzel lenses to test for nystagmus) exploited elements of this bedside exam and showed that it decreases both CT use and hospitalization [59]. However, another survey study found that many emergency physicians clearly do not understand or feel confident in HINTS testing and overuse CT [41]. This same study showed that emergency physicians tend to overvalue the dizziness type in making a diagnosis. Although traditional vascular risk factors underperform HINTS and neurological exam testing [19, 63], emergency physicians still value them over bedside testing [41].

Triggered Episodic Vestibular Syndrome (t-EVS)

Patients with t-EVS have short-lived episodes of dizziness lasting seconds to a few minutes, depending on the underlying etiology. There is an “obligate” trigger, meaning that each time the specific trigger occurs, the dizziness follows. Common triggers are changes in head position or body posture, especially arising from the lying or seated position to standing. Vomiting can occur and may lead patients to overestimate episode duration. Clinicians must distinguish triggers (provoke new symptoms not present at baseline) from exacerbating features (worsen preexisting baseline symptoms), since head movement will exacerbate acute vestibular dizziness of any cause. Common etiologies are BPPV and orthostatic hypotension. Dangerous causes include central (neurologic) mimics of BPPV and serious causes of orthostatic hypotension such as internal bleeding or sepsis with relative hypovolemia. Since the symptoms can be triggered, the physician should be able to re-create them at the bedside.

BPPV, the most common vestibular cause of dizziness with a lifetime prevalence of 2.4% and increasing incidence with age [68], results from mobile crystalline debris in one or more semicircular canals (“canaliths”). Classical symptoms are repetitive brief, triggered episodes of rotational vertigo lasting more than a few

Table 6.5 Positional nystagmus findings in triggered, episodic vestibular syndrome (t-EVS)

Positional tests in t-EVS	BPPV (posterior canal)	BPPV (horizontal canal)	Central
Dix-Hallpike test (diagnostic test)	Upbeat-torsional ^a 5–30 s No spontaneous reversal	None ^b	Variable direction (downbeat or horizontal; almost never upbeat) Variable duration (often >90 s) No spontaneous reversal
Supine roll test (diagnostic test)	None ^b	Pure horizontal ^c 30–90 s Spontaneous reversal typical	Variable direction (downbeat or horizontal; almost never upbeat) Variable duration (often >90 s) No spontaneous reversal

BPPV benign paroxysmal positional vertigo

^aThe nystagmus of posterior canal BPPV will have a prominent torsional component, and the 12 o'clock pole of the eye will beat toward the down-facing (tested) ear. Although the nystagmus will reverse on arising from the Dix-Hallpike position, there will be no spontaneous reversal

^bAlthough the Dix-Hallpike test is fairly specific to posterior canal BPPV and the supine roll test to horizontal canal BPPV, the maneuvers may sometimes stimulate the other canal. If so, the nystagmus direction will depend on the affected canal, not on the type of maneuver eliciting the nystagmus. The nystagmus may be considerably weaker and less evident than when using the “correct” maneuver

^cThe nystagmus of horizontal canal BPPV may beat toward the down-facing ear or away from it. The nystagmus will often crescendo and then slow down and reverse spontaneously even without moving the head. When the opposite side is tested, the nystagmus will usually beat in the opposite direction (e.g., if right-beating initially with the right ear down and then left-beating initially with the left ear down)

seconds and less than a minute [69, 70]; non-vertiginous symptoms are frequent [25]. The diagnosis is confirmed by reproducing symptoms using canal-specific positional testing maneuvers (Table 6.5) [70–72]. Since the offending canal(s) are generally not known in advance, a sequence of multiple diagnostic maneuvers is typically performed starting with the Dix-Hallpike maneuver because this tests the posterior canal, which is by far the most common involved [60]. A detailed recent review of these exam maneuvers includes instructive video clips [27]. Despite the fact that BPPV is quite common, a majority of emergency physicians report that they do not use the Dix-Hallpike (diagnostic) or Epley (therapeutic) maneuvers in practice [41]. Once the correct canal is identified by these maneuvers, bedside treatment with canal repositioning maneuvers can follow [70].

Rarely, central paroxysmal positional vertigo (CPPV) mimics BPPV. This is usually caused by posterior fossa lesions including neoplasm, infarction, hemorrhage, and demyelination. Factors that help to distinguish BPPV from CPPV are summarized in Table 6.6 [73].

Orthostatic hypotension affects 16% of adults [74] and accounts for 24% of acute syncopal presentations [75]. Classical symptoms are brief presyncope on arising, but vertigo is common [24]. Orthostatic hypotension is a sustained decline in blood pressure of at least 20 mmHg systolic or 10 mmHg diastolic within 3 min of standing [76]. Recent work suggests optimal cutoffs should be adjusted based on baseline blood pressure [77]. However, the orthostasis can be delayed (onset >10 min), and the duration of monitoring remains controversial [78–80].

Emergency physicians are familiar with the most common causes of acute orthostasis such as medications and hypovolemia. Strong bedside predictors of

Table 6.6 Characteristics of patients with t-EVS that suggest a central mimic (CPPV) rather than typical BPPV

1. Presence of symptoms or signs that are NOT seen in BPPV
(a) Headache
(b) Diplopia
(c) Abnormal cranial nerve or cerebellar function
2. Presence of nystagmus without dizziness
3. Atypical nystagmus characteristics
(a) Down-beating nystagmus ^a
(b) Nystagmus that beats in different directions on repeat testing
4. Poor response to therapeutic maneuvers
(a) Unable to cure patient with typical canalith repositioning maneuver
(b) Frequent recurrent symptoms

^aDown-beating nystagmus can be seen with anterior canal BPPV. However because BPPV of this canal is rare and because down-beating nystagmus is also seen with central causes, it is safer for emergency physicians to consider this finding to be *always* worrisome prompting imaging, consultation, and/or referral

moderate blood loss are postural dizziness so severe as to prevent standing or a postural pulse increment >30 beats per min, but the sensitivity of these findings is only 22% [81]. Furthermore, the benign postural orthostatic tachycardia syndrome (POTS) produces similar clinical findings [82]. The absence of tachycardia or even relative bradycardia can occur with intraperitoneal blood such as ruptured ectopic pregnancy [83].

BPPV produces dizziness upon arising in 58% [68], which can mimic orthostatic hypotension [84], and often goes undiagnosed in the elderly [25, 85]. Alternatively, orthostatic hypotension may be incidental and misleading, especially in older patients taking antihypertensive medications [86]. In patients with postural symptoms, BPPV and orthostatic hypotension can usually be differentiated by considering other positional triggers such as rolling over in bed or reclining, both of which are common in BPPV but should not occur with orthostatic hypotension.

BPPV notwithstanding, orthostatic dizziness and orthostatic hypotension are not always related [74, 87]. Orthostatic dizziness without systemic orthostatic hypotension has been reported with hemodynamic TIA due to vascular stenosis [88] and in patients with intracranial hypotension [89]. Neurological evaluation is probably indicated for patients with reproducible and sustained orthostatic dizziness but no demonstrable hypotension.

Spontaneous Episodic Vestibular Syndrome (s-EVS)

The s-EVS is marked by recurrent, spontaneous episodic dizziness that ranges in duration from seconds to days but usually lasts minutes to hours. Most patients are therefore asymptomatic at the time of clinical assessment, and if they are, one cannot provoke an episode at the bedside (because it is not “triggerable”), so the

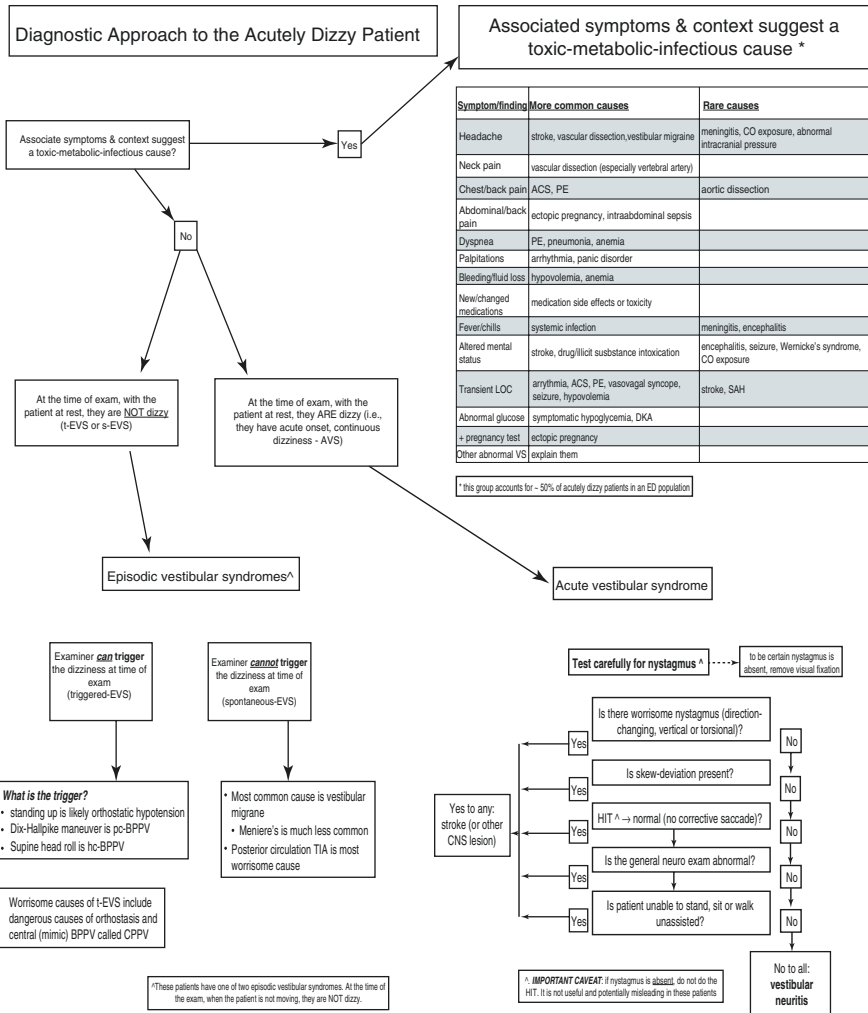
evaluation relies almost entirely on history. The most common benign cause is vestibular migraine [90–92] followed by Ménière's disease [91]. The most common dangerous cause is vertebrobasilar TIA [93]. Other causes of the s-EVS include reflex (e.g., vasovagal) syncope [94] and panic attacks [95]. Uncommon dangerous causes of s-EVS are cardiovascular (cardiac arrhythmia, unstable angina pectoris, pulmonary embolus), endocrine (hypoglycemia, neurohumoral neoplasms), or toxic (intermittent carbon monoxide exposure). Diagnosis is not difficult when cases are typical. Unfortunately, classical features such as frank loss of consciousness in reflex syncope [96], headache in vestibular migraine [97], and fear in panic attacks [98] are frequently absent. Atypical case presentations probably contribute to diagnostic confusion in patients with transient neurological attacks [99].

Definite vestibular migraine diagnosis requires recurrent attacks with vestibular symptoms, a history of migraine according to the International Classification of Headache Disorders, and migraine symptoms during at least half of the attacks [91]. Attack duration in vestibular migraine ranges from seconds to days [91]. Headache is often absent with the attack; when headache does occur, it may begin before, during, or after the dizziness and may differ from the patient's other "typical" migraine headaches [91, 100]. Nausea, vomiting, photophobia, phonophobia, and visual auras may accompany vestibular migraine. Hearing loss or tinnitus sometimes occurs [101], creating some overlap between vestibular migraine and Ménière's disease [102]. If present, nystagmus can be of a peripheral, central, or mixed type [100]. The diagnosis is normally made based purely on clinical history and the exclusion of alternative causes [91].

Patients with Ménière's disease classically present with episodic vertigo accompanied by unilateral tinnitus and aural fullness, often with reversible sensorineural hearing loss. Episodes typically last minutes to hours. Only one in four initially present with the complete symptom triad [103], and non-vertiginous dizziness is common [104]. Definite Ménière's disease requires at least two spontaneous episodes of vertigo lasting at least 20 min, audiometrically documented hearing loss (at least once, whether transient or persistent), and tinnitus or aural fullness in the affected ear, with other causes excluded [91].

Reflex syncope (also called neurocardiogenic or neurally mediated syncope) includes vasovagal syncope, carotid sinus hypersensitivity, and situational syncope (e.g., micturition, defecation, cough) [105]. Those who faint usually experience prodromal symptoms; presyncopal spells without loss of consciousness substantially outnumber spells with syncope [94]. Dizziness is the most common presyncopal symptom, and it may be of any type, including vertigo [106]. Presyncopal symptoms usually last 3–30 min [107]. Diagnosis is based on clinical history, excluding dangerous mimics (especially arrhythmia), and can be confirmed by formal head-up tilt table testing [82].

The principal dangerous diagnosis for s-EVS is TIA [93]. Although for years isolated vertigo was considered to not be due to TIA, recent evidence strongly suggests that TIA can present with dizziness, even isolated attacks of vertigo [108]. TIAs can present with isolated episodes of dizziness weeks to months or even years



prior to a completed infarction [109, 110]. Dizziness is the most common symptom in basilar artery occlusion [111] and occurs without other neurological symptoms in 20% of cases [112]. Dizziness is the most common presenting symptom of vertebral artery dissection [113], which affects younger patients, mimics migraine, and is easily misdiagnosed [5]. Because 5% of TIA patients suffer a stroke within 48 h, prompt diagnosis is critical [114]. Patients with posterior circulation TIA may have an even higher stroke risk than those with anterior circulation spells [115, 116]. Rapid treatment lowers stroke risk after TIA by about 80% [117, 118].

Cardiac arrhythmias should also be considered in any patient with spontaneous EVS, particularly when syncope occurs [24]. Although some clinical features may increase or decrease the odds of a cardiac cause [105], additional testing (e.g., cardiac loop recording) is often required to confirm the final diagnosis [82].

Putting It All Together: An Overarching Algorithm

Taking a history of a dizzy patient should be no different than taking a history in nearly any other patient. The timing, triggers of the dizziness (and not the descriptor used), as well as the evolution of the symptoms, associated symptoms, and epidemiologic context inform the differential diagnosis. Besides, physical examination can frequently establish a specific diagnosis. This newer paradigm (see Figure) has not yet been validated in large numbers of ED patients treated by emergency physicians, but current evidence and experience suggest that this is possible.

Conclusions

Dizziness, vertigo, and unsteadiness are extremely common complaints caused by numerous diseases that span organ systems. Diagnosis can therefore be difficult, a fact leading to overutilization of resources and misdiagnosis. The current paradigm used by most physicians is based on symptom quality, a paradigm created 40 years ago; a newer paradigm, based on timing and triggers, is more consistent with current evidence. History and physical examination is more accurate, more efficient, and more likely to result in a specific diagnosis than the traditional paradigm.

Pearls and Pitfalls

- The timing and triggers of a patient's dizziness are *much* more important than the word that a patient uses to describe their dizziness (e.g., "vertigo" versus "light-headed" versus "imbalance").
- In patients with an acute vestibular syndrome (nausea or vomiting, gait instability, nystagmus, and head-motion intolerance that lasts days or weeks and gradually improving), physical examination allows better distinction between vestibular neuritis and stroke (the two most common causes) than MRI during the first 2 days of illness.
- Patients with BPPV can be diagnosed and treated using bedside maneuvers (Dix-Hallpike and Epley maneuvers) without the need for imaging or consultation.

References

1. Cheung CS, Mak PS, Manley KV, et al. Predictors of important neurological causes of dizziness among patients presenting to the emergency department. *EMJ*. 2010;27:517–21.
2. Newman-Toker DE, Hsieh YH, Camargo CA Jr, Pelletier AJ, Butchy GT, Edlow JA. Spectrum of dizziness visits to US emergency departments: cross-sectional analysis from a nationally representative sample. *Mayo Clin Proc*. 2008;83:765–75.
3. Saber Tehrani AS, Coughlan D, Hsieh YH, et al. Rising annual costs of dizziness presentations to U.S. emergency departments. *Acad Emerg Med*. 2013;20:689–96.

4. Improving diagnosis in health care. Washington, DC: National Academies Press; 2015.
5. Savitz SI, Caplan LR, Edlow JA. Pitfalls in the diagnosis of cerebellar infarction. *Acad Emerg Med.* 2007;14:63–8.
6. Newman-Toker DE, Edlow JA. TiTrATE: a novel, evidence-based approach to diagnosing acute dizziness and vertigo. *Neurol Clin.* 2015;33:577–99, viii.
7. Newman-Toker DE, Camargo CA Jr, Hsieh YH, Pelletier AJ, Edlow JA. Disconnect between charted vestibular diagnoses and emergency department management decisions: a cross-sectional analysis from a nationally representative sample. *Acad Emerg Med.* 2009;16:970–7.
8. Cooper H, Bhattacharya B, Verma V, McCulloch AJ, Smellie WS, Heald AH. Liquorice and soy sauce, a life-saving concoction in a patient with Addison's disease. *Ann Clin Biochem.* 2007;44:397–9.
9. Demiryoguran NS, Karcioğlu O, Topacoglu H, Aksakalli S. Painless aortic dissection with bilateral carotid involvement presenting with vertigo as the chief complaint. *Emerg Med J.* 2006;23:e15.
10. Heckerling PS, Leikin JB, Maturen A, Perkins JT. Predictors of occult carbon monoxide poisoning in patients with headache and dizziness. *Ann Intern Med.* 1987;107:174–6.
11. Wolfe TR, Allen TL. Syncope as an emergency department presentation of pulmonary embolism. *J Emerg Med.* 1998;16:27–31.
12. Choi KD, Oh SY, Kim HJ, Kim JS. The vestibulo-ocular reflexes during head impulse in Wernicke's encephalopathy. *J Neurol Neurosurg Psychiatry.* 2007;78:1161–2.
13. Herr RD, Zun L, Mathews JJ. A directed approach to the dizzy patient. *Ann Emerg Med.* 1989;18:664–72.
14. Royl G, Ploner CJ, Leithner C. Dizziness in the emergency room: diagnoses and misdiagnoses. *Eur Neurol.* 2011;66:256–63.
15. Navi BB, Kamel H, Shah MP, et al. Rate and predictors of serious neurologic causes of dizziness in the emergency department. *Mayo Clin Proc.* 2012;87:1080–8.
16. Chase M, Joyce NR, Carney E, et al. ED patients with vertigo: can we identify clinical factors associated with acute stroke? *Am J Emerg Med.* 2012;30:587–91.
17. Moubayed SP, Saliba I. Vertebrobasilar insufficiency presenting as isolated positional vertigo or dizziness: a double-blind retrospective cohort study. *Laryngoscope.* 2009;119:2071–6.
18. Navi BB, Kamel H, Shah MP, et al. Application of the ABCD2 score to identify cerebrovascular causes of dizziness in the emergency department. *Stroke.* 2012;43:1484–9.
19. Kerber KA, Meurer WJ, Brown DL, et al. Stroke risk stratification in acute dizziness presentations: a prospective imaging-based study. *Neurology.* 2015;85(21):1869–78.
20. Drachman DA, Hart CW. An approach to the dizzy patient. *Neurology.* 1972;22:323–34.
21. Edlow JA. Diagnosing dizziness: we are teaching the wrong paradigm! *Acad Emerg Med.* 2013;20:1064–6.
22. Newman-Toker DE, Cannon LM, Stofferahn ME, Rothman RE, Hsieh YH, Zee DS. Imprecision in patient reports of dizziness symptom quality: a cross-sectional study conducted in an acute care setting. *Mayo Clin Proc.* 2007;82:1329–40.
23. Kerber KA, Brown DL, Lisabeth LD, Smith MA, Morgenstern LB. Stroke among patients with dizziness, vertigo, and imbalance in the emergency department: a population-based study. *Stroke.* 2006;37:2484–7.
24. Newman-Toker DE, Dy FJ, Stanton VA, Zee DS, Calkins H, Robinson KA. How often is dizziness from primary cardiovascular disease true vertigo? A systematic review. *J Gen Intern Med.* 2008;23:2087–94.
25. Lawson J, Bamiou DE, Cohen HS, Newton J. Positional vertigo in a falls service. *Age Ageing.* 2008;37:585–9.
26. Kerber KA, Morgenstern LB, Meurer WJ, et al. Nystagmus assessments documented by emergency physicians in acute dizziness presentations: a target for decision support? *Acad Emerg Med.* 2011;18:619–26.
27. Edlow J, Newman-Toker D. Using the physical examination to diagnose patients with acute dizziness and vertigo. *J Emerg Med.* 2016;50(4):617–28.

28. Braun EM, Tomazic PV, Ropposch T, Nemetz U, Lackner A, Walch C. Misdiagnosis of acute peripheral vestibulopathy in central nervous ischemic infarction. *Otol Neurotol*. 2011;32:1518–21.
29. Casani AP, Dallan I, Cerchiai N, Lenzi R, Cosottini M, Sellari-Franceschini S. Cerebellar infarctions mimicking acute peripheral vertigo: how to avoid misdiagnosis? *Otolaryngol Head Neck Surg*. 2013;148:475–81.
30. Lee H, Sohn SI, Cho YW, et al. Cerebellar infarction presenting isolated vertigo: frequency and vascular topographical patterns. *Neurology*. 2006;67:1178–83.
31. Martin-Schild S, Albright KC, Tanksley J, et al. Zero on the NIHSS does not equal the absence of stroke. *Ann Emerg Med*. 2011;57:42–5.
32. Masuda Y, Tei H, Shimizu S, Uchiyama S. Factors associated with the misdiagnosis of cerebellar infarction. *J Stroke Cerebrovasc Dis*. 2013;22:1125–30.
33. Honda S, Inatomi Y, Yonehara T, et al. Discrimination of acute ischemic stroke from non-ischemic vertigo in patients presenting with only imbalance. *J Stroke Cerebrovasc Dis*. 2014;23:888–95.
34. Kuruvilla A, Bhattacharya P, Rajamani K, Chaturvedi S. Factors associated with misdiagnosis of acute stroke in young adults. *J Stroke Cerebrovasc Dis*. 2011;20:523–7.
35. Nakajima M, Hirano T, Uchino M. Patients with acute stroke admitted on the second visit. *J Stroke Cerebrovasc Dis*. 2008;17:382–7.
36. Atzema CL, Grewal K, Lu H, Kapral MK, Kulkarni G, Austin PC. Outcomes among patients discharged from the emergency department with a diagnosis of peripheral vertigo. *Ann Neurol*. 2016;79(1):32–41.
37. Kerber KA, Zahuranec DB, Brown DL, et al. Stroke risk after nonstroke emergency department dizziness presentations: a population-based cohort study. *Ann Neurol*. 2014;75:899–907.
38. Kim AS, Fullerton HJ, Johnston SC. Risk of vascular events in emergency department patients discharged home with diagnosis of dizziness or vertigo. *Ann Emerg Med*. 2011;57:34–41.
39. Kerber KA, Newman-Toker DE. Misdiagnosing dizzy patients: common pitfalls in clinical practice. *Neurol Clin*. 2015;33:565–75, viii.
40. Grewal K, Austin PC, Kapral MK, Lu H, Atzema CL. Missed strokes using computed tomography imaging in patients with vertigo: population-based cohort study. *Stroke*. 2015;46:108–13.
41. Kene MV, Ballard DW, Vinson DR, Rauchwerger AS, Iskin HR, Kim AS. Emergency physician attitudes, preferences, and risk tolerance for stroke as a potential cause of dizziness symptoms. *West J Emerg Med*. 2015;16:768–76.
42. Tarnutzer AA, Berkowitz AL, Robinson KA, Hsieh YH, Newman-Toker DE. Acute vestibular syndrome: does my patient have a stroke? A systematic and critical review of bedside diagnostic predictors. *Can Med Assoc J*. 2011;183(9):E571–92.
43. Edlow JA, Newman-Toker DE. Medical and nonstroke neurologic causes of acute, continuous vestibular symptoms. *Neurol Clin*. 2015;33:699–716, xi.
44. Pula JH, Newman-Toker DE, Kattah JC. Multiple sclerosis as a cause of the acute vestibular syndrome. *J Neurol*. 2013;260:1649–54.
45. Kerber KA, Burke JF, Brown DL, et al. Does intracerebral haemorrhage mimic benign dizziness presentations? A population based study. *Emerg Med J*. 2011;29(1):43–6.
46. Stanton VA, Hsieh YH, Camargo CA Jr, et al. Overreliance on symptom quality in diagnosing dizziness: results of a multicenter survey of emergency physicians. *Mayo Clin Proc*. 2007;82:1319–28.
47. Cutfield NJ, Seemungal BM, Millington H, Bronstein AM. Diagnosis of acute vertigo in the emergency department. *Emerg Med J*. 2011;28(6):538–9.
48. Arbusow V, Theil D, Strupp M, Mascolo A, Brandt T. HSV-1 not only in human vestibular ganglia but also in the vestibular labyrinth. *Audiol Neurootol*. 2001;6:259–62.
49. Strupp M, Jager L, Muller-Lisse U, Arbusow V, Reiser M, Brandt T. High resolution Gd-DTPA MR imaging of the inner ear in 60 patients with idiopathic vestibular neuritis: no evidence for contrast enhancement of the labyrinth or vestibular nerve. *J Vestib Res*. 1998;8:427–33.
50. Lu YC, Young YH. Vertigo from herpes zoster oticus: superior or inferior vestibular nerve origin? *Laryngoscope*. 2003;113:307–11.

51. Baloh RW. Clinical practice. Vestibular neuritis. *N Engl J Med*. 2003;348:1027–32.
52. Chalela JA, Kidwell CS, Nentwich LM, et al. Magnetic resonance imaging and computed tomography in emergency assessment of patients with suspected acute stroke: a prospective comparison. *Lancet*. 2007;369:293–8.
53. Hwang DY, Silva GS, Furie KL, Greer DM. Comparative sensitivity of computed tomography vs. magnetic resonance imaging for detecting acute posterior fossa infarct. *J Emerg Med*. 2012;42:559–65.
54. Simmons Z, Biller J, Adams HP Jr, Dunn V, Jacoby CG. Cerebellar infarction: comparison of computed tomography and magnetic resonance imaging. *Ann Neurol*. 1986;19:291–3.
55. Kattah JC, Talkad AV, Wang DZ, Hsieh YH, Newman-Toker DE. HINTS to diagnose stroke in the acute vestibular syndrome: three-step bedside oculomotor examination more sensitive than early MRI diffusion-weighted imaging. *Stroke*. 2009;40:3504–10.
56. Saber Tehrani AS, Kattah JC, Mantokoudis G, et al. Small strokes causing severe vertigo: frequency of false-negative MRIs and nonlacunar mechanisms. *Neurology*. 2014;83:169–73.
57. Chen L, Lee W, Chambers BR, Dewey HM. Diagnostic accuracy of acute vestibular syndrome at the bedside in a stroke unit. *J Neurol*. 2011;258(5):855–61.
58. Vanni S, Nazerian P, Casati C, et al. Can emergency physicians accurately and reliably assess acute vertigo in the emergency department? *Emerg Med Australas*. 2015;27:126–31.
59. Vanni S, Pecci R, Casati C, et al. STANDING, a four-step bedside algorithm for differential diagnosis of acute vertigo in the emergency department. *Acta Otorhinolaryngol Ital*. 2014;34:419–26.
60. Welgampola MS, Bradshaw AP, Lechner C, Halmagyi GM. Bedside assessment of acute dizziness and vertigo. *Neurol Clin*. 2015;33:551–64, vii.
61. Halmagyi GM, Curthoys IS. A clinical sign of canal paresis. *Arch Neurol*. 1988;45:737–9.
62. Newman-Toker DE, Kattah JC, Alvernia JE, Wang DZ. Normal head impulse test differentiates acute cerebellar strokes from vestibular neuritis. *Neurology*. 2008;70:2378–85.
63. Newman-Toker DE, Kerber KA, Hsieh YH, et al. HINTS outperforms ABCD2 to screen for stroke in acute continuous vertigo and dizziness. *Acad Emerg Med*. 2013;20:986–96.
64. Lee H. Neuro-otological aspects of cerebellar stroke syndrome. *J Clin Neurol*. 2009;5:65–73.
65. Lee H, Kim JS, Chung EJ, et al. Infarction in the territory of anterior inferior cerebellar artery: spectrum of audiovestibular loss. *Stroke*. 2009;40:3745–51.
66. Lee SH, Kim JS. Acute diagnosis and management of stroke presenting dizziness or vertigo. *Neurol Clin*. 2015;33:687–98, xi.
67. Kim JS. Pure lateral medullary infarction: clinical-radiological correlation of 130 acute, consecutive patients. *Brain*. 2003;126:1864–72.
68. von Brevern M, Radtke A, Lezius F, et al. Epidemiology of benign paroxysmal positional vertigo: a population based study. *J Neurol Neurosurg Psychiatry*. 2007;78:710–5.
69. Baloh RW, Honrubia V, Jacobson K. Benign positional vertigo: clinical and oculographic features in 240 cases. *Neurology*. 1987;37:371–8.
70. Fife TD, von Brevern M. Benign paroxysmal positional vertigo in the acute care setting. *Neurol Clin*. 2015;33:601–17, viii–ix.
71. Bhattacharyya N, Baugh RF, Orvidas L, et al. Clinical practice guideline: benign paroxysmal positional vertigo. *Otolaryngol Head Neck Surg*. 2008;139:S47–81.
72. Fife TD, Iverson DJ, Lempert T, et al. Practice parameter: therapies for benign paroxysmal positional vertigo (an evidence-based review): report of the quality standards subcommittee of the American Academy of Neurology. *Neurology*. 2008;70:2067–74.
73. Soto-Varela A, Rossi-Izquierdo M, Sanchez-Sellero I, Santos-Perez S. Revised criteria for suspicion of non-benign positional vertigo. *QJM*. 2013;106:317–21.
74. Wu JS, Yang YC, Lu FH, Wu CH, Chang CJ. Population-based study on the prevalence and correlates of orthostatic hypotension/hypertension and orthostatic dizziness. *Hypertens Res*. 2008;31:897–904.
75. Sarasin FP, Louis-Simonet M, Carballo D, Slama S, Junod AF, Unger PF. Prevalence of orthostatic hypotension among patients presenting with syncope in the ED. *Am J Emerg Med*. 2002;20:497–501.

76. Freeman R, Wieling W, Axelrod FB, et al. Consensus statement on the definition of orthostatic hypotension, neurally mediated syncope and the postural tachycardia syndrome. *Clin Auton Res.* 2011;21:69–72.
77. Fedorowski A, Burri P, Melander O. Orthostatic hypotension in genetically related hypertensive and normotensive individuals. *J Hypertens.* 2009;27:976–82.
78. Cheshire WP Jr, Phillips LH 2nd. Delayed orthostatic hypotension: is it worth the wait? *Neurology.* 2006;67:8–9.
79. Cohen E, Grossman E, Sapoznikov B, Sulkes J, Kagan I, Garty M. Assessment of orthostatic hypotension in the emergency room. *Blood Press.* 2006;15:263–7.
80. Gibbons CH, Freeman R. Delayed orthostatic hypotension: a frequent cause of orthostatic intolerance. *Neurology.* 2006;67:28–32.
81. McGee S, Abernethy WB 3rd, Simel DL. The rational clinical examination. Is this patient hypovolemic? *JAMA.* 1999;281:1022–9.
82. Moya A, Sutton R, Ammirati F, et al. Guidelines for the diagnosis and management of syncope (version 2009). *Eur Heart J.* 2009;30:2631–71.
83. Birkhahn RH, Gaeta TJ, Van Deusen SK, Tloczkowski J. The ability of traditional vital signs and shock index to identify ruptured ectopic pregnancy. *Am J Obstet Gynecol.* 2003;189:1293–6.
84. Lawson J, Johnson I, Bamioi DE, Newton JL. Benign paroxysmal positional vertigo: clinical characteristics of dizzy patients referred to a falls and syncope unit. *QJM.* 2005;98:357–64.
85. Oghalai JS, Manolidis S, Barth JL, Stewart MG, Jenkins HA. Unrecognized benign paroxysmal positional vertigo in elderly patients. *Otolaryngol Head Neck Surg.* 2000;122:630–4.
86. Poon IO, Braun U. High prevalence of orthostatic hypotension and its correlation with potentially causative medications among elderly veterans. *J Clin Pharm Ther.* 2005;30:173–8.
87. Radtke A, Lempert T, von Brevern M, Feldmann M, Lezius F, Neuhauser H. Prevalence and complications of orthostatic dizziness in the general population. *Clin Auton Res.* 2011;21(3):161–8.
88. Stark RJ, Wodak J. Primary orthostatic cerebral ischaemia. *J Neurol Neurosurg Psychiatry.* 1983;46:883–91.
89. Blank SC, Shakir RA, Bindoff LA, Bradey N. Spontaneous intracranial hypotension: clinical and magnetic resonance imaging characteristics. *Clin Neurol Neurosurg.* 1997;99:199–204.
90. Neuhauser HK, Radtke A, von Brevern M, et al. Migrainous vertigo: prevalence and impact on quality of life. *Neurology.* 2006;67:1028–33.
91. Seemungal B, Kaski D, Lopez-Escamez JA. Early diagnosis and management of acute vertigo from vestibular migraine and Meniere's disease. *Neurol Clin.* 2015;33:619–28, ix.
92. Strupp M, Versino M, Brandt T. Vestibular migraine. *Handb Clin Neurol.* 2010;97:755–71.
93. Blum CA, Kasner SE. Transient ischemic attacks presenting with dizziness or vertigo. *Neurol Clin.* 2015;33:629–42, ix.
94. Romme JJ, van Dijk N, Boer KR, et al. Influence of age and gender on the occurrence and presentation of reflex syncope. *Clin Auton Res.* 2008;18:127–33.
95. Kanner AM. Ictal panic and interictal panic attacks: diagnostic and therapeutic principles. *Neurol Clin.* 2011;29:163–75, ix.
96. Mathias CJ, Deguchi K, Schatz I. Observations on recurrent syncope and presyncope in 641 patients. *Lancet.* 2001;357:348–53.
97. Dieterich M, Brandt T. Episodic vertigo related to migraine (90 cases): vestibular migraine? *J Neurol.* 1999;246:883–92.
98. Chen J, Tsuchiya M, Kawakami N, Furukawa TA. Non-fearful vs. fearful panic attacks: a general population study from the National Comorbidity Survey. *J Affect Disord.* 2009;112:273–8.
99. Fonseca AC, Canhao P. Diagnostic difficulties in the classification of transient neurological attacks. *Eur J Neurol.* 2010;18(4):644–8.
100. Lempert T, Neuhauser H, Daroff RB. Vertigo as a symptom of migraine. *Ann NY Acad Sci.* 2009;1164:242–51.
101. Kayan A, Hood JD. Neuro-otological manifestations of migraine. *Brain.* 1984;107(Pt 4):1123–42.

102. Millen SJ, Schnurr CM, Schnurr BB. Vestibular migraine: perspectives of otology versus neurology. *Otol Neurotol*. 2011;32:330–7.
103. Mancini F, Catalani M, Carru M, Monti B. History of Meniere’s disease and its clinical presentation. *Otolaryngol Clin N Am*. 2002;35:565–80.
104. Faag C, Bergenius J, Forsberg C, Langius-Eklöf A. Symptoms experienced by patients with peripheral vestibular disorders: evaluation of the vertigo symptom scale for clinical application. *Clin Otolaryngol*. 2007;32:440–6.
105. van Dijk JG, Thijs RD, Benditt DG, Wieling W. A guide to disorders causing transient loss of consciousness: focus on syncope. *Nat Rev Neurol*. 2009;5:438–48.
106. Sloane PD, Linzer M, Pontinen M, Divine GW. Clinical significance of a dizziness history in medical patients with syncope. *Arch Intern Med*. 1991;151:1625–8.
107. Sheldon R, Hersi A, Ritchie D, Koshman ML, Rose S. Syncope and structural heart disease: historical criteria for vasovagal syncope and ventricular tachycardia. *J Cardiovasc Electrophysiol*. 2010;21:1358–64.
108. Paul NL, Simoni M, Rothwell PM, Oxford VS. Transient isolated brainstem symptoms preceding posterior circulation stroke: a population-based study. *Lancet Neurol*. 2013;12:65–71.
109. Gomez CR, Cruz-Flores S, Malkoff MD, Sauer CM, Burch CM. Isolated vertigo as a manifestation of vertebrobasilar ischemia. *Neurology*. 1996;47:94–7.
110. Grad A, Baloh RW. Vertigo of vascular origin. Clinical and electronystagmographic features in 84 cases. *Arch Neurol*. 1989;46:281–4.
111. von Campe G, Regli F, Bogousslavsky J. Heraldng manifestations of basilar artery occlusion with lethal or severe stroke. *J Neurol Neurosurg Psychiatry*. 2003;74:1621–6.
112. Fisher CM. Vertigo in cerebrovascular disease. *Arch Otolaryngol*. 1967;85:529–34.
113. Gottesman RF, Sharma P, Robinson KA, et al. Clinical characteristics of symptomatic vertebral artery dissection: a systematic review. *Neurologist*. 2012;18:245–54.
114. Shah KH, Kleckner K, Edlow JA. Short-term prognosis of stroke among patients diagnosed in the emergency department with a transient ischemic attack. *Ann Emerg Med*. 2008;51:316–23.
115. Flossmann E, Rothwell PM. Prognosis of vertebrobasilar transient ischaemic attack and minor stroke. *Brain*. 2003;126:1940–54.
116. Gulli G, Khan S, Markus HS. Vertebrobasilar stenosis predicts high early recurrent stroke risk in posterior circulation stroke and TIA. *Stroke*. 2009;40:2732–7.
117. Lavallee PC, Meseguer E, Abboud H, et al. A transient ischaemic attack clinic with round-the-clock access (SOS-TIA): feasibility and effects. *Lancet Neurol*. 2007;6:953–60.
118. Rothwell PM, Giles MF, Chandratheva A, et al. Effect of urgent treatment of transient ischaemic attack and minor stroke on early recurrent stroke (EXPRESS study): a prospective population-based sequential comparison. *Lancet*. 2007;370:1432–42.

David C. Lebowitz, Amninder Singh, and Amanda Webb

Acute Vision Loss

Case Presentation

A 57-year-old female with past medical history of atrial fibrillation, diabetes mellitus, hyperlipidemia, and hypertension presents to the emergency department for a brief episode of painless vision loss in her left eye shortly before arrival. She describes the vision loss as a curtain pulled over the eye with vision returning spontaneously minutes later. She denies trauma to the eye, headache, fever, history of migraines, or prior similar episodes.

Approach to Vision Loss

When approaching eye emergencies, it's important to have an algorithmic approach that depends on the patient's history. The differential diagnosis for vision loss is vast and can include ophthalmologic as well as neurologic etiologies. Using the patient's history and key physical exam findings will help point to a specific pathology. When a patient presents with vision loss, it's important to ascertain what their true perception is. Asking about blurry or cloudy vision, difficulty seeing far or near, and loss of certain areas of vision is important and can help cue you into their specific diagnosis. In addition, it's important to specify whether the visual loss is monocular or binocular which sometimes can be difficult for patients themselves to determine [1].

Physical exam should include a full ocular exam including assessment of pupillary size and response, searching for an afferent pupillary defect. Funduscopic exam

D.C. Lebowitz, M.D. (✉) • A. Singh, M.D., M.P.H. • A. Webb, M.D.
University of Central Florida College of Medicine, Orlando, FL, USA
e-mail: David.lebowitz@ucf.edu; Amninder.Singh@ucf.edu; Amanda.Webb@ucf.edu

should be attempted and dilating drops can be given for ease of exam, so long as there is not a contraindication, such as concern for acute angle-closure glaucoma. Visual acuity testing should be done with patients wearing their glasses, to test for corrected vision. Additionally, visual field testing by confrontation with assessment of each eye separately can reveal certain visual deficits and diagnoses [1].

The following will be a discussion on the various possibilities of vision loss organized by type of vision impairment: transient monocular vision loss, persistent monocular vision loss, persistent monocular or binocular vision loss, and binocular vision loss.

Transient Monocular Vision Loss

Amaurosis fugax is a painless, monocular loss of vision caused by hypoperfusion to the retina and optic nerve. This is described as transient with a return to baseline over seconds to minutes [2]. *Amaurosis fugax* is associated with carotid artery disease, hypercoagulable states, and illicit drug use [2, 3]. Emboli from either the common or internal carotid arteries embolize to the retinal circulation [1]. The visual deficits may include a gradual progression of symptoms such as scintillating scotomas, colors, or moving specs that can be visible even when the eye is closed. The funduscopic exam is nonspecific but may include findings of arteriovenous nicking, cotton wool spots, retinal hemorrhages, Hollenhorst plaques, and papilledema [2, 4].

Patients with presumed *amaurosis fugax* will require imaging to uncover the underlying etiology such as ischemic or embolic causes which, will be equivalent to a traditional stroke workup. Bilateral carotid doppler ultrasonography, magnetic resonance angiography (MRA), and/or computed tomography angiography of the head and neck can be performed. Echocardiogram should also be considered to look for sources of emboli [2]. For suspected ischemic and embolic causes, aspirin can be given [2]. Depending on your institutional protocol for stroke and TIA patients, patients should be admitted for this workup with ophthalmology and neurology consultation. Vascular surgery consultation should be done if the patient has carotid artery stenosis greater than 70% [2].

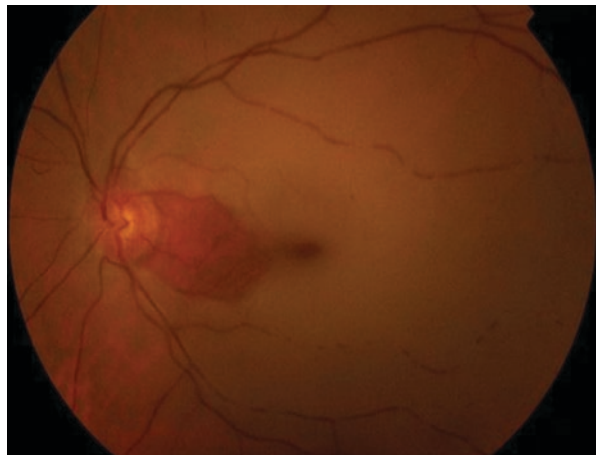
Increased intracranial pressure from idiopathic intracranial hypertension, hydrocephalus, cranial masses, or venous sinus thrombosis can also lead to papilledema and transient vision loss [1]. Funduscopic exam will show signs of papilledema with blurring of disc borders and elevated optic nerve heads. Papilledema is usually bilateral; however, there can be asymmetry leading to monocular vision changes. The vision changes may only last seconds and can be exacerbated by changes in postures. Visual acuity can be normal [1]. Due to the large differential, CT of the brain or preferably MRI, if available, should be performed. If imaging is negative, lumbar puncture should be considered to evaluate for idiopathic intracranial hypertension or infectious causes [1].

Persistent Monocular Vision Loss

Similar to amaurosis fugax, *central retinal artery occlusion (CRAO)* is described as a sudden, painless, monocular vision loss; however, CRAO is considered persistent vision loss. The vision loss can be complete or partial monocular vision loss depending on the severity of the occlusion and retinal branches involved [5]. Some patients may have experiences of amaurosis fugax as a precursor to CRAO [5]. Risk factors include hypercoagulable state, age > 70 years old, diabetes, hypertension, and high cholesterol [2, 5, 6]. The central retinal artery originates from the ophthalmic artery, which is a branch of the internal carotid artery [7]. The most common cause of CRAO is emboli from the carotid artery spreading to the central retinal artery [7]. These emboli can originate from carotid artery atherosclerosis or from cardiac sources [7]. Carotid artery dissection should be considered as a possible cause in patients with clinical features and risk factors [6]. Inflammatory causes such as temporal arteritis can also lead to CRAO especially in patients older than age 50 [7]. On physical exam, an afferent pupillary defect may be present [5, 7]. In addition, on funduscopic exam (Fig. 7.1) a cherry-red spot at the macula with retinal pallor due to retinal ischemia is classically present [5, 7]. Boxcarring in the retinal vessels is a finding that can also be seen [7].

CRAO is considered a stroke equivalent [6]. Therefore, management should be per your institutional protocol and can include magnetic resonance imaging (MRI) with diffusion-weighted imaging (DWI) of the brain to diagnose simultaneous cerebral stroke and magnetic resonance angiography (MRA) of the head and neck to assess for vascular emboli and occlusion [6]. A baseline electrocardiogram and echocardiogram evaluating cardiovascular risk factors should be performed [6]. ESR and CRP in patients older than 50 with signs of giant cell arteritis and hypercoagulability studies in younger patients are recommended [6].

Fig. 7.1 Funduscopy showing acute CRAO with *cherry-red* spot and boxcarring of the arterioles (From: Zairi I, Mzoughi K, Jnifene Z, et al. Ischemic cardiomyopathy revealed by central retinal artery occlusion (CRAO). *The Pan African Medical Journal*. 2015;22:250. doi:10.11604/pamj.2015.22.250.7308. With permission)



There are a variety of treatments that exist for CRAO. Treatment is time sensitive, preferably within the first 3 h of visual loss. After 12 h of symptoms, treatment is unlikely to have an impact [5, 6]. Medications to lower IOP have been used including intravenous mannitol and acetazolamide [6]. Carbogen (95% O₂, 5% CO₂) inhalation and hyperventilation into a brown bag theoretically work through retinal vasodilatation by increasing serum CO₂ concentration, but this is of questionable benefit [6]. In fact, there really are no strong evidence-based studies that support any specific treatment. Due to the underlying pathology of CRAO as a stroke-like equivalent, thrombolytics have been studied but are not recommended at this time [6, 7] Digital ocular massage can also be attempted to help dislodge the embolus and relieve ocular pressure [7]. It is performed by applying digital pressure for 10–20 min over the closed affected eye; however, this maneuver unfortunately has also not been proven to improve outcomes [6]. In general, these patients should be managed similarly to your stroke population with inpatient admission but with emergent neurology and ophthalmology consultation.

Central retinal vein occlusion (CRVO) is another common cause of painless, monocular visual loss. There are two types of CRVO: ischemic and nonischemic, related to the severity of clot buildup in the central vein [7]. Those with nonischemic CRVO usually experience mild visual loss affecting central vision and may be asymptomatic. Ischemic CRVO is characterized by a more pronounced vision loss and is associated with worse long-term visual acuity [7]. Risk factors for CRVO include glaucoma, hypertension, diabetes, and arteriosclerotic risk factors [9].

Funduscopy exam (Fig. 7.2) for CRVO classically reveals the “blood and thunder” appearance due to retinal hemorrhages. Exam may also contain dilated and tortuous retinal veins, optic disc edema, and cotton wool spots. Treatment from an emergency medicine standpoint is very limited, and our main role is to consider this diagnosis and consult ophthalmology for referral and guidance [7]. A full neurologic workup and inpatient admission are unnecessary in CRVO as the etiology is not from an embolic event [2].

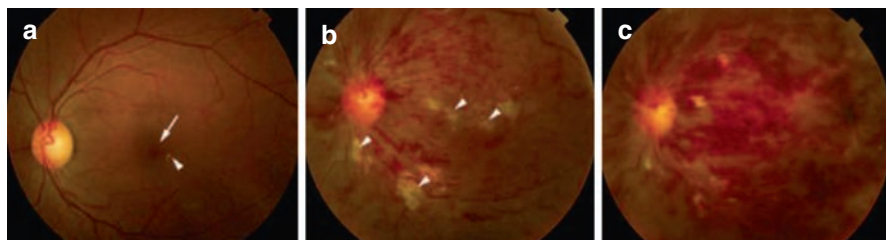

Fig. 7.2 Central retinal vein occlusion (CRVO) photographs of the fundus. (a) Before the onset of CRVO. Simple diabetic retinopathy indicated by a small retinal hemorrhage and hard exudates (*arrowhead*) was observed. The *arrow* shows the macular region. (b) CRVO. Retinal hemorrhage spread throughout the retina. Soft exudates (*arrowheads*), indicating retinal ischemia, were obvious. Edema could be seen in the macular region. (c) Recurrence of CRVO. The retinal hemorrhage and macular edema increased (From: Ozawa Y, Koto T, Shinoda H, Tsubota K. Vision Loss by Central Retinal Vein Occlusion After Kaatsu Training: A Case Report. Edoardo V, ed. *Medicine*. 2015;94(36):e1515. doi:10.1097/MD.0000000000001515. With permission)

Retinal detachment can cause monocular, painless vision changes. There are three subtypes of retinal detachment. Exudative retinal detachment is caused by hemorrhagic or serous fluid collecting in the subretinal space. Tractional retinal detachment results from fibrotic tissue causing traction on the retina [7]. This can be secondary to postoperative causes, infection, trauma, or inflammation. The most common type is rhegmatogenous retinal detachment, which is secondary to vitreous detachment posteriorly, causing tears in the retina, leading to fluid accumulating from the vitreous cavity into the subretinal space, which leads to retinal detachment. Posterior vitreous detachment is very common later in life, affecting as much as 63% of patients in their eighth decade, and approximately 11–15% of these patients develop retinal breaks [10].

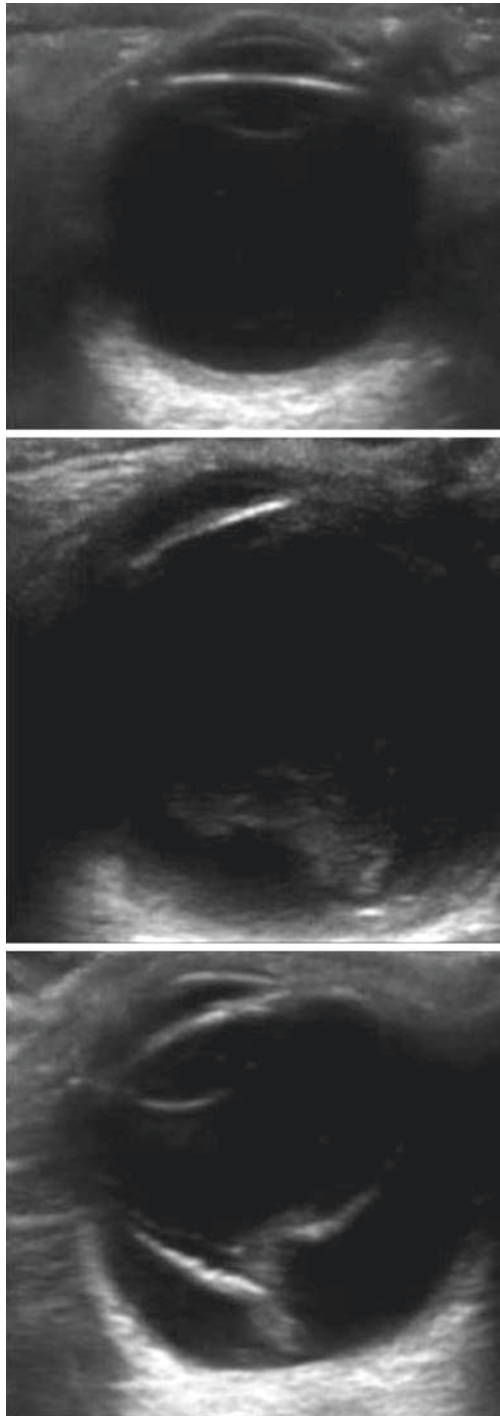
Clinical presentation of retinal detachment can include flashes of lights and floaters, and this is usually secondary to symptomatic posterior vitreous detachment. This can progress to the classic dark curtain over one's visual field usually starting out in the periphery but advancing into the central vision once the macula is involved [10, 11].

Approach to these patients should start by measuring visual acuity and performing visual field testing. An afferent pupillary defect may be seen when retinal detachment is severe. On funduscopic exam, a detached retina may be visualized, appearing pale and wrinkled, but unfortunately is not sensitive enough. A slit lamp exam can also be performed to assess for retinal tears and to also look for pigment granules which are associated with detachment. Point-of-care ultrasound (Fig. 7.3) by trained emergency physicians is of diagnostic utility with sensitivity for diagnosis of retinal detachment as high as 91–100% [12]. Ophthalmology should be consulted immediately for presumed retinal detachment as early intervention and/or surgery is associated with better visual outcome [11].

Acute angle-closure glaucoma can cause a painful monocular vision loss. The pathophysiology is related to obstruction of normal aqueous outflow leading to elevated intraocular pressure and ocular nerve injury [13]. This can occur on a sub-acute basis or acutely and suddenly. Patients with acute angle-closure glaucoma experience blurry vision that can be described as halos or rainbows around lights [13]. They usually experience periorbital and ocular pain [14]. Diagnosis can be tricky because sometime patients can also experience a frontal headache and nausea and vomiting, which can be mistaken for a migraine [5, 13]. Patients may also have abdominal pain associated with their symptoms [8]. Pupillary dilation from darkness can incite symptoms of glaucoma due to worsening aqueous humor obstruction, whereas a bright room or space can improve symptoms [13].

Examination findings (Fig. 7.4) include a sluggish or fixed mid-dilated pupil, conjunctival injection, and a hazy or cloudy cornea [8, 13]. A firm and tender globe and narrow anterior chamber angle can also be present [8]. The anterior chamber angle is considered narrow if a shadow appears on the nasal portion of the iris as opposed to illumination of the entire iris [8]. Intraocular pressure greater than 30 mmHg suggests this diagnosis [5]. Pressure greater than 70 mmHg can be seen although 40–50 mmHg is enough to cause rapid visual loss [8]. The goal for treatment is to reduce intraocular pressure with a return to visual baseline [8].

Fig. 7.3 Ocular ultrasound representing normal retina (*top*), vitreous hemorrhage (*middle*), and retinal detachment (*bottom*) (From: Jacobsen B, Lahham S, Lahham S, Patel A, Spann S, Fox JC. Retrospective Review of Ocular Point-of-Care Ultrasound for Detection of Retinal Detachment. *Western Journal of Emergency Medicine*. 2016;17(2):196–200. doi:[10.5811/westjem.2015.12.28711](https://doi.org/10.5811/westjem.2015.12.28711). With permission)



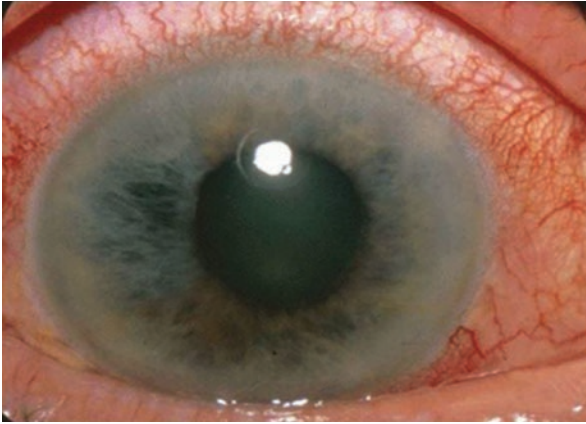


Fig. 7.4 Acute angle-closure glaucoma: note cloudy/“steamy” cornea and mid-position, fixed pupil (Image courtesy of Jonathan Trove, MD, Wikimedia Creative Common post-content. From: Gilani CJ, Yang A, Yonkers M, Boysen-Osborn M. Differentiating Urgent and Emergent Causes of Acute Red Eye for the Emergency Physician. *Western Journal of Emergency Medicine*. 2017;18(3):509–517. doi:[10.5811/westjem.2016.12.31798](https://doi.org/10.5811/westjem.2016.12.31798). With permission)

One drop each of topical timolol 0.5%, apraclonidine 1%, and pilocarpine 2% each given 1 min apart and repeated up to three times every 5 min is recommended to help reduce the intraocular pressure [5, 8]. Acetazolamide 500 mg IV or PO can also be given, but it is contraindicated in sulfa-allergic patients [5, 8]. IV mannitol can also be considered as a treatment modality [8]. Definitively, laser iridotomy by an ophthalmologist is the preferred surgical treatment [14].

Persistent Monocular or Binocular Vision Loss

Optic neuritis causes a subacute vision loss predominately in younger people, and it is triggered by inflammation of the optic nerve. Optic neuritis frequently involves only one eye; however, there are cases of binocular vision loss [15]. Optic neuritis is associated with demyelinating lesions and multiple sclerosis; however, it can be related to many other systemic and autoimmune diseases as well [16]. Patients will typically present with a complaint of blurry vision which can be acute or gradual. They may describe difficulty distinguishing colors, and more than 90% experience periorbital pain and pain with eye movement [16, 17]. Symptoms usually last 2–3 weeks and most recover spontaneously, even without medications [17]. On exam, an afferent pupillary defect is commonly present. Visual field loss is frequently present as well [15]. Two thirds of patients on exam will display a normal optic disc which indicates a retrobulbar optic neuritis. Optic disc swelling from papillitis is present in some patients but is usually mild, without any hemorrhage, cotton wool spots, or retinal exudate and deposits [15]. An MRI should be obtained in patients with presumed optic neuritis within 2 weeks of start of symptoms.

Treatment for optic neuritis includes intravenous methylprednisolone 1 g daily for 3 days plus oral prednisone daily [15]. Treatment decisions should be made in consultation with neurology.

Ischemic optic neuropathy is another cause of sudden onset, painless vision loss. Its etiology is due to decreased optic nerve perfusion and frequently occurs in elderly patients with vascular risk factors. Ischemic optic neuropathy can be divided by anterior and posterior optic nerve involvement [18]. Anterior ischemic optic neuropathy is related to intermittent hypotension and dysregulation of optic nerve perfusion and is usually from idiopathic causes. Anterior ischemic optic neuropathy can also be divided into nonarteritic and arteritic causes [18]. Arteritic anterior ischemic optic neuropathy is associated with giant cell arteritis due to inflammation of the blood vessel supply leading to obstruction of blood flow to the optic nerve [2, 18]. Posterior ischemic optic neuropathy is related to hypoperfusion associated with surgery from hypotension, anemia, and positioning while in the operating room [2].

Symptoms of ischemic optic neuropathy include an acute, painless loss of vision usually monocular; however, in posterior neuropathy binocular involvement may occur. Visual field deficits and diminished color vision can be involved as well. Patients with giant cell arteritis will usually have other symptomatology such as headache, jaw claudication, and/or proximal hip and shoulder stiffness and aches. Exam may reveal an afferent pupillary defect and visual field deficits. On fundoscopic exam, there can be papilledema with hemorrhages especially in anterior ischemic optic neuropathy [2]. Whereas patients with giant cell arteritis may have optic disc pallor.

Workup should include ruling out giant cell arteritis based on history and physical and by obtaining an ESR and C-reactive protein. Temporal artery biopsy is the gold standard definitive test for giant cell arteritis [18]. As there can be some overlap between ischemic optic neuropathy and optic neuritis, an MRI with gadolinium can be obtained to distinguish between the two, especially in younger patients. Otherwise, workup is limited in the emergency department and ophthalmology should be consulted early.

Binocular Visual Loss

An insult to the *optic chiasm* can lead to a bitemporal hemianopia. Central vision is spared and the visual deficit can be mild. A pituitary adenoma is a common cause of optic chiasm impingement leading to vision changes. Patients can exhibit endocrine symptoms such as galactorrhea [1]. Pituitary apoplexy can cause sudden symptoms due to hemorrhage or infarction of a pituitary adenoma and is usually associated with headache, facial pain, and facial numbness [19]. This occurs acutely and can lead to altered mental status and can enlarge into the cavernous sinus causing impairment of cranial nerve three, four, and six [1]. Meningiomas, craniopharyngiomas, optic gliomas, as well as several other neoplasms can also impinge the optic chiasm and cause visual deficits. Patients with

optic chiasm involvement may experience decreased peripheral vision, loss of depth perception, or double vision. MRI is the preferred diagnostic modality, but CT scan can be performed initially [19]. Intracranial aneurysms in the suprasellar region can also impinge on the optic chiasm and lead to visual field deficits. Patients usually exhibit other symptoms such as a headache, seizure, and decreased responsiveness, and on exam they can display neurologic deficits, especially if they have an aneurysmal rupture. Concern for aneurysm should be worked up with CTA or MRA of the brain.

Migraine auras are the most common cause of a transient binocular visual loss causing scotomas in the visual field and sometimes a complete homonymous hemianopia. Patients that experience binocular vision loss even transiently should be considered for a *transient ischemic attack (TIA)*. Differentiating a TIA-provoked vision loss from a migraine can be difficult. Migraines are usually sudden onset and have a predictable headache, whereas TIAs are sudden onset and do not always coexist with a headache, plus there can be other neurologic deficits [20]. The origin of a TIA that causes binocular visual loss could be from the distribution of the basilar artery or the posterior cerebral arteries.

Lesions that are retrochiasmal can lead to a bilateral vision loss displayed as a homonymous hemianopia. These lesions can involve the optic tract, lateral geniculate nucleus, optic radiations, or occipital cortex. Lesions can be secondary to tumors, cerebrovascular accidents, and arteriovenous malformations [21]. An isolated homonymous hemianopia most commonly originates from a lesion of the occipital lobe, which is usually secondary to cerebrovascular disease [1]. This can be evaluated with a CT and/or MRI brain depending on etiology.

Posterior reversible encephalopathy syndrome (PRES) can manifest as binocular, sometimes complete vision loss in patients. They typically will also present with hypertension, headache, seizures, and decreased responsiveness [1]. In order of clinical frequency, PRES etiologies include HTN (61%), cytotoxic medications (19%), preeclampsia or eclampsia (6%), and autoimmune and systemic conditions, including sepsis [22]. MRI is diagnostic of this rare syndrome. The mechanism is thought to be a neurotoxic state that occurs secondary to the inability of the [posterior circulation](#) to autoregulate in response to acute changes in blood pressure. The resultant hyperperfusion disrupts the [blood-brain barrier](#) causing vasogenic edema, but not infarction initially, most commonly in the parieto-occipital regions (which is why vision is often affected). The treatment of the underlying cause is typically sufficient to reverse this condition; however, delay to treatment can lead to irreversible brain infarction [22].

Cerebral blindness is described as a complete loss of all vision. This is characterized by loss of perception to light and dark and loss of reflexive lid close in response to bright light or threats to the eye. Patients will still exhibit normal pupillary response and normal extraocular movements, with a normal ocular exam. Cerebral blindness is commonly caused by a cerebrovascular accident involving the posterior cerebral arteries leading to ischemia to the occipital lobes. Other possible causes include cerebral masses, persistent hypotension, and infection (Table 7.1).

Table 7.1 Vision loss summary

Type of vision impairment	Diagnosis	Key characteristics	Exam findings	Diagnostic studies
Transient monocular vision loss	Amaurosis fugax	Painless, associated with vascular disease	Nonspecific funduscopic exam	CVA evaluation CT/CTA and/or MRI/MRA brain/neck +/- Bilateral carotid Doppler, echocardiogram
	Increased ICP	Vision loss can be exacerbated by change in posture Differential: idiopathic intracranial hypertension, hydrocephalus, cranial masses, or venous sinus thrombosis	Papilledema	CT/MRI brain +/- LP
Persistent monocular vision loss	Central retinal artery occlusion (CRAO)	Sudden, painless, associated with vascular disease	+/- Afferent pupillary defect Funduscopic exam: cherry-red spot at the macula +/- Boxcarring	
		Painless Associated with vascular disease	Funduscopic exam: retinal hemorrhages—“blood and thunder” appearance	CVA evaluation CT/CTA and/or MRI/MRA brain/neck +/- Bilateral carotid Doppler, echocardiogram
	Retinal detachment	Painless, flashes of lights/floaters, dark curtain over visual field	+/- Afferent pupillary defect Funduscopic exam: detached pale/wrinkled retina	+/- Bedside orbital US
	Acute angle-closure glaucoma	Painful, blurry vision described as halos and rainbows around light, nausea/vomiting, headache	+/- Fixed mid-dilated pupil, conjunctival injection, hazy or steamy cornea	Intraocular pressure
Persistent monocular or binocular vision loss	Optic neuritis	Painful, pain with EOM, associated with MS	+/- Papilledema (most are normal)	MRI brain with gadolinium
	Ischemic optic neuropathy	Painless, diminished color vision Associated with giant cell arteritis	Afferent pupillary defect, visual field deficits Funduscopic exam: papilledema	+/- MRI brain with gadolinium +/- ESR, CRP

Table 7.1 (continued)

Type of vision impairment	Diagnosis	Key characteristics	Exam findings	Diagnostic studies
Binocular vision loss	Optic chiasm involvement	Most common cause is a pituitary adenoma Consider pituitary apoplexy in patients with headache, facial pain and facial numbness	Bitemporal hemianopia	CT/MRI brain +/- CTA/MRA brain
	Migraines	Transient, associated with headache	Scotomas Complete homonymous hemianopia	
	Retrochiasmal vision loss	Associated with CVA	Homonymous hemianopia	CVA evaluation CT/CTA and/or MRI/MRA brain/neck +/- Bilateral carotid Doppler, echocardiogram
	Posterior reversible encephalopathy syndrome (PRES)	Associated with headache, altered mental status, seizures, and hypertension	+/- Complete vision loss	MRI brain
	Cerebral blindness		Complete vision loss Loss of light/dark perception	CVA evaluation CT/CTA and/or MRI/MRA brain/neck +/- Bilateral carotid Doppler, echocardiogram

Diplopia

Case Presentation

A 60-year-old female with history of diabetes mellitus presents to the emergency department with new onset double vision that started 2 h prior to arrival. She describes her vision as seeing two of the same images side by side. She denies any systemic symptoms such as fever, headache, numbness, and weakness.

Approach to Diplopia

Diplopia is described as double vision and is due to the perception of two images of a single object [23]. A chief complaint of diplopia can be complicated and daunting.

Therefore, it's important to develop a standardized approach to help recognize the etiology. The first question that one should ascertain is if the diplopia resolves when the affected eye is covered, as this indicates a binocular diplopia. Monocular diplopia is suggested if the diplopia still exists with closure of either eye [24]. Monocular diplopia is ocular in origin. The most common cause of this is from dry eyes; however, it can also be caused by abnormalities of the cornea, lens, and retina [25]. If it is determined that the patient's diplopia is monocular in origin, then your workup other than a thorough ophthalmological exam mainly consists of consulting ophthalmology.

Binocular diplopia is the most common type of diplopia and is due to ocular misalignment. This can be further divided into horizontal, vertical, and oblique diplopia [23]. Horizontal diplopia is when the images are side by side, and vertical diplopia is when the images are diagonal to each other [25]. Horizontal diplopia is secondary to medial and/or lateral rectus muscle pathology with diminished abduction or adduction [25, 26]. Vertical diplopia is secondary to inferior rectus, superior rectus, inferior oblique, and/or superior oblique muscle pathology with diminished elevation or depression [25, 26]. If the diplopia worsens in a certain direction of gaze, then the extraocular muscle that functions in that direction is likely involved. For instance, if a vertical diplopia worsens with downgaze, this indicates inferior rectus weakening or a trochlear nerve palsy. If there is worsening of diplopia with upgaze, then this can suggest weakness of the superior rectus and inferior oblique or an oculomotor nerve palsy [24]. If the diplopia worsens with distance, then that suggests a problem with ocular abduction, which would indicate abducens nerve involvement. If the diplopia worsens when near, this implies a problem with ocular adduction, which indicates oculomotor nerve involvement [24, 26].

A thorough history and review of symptoms is very important and can point to a specific diagnosis. If the patient experiences a headache with the diplopia, then this can indicate an intracranial aneurysm or a microvascular ischemia causing a cranial nerve palsy. If the patient has pain with extraocular movement, this can be due to orbital disease, like idiopathic orbital inflammation. In addition, temporal arteritis can be associated with diplopia, which would be suggested if the patient has jaw claudication, scalp tenderness, or signs of polymyalgia rheumatica [24]. Myasthenia gravis, Wernicke's encephalopathy, Guillain-Barre and Miller Fisher syndrome, and trauma could cause both a horizontal and vertical diplopia [25]. Therefore, history taking is of importance and can influence the presume diagnosis.

Physical exam is paramount and should be done carefully to help locate impairment of ocular motility. Each eye should be examined initially independently to help locate any restriction of extraocular movement. They can then be examined together for comparison [24].

Cranial Nerve Palsies

Cranial nerve palsies causing a diplopia involve cranial nerves three, four, and six. When approaching a patient with a presumed cranial nerve palsy, it is important to

have a systematic approach to help uncover the etiology and to aid you in performing a proper diagnostic workup. Asking about neurologic signs and symptoms and history of trauma can help hint at the diagnosis. The age of patient is pertinent, as microvascular ischemia to the cranial nerve is a very common cause of cranial nerve palsy, in patients older than 50 or younger patients with diabetes and hypertension [26, 28].

An *oculomotor nerve palsy* (cranial nerve three palsy) on exam appears as the classic “down and out” orientation and may demonstrate mydriasis and ptosis. Upward, downward, and medial gaze is inhibited [26]. If the pupil is dilated, then this indicates a compressive oculomotor nerve palsy, which can be caused by an intracranial aneurysm. It’s important to meticulously examine the patient to determine the degree of involvement. If the extraocular muscles are only partially affected, then a compressive/aneurysmal oculomotor nerve palsy can still be the etiology, even with a normal pupil size [28]. Other causes of an oculomotor nerve palsy include microvascular ischemia, trauma, and multiple sclerosis [28]. If a patient presents with diplopia and the exam demonstrates oculomotor nerve palsy with pupil involvement or a partial oculomotor nerve palsy, an MRI and MRA of the brain should be performed to rule out an intracranial aneurysm. A CTA of the brain can also be performed, especially in the setting of the emergency department. Even if the CTA or MRA is negative, if the pupil is involved, the patient should be further worked up, and a formal angiogram can be considered. If the angiogram is negative, MRI with gadolinium should be done through the brainstem to rule out small neoplasms or inflammatory lesions that can affect the oculomotor nerve [27].

Trochlear nerve palsy (cranial nerve four palsy) affects the superior oblique muscle, the action of which is to depress and abduct the eye. Trochlear nerve palsy leads to inability of intorsion and depression leading to hypertropia where the eye deviates upward on the ipsilateral side. Patients may tilt their head toward the opposite side of lesion with chin down to bring both eyes into alignment [27]. A trochlear nerve palsy can lead to a vertical diplopia that is exacerbated by downgaze [26]. Trochlear nerve palsies can be congenital but unnoticed until there is a decompensation which occur at any age after trauma or medical illness. Patient may recall previous intermittent transient episodes of vertical diplopia brought about by alcohol or fatigue. Other causes of a trochlear nerve palsy include microvascular ischemia, trauma, and tumors [28]. A trochlear nerve palsy is rarely caused by microvascular ischemia, so an MRI of the brain and brainstem with gadolinium should be performed [26].

Abducens nerve palsy (cranial nerve six palsy) affects the lateral rectus muscles resulting in an inability of abduction of the ipsilateral eye. This can lead to a horizontal diplopia [26]. The abducens nerve is known to be sensitive to high intracranial pressure. Causes include microvascular ischemia, trauma, tumors, and multiple sclerosis [28]. A new onset painful abducens nerve palsy in a patient with hypertension and diabetes is usually due to microvascular ischemia; however, if this is persistent for 8–12 weeks or if there are any other symptoms or red flags, then imaging such as an MRI should be performed to rule out neoplasm, demyelination, and inflammatory causes [25].

When multiple cranial nerves are involved, the cavernous sinus may be involved. The cavernous sinus can be affected by meningiomas, carotid artery aneurysms, thrombosis, and inflammation. Dedicated cavernous sinus imaging should be performed [27].

Orbital Disease

Orbital disease can be vast and can be due to trauma, infection, neoplasm, inflammation, congenital myopathies, and from thyroid eye disease. Emergent signs of orbital disease in general include proptosis, lid retraction, and periorbital edema [24]. *Idiopathic orbital inflammation* can lead to diplopia. Other signs and symptoms include pain with extraocular movement, proptosis, and decreased vision. The inflammation can occur throughout the extraocular muscles, soft tissues, and optic nerve. Idiopathic orbital inflammation can be due to a variety of illnesses and autoimmune diseases, such as giant cell arteritis. Treatment includes corticosteroids and nonsteroidal anti-inflammation drugs [24]. *Thyroid eye disease* occurs in about 50% of patients with Graves' disease and is due to inflammation and infiltration of the tissues around the orbit. They can present with a complaint of diplopia, but they can also exhibit proptosis, conjunctival erythema, chemosis, and eyelid swelling and redness [24]. Patient with thyroid eye disease will often exhibit diplopia that is worse upon awakening and improves progressively throughout the day [28]. An *orbital neoplasm* can lead to diplopia due to involvement of the extraocular muscles. Patients with an orbital neoplasm may also display proptosis on exam. In general, MRI of the brain can miss pathology that causes orbital disease, so one should consider ordering an MRI and/or CT of the orbit to rule out orbital disease [24].

Myasthenia gravis can also cause diplopia and can present similarly to a cranial nerve palsy, as there can be weakness of the extraocular muscles. It's important to do a thorough history and physical to distinguish between the two. With myasthenia gravis, the pupil is not affected and there will usually be other symptoms such as weakness of the proximal muscles especially after exertion and ptosis [25]. Patients will typically exhibit no diplopia upon awakening or at rest [27]. On exam, the patient can be asked to sustain upgaze for 2 min, and if the patient is unable to do this and/or there is ptosis, then this suggests a diagnosis of myasthenia gravis [25].

Pearls and Pitfalls

Acute Vision Loss

- Perform extensive history taking asking about the patient's true visual perception, blurry or cloud vision, difficulty with far/near vision, loss of certain regions of vision, and monocular vs. binocular deficits.
- Thorough physical exam including visual acuity, pupillary size/response, and funduscopic exam should be performed.

- Amaurosis fugax is a cause of transient monocular vision, and CRAO and CRVO are both causes of persistent monocular vision loss that requires a stroke workup.
- Retinal detachment is associated with painless floaters and flashes of light. Bedside ultrasound can be diagnostic.
- Migraines or gastroenteritis can be mimics for acute angle-closure glaucoma. Diagnose by tonometry and treat promptly with ophthalmology consultation.
- Bitemporal hemianopia are caused by lesions to the optic chiasm. CT/MRI is required for diagnosis. Consider pituitary apoplexy in patients with headache, altered mental status, and facial pain/numbness.
- TIA can cause transient binocular vision changes.
- CVA can cause binocular visual deficits or complete blindness depending on lesion location.
- PRES can cause binocular or complete visual loss. Consider in patients with hypertension, headache, seizures, and decreased responsiveness.

Diplopia

- First approach to diplopia is to determine monocular vs. binocular.
- Microvascular ischemia is the most common cause of cranial nerve palsies.
- Oculomotor nerve palsy with pupillary involvement or partial palsy should be worked for compressive/aneurysmal etiologies.
- Trochlear nerve palsies should be worked up with an MRI of the brain and brainstem, as ischemic causes are rare in this type of palsy.
- Abducens nerve palsy is commonly caused by microvascular ischemia; MRI should be performed if symptoms are persistent for several weeks.
- More than one cranial nerve involvement can indicate cavernous sinus disease. Dedicated cavernous sinus images should be obtained.
- Patients with diplopia and proptosis should be worked up for orbital neoplasms with dedicated images of the orbit.
- Thyroid eye disease is often characterized by diplopia that worsens upon awakening and improves gradually throughout the day.
- Myasthenia gravis is characterized by no symptoms of diplopia upon awakening or at rest. Diplopia worsens with fatigue and later in the day.

References

1. Newman N, Biouesse V. Diagnostic approach to vision loss. *Continuum (Minneapolis)*. 2014;20:785–815.
2. Bagheri N, Mehta S. Acute vision loss. *Prim Care*. 2015;42(3):347–61.
3. Hoya K, Morikawa E, Tamura A, Saito I. Common carotid artery stenosis and amaurosis fugax. *J Stroke Cerebrovasc Dis*. 2008;17(1):1–4.
4. Lawlor M, Perry R, Hunt BJ, Plant GT. Strokes and vision: the management of ischemic arterial disease affecting the retina and occipital lobe. *Surv Ophthalmol*. 2015;60(4):296–309.
5. Pokhrel P, Loftus SA. Ocular Emergencies. *Am Fam Physician*. 2007;76(6):829–36.

6. Dattilo M, Biousse V, Newman N. Update on the management of central retinal artery occlusion. *Neurol Clin*. 2017;35(1):83–100.
7. Vortmann M, Schneider JI. Acute monocular visual loss. *Emerg Med Clin N Am*. 2008;26:73–96.
8. Dargin JM, Lowenstein RA. The painful eye. *Emerg Med Clin N Am*. 2008;26:199–216.
9. McAllister IL. Central retinal vein occlusion: a review. *Clin Experiment Ophthalmol*. 2012;40:48–58.
10. D’Amico DJ. Primary retinal detachment. *N Engl J Med*. 2008;359(22):2346–54.
11. Kang HK, Luff AJ. Management of retinal detachment: a guide for non-ophthalmologists. *BMJ*. 2008;336(7655):1235–40.
12. Jacobsen B, Lahham S, Patel A, et al. Retrospective review of ocular point-of-care ultrasound for detection of retinal detachment. *West J Emerg Med*. 2016;17(2):196–200.
13. Gupta D, Chen P. Glaucoma. *Am Fam Physician*. 2016;93(8):668–74.
14. Prum BE Jr, Herndon LW Jr, Moroi SE, et al. Primary angle closure preferred practice pattern guidelines. *Ophthalmology*. 2016;123:P1–P40.
15. Balcer LJ. Clinical practice. Optic neuritis. *N Engl J Med*. 2006;354(12):1273–80.
16. Hoorbakht H, Bagherkashi F. Optic neuritis, its differential diagnosis and management. *Open Ophthalmol J*. 2012;6:65–72.
17. Voss E, Raab P, Trebst C, et al. Clinical approach to optic neuritis: pitfalls, red flags, and differential diagnosis. *Ther Adv Neurol Dis*. 2011;4(2):123–34.
18. Rucker JC, Biousse V, Newman NJ. Ischemic optic neuropathies. *Curr Opin Neurol*. 2004;17(1):27–35.
19. Rubin RM, Sadun AA, Piva A. Optic chiasm, parasellar region, and pituitary fossa. In: Yanoff M, Duker JS, editors. *Ophthalmology*. 3rd ed. St Louis: Mosby; 2008.
20. Biousse V, Newman NJ. Vision loss: overview. *Semin Neurol*. 2007;27(3):199–210.
21. Corbett JJ. Approach to the patient with visual loss. In: Biller 4th J, editor. *Practical neurology*. Philadelphia: Lippincott Williams & Wilkins; 2012.
22. Hedna VS, Stead LG, Bidari S, et al. Posterior reversible encephalopathy syndrome (PRES) and CT perfusion changes. *Int J Emerg Med*. 2012;5:12. doi:[10.1186/1865-1380-5-12](https://doi.org/10.1186/1865-1380-5-12).
23. Alves M, Miranda A, Narciso MR, et al. Diplopia: a diagnostic challenge with common and rare etiologies. *Am J Case Rep*. 2015;16:220–3.
24. Dinkin M. Diagnostic approach to diplopia. *Continuum (Minneapolis)*. 2014;20:942–65.
25. Friedman DI. Pearls: diplopia. *Semin Neurol*. 2010;30(1):54–65.
26. Rucker JC, Tomsak RL. Binocular diplopia: a practical approach. *Neurologist*. 2005;11:98–110.
27. Halpern JI, Gordon WH. Trochlear nerve palsy as a false localizing sign. *Ann Ophthalmol*. 1981;13(1):53–6.
28. Cornblath WT. Diplopia due to ocular motor cranial neuropathies. *Continuum (Minneapolis)*. 2014;20:966–80.

Perrin T. Considine, Levi Filler, and Murtaza Akhter

Case Presentation

A 47-year-old female presents to your emergency department at 6 pm on a Sunday evening complaining of severe headache. She stated she felt fine when she woke up (at 7 am), and the headache started at 9 am while she was getting ready for church. It was severe on onset and was minimally helped with acetaminophen and ibuprofen. She has vomited four times since, and light and loud sounds make it feel worse.

On exam, she has her eyes closed while talking to you and keeps her head still while answering questions. Her vital signs are within normal limits. She has no aphasia or dysarthria. Her pupils are round and reactive equally. She has no finger-to-nose dysmetria, heel-shin ataxia, or dysdiadochokinesia. Strength is 5/5 in all extremities. She states mild pain when you flex her neck but has no Kernig's or Brudzinski's signs. She walks for you but hesitantly because of pain; however, she has no obvious ataxia or imbalance.

Introduction

Two percent of ED patients present with a chief complaint of atraumatic headache [1]. The majority of these patients will have benign conditions underlying their pain, but 2–4% of these patients, or approximately 1 in 25, will have a high-risk etiology to their headache (see Tables 8.1 and 8.2, Emergent causes of secondary headache) [2]. Identifying patients with headaches that may deteriorate quickly and

P.T. Considine, M.D. • L. Filler, D.O.

Department of Emergency Medicine, Maricopa Integrated Health System, Phoenix, AZ, USA

M. Akhter, M.D. (✉)

Department of Emergency Medicine, University of Arizona College of Medicine–Phoenix, Maricopa Integrated Health System, Phoenix, AZ, USA

e-mail: murtzaakhter@gmail.com

Table 8.1 Emergent secondary causes of acute headache

	Cause of secondary headache	Risks of missing
Vascular	Subarachnoid hemorrhage/pituitary apoplexy	Death, neurologic disability
	Subdural hematoma	Death, neurologic disability
	Idiopathic intracranial hypertension	Neurologic disability (blindness)
	Intracerebral tumor with increased ICP	Death, neurologic disability
	Pituitary apoplexy	Death, neurologic disability
Infectious	Venous sinus thrombosis	Death, neurologic disability
	Cervical artery dissection	Death, neurologic disability
	Cerebellar infarction	Death, neurologic disability
	Hypertensive encephalopathy	Death, neurologic disability, other hypertensive sequelae
	Preeclampsia	Death, neurologic disability, seizures
	Temporal arteritis	Neurologic disability (blindness)
Environmental	Meningitis	Death, neurologic disability
	Encephalitis	Death, neurologic disability
Other	Carbon monoxide poisoning	Death (upon return to environment)
Structural	Glaucoma	Neurologic disability (blindness)

Table 8.2 Emergent causes of secondary headache by prevalence

Diagnosis	Proportion of headache patients (%)
Benign diagnosis	98
Any pathologic diagnosis	2.00
CVA (stroke, TIA)	0.80
Bleeds (ICH, SAH, aneurysm)	0.60
CNS infection (meningitis, encephalitis)	0.50
Other pathological diagnoses	0.20

n = 5198, adapted from Goldstein et al. [4]

threaten life, limb, or neurologic disability is the primary goal in the ED and is performed alongside analgesic treatment.

The patient with obvious neurologic deficits or toxic appearance has a relatively clear-cut workup in front of them. Unfortunately, the most nefarious disease entities in headache may also present subtly, particularly early in their courses. These cases manifest few, if any, red flags on their first ED visit, and it is these subtle presentations whose outcomes are determined by the finesse of the emergency physician [3].

In the case of insidious pathology that may threaten life, limb, or neurologic capability, a goal-oriented approach allows the practitioner to detect what is

reasonably possible or, in the absence of abnormalities, accurately document a fair workup.

Concurrent Analgesia

Generally speaking, oral non-steroidal anti inflammatory drugs (NSAIDs) are appropriate starting therapy for nonspecific headache of mild to moderate intensity when an intracranial bleed is not in the differential diagnosis. For a patient with suspected migraine, one of any of an institution's standard parenteral migraine cocktails is appropriate first-line therapy. Opiates are generally avoided [5, 6] unless subarachnoid hemorrhage (SAH) is suspected, in which case it is thought that effectively treating a patient's pain will reduce associated intracranial pressure [7]. See also Table 8.11 for acute treatment for primary headache disorders.

History and Physical Examination

While a comprehensive history and physical is the paragon of virtue, the impetus in the emergency department is to utilize the history and physical to evaluate which, if any, diagnostic evaluations are merited. While appropriate tests are ordered or deferred, distinguishing primary or easily reversible headaches can be performed in parallel [5].

A convincing history and physical examination may be used to justify not performing certain studies, but only if all adequate data is obtained. This can be performed in a systematic fashion that starts before setting eyes on a patient.

History

Table 8.3 lists the classic red flags that must be assayed for in acute headache [1, 2]. Essentially, these red flags address [1] classic attributes of SAH and meningitis, [2] neurologic deficits or signs of neurologic compromise, [3] symptoms of or risk factors for increased intracranial pressure, or [4] other. "Have you recently been pregnant?" can be informative, given that both postpartum eclampsia and postpartum venous thrombosis may occur even 4–6 weeks postpartum, respectively [8, 9]. Specific elements to be elicited from the History of Present Illness are listed in Table 8.4 [1, 5]. Notably, age is a significant risk factor as well (see Table 8.5), with increased age correlated with an increased risk for significant pathology [4].

Assaying for these four elements of the history—classic attributes of SAH, neurologic deficits, increased intracranial pressure, and pregnancy status—may be approached in any number of ways that are appropriate, provided that they are systematic and replicable.

For a patient with a history of headaches, assessing for deviation from a patient's normal headache pattern and recent neuroimaging, if applicable, may reduce the

Table 8.3 Headache red flags

Category	Red flag
Attribute of SAH	>50 y/o with new headache
	“Thunderclap headache” (maximal intensity within 1 min of onset ^a)
	Traumatic/exertional onset
	Anticoagulated/antiplatelet therapy
Attribute of meningitis	Fever
Signs of neurologic compromise	Altered level of consciousness
	Altered mental status
	Focal neurologic deficits
	Blurry vision
	Seizure
	Syncope
Signs of elevated ICP or focal mass effect	History of immunocompromise (HIV, etc.)
	History of malignancy
	History of neurosurgery or cerebral shunt
	Papilledema
Risk for pregnancy-related complications	Currently pregnant
	Postpartum
Other	Systemic lupus erythematosus
	Behcet’s disease
	Vasculitis
	Sarcoidosis
	Recent antibiotic use

Adapted from Singh et al. [1] and Tintinalli [2]

^aSee SAH section for more on definition of thunderclap

Table 8.4 Concerning historical findings for acute headache

Historical findings	Concerning for
Sudden onset	SAH
Worse with supine position, cough, or straining	Increased ICP
Occipital headache (with double vision, dysarthria, dysphagia, or ataxia)	Occipital bleed, tumor, or stroke
Neck pain	SAH, meningitis, carotid or vertebral artery dissection
Neck stiffness	SAH, meningitis
Thunderclap headache (reaches maximum pain <1 min ^a)	SAH, CVT, ICH
Chronic, progressively worsening	Intracranial mass
Fever	Infection, intracranial hemorrhage
Neurologic deficits	ICH, mass, ITH

Adapted from Singh et al. [1]. Abbreviations: *ICP* intracranial pressure, *ITH* idiopathic intracranial hypertension, *ICH* intracranial hemorrhage, *SAH* subarachnoid hemorrhage

^aSee SAH section for more on definition of thunderclap

Table 8.5 Frequency of pathological etiology of headache by age group

Age group	Likelihood of <i>significant pathology underlying headache</i> (%)
<25	1
25–49	1
50–74	5
75+	11
Overall	2

requirement for new diagnostic studies and neuroimaging if the headache continues to follow a stereotypical pattern following an appropriately comprehensive workup. Specifically, a patient with history of benign headaches who presents with a stereotypical headache without new concerning historical features, neurologic deficits, or significant comorbidities is considered low risk and does not typically require neuroimaging [10]. A headache that does not fit readily into the patient’s previous pattern of headaches is suspect, and any headache that prompts a patient who would not normally come to the ED for evaluation does warrant de novo consideration, whether or not this involves invasive or irradiating diagnostics.

Additional questions, such as assaying for polycystic kidney disease, family history of subarachnoid hemorrhage, or vascular malformations in other parts of the body to gauge the risk of intracranial hemorrhage—or prior vasculitis for the risk of giant cell arteritis—may be performed as needed to develop the clinician’s gestalt when suspicion is high but diagnostic criteria are not easily met. Certain findings such as vomiting may occur commonly with benign causes such as migraine, as well as increased intracranial or intraocular pressure such as in SAH or glaucoma.

Physical Examination

The physical examination is organized around similar goals as the history’s but performed in the usual head-to-toe manner. Most elements of the exam, including a comprehensive emergent neurologic exam, are routine parts of the examination, given the potential for yielding subtle clues of neurologic deficit, immunocompromise, or increased intracranial pressure. Elements that may variably be included include measuring visual acuity and visual fields in the case of visual complaints and intraocular pressure in the case of visual complaints, eye pain, or other elements concerning for glaucoma, such as pain severe enough that it may not localize to the eye.

A summary of essential physical exam elements for evaluating headache is presented in Tables 8.6 and 8.7 [1, 2, 5].

The history and physical begin generally with vital signs and general appearance, which should indicate a general degree of illness. Fever without any other attributable cause will likely indicate an LP in a headache patient. Blood pressure may indicate hypertensive emergency or hypoperfusion [12]. If the patient is acutely

altered from neurological baseline (i.e., less alert or oriented or not mentating at baseline), head imaging in the form of CT or MRI is required unless harmful secondary headache disorders have otherwise been ruled out [13].

Other actionable exam findings include meningismus, which may indicate irritation of the meninges by infection, inflammation, or hemorrhage and papilledema, which is most reliably assayed by panoptic ophthalmoscopy or bedside ultrasound [14]. Papilledema is a delayed indicator of increased intracranial pressure that may not be present initially despite intracranial hypertension and may persist after nor-

Table 8.6 Standard physical examination elements for emergent evaluation of headache

Organ system	Elements evaluated	Potential findings	Potential clues of...
Vitals	Temperature	Fever	Meningitis, encephalitis, worse prognosis in SAH
	BP	Hypertension	SAH, hypertensive emergency
	Heart rate	Bradycardia/tachycardia	Cushing reflex (bradycardia, hypertension, widened pulse pressure)
General	Level of consciousness	Diminished	CNS compromise
	Mental status	Altered	CNS compromise
HEENT	Temporal artery tenderness	+	GCA
	Fundoscopy	Papilledema	Increased ICP
	Oropharynx	Thrush	Immunocompromise
	Dentition	Caries	Infection
	Nuchal rigidity	Meningismus	Meningitis, SAH
	Jolt accentuation	+	Meningitis
	Carotid tenderness	+	Carotid dissection
Carotid bruits	+	Carotid dissection, atherosclerotic disease	
Pulmonary	Air movement	Abnormal sounds	Routine
Cardiovascular	Rate, rhythm, murmurs	Irregular rhythm, + murmurs	Consider emboli secondary to atrial fibrillation or vegetative endocarditis
Abdomen	Focal tenderness	+	Routine
Extremities	Pulse symmetry	–	Consider aortic/cervical dissection

malization of the pressure, but when it is clearly present, it constitutes an indication for CT imaging before LP—the theory being that CT can evaluate for the risk of

Table 8.6 (continued)

Organ system	Elements evaluated	Potential findings	Potential clues of...
Neurological	Visual fields	Reduced	Pathology along visual axis
	Pupillary response	Afferent defect, ocular CN palsy	Peripheral neuropathy (CN III compression by PCom aneurysm), optic neuropathy, Horner's syndrome, CVA)
	Extraocular movements	Ocular palsy	Brainstem pathology
	Facial symmetry with CN VII	Forehead-sparing CN VII palsy	CVA
	Extremity sensory examination	Diminished sensation	Cortical lesion
	Extremity motor examination	Diminished strength	CNS involvement
	Pronator drift	+	Upper motor neuron disorder [11]
	Gait	Altered	Cerebellar lesion
	Tandem gait	Altered	Cerebellar lesion
	Finger-to-nose, heel-to-shin	Altered	Cerebellar lesion
Reflexes (DTR, Babinski)	Altered	Upper vs. lower motor neuron pathology	

Adapted from Singh et al. [1], Tintinalli [2]

Table 8.7 Other physical exam elements for emergent evaluation of headache

Organ system	Elements evaluated	Indications	Potential etiologies
Ophthalmologic	Intraocular pressure	Eye pain	Acute angle-closure glaucoma
Ophthalmologic	Visual acuity	Visual complaints	Ocular infection, optic neuritis, pituitary apoplexy, ICH
Ophthalmologic	Visual fields	Visual complaints	Ocular infection, optic neuritis, pituitary apoplexy, ICH
Dermatologic	Rash	Petechial/purpurral rash	Meningitis, vasculitis

tonsillar herniation that may occur when performing an LP in the presence of increased ICP [2]. See further discussion of this in “Clinical Investigations.”

Differential Diagnosis

Primary Headache Disorders

- Tension-type headache
- Migraine headache
- Cluster headache
- “Other”

Secondary Headache Disorders

- Vascular etiology
 - Subarachnoid hemorrhage
 - Subdural hematoma
 - Cerebral venous sinus thrombosis
 - Cervical artery dissection
 - Giant cell arteritis
 - Hypertensive headache/encephalitis
 - Pituitary apoplexy
- Nonvascular/other intracranial etiology
 - Hydrocephalus
 - Space-occupying lesion
 - Pseudotumor cerebri
 - Acute angle-closure glaucoma
 - Dural puncture headache
 - Carbon monoxide poisoning
 - Meningitis

The primary objective for the emergency practitioner is to identify and rapidly treat and stabilize any life-threatening cause of headache. The differential diagnosis for a patient who presents with a chief complaint of headache is broad, and recognizing important details of the history and physical examination can assist the provider in narrowing a specific headache etiology. Furthermore, headache can be broken down into subcategories in order to assist the physician and guide management. Among the various resources available to the emergency physician, the International Headache Society has clear guidelines and classifications of various headache disorders. The International Classification of Headache Disorders (ICHD) divides headaches into primary and secondary disorders [15]. According to the ICHD, primary headaches are comprised of tension-type headache, migraine-type headache, cluster headache, and “other primary headache” (exercise induced,

postcoital, etc.), whereas secondary causes of headache are manifestations of a separate disease entity. Secondary causes of headache can be broad, but are important nonetheless, given that the secondary causes are among the most life-threatening and must be ruled out first and foremost.

Primary Headache Disorders

Tension-Type Headache

Tension-type headache is classified by the International Headache Society as a primary headache disorder [15]. It is the most common type of primary headache, with an estimated prevalence approaching 40% [16]. Tension-type headaches are defined as having two of the following characteristics: bilateral location, non-pulsating quality of pain, mild to moderate intensity, and not aggravated by physical activity [1]. Tension-type headaches differ from other primary causes of headache mostly due to the fact that they are not functionally disabling, and patients are able to continue with their normal daily activities [17]. Increased pericranial tenderness recorded by manual palpation is the most significant abnormal finding in patients with tension-type headache [15]. By definition, episodic tension-type headache lasts as little as 30 min and as long as 7 days [17].

Migraine Headache

Migraine headache is the second most common headache disorder, affecting 12% of the United States population [1]. Multiple subtypes of migraine headache have been described in the literature, resulting in varying degrees of clinical presentations. The two major subtypes of migraine headache include migraine with aura and migraine without aura [15]. This diagnosis can often be difficult for the emergency physician to make and is typically considered in the right historical context only when more serious causes of headache have been ruled as less likely. Unlike tension-type headache, a migraine headache can be very disabling. Typical characteristics of the headache are unilateral location, pulsating quality, moderate or severe intensity, aggravation by routine physical activity, and association with nausea and/or photophobia and phonophobia [15]. Migraine with aura requires one or more fully reversible aura symptoms, including visual, sensory, speech and/or language, motor, brainstem, or retinal [15]. Migraine headaches can last from 4–72 h in duration, and aura symptoms typically last 10–20 min, although can persist up to an hour [17].

Cluster Headache

Cluster headache can mimic various severe secondary causes of headache, owing to its presentation and severity at onset. Cluster headaches are relatively rare compared

to the other primary causes of headache, with a prevalence estimated at 0.1% of the population [18]. True to its name, cluster headaches present temporally in clusters, meaning that multiple headaches can occur within a 24 h period of time, with periods of pain-free episodes between events [17]. The presentation of cluster headaches can mimic that of other serious headaches, including acute angle-closure glaucoma, trigeminal neuralgia, subarachnoid hemorrhage, and dental pain, among others. Typically, pain is described as unilateral in location and excruciating in quality [2]. Cluster headaches can also feature parasympathetic autonomic features including injected sclera, lacrimation, rhinorrhea, and facial and eyelid sweating [1]. At first glance, these symptoms can be similar to an ipsilateral Horner's syndrome presentation, and one must also think of the more serious carotid artery dissection as a secondary cause of this headache in the right clinical context. Typically, in contrast to other primary headache disorders (i.e., migraine), one will have trouble resting and can be typically found pacing the floor [15].

Secondary Headache Disorders

Vascular Etiology

Subarachnoid Hemorrhage

Subarachnoid hemorrhage is one of the most common and well-known life-threatening causes of headache. SAH is often described as a “thunderclap” headache, owing to its abrupt onset nature and severity, although many other causes of headache will present similarly. Even though SAH is well-known and described in the literature, only 1% of patients presenting to the ED with a headache have a subarachnoid hemorrhage [4, 19]. A well-obtained history is crucial to the diagnosis of SAH. The provider should be cognizant of potential “red flag” signs of the headache, with characteristics of onset and of severity being of utmost importance. Other associated symptoms of SAH will include neck pain or stiffness, nausea, vomiting, light-headedness, or syncope, as described by the patient.

While there are many features in the history and physical that can increase the risk of SAH, virtually none are specific or sensitive enough to rule in or rule out, respectively, the disease [3, 20–22]. The exception to this is the sudden onset nature of the headache, which is virtually the sine qua non of SAH [20–22]; patients presenting with sudden onset headache, regardless of severity, should be worked up for potential SAH [22, 23].

There is some confusion among providers as to what constitutes “sudden onset.” The Headache Classification Committee of the International Headache Society defines a sudden onset as one that reaches its maximal intensity within 1 min [15]. This definition is used in guidelines as well [10, 24]. However, landmark studies evaluating the diagnostic accuracy in the workup of SAH use 1 h as the cutoff for a headache reaching its maximal intensity [7, 19, 25]. Therefore, we recommend the 1-h timeframe as used by Perry et al. for considering a headache as sudden onset.

Aside from described symptoms in the ED, one must ask about past medical history and family history, as this may reveal significant underlying risk factors that would predispose the patient to SAH. According to Van Gijn, et al., approximately 86% of SAH are from ruptured intracranial saccular aneurysms with 11% caused by perimesencephalic syndrome and the remainder by AV anomalies and rare causes [26]. It has been well described that intracranial aneurysms may follow a familial pattern via various genetic mechanisms. According to a study by Schievink et al., spanning from 1970 to 1979, that evaluated families of patients with aneurysmal SAH, it was found that 15 out of 76 patients (20%) had a first- or second-degree relative with aneurysmal SAH [27, 28]. One should have a lower threshold for emergent workup once a familial history is obtained and confirmatory for cerebral aneurysm, especially in a first-degree relative. Other genetic factors are also known to play a role in the development and rupture of SAH and include autosomal dominant polycystic kidney disease, Marfan syndrome, and Ehlers-Danlos syndrome type IV, among other postulated inherited genetic defects [28]. Along with associated symptoms and family history, other factors should be considered when considering subarachnoid hemorrhage, including sex, hypertension, atherosclerosis, diabetes, and vascular anatomic differences. These additional findings are thought to be implicated in the pathogenesis of aneurysms [29, 30].

According to the American College of Emergency Physicians (ACEP) clinical guidelines, those patients presenting with a new, sudden onset severe headache should undergo an emergent head CT [10]. Aside from these recommendations, one should consider other possibilities for a new, sudden onset headache as well, and family history along with other pertinent risk factors described above should sway the physician to ordering emergent neuroimaging, as missing this diagnosis carries lethal consequences.

Additional Diagnostic Considerations for Workup of Subarachnoid Hemorrhage

The standard approach to working up SAH involves a computed tomography (CT) scan of the head followed by lumbar puncture (LP) if the CT is negative for SAH. This approach has been validated, with 100% sensitivity, by Perry et al. [19], and is the guideline as recommend by the American College of Emergency Physicians (ACEP) [10] as well as the American Heart Association (AHA) and American Stroke Association (ASA) [31].

Most providers obtain a CT of the head before performing an LP in patients in whom they are considering SAH. Some providers obtain an LP before CT. ACEP recommends that adult patients with headache and exhibiting signs of increased intracranial pressure (e.g., papilledema, absent venous pulsations on fundoscopic examination, altered mental status, focal neurologic deficits, signs of meningeal irritation) should undergo a neuroimaging study before having a lumbar puncture; otherwise, in the absence of clinical findings suggestive of increased intracranial pressure, a lumbar puncture can be performed without obtaining a neuroimaging study [10].

There is some controversy over what constitutes a “positive” spinal tap as opposed to a “traumatic tap.” Some providers obtain cell counts in tubes 1 and 4

from an LP, but red blood cell “clearing” is an insensitive test to distinguish between a traumatic tap and a true SAH [32, 33]. Furthermore, studies have shown that xanthochromia is also an insensitive test for ruling in SAH; this is particularly true when assessed for visually, as done in virtually every medical center in the country [34–39]. Fortunately, Perry et al. recently found that findings of no xanthochromia and red blood cell count $<2000 \times 10^6/L$ (same as <200 red blood cells/ mm^3) were 100% sensitive and 91.2% specific for the diagnosis of SAH [25].

In some cases, an LP may not be necessary. Perry et al. have showed that a CT performed within 6 h of symptom onset was 100% sensitive and 100% specific for diagnosing SAH [7]. This suggests that patients with a negative CT of the head can be safely discharged without an LP, assuming they presented within 6 h of symptom onset. However, the ACEP still recommends the CT/LP approach [10] regardless of time of presentation.

Some studies have looked at the potential of CT angiography (CTA) to supplant LP in sudden onset headache patients with a negative CT [40–46]. While CTAs tend to be easier to perform for the emergency provider (rather than a time-consuming LP) and patients prefer to not be stuck by a needle in their backs, CTAs also induce radiation and come with contrast. While some argue that the CT/CTA approach can replace the CT/LP pathway [40, 44–46], other groups have performed cost-effectiveness analyses (CEAs) that suggest that the CT/LP approach dominates the CT/CTA approach [41, 43]. These CEAs, however, omit the potential of CTA to catch other serious causes of thunderclap headache beyond aneurysms, including cervical arterial dissection, reversible cerebral vasoconstriction syndrome (RCVS), and even cerebral venous sinus thrombosis (CVST) [47, 48]. Moreover, these are conditions that cannot be diagnosed by LP. These CEAs also do not account for the pain associated with a spinal puncture [49]. The ACEP and AHA/ASA guidelines still recommend the CT/LP approach as of now [10, 31], but many experts recommend a shared decision-making approach to patients who present with sudden onset headache and a negative head CT [49–51].

Subdural Hematoma

Subdural hematomas can be spontaneous events or occur in the setting of trauma. The mechanisms of subdural hematomas are usually secondary to forces that shear the bridging dural veins between the dura mater and the subarachnoid mater [52]. Classically, subdural hematomas on CT imaging are described as concave and crescent shape in appearance and follow the curvature of the skull, as opposed to the biconvex, lens-type appearance of an epidural hematoma [52]. Subdural hematomas can be acute, subacute, or chronic and can vary widely in terms of presenting symptoms. Subdural hematomas are common in the elderly population; they account for 46% of TBI cases in elderly patients versus only 28% in younger cohorts [53]. The increased prevalence of subdural hematoma in the elderly population is attributed to multiple factors, including cortical atrophy, increased fall risk, and likelihood of the elderly being on anticoagulation medications—all of which increase bleeding risk following even minor trauma [53]. Minor trauma also is thought to contribute to chronic subdural hematomas, which have a more insidious presentation and are

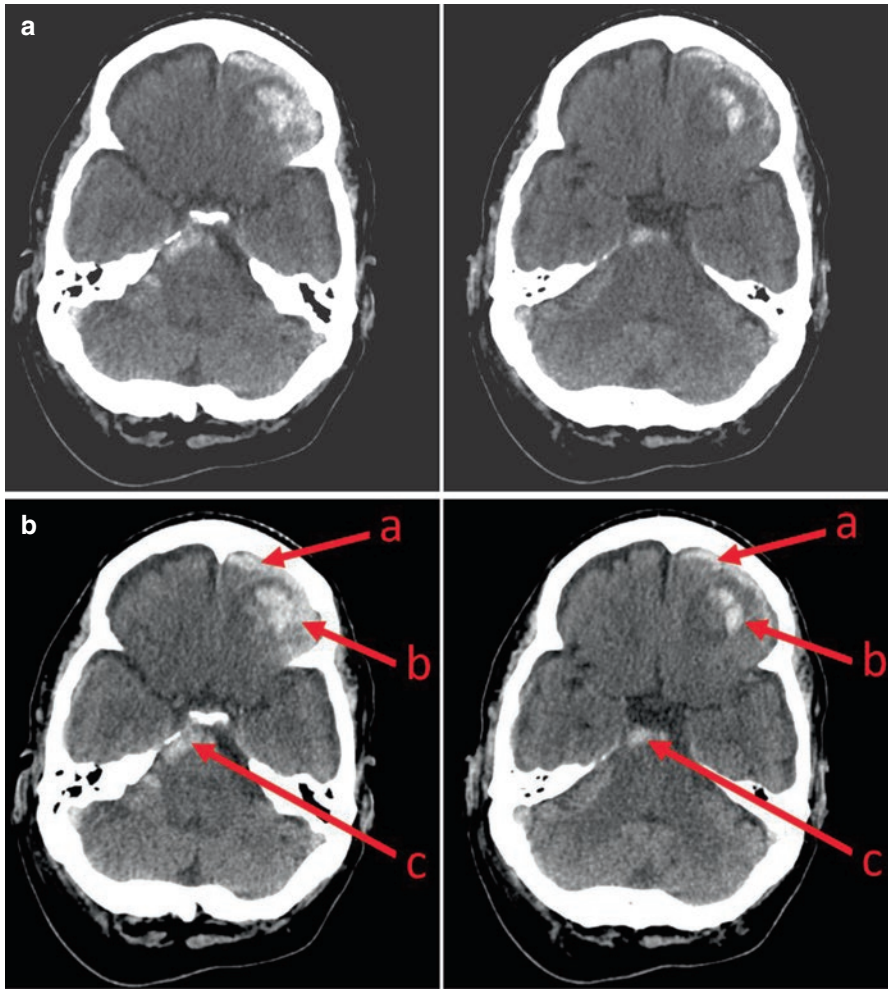


Fig. 8.1 (a) Axial images of a CT without contrast of a 55-year-old male found down and altered, see (b) for labeled pathology. (b) Axial images of a CT without contrast obtained for altered mental status. (a) Left frontotemporal subdural hemorrhage, (b) left frontal intraparenchymal hemorrhage, (c) subarachnoid hemorrhage in right cerebellopontine cistern. Courtesy of Perrin Considine

unlikely to present with symptoms classical for abrupt ICP elevation, including headache, visual changes, and vomiting [54, 55]. Overall, the elderly patient who presents with headache along with mental status changes that have been progressive and insidious in nature or with a history of anticoagulant use should be evaluated for subdural hematoma. One should be aware of common mimickers of SDH as well. In one systematic review, the most common mimicker was lymphoma (29%), followed by metastasis (21%), sarcoma (15%), infectious diseases (8%), and autoimmune disorders (8%) [56]. These alternative diagnoses should be considered as well when evaluating a patient for subdural hematoma (Fig. 8.1).

Cerebral Venous Sinus Thrombosis

Cerebral venous sinus thrombosis (CVST) is a well-described but overall lesser thought-of entity regarding the spectrum of headache disorders. Important keys to diagnosing this headache etiology partly lie with the past medical history. Similar to those with a history of deep venous thrombosis (DVT), those who have CVST will often have a prior history of hypercoagulable disorders, pregnancy, systemic inflammatory disease, connective disorders, or oral contraceptive medications [5, 57]. This is part of the reason why a CVST is colloquially called a “DVT of the brain.” CVST is much more prevalent in females than in males; in fact, 75% of CVST patients are female [58]. Furthermore, it accounts for 50% of strokes during pregnancy and the peripartum period [58]. Indeed, it strikes more often at a younger age, being most prevalent in the second and third decades of life [59]. Almost 80% of cases occur in patients under 50 years of age [60].

CVST presents in two types: those that are related to increased intracranial pressure attributable to impaired venous drainage and those related to focal brain injury from venous ischemia/infarction or hemorrhage [59]. Symptoms will be variable depending on the location of the thrombosis but have the possibility to include headache, decreased level of consciousness, seizures, focal neurologic deficits, or even coma [5, 57]. In particular, headache is present in 90% of patients, symptoms of stroke in 50%, and seizures in 40% [57]. Providers should beware that up to 25% of patients with CVST present with isolated headache without focal neurological findings or papilledema [61].

The AHA/ASA recommends obtaining a complete blood count, chemistry panel, sedimentation rate, and measures of the prothrombin time and activated partial

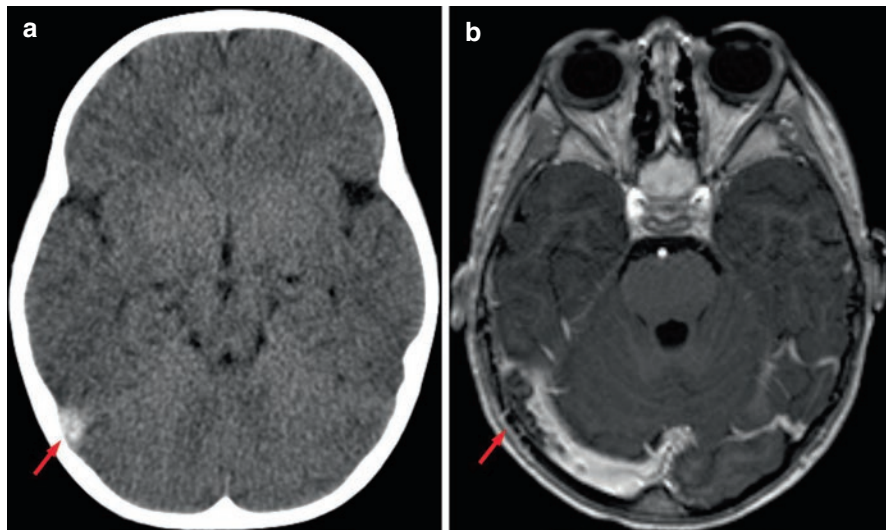


Fig. 8.2 Head CT without contrast and MR venography demonstrating cerebral venous thrombosis (arrows). By Hellerhoff—Own work, CC BY-SA 3.0, <https://commons.wikimedia.org/w/index.php?curid=8938877>

thromboplastin time in patients with suspected CVST [59]. A D-dimer can be invaluable as part of the evaluation, as it can be quite accurate in helping diagnose CVST [62, 63]. Imaging studies are needed to confirm (or sometimes exclude) the diagnosis [59]. Magnetic resonance venography is the gold standard, although CT venography is very sensitive and specific also (Fig. 8.2) [64].

Cervical Artery Dissection

Among the many vascular causes of headache, arterial dissection remains high on the list for emergency practitioners given its associated morbidity and mortality if missed. Specifically, headache can be caused by vertebral artery dissections and carotid artery dissections. Generally, dissections will present with focal neurologic deficits, and the causative vessel will determine the associated symptomatology. Often times, there can be delayed neurologic symptoms due to the eventual thrombosis of the dissected segment, causing obstruction of flow or embolization of thrombus from the dissected segment to the intracranial arteries [52]. Only 1–2% of all ischemic strokes are caused by cervical artery dissection, but in younger patients, cervical artery dissection accounts for 10–25% of strokes [65]. Unlike in subarachnoid hemorrhage, family history is not a common risk factor for this process [65]. Cervical neck pain is twice as common in patients with vertebral artery dissection compared to those with internal carotid dissection [65]. Commonly known symptoms of carotid artery dissection include those attributed to a partial Horner's syndrome, namely, miosis and ptosis; however, this only occurs in about 25% of patients [2]. In contrast, vertebral artery dissections typically will have vertigo as a presenting symptom, along with headache and neck pain, commonly in the setting of trauma [2]. Patients typically have headaches, facial pain, or neck pain that are usually ipsilateral to the dissected vessel and sudden in onset [15, 65]. A clear history and thorough neurologic examination can assist when differentiating these causes of headache.

Giant Cell Arteritis

While the majority of headaches from a vascular cause are mostly attributed to a bleed or thrombosis of the brain, giant cell arteritis differs in that it is medium- and large-sized arteritis with localized lesions to the temporal artery that result in secondary manifestations of headache [66]. Giant cell arteritis is commonly known to be a disease of the elderly population. Primarily, giant cell arteritis affects those over 50 years of age, with incident rates peaking around age 80 [67]. Symptoms of GCA can include systemic features of fever, anorexia, fatigue, and weight loss with ischemic manifestations of localized headache, scalp tenderness, jaw and upper limb claudication, and visual disturbance or loss [67]. This presentation differs from other vascular causes of headache, as it is not typically described as abrupt onset, nor severe in quality, and lacks other focal neurologic manifestations aside from potential visual loss. Visual loss may occur in up to 15–30% of cases [67]. Furthermore, up to 50% of patients may also present with symptoms of polymyalgia rheumatica [67]. This diagnosis may be difficult to diagnose as well given the potential for comorbid conditions to cloud the overall presentation.

Hypertensive Headache/Encephalitis

During a clinical evaluation of a headache, one may think that elevated blood pressure could be linked to headache; however, there is no clear evidence to suggest a link between the two [2]. A study by Gus et al. that monitored ambulatory blood pressure and relation to headache found that blood pressure did not differ significantly between hypertensive patients with and without headache during 24 h ambulatory blood pressure monitoring [68]. Furthermore, they found that blood pressure did not vary in the period surrounding episodes of tension or migraine-type headache. This study, however, only evaluated mild blood pressure elevation and could not comment on those with severe hypertension [68]. The association between systemic blood pressure elevation and headache remains controversial. According to the International Headache Society, chronic arterial hypertension of mild to moderate degree does not cause headache; however, headache caused by rises in intracranial pressures are well described [15]. There is ample evidence to suggest that severe elevations or rapid rise in blood pressure can be related to headache, such as in pheochromocytoma or posterior reversible encephalopathy [2]. Most headaches attributed to severe hypertension have readings in the range of 250/150 mmHg [17].

Pituitary Apoplexy

Pituitary apoplexy is a rare cause of headache; however, it is a life-threatening secondary cause of headache and thus worth mentioning. Pituitary apoplexy can manifest as a severe, abrupt onset, “thunderclap”-type headache; in fact, it is known as one of the causes of non-aneurysmal subarachnoid hemorrhage [15]. Pituitary apoplexy is typically in the setting of a spontaneous hemorrhage or infarction of a pre-existing pituitary adenoma [2]. Once hemorrhage or ischemia occurs, rapid expansion of a pituitary adenoma can cause pituitary apoplexy, occurring in about 14–22% of patients [69]. Given involvement of the pituitary gland, hormonal effects can occur as well and can occur acutely after the event or can have a delayed presentation. Hypopituitarism can occur in 70–80% of patients with pituitary apoplexy [69]. Given that the pituitary is involved, headache along with visual symptoms are likely. In 43% of cases, involvement of multiple cranial nerves has been described [69].

Nonvascular/Other Intracranial Etiology

Hydrocephalus

Hydrocephalus is a broad term that suggests an abnormal collection of cerebrospinal fluid around the brain. This term has originations in Greek and Latin, with “hydro” meaning water and “cephalus” meaning head. Various types of hydrocephalus exist and can be largely classified into acquired and congenital causes. They can be further described as obstructive (non-communicating) and nonobstructive (communicating) [70]. True to the name, obstructive hydrocephalus is caused by an obstruction of flow at various points in the ventricular system. In contrast, communicating hydrocephalus is secondary to impaired absorption or production of CSF

[70]. Normal pressure hydrocephalus is a type of communicating hydrocephalus and is a disease process that can be encountered in the emergency department. According to the International Headache Society, normal pressure hydrocephalus usually does not cause headache; occasionally mild dull headache is reported [15]. In 1965, Hakim and Adams first described normal pressure hydrocephalus as a condition characterized by gait disturbance, urinary incontinence, and memory impairment [71]. These symptoms, along with a mild, dull headache, should lead one to consider this diagnosis.

Space-Occupying Lesion

Headaches can occur in the setting of a space-occupying lesion, most commonly in setting of a brain tumor. This mass effect is thought to cause headache partly by increased intracranial hypertension and cerebrospinal fluid flow obstruction [2]. Patients can present with focal neurologic findings as well, and their presentation will depend largely on the location and size of the lesion. General signs of brain tumor can also include headache worse with Valsalva maneuver, seizures, mental status change, recent diagnosis of cancer, or a headache that awakens the patient from sleep [2]. This headache is typically a progressive headache versus the abrupt onset, severe headache caused by other vascular disorders, and is typically worse in the morning or after daytime napping [15]. The classic triad of brain tumor headache—sleep disturbance, severe pain, and nausea and vomiting—is only seen in a minority of patients (Fig. 8.3) [17].

Idiopathic Intracranial Hypertension

Idiopathic intracranial hypertension, also known as pseudotumor cerebri and benign intracranial hypertension, is a disease in which there is increased intracranial pressure in the absence of other obvious disease processes. The incidence of this etiology is approximately 1.2/100,000 individuals per year and is more common in young women with higher body weight. It is also associated with contraceptive medications [72].

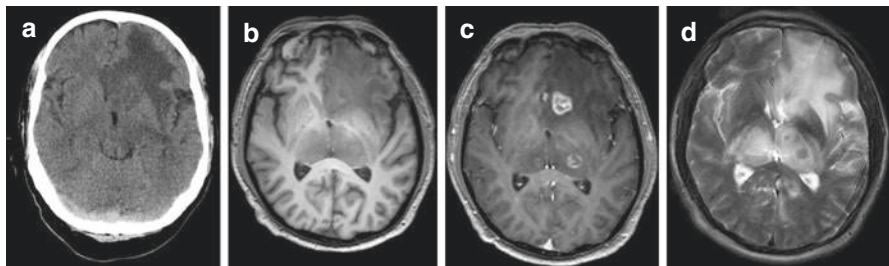


Fig. 8.3 (a) CT without contrast, (b) MRI T1 without contrast, (c) MRI T1 with contrast, (d) MRI T2 without contrast of a 54-year-old HIV+ male found confused after a syncopal event following discharge from jail. Left frontal lobe mass with 4 mm midline shift and vasogenic edema identified on noncontrasted head CT (a), concerning for GBM vs. lymphoma vs. metastases. This prompted an MRI without contrast (b, d) radiologically concerning for CNS lymphoma, and a contrasted MRI (c) ordered the next day after admission and demonstrating ring-enhancing lesions, which can also be found with toxoplasmosis (Courtesy of Perrin Considine)

According to Tintinalli's textbook, the incidence is 19.3 per 100,000 of obese women between the ages of 20–44 years of age [2]. Typical symptoms include headache, transient visual obscurations, back pain, pulsatile tinnitus, and visual loss [2]. Once a history of headache and visual symptoms are described in the abovementioned demographic, one should be keen on moving toward funduscopic examination, which will likely reveal unilateral or bilateral papilledema. In one study, bilateral papilledema was present in 81.96% of patients [73]. Diagnostic criteria exist as well, and one can follow the modified Dandy criteria in order to assist with diagnosis. The Dandy criteria arose from Dr. Walter Dandy, an American neurosurgeon, who in the 1930s advanced our conceptions of normal and compromised CSF circulation [74]. Original criteria have since been modified. Current criteria include signs and symptoms of increased intracranial pressure, no other neurologic abnormalities or impaired level of consciousness (with the exception of CN VI palsy), elevated intracranial pressure with normal CSF composition, computed tomography scan which shows no etiology for increased ICP, and no other cause for intracranial hypertension found [75]. Although these criteria can serve as an overall guideline to provide assistance when diagnosing this condition, ultimately, a more detailed history and thorough funduscopic and neurologic examination will be of the utmost importance along with definitive CSF pressure measurement with a lumbar puncture [76]. The IIHTT criteria suggest a CSF pressure of 200 mm H₂O as a diagnostic criterion [77]. The Friedman criteria [78] and the traditional modified Dandy criteria [79, 80] both suggest a higher threshold: 250 mm H₂O.

Acute Angle-Closure Glaucoma (See also Chap. 7)

Acute angle-closure glaucoma can present as an abrupt onset headache with associated intense eye pain and sharp vision loss, sometimes associated with systemic symptoms like severe forehead ache above the affected eye and nausea and vomiting [81]. This may at times have similar symptomatology shared by that of subarachnoid hemorrhage, iritis, cluster headache, and migraine. This can be a similar presentation to and sometimes mistaken for subarachnoid hemorrhage, iritis, cluster headache, and migraine. Subtle clues in the history can help delineate this condition from other causes of abrupt onset headache. Acute angle-closure glaucoma can precipitate after pupillary dilation, with a classically known history of a patient walking out of a well-lit environment and into a dark room (i.e., movie theater). Anatomically, dilation increases contact between the iris and the lens, which overall causes the angle between the peripheral iris, trabecular meshwork, and cornea to become acutely closed, resulting in a precipitous increase in intraocular pressure [2]. Physical examination can reveal a red eye with a fixed and mid-dilated pupil with corneal clouding and a shallow anterior chamber [17]. A measurement of intraocular pressure in the range of 60–90 mmHg (10–20 mmHg being normal) is diagnostic of this condition and can separate acute angle-closure glaucoma from other similar causes of headache [17].

Dural Puncture Headache

Headache after undergoing a lumbar puncture is largely thought to be secondary to intracranial hypotension. Intracranial pressure is determined by the flow and absorption of cerebral spinal fluid in the brain, and low levels can be caused by leaks in the vertebral column and skull [82]. Headache is the most common complication of lumbar puncture, occurring in up to 40% of patients [17]. Factors associated with increased risk of dural puncture headache include young age, low body mass index, chronic headache or prior dural puncture headache, female gender, large needle diameter, and cutting needle design [83]. This diagnosis is relatively straightforward to make in the setting of recent lumbar puncture, although very rarely can this be a spontaneous cause of headache. This headache is characteristically positional and increases with upright position and decreases with recumbency [17]. Symptoms will typically be relieved within 30 min of lying down [82]. According to the International Headache Society, headache occurring within 5 days of lumbar puncture is usually accompanied by neck stiffness and/or subjective hearing symptoms and remits spontaneously within 2 weeks or after sealing the leak with autologous epidural lumbar patch [15]. Other symptoms can include photophobia, interscapular pain, tinnitus, hypoacusis, and nausea or vomiting [82].

Carbon Monoxide Poisoning

Carbon monoxide poisoning can occur via many sources and does not discriminate, affecting those of all age groups and demographics. Carbon monoxide exists typically in the environment as a by-product of combustion and is present in exhaust from combustion engines and other motors [2]. Other sources include stoves, heaters, or natural gas-producing mechanisms. The pathophysiology of carbon monoxide poisoning involves the binding of carbon monoxide to hemoglobin and the resulting deleterious effect on oxygen equilibrium in the body. This diagnosis can be difficult to make given the lack of any specific toxidrome for carbon monoxide poisoning [2]. Typically, carboxyhemoglobin levels of 10–20% can cause a mild headache without gastrointestinal or neurological symptoms; levels of 20–30% cause a moderate pulsating headache and irritability; and levels of 30–40% cause a severe headache with nausea, vomiting, and blurred vision [15]. Given the nonspecific signs and symptoms related to carbon monoxide poisoning including vomiting, ataxia, seizure, syncope, chest pain, and focal neurologic deficits, one must rely on other situational history to assist with the diagnosis [2]. At times, family members may present with similar symptoms at similar times, and one should be more concerned if symptoms occur in the winter months, owing to a greater use of heaters, stoves, and generators.

Meningitis

Meningitis is a well-known and well-described cause of headache and is likely one of the more concerning disorders at the forefront of any emergency physician's differential diagnosis when working up the acute headache presentation. There are two distinct causes of meningitis—viral (aseptic) and bacterial—both of which differ in morbidity and mortality as well as presentation. Viral meningitis has an overall

more indolent presentation compared to acute bacterial meningitis [17]. The severity of viral meningitis can vary depending on the virus involved. Some cases are mild and resolve with no sequelae, while viruses such as the herpes virus can be potentially devastating [2]. Acute bacterial meningitis is defined as acute inflammation of the leptomeninges caused by bacteria and is a major cause of death and disability [84]. The case fatality rate of acute bacterial meningitis remains around 10–30%, and an additional 5–40% of cases have only partial recovery with late sequelae [84]. Overall, although the cases of bacterial meningitis have declined since the development of vaccines, it still remains an issue, especially in developing countries. Clinically, the presentation of fever, headache, stiff neck, and altered mental status should sway the physician toward this diagnosis; however, absence of these symptoms does not exclude meningitis [2]. Headache is seen in more than 85% of patients, along with fever being the second most common symptom and seizures and focal neurologic deficits found in 25–30% of patients [2]. Currently, it is near impossible to clinically determine viral versus bacterial etiology without a lumbar puncture. However, in one study, confusion or altered level of consciousness was more frequent in bacterial meningitis than in viral meningitis (73.7% vs. 24.2%) [85]. Physical examination findings include the classically taught meningeal signs: Kernig and Brudzinski. In a study by Thomas, et al., these signs, although very well-known, do not accurately discriminate between patients with meningitis and those without and showed a sensitivity of only 5% for each sign [86]. Nuchal rigidity had an overall higher sensitivity of 30% in this study, making it a more reliable physical examination component compared to Kernig’s and Brudzinski’s sign [86]. Overall, one should continue to have a high suspicion for meningitis in the patient that presents with headache, neck symptoms, fever, or signs of sepsis, as delaying treatment can have devastating effects.

Clinical Investigations

Table 8.8 lists standard investigations to consider for various potentially emergent causes of headache. The emergent evaluation of acute headache is less an elegant search for a definitive diagnosis, and more a clinical judgment of how much, if any, diagnostic workup is warranted in evaluating for potentially disabling (if not fatal) conditions. Standard laboratory and imaging studies are depicted in Table 8.8, “Standard Laboratory and Imaging Investigations to Consider in Evaluation of Acute Headache.” Justifying the pursuit or deferment of these studies is the focus of a thorough, goal-oriented history and physical.

In a study of US Emergency Departments from 1992 to 2001, approximately 1 in 6 patients with acute headache underwent head CT or MRI. Two percent received an LP. From there, 5% of head imaging and 10% of LPs were diagnostic for “can’t-miss” pathology (see Table 8.1) [4]. The decision of whether or not to pursue further diagnostic studies depends immensely on the history and physical. For example, a patient with acute headache and a normal neuro exam has 2.4% chance of anomalies

Table 8.8 Standard laboratory and imaging investigations to consider in evaluation of acute headache

Modality	Investigation	Findings	Indications
Imaging	Noncontrast CT	ICH (SAH, SDH, EDH, IPH)	+ Red flags (see Table 8.3)
	MRI	Posterior fossa masses, infarcted tissue	Suspicion of posterior fossa pathology, evaluate for infarcted tissue
	MRV	Cerebral venous thrombosis	Suspicion of hypercoagulability, increased intracranial pressure, physician gestalt
Laboratory studies	ESR	Temporal arteritis	Two or more + criteria for GCA or physician gestalt
	Carboxyhemoglobin	Carbon monoxide poisoning	Clinical suspicion
	CBC	Leukocytosis	Concern for high-risk headache
	BMP	Electrolyte derangement	Concern for high-risk headache
	Coagulation panel	Coagulopathy	Plan for LP
	Blood cultures	Organism and sensitivities	Concern for high-risk headache
Procedure	Lumbar puncture	Meningitis, SAH	Concern for infection, intracranial bleed, IIH

Adapted from Singh et al. [1], Rosen [5]. Abbreviations: *ICP* intracranial pressure, *IIH* idiopathic intracranial hypertension, *ICH* intracranial hemorrhage, *SAH* subarachnoid hemorrhage

Table 8.9 Indications for head CT before LP

Indications that LP without CT is likely safe	Indications from CT not to perform LP
Age < 60	Midline shift
Not immunocompromised	Obstructive hydrocephalus
No history of CNS disease	Compressed basilar cisterns
No seizure <1 week	Displacement/compression of 4th ventricle (often posterior fossa mass)
No ALOC	
Normal neurologic exam	

Ninety-seven percent of patients with above criteria had no signs of increased ICP CT (and none of the patients experienced herniation). *N* = 235 adults with suspected meningitis and CT scans [88]

on neuroimaging; this number decreases to 0.4% in patients with features classic for migraine [87].

If an LP is to be pursued, there should first be a CT scan performed to assess for increased intracranial pressure (ICP) *unless* there is sufficient clinical information suggesting that the patient does not have increased ICP [88]. See Table 8.9 for imaging findings that would hazard against performing LP given the concern for

increased intracranial pressure. For a young patient with a normal neuro exam (including normal mental status) and no known intracranial lesions or reasons to suspect increased intracranial pressure and risk of tonsillar herniation (such as immunocompromise, which can predispose to lesions such as toxoplasmosis or CNS lymphoma), an LP is likely to be safe [88]. For all other patients, CT imaging is routine to evaluate for signs of potential complications with LP. This is also the policy of ACEP, namely, that adult patients with headache and exhibiting signs of increased intracranial pressure (e.g., papilledema, absent venous pulsations on fundoscopic examination, altered mental status, focal neurologic deficits, signs of meningeal irritation) should undergo a neuroimaging study before having a lumbar puncture; otherwise, in the absence of clinical findings suggestive of increased intracranial pressure, a lumbar puncture can be performed without obtaining a neuroimaging study [10].

For further discussion of imaging modalities, see NEUROIMAGING below.

The other main risks of an LP include infection—such that an LP is not performed over an area of cellulitic skin or suspicion for an infection that can be seeded into the epidural space—and coagulopathy, such as INR > 1.8 or platelets <50 k in the presence of active bleeding at another site [89].

In the realm of emergent acute headache, the LP is primarily a diagnostic procedure but may also be therapeutic in the case of idiopathic intracranial hypertension (see section “Differential Diagnosis”) [2]. A goal of 15–20 mL should be obtained from a complicated adult patient to avoid need for repeating the procedure to obtain an adequate sample [90]. For example, an immunocompromised patient for whom tuberculosis is on the differential, 10 cm³ is required for acid fast culture alone [90]. Standard studies include glucose, protein, gram stain, cell count and differential, and opening pressure—which must be performed while the patient is in the lateral decubitus position, as it is inaccurate from the seated position [2]. Repeat LP may be indicated at a higher interspace (providing it stays at L3/L4 or lower) if blood is present and a traumatic tap is suspected [89].

ESR and carboxyhemoglobin may also be considered for patients with concerns for giant cell arteritis (GCA) and carbon monoxide poisoning, respectively. For more information, see section “Differential Diagnosis.”

For a generally ill-appearing patient or one who may require hospitalization or surgery, basic labs such as CBC, CMP, and urine pregnancy test may be obtained, which may be useful to consultants. INR is indicated prior to LP and for patients who are anticoagulated or with suspicion of bleeding. Point-of-care glucose is indicated for the patient with neurologic symptoms with acute onset and suspicion for hypoglycemia [2].

Neuroimaging

Most patients with acute headache who have significant red flags in their H and P will undergo neuroimaging. See Table 8.10 [1, 2, 17] for a summary of indications and caveats of common imaging modalities in acute headache.

Table 8.10 Indications and caveats in neuroimaging for acute headache

Imaging study	Indications	Potential findings	Caveats
Noncontrast head CT	Concern for intracranial hemorrhage or elevated ICP (trauma, thunderclap headache, new headache with focal neurologic deficit or papilledema)	Hydrocephalus, intracranial bleeding (SAH, SDH, EDH, IPH), mass lesion, pale infarct	Not ideal for posterior fossa pathology, may not visualize all intracranial masses
Contrasted head CT	Intolerance to MRI, suspicion of abscess, vascular lesion, mass lesion, aneurysm	Increased delineation of nonhemorrhagic soft tissue lesions	Contraindicated in renal insufficiency (unless anuric) due to risk for contrast-induced nephropathy from iodinated contrast
MRI	Need for increased detail of soft tissues, suspicion of posterior fossa pathology, intracranial lesions, hypertensive encephalopathy	Increased delineation of nonhemorrhagic soft tissue lesions	Some patients may require sedation for MRI Availability dependent on resources May be contraindicated in some patients with metallic hardware or foreign bodies
MR angiography	Suspicion for arterial pathology such as stenosis, dissection, vasculitis, congenital anomalies	Arterial abnormality	Contrast contraindicated in renal insufficiency to risk for nephrogenic systemic fibrosis from gadolinium
MRV	Suspicion for cerebral venous thrombosis	Filling defect, positive delta sign	Contrast relatively contraindicated in pregnancy and breastfeeding women

The most common modality is the noncontrasted head CT, which serves primarily to evaluate for acute intracranial hemorrhage or initial evaluation of acutely elevated intracranial pressure [2, 91]. There is some debate as to when a CT is sufficient by itself, or whether a LP is needed as well, to rule out subarachnoid hemorrhage (SAH) in acute headache. Head CT is considered adequately sensitive (97–100% sensitive) in identifying SAH if it is carried out within 6 h of headache onset and is interpreted by a qualified radiologist. See section “Differential Diagnosis,” in particular, “Additional Diagnostic Considerations for Workup of Subarachnoid Hemorrhage” [7]. Noncontrasted head CT may also demonstrate hydrocephalus, effaced gyri, midline shift, or effacement of the basal cisterns, which may be causal or secondary to increased ICP [91].

MRI with gadolinium contrast may also be performed in the emergency department, commonly in conjunction with a noncontrasted head CT, with superior detection of nonhemorrhagic intracranial masses than CT alone. Specifically, it should be

ordered in the suspicion for mass lesion such as intracranial abscess, toxoplasmosis, and CNS lymphoma, and it may better delineate lesions in the posterior fossa [2].

CT angiography (CTA) and MR angiography (MRA) may be used to better delineate vasculature. Generally speaking, MRA may be used when there is suspicion for arterial pathology such as stenosis, dissection, vascular anomalies such as aneurysms or arteriovenous malformations, or vasculitis [17].

MR venography can evaluate for cerebral venous thrombosis. Renal insufficiency may be a relative contraindication to contrast for both CT and MR, depending on whether the patient is anuric or oliguric, as patients who are producing some urine do have residual renal function that they are at risk of losing [2].

When there is confusion as to which study to order due to infrequent usage, atypical patient characteristics, or resource limitations, the radiologist is often an invaluable resource in advising optimal imaging.

Treatment/Analgesia

Definitive treatment will, as in all medical cases, depend upon the underlying cause. Emergent conditions such as intracranial bleeds will likely be admitted to a neurological ICU with a neurosurgery consult. Bacterial meningitis is usually admitted to the medicine service, with antibiotics. More definitive management strategies for various emergent headache conditions are covered in other chapters in this book.

However, all headache patients are, by definition, in pain. When not contraindicated, analgesia should be given. Table 8.11 has some possible treatment options for *primary* headaches (note that, for example, for a secondary headache due to SAH, NSAIDs should not be given).

Disposition

In the presented case, you gave the patient normal saline and IV metoclopramide for her headache and a small dose of IV lorazepam for her nausea. You obtained basic labs, which were unremarkable. A noncontrast head CT was negative for acute pathology. The patient felt slightly improved but still had significant pain. With the patient and her sister at the bedside, you performed shared decision-making, and the patient opted for an LP. The LP showed 500 RBCs/mm³. You consulted neurosurgery, who recommended you keep the patient's systolic blood pressure below 140 mm Hg, asked for a CT angiogram, and recommended admission to the neurological intensive care unit. Being an astute emergency physician, you also gave nimodipine to the patient, even though you had heard differing opinions on the abilities of calcium channel blockers to prevent vasospasm in SAH. Later that evening, a medical student stopped by the ED to tell you that the patient's imaging showed a culprit aneurysm and that she was taken to the operating room to have her aneurysm coiled. He thanked you for the excellent consult.

Table 8.11 Acute treatment for primary headache disorders

	Tension headache	Cluster headache	Migraine headache
NSAIDs	Adequate treatment [92]	Poor evidence available	First-line therapy [1]
Dopamine antagonists	May be useful [92]	May be useful [93]	More effective than placebo [1]
– Chlorpromazine	Not first line, but may be useful	Not first line but may be useful. Poor side effect profile	Fallen out of favor as first-line agent due to side effects (i.e., anticholinergic) [1]
– Metoclopramide	Not first line but may be useful	Not first line but may be useful	Similar efficacy to ibuprofen and sumatriptan [1]
– Prochlorperazine	Not first line but may be useful	Not first line but may be useful	Some studies suggest to be more effective than metoclopramide but may have more side effects [1]
Triptans	Not typically used	First-line treatment. Shown to be better than placebo [1]	First-line therapy, but with relative and absolute contraindications [1]
DHE (dihydroergotamine)	Not typically used	May be used but evidence is lacking [93].	No significant benefit for initial treatment when compared to sumatriptan and phenothiazine [1]
Opioids	Not typically used	Poor evidence available	Current guidelines recommend for only severe, refractory headaches [1]
Steroids	Not typically used	Can be used but high-quality evidence is unavailable [92]	RTCs have shown no benefit for acute headache [1], may prevent recurrence [2]
Oxygen therapy	Not typically used	First-line treatment [2, 92]	Not effective [94]

Dopamine antagonists, or neuroleptics, can include chlorpromazine, metoclopramide, and prochlorperazine

Medication alternatives for tension-type headache can include massage, biofeedback, and meditation [92]

Pearls and Pitfalls

Primary Headache Disorders

- Evaluate for life-threatening secondary causes of headache before diagnosing a benign primary headache disorder.
- Do the following with extreme caution:

- Attribute persistent neurologic findings to migraine headache with aura.
- Diagnose cluster headache, which is relatively rare, without evaluating for acute angle-closure glaucoma, Horner's syndrome, etc.
- Tension-type headaches, while common, do not commonly present to the emergency department.
- Treating symptoms of headache is no substitute for a thorough history and physical examination, as analgesia can be achieved in headaches with serious etiology as well.

Secondary Headache Disorders

- While studies suggest that CT head within 6 h of symptom onset has high sensitivity and specificity (100% and 100%, respectively) for acute subarachnoid hemorrhage, ACEP continues to recommend CT and LP.
- The elderly population, especially if taking anticoagulants, can have subdural hematomas with minimal trauma or even spontaneously.
- Headache and neurologic symptoms in a patient with risk factors for hypercoagulable states should prompt consideration of cerebral venous sinus thrombosis (CVST).
- Up to 25% of patients with CVST present with isolated headache without focal neurological findings or papilledema.
- Cervical artery dissection accounts for 10–25% of strokes in the younger population.
- Once suspected, treat patients with suspected temporal arteritis with steroids early to preserve potential vision loss—even prior to confirmatory studies.
- Mild to moderate blood pressure elevations are unlikely to cause headache.
- Suspect pituitary apoplexy in patients with abrupt onset headache and pituitary symptoms.
- Recognize that normal pressure hydrocephalus (NPH) can present only as a dull headache, not necessarily with the classic symptoms of gait disturbance, urinary incontinence, and memory impairment being predominant.
- Do not fail to perform a funduscopic examination when NPH is suspected, given that a high percentage of these patients will have papilledema.
- Headaches that worsen with Valsalva or waking the patient from sleep strongly suggest intracranial malignancy, especially in a patient with a known history of cancer.
- Perform a prompt tonometry examination in cases of suspected acute angle-closure glaucoma, especially when there is a history of abrupt pupillary dilation.
- The size and type of cutting needle affects the incidence of post-dural puncture headache.
- Multiple family members presenting with headache, especially in the winter months, should raise suspicion for CO poisoning.

References

1. Singh A, Soares WE. Management strategies for acute headache in the emergency department. *Emerg Med Pract.* 2012;14(6):1–23.
2. Harrigan M, Felix ACG. Headache. In: Tintinalli JE, Stapczynski JS, Ma OJ, Yealy DM, Meckler GD, editors. *Tintinalli's emergency medicine: a comprehensive study guide.* 8th ed. New York: McGraw Hill; 2017.
3. Edlow JA, Caplan LR. Avoiding pitfalls in the diagnosis of subarachnoid hemorrhage. *N Engl J Med.* 2000;342(1):29–36. doi:10.1056/NEJM200001063420106.
4. Goldstein JN, Camargo CA, Pelletier AJ, Edlow JA. Headache in United States emergency departments: demographics, work-up and frequency of pathological diagnoses. *Cephalalgia.* 2006;26(6):684–90.
5. Russi CS. Headache. In: Marx J, Hockberger R, Walls R, editors. *Rosen's emergency medicine—concepts and clinical practice.* 8th ed. Philadelphia: Saunders; 2014. p. 170–5.
6. Derry S, Moore RA. Paracetamol (acetaminophen) with or without an antiemetic for acute migraine headaches in adults (Review) SUMMARY OF FINDINGS FOR THE MAIN COMPARISON. *Cochrane Database Syst Rev.* 2010.
7. Perry JJ, Stiell IG, Sivilotti MLA, Bullard MJ, Emond M, Symington C, et al. Sensitivity of computed tomography performed within six hours of onset of headache for diagnosis of subarachnoid haemorrhage: prospective cohort study. *BMJ.* 2011;343:d4277. <http://www.ncbi.nlm.nih.gov/pubmed/21768192>.
8. Vest AR, Cho LS. Hypertension in pregnancy. *Cardiol Clin.* 2012;30(3):407–23.
9. Moschiano F, Di Stefano M. Stroke and pregnancy. *Riv Ital di Neurobiol.* 2008;5(1):64–71.
10. Edlow JA, Panagos PD, Godwin SA, Thomas TL, Decker WW. Clinical policy: critical issues in the evaluation and management of adult patients presenting to the emergency department with acute headache. *Ann Emerg Med.* 2008;52(4):407–36.
11. Darcy P, Moughty AM. Pronator drift. *N Engl J Med.* 2013;369(16):e20.
12. Assarzagdegan F, Asadollahi M, Hesami O, Aryani O, Mansouri B, Beladi MN. Secondary headaches attributed to arterial hypertension. *Iran J Neurol.* 2013;12(3):106–10.
13. Kaniecki R, Page P. Headache assessment and management. *Clinician's Corner.* 2013;289(11):11–4.
14. McComiskie JE, Greer RM, Gole GA. Panoptic versus conventional ophthalmoscope. *Clin Exp Ophthalmol.* 2004;32(3):238–42.
15. Headache Classification Committee of the International Headache Society (IHS), et al. Cephalalgia. 2013;33(9):629–808. doi:10.1177/0333102413485658.
16. Schwartz BS, Stewart WF, Simon D, Lipton RB. Epidemiology of tension-type headache. *JAMA.* 1998;279(5):381–3. <http://www.ncbi.nlm.nih.gov/pubmed/9459472>.
17. Kwiatkowski T, Friedman B. Headache disorders. In: Marx J, Hockberger R, Walls R, editors. *Rosen's emergency medicine—concepts and clinical practice.* 8th ed. Philadelphia: Saunders; 2013. p. 1043–55. <http://dx.doi.org/10.1016/B978-1-4557-0605-1.00103-2>.
18. Robbins MS, Lipton RB. The epidemiology of primary headache disorders. *Semin Neurol.* 2010;30(2):107–19.
19. Perry JJ, Stiell IG, Sivilotti ML, Bullard MJ, Hohl CM, Sutherland J, et al. Clinical decision rules to rule out subarachnoid hemorrhage for acute headache. *JAMA.* 2013;310(12):1248–55. <http://www.ncbi.nlm.nih.gov/pubmed/24065011>.
20. Gorelick PB, Hier DB, Caplan LR, Langenberg P. Headache in acute cerebrovascular disease. *Neurology.* 1986;36(11):1445–50. <http://www.ncbi.nlm.nih.gov/pubmed/3762963>.
21. van Gijn J, Kerr RS, Rinkel GJ. Subarachnoid haemorrhage. *Lancet.* 2007;369(9558):306–18. <http://www.ncbi.nlm.nih.gov/pubmed/17258671>.
22. Clinical manifestations and diagnosis of aneurysmal subarachnoid hemorrhage. UpToDate. 2017. [https://www.uptodate.com/contents/clinical-manifestations-and-diagnosis-of-aneurysmal-subarachnoid-hemorrhage?source=machineLearning&search=subarachnoid hemorrhage&selectedTitle=1~150§ionRank=1&anchor=H26#H12](https://www.uptodate.com/contents/clinical-manifestations-and-diagnosis-of-aneurysmal-subarachnoid-hemorrhage?source=machineLearning&search=subarachnoid%20hemorrhage&selectedTitle=1~150§ionRank=1&anchor=H26#H12).

23. Fine B, Singh N, Aviv R, Macdonald RL. Decisions: does a patient with a thunderclap headache need a lumbar puncture? *CMAJ*. 2012;184(5):555–6. doi:[10.1503/cmaj.110517](https://doi.org/10.1503/cmaj.110517).
24. Thunderclap headache. UpToDate. 2017. <https://www.uptodate.com/contents/thunderclap-headache>.
25. Perry JJ, Alyahya B, Sivilotti MLA, Bullard MJ, Émond M, Sutherland J, et al. Differentiation between traumatic tap and aneurysmal subarachnoid hemorrhage: prospective cohort study. *BMJ*. 2015;350(feb18_8):h568. <http://www.bmj.com.ezp-prod1.hul.harvard.edu/content/350/bmj.h568>.
26. van Gijn J, van Dongen KJ, Vermeulen M, Hijdra A. Perimesencephalic hemorrhage: a non-aneurysmal and benign form of subarachnoid hemorrhage. *Neurology*. 1985;35(4):493–7.
27. Schievink WI, Schaid DJ, Michels VV, Piepgras DG. Familial aneurysmal subarachnoid hemorrhage: a community-based study. *J Neurosurg*. 1995;83(3):426–9.
28. Nahed BV, Bydon M, Ozturk AK, Bilguvar K, Bayrakli F, Gunel M. Genetics of intracranial aneurysms. *Neurosurgery*. 2007;60(2):213–26. <https://academic.oup.com/neurosurgery/article/2564070/Genetics>.
29. Juvela S, Siironen J, Kuhmonen J. Hyperglycemia, excess weight, and history of hypertension as risk factors for poor outcome and cerebral infarction after aneurysmal subarachnoid hemorrhage. *J Neurosurg*. 2005;102(6):998–1003. <http://www.ncbi.nlm.nih.gov/pubmed/16028757>.
30. Ohashi Y, Horikoshi T, Sugita M, Yagishita T, Nukui H. Size of cerebral aneurysms and related factors in patients with subarachnoid hemorrhage. *Surg Neurol*. 2004;61(3):237–9. <http://www.ncbi.nlm.nih.gov/pubmed/14984993>.
31. Connolly ES, Rabinstein AA, Carhuapoma JR, Derdeyn CP, Dion J, Higashida RT, et al. Guidelines for the management of aneurysmal subarachnoid hemorrhage: a guideline for healthcare professionals from the American Heart Association/American Stroke Association. *Stroke*. 2012;43:1711–37.
32. Heasley DC, Mohamed MA, Yousem DM. Clearing of red blood cells in lumbar puncture does not rule out ruptured aneurysm in patients with suspected subarachnoid hemorrhage but negative head CT findings. *Am J Neuroradiol*. 2005;26(4):820–4.
33. Buruma OJ, Janson HL, Den Bergh FA, Bots GT. Blood-stained cerebrospinal fluid: traumatic puncture or haemorrhage? *J Neurol Neurosurg Psychiatry*. 1981;44(August 1980):144–7.
34. Petzold A, Keir G, Sharpe TL. Why human color vision cannot reliably detect cerebrospinal fluid xanthochromia. *Stroke*. 2005;36(6):1295–7.
35. Perry JJ, Sivilotti MLA, Stiell IG, Wells GA, Raymond J, Mortensen M, et al. Should spectrophotometry be used to identify xanthochromia in the cerebrospinal fluid of alert patients suspected of having subarachnoid hemorrhage? *Stroke*. 2006;37(10):2467–72.
36. Chu K, Hann A, Greenslade J, Williams J, Brown A. Spectrophotometry or visual inspection to most reliably detect xanthochromia in subarachnoid hemorrhage: systematic review. *Ann Emerg Med*. 2014;64(3):256–264.e5. doi:[10.1016/j.annemergmed.2014.01.023](https://doi.org/10.1016/j.annemergmed.2014.01.023).
37. Hann A, Chu K, Greenslade J, Williams J, Brown A. Benefit of cerebrospinal fluid spectrophotometry in the assessment of CT scan negative suspected subarachnoid haemorrhage: a diagnostic accuracy study. *J Clin Neurosci*. 2015;22(1):173–9. doi:[10.1016/j.jocn.2014.07.025](https://doi.org/10.1016/j.jocn.2014.07.025).
38. Beetham R. CSF spectrophotometry for bilirubin—why and how? *Scand J Clin Lab Invest*. 2009;69(1):1–7.
39. Arora S, Swadron SP, Dissanayake V. Evaluating the sensitivity of visual xanthochromia in patients with subarachnoid hemorrhage. *J Emerg Med*. 2010;39(1):13–6. doi:[10.1016/j.jemermed.2007.09.052](https://doi.org/10.1016/j.jemermed.2007.09.052).
40. McCormack RF, Hutson A. Can computed tomography angiography of the brain replace lumbar puncture in the evaluation of acute-onset headache after a negative noncontrast cranial computed tomography scan? *Acad Emerg Med*. 2010;17(4):444–51.
41. Ward MJ, Bonomo JB, Adeoye O, Raja AS, Pines JM. Cost-effectiveness of diagnostic strategies for evaluation of suspected subarachnoid hemorrhage in the emergency department. *Acad Emerg Med*. 2012;19(10):1134–44. <http://www.ncbi.nlm.nih.gov/pubmed/23067018>.
42. Carstairs SD, Tanen DA, Duncan TD, Nordling OB, Wanebo JE, Paluska TR, et al. Computed tomographic angiography for the evaluation of aneurysmal subarachnoid hemorrhage. *Acad Emerg Med*. 2006;13(5):486–92. <http://www.ncbi.nlm.nih.gov/pubmed/16551778>.

43. Malhotra A, Wu X, Kalra VB, Schindler J, Forman HP. Cost-effectiveness analysis of follow-up strategies for thunderclap headache patients with negative noncontrast CT. *Acad Emerg Med.* 2016;23(3):243–50. <http://www.ncbi.nlm.nih.gov/pubmed/26728524>.
44. Brunell A, Ridefelt P, Zelano J. Differential diagnostic yield of lumbar puncture in investigation of suspected subarachnoid haemorrhage: a retrospective study. *J Neurol.* 2013;260(6):1631–6. <http://www.ncbi.nlm.nih.gov/pubmed/23358626>.
45. Meurer WJ, Walsh B, Vilke GM, Coyne CJ. Clinical guidelines for the emergency department evaluation of subarachnoid hemorrhage. *J Emerg Med.* 2016;50(4):696–701.
46. Jehle D, Chae F, Wai J, Cloud S, Pierce D, Meyer M. Case series of 64 slice computed tomography-computed tomographic angiography with 3D reconstruction to diagnose symptomatic cerebral aneurysms: new standard of care? *Neurol Int.* 2012;4, 2(1). <http://www.ncbi.nlm.nih.gov/pubmed/22593806>.
47. Schwedt TJ, Matharu MS, Dodick DW. Thunderclap headache. *Lancet Neurol.* 2006;5(7):621–31.
48. Chen S, Fuh J, Lirng J, Yang Y, Wang S. Recurrence of reversible cerebral vasoconstriction syndrome. *Neurology.* 2015;84(15):1552–8.
49. Akhter MA, Chen S-P, Burton JH. Vascular emergencies and shared decision making in patients with thunderclap headache. *Acad Emerg Med.* 2016. doi:10.1111/acem.13031.
50. Long B, Koyfman A. Controversies in the diagnosis of subarachnoid hemorrhage. *J Emerg Med.* 2016;50(6):839–47. <http://www.ncbi.nlm.nih.gov/pubmed/27216942>.
51. Probst MA, Hoffman JR. Computed tomography angiography of the head is a reasonable next test after a negative noncontrast head computed tomography result in the emergency department evaluation of subarachnoid hemorrhage. *Ann Emerg Med.* 2016;67(6):773–4. <http://www.ncbi.nlm.nih.gov/pubmed/27217126>.
52. Broder J, Preston R. Chapter 1: Imaging the head and brain. In: *Diagnostic imaging for the emergency physician.* 2011. p. 1–45.
53. Mosenthal AC, Lavery RF, Addis M, Kaul S, Ross S, Marburger R, et al. Isolated traumatic brain injury: age is an independent predictor of mortality and early outcome. *J Trauma.* 2002;52(5):907–11.
54. Iantosca MR, Simon RH. Chronic subdural hematoma in adult and elderly patients. *Neurosurg Clin N Am.* 2000;11(320377466):447–54.
55. Machulda MM, Haut MW. Clinical features of chronic subdural hematoma: neuropsychiatric and neuropsychologic changes in patients with chronic subdural hematoma. *Neurosurg Clin N Am.* 2000;11(3):473–7. <http://www.ncbi.nlm.nih.gov/pubmed/10918017>.
56. Catana D, Koziarz A, Cenic A, Nath S, Singh S, Almenawer SA, et al. Subdural hematoma mimickers: a systematic review. *World Neurosurg.* 2016;93:73–80.
57. Ferro JM, Canhão P, Stam J, Boussier M-G, Barinagarrementeria F. Investigators for the I. Prognosis of cerebral vein and dural sinus thrombosis: results of the international study on cerebral vein and dural sinus thrombosis (ISCVT). *Stroke.* 2004;35(3):664–70.
58. Boussier MG, Ferro JM. Cerebral venous thrombosis: an update. *Lancet Neurol.* 2007;6(2):162–70.
59. Saposnik G, Barinagarrementeria F, Brown RD, Bushnell CD, Cucchiara B, Cushman M, et al. Diagnosis and management of cerebral venous thrombosis: a statement for healthcare professionals from the American Heart Association/American Stroke Association. *Stroke.* 2011;42(4):1158–92. doi:10.1161/STR.0b013e31820a8364.
60. Canhão P, Ferro JM, Lindgren AG, Boussier MG, Stam J, Barinagarrementeria F. Causes and predictors of death in cerebral venous thrombosis. *Stroke.* 2005;36(8):1720–5.
61. Crassard I, Boussier MG. Headache in patients with cerebral venous thrombosis. *Rev Neurol.* 2005;161(6–7):706–8.
62. Kosinski CM, Mull M, Schwarz M, Koch B, Biniek R, Schäfer J, et al. Do normal D-dimer levels reliably exclude cerebral sinus thrombosis? *Stroke.* 2004;35(12):2820–5.
63. Dentali F, Squizzato A, Marchesi C, Bonzini M, Ferro JM, Ageno W. D-dimer testing in the diagnosis of cerebral vein thrombosis: a systematic review and a meta-analysis of the literature. *J Thromb Haemost.* 2012;10(4):582–9. <http://ovidsp.ovid.com/ovidweb.cgi?T=JS&PAGE=reference&D=emed14&NEWS=N&AN=364548005>.

64. Wetzel SG, Kirsch E, Stock KW, Kolbe M, Kaim A, Radue EW. Cerebral veins: comparative study of CT venography with intraarterial digital subtraction angiography. *Am J Neuroradiol.* 1999;20(2):249–55.
65. Robertson JJ, Koyfman A. Cervical artery dissections: a review. *J Emerg Med.* 2016;51(5):508–18.
66. Janssen SP, Comans EH, Voskuyl AE, Wisselink W, Smulders YM. Giant cell arteritis: heterogeneity in clinical presentation and imaging results. *J Vasc Surg.* 2008;48(4):1025–31. [http://www.jvascsurg.org/article/S0741-5214\(08\)00698-8/pdf](http://www.jvascsurg.org/article/S0741-5214(08)00698-8/pdf).
67. Ninan J, Lester S, Hill C. Giant cell arteritis. *Best Pract Res Clin Rheumatol.* 2016;30(1):169–88. <http://www.ncbi.nlm.nih.gov/pubmed/27421223>.
68. Gus M, Fuchs FD, Pimentel M, Rosa D, Melo AG, Moreira LB. Behavior of ambulatory blood pressure surrounding episodes of headache in mildly hypertensive patients. *Arch Intern Med.* 2001;161:252–5.
69. Billeci D, Marton E, Giordan E. Post-traumatic pituitary apoplexy: case presentation and review of literature. *Interdisciplinary Neurosurgery.* 2017;7:4–8.
70. Nassar BR, Lippa CF. Idiopathic normal pressure hydrocephalus: a review for general practitioners. *Gerontol Geriatr Med.* 2016;2:2333721416643702. <http://www.ncbi.nlm.nih.gov/pubmed/28138494>.
71. Kurlan R, Schwalb JM, Cusimano MD. Practice guideline: idiopathic normal pressure hydrocephalus: response to shunting and predictors of response. *Neurology.* 2015;85:2063–71.
72. Contreras-Martin Y, Bueno-Perdomo JH. Idiopathic intracranial hypertension: descriptive analysis in our setting. *Neurologia.* 2015;30(2):106–10. <http://www.ncbi.nlm.nih.gov/pubmed/24332560>.
73. Contreras-Martin Y, Bueno-Perdomo JH. Idiopathic intracranial hypertension: descriptive analysis in our setting. *Neurologia.* 2013.
74. King RB, Davis RL, Collins GH. Third ventriculostomy for internal hydrocephalus complicated by unrecognized subdural hygroma and hematoma: a case report of a patient treated by Dr. Walter Dandy. *J Neurosurg.* 2003;98(5):1136–40. <http://thejns.org/doi/10.3171/jns.2003.98.5.1136>.
75. Shaw GY, Million SK. Benign intracranial hypertension: a diagnostic dilemma. *Case Rep Otolaryngol.* 2012;2012:814696. <http://www.pubmedcentral.nih.gov/articlerender.fcgi?artid=3423822&tool=pmcentrez&rendertype=abstract>.
76. Portelli M, Papageorgiou PN. An update on idiopathic intracranial hypertension. *Acta Neurochir.* 2017;159(3):491–9. <http://www.ncbi.nlm.nih.gov/pubmed/28013373>.
77. Liguori C, Romigi A, Albanese M, Marciani MG, Placidi F, Friedman D, et al. Revised diagnostic criteria for the pseudotumor cerebri syndrome in adults and children. *Neurology.* 2014;82(19):1752–3. <http://www.ncbi.nlm.nih.gov/pubmed/24821936>.
78. Mollan SP, Ali F, Hassan-Smith G, Botfield H, Friedman DI, Sinclair AJ. Evolving evidence in adult idiopathic intracranial hypertension: pathophysiology and management. *J Neurol Neurosurg Psychiatry.* 2016;87(9):982–92. <http://www.ncbi.nlm.nih.gov/pubmed/26888960>.
79. Smith JL. Whence pseudotumor cerebri? *J Clin Neuroophthalmol.* 1985;5(1):55–6. <http://www.ncbi.nlm.nih.gov/pubmed/3156890>.
80. Bidot S, Saïndane AM, Peragallo JH, Bruce BB, Newman NJ, Biousse V. Brain imaging in idiopathic intracranial hypertension. *J Neuroophthalmol.* 2015;35(4):400–11. <http://www.ncbi.nlm.nih.gov/pubmed/26457687>.
81. Sun X, Dai Y, Chen Y, Yu D-Y, Cringle SJ, Chen J, et al. Primary angle closure glaucoma: what we know and what we don't know. *Prog Retin Eye Res.* 2016. <http://linkinghub.elsevier.com/retrieve/pii/S1350946216300519>.
82. Ruggeri-McKinley AN, McKinley BC. The commonly missed diagnosis of intracranial hypotension. *Interdiscip Neurosurg.* 2016;4:11–2.
83. Engedal TS, Ørding H, Vilholm OJ. Changing the needle for lumbar punctures: results from a prospective study. *Clin Neurol Neurosurg.* 2015;130:74–9.
84. Prasad K, Karlupia N. Prevention of bacterial meningitis: an overview of Cochrane systematic reviews. *Respir Med.* 2007;101(10):2037–43.

85. Morales Casado MI, Moreno Alonso F, Juárez Belaunde AL, Heredero Gálvez E, Talavera Encinas O, Julián-Jiménez A. Ability of procalcitonin to predict bacterial meningitis in the emergency department. *Neurologia*. 2016;31(1):9–17. <http://linkinghub.elsevier.com/retrieve/pii/S0213485314001662>.
86. Thomas KE, Hasbun R, Jekel J, Quagliarello VJ. The diagnostic accuracy of Kernig's sign, Brudzinski's sign, and nuchal rigidity in adults with suspected meningitis. *Clin Infect Dis*. 2002;35(1999):46–52.
87. Parameters P. The utility of neuroimaging in the evaluation of headache in patients with normal neurologic examinations (summary statements). *Neurology*. 1994;44:1353–4.
88. Steigbigel NH. Computed tomography of the head before a lumbar puncture in suspected meningitis—is it helpful? *N Engl J Med*. 2001;345(24):1768–70.
89. Cutrer FM. Evaluation of the adult with headache in the emergency department. UpToDate. 2017.
90. Euerle BD. Spinal puncture and cerebrospinal fluid examination. In: Roberts JR, editor. *Roberts' and hedges' clinical procedures in emergency medicine*. 6th ed. Philadelphia: Elsevier. p. 1107–27.
91. Fink KR, Benjert JL. Imaging of nontraumatic neuroradiology emergencies. *Radiol Clin N Am*. 2015;53(4):871–90.
92. Marx JA, Hockberger RS, Walls RM, Adams J, Rosen P. *Rosen's emergency medicine: concepts and clinical practice*. Emergency Medicine. 2010. p. 2339–40.
93. Friedman BW, Grosberg BM. Diagnosis and management of the primary headache disorders in the emergency department setting. *Emerg Med Clin North Am*. 2009;27(1):71–87.
94. Myers DE, Myers RA. A preliminary report on hyperbaric oxygen in the relief of migraine headache. *Headache*. 1995;35(4):197–9.

John W. Martel and J. Brooks Motley

Acute Back Pain

Case 1: A 39-year-old male with a history of intravenous drug use (IVDU) presents to the ED with a complaint of low back pain. On two prior visits, he was thought to have an etiology of musculoskeletal pain and was discharged after symptomatic treatment. He now complains of numbness in his groin, difficulty urinating, and weakness in his legs. He denies fever or trauma. MRI of his lumbar spine shows an epidural abscess causing compression of the cauda equina nerve roots. He is taken emergently to the OR for decompression.

Introduction

Back pain is a common reason for seeking medical evaluation in the United States and is one of the top five most common emergency department (ED) chief complaints [1, 2]. Approximately 85–90% of patients complaining of back pain ultimately have no clear etiology for their discomfort and experience varying degrees of pain relief within 4–6 weeks irrespective of therapy [3–6]. The challenge for the emergency physician is to identify the rare patient with a catastrophic etiology of back pain from the majority of patients who present with benign causes. Approximately 2% of acute back pain complaints are attributed to life and/or function-threatening processes [7].

J.W. Martel, M.D., Ph.D., F.A.C.E.P. (✉)
Tufts University School of Medicine, Boston, MA, USA
e-mail: JMartel@mmc.org

J.B. Motley, M.D.
Maine Medical Center, Portland, Maine, USA

Neck pain is also a common complaint in US adults but does not occur as frequently as lower back pain or present the same degree of disease burden with respect to physical disability, decreased productivity/income loss, and health-care expenditure [8]. As with back pain, there are high-risk diagnoses to consider when distinguishing between who can be safely discharged from the ED with conservative treatment and what presentations require further acute evaluation.

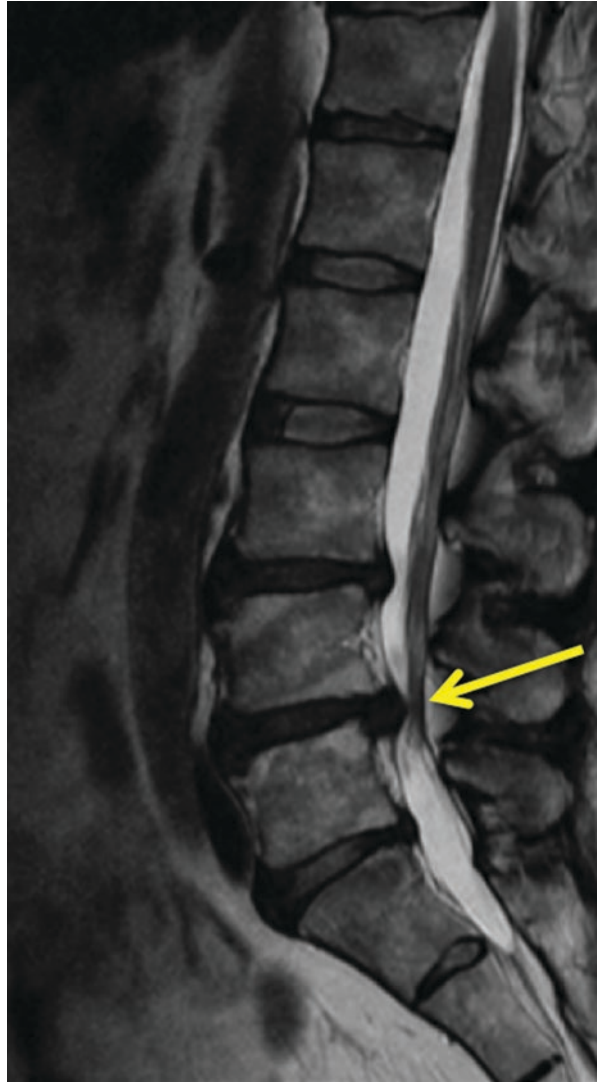
Emergent Differential Diagnosis

- Spinal cord or nerve root compression
 - Cauda equina syndrome
 - Disk herniation with neurologic compromise
 - Malignancy
- Vascular catastrophe
 - Aortic dissection
 - Ruptured AAA
- Infection
 - Epidural abscess
 - Vertebral osteomyelitis
- Malignancy
 - Primary spinal neoplasm
 - Metastatic disease

Spinal cord or nerve root compression: Intervertebral disks exhibit varying degrees of mechanical degeneration over time, usually starting in the third decade of life. Traumatic and age-related tears in the ligamentous annulus fibrosus increase the risk of nucleus pulposus herniation from out of the central cavity, thereby placing local nerve roots or the spinal cord itself at risk for acute compression (see Fig. 9.1). Spinal cord compression can also be caused by a wide variety of other mechanisms, including epidural abscess, osteomyelitis, primary neoplasm or metastatic disease, postoperative hematoma, or trauma [9].

The adult spinal cord generally terminates at the level of L1, and distal to this point exist the spinal roots known collectively as cauda equina. The primary role of this cord region is sensorimotor innervation to multiple structures, including the urinary bladder, perineum, and lower extremities. *Cauda equina syndrome* is an acute surgical emergency comprised of several key “red flag” symptoms, including urinary retention, fecal and/or urinary overflow incontinence, decreased rectal tone, and loss of perineal sensation referred to as “saddle anesthesia.” It has the potential to be a permanent function-limiting process that is often attributed to large central disk herniations. However, it can also occur with the majority of other pathologies previously described [7].

Fig. 9.1 L4/L5 paracentral disk herniation (*arrow*), on T2-weighted MR image



Vascular catastrophe: Aortic dissection and ruptured abdominal aortic aneurysm (rAAA) can both present with acute back pain. Patients experiencing aortic dissection typically report severe acute back pain, often described as a sudden-onset, ripping/tearing sensation. Although complaint of abdominal pain is more common in rAAA, back pain has been reported to occur in nearly 20% of cases [10]. It is also important to consider the possibility of endovascular leak as a remote complication of prior AAA repair in the context of acute back pain and appropriate past medical

history [11]. Mortality in acute aortic dissection increases by as much as 1% per hour in the early stages [12]. In untreated patients, mortality approaches 50% in the first 48 h and increases to 90% within 3 months [13]. Similarly, rAAA is associated with 90% mortality when untreated [14].

Infection: Spinal epidural abscess and vertebral osteomyelitis (see Fig. 9.2) are causes of serious infection in some patients complaining of back pain [7]. Spinal epidural abscess is a relatively uncommon but serious infection of the central nervous system (CNS) that generally involves three to five contiguous vertebral levels and most commonly manifests in the thoracolumbar region. It has been reported that the larger epidural spaces and fat-containing tissues in this region contain more extensive extradural venous plexus and are subsequently at risk for acute infection per hematogenous spread [15, 16]. However, they certainly can occur at any point along the spine and may feature noncontiguous lesion distributions as well [15]. In addition,

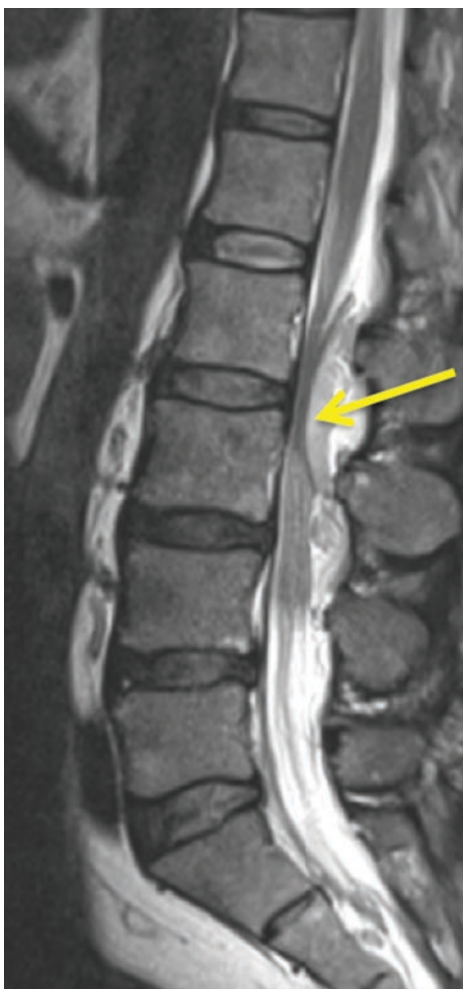
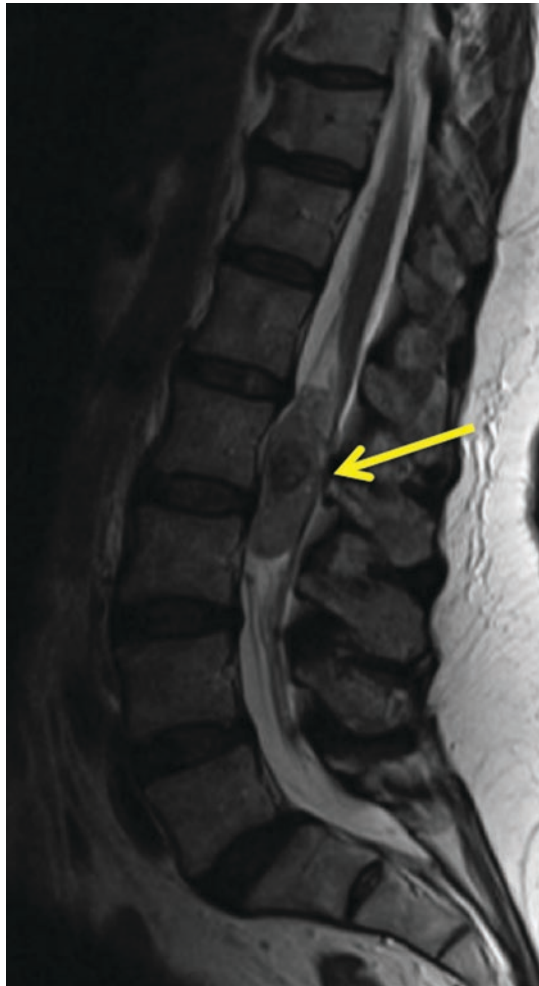

Fig. 9.2 Epidural abscess. T2-weighted MR image depicting an abscess (*arrow*) extending from the T12/L1 level to the sacrum, with associated spinal canal stenosis and cauda equina nerve root compression

Fig. 9.3 Spinal neoplasm. (arrow) T2-weighted MR image of schwannoma that fills the spinal canal in a patient with classic symptoms of cauda equina syndrome



this process may also arise as a result of local muscle or disk infection or from direct inoculation of the spinal canal during invasive procedures. Epidural abscesses are associated with a wide array of morbidities, including acute spinal cord compression, compromise of local blood supply, thrombophlebitis, and sepsis. Both entities are primarily considered to be diseases impacting adult males older than age 50 [17]. The steady increase in the incidence reported over the last 30 years has been attributed to increased IVDU, increased average patient age, and increased rates of infections associated with invasive procedures and indwelling medical devices [18, 19]. These infectious etiologies often initially present without systemic symptoms and are frequently diagnosed only after multiple visits to various health-care providers [17].

Malignancy: Metastatic involvement of the bone is commonly seen in a variety of neoplastic processes, including primary breast, lung, prostate, kidney, and thyroid carcinomas (see Fig. 9.3). An estimated 80% of cancer patients who present

with acute back pain may actually have associated underlying metastatic disease. In contrast, primary neoplastic processes of the spine are quite uncommon and comprise only 0.7% of total patients presenting with this complaint [7].

History

A careful, targeted history is vital to estimating a given patient's pretest probability of presenting with an emergent diagnosis. The past medical history may point to a particular organ system as the root cause of the complaint, including known previous AAA, peripheral vascular disease, IVDU, prior/current indwelling vascular access, previous back surgery, or malignancy. Any significant trauma associated with the onset of pain should prompt consideration of acute fracture.

Surveillance for emergent pathology may be facilitated via screening for so-called *red flag signs and symptoms* that are widely used to help identify potentially life-threatening etiologies of acute back pain (see Table 9.1). However, it is important to note that screening in this manner is often complicated by a high false-positive rate. A recent study showed that only 0.9% of patients presenting with acute low back pain ultimately are determined to have an emergent diagnosis, yet 80% of the patients reported at least one positive red flag sign or symptom [20]. Therefore, it is crucial that clinicians gather key historical information and consider the entire clinical picture before moving forward diagnostically.

Table 9.1 Acute back pain red flag signs and symptoms of back pain [6, 65]

History	Exam
Age > 50 or <30 years old	Neurologic findings (for >4 weeks)
History of cancer	Saddle anesthesia
Unexplained weight loss	Loss of anal sphincter tone
Immunosuppression	Major motor weakness in lower extremities
Prolonged use of steroids	Fever
Intravenous drug use	Vertebral tenderness
Known aortic aneurysm	Limited spinal range of motion
Pain increased or unrelieved by rest	
Persistent fevers and/or night sweats	
Significant trauma	
Bladder or bowel incontinence	
Urinary retention	

Physical Examination

A complete physical examination in the setting of back pain includes evaluation of the musculoskeletal, neurologic, and vascular systems, with several maneuvers tailored to the specific complaint. Incomplete clinical evaluation may lead to unnecessary pursuit of advanced imaging that does not improve patient outcome, places patients at additional risk, and inappropriately increases health-care expenditures [21–23].

Abnormal vital signs are important to consider. An initial rapid assessment of overall clinical status may reveal fever, tachycardia, or hypotension, all of which are unexpected in the setting of acute mechanical back pain and are concerning for potentially serious underlying pathologies.

The musculoskeletal examination is comprised of systematic palpation of paravertebral musculature and midline vertebral evaluation of the entire spine, including the sacroiliac joints and hips. These maneuvers may elucidate focal muscle or vertebral tenderness. Midline tenderness is generally more concerning than focal paraspinal muscle tenderness, though this is not specific to any particular pathology and inter-rater reliability is thought to be poor [7, 24].

It is important to perform a thorough neurologic examination; key elements include specific evaluation of motor power, sensation, and reflexes (Fig. 9.4, Table 9.2). The majority of symptomatic disk herniations occur at the L4, L5, and/or S1 levels and often present with predictable patterns of sensorimotor deficit [7, 25]. The *straight leg raise* and *slump tests* elicit radicular symptoms with varying degrees of sensitivity and specificity. The former is performed while the patient is supine by elevating the affected lower extremity after extending the knee. A positive test occurs when pain radiates distal to the knee in a dermatomal distribution when the leg is at an angle less than 90°. In contrast, the slump test is performed in the seated position. While both hips and knees flexed to 90°, the patient “slumps” forward while the examiner applies pressure over the thoracic spine to flex the patient’s neck. The knee and foot of the affected extremity are then extended and dorsiflexed, respectively. In this case, a positive test elicits radicular lower extremity symptoms in a dermatomal distribution. Sensitivities of these tests are variable. There is a reported sensitivity range of 50–80%, with specificities between 80 and 90% [7, 26]. Of note, a positive test does not mandate further emergent evaluation if no sensorimotor deficits are identified. Instead, such results help narrow the differential for the cause of discomfort and may aid in establishing appropriate outpatient follow-up. In addition, gait testing provides invaluable information with regard to overall mechanical and neurologic functioning and should be assessed in patients that are able to comply.







Nerve root	L4	L5	S1
Pain			
Numbness			
Motor weakness	Extension of quadriceps.	Dorsiflexion of great toe and foot.	Plantar flexion of great toe and foot.
Screening exam	Squat & rise.	Heel walking.	Walking on toes.
Reflexes	Knee jerk diminished.	None reliable.	Ankle jerk diminished.

Fig. 9.4 Dermatomal symptoms associated with L4-S1 nerve root compromise (*Adapted from Bigos S et al. [6] (public domain)*)

Saddle anesthesia, urinary retention, and fecal or urinary overflow incontinence are all part of an alarming suite of symptoms concerning for cauda equina syndrome [27, 28]. Urinary retention has a reported sensitivity of 90%, and the absence of a significant post-void residual (PVR) has a negative predictive value of 99.9% [24]. Although PVR greater than 100 cm³ may be abnormal in the appropriate clinical context, PVR greater than 300 cm³ is considered pathologic. Nearly 75% of patients with acute spinal cord compression have objective impairment of perineal sensation

Table 9.2 Neurologic exam findings associated with L1-S1 nerve roots

Nerve root	Reflex	Pain distribution	Motor weakness	Sensory loss
L1	Cremasteric	Inguinal	Hip flexion	Inguinal
L2	Cremasteric, thigh adductor	Inguinal, anterior thigh	Hip flexion and adduction	Anterior thigh
L3	Patellar	Anterior thigh, knee	Quadriceps adductors	Anterior, medial thigh
L4	Patellar	Anterior thigh, medial leg	Knee extension, hip flexion	Anterior leg, first toe, medial malleolus
L5	None	Posterolateral thigh, lateral leg	Great toe dorsiflexion	Dorsal foot, middle three toes
S1	Achilles	Posterior thigh and leg, lateral foot	Plantar flexion	Lateral foot, heel

(saddle anesthesia) as well as lower extremity sensorimotor deficit. Up to 50% of patients present with foot drop and an absent ankle reflex [29]. Diminished rectal tone is also very concerning within this clinical context and should be assessed per digital rectal exam [30].

In addition to a thorough neurologic examination, evaluation of peripheral pulses helps screen for serious vascular pathology such as aortic dissection or rAAA, and a thorough abdominal examination may yield pulsatile masses indicative of rAAA. A combination of severe pain, palpable abdominal pulsatile mass, and hypotension is seen in approximately 50% of rAAA [10, 31]. When combined with widened mediastinum (CXR), peripheral pulse deficits and/or hypotension are associated with 96% of dissections [32]. Bedside ultrasonography (US) is a vital tool to rapidly evaluate for the presence of AAA.

Given the sheer volume of annual ED back pain presentations in the US, it is also important to evaluate for potential psychosocial and nonorganic elements. This is important for improving the use of clinical resources as well as minimizing the risk of adverse effects associated with radiation and contrast exposure. The *Waddell signs* (see Table 9.3) were developed to evaluate nonorganic components of acute back pain complaints. The overall test is considered to be positive when a patient scores positively in three or more categories. This suggests a potentially nonorganic basis of the complaint and is associated with coexisting psychiatric pathology [33]. However, malingering and underlying psychosocial etiologies of acute back pain remain diagnoses of exclusion.

Emergency Department Workup

The initial goal in diagnosing back pain in the ED is to rule out life-threatening or disabling disease. This can often be accomplished by obtaining a thorough history and performing a complete physical examination as described above but in some cases requires neuroimaging.

Table 9.3 Waddell's signs suggestive of nonorganic back pain

Category	Nonorganic test	Nonorganic sign
Tenderness	Superficial	Widespread tenderness to light pinches over lumbar skin
	Nonanatomic	Deep tenderness over a wide area, not localized to one structure; often extends to thoracic spine, sacrum, or pelvis
Stimulation	Axial loading	Low back pain reported even when light pressure is given on the patient's head while standing
	Rotation	Low back pain reported when the shoulders and pelvis are passively rotated in the same plane as the patient stands with his feet together
Distraction	Distraction	Inconsistent limitation of straight leg raising in supine and seated position
Regional disturbance	Weakness	Partial cogwheel giving way in many muscle groups
	Sensory	Sensory disturbances include diminished sensation to light-touch, pinprick, and sometimes other modalities, in a "stocking" rather than a dermatomal pattern
Overreaction	Overreaction	Disproportionate verbalization, facial expression, muscle tension and tremor, collapsing, or sweating during examination

Adapted from Apeldoorn et al. [33]

Neuroimaging

The vast majority of patients presenting to the ED with back pain do not require emergent imaging. Routine plain films generally are not indicated given the low utility and adverse effect of radiation exposure [6]. If no red flag signs or symptoms are present and the pain has been present for less than 4 weeks, no further evaluation is often necessary. However, in the setting of concerning historical or physical exam elements, imaging may be warranted.

Spinal Cord Compression

Magnetic resonance imaging (MRI) is the diagnostic imaging test of choice in the evaluation of compressive etiologies, including spinal epidural abscess (see Fig. 9.2) and disk herniation, as well as in vertebral osteomyelitis and vertebral body metastatic lesions [34]. Gadolinium-enhanced MRI is generally used for epidural abscess and vertebral osteomyelitis evaluation and is considered highly sensitive and specific for both entities [35, 36]. Evaluation of neoplastic spinal mass and metastatic disease is usually performed both with and without contrast. Contrast is not typically used when specifically evaluating for acute disk herniation.

Vascular Emergencies

Bedside US may aid in rapid diagnosis of AAA as both sensitivity and specificity approach 100% for non-ruptured AAA with an aortic diameter greater than 3.0 cm

[37, 38]. Computed tomography angiogram (CTA) is considered to be better than US for evaluating suprarenal aneurysms, discerning between ruptured and non-ruptured aneurysms, and screening for potential endovascular leak [39, 40]. Although many centers use IV contrast, it is not required to evaluate for rAAA and may be associated with contrast-induced nephropathy in the context of acute volume depletion and chronic kidney disease [41]. CTA is the study of choice when evaluating for aortic dissection.

Acute Neck Pain

Case 2: An 80-year-old male with a history of hypertension, hyperlipidemia, CAD, and diabetes presents to the emergency department complaining of left-sided neck pain radiating to his left ear. There had been no preceding trauma or invasive procedures. His neurologic exam was normal. He was treated for myofascial neck pain and discharged home. Once home he developed abrupt onset of vertigo and returned to the ED. A CTA of his head and neck revealed a left vertebral artery dissection.

It has been reported that up to 16% of US adults report neck pain annually, with one third also reporting concomitant lower back pain [42]. Several risk factors for developing neck pain have been reported and include history of previous injury [43], workplace-related physical demands, and female gender [43, 44]. Neck pain symptoms may arise either from local anatomical structures or be referred. A specific etiology is often not identified, even when radiographic imaging is obtained [45]. Symptoms concerning for potentially clinically significant disease include (1) prior history of acute or prior localized traumatic injury; (2) evidence of systemic illness, the presence of a structural mass/history of neoplasm, immunosuppression, or IVDU; (3) the presence of acute neurological deficits; (4) anterior neck pain (generally a non-spinal etiology); and (5) acute neck pain associated with headache, vision change (e.g., temporal arteritis), or concomitant muscle girdle discomfort (e.g., polymyalgia rheumatica).

Common and Concerning Causes of Neck Pain

- Cervical strain
- Cervical radiculopathy
- Cervical artery dissection
- Meningitis
- Cord compression

Cervical strain: Acute strain of neck musculature is associated with a wide variety of nontraumatic causes, ranging from sleeping position to posture. There may be associated upper back and shoulder tenderness that can persist for up to 6 weeks. It

is thought to occur secondary to mild cervical paravertebral musculature injury and is typically associated with spasm. However, there are no acute neurological deficits associated with this syndrome, and if present, suggest a different and potentially more serious etiology.

Cervical radiculopathy: Discomfort associated with cervical disk herniation often is attributed to compression of nerve roots, leading to radiating upper extremity discomfort described as having a similar character to sciatica pain in the lower extremity. It has been estimated that up to 22% of patients reporting cervical radicular discomfort have an associated lateral disk herniation [46].

Cervical artery dissection: Carotid and vertebral artery dissections occur with intimal wall disruption that enables creation of a false lumen and accumulation of blood leading to formation of an intramural hematoma (see Fig. 9.5). They are commonly associated with headache, neck pain, as well as acute neurological deficits in more severe cases. In particular, patients may present with Horner's syndrome, which is comprised of a triad of ptosis, miosis, and anhydrosis. This deficit is seen in approximately 25% of cases and has been attributed to distension of sympathetic fibers that traverse the external surface of the internal carotid artery [47]. In addition, cranial nerve deficits and cervical nerve root impingement may also be seen [48]. Spontaneous cervical artery dissections are known to occur in association with minor trauma (e.g., sports-related) and connective tissue disease (e.g., Marfan syndrome) and are considered to be a leading cause of stroke in patients under age 40 [49].

Meningitis: Acute neck pain is commonly reported by patients with inflammation of the leptomeninges that surround the brain and spinal cord. Bacterial meningitis is considered one of the ten most common infectious causes of death worldwide [50]. Likewise, neck pain may be associated with the more common and less deadly

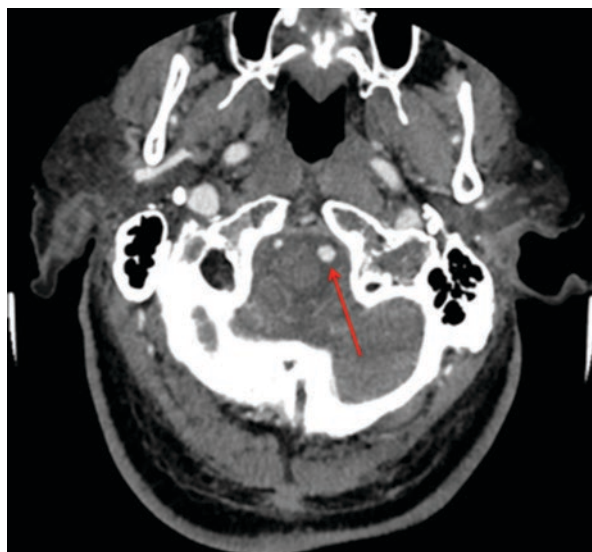


Fig. 9.5 Vertebral artery dissection (arrow). CTA image of a left vertebral artery dissection with flap resulting in acute neck pain and vertigo

viral-associated meningitis that primarily affects children and accounts for nearly 40,000 hospitalizations annually [51, 52]. Although both entities may present with symptoms that include fever, neck stiffness, altered mental status, and photophobia, nuchal rigidity may be absent even in the presence of a bacterial process [52]. It has been estimated that 44% of nearly 700 cases of community-acquired bacterial meningitis presented with concomitant fever, nuchal rigidity, and altered mental status. Alternatively, upward of 95% of patients with an ultimate diagnosis of bacterial meningitis reported at least two of the following four symptoms: headache, nuchal rigidity, altered mental status, and fever [53]. Patients with meningitis seldom are normothermic [54]. Although high fever is most common, hypothermia does also occur as well [55]. In contrast to bacterial meningitis, there is no specific treatment for the viral-mediated variety.

History

Similar to the evaluation of atraumatic back pain, obtaining a thorough and targeted history is vital to establishing a threshold of concern for serious neck pathology. In this case, the past medical history may also point to a certain organ system as the root cause of the complaint, such as prior head/neck malignancy or periodontal disease in the case of neck masses, stroke risk factors (e.g., cardiovascular disease or prior stroke), or focal neurological deficit in the case of cervical arterial dissection. In addition, a history of prior neck trauma, pain, and/or radicular upper extremity symptoms should prompt further physical exam evaluation as well as potential imaging.

Physical Exam

A complete neurologic exam is required to thoroughly evaluate any complaint of neck pain. Findings, such as Horner's Sx (ptosis, miosis, anhidrosis), extremity sensorimotor deficits, gait disturbance, hyperreflexia, and/or Babinski sign, all contribute important information to narrowing the differential diagnosis. Maneuvers specific to individual diagnoses are discussed below.

Cervical radiculopathy: There are several clinical tests utilized to evaluate for cervical radiculopathy. The *manual distraction test* is performed by exerting a manual vertical upward traction under the patient's mandible and occiput [56]. The test is considered positive if their discomfort is decreased with the maneuver, thereby suggesting relief of pressure exerted on nerve roots. The *Spurling maneuver* is performed by turning the patient's head to the affected side and applying downward pressure at the cranial vertex. Reproduction of ipsilateral radicular discomfort is considered to be a positive result. In each case, care must be taken to avoid these maneuvers in patients with suspected rheumatoid arthritis, metastatic disease, or known cervical bony malformations. Finally, Elvey's upper limb tension test is an upper extremity analogue of the so-called straight leg raise used to evaluate lower extremity

radiculopathy. It is performed by turning the patient's head to the contralateral side while simultaneously abducting the ipsilateral shoulder and extending the elbow. Reproduction of radicular discomfort that radiates down the extremity is considered to be positive.

Meningitis: Brudzinski's and Kernig's signs are each associated with a specific clinical maneuver utilized in the evaluation of nuchal rigidity; positive findings raise concern for potential meningitis. A positive Brudzinski's sign refers to spontaneous hip flexion in response to passive neck flexion, whereas a positive Kernig's sign refers to the inability to extend the knee during 90° hip flexion or if lower back pain is experienced. Although sensitivity of each test is considered to be low, specificity was reported to approach 95% [57].

Cervical cord compression: Shock-like paresthesia occurring with neck flexion (Lhermitte's phenomenon) suggests compression of the cervical cord by a midline disk herniation or spondylosis but may also be a sign of intramedullary pathology such as a multiple sclerosis plaque. Patients with narrowed spinal canals (e.g., cervical spondylotic myelopathy) may experience focal symptoms similar to those associated with compressive lesions (e.g., tumor, epidural abscess), such as upper extremity sensorimotor deficits, as well as bladder incontinence and ataxia.

Emergency Department Workup

As with acute back pain, most patients with atraumatic neck pain do not require imaging in the emergency department. Routine imaging is not indicated for patients who present with symptoms consistent with cervical strain and have a normal neurologic exam. Specific imaging modalities are discussed below with specific indications for each.

Neuroimaging

Computed tomography (CT) and magnetic resonance imaging (MRI) are both routinely used in the evaluation of select neck pain complaints. MRI is specifically indicated when there is concern for spinal cord compression, infection (epidural abscess), and malignancy [58]. In contrast, CT is preferred when there is suspicion for deep space neck infection [59].

Cervical Strain and Radiculopathy

Advanced imaging is generally not necessary in the ED setting for these etiologies. As described above, a combination of history and physical exam usually suffices, as the utility of imaging is low.

Cervical Arterial Dissection

In the patient that presents with severe acute neck pain and/or headache with concomitant focal neurological deficits, advanced imaging can help evaluate for arterial dissection. Computed tomography angiogram (CTA) of both neck and brain

vasculature is an excellent first-line investigative study in the ED due to rapid availability when compared with MRA and similar sensitivity and specificity [60].

Meningitis

Although imaging is not necessary in most meningitis evaluations [61], there are several specific instances where it should be considered. Per current Infectious Disease Society of America (IDSA) guidelines, a noncontrast CT brain study should be obtained prior to LP when there is concern for immunocompromised states (e.g., HIV infection, current immunosuppressive therapy, and history of solid organ/hematopoietic stem cell transplant), history of structural CNS disease (e.g., mass lesion, stroke), new onset seizure, papilledema, altered mental status, or focal neurological deficit [62]. The priority is to identify patients with a mass lesion or other potential cause of increased intracranial pressure.

Cervical Mass Lesion

If there is specific concern for a neck mass or deep space infection, especially in the setting of prior history of neoplasm or periodontal disease, then obtaining a CT neck soft tissue study with contrast is indicated [63].

Disposition

The disposition of this diverse group of patients varies widely from immediate discharge to emergent subspecialist consultation and operative intervention. Patients with normal vital signs who do not exhibit evidence of acute systemic infection or neurologic/vascular compromise usually can be discharged with close outpatient follow-up. Up to 90% of patients who are discharged with a diagnosis of acute back pain will have resolution of symptoms within 4–6 weeks [3–6].

Those patients with a life- and/or function-threatening diagnosis generally require admission, specialist consultation, and emergent imaging as detailed in previous sections. Neurosurgical evaluation is necessary for those with acute cord compression stemming from a variety of causes, including disk herniation, adjacent hematoma, vertebral osteomyelitis, and epidural abscess. In addition, radiation oncology evaluation may also be required where primary neoplasm or metastatic lesions are the underlying cause of acute cord compression [6]. For those patients with symptomatic disk herniation that does not cause acute cord compression but is associated with nerve root impingement, urgent surgery may also be performed in select cases (e.g., acute foot drop).

Those patients with emergent vascular pathology such as rAAA or aortic dissection also require immediate surgical evaluation. Infectious etiologies such as vertebral osteomyelitis and epidural abscess require broad-spectrum IV antibiotics in conjunction with surgical evaluation. One study showed that approximately 40% of patients with vertebral osteomyelitis may develop complications requiring surgery [64].

Ultimately, the goal of effective ED evaluation is surveillance for acute life and/or function-threatening conditions that require immediate treatment, imaging,

admission, and/or possibly surgical intervention. Acknowledging vital sign abnormalities, eliciting concerning historical elements including key red flag signs and symptoms, and performing a complete physical/neurologic examination are all crucial to distinguishing between cases that require immediate intervention from those that require little or no evaluation.

Pearls and Pitfalls

- Eighty-five to ninety percent of patients with back pain have no clear etiology, and symptoms resolve in 4–6 weeks.
- $\approx 2\%$ of back pain complaints can be attributed to a life-threatening or permanently disabling process.
- Disk herniations occur most commonly at the L4, L5, and S1 levels.
- Cauda equina syndrome is an acute surgical emergency composed of several key symptoms, including urinary retention, urinary overflow and/or fecal incontinence, decreased rectal tone, and saddle anesthesia.
- Metastatic disease involvement of vertebral bone is most commonly seen in the thoracic spine and is associated with primary breast, lung, prostate, kidney, and thyroid carcinomas.
- Up to 80% of cancer patients who present with acute back pain may have underlying metastatic disease.
- Aortic dissection and rAAA can each present with acute back pain, and both have a high mortality when unrecognized and/or when treatment is delayed.
- Abdominal ultrasound is 100% sensitive and 98% specific for AAA.
- Red flag signs and symptoms should be used within the context of the entire clinical picture as they have a high false-positive rate when used alone.
- Malingerers and underlying psychosocial etiologies of acute back pain are diagnoses of exclusion (see Table 9.3—Waddell's score).
- MRI is the diagnostic imaging test of choice in the evaluation of cauda equina syndrome as well as primary neoplastic/bony metastatic lesions and vertebral osteomyelitis.
- CTA is the diagnostic test of choice in the evaluation of cervical arterial dissection, rAAA, and aortic dissection.

References

1. Hart LG, Deyo RA, Cherkin DC. Physician office visits for low back pain. Frequency, clinical evaluation, and treatment patterns from a U.S. national survey. *Spine (Phila Pa 1976)*. 1995;20:11–9.
2. Deyo RA, Mirza SK, Martin BI. Back pain prevalence and visit rates: estimates from U.S. national surveys, 2002. *Spine (Phila Pa 1976)*. 2006;31:2724–7.
3. Cunningham LS, Kelsey JL. Epidemiology of musculoskeletal impairments and associated disability. *Am J Public Health*. 1984;74:574–9.

4. Andersson GB. Epidemiological features of chronic low-back pain. *Lancet*. 1999;354:581–5.
5. Chou R, Qaseem A, Snow V, Casey D, et al. Clinical guidelines diagnosis and treatment of low back pain: a joint clinical practice guideline from the American College of Physicians and the American. *Ann Intern Med*. 2007;147:478–91.
6. Bigos S, Bowyer O, Braen G, Brown K, Deyo R, Haldeman S, Hart JL, Johnson EW, Keller R, Kido D. *Acute lower back problems in adults*. Rockville, MD: Agency for Health Care Policy and Research; 1995.
7. Deyo RA, Weinstein JN. Primary care: low back pain. *N Engl J Med*. 2001;344:363–70.
8. Nachemson A, Waddell G, Norlund A. Epidemiology of neck and low back pain. In: Nachemson AL, Jonsson E, editors. *Neck and back pain: the scientific evidence of causes, diagnosis and treatment*. Philadelphia, PA: Lippincott Williams & Wilkins; 2000.
9. Rubin M. Spinal cord compression. *Merck Manuals Professional Ed*. 2014. <http://www.merckmanuals.com/professional/neurologic-disorders/spinal-cord-disorders/spinal-cord-compression#>. Accessed 13 Oct 2016.
10. Rinckenbach S, Albertini J-N, Thaveau F, et al. Prehospital treatment of infrarenal ruptured abdominal aortic aneurysms: a multicentric analysis. *Ann Vasc Surg*. 2010;24:308–14.
11. Maleux G, Koolen M, Heye S. Complications after endovascular aneurysm repair. *Semin Intervent Radiol*. 2009;26:3–9.
12. Hagan PG, Nienaber CA, Isselbacher EM, et al. The International Registry of Acute Aortic Dissection (IRAD): new insights into an old disease. *JAMA*. 2000;283:897–903.
13. Scott C, Burruss N, Kalimi R, Manetta F, Palazzo RS, Graver LM. Acute ascending aortic dissection during pregnancy. *Am J Crit Care*. 2001;10:430–3.
14. Thompson RW, Curci JA, Ennis TL, Mao D, Pagano MB, Pham CTN. Pathophysiology of abdominal aortic aneurysms: insights from the elastase-induced model in mice with different genetic backgrounds. *Ann NY Acad Sci*. 2006;1085:59–73.
15. Darouiche RO, Hamill RJ, Greenberg SB, Weathers SW, Musher DM. Bacterial spinal epidural abscess. Review of 43 cases and literature survey. *Medicine*. 1992;71:369–85.
16. Akalan N, Ozgen T. Infection as a cause of spinal cord compression: a review of 36 spinal epidural abscess cases. *Acta Neurochir*. 2000;142:17–23.
17. Sendi P, Bregenzler T, Zimmerli W. Spinal epidural abscess in clinical practice. *QJM*. 2008;101:1–12.
18. Sapico FL, Montgomerie JZ. Vertebral osteomyelitis in intravenous drug abusers: report of three cases and review of the literature. *Rev Infect Dis*. 2016;2:196–206.
19. Beronius M, Bergman B, Andersson R. Vertebral osteomyelitis in Göteborg, Sweden: a retrospective study of patients during 1990–95. *Scand J Infect Dis*. 2001;33:527–32.
20. Henschke N, Maher CG, Refshauge KM, Herbert RD, Cumming RG, Bleasel J, York J, Das A, McAuley JH. Prevalence of and screening for serious spinal pathology in patients presenting to primary care settings with acute low back pain. *Arthritis Rheum*. 2009;60:3072–80.
21. Atlas SJ, Keller RB, Wu YA, Deyo RA, Singer DE. Long-term outcomes of surgical and non-surgical management of sciatica secondary to a lumbar disc herniation: 10 year results from the maine lumbar spine study. *Spine (Phila Pa 1976)*. 2005;30:927–35.
22. Martin BI, Turner JA, Mirza SK, Lee MJ, Comstock BA, Deyo RA. Trends in health care expenditures, utilization, and health status among US adults with spine problems, 1997–2006. *Spine (Phila Pa 1976)*. 2009;34:2077–84.
23. Deyo RA, Mirza SK, Turner JA, Martin BI. Overtreating chronic back pain: time to back off? *J Am Board Fam Med*. 2009;22:62–8.
24. Deyo RA, Rainville J, Kent DL. What can the history and physical examination tell us about low back pain? *JAMA*. 1992;268:760–5.
25. Hadjipavlou AG, Tzermiadianos MN, Bogduk N, Zindrick MR. The pathophysiology of disc degeneration: a critical review. *J Bone Joint Surg Br*. 2008;90:1261–70.
26. Majlesi J, Togay H, Unalan H, Toprak S. The sensitivity and specificity of the slump and the straight leg raising tests in patients with lumbar disc herniation. *J Clin Rheumatol*. 2008;14:87–91.

27. Ahn UM, Ahn NU, Buchowski JM, Garrett ES, Sieber AN, Kostuik JP. Cauda equina syndrome secondary to lumbar disc herniation: a meta-analysis of surgical outcomes. *Spine (Phila Pa 1976)*. 2000;25:1515–22.
28. Gleave JRW, MacFarlane R. Cauda equina syndrome: what is the relationship between timing of surgery and outcome? *Br J Neurosurg*. 2002;16:325–8.
29. McCarthy MJH, Aylott CEW, Grevitt MP, Hegarty J. Cauda equina syndrome: factors affecting long-term functional and sphincteric outcome. *Spine (Phila Pa 1976)*. 2007;32:207–16.
30. Kennedy JG, Soffe KE, McGrath A, Stephens MM, Walsh MG, McManus F. Predictors of outcome in cauda equina syndrome. *Eur Spine J*. 1999;8:317–22.
31. Azhar B, Patel SR, Holt PJE, Hinchliffe RJ, Thompson MM, Karthikesalingam A. Misdiagnosis of ruptured abdominal aortic aneurysm: systematic review and meta-analysis. *J Endovasc Ther*. 2014;21:568–75.
32. Kodolitsch Y, Schwartz AG, Nienaber CA. Clinical prediction of acute aortic dissection. *Arch Intern Med*. 2000;160:5–10.
33. Apeldoorn AT, Bosselaar H, Blom-Luberti T, Twisk JWR, Lankhorst GJ. The reliability of nonorganic sign-testing and the Waddell score in patients with chronic low back pain. *Spine (Phila Pa 1976)*. 2008;33:821–6.
34. Patel ND, Broderick DF, Burns J, et al. ACR appropriateness criteria low back pain. *J Am Coll Radiol*. 2016;13:1069–78.
35. Sharif HS. Role of MR imaging in the management of spinal infections. *AJR Am J Roentgenol*. 1992;158:1333–45.
36. Carragee EJ. Pyogenic vertebral osteomyelitis. *J Bone Joint Surg Am*. 1997;79:874–80.
37. Tayal VS, Graf CD, Gibbs MA. Prospective study of accuracy and outcome of emergency ultrasound for abdominal aortic aneurysms over two years. *Acad Emerg Med*. 2003;10:4–8.
38. LaRoy LL, Cormier PJ, Matalon TAS, Patel SK, Turner DA, Silver B. Imaging of abdominal aortic aneurysms. *Am J Roentgenol*. 1989;152(4):785–92.
39. Litmanovich D, Bankier AA, Cantin L, Raptopoulos V, Boiselle PM. CT and MRI in diseases of the aorta. *Am J Roentgenol*. 2009;193:928–40.
40. Ten Bosch JA, Teijink JAW, Willigendael EM, Prins MH. Endovascular aneurysm repair is superior to open surgery for ruptured abdominal aortic aneurysms in EVAR-suitable patients. *J Vasc Surg*. 2010;52:13–8.
41. Mehta M, Taggert J, Darling RC, Chang BB, Kreienberg PB, Paty PSK, Roddy SP, Sternbach Y, Ozsvath KJ, Shah DM. Establishing a protocol for endovascular treatment of ruptured abdominal aortic aneurysms: outcomes of a prospective analysis. *J Vasc Surg*. 2006;44:1–8.
42. Wolsko PM, Eisenberg DM, Davis RB, Kessler R, Phillips RS. Patterns and perceptions of care for treatment of back and neck pain: results of a national survey. *Spine (Phila Pa 1976)*. 2003;28:292–7.
43. Côté P, Cassidy JD, Carroll L. The factors associated with neck pain and its related disability in the Saskatchewan population. *Spine (Phila Pa 1976)*. 2000;25:1109–17.
44. Peterson C, Bolton J, Wood AR, Humphreys BK. A cross-sectional study correlating degeneration of the cervical spine with disability and pain in United kingdom patients. *Spine (Phila Pa 1976)*. 2003;28:129–33.
45. Ferrari R, Russell AS. Neck pain. *Best Pract Res Clin Rheumatol*. 2003;17:57–70.
46. Radhakrishnan K, Litchy WJ, Fallon WMO, Kurland LT. Epidemiology of cervical radiculopathy. A population-based study from Rochester, Minnesota, 1976 through 1990. *Brain*. 1994;117(Pt 2):325–35.
47. Lee VH, Brown RD, Mandrekar JN, Mokri B. Incidence and outcome of cervical artery dissection: a population-based study. *Neurology*. 2006;67(10):1809–12.
48. Mattioni A, Paciaroni M, Sarchielli P, Murasecco D, Pelliccioli GP, Calabresi P. Multiple cranial nerve palsies in a patient with internal carotid artery dissection. *Eur Neurol*. 2007;58(2):125–7.
49. Kristensen B, Malm J, Carlberg B, Stegmayr B, Backman C, Fagerlund M, Olsson T. Epidemiology and etiology of ischemic stroke in young adults aged 18 to 44 years in Northern Sweden. *Stroke*. 1997;28:1702–9.

50. Scheld WM, Koedel U, Nathan B. Pathophysiology of bacterial meningitis: mechanism(s) of neuronal injury. *J Infect Dis.* 2002;186(Suppl 2):S225–33.
51. Rotbart HA. Viral Meningitis. *Semin Neurol.* 2000;20(3):277–92.
52. Tu E. Outbreaks of aseptic meningitis associated with echoviruses 9 and 30 and preliminary surveillance reports on enterovirus activity—United States. *MMWR Morb Mortal Wkly Rep.* 52; 2003.
53. van de Beek D, de Gans J, Spanjaard L, Weisfelt M, Reitsma JB, Vermeulen M. Clinical features and prognostic factors in adults with bacterial meningitis. *N Engl J Med.* 2004;351:1849–59.
54. Domingo P, Mancebo L, Blanch L, Net A, Nolla J. Fever in adult patients with acute bacterial meningitis. *J Infect Dis.* 1988;158:496.
55. Aronin SI, Peduzzi P, Quagliarello VJ. Community-acquired bacterial meningitis: risk stratification for adverse clinical outcome and effect of antibiotic timing. *Ann Intern Med.* 1998;129:862–9.
56. Robinson HS, Brox JI, Robinson R, Bjelland E, Solem S, Telje T. The reliability of selected motion- and pain provocation tests for the sacroiliac joint. *Man Ther.* 2007;12:72–9.
57. Thomas KE, Hasbun R, Jekel J, Quagliarello VJ. The diagnostic accuracy of Kernig’s Sign, Brudzinski’s Sign, and Nuchal Rigidity in adults with suspected meningitis. *Clin Infect Dis.* 2002;35:46–52.
58. Nordin M, Carragee EJ, Hogg-Johnson S, et al. Assessment of neck pain and its associated disorders: results of the bone and joint decade 2000–2010 task force on neck pain and its associated disorders. *Eur Spine J.* 2009;18:435–6.
59. Hurley MC, Heran MKS. Imaging studies for head and neck infections. *Infect Dis Clin N Am.* 2007;21:305–53.
60. Provenzale JM, Sarikaya B. Comparison of test performance characteristics of MRI, MR angiography, and CT angiography in the diagnosis of carotid and vertebral artery dissection: a review of the medical literature. *Am J Roentgenol.* 2009;193:1167–74.
61. Hasbun R, Abrahams J, Jekel J, Quagliarello VJ. Computed tomography of the head before lumbar puncture in adults with suspected meningitis. *N Engl J Med.* 2001;345:1727–33.
62. Tunkel AR, Hartman BJ, Kaplan SL, Kaufman BA, Roos KL, Scheld WM, Whitley RJ. Practice guidelines for the management of bacterial meningitis. *Clin Infect Dis.* 2004;39:1267–84.
63. Weber AL, Romo L, Hashmi S. Malignant tumors of the oral cavity and oropharynx: clinical, pathologic, and radiologic evaluation. *Neuroimaging Clin N Am.* 2003;13:443–64.
64. McHenry MC, Easley KA, Locker GA. Vertebral osteomyelitis: long-term outcome for 253 patients from 7 Cleveland-Area Hospitals. *Clin Infect Dis.* 2002;34:1342–50.
65. Graham PH, Capp A, Dalaney G, Gooze G, Hickey B, Turner S, Browne L, Milross C, Wirth A. A pilot randomised comparison of dexamethasone 96 mg vs 16 mg per day for malignant spinal-cord compression treated by radiotherapy: TROG 01.05 superdex study. *Clin Oncol.* 2006;18:70–6.

Michael Hoffmann

Case Presentation

A 21-year-old college student developed sudden right arm and leg weakness after a bout of unusually strenuous coughing while talking to her roommate about her recent “breakup” with her boyfriend. They had planned to go out that evening, but she changed plans on account of a migraine headache and neck discomfort that had developed during the day. Alarmed by her friend’s limp limbs, she called 911, and the EMS team arrived promptly, appropriately considered her to have a potential stroke syndrome, and sped to the nearest comprehensive stroke center. During the emergency vehicle transportation, she was able to speak fluently and comprehend all questions asked of her by the emergency personnel. They documented a blood pressure and pulse within normal range but a slight tachycardia at times between 90 and 110 per min, without pyrexia or oxygen desaturation. On arrival at the emergency department, she was triaged as a possible stroke patient, and emergency CT brain, glucose test, PT, PTT, platelet count, basal metabolic panel, and comprehensive metabolic panel were performed all of which were normal. She was examined briefly and found to be alert, rational, and fully conversant; power grading of the right arm was 1–2/5 and right leg 1–2/5 (flicker of movement and not able to overcome gravity) on the MRC scale. Reflexes were symmetrical in both arms and legs. She declined to attempt walking. She was considered for intravenous tissue plasminogen activator therapy by the emergency physician in consultation with the on-call neurologist. In the meantime, the nurse obtained additional history from the patient.

M. Hoffmann, M.D., Ph.D.
University of Central Florida, Orlando, FL, USA
e-mail: Michael.Hoffmann@ucf.edu

Breakout Box: Differential Diagnosis

1. Right hemisphere stroke—embolic (paradoxical)
2. Right hemisphere stroke—cervicocephalic dissection
3. Migraine
4. Cervical myeloradiculopathy
5. Metabolic—hypoglycemic
6. Conversion disorder-related weakness

Additional information gleaned from the patient while awaiting the stroke was of extensive abusive childhood relationships. She is frequently depressed and suffers from anxiety. The breakup with her boyfriend was very “traumatic for her.” With the atypical features of the hemiparesis, alertness, absence of aphasia, and Broadbent’s type hemiparesis (the arm weaker than the leg) of a typical left middle cerebral artery (MCA) stroke syndrome, a diagnosis of conversion disorder was considered a more likely entity in the differential diagnosis.

History Background Information

Any relatively sudden neurological deficit includes stroke in the differential and if within 4.5 h of onset requires urgent consideration for intravenous tissue plasminogen activator (TPA) and intra-arterial therapy. There is extreme urgency around such presentations, and this limits the time for history and examination.

Clinically it is important to distinguish conversion disorders from the factitious illness group comprising of feigning of physical or psychological symptoms with intentional production of these. The best known example is the entity referred to as Munchausen’s syndrome. Key features include recurrent simulated illness, pathological lying, and peregrination (traveling, wandering). A number of other associations include borderline/antisocial traits and equanimity for diagnostic procedures, treatments, and operations. Many have experience with the medical field and have had multiple hospitalizations and surgeries, with the scars as evidence (Tables 10.1 and 10.2).

Conversion disorders frequently include symptoms of motor function, sensory function tremor, dystonia, and pseudo-epilepsy mimicking neurological syndromes. Contrary to malingering or factitious disorders, conversion symptoms are unintentional and not deliberately produced.

Table 10.1 Commonly used terms and synonyms or terms that describe very similar presentations

<i>Two main groups</i>	
A.	Conversion disorders
	Functional neurological syndromes (FNS, preferred term)
	Hysteria (Briquet’s disease)
	Somatoform disorders
B.	Malingering
	Hypochondriasis

Table 10.2 Principal presentations of conversion disorder

1. <i>Neurological</i>
• Paralysis or paresis of a limb or limbs
• Amnesia
• Vision impairment such as blindness, diplopia
• Fainting, seizures
• Deafness
• Aphonia
• Imbalance and gait disorder
• Body dysmorphic disorder
• Pseudocyesis
2. <i>Pain</i>
• Low back pain
• Joint pain
• Chronic headaches
3. <i>Cardiovascular</i>
• Chest pain
• Palpitations
• Dyspnea
4. <i>Gastrointestinal</i>
• Abdominal pain
• Diarrhea
• Vomiting
5. <i>Genitourinary tract</i>
• Dysmenorrhea
• Metrorrhagia
• Impotence

Table 10.3 Working definition: the essential features also embodied in more detail in the DSM V and ICD 10 classifications include [1, 2]

1. Relatively sudden loss of function of a body part, such as a limb
2. Psychological factors particularly childhood abuse or other psychosocial stressor feature prominently in the history
3. The individual is seemingly unconcerned and not conscious of intentionally producing the deficit, abnormality, or symptom

At this time, the only feature in the history in support of a potential psychogenic disorder is the psychological trauma from partner separation (Table 10.3).

Physical Examination

The focused neurologic exam should evaluate for red flags. In the case above, for example, her weakness is atypical with profound weakness of the arm equal to leg weakness, aphasia, and relatively intact attention. Although seen with some rare strokes (anterior cerebral artery, brainstem stroke), this is very unusual for a typical

MCA territory stroke syndrome and relatively intact attention. Such a degree of weakness typically is associated with aphasia and a degree of inattention and even obtundation.

Because of the possibility of conversion disorder, the focused exam will assist the history in arriving at a more precise diagnosis. Some physical exam findings that can help stratify risk of conversion disorder are below.

Hoover's Sign

An important test of motor examination is to perform Hoover's test (Hoover 1908) [3, 4]. This is probably the best known and touted as one of the more reliable signs to assess conversion type paresis or plegia.

Agree with three or four figures for these maneuvers.

In brief it involves two steps:

- (a) With a presentation of right leg weakness, the examiner places the right hand under the heel of the patient's foot who is requested to apply downward pressure (hip extension). In organic and functional plegia, no pressure will be perceived by the examiner's hand.
- (b) With the hand still under the right heel, the patient is requested to raise the left leg off the bed (hip flexion) against resistance of the examiner's other hand. In functional weakness, downward pressure will be perceived from the right leg due to involuntary hip extension (associated movements).

A possible explanation of the spinal reflex mechanism, first proposed by Sherrington and genesis of Hoover's sign, involves excitatory spinal interneurons traversing many levels of the spinal cord that induce an antagonistic contraction in the opposite leg. This may be regarded as a protective spinal reflex mechanism that allows stabilization of the body and trunk [5].

False-positive Hoover's signs can occur with cortical neglect, hip pain, and multiple sclerosis. However, Hoover's sign does not differentiate conversion disorder from feigning, simulated weakness, or malingering [6].

Hoover's Signs in the Arms

In the index patient presented above, the equivalent of Hoover's sign in the arms is also applicable. With this test, a complementary opposition of the arms occurs. Flexion of the outstretched (good) arm against resistance normally causes an involuntary extension of the other "paretic" arm. In addition, with shoulder adduction in one arm, the other arm will also adduct in patients with functional paresis of the upper limb, which does not happen with organic weakness [7].

Sonoo Abductor Sign

Ask the patient to abduct one leg at a time and provide resistance to the movement by placing the hands on the outside of the legs. With organic weakness, when the weak leg is abducted, the normal leg remains stable. In CD, the normal leg hyper-adducts. The abductor sign has an advantage in that it has a good visual assessment rather than relying on the subjective appreciation of the examiners in Hoover's sign. This sign has good sensitivity and specificity for CD as the leg contralateral to the abducted one shows opposite action in CD versus organic paresis [8].

Co-contraction Test

In CD weakness, the contraction of antagonist muscles can be felt when testing the agonist muscle. This is easiest when testing biceps contraction, the triceps contracts as well.

With muscle co-contractions, the movement becomes awkward and slowed, despite seemingly adequate muscle power. The two opposing muscles may also be seen to contract during a movement or sequentially which assists in the diagnosis.

Sternocleidomastoid Test

The sternocleidomastoid muscles have bilateral innervation. In people with organic hemiparesis due to cerebral lesions, for example, there is no sternocleidomastoid weakness. This is not the case with CD-related weakness [9].

Motor Findings and Testing

There are many examples of what has been termed coordinated associated movements that are associated with voluntary action in those with limb weakness. In essence there is a spread of activity to contiguous muscle groups which is reflected in the adoption of new postures or limb positions. Importantly these do not occur in normal people without weakness nor in those with so-called nonorganic paresis or conversion disorders. In addition to the mechanism Hoover's sign, some examples include the pronator drift (Barre's sign), Babinski's sign, and Wartenberg's sign, and many others have been described [10] (Table 10.4).

Important Sensory Testing

Clinicians frequently resort to what has been termed "clinical subterfuge" to evaluate for functional sensory loss to verify that sensation loss is nonorganic. None of

Table 10.4 A selection of associated movement signs

Wartenberg's sign—In a weak hand, the flexion of the terminal four fingers against resistance induces adduction, opposition, and flexion of the thumb
Sterling's sign—On the normal arm, adduction of the shoulder against resistance induces shoulder adduction on the weak side
Neri's flexion of the thigh and leg
Neri's sign is useful for establishing organic weakness. There is a spontaneous flexion at the knee of the weak side with passive elevation of the leg
Radialis sign of Strümpell [10]
A sign in assisting the diagnosis of an organic deficit; with palmar or volar flexion of a finger, there is an accompanying involuntary dorsiflexion of the affected hand

the maneuvers have been found to be foolproof however with the exception of Campbell terms the SHOT syndrome.

SHOT syndrome

No sight in the eye

No hearing in the ear

No olfaction in the nose

No touch sensation on the body

All of which are reported on the same side of the body [10].

1. Sensory testing may be employed in some gullible patients with the command, say “yes” when you feel and “no” if you do not. The patient responds “no” when he/she cannot “feel.”
2. Check sensation when the hands are in confusing or contorted positions with fingers intertwined. This causes difficulty in determining which finger belongs to which hand and may be useful in distinguishing “functional analgesia.”
3. Midline sensory loss splitting. Functional sensory loss is often presented in a hemi-anesthetic distribution, interestingly mostly on the left side. Sensory changes are carefully tested by pinprick or other sharp objects (but not too sharp objects such as needles) along the midline. In organic sensory loss, the impairment does not precisely extend to the midline with sensation usually beginning several millimeters before the midline is reached. With functional sensory loss, there is often a very abrupt delineation at the midline that may also include the genitalia and may also involve the vibration modality.
4. Truncal sensory levels slant downward when tested from back to front in organic lesions, whereas a functional level is often depicted as strictly horizontal.
5. Glove and stocking level distributions can also be informative. If the deficit is defective up to the knees, then the level in the upper limbs must be approximately at the wrist. This conforms to the typical characteristic clinical glove and stocking distribution. With functional impairment, the deficit may be distal to the wrists and ankles describing a so-called glove-ankle sock distribution [11, 12] (Table 10.5).

Table 10.5 Motor and sensory tests in conversion disorder

<i>Motor tests</i>	
1.	Hoover's sign
2.	Hoover's arm sign
3.	Sonoo abductor sign
4.	Co-contraction sign
5.	Sternocleidomastoid sign
<i>Sensory tests</i>	
1.	Reporting sensory testing perception with "yes" and "no"
2.	Sensory testing of fingers with the hands in contorted positions
3.	Midline sensory splitting
4.	Slanting and horizontal truncal sensory levels
5.	Glove and stocking and glove-ankle sock distributions

Emergency Department Workup

The focused history and physical exam should guide a workup aimed at excluding time-dependent acute organic conditions, as described in other relevant chapters. Once an emergent condition is excluded, patients with conversion or malingering can generally be safely managed as outpatients.

Clinical Investigations

Clinical testing may include neuroimaging, lumbar puncture, or video EEG based on the presentation.

In covert or complex cerebrovascular syndromes such as hemodynamic TIAs and Moyamoya syndrome, the patient may present with recurrent stereotyped transient ischemic events. These watershed or ischemic events may include so-called limb-shaking TIAs that in the context of normal MR imaging may be considered "functional."

Neuroimaging

Routine neuroimaging is generally normal in patients with conversion disorder. However functional neuroimaging, in particular PET brain and functional MR imaging, has yielded intriguing insights into a possible neurobiological process in many patients with CD (not so in malingering).

The only tool available in deciphering the possible cause is functional neuroimaging. Clinical and cognitive neuroscience insights have greatly informed the contemporary cognitive neuroscience view of conversion disorders.

Neuroimaging and Functional Imaging Overview

Overall, abnormalities in neural networks rather than specific areas are being appreciated by functional imaging (f-MRI, PET brain, SPECT brain, resting state networks). Increased sensitivity of the amygdala fear responses due to adverse experiences may be driving changes in frontal and limbic networks that subsequently alter both perception experiences (sensory loss) and planned movements (weakness).

One of the first functional imaging studies in conversion disorder was published by Marshall et al. in 1997 whereby the investigators noted failure of movement in the CD patient was associated with specific right frontal lobe activation that suggested that the inhibitory effect on either motor or sensory actions was dictated to by higher tertiary association cortex in the frontal lobes [13]. Aberrant limbic motor interactions have been discovered by functional MRI (f-MRI) scanning in patients with conversion disorder. These may represent the effect of arousal on motor limb function. Those with motor conversion disorder were shown to have greater functional connectivity by f-MRI between the right amygdala and right supplementary motor region when tested both to happy and fearful faces, for example. This is despite no direct neuroanatomical networks existing, between the amygdala and supplementary motor area [14]. The supplementary motor is involved in self-initiated movements and actions and the source of the “Bereitschaftspotential” (readiness potential). This is an electrophysiological negative potential in the frontal lobe that precedes movement by about 1 s [15].

The right temporoparietal junction (TPJ) has also been implicated in CD, with hypoactivity of the TPJ in this population. IT is regarded as comparator of prediction of actual events with internal predictions and leads to the perception that a conversion reaction is not generated by the person [16]. This may be viewed as a kind of mismatch between external and internal processing of events. The parietal lobes have also been shown to be abnormally activated in CD. Von Van Beilen et al. showed that there was decreased precuneus activity (medial parietal lobe area) interpreted to be the result of unintentional influence of stressors of psychological origin (Fig. 10.1). There is also increased supramarginal gyrus activity (lateral

- Reduced activity in the prefrontal cortex, supramarginal gyrus (6) and precuneus (2)
- The decreased supramarginal gyrus activity is involved in motor preparation and control activation reflects the development of paresis
- Decreased prefrontal activity (4) is thought to reflect the unintentional nature of conversion paresis that occurs in combination with the precuneus.

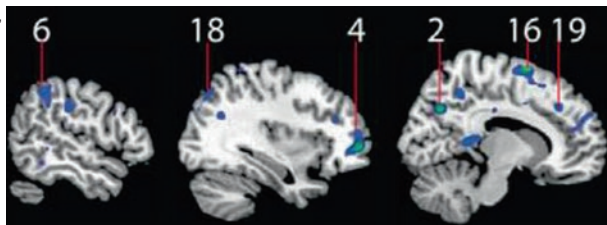


Fig. 10.1 Abnormal parietal activity in conversion paresis: a neurophysiological study. 2 precunei in parietal lobes, 4 frontal poles, 6 supramarginal gyri in the parietal lobe, 16 supplementary motor areas and cingulate cortices, 18 superior parietal cortices, and 19 frontal eye fields (Figure with permission: Van Beilen M, de Jong BM, Gieteling EW, Renken R, Leenders KL. Abnormal Parietal Function in Conversion Paresis. PLOS ONE. 2011;6(10):e25918)

parietal lobe) where motor preparation activity takes place together with the SMA and organization of motor control. These areas are therefore neurobiologically related to the conversion paresis [17].

Overall, functional neuroimaging is implicating a network disturbance of the brain involving the frontal lobes and amygdala that in turn influences the premotor cortex (Fig. 10.2).

For example, passive stimulation in the setting of functional sensory loss and also in attempted movement in CD paralysis was associated with right frontal activation implying inhibition of sensorimotor action by higher cortical areas. Cojan et al. noted that with functional paralysis there was ventrolateral PFC activity, a region with major input from emotional processing areas such as the amygdala [18].

In a f-MRI study, the relationship of emotions and symptom production revealed abnormal correlations in amygdala activation (expected) and the supplementary motor cortical region (not expected) [19]. This study suggested a mechanism for the symptom generation due to significant life-triggering episodes potentially triggering life events [20].

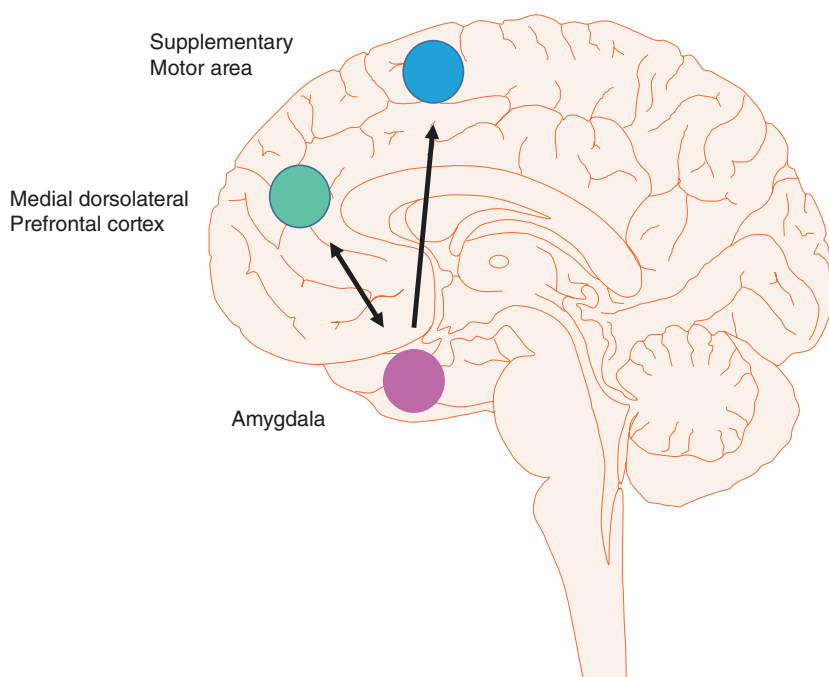


Fig. 10.2 Overview of the hypothetical pathophysiology of conversion disorder from functional neuroimaging studies. The three key areas involved are an overactive amygdala that influences the supplementary motor areas (motor programming area and preparation for movement). With functional paralysis increased activity of the ventrolateral prefrontal cortex was noted, an area that has major input from cortical areas involved in emotional processing. Dorsolateral prefrontal cortex (*green*), amygdala (*pink*), and supplementary motor area (SMA) (*blue*)

The current understanding of motor conversion disorder is therefore regarded as associated with an above-normal amygdala activity (due to stress, threats, adverse experiences) with a consequent downstream influence affecting the supplementary motor area (SMA). The SMA region is the site of motor plans and initiation as well as the nonconscious response inhibition. This model is helpful in that it explains most of if not all the clinical symptoms, signs, and syndromes clinicians have recorded with conversion disorders for the last 200 years [21].

Disposition

Discharge Versus Admit, Referrals, and Follow-Up

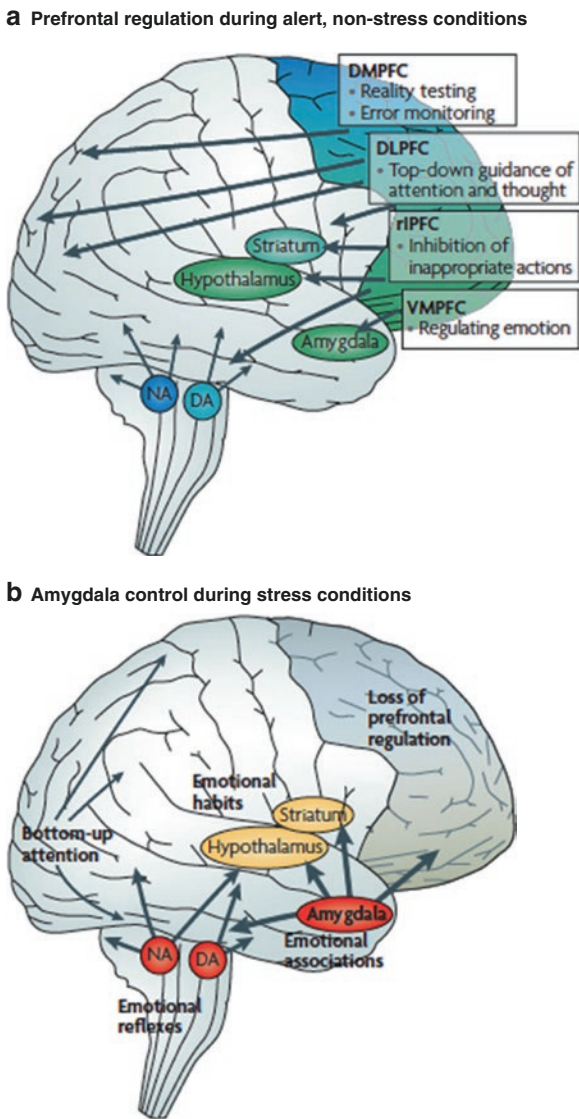
1. Admit to the hospital if stroke or other acute process cannot be confidently excluded.
2. Psychiatry referral to evaluate and manage the commonly associated anxiety, depression, and abuse history that may or may not be applicable to the patient.
3. Discussion of probable process with patient. This may entail demonstration of the neurological examination and findings of non-congruence with neuroanatomy. However there are processes in the brain that do not follow anatomical rules, and CD is likely to be one of them. Stressing to the patient that within the limits of our investigations, no adverse pathology has been uncovered is often helpful.
4. The best evidence to date as a randomized controlled trial of a cognitive behavioral therapy comprising of four-session self-help program. This led to an improvement in the quality of life health rating scores and symptom alleviation in the longer term with a modest overall 13% improvement [22].
5. Other potential future treatments may include transcranial magnetic stimulation for a paretic limb and hypnotherapy [23, 24].
6. Meditation may offer a significant benefit. Cognitive neuroscience has led the way in helping understand the importance not only of severe stressors such as post-traumatic stress disorder but also the effect of lesser stressful day-to-day situations. Neurobiological insights of stress on the brain support this premise [21] (Fig. 10.3).

Pearls and Pitfalls

The misdiagnosis of hysteria when organic illness is present is relatively high. Many previously hysterical diagnoses are today recognized as organic neurological illnesses [24].

It is a relatively common disorder. The overall incidence in varying geographical settings is between 4–12/100,000 per year. Estimates of the incidence of CD performed in a controlled study in SE Scotland revealed an annual incidence of 3.9/100,000 [24, 25].

Fig. 10.3 Stress and the brain. The prefrontal cortex, the most evolved brain region, is also the most vulnerable to everyday stress, toxins, and vascular disease. Stress incurs deficits in working memory, attention, and emotional regulation. **(a)** Prefrontal regulation during alert, nonstress conditions. **(b)** Amygdala control during stress conditions (Figure with permission: Arnsten AFT. *Nature Reviews Neuroscience* 2009;10:410–422)



About 30% of neurology outpatients had symptoms that were not explained (or marginally) by neurological disease [26].

Of these a subsequent estimate of 5.6% were diagnosed with conversion disorder [27].

The most disturbing data concerning potential misdiagnosis stems from the psychogenic non-epileptic seizure (PNES) literature. A physical brain abnormality in terms of MRI brain, EEG, or neuropsychological testing was found in 22.3% of patients with only PNES and in 91.9% of patients with both PNES and organic epilepsy [28].

The Least You Need to Know Points

There are two major presentations of functional neurological symptoms.

1. Conversion disorder (Briquet's, hysteria) disease of young women
 - Psychological trauma
 - Seemingly unaware
2. Malingering syndrome of men
 - Deliberate, insightful
 - May take the form of Munchausen's syndrome
 - May overlap with sociopathy

References

1. American Psychiatric Association. Diagnostic and statistical manual of mental disorders. 5th ed. Arlington, VA: American Psychiatric Association; 2013. p. 2013. isbn:978-0-89042-555-8.
2. ICD 10 CM. International classification of diseases. 10th Revision; 2013. www.cdc.gov
3. Hoover CF. A new sign for the detection of malingering and functional paresis of the lower extremities. *JAMA*. 1908;51:746–7.
4. Koehler PJ, Okun MS. Important observations prior to the description of the Hoover sign. *Neurology*. 2004;63:1693–7.
5. Sherrington CS. Flexion-reflex of the limb, crossed extension reflex, and reflex stepping and standing. *J Physiol*. 1910;40:28–121.
6. Mehndiratta MM, Kumar M, Nayak R, Garg H, Pandey S. Hoover's sign: clinical relevance in neurology. *J Postgrad Med*. 2014;60:297–9.
7. Stone J, Carson A, Sharpe M. Functional symptoms and signs in neurology: assessment and diagnosis. *J Neurol Neurosurg Psychiatry*. 2005;76(Suppl 1):i2–12.
8. Sonoo M. Abductor sign: a reliable new sign to detect unilateral non-organic paresis of the lower limb. *J Neurol Neurosurg Psychiatry*. 2004;75:121–5.
9. Diukova GM, Stolajrova AV, Vein AM. Sternocleidomastoid (SCM) muscle test in patients with hysterical and organic paresis. *J Neurol Sci*. 2001;187(Suppl 1):S108.
10. Campbell WW. Dejong's the neurologic examination. New York: Lippincott Williams and Wilkins; 2005.
11. Stone J, Zeman A, Sharpe M. Functional weakness and sensory disturbance. *J Neurol Neurosurg Psychiatry*. 2002;73:241–5.
12. Vuilleumier P, Chicherio C, Assal F, Schwartz S, Slosman D, Landis T. Functional neuroanatomical correlates of hysterical sensorimotor loss. *Brain*. 2001;124:1077–90.
13. Marshall JC, Halligan PW, Fink GR, Wade DT, Frackowiak RS. The functional anatomy of a hysterical paralysis. *Cognition*. 1997;64(1):B1–8.
14. Groenewegen HJ, Wright CI, Uylings HB. The anatomical relationships of the prefrontal cortex with limbic structures and the basal ganglia. *J Psychopharmacol*. 1997;11:99–106.
15. Shibasaki H, Hallett M. What is the Bereitschaftspotential? *Clin Neurophysiol*. 2006;117:2341–56.
16. Voon V, Gallea C, Hattori N, Bruno M, Ekanayake V, Hallett M. The involuntary nature of conversion disorder. *Neurology*. 2010;74:223–8.
17. Van Beilen M, de Jong BM, Gieteling EW, Renken R, Leenders KL. Abnormal parietal function in conversion paresis. *PLoS One*. 2011;6(10):e25918.
18. Cojan Y, Waber L, Carruzzo A, Vuilleumier P. Motor inhibition in hysterical conversion paralysis. *NeuroImage*. 2009;47(3):1026–37.

19. Voon V, Brezing C, Gallea C, et al. Emotional stimuli and motor conversion disorder. *Brain*. 2010;133:1526–36.
20. Kanaan RA, Craig TK, Wessely SC, et al. Imaging repressed memories in motor conversion disorder. *Psychosom Med*. 2007;69:202–5.
21. Arnsten AFT. Stress signalling pathways that impair prefrontal cortex structure and function. *Nat Rev Neurosci*. 2009;10:410–22.
22. Goldstein LH, Chalder T, Chigwedere C, et al. Cognitive-behavioral therapy for psychogenic nonepileptic seizures: a pilot RCT. *Neurology*. 2010;74:1986e94.
23. Halligan PW, Athwal BS, Oakley DA, Frackowiak RS. Imaging hypnotic paralysis: implications for conversion hysteria. *Lancet*. 2000;355(9208):986–7.
24. Bell V, Oakley DA, Halligan PW, Deeley Q. Dissociation in hysteria and hypnosis: evidence from cognitive neuroscience. *J Neurol Neurosurg Psychiatry*. 2011;82(3):332–9. doi:[10.1136/jnnp.2009.199158](https://doi.org/10.1136/jnnp.2009.199158); Epub 2010 Sep 30.
25. Carson AH, et al. Functional (conversion) Neurological Syndromes: research since the millennium. *J Neurol Neurosurg Psychiatry*. 2012;83:842–50.
26. Stone J, Warlow C, Sharpe M. The symptom of functional weakness: a controlled study of 107 patients. *Brain*. 2010;132:2878–88.
27. Stone J, Carson A, Duncan R, et al. Who is referred to neurology clinics ?—the diagnoses made in 3781 new patients. *Clin Neurol Neurosurg*. 2010;112:747–51.
28. Reuber M. The etiology of psychogenic non-epileptic seizures: toward a biopsychosocial model. *Neurol Clin*. 2009;27:909e24.

Austin T. Smith and Jin H. Han

Introduction

Altered mental status is a broad term that encompasses a wide range of illnesses that vary in acuity and chronicity. Because the differential diagnosis is broad, we recommend a systems-based approach to uncover the underlying illness causing the altered mental status. The initial evaluation should comprise a quick but thorough evaluation that rules out immediate life-threatening causes, and rapid treatment if a life-threatening cause is identified. After the initial evaluation and stabilization, a more thorough history and physical exam should be performed. Because the history provided by an altered patient may be inaccurate, obtaining collateral history from a family member, caregiver, or friend is crucial. History should focus on the timing of the altered mental status, associated symptoms, and a detailed medication and substance abuse history. Because a history may not be obtainable, it is imperative that a complete head-to-toe physical exam be completed with the patient fully exposed. A broad diagnostic evaluation may be required if the diagnosis is unclear. Disposition of patients with altered mental status is determined based on the etiology, severity, and reversibility of the underlying process

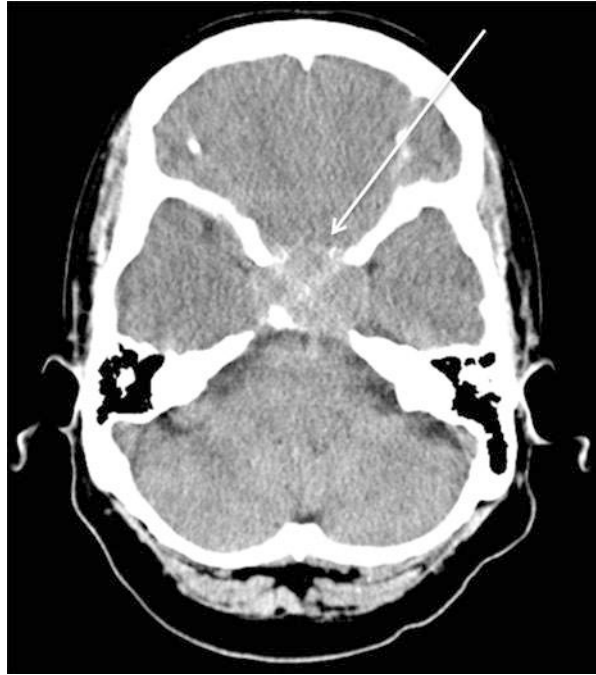
Case Presentation

A previously healthy 44-year-old male is brought to the emergency department (ED) by his wife with a chief complaint of altered mental status. Five days ago, he developed

A.T. Smith, M.D. (✉)
Department of Emergency Medicine, Vanderbilt University Medical Center,
1313 21st Avenue, South, 703 Oxford House, Nashville, TN 37232-4700, USA
e-mail: AustinSmith@utexas.edu

J.H. Han, M.D., M.Sc.
Department of Emergency Medicine, Vanderbilt University School of Medicine,
1313 21st Avenue, South, 703 Oxford House, Nashville, TN 37232-4700, USA
e-mail: jin.h.han@vanderbilt.edu

Image 11.1 A non-contrast CT scan demonstrating a sellar/suprasellar mass (arrow)



herpes zoster over his left flank for which he was prescribed valacyclovir. Around that time, his wife states he had gradual onset bizarre behavior. She describes initial disorientation and grandiose ideas which then progressed to his current state of incoherence. Other than recent herpes zoster, he has not had any infectious symptoms.

The patient has no past medical or surgical history and has no allergies to medications. He does not use any alcohol, tobacco, or illicit drugs.

On physical exam, the patient is in no apparent distress. His neck is supple without any pain or rigidity with flexion/extension. His lungs are clear to auscultation, and his heart is at normal rate and regular rhythm without extra heart sounds. His abdomen is soft and nontender. He is able to answer yes/no questions appropriately and has a nonfocal neurologic exam though he does exhibit flight of ideas.

The patient is protecting his airway and vital signs are within normal limits. His finger-stick blood glucose is 104 mg/dL. Given his profound mental status changes, a non-contrast head computed tomography (CT) was ordered. Due to his history of a herpes zoster infection, he was empirically started on intravenous (IV) acyclovir. Empiric antibiotics are withheld given his lack of fevers, neck pain, and otherwise reassuring physical exam.

Laboratory evaluation is significant for a serum sodium of 117 ng/dL, and the CT (Image 11.1) demonstrates a sellar/suprasellar mass.

A magnetic resonance imaging (MRI) of the brain with and without contrast is ordered which shows a sellar/suprasellar mass that reveals a pituitary macroadenoma. The neurosurgery service is consulted, and he is admitted to the neurologic intensive care unit and days later undergoes an endonasal tumor resection.

This case demonstrates several of the challenges involved in a patient presenting with altered mental status. Though history is vital, it will likely yield unrelated facts

or “red herrings.” In this case, the history of herpes zoster was concerning for herpes encephalitis, though it was unrelated to his presentation. This highlights the importance of maintaining a broad differential diagnosis and considering several diagnoses while obtaining a thorough history. Additionally, the cause of the altered mental status must be explored thoroughly. Though the change in mental status in this case was due to severe hyponatremia, the cause of that hyponatremia was a pituitary macroadenoma causing syndrome of inappropriate antidiuretic hormone (SIADH). Several “red flags” exist in this patient. The patient’s young age and lack of medical comorbidities should raise the clinician’s concern for a major physiologic insult.

What Is Altered Mental Status and How Do You Assess It?

Altered mental status (AMS) is a common chief complaint among older emergency department (ED) patients, but it can afflict all age groups. Despite its relatively high frequency, “altered mental status” is a vague complaint with several synonyms such as confusion, not acting right, altered behavior, generalized weakness, lethargy, agitation, psychosis, disorientation, inappropriate behavior, inattention, and hallucination [1]. Consequently, AMS can represent a variety of neurocognitive and psychiatric disorders.

Altered mental status has varying time courses and degrees of severity. Acute (hours to days) changes in mental status are likely secondary to delirium, stupor, and coma and are usually precipitated by a potentially life-threatening underlying medical illness. Acute changes in mental status indicate end-organ dysfunction of the brain and, hence, are typically referred to as “acute brain dysfunction” or “acute brain failure.” Chronic or gradual (months to years) changes in mental status (e.g., dementia) are less likely to be precipitated by a life-threatening illness [2]. For these reasons, acute changes in mental status will be the focus of this review.

Delirium, stupor, and coma represent the broad spectrum of acute brain dysfunction (Fig. 11.1). *Delirium* describes an acute disturbance of consciousness that is accompanied by an acute loss in consciousness and cognition that is not better explained by a preexisting dementia [3]. *Stupor* describes a state of arousal only

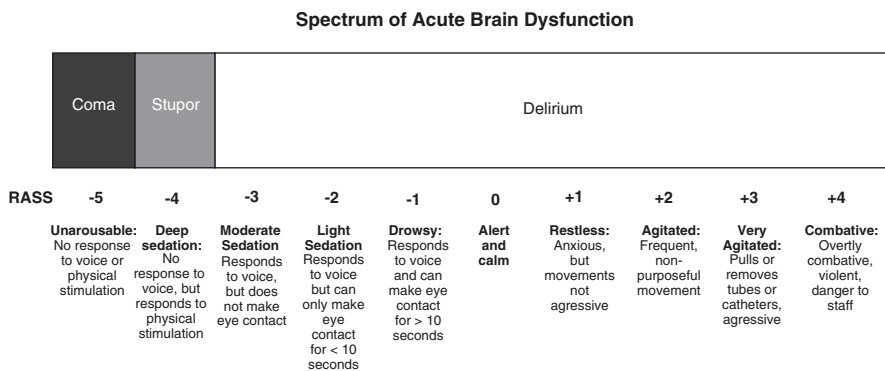


Fig. 11.1 Spectrum of acute brain dysfunction based upon the Richmond Agitation and Sedation Scale (RASS) [7, 8]. Courtesy of Vanderbilt University, Nashville, TN. Copyright © 2012. Used with permission

with vigorous and continuous stimulation. A *comatose* patient is unresponsive to any stimuli. Altered mental status is occasionally caused by psychiatric illnesses such as depression or schizophrenia. These should be diagnoses of exclusion, especially in the elderly, where the chief complaint of “altered mental status” is strongly indicative of delirium [4]. Acute brain dysfunction (delirium, stupor, and coma) and their underlying etiology should be ruled out prior to considering any psychiatric diagnoses, especially in patients without a previous history of psychiatric illness.

Acute brain dysfunction is usually assessed for using the Glasgow Coma Scale (GCS) or the Alert, Voice, Pain, Unresponsive (AVPU) scale. The GCS assesses the patient’s eye opening and verbal and motor responses to stimuli and ranges from 3 (comatose) to 15 (normal). It can be difficult to use reliably, however, if it not used regularly [5]. AVPU stands for alert, responsive to verbal stimuli, responsive to painful stimuli, and unresponsive. While it is easy to remember, it lacks granularity to detect subtle impairments [6].

Because impaired level of arousal or consciousness (patient’s responsiveness to the environment) is typically present in patients with acute brain dysfunction, we prefer using a structured arousal scale such as the Richmond Agitation and Sedation Scale (RASS) (Fig. 11.1) to characterize acute brain dysfunction. This scale ranges from -5 (unresponsive to pain and voice) to $+4$ (extreme combativeness) [7, 8].

Table 11.1 Delirium assessments

Delirium scales				
Scale	Advantage	Disadvantage	Sensitivity ^a (%)	Specificity ^a (%)
CAM [18]	Validated in ED setting, widely used	Takes 5–10 min, heavily reliant on subjective impression	86	93
bCAM [19]	Takes less than 2 min to complete. Validated in ED setting	Validated in single center	78–84	96–97
CAM-ICU [20]	Takes less than 2 min to complete. Validated in ED setting	Validation results mixed in noncritically ill patients	18–76	98–99
3D-CAM [21]	Excellent diagnostic accuracy	Takes 3 min to complete, single-center validation	93	96
4AT [22]	Takes less than 2 min to complete	Only validated in medical inpatients from Italy	90	84
DDT-Pro [23]	Validated in noncritically ill patients	Only validated on traumatic brain injury patients	100	94
SQid [24]	One question test	Relies on caregiver, friend, or family member. Validated in oncology patients.	80	71
mRASS [25]	Takes only 10 s, validated in older ED patients	Moderate inter-rater reliability, heavily reliant on subjective impression	82–84	85–88

Most of these delirium assessments have only been validated in older patients
ED emergency department

^aPooled sensitivity and specificity from 12 validation studies

Delirium is a form of acute brain dysfunction that affects 10% of older ED patients [9] and 75% of critically ill patients of all ages [10]. Delirium is associated with higher mortality [11], prolonged hospitalizations [12], and accelerated cognitive and functional decline [10, 13, 14]. As a result, routine delirium monitoring is advocated for older and critically ill patients [15–17]. Several delirium assessments have been developed over the past two decades and are summarized in Table 11.1 [18–25]. The Confusion Assessment Method [26], the Brief Confusion Assessment Method [19], the Confusion Assessment Method for the Intensive Care Unit [20], and the RASS [25] are the only delirium assessments validated in older ED patients. Additional details of these assessments can be found in www.eddelirium.org. Very few delirium assessments have been validated for younger patients, especially in the ED setting.

Differential Diagnosis

Although a central nervous system etiology such as a cerebrovascular accident (CVA) should be strongly considered, AMS is often precipitated by an underlying medical illness. Because of how broad the differential is, we suggest a systems-based approach. When considering the etiologies of AMS (Table 11.2), multiple precipitants can often exist concurrently especially in older ED patients [27].

When thinking about what precipitated the AMS, it is important to consider a patient’s vulnerability to developing acute brain dysfunction. Examples of

Table 11.2 Precipitating factors for altered mental status

Precipitating causes for altered mental status	
<p>Vital sign abnormalities</p> <ul style="list-style-type: none"> • Hypertensive encephalopathy • Inadequate pain control • Hypotension (shock) • Hypo- or hyperthermia • Hypoxemia <p>Toxic</p> <ul style="list-style-type: none"> • Medications and medication changes • Recreational drug use or withdrawal • Neuroleptic malignant syndrome • Serotonin syndrome <p>Metabolic: <i>electrolytes, endocrine, hepatic</i></p> <ul style="list-style-type: none"> • Hepatic or renal failure • Hypo- and hypernatremia • Hypo- and hypercalcemia • Hypoglycemia/hyperglycemia • Thyroid dysfunction • Hypoxemia • Hypercarbia • Dehydration • Adrenal insufficiency • Corticoid-producing condition 	<p>Neurologic</p> <ul style="list-style-type: none"> • Cerebrovascular accident • Intracerebral hemorrhage • Subarachnoid hemorrhage • Subdural/epidural hematoma • Nonconvulsive status epilepticus • Brain mass ± edema • Hydrocephalus • Locked-in syndrome • Seizure • Posterior reversible encephalopathy syndrome • Thiamine deficiency (Wernicke’s encephalopathy) <p>Infectious</p> <ul style="list-style-type: none"> • Sepsis • Meningitis/encephalitis <p>Psychiatric</p> <ul style="list-style-type: none"> • Mania • Psychosis • Depression • Anxiety • Catatonia

Adapted from Pun et al., Fearing et al., and the American Psychiatry Association Delirium Guidelines [49, 77, 78]

Table 11.3 Risk factors that increase a patient's vulnerability to developing altered mental status [77, 78]

Vulnerability factors
Older age
Dementia
Functional impairment
Medical comorbidities
Malnutrition
Substance abuse

vulnerability risk factors for developing AMS can be seen in Table 11.3. A patient with AMS who has little vulnerability risk factor is worrisome and should be considered to have a life-threatening illness [28–36].

Vital Sign Abnormalities

Vital sign abnormalities such as hypotension, hypertension, hypoxemia, hyperthermia, and hypothermia can result in AMS and should be addressed immediately, and the patient should be reassessed after doing so. Though vital sign abnormalities may be the direct cause of the AMS, it is often caused by an underlying medical illness.

Toxic

Toxins can cause acute brain dysfunction through a variety of mechanisms. This may be from release of endogenous neurotransmitters, metabolic derangements, or alterations in normal physiology. Alcohol, opioid, and benzodiazepine overdose can cause drowsiness or lethargy, while sympathomimetics (e.g., cocaine, amphetamines) and anticholinergics (e.g., jimson weed) can cause agitation or even combativeness. Similarly, ethanol and benzodiazepine withdrawal can also cause AMS. Medication reactions such as serotonin syndrome or neuroleptic malignant syndrome (NMS) can present with AMS. Unintentional and intentional overdoses of home medications or over-the-counter medications can also result in AMS.

Metabolic

Several metabolic abnormalities can lead to changes in mental status. For ease of recall, we suggest separating them into three major categories: *electrolyte*, *hepatic*, and *endocrine*.

Electrolytes

- **Glucose:** Hypoglycemia may present as a comatose patient or with focal neurologic findings. Hyperglycemia may suggest diabetic ketoacidosis (DKA) or hyperosmolar hyperglycemic state (HHS).
- **Sodium:** The most common electrolyte disorder in clinical practice is hyponatremia [37], and the most common cause is thiazide diuretic use [38]. Hyponatremia can also occur in hypovolemic (dehydration with poor PO intake), euvolemic (SIADH), and hypervolemic (heart failure, cirrhosis) states. It is usually not associated with changes in mentation until the level falls below 120 mEq/L. Similarly,

hypernatremia can cause acute brain dysfunction. The most common causes are diabetes insipidus and dehydration.

- Bicarbonate: Severe acidosis or alkalemia can cause changes in mental status, especially respiratory acidosis secondary to acute respiratory failure and hypercarbia.
- Calcium: Disorders in calcium may result in changes in mental status. The most common cause of hypercalcemia in outpatients is primary hyperparathyroidism; in the hospital setting, it is malignancy [39]. Hypocalcemia can lead to hypotension and arrhythmias which can result in acute brain dysfunction [40, 41].
- BUN: Though not an electrolyte, blood urea nitrogen (BUN) is discussed with electrolytes because they are reported in the chemistry together. When levels reach 100 mg/dL or higher, mental status changes may develop [42]. At these levels, uremia is likely present.

Hepatic

- Acute liver failure causing hepatic encephalopathy can also lead to acute brain dysfunction. Several hypotheses regarding its pathogenesis exist, but ammonia, along with several other toxins, is believed to play a key role.

Endocrine

- Hypothyroidism can cause a wide spectrum of changes in mental status, the worst being myxedema coma, which is exceedingly rare. It typically presents with signs of hypothyroidism plus multisystem organ failure [43]. It is important to consider hypothyroidism in elderly patients as their symptoms are often attributed to normal aging and the diagnosis ignored or attributed to another cause [44].
- Hyperthyroidism can also cause a wide spectrum of acute mental status changes depending on severity with the most severe being thyroid storm.
- Adrenal insufficiency may present as AMS, particularly in the hypotensive patient not responding to therapy. Other clues to making this diagnosis may include dark skin pigmentation, hyponatremia with hyperkalemia, hypoglycemia, or cardiovascular collapse.
- Similarly, a corticosteroid-producing (i.e., Cushing) condition may present with acute changes in mental status.

Infectious

Both systemic (e.g., pneumonia, urinary tract infections) and central nervous system (e.g., meningitis, encephalitis) infections should be considered as a source of acute brain dysfunction. It is also important to note that AMS in the setting of infection is indicative of severe disease and is a component in the SOFA score which has been shown to be a predictor of ICU and hospital mortality [45, 46].

Neurologic

A primary neurologic cause should always be considered in the patient presenting with acute brain dysfunction. These can include intracranial hemorrhage, subarachnoid hemorrhage, subdural/epidural hemorrhage, cerebral edema, hydrocephalus, locked-in

Table 11.4 Features that should raise suspicion for a medical cause of a psychiatric presentation

Features concerning for a medical cause of a psychiatric presentation
Changes in vision [47]
Abnormal ocular exam (miosis, mydriasis, nystagmus)
No prior psychiatric history
Vital sign abnormalities
Older age without previous psychiatric history
Altered level of arousal
Visual hallucinations [47]
Medical comorbidities [47]

syndrome, cerebrovascular accidents (CVA), seizure, nonconvulsive status epilepticus (NCSE), posterior reversible encephalopathy syndrome (PRES), anti-NMDA (N-methyl-D-aspartate) encephalitis, meningitis, and other forms of encephalitis. Many of these causes will be discussed in more detail in other chapters.

Psychiatric

A psychiatric cause of acute brain dysfunction is a diagnosis of exclusion in the ED. It is important to note that several studies have shown increased death rates among psychiatric patients from both natural and unnatural causes [47]. Psychiatric patients suffer from a high rate of comorbid medical illness which are largely undiagnosed and untreated [47]. Twenty percent of psychiatric patients have a medical problem causing or exacerbating their psychiatric condition [47]. *Atypical presentations of medical problems are common, and changes in vision appear to be the most predictive of a medical illness causing, or at least contributing to, their symptoms* [47]. Table 11.4 lists features that should raise suspicion for a medical cause of a psychiatric presentation.

Initial Evaluation and Management of Patients with Altered Mental Status in the Emergency Department

Initial Evaluation

When a patient with AMS arrives to the ED, the initial step is to determine whether the patient is critically ill or not. More significant impairments of mental status should increase the suspicion for an underlying life-threatening illness, especially in patients who are stuporous or comatose (RASS of -4 or -5). Such patients should become the emergency physician's immediate priority, and the primary goal should be to promptly assess and stabilize the patient with as little delay as possible.

Initial Stabilization

The initial evaluation and management for ED patients with AMS is summarized in Table 11.5. The patient's airway, breathing, circulation, and disability should be rapidly assessed and addressed. The patient should also be fully exposed to facilitate

evaluation and treatment. Vital signs should also be quickly obtained to rule out hypotension, and if possible, a rectal temperature should be performed to accurately rule out hypo- or hyperthermia. Concurrently, a pulse oximeter and cardiac monitor should be placed to rule out hypoxemia or arrhythmias. An intravenous line should be established, and if the patient is hemodynamically unstable, then two large bore intravenous lines should be started in the antecubital fossa. Finger-stick blood glucose should be rapidly obtained to rule out hypoglycemia.

Table 11.5 Initial assessment and management of a patient with altered mental status

	Assessment	Intervention
Airway	<ul style="list-style-type: none"> • Is patient protecting his/her airway? • Look for airway obstruction including foreign bodies 	<ul style="list-style-type: none"> • Extend the neck, provide chin lift or jaw thrust • Suction the oropharynx • In cases of trauma, provide cervical spine immobilization • Nasopharyngeal airway • Oropharyngeal airway if no gag • Endotracheal intubation if patient is not able to protect airway
Breathing	<ul style="list-style-type: none"> • Is there respiratory distress? • Is the patient hypoventilating? • Is the patient cyanotic or hypoxic? • Auscultate the chest 	<ul style="list-style-type: none"> • Provide high flow oxygen^a • Provide bag-valve-mask ventilation if hypoventilating
Circulation	<ul style="list-style-type: none"> • Check for pulse while getting blood pressure measurement • Look for other signs of hypoperfusion (i.e., capillary refill, skin temperature) • Place on electrocardiographic monitor to look for dysrhythmias • Look for obvious bleeding • If hypotensive or signs hypoperfusion, consider bedside ultrasound^b 	<ul style="list-style-type: none"> • Establish intravenous access • Two large bore intravenous lines are needed in patients who are hemodynamically unstable • Fluid challenge with intravenous crystalloid if hypotensive or has other signs of hypoperfusion • Stop hemorrhage if accessible
Disability	<ul style="list-style-type: none"> • Examine pupils • Assess responsiveness using a scale such as the RASS • Check finger-stick blood glucose • Consider toxicologic causes (i.e., opioid overdose) 	<ul style="list-style-type: none"> • One amp (50 cm³) of D50 in hypoglycemia • Nalaxone in suspected opioid overdose
Exposure	<ul style="list-style-type: none"> • Expose the patient. Minimize heat loss in patients who are normothermic or hypothermic • Look for transdermal drug patches (e.g., fentanyl) that could cause mental status changes • Look for signs of infection 	<ul style="list-style-type: none"> • Remove drug patches

The inferior vena cava can also be assessed using the bedside ultrasound to assess whether a patient is hypovolemic (dehydration, hemorrhage) or hypervolemic (heart failure)

RASS Richmond Agitation and Sedation Scale

^aIn patients who have chronic obstructive pulmonary disease, high flow oxygen may remove their respiratory drive especially in patients with chronic respiratory failure. Oxygen saturation should be titrated to the low 90s%

^bPoint-of-care ultrasound can be used to rapidly rule out causes of hypotension such as cardiac tamponade and intra-abdominal blood in the emergency department

If the patient is hypotensive, IV crystalloid fluid resuscitation should commence immediately. If the finger-stick blood sugar indicates hypoglycemia, one ampule (50 cm³) of D50 should be administered intravenously. Alternatively, 2 mg glucagon can be given intramuscularly if intravenous access is difficult to obtain. In ethanol abuse or malnourished patients, thiamine 100 mg given parenterally or intramuscularly can also be considered if Wernicke's encephalopathy is suspected. Based upon animal models, there is a theoretical risk that glucose administration may worsen encephalopathy in those who are thiamine deficient [48]. As a result, thiamine should be given prior to glucose administration.

If the AMS patient's airway or respiratory status is tenuous, or if opioid overdose is suspected, naloxone should be considered. The initial dose of naloxone is not well established, but is generally considered to be 0.4 mg intravenously. This initial dose should be diluted in 10 cm³ of normal saline and be administered slowly over several minutes to avoid severe withdrawal symptoms. If there is no response, then the dose can be escalated to 2 mg and up to 10 mg intravenously. Such higher doses may be needed if the patient is on a long-acting opioid medication such as methadone. Because of the short half-life of naloxone, the clinician should consider a naloxone infusion or anticipate administering several more doses and monitoring the patient very closely. Transdermal fentanyl patches should also be looked for while exposing the patient, and if present, they should be removed immediately. Reversing benzodiazepine overdoses with flumazenil is not routinely recommended because it may elicit life-threatening withdrawal and seizures in patients who are chronic users.

Management of Combative Patients

In patients who are agitated or combative (RASS +3 or +4), verbal de-escalation should be attempted. An attempt at satisfying the patient's physical needs should also be attempted. Initial steps should be to modify the environment which involves dimming or turning off the lights, minimizing auditory stimulation from cardiac monitor or infusion pump alarms, and having family members at the patient's bedside [49, 50].

If this is unsuccessful or the patient is an immediate threat to himself/herself or others, a pharmacologic approach may be necessary. Treatment should target the cause, which is believed to be neurochemical alterations leading to dopamine excess and autonomic hyperactivity [51]. Neuroleptics, benzodiazepines, and a combination of different classes of medications are commonly used in managing these patients (Table 11.6). Intramuscular ketamine is gaining popularity as it has been shown to reliably sedate patients with an adequate safety profile [52–54]. Pain can also precipitate delirium and agitation especially in patients with traumatic injuries. In these cases, opioid medications or regional nerve blocks can be used for pain control and help reduce agitation [55]. If ethanol or benzodiazepine withdrawal is suspected, benzodiazepine and alpha-2 agonists such as clonidine can be administered. For older patients with AMS, benzodiazepines should be avoided unless the patient is believed to be withdrawing from ethanol or benzodiazepines [49, 56] as they can exacerbate delirium. As a result, typical and atypical antipsychotics are preferred in this patient age group.

Table 11.6 Agents for acute undifferentiated agitation in the emergency department

Agents for acute agitation in the emergency department				
Agent	Formulation	Dose (mg)	Onset of action (min)	Max daily dose (mg)
Lorazepam	IV	2	2–3	12
	IM	2–4	3–5	12
Midazolam	IV	2–5	1–5	15
	IM	5	5–10	15
Haloperidol	IV	5–10	5–10	20–30
	IM	5–10	15–20	20–30
Droperidol	IV	2.5–5	3–10	15
	IM	2.5–10	3–10	15
Olanzapine	IM	5–10	15	30
	PO	5–10	30–60	30
Ketamine	IM	4–5/kg	3–4	1000
	IV	0.5–1/kg	0.5	5/kg

Adapted from Vilke GM et al. *J Forensic Leg Med* 2012;19:117–121 [79] and Wilson MP et al. *West J Emerg Med* 2012;13:26–34 [80]. *IV* intravenous, *IM* intramuscular, *PO* oral

Some agitated patients may even require physical restraint prior to giving chemical sedation. If physical restraints are used, then it should be for the shortest time possible, and the prone position should be avoided as this has been associated with increased mortality [57].

History

Obtaining a thorough and accurate history is a critical component to evaluating a patient with acute brain dysfunction. Because these patients, including those with subtle changes in mental status, are unlikely to provide an accurate history [58], most of this information will need to be obtained from a collateral historian. Preferably, this should be a person that also knows the patient's baseline mental status such as a family member, caregiver, or friend.

Timing

In general, more acute (hours to days) changes in mental status indicate a more life-threatening underlying illness as compared to a patient who has gradual (months to years) change. An abrupt (seconds) change in mental status may also suggest a cerebrovascular accident especially in the presence of focal neurologic findings.

Associated Symptoms

Determining associated symptoms can help guide the clinician toward the cause of the mental status change and expedite treatment. Any focal neurologic complaints

should raise suspicion for a neurologic source and lead to neuroimaging. Fevers, chills, or other infectious symptoms should heighten suspicion for sepsis.

Medications

Obtaining the patient's medications, and whether or not there were recent changes, is also important. Because medication history obtained secondhand (i.e., through chart review or from triage) is notoriously inaccurate [59, 60], every effort should be made to obtain an accurate record of the patient's medications. A history of any recent changes or additions to the patient's home medication regimen should be elicited as well as changes in dosages; the clinician should determine if these changes are temporally related to the development of symptoms. In addition to prescribed medications, history of over-the-counter and alternative medication use should also be obtained.

Social History

A social history should focus on alcohol, drug, and tobacco use. This may be important in cases of substance withdrawal or if the patient appears intoxicated. Though often ignored, many elderly patients are abusers of ethanol and sedative-hypnotics [61, 62]. In elderly patients, social history should also investigate the patient's living situation. Elderly patients who administer their own medications should be investigated to ensure that they have not unintentionally overdosed. If such suspicion exists, the clinician can compare fill date to the number of pills present.

Surgical History

Lastly, any recent surgery should be elicited as certain postsurgical complications, particularly infections, can precipitate AMS.

Physical Examination

The First 5 min

A thorough physical exam is particularly important in patients with acute brain dysfunction as it may be the first clue to the cause. Because timely intervention may improve outcomes, a brief but thorough neurologic exam should initially be performed to evaluate for a CVA. Any focal neurologic findings such as hemiparesis, dysarthria, or visual changes should increase the clinician's concern for a CVA. However, some CVAs may cause AMS in the absence of any focal neurologic findings, especially if the right parietal lobe is affected [63]. Basilar artery occlusions can also cause coma and should be considered in the differential diagnosis.

After the First 5 min

When the patient is stabilized and the emergent interventions have been completed, a more thorough physical exam should be performed (Fig. 11.2). The patient should be fully exposed to ensure that no physical abnormalities are missed.

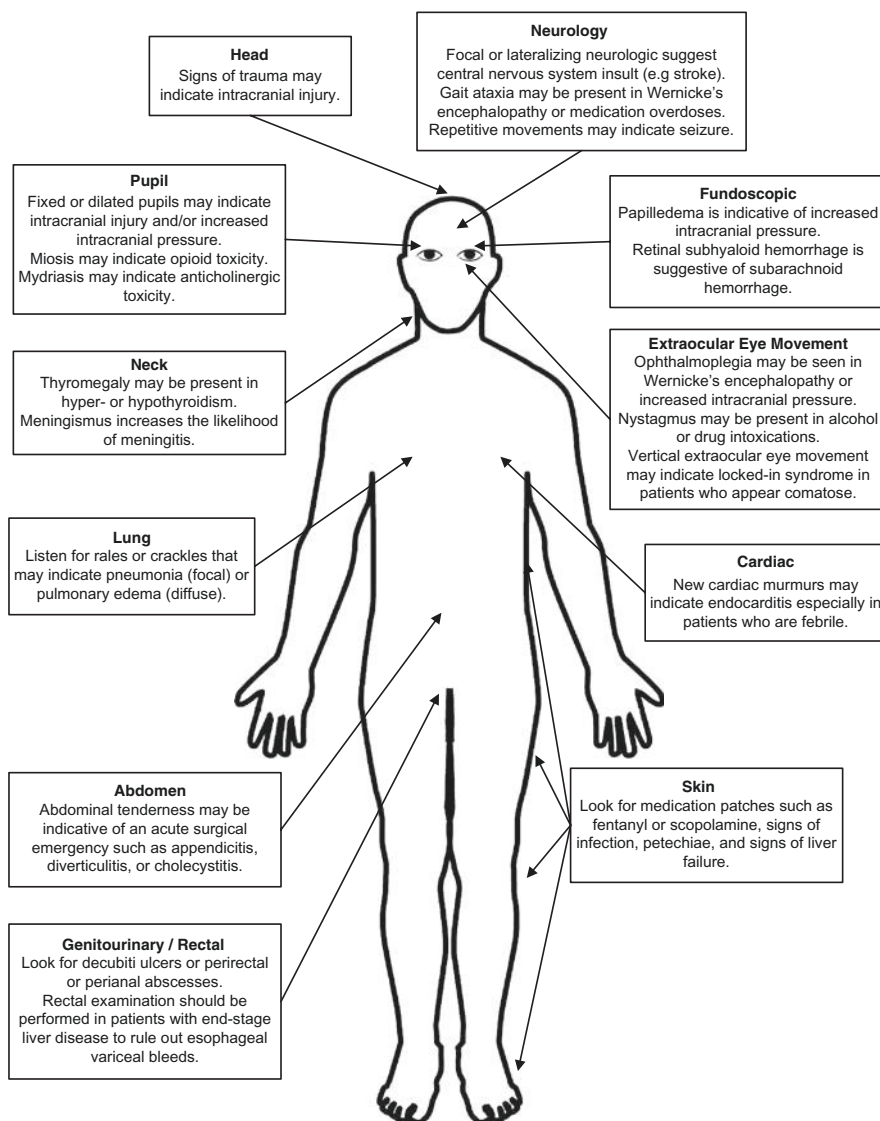


Fig. 11.2 The physical examination of the patient presenting with altered mental status

Ear, Eyes, Nose, and Throat

A head examination should look for any signs of recent head trauma as it can indicate the presence of a subdural hematoma, subarachnoid hemorrhage, or other traumatic intracranial injury. An ocular exam should be performed to look for pupil size/reactivity, extraocular movements, visual field deficits, presence of scleral icterus, presence of proptosis, presence of nystagmus, or presence of exophthalmos. Findings and causes are summarized on Table 11.7. The presence of miosis and mydriasis may indicate opioid and anticholinergic medication toxicity, respectively. If possible, an extraocular muscle examination should also be performed especially in patients who appear to be unresponsive. The presence of vertical eye movements may suggest locked-in syndrome. Ophthalmoplegia may be present in patients with Wernicke's encephalopathy or increased intracranial pressure. The presence of nystagmus may indicate intoxication with alcohol or other drugs. A fundoscopic exam can also be performed to assess for increased intracranial pressure or retinal subhyaloid suggestive of subarachnoid hemorrhage.

Neck

An examination of the patient's neck should focus on presence of thyromegaly indicating thyroid dysfunction. The clinician should also evaluate for meningismus suggestive of meningitis or subarachnoid hemorrhage, although this does not rule out either condition.

Table 11.7 Findings and differential diagnosis on ocular exam

Ocular exam	
Mydriasis	Sympathomimetic Anticholinergic
Miosis	Opiate Pontine stroke
Horizontal nystagmus	Drug intoxication Peripheral nervous system lesion [81]
Vertical nystagmus	Central nervous system lesion [81] Wernicke's encephalopathy
Rotary nystagmus	Drug intoxication Central nervous system lesion
Exophthalmos	Grave's disease (hyperthyroid)
Ophthalmoplegia	Wernicke's encephalopathy Increased intracranial pressure
Proptosis	Retrobulbar hematoma Orbital cellulitis
Scleral icterus	Hepatic failure
Gaze deviation	Seizure Oculogyric crisis
Visual field deficit	Central retinal artery occlusion Occipital lobe infarct

Cardiopulmonary

The pulmonary exam may suggest pulmonary edema, pneumonia, or pneumothorax based on auscultation. A cardiac exam should evaluate for rate, rhythm, and extra heart sounds. A new murmur may suggest cardiogenic shock from a ruptured heart valve or endocarditis in a patient with a fever.

Abdomen

An abdominal exam should focus on tenderness, presence of hepatosplenomegaly, and presence of ascites. Tenderness may suggest intra-abdominal pathology such as cholecystitis, appendicitis, diverticulitis, mesenteric ischemia, or volvulus, among other causes. Hepatosplenomegaly may suggest liver disease, a hematologic cause, or an oncologic cause.

Neurologic

The neurologic examination should assess for focal abnormalities in strength, sensation, and cranial nerves. Reflexes should be obtained to evaluate for hyporeflexia or hyperreflexia. Hyperreflexia may suggest an upper motor neuron lesion, while hyporeflexia may suggest an infectious or demyelinating cause. Gait should be assessed to evaluate for ataxia which may suggest Wernicke's encephalopathy, toxicologic causes, or medication overdoses. Tone, speech, balance, coordination, reflexes, and position sense should also be assessed. Increased tone may suggest a hypermetabolic state or condition such as serotonin syndrome, malignant hyperthermia, or NMS.

Genitourinary

A rectal exam should focus on tone, blood, and pain out of proportion to the exam. Decreased tone may suggest a spinal cord injury from tumor, trauma, or infection. Pain may suggest prostatitis and perirectal or perianal abscess. Melena or frank blood may suggest a gastrointestinal bleed. If present, decubitus ulcers should also be inspected for possible infection, especially in older or immobilized patients.

Skin

A skin exam should focus on both acute and chronic conditions. Findings such as jaundice, scleral icterus, and caput medusa may suggest hepatic encephalopathy. Other findings such as petechiae or purpura may suggest a hematologic cause or infectious cause such as bacterial meningitis. The skin should also be assessed for

soft tissue infections, particularly in the decubitus regions, and for the presence of drug patches (e.g., fentanyl).

Diagnostic Evaluation

The diagnostic evaluation should be tailored to the history and physical examination as described below.

Laboratory Evaluation

Laboratory tests are routinely performed in patients with acute mental status. When the patient initially presents to the ED, a finger-stick blood sugar should be obtained to rule out hypoglycemia.

CBC

A complete blood count (CBC) with differential may reveal a profound anemia or polycythemia. Thrombocytopenia may result in a spontaneous intracranial hemorrhage which can lead to AMS. While not particularly sensitive or specific, marked leukocytosis or leukopenia may suggest an infectious etiology. Leukopenia should also raise suspicion for an immunocompromised state, which demands an even broader differential.

BMP

A basic metabolic profile (BMP) should also be routinely obtained to rule out electrolyte abnormalities such as hypernatremia, hyponatremia, hypercalcemia, or hypocalcemia. Because uremia can precipitate AMS, a BUN and serum creatinine should be ordered. An ionized calcium level should be obtained in patients with hyperparathyroidism, hypercalcemia of malignancy, and patients with a low calcium level on their BMP [64].

LFTs

A liver function panel or liver function tests (LFT) may reveal evidence of liver disease, though normal liver enzymes do not rule out liver disease. Elevated alkaline phosphatase should raise suspicion for gallbladder disease but is nonspecific and may represent bone breakdown. If stigmata of liver disease is present (i.e., jaundice, musky odor, venous varicosities, ascites), an ammonia level should be considered. Though it should not be used for screening [65], it may be helpful for trending when being treated for hepatic encephalopathy to assess response to therapy.

Lipase

A lipase should be considered in patients with upper quadrant or midepigastic pain. Severe acute pancreatitis can even lead to pancreatic encephalopathy, a rare but poorly understood complication of acute pancreatitis [66].

Endocrine Studies

Other important laboratory studies to consider are thyroid function tests and a random cortisol. Patients with hyperthyroidism typically present more classically than those with hypothyroidism. It is important to consider hypothyroidism in elderly patients who are hypoactive as their symptoms are often attributed to age, dementia, etc. Consider adrenal insufficiency in patients who present with hyperkalemia with hyponatremia and in those with shock not responsive to fluids and antibiotics. A random cortisol can help with diagnosis, but further testing is required to confirm the diagnosis.

Urinalysis

A urinalysis should be considered in patients with acute brain dysfunction, particularly in elderly patients. Results should be carefully interpreted, however, as asymptomatic bacteriuria is common among all age groups and is frequently overtreated [67]. The diagnosis of a UTI should be based on several factors rather than by urinalysis alone. A urinalysis can also assist in determining hydration status based on the urine specific gravity and presence/absence of ketones. It can also suggest other diagnoses such as rhabdomyolysis if blood is present without red blood cells.

Toxicologic Evaluation

A urine drug screen (UDS) may be helpful but must be interpreted with caution. Though they can be obtained rapidly, they are prone to false positives, are not particularly sensitive, and rely on multiple factors for detection [68]. In patients with a toxic overdose in which the substance is unknown, or concern for polysubstance ingestion is present, a serum osmolality should be drawn to evaluate for toxic alcohols. Acetaminophen and salicylate levels should be considered in this patient population as well.

Lumbar Puncture

A lumbar puncture can evaluate for several etiologies including bacterial and viral meningitis, neurosyphilis, cryptococcal meningitis, Lyme disease, and several forms of encephalitis including anti-NMDA (N-methyl-aspartate) encephalitis. A lumbar puncture should be considered in patients with acute brain dysfunction particularly if no cause has been discovered, the patient is immunocompromised, or the patient has a history of fever. In a patient with AMS, a head CT is recommended prior to lumbar puncture due to a potential risk of iatrogenic herniation if increased intracranial pressure (ICP) is present [69]. The basic evaluation of cerebral spinal fluid (CSF) should include total WBC count, protein, glucose, and culture. If concerns for other processes are present, specific antigens should be sent. We also recommend drawing an additional 3–4 cm³ to freeze in the event that further testing is needed in the future.

Radiography

A chest x-ray should be considered to evaluate for an infectious infiltrate in the undifferentiated patient with acute brain dysfunction. It may also be useful to identify a pneumothorax, neoplasm, pulmonary edema, or pleural effusion. If the patient has a tender abdomen, the clinician should pay particular attention to the

hemidiaphragms on the film to evaluate for free air. Similarly, an abdominal x-ray should be considered in patients with abdominal pain. Though much less sensitive than an abdominal computed tomography (CT) scan, they are usually much quicker to obtain. The clinician should evaluate for free air, an obstructive bowel gas pattern, presence of a volvulus, and air within the walls of the bowel.

ECG

An electrocardiogram (ECG) should be considered in those with acute brain dysfunction, particularly those whose heart is bradycardic or tachycardic. It should be evaluated for rate, rhythm, ischemia, and intervals.

EEG

Nonconvulsive status epilepticus (NCSE) should be considered in two major patient populations: those in which no cause can be discovered and those with a seizure history or who seized prior to arrival. The incidence of NCSE in patients with AMS is 8–30% [70]. It is an under-recognized and therefore undertreated cause of acute brain dysfunction. Electroencephalography (EEG) should be performed on patients with suspected NCSE.

Neuroimaging

Depending on the suspected cause, neuroimaging should be considered. A summary of neuroimaging is listed in Table 11.8.

Non-contrast Head CT

A non-contrast head CT is the most common neuroimaging test ordered in the ED and is generally the first line of imaging due to its speed and availability. It provides rapid information about hemorrhage, infarction, tumor, cerebral edema, and bony

Table 11.8 Common neuroimaging modalities and indications

Neuroimaging		
	CT	MRI
No contrast	Intracranial hemorrhage Assessing ICP	CVA [73] Posterior fossa [74]
With contrast	Tumor Mass Abscess Immunocompromised	Tumor Mass Abscess Immunocompromised
Angiogram	CVA [71] Dissection Aneurysm	Contrast contraindication
Venogram	Dural venous thrombosis	Contrast contraindication

CT computed tomography, *MRI* magnetic resonance imaging, *ICP* intracranial pressure, *CVA* cerebrovascular accident

injury [71] and should be considered if there is any concern for those processes or no other cause of AMS has been discovered. For older patients who are delirious, performing routine head CT is controversial [72]. In general, though, older patients with delirium should receive a head CT if there has been history of trauma, a focal neurologic deficit, or impaired level of consciousness [29, 72].

CT Angiography

CT angiography can be performed by injecting contrast and timing the uptake into the intracranial vasculature while obtaining images. Imaging is highly sensitive for detecting stenosis of vessels, aneurysms, and dissections. It can additionally be used to estimate perfusion of the brain parenchyma [71] and whether or not a vertebral or basilar artery CVA is present.

Brain MRI

Though MRI is a more time-consuming imaging modality and is not available in all centers, it has the advantage of being radiation-free and is superior at detecting ischemic change [73] and visualizing the posterior fossa [74]. A brain MRI can also be considered if no other etiologies for the patient's AMS are found. If MRI is unavailable or the patient has a contraindication, a contrast-enhanced CT may be the test of choice.

Disposition

Disposition for patients with acute brain dysfunction depends on the cause and stability of the patient:

- Stuporous or comatose patients will need hospital admission and likely require the intensive care unit.
- Patients with a CVA should be admitted to a stroke care unit as this has been associated with improved mortality and outcomes [75].
- If the cause of AMS is toxicologic, a poison center should be consulted (1-800-222-1222). Poison centers can help with the treatment and stabilization of the patient and can assist with disposition as well. Many ingestions require 24-h monitoring even with stable vital signs.
- If a cause is determined and symptoms resolve, observation or discharge home with close supervision and close follow-up can be considered.
- A psychiatric cause should be a diagnosis of exclusion. A psychiatry and/or neurologic consultation should be strongly considered prior to discharging a patient or admitting a patient to a psychiatric treatment facility.

For many patients, the cause of acute brain dysfunction is not determined. If the cause is thought to be delirium, particularly in elderly patients, there is little

evidence-based guidance regarding their disposition. There is some evidence, however, that those who are discharged from the ED are more likely to die than non-delirious patients, particularly if the diagnosis of delirium is missed by the ED [76]. If discharge is indeed deemed suitable, close supervision and outpatient follow-up should be ensured.

Pearls and Pitfalls

Pearls

- Obtain a thorough history.
- Perform a thorough physical exam.
- Obtain blood glucose early.
- Determine baseline early.
- Keep a broad differential.
- Consider medical causes of AMS in psychiatric patients, especially when visual hallucinations are present.
- Expect atypical presentations of medical problems in psychiatric patients.

Pitfalls

- Forgoing skin/rectal exam
- Anchoring on the first positive finding (i.e., UTI is primary cause)
- Relying on chart for medical history and medication list
- Attributing AMS to a psychiatric disorder

Critical features: history	
<i>Likely emergent</i>	<i>Less likely to be emergent</i>
Vital sign abnormalities	New or change in medications
Young age	Older age
Neurologic deficits	History of similar episodes
Sudden onset	Gradual onset
Fever	History of dementia

Critical features: physical exam	
ABCs	Must be secured before moving forward
Finger-stick glucose	Hypoglycemia can present in many ways
Neurologic exam	Evaluate for CVA quickly
Survey for trauma	A medical vs. trauma differentiation must be done early
Ocular exam	Pupils, extraocular movements, visual fields, nystagmus
Neck	Masses, scars, presence/absence of rigidity
Cardiopulmonary	Breath sounds, heart rate and rhythm
Abdominal exam	Tenderness, masses
Rectal exam	Tone, pain, blood
Skin exam	Eruptions, fistulas, skin color, liver failure sequelae

References

1. Morandi A, Pandharipande P, Trabucchi M, Rozzini R, Mistraletti G, Trompeo AC, et al. Understanding international differences in terminology for delirium and other types of acute brain dysfunction in critically ill patients. *Intensive Care Med.* 2008;34(10):1907–15.
2. Clarfield AM. The decreasing prevalence of reversible dementias: an updated meta-analysis. *Arch Intern Med.* 2003;163(18):2219–29.
3. American Psychiatric Association, American Psychiatric Association. DSM-5 Task Force. Diagnostic and statistical manual of mental disorders: DSM-5. 5th ed. Washington, DC: American Psychiatric Association; 2013. xlv, 947p.
4. Han JH, Schnelle JF, Ely EW. The relationship between a chief complaint of “altered mental status” and delirium in older emergency department patients. *Acad Emerg Med.* 2014;21(8):937–40.
5. Gill MR, Reiley DG, Green SM. Interrater reliability of Glasgow coma scale scores in the emergency department. *Ann Emerg Med.* 2004;43(2):215–23.
6. McNarry AF, Goldhill DR. Simple bedside assessment of level of consciousness: comparison of two simple assessment scales with the Glasgow coma scale. *Anaesthesia.* 2004;59(1):34–7.
7. Sessler CN, Gosnell MS, Grap MJ, Brophy GM, O’Neal PV, Keane KA, et al. The Richmond agitation-sedation scale: validity and reliability in adult intensive care unit patients. *Am J Respir Crit Care Med.* 2002;166(10):1338–44.
8. Ely EW, Truman B, Shintani A, Thomason JW, Wheeler AP, Gordon S, et al. Monitoring sedation status over time in ICU patients: reliability and validity of the Richmond agitation-sedation scale (RASS). *JAMA.* 2003;289(22):2983–91.
9. Hustey FM, Meldon SW, Smith MD, Lex CK. The effect of mental status screening on the care of elderly emergency department patients. *Ann Emerg Med.* 2003;41(5):678–84.
10. Pandharipande PP, Girard TD, Jackson JC, Morandi A, Thompson JL, Pun BT, et al. Long-term cognitive impairment after critical illness. *N Engl J Med.* 2013;369(14):1306–16.
11. Han JH, Shintani A, Eden S, Morandi A, Solberg LM, Schnelle J, et al. Delirium in the emergency department: an independent predictor of death within 6 months. *Ann Emerg Med.* 2010;56(3):244–52.
12. Han JH, Eden S, Shintani A, Morandi A, Schnelle J, Dittus RS, et al. Delirium in older emergency department patients is an independent predictor of hospital length of stay. *Acad Emerg Med.* 2011;18(5):451–7.
13. Gross AL, Jones RN, Habtemariam DA, Fong TG, Tommet D, Quach L, et al. Delirium and long-term cognitive trajectory among persons with dementia. *Arch Intern Med.* 2012;172(17):1–8.
14. McCusker J, Cole M, Dendukuri N, Belzile E, Primeau F. Delirium in older medical inpatients and subsequent cognitive and functional status: a prospective study. *CMAJ.* 2001;165(5):575–83.
15. Young J, Murthy L, Westby M, Akunne A, O’Mahony R. Diagnosis, prevention, and management of delirium: summary of NICE guidance. *BMJ.* 2010;341:c3704.
16. Barr J, Fraser GL, Puntillo K, Ely EW, Gelinas C, Dasta JF, et al. Clinical practice guidelines for the management of pain, agitation, and delirium in adult patients in the intensive care unit. *Crit Care Med.* 2013;41(1):278–80.
17. Carpenter CR, Bromley M, Caterino JM, Chun A, Gerson LW, Greenspan J, et al. Optimal older adult emergency care: introducing multidisciplinary geriatric emergency department guidelines from the American College of Emergency Physicians, American Geriatrics Society, Emergency Nurses Association, and Society for Academic Emergency Medicine. *Ann Emerg Med.* 2014;63(5):e1–3.
18. Wong CL, Holroyd-Leduc J, Simel DL, Straus SE. Does this patient have delirium?: value of bedside instruments. *JAMA.* 2010;304(7):779–86.
19. Han JH, Wilson A, Vasilevskis EE, Shintani A, Schnelle JF, Dittus RS, et al. Diagnosing delirium in older emergency department patients: validity and reliability of the delirium triage screen and the brief confusion assessment method. *Ann Emerg Med.* 2013;62(5):457–65.

20. Han JH, Wilson A, Graves AJ, Shintani A, Schnelle JF, Dittus RS, et al. Validation of the confusion assessment method for the intensive care unit in older emergency department patients. *Acad Emerg Med.* 2014;21(2):180–7.
21. Marcantonio ER, Ngo LH, O'Connor M, Jones RN, Crane PK, Metzger ED, et al. 3D-CAM: derivation and validation of a 3-minute diagnostic interview for CAM-defined delirium: a cross-sectional diagnostic test study. *Ann Intern Med.* 2014;161(8):554–61.
22. Bellelli G, Morandi A, Davis DH, Mazzola P, Turco R, Gentile S, et al. Validation of the 4AT, a new instrument for rapid delirium screening: a study in 234 hospitalised older people. *Age Ageing.* 2014;43(4):496–502.
23. Kean J, Trzepacz PT, Murray LL, Abell M, Trexler L. Initial validation of a brief provisional diagnostic scale for delirium. *Brain Inj.* 2010;24(10):1222–30.
24. Sands MB, Dantoc BP, Hartshorn A, Ryan CJ, Lujic S. Single question in delirium (SQiD): testing its efficacy against psychiatrist interview, the confusion assessment method and the memorial delirium assessment scale. *Palliat Med.* 2010;24(6):561–5.
25. Han JH, Vasilevskis EE, Schnelle JF, Shintani A, Dittus RS, Wilson A, et al. The diagnostic performance of the Richmond agitation sedation scale for detecting delirium in older emergency department patients. *Acad Emerg Med.* 2015;22(7):878–82.
26. Fabbri RM, Moreira MA, Garrido R, Almeida OP. Validity and reliability of the Portuguese version of the confusion assessment method (CAM) for the detection of delirium in the elderly. *Arq Neuropsiquiatr.* 2001;59(2-A):175–9.
27. Francis J, Martin D, Kapoor WN. A prospective study of delirium in hospitalized elderly. *JAMA.* 1990;263(8):1097–101.
28. Inouye SK. Delirium in hospitalized elderly patients: recognition, evaluation, and management. *Conn Med.* 1993;57(5):309–15.
29. Elie M, Cole MG, Primeau FJ, Bellavance F. Delirium risk factors in elderly hospitalized patients. *J Gen Intern Med.* 1998;13(3):204–12.
30. Schor JD, Levkoff SE, Lipsitz LA, Reilly CH, Cleary PD, Rowe JW, et al. Risk factors for delirium in hospitalized elderly. *JAMA.* 1992;267(6):827–31.
31. Marcantonio ER, Goldman L, Mangione CM, Ludwig LE, Muraca B, Haslauer CM, et al. A clinical prediction rule for delirium after elective noncardiac surgery. *JAMA.* 1994;271(2):134–9.
32. Gustafson Y, Berggren D, Brannstrom B, Bucht G, Norberg A, Hansson LI, et al. Acute confusional states in elderly patients treated for femoral neck fracture. *J Am Geriatr Soc.* 1988;36(6):525–30.
33. Jitapunkul S, Pillay I, Ebrahim S. Delirium in newly admitted elderly patients: a prospective study. *Q J Med.* 1992;83(300):307–14.
34. Kolbeinsson H, Jonsson A. Delirium and dementia in acute medical admissions of elderly patients in Iceland. *Acta Psychiatr Scand.* 1993;87(2):123–7.
35. Rockwood K. Acute confusion in elderly medical patients. *J Am Geriatr Soc.* 1989;37(2):150–4.
36. Pompei P, Foreman M, Rudberg MA, Inouye SK, Braund V, Cassel CK. Delirium in hospitalized older persons: outcomes and predictors. *J Am Geriatr Soc.* 1994;42(8):809–15.
37. Upadhyay A, Jaber BL, Madias NE. Incidence and prevalence of hyponatremia. *Am J Med.* 2006;119(7 Suppl 1):S30–S5.
38. Tasdemir V, Oguz AK, Sayin I, Ergun I. Hyponatremia in the outpatient setting: clinical characteristics, risk factors, and outcome. *Int Urol Nephrol.* 2015;47(12):1977–83.
39. Barri YM, Knochel JP. Hypercalcemia and electrolyte disturbances in malignancy. *Hematol Oncol Clin North Am.* 1996;10:775–90.
40. Hurley K, Baggs D. Hypocalcemic cardiac failure in the emergency department. *J Emerg Med.* 2005;28(2):155–9.
41. Chavan CB, Sharada K, Rao HB, Narsimhan C. Hypocalcemia as a cause of reversible cardiomyopathy with ventricular tachycardia. *Ann Intern Med.* 2007;146(7):541–2.
42. Waika SS, Bonventre JV. Acute kidney injury. New York: McGraw-Hill; 2015. <http://access-medicine.mhmedical.com/content.aspx?bookid=1130&Sectionid=79746409>.
43. Kwaku MP, Burman KD. Myxedema coma. *J Intensive Care Med.* 2007;22(4):224–31.

44. Rehman SU, Cope DW, Senseney AD, Brezezinski W. Thyroid disorders in elderly patients. *South Med J*. 2005;98(5):543–9.
45. Jones AE, Trzeciak S, Kline JA. The sequential organ failure assessment score for predicting outcome in patients with severe sepsis and evidence of hypoperfusion at the time of emergency department presentation. *Crit Care Med*. 2009;37(5):1649–54.
46. Cardenas-Turan M, Ensor J, Wakefield C, Zhang K, Wallace SK, Price KJ, et al. Cross-validation of a sequential organ failure assessment score-based model to predict mortality in patients with cancer admitted to the intensive care unit. *J Crit Care*. 2012;27(6):673–80.
47. Felker B, Yazel JJ, Short D. Mortality and medical comorbidity among psychiatric patients: a review. *Psychiatr Serv*. 1996;47(12):1356–63.
48. Zimitat C, Nixon PF. Glucose loading precipitates acute encephalopathy in thiamin-deficient rats. *Metab Brain Dis*. 1999;14(1):1–20.
49. Practice guideline for the treatment of patients with delirium. American Psychiatric Association. *Am J Psychiatry*. 1999;156(5 Suppl):1–20.
50. Inouye SK, Bogardus ST Jr, Charpentier PA, Leo-Summers L, Acampora D, Holford TR, et al. A multicomponent intervention to prevent delirium in hospitalized older patients. *N Engl J Med*. 1999;340(9):669–76.
51. Takeuchi A, Ahern TL, Henderson SO. Excited delirium. *West J Emerg Med*. 2011;12(1):77–83.
52. Green SM, Rothrock SG, Lynch EL, Ho M, Harris T, Hestdalen R, et al. Intramuscular ketamine for pediatric sedation in the emergency department: safety profile in 1,022 cases. *Ann Emerg Med*. 1998;31(6):688–97.
53. Schepke KA, Braghiroli J, Shalaby M, Chait R. Prehospital use of i.m. ketamine for sedation of violent and agitated patients. *West J Emerg Med*. 2014;15(7):736–41.
54. Hopper AB, Vilke GM, Castillo EM, Campillo A, Davie T, Wilson MP. Ketamine use for acute agitation in the emergency department. *J Emerg Med*. 2015;48(6):712–9.
55. Vaurio LE, Sands LP, Wang Y, Mullen EA, Leung JM. Postoperative delirium: the importance of pain and pain management. *Anesth Analg*. 2006;102(4):1267–73.
56. National Institute of Health and Clinical Excellence. Delirium: diagnosis, prevention, and management. (Clinical guideline 103). 2010. <http://publications.nice.org.uk/delirium-cg103>.
57. Chan TC, Vilke GM, Neuman T, Clausen JL. Restraint position and positional asphyxia. *Ann Emerg Med*. 1997;30(5):578–86.
58. Han JH, Bryce SN, Ely EW, Kripalani S, Morandi A, Shintani A, et al. The effect of cognitive impairment on the accuracy of the presenting complaint and discharge instruction comprehension in older emergency department patients. *Ann Emerg Med*. 2011;57(6):662–71.
59. Mazer M, Deroos F, Hollander JE, McCusker C, Peacock N, Perrone J. Medication history taking in emergency department triage is inaccurate and incomplete. *Acad Emerg Med*. 2011;18(1):102–4.
60. Staroselsky M, Volk LA, Tsurikova R, Newmark LP, Lippincott M, Litvak I, et al. An effort to improve electronic health record medication list accuracy between visits: patients' and physicians' response. *Int J Med Inform*. 2008;77(3):153–60.
61. Finlayson RE, Davis LJ Jr. Prescription drug dependence in the elderly population: demographic and clinical features of 100 inpatients. *Mayo Clin Proc*. 1994;69(12):1137–45.
62. Blazer DG, Wu LT. The epidemiology of substance use and disorders among middle aged and elderly community adults: national survey on drug use and health. *Am J Geriatr Psychiatry*. 2009;17(3):237–45.
63. Mesulam MM, Waxman SG, Geschwind N, Sabin TD. Acute confusional states with right middle cerebral artery infarctions. *J Neurol Neurosurg Psychiatry*. 1976;39(1):84–9.
64. Calvi LM, Bushinsky DA. When is it appropriate to order an ionized calcium? *J Am Soc Nephrol*. 2008;19(7):1257–60.
65. Stahl J. Studies of the blood ammonia in liver disease. Its diagnostic, prognostic, and therapeutic significance. *Ann Intern Med*. 1963;58:1–24.
66. Zhang XP, Tian H. Pathogenesis of pancreatic encephalopathy in severe acute pancreatitis. *Hepatobiliary Pancreat Dis Int*. 2007;6(2):134–40.

67. Schulz L, Hoffman RJ, Pothof J, Fox B. Top ten myths regarding the diagnosis and treatment of urinary tract infections. *J Emerg Med.* 2016.
68. Moeller KE, Lee KC, Kissack JC. Urine drug screening: practical guide for clinicians. *Mayo Clin Proc.* 2008;83(1):66–76.
69. Hasbun R, Abrahams J, Jekel J, Quagliarello VJ. Computed tomography of the head before lumbar puncture in adults with suspected meningitis. *N Engl J Med.* 2001;345(24):1727–33.
70. Zehtabchi S, Abdel Baki SG, Malhotra S, Grant AC. Nonconvulsive seizures in patients presenting with altered mental status: an evidence-based review. *Epilepsy Behav.* 2011;22(2):139–43.
71. Broder JPR. Imaging the head and brain. In: Broder J, editor. *Diagnostic imaging for the emergency physician.* Philadelphia, PA: Elsevier Saunders; 2011. p. 1–45.
72. Naughton BJ, Moran M, Ghaly Y, Michalakes C. Computed tomography scanning and delirium in elder patients. *Acad Emerg Med.* 1997;4(12):1107–10.
73. Fiebich JB, Schellinger PD, Jansen O, Meyer M, Wilde P, Bender J, et al. CT and diffusion-weighted MR imaging in randomized order: diffusion-weighted imaging results in higher accuracy and lower interrater variability in the diagnosis of hyperacute ischemic stroke. *Stroke.* 2002;33(9):2206–10.
74. Teasdale GM, Hadley DM, Lawrence A, Bone I, Burton H, Grant R, et al. Comparison of magnetic resonance imaging and computed tomography in suspected lesions in the posterior cranial fossa. *BMJ.* 1989;299(6695):349–55.
75. Jorgensen HS, Nakayama H, Raaschou HO, Larsen K, Hubbe P, Olsen TS. The effect of a stroke unit: reductions in mortality, discharge rate to nursing home, length of hospital stay, and cost. A community-based study. *Stroke.* 1995;26(7):1178–82.
76. Kakuma R, du Fort GG, Arsenault L, Perrault A, Platt RW, Monette J, et al. Delirium in older emergency department patients discharged home: effect on survival. *J Am Geriatr Soc.* 2003;51(4):443–50.
77. Pun BT, Ely EW. The importance of diagnosing and managing ICU delirium. *Chest.* 2007;132(2):624–36.
78. Fearing MA, Inouye SK. Delirium. In: Blazer DG, Steffens DC, editors. *The American Psychiatric Publishing textbook of geriatric psychiatry.* 4th ed. Washington, DC: American Psychiatric Publishing; 2009.
79. Vilke GM, Bozeman WP, Dawes DM, Demers G, Wilson MP. Excited delirium syndrome (ExDS): treatment options and considerations. *J Forensic Legal Med.* 2012;19(3):117–21.
80. Wilson MP, Pepper D, Currier GW, Holloman GH Jr, Feifel D. The psychopharmacology of agitation: consensus statement of the american association for emergency psychiatry project Beta psychopharmacology workgroup. *West J Emerg Med.* 2012;13(1):26–34.
81. Kerber KA. Vertigo and dizziness in the emergency department. *Emerg Med Clin North Am.* 2009;27(1):39–50.

Latha Ganti and Vaibhav Rastogi

Case Presentation

A 37-year-old male presents to your emergency department Saturday afternoon complaining of generalized weakness, a feeling of being wiped out, and no strength in his legs. It started the previous day at work, and by midday today, he knew something was wrong. His kids had been sick with a cold the last week, and he too just recovered from an upper respiratory infection a few days before that. He reports back pain as well. He took 800 mg of ibuprofen with minimal relief. On neurologic exam, he is fully awake and alert, without any change in level of consciousness. He has decreased power in both his upper and lower extremities. His deep tendon reflexes are difficult to detect. He does not have dysmetria or dysarthria. He states “I feel weak.”

Introduction

Weakness is a common complaint in the emergency department (ED) and a most challenging one because before the emergency physician can proceed with an evaluation, the complaint of “weakness” must be fully clarified to determine what the patient is actually complaining about.

A prospective observational study from Switzerland underscores the vast differential diagnosis of the chief complaint of weakness [1]. Of 79 consecutive patients presenting to the ED with generalized weakness, the spectrum of diagnoses spanned 14 distinct ICD-10 codes. The most frequent were diseases of the respiratory system

L. Ganti, M.D., M.S., M.B.A., F.A.C.E.P. (✉)
University of Central Florida College of Medicine, Orlando, FL, USA
e-mail: latha.ganti@ucf.edu

V. Rastogi, M.D.
University of Central Florida College of Medicine, Orlando, FL, USA

(18%), followed by endocrine, nutritional, and metabolic diseases (14%), and neoplasms (10%). Infections were the most common cause of generalized weakness. The authors attributed this to the median age of 78 in their cohort; this highlights the fact that older patients may not have fever, cough, or other specific signs of infection, but rather present as generalized weakness.

When patients complain about weakness, the first distinction that is important to make is whether it is true neuromuscular weakness or rather feeling fatigue, malaise, or asthenia. Fatigue is the inability to continue performing a task after multiple repetitions—the muscle gets weak after sustained activity. Malaise is a general feeling of being ill or having no energy. Malaise is perhaps more properly described as asthenia, which is defined as a sense of weariness or exhaustion in the absence of muscle weakness [2]. The key difference is that with true neuromuscular weakness, the patient is unable to partially or fully perform the task in the first place.

Weakness can be unilateral or bilateral. The most common cause of unilateral weakness is acute brain infarction or ischemia (stroke or TIA) and intracerebral hemorrhage (including subarachnoid hemorrhage; see Chap. 2). Poisons are also a class of other potential contributors to weakness, which have their own vast separate discussion. The focus of this chapter will thus be causes of acute generalized non-traumatic bilateral weakness. Evaluation begins with the history and physical examination followed by diagnostic testing in some cases.

History

Onset

The timing of weakness can sometimes provide a clue to diagnosis. Generally, weakness that develops minutes to hours prior to presentation is due to metabolic (electrolyte) or toxic disorders or stroke. Weakness that began within the last 24 h includes etiologies such as acute porphyric neuropathy, Guillain-Barré syndrome (GBS), myasthenia gravis (MG), and tick paralysis. Weakness that has been going on for a week or longer is often associated with peripheral nerve problems and NMJ diseases. Weakness characterized by frequent relapses is suggestive of multiple sclerosis, periodic paralysis, and myasthenia gravis. Weakness that is transient in nature is seen with peripheral nerve entrapment problems, hemiplegic migraine, and periodic paralysis.

Description of Weakness

Asking the patient what they can no longer do or do without difficulty is a good start to localizing the problem. For example, difficulty combing one's hair or climbing stairs suggests proximal muscle weakness, whereas difficulty buttoning one's shirt or turning a door knob indicates distal muscle weakness. Dysphagia, a nasal voice, and dysarthria are associated with bulbar muscle weakness and raise

Table 12.1 Drugs that can cause myopathy

HMG Co-A reductase inhibitors (statins)
Gemfibrozil
Alcohol
D-penicillamine
Interferon-a
Procainamide
Zidovudine
Lamivudine
Germanium
Colchicine
Vincristine
Quinine drugs
Amiodarone
Emetine
Ipecac
Corticosteroids
Hydroxyurea
Leuprolide
Sulfonamides

From: Ganti and Rastogi [42]

concern for impending airway compromise. Generally, proximal muscle weakness suggests a myopathic process, while distal muscle weakness indicates a (poly) neuropathy.

Comorbidities

Underlying systemic illnesses can contribute to the presentation of weakness. For example, diabetes and some rheumatic disorders cause neuropathy.

Family History

A family history of dystrophy, periodic paralysis, porphyria, paraneoplastic syndromes, and hereditary predisposition to pressure palsies can be important in generating an appropriate differential diagnosis. Sometimes patients may not know the names of diseases, so asking about specific symptoms as in the patient history may be more useful.

Medications

A number of medications can cause myopathy (muscle disease), most notably the statins that are in widespread use. Table 12.1 summarizes some of the most common drugs associated with myopathies [3, 4]. Myopathies can also be inherited such as muscular dystrophies or acquired.

Physical Examination

Motor Nervous System

Weakness can be caused by problems affecting upper motor neurons (UMNs), lower motor neurons (LMNs), the neuromuscular junction (NMJ), or the muscle itself (Fig. 12.1).

The LMNs are comprised of anterior horn cells (AHC) and innervate the skeletal muscle. UMNs provide impulses and regulate the activity of lower motor neurons [5]. The neuromuscular junction is a chemical synapse formed by the contact between the motor neuron and a muscle fiber.

The motor neuronal pathway originates in the primary motor cortex (precentral gyrus) of the cerebral cortex. The corticobulbar and corticospinal tracts are the two main pathways of motor conduction, with the majority of axons from the corticospinal tract. Corticobulbar fibers terminate in the brain stem. Corticospinal fibers pass through the internal capsule; most of them cross to the contralateral side in the brain stem (pyramidal decussations of the medulla) and continue as lateral corticospinal tract in the spinal cord. They ultimately terminate in the gray matter of the spinal cord. Peripheral nerves (LMNs) arising from the spinal cord supply skeletal muscle. LMN disorders affect a particular muscle that is innervated by that nerve. Signs of LMN disease include decreased muscle tone, hyporeflexia, fasciculations, and an absent Babinski sign (Table 12.2). The Babinski sign is extension (rather than the normal flexion response) of the hallux (great toe) in response to stimulation of the sole of the foot with a blunt instrument.

Examples of LMN problems include poliomyelitis, lower spinal cord injury (L4–S2) with nerve root compression, amyotrophic lateral sclerosis (ALS), progressive spinal muscular atrophy, spondylotic myelopathy, and radiation myelopathy. Problems that affect the peripheral nerves include trauma (including entrapment); toxins such as lead, alcohol, and many drugs; infectious causes such as diphtheria, Lyme disease, and HIV; inflammatory polyneuropathies such as GBS; metabolic derangements such as diabetes and porphyria; vascular problems such as autoimmune arteritis; nutritional disturbances such as vitamin B1 or B12 deficit or pyridoxine toxicity; heredity conditions such as Charcot-Marie-Tooth disease; neoplasms; and abnormal proteins (amyloidosis).

By contrast, UMN disorders have widespread manifestations and a more complicated pathophysiology. Signs of UMN disease include increased muscle tone (spasticity), hyperreflexia, and a positive Babinski. Examples of problems associated with UMN disease include cerebrovascular accidents, intracranial tumor, cervical spine injury (C1–C6), transverse myelitis, HIV, ALS, cerebral palsy, multiple sclerosis, and spinal stenosis.

Diseases of the NMJ are characterized by fluctuating strength based on muscle use. The classic examples of NMJ diseases are myasthenia gravis, where repeated contractions result in *decreasing* power, and Eaton-Lambert myasthenic syndrome

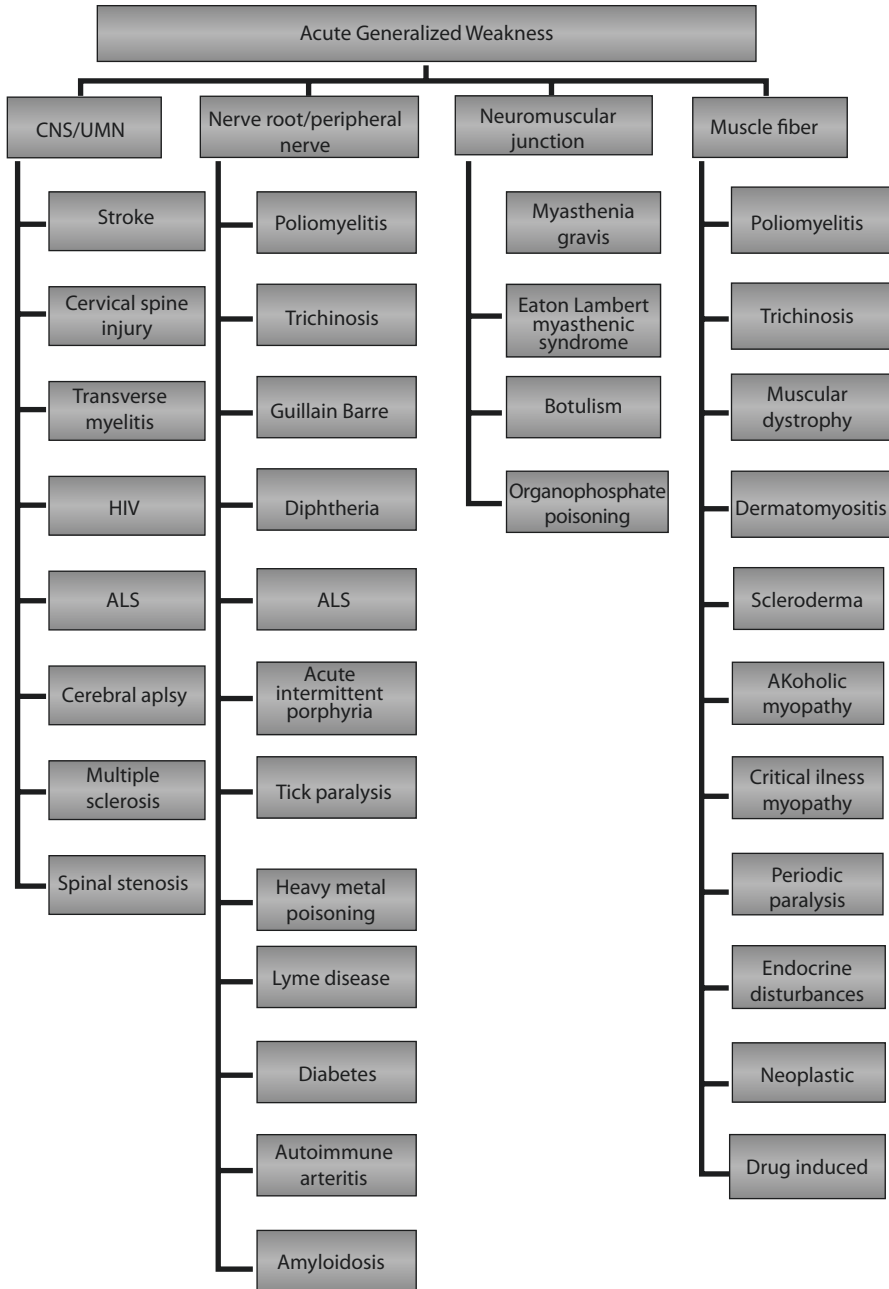


Fig. 12.1 Anatomic localization of various etiologies of muscle weakness

Table 12.2 Comparison of the signs of upper motor neuron vs. lower motor neuron

Sign	UMN	LMN
Reflexes	Increased	Decreased
Atrophy	Absent	Present
Weakness	Present	Present
Fasciculations	Absent	Present
Tone	Increased	Decreased
Extensor	Present	Absent

in which repeated contractions result in *increasing* power. Botulism and organo-phosphate poisoning are other examples.

Diseases that cause myopathy include congenital problems such as muscular dystrophy; infection such as trichinosis; connective tissue disease such as polymyositis, scleroderma, and mixed connective tissue disorder; endocrine derangements such as hypo-/hyperthyroidism, hyperparathyroidism, and hypo-/hyperadrenalism; neoplastic; and drug-induced.

Elements of the Motor Examination

The motor component of the neurological examination comprises of four main elements [6]: muscle bulk, tone, strength, and stretch reflexes. These assist in localizing the lesion responsible for the weakness.

Bulk: To ascertain muscle bulk, careful inspection of the muscles bilaterally is required. Decreased muscle bulk (atrophy) is seen in denervation disorders involving the peripheral nerves. Fasciculations (rapid twitching of the muscle) can also be noticed in the atrophic muscle. Non-neurological disorders can also result in atrophy such as disuse, and patient history can help in this regard.

Tone: Passive movement of the muscles can elucidate the tone, which is basically a resistance in the movements. Tone can either be normal or increased or decreased. A slight resistance is observed in normotonic muscle. Hypertonicity mostly commonly presents in the form of rigidity or spasticity. Rigidity is constant increase in tone over the entire range of motion, also described as “lead pipe.” Spasticity on the other hand is variable increase in the tone and is dependent on velocity, also known as “clasp-knife” form. Rigidity is classically associated with a basal ganglia disorder, whereas spasticity is commonly observed in diseases involving corticospinal tracts. Hypotonicity (decreased muscle tone) is seen in lower motor neuron disorders.

Assessment of muscle strength: Strength (power) of the muscle can be graded per the British Research Council system (Table 12.3) [7].

Stretch reflexes: Stretch reflexes are muscle contraction occurring when the tendon is percussed over a stretched muscle. They can either be normal, decreased (lower motor neuronal disorders), or increased (upper motor neuronal disorders). They are graded on the basis on intensity of contraction: 4, clonus (very brisk); 3, brisk but normal; 2, normal; 1, minimal; and 0, absent.

Table 12.3 Grading scale for muscle strength

Grade	Description
Grade 5	Normal strength
Grade 4	Reduced strength but can still move joints against resistance
Grade 3	Movements against gravity but not against resistance
Grade 2	Movements only with the elimination of gravity
Grade 1	Only fasciculations are noticed, and no movement is observed
Grade 0	No muscle contractions

Table 12.4 Acute life-threatening causes of “weakness”

Myasthenia gravis
Guillain-Barré
Botulism
Adrenal insufficiency/hypermagnesemia
Organophosphate poisoning
Carbon monoxide poisoning
Hypokalemia
Hypoglycemia
Cerebrovascular accident
Seizure
Spinal cord compression
Encephalopathy
Sepsis

From: Ganti and Rastogi [42]

ED Management

The first priority with any patient presenting to the ED for any complaint always includes the ABCs of airway, breathing, and circulation. In this immediate assessment, a quick mental checklist of life-threatening causes of “weakness” (not necessarily true neuromuscular weakness) is helpful (Table 12.4) to decide which further investigations might be warranted. In general, obtaining a CBC, chemistry, and urinalysis covers a broad scope. If there is any respiratory compromise, an ABG and an inspiratory pressure (or negative inspiratory force—NIF) should be obtained as well. CPK is useful when considering rhabdomyolysis. Blood cultures and lactate are obtained when sepsis is in the differential. For most cases of acute generalized weakness, brain imaging will be of low yield, unless an acute stroke is still in the differential (see Chap. 2 for diagnosis and treatment of acute stroke). A lumbar puncture is helpful for diagnosing encephalitis. Once initial stabilization is complete, focusing on a detailed history and physical examination can provide clues as to which specific disease entity may be present (Table 12.5).

Table 12.5 Features of various diseases that cause generalized weakness

	Symptom onset	Pattern of paralysis	Deep tendon reflexes	Sensory exam	CSF
Guillain-Barré syndrome	5–7 days after viral illness	Ascending, symmetric	Absent or diminished	Abnormal	High protein
Botulism	12–36 h after ingestion of preformed toxin	Descending, symmetric	Normal	Normal	Normal
Organophosphate toxicity	24–96 h after exposure (intermediate syndrome)	Proximal muscle weakness, neck flexion weakness	Diminished	Normal	Normal
Diphtheria	Few days after high fever and oral lesions	Ascending, symmetric Cranial nerves affected first	Absent or diminished	Normal	Normal
Tick paralysis	3–7 days after tick attaches	Ascending, symmetric	Absent	Normal	Normal
Acute intermittent porphyria	Hours to days	Descending, symmetric Proximal upper extremities to lower extremities	Absent or diminished	Pain in extremities, patchy numbness, paresthesias, and dysesthesias	Normal
Myasthenia gravis	Few days	Ocular muscle, bulbar weakness, fatigable weakness, normal pupil function	Normal	Normal	Normal
Eaton-Lambert syndrome	Insidious	Progressive proximal lower limb weakness, autonomic symptoms, strength gets better with brief exercise	Absent or diminished	Normal	Normal
Transverse myelitis	Symptoms develop over hours	Flaccid paralysis below lesion level	Brisk	Sensory level below lesion level (increased or decreased, +/- paresthesias)	Pleocytosis, elevated IgG
Polio	2–3 days after high fever, headache, and myalgia	Asymmetric proximal	Absent or diminished	Normal	Pleocytosis, mildly elevated protein, normal glucose
Hypokalemic periodic paralysis	Hours to days	Fixed proximal weakness	Diminished during episode	Normal	Normal

From: Ganti and Rastogi [42]

Guillain-Barré Syndrome [GBS]

Although GBS is an uncommon presentation in the ED, it is the most common cause of acute paralysis [8]. Also known as acute inflammatory demyelinating polyneuropathy (AIDP), Guillain-Barré syndrome is an immune-mediated neuropathy that typically starts after a respiratory or gastrointestinal infection. *Campylobacter jejuni* gastroenteritis has been most commonly associated with GBS. It typically presents as numbness in the distal extremities followed by *progressive ascending weakness*. The weakness progresses symmetrically from the distal extremities proximally. Pain can be present in the disease, most often in the back and extremities, and can overshadow the weakness. *Areflexia* is typical. The weakness can progress to involve the respiratory muscles in 10–30%, at which point the patient requires respiratory support in the form of early intubation and mechanical ventilation. Indications for intubation include forced vital capacity <20 mL/kg, maximum inspiratory pressure <30 cmH₂O, and maximum expiratory pressure <40 cmH₂O [9, 10]. “Softer” indicators, but perhaps more useful in the emergency department, are the inability of the patient to lift his head or shoulders or to cough and fewer days between onset of symptom and presentation to the ED. Succinylcholine should be avoided for paralysis during intubation due to significant risk of hyperkalemia, which is a result of upregulation of muscle acetylcholine receptors [11].

Seventy percent have autonomic dysfunction, which manifests as tachycardia, urinary retention, hypertension alternating with hypotension, ileus, and loss of sweating. The Miller Fisher variant of GBS is characterized by ophthalmoplegia with ataxia and areflexia and comprises about 5% of GBS cases.

Cerebrospinal fluid analysis reveals albuminocytologic dissociation, which is an increase in protein levels without associated pleocytosis, but the elevated protein may be absent in the first week of the disease.

Plasmapheresis and intravenous immunoglobulins (IVIG) are used to treat GBS and are more efficacious when given during first 1–2 weeks [12]. A Cochrane review of 649 patients noted more improvement with plasma exchange than with supportive care alone [13]. IVIG started within 2 weeks hastens recovery as much as plasma exchange. However, IVIG are more likely to be completed by the patient [14]. Side effects of IVIG include hypertension, headache, nausea, fever, chills, and renal failure. Side effects of plasmapheresis include hypotension, bleeding, and allergic reaction. There is no role for corticosteroids in the treatment of GBS [15]. Prompt treatment is associated with a good long-term prognosis, with 85% recovering fully [16].

Myasthenia Gravis

Myasthenia gravis (MG), although rare, is the most common disease of the NMJ. It most commonly is a T-cell-mediated disease in which autoantibodies are generated against the postsynaptic acetylcholine receptors. After binding to these receptors, they prevent the binding of the neurotransmitter (acetylcholine). This prevents the

transmission of action potentials from nerve to muscle ultimately resulting in weakness. Although this is a chronic process which involves the blockade, downregulation, and complement-mediated destruction of the postsynaptic receptor, it can also appear as an acute entity in the form of acute myasthenic crisis or cholinergic crisis, which is described below. MG affects approximately 59,000 people in the United States (2003 estimate, [17]) with a predisposition toward women and people aged 20–30 and 60–70 years. Acute myasthenic crisis occurs in approximately 3% of MG patients and can be a presenting symptom in 13–20% of patients.

The most common initial presenting symptoms are ptosis and diplopia [18]. The “curtain sign” reflects fatigable ptosis with sustained gaze. Dysarthria, dysphagia, fatigue, and generalized weakness (proximal > distal) can also be seen. Symptoms are less severe in the morning with severity increasing as the day progresses and are worsened by exertion. Typical clinical features of MG include ptosis and diplopia in about half of all MG patients and bulbar symptoms of dysarthria, dysphagia, and fatigable chewing in 15%. Ocular dysfunction in MG is variable over the course of the day and ranges from internuclear ophthalmoplegia to vertical gaze paresis. One hallmark is that **pupillary function is always spared** in MG.

Laboratory diagnosis of MG includes serum assays for the acetylcholine receptor antibody. Eighty percent of general MG patients have anticholinesterase receptor IgG, while 30–50% of those with the ocular variant of MG do. Another 30–40% have the anti-Msk antibody, while 5% have no identifiable antibody [19]. One or more of these antibodies are elevated in the majority of patients with MG and rarely elevated in other disorders.

The mainstay of treatment for MG is a cholinesterase inhibitor such as pyridostigmine or neostigmine. These drugs inhibit the breakdown of acetylcholine, allowing it to act longer at the NMJ. Side effects include nausea, vomiting, abdominal cramps, diarrhea, and fasciculations. Thymic dysplasia is present in 65% of MG patients, and 10% have thymoma; thus, thymectomy is recommended for patients with MG.

Patients with MG can present with acute weakness either because they have too much medication (resulting in a cholinergic crisis) or because of an exacerbation of their myasthenia, usually secondary to an acute illness or stress (myasthenic crisis) which results in not enough anticholinesterase inhibitor. It is not always possible to distinguish the two types of crises based on physical examination. The edrophonium (Tensilon) test can be used to differentiate the two; a patient with a myasthenic crisis will improve, while the patient with a cholinergic crisis will worsen. Both problems can coexist. However, this puts patients with cholinergic crisis at risk for airway compromise; further, there are several false positives seen with the edrophonium test, resulting in further danger for patients with cholinergic crisis. The preferred approach to MG in crisis from either cause is to admit to a monitored setting (ICU), provide respiratory support in the form of BiPAP (preferred, in contrast to GBS) or intubation (if BiPAP not adequate), take away all cholinergic medications, and slowly add pyridostigmine (0.5 mg/kg q3h) while carefully monitoring the patient [20]. Although BiPAP is the preferred mode of ventilation for respiratory failure in myasthenia gravis, if one does proceed to endotracheal intubation,

Table 12.6 Features of Eaton-Lambert syndrome (ELS) vs. myasthenia gravis (MG)

	ELS	MG
Pattern of weakness	Proximal limbs	Eyes Bulbar muscles
Reflexes		Limbs and trunk
Involvement of peripheral nervous system and autonomic nervous system	Paresthesias Dry mouth Impotence	None
Effect of exercise	Improves muscle weakness	Worsens muscle weakness
EMG	Amplitude increases with exercise (stimulation facilitates muscle action potential)	Amplitude decreases with exercise
M:F ratio	5:1	2:3

it should be noted that succinylcholine will be relatively ineffective to achieve muscle relaxation. Either a higher dose (approximately 2.5 times standard dose) of succinylcholine or a half dose of a nondepolarizing agent (e.g., rocuronium 0.5–0.6 mg/kg) should be used. Plasma exchange, intravenous immunoglobulins, and corticosteroids can be helpful in managing crises [21]. First-line treatment for long-term immunosuppression is with azathioprine. Alternative immunosuppressive drugs for MG include cyclosporine, cyclophosphamide, methotrexate, mycophenolate mofetil, and tacrolimus and rituximab [19].

Eaton-Lambert Syndrome

Eaton-Lambert syndrome (ELS) is a myasthenic syndrome characterized by defective acetylcholine release at the presynaptic nerve terminal resulting in proximal muscle weakness. The hallmark of the disease that distinguishes it from MG is that repetitive muscle effort actually *improves* the weakness. Table 12.6 summarizes the features of ELS vs. MG. As a paraneoplastic syndrome, the mainstay of ELS treatment is treatment of the underlying malignancy if applicable, followed by treatments similar to MG including steroids, immunosuppressives, plasma exchange, and IVIG.

Botulism

Botulism results from ingestion of preformed toxin or infection with botulinum spores which elaborate botulinum toxin by the bacteria *Clostridium botulinum*. It is a rare disease in adults, with most outbreaks related to ingesting contaminated foods (foodborne botulism). Less common modes of contracting it include via open wounds and, more recently, from direct inoculation for cosmetic purposes [22]. It presents with acute onset of bilateral cranial neuropathies approximately 12–36 h after ingesting the toxin and presents with **symmetric descending weakness**.

Patients are afebrile and have intact mental status. Reflexes are normal and there are generally no sensory deficits. Cranial nerve involvement is manifested by blurred vision, diplopia, nystagmus, ptosis, dysphagia, dysarthria, and facial weakness. **Pupils are often involved in botulism, distinguishing it from MG.** Smooth muscle paralysis results in urinary retention and constipation. Paralysis of the diaphragm results in respiratory compromise which requires mechanical ventilation [23]. The disease spectrum can range from mild cranial nerve palsies to rapid death. Treatment of foodborne and wound botulism consists of antitoxin therapy with equine serum heptavalent botulism antitoxin [24] in an attempt to prevent neurologic progression of a moderate, slowly progressive illness or to shorten the duration of ventilatory failure in those with a severe, rapidly progressive illness and hospital admission to monitor respiratory status and begin prompt mechanical ventilation when needed [25]. The antitoxin is stockpiled regionally by the CDC and can be accessed by notification on one's local health department. Antibiotics and wound debridement are additional measures for wound botulism.

Infant botulism is a distinct illness associated with the ingestion of *Clostridium botulinum* spores (vs. direct ingestion of the toxin as seen in adult foodborne botulism) and is actually the most common form of botulism. As the name implies, it is seen in infants and is most commonly attributed to the ingestion of honey, which is why the American Academy of Pediatrics recommends no honey for children under the age of 12 months [26]. Clinical manifestations of infant botulism mirror those of adult foodborne botulism with signs such as inability to suck and swallow, weakened voice, ptosis, and floppy neck and that may progress to generalized flaccidity and respiratory compromise [27]. Infant botulism is treated with intravenous botulism immunoglobulin [26].

Familial Periodic Paralyzes

The familial periodic paralyzes are a group of hereditary diseases associated with abnormal ion channels [28]. This condition can be particularly difficult to diagnose because examination in between attacks may be completely normal until late the condition. The hallmark is a description of weakness that comes on randomly (not associated with any particular time of day or activity). Symptoms typically start before 20 years of age and can be triggered by certain foods (carbohydrates or potassium-rich foods) or rest after exercise.

Patients often show abnormal serum potassium (either hyper- or hypokalemia) during the episode of weakness. Hypokalemic periodic paralysis is the most common type and is a calcium channelopathy. Symptoms often follow exercise or a heavy carbohydrate meal. Acute treatment is supportive. Total body potassium is normal. Hyperkalemic periodic paralysis, which is much less common, is a sodium channelopathy, and the acute treatment consists of carbohydrate meal/glucose. Electrodiagnostic testing shows a characteristic drop in compound muscle action potentials with exercise [29].

Poliomyelitis

Poliovirus is an enterovirus that is transmitted by fecal-hand-oral transmission and can result in acute flaccid paralysis. While poliovirus has been eradicated in much of the world, it remains endemic in sub-Saharan Africa and parts of Asia. It infects the anterior horn cells and can ultimately cause the death of these motor neurons and paralyze the muscle fibers supplied by them. Only a minority of infections (<5%) experience paralytic poliomyelitis [30]. The infection commences with a flu-like illness that leads to meningismus characterized by high fever, headache, and myalgia. Thereafter, **asymmetric** muscle spasms and muscle weakness set in which gradually worsen over 2–3 days. Proximal muscle weakness is more common than distal muscle weakness with predominant involvement of the legs. Bulbar involvement can also be noted in a subgroup of these patients, more commonly in adults, with symptoms such as dysarthria and dysphagia.

Polymerase chain reaction (PCR) amplification of poliovirus is the most sensitive method for diagnosis. Poliovirus is most likely to be isolated from stool specimens. It may also be isolated from pharyngeal swabs. Isolation is less likely from blood or CSF [31]. Treatment recommendations for an acute attack are supportive, with a focus on pain relief and physiotherapy. Strict bed rest is required to prevent paralysis extension. Physical therapy assists in prevention of the development of contractures and joint ankylosis. In some patients, respiratory failure can also ensue necessitating intubation and mechanical ventilation. Approximately 25% of polio survivors develop post-polio syndrome, characterized by progressive muscle weakness [32], typically in previously affected muscles.

Organophosphate and Carbamate Poisoning

Organophosphates (OP) and carbamates are found in many pesticides and household products. These compounds cause weakness by binding to acetylcholinesterase and rendering it inactive, which leads to an excess of acetylcholine at the NMJ. Organophosphates bind the receptor irreversibly, whereas carbamates bind it transiently. Symptoms of OP poisoning include muscarinic effects and nicotinic effects. The muscarinic effects are what one classically thinks of as the cholinergic toxidrome: salivation, lacrimation, urination, defecation, emesis, bronchorrhea, and miosis. The nicotinic manifestations are muscle weakness, fasciculations, and paralysis. In up to 20% of patients with OP poisoning, a new neuromuscular weakness sets in approximately 24–96 h after initial exposure, and this phenomenon has been termed the intermediate syndrome [33]. It consists of proximal limb weakness and weakness of the respiratory muscles. The resulting respiratory distress needs to be aggressively managed, and when this is done, most patients recover fully without sequelae.

Treatment of OP poisoning includes atropine (which only reverses the muscarinic effects) plus an oxime such as pyridoxine (which reverses both nicotinic and muscarinic effects) [34]. They should be given together. The endpoint to atropine

treatment is resolution of respiratory secretions and cessation of bronchoconstriction. Very large quantities of atropine, in the order of hundreds of milligrams, are required. Pralidoxime is administered slowly at a dose of 30 mg/kg. If intubation is required, succinylcholine should be avoided since OPs inhibit acetyl cholinesterase, the enzyme that metabolizes succinylcholine. Nondepolarizing neuromuscular blocking agents will work, but larger doses are required. CNS effects include seizures, and these should be treated with benzodiazepines, rather than phenytoin, which have not been shown to be effective [35].

Transverse Myelitis

Transverse myelitis is a monophasic immune-mediated condition restricted to the spinal cord. In children, up to 60% cases occur as an autoimmune phenomenon following an infection or vaccination. This association is less common in adults. Up to one third of cases are idiopathic [36]. Multiple sclerosis is another relatively common cause; Lyme disease and schistosomiasis are two infectious causes. Symptoms depend on the spinal cord level involved and can include motor symptoms such as paraparesis or quadriparesis, autonomic dysfunction such as bowel and bladder dysfunction, and a sensory level below the lesion. The symptoms are **bilateral**, and typically **symmetric**, but can occasionally be asymmetric. Leg flexors and arm extensors are more commonly affected. Symptoms evolve over hours to days, with an average of 4–21 days, with the nadir at 2 weeks. **Progression to nadir within 4 h excludes the diagnosis** of transverse myelitis. In the acute phase, muscle flaccidity is observed; this converts into spasticity later in the disease course [37]. Pain is a common symptom both during and after an attack of transverse myelitis and can be neuropathic or musculoskeletal in nature.

Diagnostic adjuncts include MRI, which demonstrates spinal cord inflammation, and lumbar puncture, which again demonstrates inflammation with pleocytosis and IgG. Treatment consists of high-dose corticosteroids (e.g., methylprednisolone 1000 mg IV daily for 3–5 days). Plasma exchange can be used for refractory cases. DVT prophylaxis should be administered for patients who are immobile. In the occasional case caused by Lyme disease, anti-borrelial antibiotics would be prescribed. Prognosis depends on the underlying etiology, timely diagnosis, and appropriate treatment; overall, the prognosis is fair. Spinal shock, back pain, and rapid symptoms progression can result in dismal prognosis. Approximately 50–70% of patients have partial or full recovery [38].

Tick Paralysis

Tick paralysis is an uncommon disorder that is caused by the neurotoxins present in the saliva of gravid female ticks. There are 40 species known to produce these toxins; of them, *Dermacentor andersoni* (the Rocky Mountain wood tick) and *D. variabilis* (the American dog tick) are the most common causative agents in North America. The symptoms begin with paresthesias and gradually progress to unsteady

gait and ultimately asymmetric ascending flaccid paralysis. The toxins are transmitted when ticks feed on human blood, and symptoms progress as long as the ticks feed. Treatment consists of tick removal, which requires meticulous search for the tick on physical examination. Tick removal results in rapid improvement and is associated with an excellent prognosis [39].

Amyotrophic Lateral Sclerosis (ALS)

ALS also known as Lou Gehrig's disease is the most common form of degenerative motor neuron disease. It has an incidence of 2–3 cases per 100,000 individuals in the general population and is idiopathic in most instances. It affects both upper and lower motor neurons. There is progressive decrease in bulbar and limb function with symptoms onset more commonly seen in the limbs and later progressing to the bulbar segment. Sensory symptoms including pain may be seen in only 20% of the patients. Cognitive dysfunction is frequently seen in ALS patients; frontotemporal dementia develops with disease progression. Muscle weakness, spasticity, and fasciculations are noted on the physical examination, as well as muscle atrophy.

Differential diagnosis for ALS includes MG and neurodegenerative disorders such as Parkinson's disease, Huntington disease, and progressive muscular atrophy. There is no definitive diagnostic test for ALS; negative labs and imaging studies help in ruling out the differentials. Elaborate history and physical examination are key to the diagnosis. Electrodiagnostic tests such as electromyography can help in identification of the loss in lower motor neurons. There is no effective treatment for ALS; riluzole is the only FDA-approved disease-modifying drug that can provide symptomatic relief in ALS patients [40]. Respiratory failure is seen in approximately 60% of patients within 3 years of symptom onset and is the most common cause of death in ALS patients. Mechanical ventilation is necessary in patients that develop respiratory failure. Physical therapy and rehabilitation along with gastrostomy improve the quality of life of patients. Although the overall prognosis is poor, site of initial symptom onset; for example, the limbs tend to have a better prognosis [41].

Pearls and Pitfalls

- Asking the patient what they can no longer do or do without difficulty is a good start to localizing the problem.
- Generally, proximal muscle weakness suggests a myopathic process, while distal muscle weakness indicates a (poly)neuropathy.
- Many drugs can cause myopathy; anti-dyslipidemia drugs are a common culprit.
- Pupillary function is typically *spared* in myasthenia gravis, but *compromised* in botulism.
- In contrast to GBS, the best respiratory support strategy in MG is bi-level positive airway pressure (BiPAP).
- The weakness of botulism is symmetric and *descending*, whereas it is symmetric and *ascending* in GBS.

References

1. Nickel CH, Nemeč M, Bingisser R. Weakness as presenting symptom in the emergency department. *Swiss Med Wkly*. 2009;139:271–2.
2. Saguil A. Evaluation of the patient with muscle weakness. *Am Fam Physician*. 2005;171(7):1327–36.
3. Valiyil R, Christopher-Stine L. Drug-related myopathies of which the clinician should be aware. *Curr Rheumatol Rep*. 2010;12(3):213–20. doi:10.1007/s11926-010-0104-3.
4. Bannwarth B. Drug-induced myopathies. *Expert Opin Drug Saf*. 2002;1(1):65–70.
5. Mancall EL. Overview of the organization of the nervous system. In: Mancall EL, Brock, D. G., & Gray, H., ed. *GRAY'S clinical neuroanatomy the anatomic basis for clinical neuroscience*. 7 ed. Philadelphia: Elsevier Health Sciences; 2011:3–10.
6. Greenberg DA, Aminoff MJ, Simon RP. Neurologic history & examination. In: Greenberg DA AM, Simon RP, editors. *Clinical neurology*. 8th ed. New York: McGraw-Hill; 2012.
7. Medical Research Council. *Aids to the investigation of peripheral nerves*. London: Crown Publishing; 1976.
8. McGillicuddy DC, Walker O, Shapiro NI, Edlow JA. Guillain-Barré syndrome in the emergency department. *Ann Emerg Med*. 2006;47(4):390–3.
9. Sharshar T, Chevret S, Bourdain F, et al. Early predictors of mechanical ventilation in Guillain-Barré syndrome. *Crit Care Med*. 2003;31:278.
10. Walgaard C, Lingsma HF, Ruts L, et al. Prediction of respiratory insufficiency in Guillain-Barré syndrome. *Ann Neurol*. 2010;67:781.
11. Gronert GA. Cardiac arrest after succinylcholine: mortality greater with rhabdomyolysis than receptor upregulation. *Anesthesiology*. 2001;94(3):523–9.
12. So YT. Immune-mediated neuropathies. *Continuum (Minneapolis)*. 2012;18(1):85–105.
13. Raphael JC, Chevret S, Hughes RAC, Annane D. Plasma exchange for Guillain Barre syndrome. *Cochrane Database Syst Rev*. 2012;(7):CD001798. doi:10.1002/14651858.CD001798.
14. Hughes RAC, Swan AV, van Doorn PA. Intravenous immunoglobulin for Guillain Barre syndrome. *Cochrane Database Syst Rev*. 2014;(9):CD002063. doi:10.1002/14651858.CD002063.
15. Hughes RAC, van Doorn PA. Corticosteroids for Guillain Barre syndrome. *Cochrane Database Syst Rev*. 2012;(8):CD001446. doi:10.1002/14651858.CD001446.
16. van Doorn PA. Diagnosis, treatment and prognosis of Guillain-Barré syndrome (GBS). *Presse Med*. 2013;42(6 Pt 2):e193–201. doi:10.1016/j.lpm.2013.02.328; Epub 2013 Apr 28.
17. Phillips LH 2nd. The epidemiology of myasthenia gravis. *Ann NY Acad Sci*. 2003;998:407–12.
18. Sanders DB, Guptill JT. Myasthenia gravis and Lambert-Eaton myasthenic syndrome. *Continuum (Minneapolis)*. 2014;20(5):1413–25.
19. Sieb JP. Myasthenia gravis: an update for the clinician. *Clin Exp Immunol*. 2014;175(3):408–18. doi:10.1111/cei.12217.
20. Rabinstein AA. Acute neuromuscular respiratory failure. *Continuum (Minneapolis)*. 2015;21(5):1324–45. doi:10.1212/CON.0000000000000218.
21. Berrouscho J, Baumann I, Kalischewski P, Sterker M, Schneider D. Therapy of myasthenic crisis. *Crit Care Med*. 1997;25(7):1228–35.
22. Ghasemi M, Norouzi R, Salari M, Asadi B. Iatrogenic botulism after the therapeutic use of botulinum toxin-A: a case report and review of the literature. *Clin Neuropharmacol*. 2012;35(5):254–7.
23. Koussoulakos S. Botulinum neurotoxin: the ugly duckling. *Eur Neurol*. 2009;61:331–42. doi:10.1159/000210545.
24. Centers for Disease Control and Prevention (CDC). Investigational heptavalent botulinum antitoxin (HBAT) to replace licensed botulinum antitoxin AB and investigational botulinum antitoxin E. *Morb Mortal Wkly Rep*. 2010;59(10):299.
25. Centers for Disease Control and Prevention: Botulism in the United States, 1899–1996. Handbook for epidemiologists, clinicians, and laboratory workers. Atlanta, GA: Centers for Disease Control and Prevention; 1998.

26. American Academy of Pediatrics. Botulism and infant botulism (*Clostridium botulinum*). In: Kimberlin DW, Brady MT, Jackson MA, Long SS, editors. Red book: 2015 report of the committee on infectious diseases. 30th ed. Elk Grove Village, IL: American Academy of Pediatrics; 2015. p. 294.
27. Sobel J. Botulism. *Clin Infect Dis*. 2005;41(8):1167–73; Epub 2005 Aug 29.
28. Venance SL, Cannon SC, Fialho D, et al. The primary periodic paralyses: diagnosis, pathogenesis, and treatment. *Brain*. 2006;129:8.
29. Statland JM, Barohn RJ. Muscle channelopathies: the nondystrophic myotonias and periodic paralyses. *Continuum (Minneapolis, Minn)*. 2013;19(6):1598–614. doi:10.1212/01.CON.0000440661.49298.c8.
30. Flower O, Wainwright MS, Caulfield AF. Emergency neurological life support: acute non-traumatic weakness. *Neurocrit Care*. 2015;23:S23–47.
31. <http://www.cdc.gov/polio/us/lab-testing/diagnostic.html>. Accessed 29 Dec 2015.
32. Howard RS. Poliomyelitis and the postpolio syndrome. *BMJ*. 2005;330(7503):1314–8.
33. Karalliedde L, Baker D, Marrs TC. Organophosphate-induced intermediate syndrome: etiology and relationships with myopathy. *Toxicol Rev*. 2006;25(1):1–14.
34. <http://www.uptodate.com/contents/organophosphate-and-carbamate-poisoning>. Accessed 29 Dec 2015.
35. World Health Organization. Organophosphorus pesticides: a general introduction. Environmental Health Criteria No 63. World Health Organization, Geneva; 1986. <http://www.inchem.org/documents/ehc/ehc/ehc63.htm#SubSectionNumber:7.4.3>. Accessed 29 Dec 2015.
36. de Seze J, Lanctin C, Lebrun C, et al. Idiopathic acute transverse myelitis: application of the recent diagnostic criteria. *Neurology*. 2005;65:1950–3.
37. West TW. Transverse myelitis—a review of the presentation, diagnosis, and initial management. *Discov Med*. 2013;16(88):167–77.
38. Frohman EM, Wingerchuk DM. Transverse myelitis. *N Engl J Med*. 2010;363:564–72.
39. Pecina CA. Tick paralysis. *Semin Neurol*. 2012;32(5):531–2.
40. Salameh JS, Brown RH Jr, Berry JD. Amyotrophic lateral sclerosis: review. *Semin Neurol*. 2015;35(4):469–76. doi:10.1055/s-0035-1558984; Epub 2015 Oct 6.
41. Hardiman O, van den Berg LH, Kiernan MC. Clinical diagnosis and management of amyotrophic lateral sclerosis. *Nat Rev Neurol*. 2011;7(11):639–49.
42. Ganti L, Rastogi V. Acute generalized weakness. *Emerg Med Clin North Am*. 2016;34(4):795–809. doi:10.1016/j.emc.2016.06.006.

Ogonna Felton and Charles R. Wira III

Case Presentation

An 80-year-old man presents to the ED via ambulance from a local nursing home with confused speech (episodic/waxing and waning), fever, and chills for 1 day. Per nursing home report, he had been feeling unwell for the last 2 days. Paperwork reveals he has had a nonproductive cough and sore throat, and several other residents at the facility had been ill with similar symptoms. He reports a frontal headache which is more painful than his associated myalgias and was given Tylenol. There is no report of a fall or trauma. His baseline mental status is alert and oriented with the ability to converse and perform many activities of daily living. He is unable to manage his finances and medications. His baseline heart rate is 70–90s; his blood pressure range is in the 120–130s/60–90s. He has lived at the nursing home for the past year since diagnosed with mild cognitive impairment. He previously lived alone and his wife died 2 years ago. There is no family in the region. On arrival to the ED, his initial vital signs are T 103 F, BP 94/49, R 24, HR 108, and O2 sats 94% on room air with a GCS 13.

PMHx: COPD with no baseline supplemental O2 requirement, hypertension, and hyperlipidemia

PSHx: bilateral knee replacement years ago

Allergies: NKDA

Current medications: lisinopril 10 mg QD, atorvastatin 40 mg QD, Spiriva 18 mcg 2 puffs QD, and aspirin 81 mg QD

O. Felton, M.D. • C.R. Wira III, M.D. (✉)
Department of Emergency Medicine, Yale School of Medicine,
464 Congress Avenue STE 260, New Haven, CT 06519, USA
e-mail: Ogonna.umeh@yale.edu; charles.wira@yale.edu

Physical Exam

Constitutional: Caucasian elderly man; medium build, who appears his age; and is in no acute distress but is mildly restless

HEENT: erythema to the right TM, left TM normal, PERRL, no evidence of papilledema, non-tender sinuses, no conjunctival injection, and no scleral icterus

Neck: no JVD

Cardiac: tachycardic to 108, normal S1 and S2, and no appreciable murmurs or rubs

Lungs: bibasilar rales

Abdomen: soft and non-tender

Extremities: warm and well perfused

Neurological exam: awake and alert to self and place only, CN II-XII grossly intact, equal 5/5 strength to upper and lower extremities, no sensory deficits, no dysarthria, no abnormal coordination, unable to perform three-step command, can occasionally name some simple objects, and negative Brudzinski and Kernig

Skin: feels warm to touch, no rash, and no pallor

Differential Diagnosis

When presented with altered mental status in the ED, a common mnemonic used is AEIOUTIPS, which stands for:

Alcohol/**a**cidosis/**a**lkalosis

Epilepsy/**e**ndocrine/**e**ncephalopathy/**e**lectrolytes

Insulin

Overdose/**o**piates/**o**xxygen

Uremia

Trauma

Infection/**i**schemia/**i**mpaired ventilation

Psychosis/**p**oisoning

Stroke/**s**yncope/**s**pace-occupying lesion

It provides a fast and simple approach to consider a wide range of conditions. Some of the neurologic infections to be discussed and the associated pathogens are listed below:

Bacterial meningitis

- *Streptococcus pneumoniae*
- *Neisseria meningitidis*
- *Haemophilus influenzae*
- *Listeria monocytogenes*
- *Staphylococcus aureus*

Viral and aseptic meningitis

- Viral meningitis
 - Echovirus
 - Coxsackie virus

- Arboviruses, including West Nile virus
- Influenzae/parainfluenzae
- Mollaret’s meningitis (HSV reactivation with giant monocytes)
- Tuberculosis meningitis
- HIV
- Polio virus
- Mumps virus
- Other etiologies
 - Drug-induced (TMP/SMX, IVIG, NSAIDs, AED) meningitis
 - Fungal meningitis
 - Cryptococcus
 - Coccidioidomycosis
 - Tick borne diseases
 - Borrelia burgdorferi* (causative agent of Lyme meningitis)
 - Rocky Mountain spotted fever
 - Ehrlichiosis

Viral encephalitis

- Herpes simplex virus (HSV) and West Nile virus

CNS amoeba infections

Rabies encephalitis

Prion disease

Neurosyphilis

Malaria

Some infections can cause CNS injury from secondary postinfectious immune-mediated mechanisms, including:

Transverse myelitis

- From an acute or postinfectious process

Guillain-Barre syndrome variants

- Bickerstaff brainstem encephalitis from initial bacterial (i.e., campylobacter) or viral infections (i.e., Epstein-Barr virus)

An important consideration in establishing the initial differential diagnosis is to localize the level of the neurological lesion (see “Physical Exam” section differentiating upper and lower motor neuron signs), specifically at the level of the:

1. Brain: cerebral hemispheres, cerebellum, and brainstem
2. Spinal cord
3. Peripheral nervous system

With a wide range of differentials to consider, the history and physical exam are integral in deciding which diagnostic and therapeutic path to follow. The nature of the ED and cryptic presentation of some of these conditions may limit the ability for an exhaustive initial workup. The emergency physician has to be astute in recognizing signs of acute life-threatening conditions. They can begin the diagnostic workup

process by obtaining appropriate initial labs, neuroimaging if indicated, performing an LP if indicated, and providing early initial appropriate antibiotic coverage which can then be continued in the inpatient setting.

The case presentation illustrates a common encounter in the ED. The patient has a fever, a change from baseline mental status, and a borderline low blood pressure. This triad of signs in the history should alert the clinician toward an infectious etiology.

History

Key points to note in the history-taking process:

First time onset of symptoms: typically CNS infections are not recurrent, with the exception of some rare examples (i.e., Mollaret's HSV reactivation meningitis).

Slow or rapid onset of symptoms: typically CNS infections have a brief time period of prodromal symptoms (i.e., generalized malaise) or are preceded by another illness (i.e., viral syndrome) with a relatively slow onset of CNS symptoms in comparison to some other CNS conditions (i.e., rapid-onset thunderclap headache from a SAH, sudden change in neurological status from a stroke or seizure).

Neurological review of systems: has the patient had any sustained or transient focal deficits at any point in time, which may point toward an alternative diagnosis.

Signs of potential mass effect from elevated ICP: increased sleepiness, nausea and/or vomiting, blurry vision from papilledema, and focal findings on neurological review of systems (i.e., signs of cranial nerve palsies).

Signs of spinal cord involvement: extremity weakness or sensory changes and bowel or bladder dysfunction.

Exposure history: ask about sick contacts and close personal contacts (i.e., shared living space, sexual partners, and shared food), exposure to viral hosts (rodents, ticks, mosquitoes, bats, and wild animals), history of exposure to tuberculosis, and prior history of HSV.

Immunocompromised status: HIV, organ transplant, diabetes, prolonged corticosteroid use, active malignancy, splenectomy, bone marrow suppression, and alcoholism.

Recent instrumentation: neurosurgical or ENT procedure.

Recent infection: oropharyngeal infection, nasal cavity, sinus infection (i.e., mastoiditis), ear infection, and gastrointestinal illness.

Medication history: i.e., NSAIDs (Motrin, Advil, Aleve), intravenous immunoglobulin (IVIG), trimethoprim/sulfamethoxazole (TMP-SMX), antiepileptic medications, and chemotherapy agents.

Travel history: to endemic areas (i.e., Florida, Africa, South America, Asia, the Caribbean) or areas with known vectors for infectious diseases (arthropod, tick-borne, mosquito-borne diseases); recent incarceration or employment in a prison or military facility.

Vaccination status: *Haemophilus influenzae*, *Streptococcus pneumoniae*, and *Neisseria meningitidis*.

Classically, patients with meningitis will present with the triad of fever greater than 38 °C (100.4 °F), neck stiffness, and altered mental status, but this is not common in clinical practice. The sensitivity for any two or more of these symptoms in patients with meningitis is as high as 95% [2]. An absence of all three can effectively rule out meningitis [2]. In one study, fever alone was found to be 85% sensitive, neck stiffness alone was found to be 70% sensitive, and altered mental status alone was 67% sensitive [2]. All of these symptoms may or may not be present at the same time, but several studies have noted at least three of these symptoms to be present in a large proportion of patients. For example, one study reported 67% of patients had fever, nuchal rigidity, and altered mental status [10], whereas in another study, 44% of patients had the classic triad of altered mental status, fever, and neck stiffness, while 87% of patients in the same cohort had only headache, 83% had only neck stiffness, and 77% had only fever greater than or equal to 38 °C (100.4 °F) [23]. If headache is included with any two of the following features (fever, neck stiffness, headache, and altered mental status), then sensitivity for meningitis approaches 95% [2, 23].

Physical Examination

Vital signs: Vital sign derangements may occur with ongoing bacteremia, global tissue hypoxia, oxygen delivery/consumption mismatches, and dysregulation of the inflammatory cascade. Fever greater than 38 °C (100.4 °F) is seen in >95% of cases of meningitis. However, both normal blood pressure and hypotension can be seen, with the latter being more suggestive of ongoing bacteremia. The respiratory rate can be normal or elevated depending on associated lactic acidosis or secondary pulmonary involvement (i.e., acute lung injury, aspiration). Hypoxia also may occur. The heart rate can be normal or elevated depending on other clinical factors like dehydration, presence of atrial-ventricular (AV) nodal blocking agents, age, and presence or absence of a robust sympathetic nervous system. An elevation of the shock index (HR/SBP, abnormal >0.8) may indicate a more severe host systemic response to the underlying infectious process. Severe vital sign derangements may be indicative of a shock or pre-shock state.

Skin: Most patients with meningitis typically do not present with a rash. In one study, 11% of people were reported to have a rash [10]. Look for any rashes especially in dependent areas of the body. Petechial rashes were seen with a prevalence of 63% [10] and 80% [18] in meningitis caused by *Neisseria meningitidis* and 73% of patients diagnosed with meningococemia. Vesicles could point toward herpes simplex virus infection. Other infections have specific patterns of rashes (i.e., Rocky Mountain spotted fever).

HEENT: Look for abnormal tympanic membrane (otitis media, 25% [3]), mastoiditis, abnormal eyes/retina (photophobia/papilledema), and sinus tenderness (sinusitis [3]). Look at the oropharynx for potential signs suggestive of viral etiology (petechial lesions/pharyngeal erythema).

Neck: Look for nuchal rigidity (resistance to forward flexion of the neck while in a supine position) and lymphadenopathy.

Neuro exam: Differing levels of altered mental status range from confusion to coma depending upon alterations in a patient's cognitive function and level of alertness. Kernig sign (resistance to knee extension when the ipsilateral hip is flexed 90 °) and Brudzinski sign (resultant hip flexion with passive neck flexion while the patient is in the supine position) are not very sensitive for meningitis though they are very specific >95% [2]. One prospective cohort study of 297 adult patients reported 5% sensitivity and 95% specificity of both Brudzinski and Kernig signs for bacterial meningitis [20]. It is thought that the greater the severity of the meningeal irritation, the more likely these signs are to be positive as with pyogenic infections such as *Mycobacterium tuberculosis* meningitis or *Streptococcus pneumoniae* meningitis. The jolt accentuation test was found to be 97% sensitive and 60% specific for CSF pleocytosis in a prospective cohort of 54 patients [22]. The jolt test is done by having the patient rotate his or her head horizontally from side to side at least twice in 1 s. It is considered positive if this head motion exacerbates the headache.

A comprehensive neurological exam may include the following variables:

- General appearance:
 - “What do you see?”
 - Level of consciousness, posture, motor activity, and interaction with environment
- Cognitive function assessment
- Speech alterations:
 - Receptive vs. expressive abnormalities
- Cranial nerve 2–12 evaluation, corresponding brainstem levels (rule of 4 s):
 - Midbrain: CNs 1–4
 - Pons: CNs 5–8
 - Medulla: CNs 9–12
- Further specialized ocular assessment:
 - Focal visual field deficits
 - Diplopia
 - Nystagmus (peripheral vs. central patterns)
 - Test for skew
 - Saccade testing
- Assessment of strength/power
- Assessment of sensory function
- Assessment for cerebellar signs:
 - Finger-to-nose, heel-to-shin, and rapid alternating movements
- Deep tendon reflexes, plantar reflex, and clonus
- Romberg test
- Gait evaluation
- The presence or absence of upper motor neuron signs (CNS vs. PNS):
 - Upper motor neuron signs: hyperreflexia, increased muscle tone/spasticity, and present Babinski sign

- Lower motor neuron signs: hyporeflexia, decreased muscle tone/flaccidity, fasciculations, and absent Babinski sign
- Evaluation of the comatose patient:
 - Glasgow coma scale evaluation
 - Level of alertness/interaction
 - Posturing/tone/localization to noxious stimuli
 - Further cranial nerve testing:
 - Oculocephalic and/or oculo-vestibular reflex
 - Corneal reflex
 - Gag reflex
 - Facial grimacing with pain
 - Asymmetric or lateralized findings (withdrawal, reflexes)

ED Workup

Vital Sign Risk Stratification

In the past the systemic inflammatory response syndrome (SIRS) criteria were utilized in research settings to initially identify and risk stratify infected patients for potential sepsis or formerly called severe sepsis. Current literature, guidelines, and clinician practices utilize more severe derangements of such criteria (i.e., RR >22, HR >110–130) and look at additional available criteria (i.e., transient hypotension, hypoxia, altered mental status from baseline, shock index elevation) [13, 17, 19, 24].

Clinical Investigations

Initial routine labs obtained in the ED include:

- A complete blood count (CBC)
- Basic metabolic panel (BMP)
- Blood cultures
- Coagulation studies
- Arterial blood gas if patient is altered to exclude hypercarbia
- Labs risk-stratifying patients with potential sepsis:
 - Lactate
 - Hepatic panel
 - Coagulation profile
 - Platelet level
- Labs evaluating for other items in differential diagnosis:
 - Urinalysis
 - Ammonia level
 - Toxicology labs/medication levels
 - Troponin level

Labs could show nonspecific leukocytosis, leukopenia, thrombocytopenia, and normal or elevated PTT or diminished fibrinogen that may be point toward disseminated intravascular coagulopathy (DIC). This derangement in coagulation portends a poorer prognosis in meningitis.

Neuroimaging

Neuroimaging is universally recommended if there are focal neurological deficits on exam, transient neurological signs identified in the neuro ROS, and signs/symptoms suggestive of elevated ICP (i.e., drowsiness, nausea/vomiting). Widespread imaging for meningitis is not universally agreed upon. The pursuit for CNS imaging should not delay antibiotics. In one study where patients had focal neurological signs, 62% had a normal head computed tomography (CT), though in that same study, 3% of patients with no focal neurological signs had a brain CT with abnormal findings [20].

Lumbar Puncture

Positioning is an important element of success in obtaining CSF sample. The upright sitting and lateral recumbent positions are two options. The latter allows for a more accurate measure of opening pressure (normal range 10–20 cmH₂O). Forced flexion may falsely elevate opening pressure measurements, and opening pressure may also be altered by body mass index (Table 13.1, Figs. 13.1 and 13.2).

Table 13.1 CSF findings in meningitis (protein counts increase 1 mg/dL for each 1000 RBC in the CSF)

	WBC (cells/ μ L)	Glucose (mg/dL)	Protein (mg/dL)	Culture	Gram stain	Opening pressure (cmH ₂ O)
Normal	0–5	50–75	15–40	No organisms	None	<20
Bacterial	100–5000 (neutrophil predominance)	<40 (↓)	>100 (↑)	Organism-dependent	GPR, GNR, GPC, GND	↑
Viral ^a	10–300 (lymphocyte predominance)	Normal	Normal/↑	No growth	None	Normal/↑
Fungal	10–200	↓	Normal/↑	No growth ^b	None	Normal/↑
Tuberculosis	10–500	↓	↑	No growth ^c	None	Normal/↑

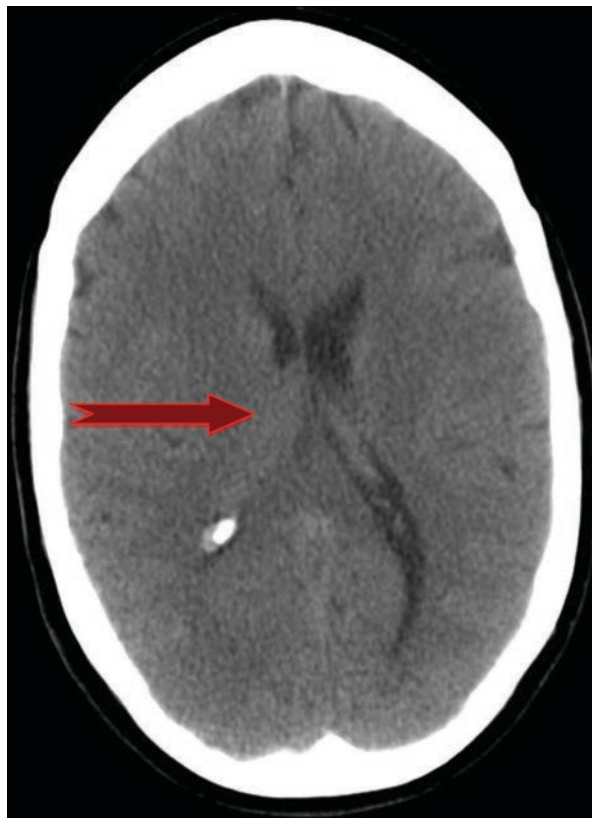
GPC gram-positive cocci in pairs (*Streptococcus pneumoniae*), singles, or chains (*Staphylococcus aureus* or *Staphylococcus epidermidis*); GND gram-negative diplococci (*Neisseria meningitidis*); GNR gram-negative coccobacilli (*Haemophilus influenzae*), gram-negative rods (*Escherichia coli*); GPR gram-positive rods (*Listeria monocytogenes*)

^aHSV can typically cause hemorrhage that is seen on brain MRI or CT.

^bNeeds special stain like India ink and latex agglutination assays for fungal antigen

^cNeeds special growth media for mycobacteria

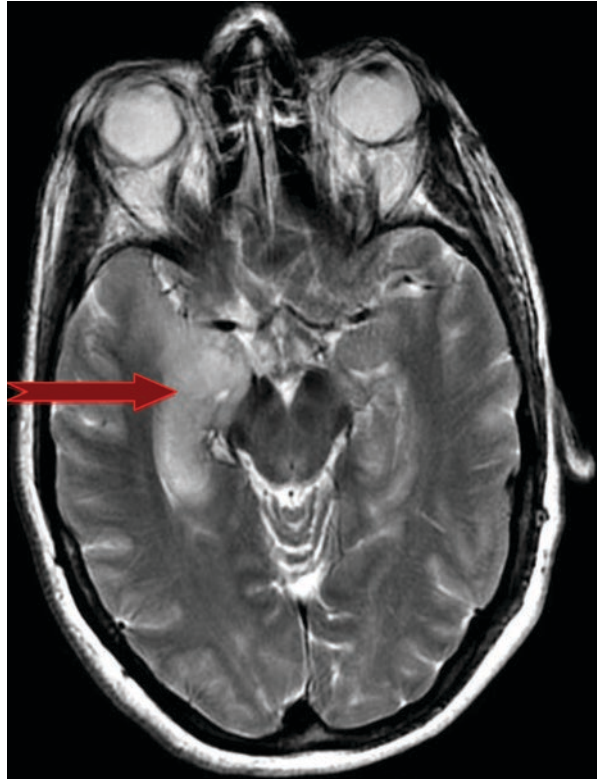Fig. 13.1 Axial computed tomography of the brain showing mild compression of the lateral right ventricle in a patient with herpes encephalitis (*arrow*)



Neurocritical Care Management

1. *Sepsis/septic shock*: It is important to recognize sepsis early on as failure to do so results in significant morbidity and mortality. Risk-stratifying labs may be sent (i.e., lactate) if the patient is perceived to have a significant physiologic response (i.e., altered mental status, tachypnea, hypotension, tachycardia, elevated shock index). Key initial interventions for patients with more severe infections include fluid resuscitation and early broad-spectrum antimicrobial coverage with appropriate antibiotics, +/- antivirals as indicated. If patients progress to shock states, then protocolized resuscitative care may be instituted in accordance with existing critical care guidelines.
2. *Elevated ICP*: Elevated ICP may result from abnormal increases in parenchymal, CSF, or blood volume, as well as lesions producing mass effect. Specifically for CNS infections, causes of elevated ICP may include parenchymal cerebral edema (i.e., encephalitis), decreased CSF absorption (i.e., meningitis), or mass effect (i.e., cerebral abscess). Clinical surveillance or neuroimaging suggestive of elevated ICP requires prompt management to prevent herniation syndromes. Resuscitative techniques may include osmotic diuretics, hyperosmolar therapy,

Fig. 13.2 Axial diffusion-weighted MRI showing a patient with herpes simplex virus encephalitis. *Red arrow* shows an area of enhancement along the right medial temporal lobe



head elevation, mild hyperventilation, and fever prevention. Direct monitoring of ICP may occur via an external ventricular drain (EVD). In extreme cases of intractable ICP elevations refractory to maximal medical treatment and continuous CSF drainage, a decompressive craniectomy may become necessary.

Special Circumstances and Specific CNS Infections

Bacterial Meningitis

Meningitis is an inflammation of the meninges and subarachnoid space of the brain and spinal cord. Symptoms of bacterial meningitis reflect irritation of this space. It is a rapidly progressive infection that is considered a life-threatening medical emergency. The incidence of meningitis has decreased since the early 1980s. The incidence of meningitis is reportedly 3/100,000 per year [21].

Some of the different organisms that cause meningitis are described below:

- *Streptococcus pneumoniae*
 - This is the most common organism associated with community-acquired meningitis (CAM)—24% of cases [10].
 - Gram-positive diplococcus.

- *Neisseria meningitidis* (meningococcus)
 - This is the second most common organism associated with community-acquired meningitis (CAM) [10].
 - Commonly associated with a petechial that can coalesce to a purpuric rash.
 - Gram-negative diplococcus.
- *Haemophilus influenzae*
 - Gram-negative coccobacillus
 - Culprit organism in 4% of cases [10]
- *Listeria monocytogenes*
 - Gram-positive bacillus
 - Culprit organism in 4% of cases [10]
 - Prone to infect extremes of age
- *Staphylococcus aureus*
 - Culprit organism in ~4% of cases [10]
 - Usually seen post-instrumentation
 - Methicillin-resistant strains becoming more common

Treatment

Time to treatment, if bacterial meningitis is suspected, should not be delayed for any reason—including neuroimaging, blood work, or LP, as delays can adversely influence mortality and clinical outcomes. Antibiotics should be initiated within 30 min of presumed bacterial meningitis. Studies have shown delays of more than 2 h to antibiotic administration portend worsening prognosis. One study found 21% absolute risk reduction when antibiotics were administered shortly after 1 h while in the ED versus hours after admission as an inpatient [14]. It is of value to know that it can take several hours to obtain CSF sterility after antibiotics have been initiated. One study found that 73% of CSF cultures obtained 4 h after initiation of antibiotics were found to have positive CSF cultures while 11% of CSF samples obtained several hours after antibiotics were started had negative cultures [15].

Corticosteroids have been suggested as an adjunct to treatment of meningitis, but there is still debate. Steroids have been thought to temper the inflammatory response secondary to bacteria lysis in the CNS. A Cochrane review [5] found benefit in reduction of hearing loss and neurological sequelae in cases of *S. pneumoniae* but not *H. influenzae* or *N. meningitidis*. There was no reduction in mortality rates. However, another prospective study [8] found improvement in unfavorable neurological outcomes and mortality rates in patients that received dexamethasone. Regardless, if the choice is made to administer steroids, then they should be given in conjunction with early antibiotic administration.

The excellent CSF penetration of third-generation cephalosporins makes them the optimal initial choice for treatment of bacterial meningitis [7,11].

Treatment Summary (Table 13.2)

In adults, treatment is based on the most common organism:

Table 13.2 Guidelines for empiric antibiotic coverage for suspected meningitis (Adapted from Tunkel and Fitch)

Age	Common organisms	Recommended antibiotic coverage
<1 month	<i>Listeria monocytogenes</i> , <i>Streptococcus agalactiae</i> , <i>Escherichia coli</i>	Ceftriaxone ^a OR Cefotaxime PLUS ampicillin Alternatively: Ampicillin ^b PLUS aminoglycoside (gentamycin)
1–23 months	<i>Streptococcus agalactiae</i> , <i>Haemophilus influenzae</i> , <i>Streptococcus pneumoniae</i> , <i>Escherichia coli</i> , <i>Neisseria meningitidis</i>	Vancomycin ^c PLUS Ceftriaxone OR Cefotaxime
2–50 years	<i>Streptococcus pneumoniae</i> , <i>Neisseria meningitidis</i>	Cefotaxime OR Ceftriaxone PLUS Vancomycin
>50 years	<i>Listeria monocytogenes</i> , <i>Streptococcus pneumoniae</i> , <i>Neisseria meningitidis</i>	Cefotaxime OR Ceftriaxone PLUS Vancomycin PLUS Ampicillin
Post-instrumentation (neurosurgery or ENT)	<i>Staphylococcus aureus</i> and <i>Pseudomonas aeruginosa</i>	Ceftazidime ^d PLUS Vancomycin

^aCeftriaxone and cefotaxime are third-generation cephalosporins.

^bAmpicillin covers *Listeria monocytogenes*.

^cVancomycin covers resistant strains of *Streptococcus pneumoniae* and methicillin-resistant *Staphylococcus aureus* (MRSA).

^dCeftazidime is a third-generation cephalosporin that covers pseudomonas.

- For *S. pneumoniae*, *N. meningitidis*, and *H. influenzae*, a third-generation cephalosporin is recommended.
- If suspected resistance to *S. pneumoniae*, then vancomycin should be added. Vancomycin can also be added to cover for methicillin-resistant *Staphylococcus aureus* (MRSA) if suspected.
- Ampicillin can be added to cover for *L. monocytogenes* in the elderly, immunocompromised populations, alcoholics, suspicion for CSF leak, and in children.
- If there is a contraindication to cephalosporins, a quinolone may be substituted for this class.
- If encephalitis is suspected, then an acyclovir should be started empirically.
- Steroids should be considered before or in conjunction with antibiotic administration.

Disposition

Most of these patients will typically be admitted to a higher level of care (ICU or step-down unit) due to risk of escalation along the sepsis cascade, seizures, and the development of elevated ICP. To protect staff patients should be placed on droplet precautions.

Meningitis is contagious but only to those that have had a prolonged close exposure to the index patient. Close contacts include those living in the same home, share utensils, coughing, sneezing, and those with kissing/oral exposure to the index patient. Chemoprophylaxis should be initiated within 24 h. The CDC recommends any one of these regimens: rifampin orally for 2 days, ceftriaxone as a single intramuscular injection, or a single dose of a quinolone (ciprofloxacin) [26].

Aseptic Meningitis

This is designated when there are clinical and CSF signs of meningitis without any organism growth on culture media:

- Common etiologies and organisms implicated in aseptic meningitis include viruses, tuberculosis, drugs, fungi, and parasites.
- Aseptic meningitis can be seasonal, i.e., *Enterovirus* and Coxsackie virus are commonly seen in the summer months but may be seen in the late fall.
- Prognosis is generally good. Most recover in a short time period.
- There have been reported cases of drug-induced meningitis from several classes of medications most notably immunomodulating drugs such as intravenous immunoglobulin (IVIG) [9], antibacterials such as TMP-SMX [6], and NSAIDs [1].
- When CSF patterns suggest viral meningitis, patients are typically started on empiric acyclovir and admitted for surveillance and HSV CSF testing to rule out clinical escalation indicative of occult encephalitis.

*The patient from the case presentation was admitted to the hospital confirmed with *Listeria meningitis*. He had an uncomplicated hospital course and was discharged to his long-term care facility.*

Encephalitis

Encephalitis is an infection of the brain parenchyma resulting in motor, sensory, cognitive, and/or behavioral changes. These signs and symptoms can help distinguish encephalitis and meningitis as the latter does not typically present with the neurological deficits. However, in the early phases of presentation, occult encephalitis may be challenging to differentiate clinically.

There are many different causes of encephalitis including bacterial, fungal, protozoal, and viral including herpes simplex virus (HSV), varicella zoster virus (VZV), and several arboviruses that cause Eastern equine encephalitis (EEE), West Nile virus (WNV), Western equine encephalitis (WEE) virus, Zika virus, Avian influenza virus, and lymphocytic choriomeningitis virus (LCMV) and prion disease. Obtaining a good travel history is crucial.

Clinical Features

May include altered mental status, cranial nerve deficits, hemiparesis, or hemiplegia

Laboratory Testing

LP for CSF analysis is obtained with consideration for polymerase chain reaction (PCR) for viruses.

Routine labs obtained as with meningitis is also appropriate including CBC, metabolic panel, and blood cultures. In cases of herpes encephalitis, it is not uncommon to note a moderate amount of red blood cells in the CSF sample.

Imaging

Brain imaging (i.e., MRI) may be useful, but CT is often more accessible and is adequate to rule out mass effect.

Basal ganglia or thalamic lesions may be seen in encephalitis secondary to arboviruses, tuberculosis, and Creutzfeldt-Jakob disease. Temporal lobe enhancement on MRI is suggestive of HSV encephalitis. HSV may also manifest temporal lobe hemorrhagic lesions.

Treatment

Empiric antibiotics are indicated with acyclovir until able to narrow the spectrum of coverage.

Rabies Encephalitis

Rabies encephalitis is caused by an infection from the rabies virus. Symptoms include fever, altered mental status, and hydrophobia with pharyngeal spasms, progressing to muscular hyperactivity similar to that seen in severe tetanus infections followed by paralysis, coma, and death [12]. Symptoms may appear days to months after exposure. It is rapidly progressive to encephalitis and subsequent death. The CDC estimates that rabies-related deaths were about 1–2 per year in the 1990s down from 100 per year the 1800s [27].

Transmission occurs via direct communication of saliva from the bite of an animal reservoir, less commonly via aerosolized virus encountered in a closed setting, i.e., cave, or through tissue or organ transplantation from a donor that was infected with the virus. Common animal reservoirs for rabies in the United States are bats, raccoons, skunks, and wild unvaccinated dogs (less common in the United States).

Diagnosis requires a detailed history and a high index of suspicion for rabies; otherwise it can be easily overlooked for other viral illnesses. CSF examination may reveal anti-rabies antibodies in unimmunized patients.

There is no current treatment for rabies, so efforts are targeted toward prevention after index exposure.

If the animal cannot be captured and monitored for signs of behavioral changes (10-day period) or if the vaccination status of the animal is unknown, then rabies prophylaxis should be considered.

Prevention

Currently the CDC recommends a four-injection vaccine regimen starting on day 0, day 3, day 7, and day 14 after the initial dose and the rabies immune globulin, for previously unvaccinated persons, given as an intramuscular injection on two separate injection sites [27].

Malaria

Malaria is a protozoal disease endemic in tropical parts of the world especially Africa, the Middle East/Asia, the Caribbean, and Central and South America. It is transmitted via the bite of an infected female anopheles mosquito, the primary vector. Malaria affects millions worldwide with high mortality especially in nonimmune hosts.

Cerebral malaria is rarely seen but when present has a high mortality. Mortality is upward of 20% with treatment and 100% without treatment [16]. It has a bimodal distribution in age (children and elderly are mostly affected), immunocompromised. *P. falciparum* is implicated in >95% of cases of cerebral malaria [16]. It is characterized by the presence of altered mental status, +/- seizures without focal neurological signs with confirmation of *P. falciparum* infection. Increased cerebral vascular permeability may lead to cerebral edema.

Clinical Features

Nonspecific flu-like symptoms: fatigue, malaise, diaphoresis, chills, fever headache, myalgias, arthralgias, hypoglycemia, and abdominal pain

In severe cases, patients may present with altered mental status, coma, severe anemia, renal failure, and shock.

Laboratory Testing

Blood smear is the gold standard for diagnosis, showing erythrocytes with ring-shaped trophozoites.

Rapid immunochromatographic testing is available in endemic areas.

Imaging

Computed tomography or magnetic resonance imaging (MRI) may be normal or show evidence of cerebral edema (loss of gray-white matter differentiation).

Patients may present at any stage of infection, so the role of the emergency physician is to rapidly recognize and triage the patient to the appropriate clinical setting; obtain necessary blood tests, fluid resuscitation if needed; and obtain imaging if warranted, stabilization, and disposition. Many of the patients may be administered with antibiotics, as the initial diagnosis may not be evident until blood smear results which can take several hours to days.

Treatment Regimens Recommended by the World Health Organization [25]

For uncomplicated *P. falciparum* malaria, treatment duration is 3 days with an artemisinin-based combination therapy. Any one of the treatment regimens listed below:

1. Artemether PLUS lumefantrine
2. Artesunate PLUS amodiaquine
3. Artesunate PLUS mefloquine
4. Dihydroartemisinin PLUS piperaquine
5. Artesunate PLUS sulfadoxine-pyrimethamine

Neurosyphilis

Untreated primary syphilis can progress to neurosyphilis. The CSF infection with *Treponema pallidum* typically can be cleared by the immune system so the typical inflammatory reaction seen with other CSF infections may not be evident. Neurosyphilis is not common given the widespread use of antibiotics. It may be seen in people with deficient immune response as in HIV/AIDS.

Diagnosis is made definitively by dark field microscopy visualizing the spirochete, but this is expensive and very complex. Other indirect options include evaluating for antibody reactivity. CSF venereal disease research laboratory (VDRL) and rapid plasma reagin (RPR) tests detect antibodies. Further confirmatory testing includes the fluorescent treponemal antibody absorption (FTA-ABS), syphilis enzyme immunoassay (EIA), or the *Treponema pallidum* particle agglutination assay (TPPA), which detects antibodies against specific *Treponema* antigens.

Treatment is with penicillin (PCN) G 24 million units intravenously for 10–14 days or procaine PCN G intramuscular daily for 10–14 days in addition to probenecid for the same duration of time. Probenecid limits renal excretion of penicillin.

Patients should be cautioned against allergic reactions and the possibility of a Jarisch-Herxheimer reaction, which is a self-limiting febrile reaction, characterized by myalgias, light-headedness, rigors, diaphoresis, headache, and a worsening rash seen typically in the first 24 h after the initial penicillin dose.

Cerebral Abscess

An abscess of the brain is a collection of purulent exudate due to bacterial and other infections (fungal, protozoal) in the brain parenchyma. The majority are caused by spread of infected material from a focus of suppuration elsewhere in the body more commonly from head and neck infections, i.e., paranasal sinuses, the middle ear, dental infection, and mastoiditis. Other areas of the body that can seed infections are the left side of the heart (bacterial endocarditis) and the lung (arteriovenous fistulas cause right to left shunting), penetrating craniocerebral trauma and neurosurgical procedures and bacteremic spread. Immunocompromised hosts are at greater risk than the general population.

Progression of disease follows chronological order:

1. Cerebritis: localized inflammation and edema without tissue necrosis (1–2 weeks).
2. Period of liquefaction and necrosis (2–3 weeks).
3. Fibrosis (scarring) occurs after 3 weeks.

Clinical Features

Altered mental status, headache, fever, seizures, nausea, vomiting, chills, personality or behavioral changes if the abscess is located in the frontal lobe and localizing neurological signs dependent on the area of the affected

Imaging

MRI is superior to CT scan of the brain in evaluating abscesses. Given the stages of progression of abscesses and surrounding edema, CT may not show changes until later, but CT can be rapidly obtained in the ED. When CT is obtained, intravenous contrast should be used, as it will help to enhance the ring of fibrotic tissue and edema.

Transesophageal echocardiogram should be considered to assess for endocarditis vegetations, but this typically may not be feasible in the ED.

Prophylaxis/Treatment

The culprit organism is dependent upon the inciting nidus of infection. Abscesses seeding from dental, nasal, and paranasal sinus infections are typically

polymicrobial (*Streptococcus*, *Staphylococcus*, and anaerobes); therefore antibiotic coverage should cover a broad range of organisms. If post-op from a neurosurgical or an otolaryngological procedure, methicillin-resistant *Staphylococcus aureus* (MRSA) and gram-negative bacilli coverage should be considered. Stereotactic aspiration can be considered to drain the abscess depending on the size, accessibility, and clinical condition; some studies noted abscesses larger than 2.5 cm should be drained [4].

Spinal Epidural Abscess

This occurs when an abscess forms in the epidural space. Different organisms have been implicated in epidural abscesses such as staphylococci species including MRSA, *E. coli*, *P. aeruginosa*, and anaerobic bacteria. Bacteria can gain access to the epidural space by local spread from a skin or soft tissue infection or via systemic spread. Risk factors include intravenous drug use (IVDU); immune suppression such as with malignancy, human immunodeficiency virus (HIV) infection/acquired immunodeficiency syndrome (AIDS), and diabetes; alcoholism; and spinal surgery. Spinal abscesses are typically located in the lumbar and thoracic spine but can happen anywhere in the spinal column. A thorough history and physical exam are keys to discerning the potential sources of infection.

Clinical Features

Clinical presentation can be insidious and nonspecific and may include fever, myalgias, malaise, back pain, and/or extremity weakness. Physical exam findings can include local back tenderness and neurological deficit +/- such as numbness, paresis, or paralysis, but features of spinal nerve compressions (numbness, bowel and bladder dysfunction, leg paresis/paralysis) may be delayed and unpredictable but are more obvious the larger the size of the abscess.

Imaging

MRI is the most sensitive modality. CT scan with myelography can be utilized if MRI is unavailable but is less sensitive for diagnosing spinal epidural abscesses.

Treatment

Antibiotic selection should be broad and cover the most common organisms including MRSA, anaerobes, pseudomonas, and gram positives followed by prompt consultation to neurosurgery and hospital admission.

Pearls

- Perform complete neurological ROS and exam; recognizing it may dynamically change or fluctuate over time rather than remain static.
- Recognize clinical signs of increased intracranial pressure.
- Recognize when to perform neuroimaging before an LP.
- Provide antimicrobial agents as quickly as possible in cases of suspected CNS infections.
- Realize that most patients with meningitis/encephalitis may not present with the classic symptoms.
- Provide isolation to protect staff.
- Consider chemoprophylaxis for close contacts in cases of meningitis.
- Have a high index of suspicion for CNS and spinal infections when dealing with immunocompromised populations.

Acknowledgment No financial/commercial conflicts to disclose

References

1. Auriel E, Regev K, Korczyn A. Non-steroidal anti-inflammatory drugs exposure and the central nervous system. *Handb Clin Neurol*. 2014;119:577–84.
2. Attia JMD, Hatala R, Cook DJ, Wong JG. Does this adult patient have acute meningitis? *JAMA*. 1999;282(2):175–81.
3. Bamberger D. Diagnosis, initial management, and prevention of meningitis. *Am Fam Physician*. 2000;82(12):1491–8.
4. Brouwer M, Tunkel A, McKhann G II, Van de Beek D. Brain abscess. *N Engl J Med*. 2014;371:447–56.
5. Brouwer MC, McIntyre P, Prasad K, Van de Beek D. Corticosteroids for acute bacterial meningitis. *Cochrane Database Syst Rev*. 2015. doi:10.1002/14651858.CD004405.
6. Bruner EKMD, Coop CCMD, White KMMD. Trimethoprim-sulfamethoxazole induced aseptic meningitis—not just another sulfa allergy. *Ann Allergy Asthma Immunol*. 2014;113(5):520–6.
7. Cherubin CE, Eng RH, Norrby R, Modai J, Humbert G, Overturf G. Penetration of newer cephalosporins into cerebrospinal fluid. *Rev Infect Dis*. 1989;11(4):526–48.
8. De Gans J, van de Beek D. Dexamethasone in adults with bacterial meningitis. *N Engl J Med*. 2002;347(20):1549–56.
9. De Vlieghere FC, Peetermans WE, Vermeylen J. Aseptic granulocytic meningitis following treatment with intravenous immunoglobulin. *Clin Infect Dis*. 1994;18(6):1008–10.
10. Durand LM, Calderwood SB, Weber DJ, Miller SI, Southwick FS, Caviness VS Jr, Swartz MN. Acute bacterial meningitis in adults—a review of 493 episodes. *N Engl J Med*. 1993;328(1):21–8.
11. Fitch MT, van de Beek D. Emergency diagnosis and treatment of adult meningitis. *Lancet Infect Dis*. 2007;7(3):191–200.
12. Hankins DG, Rosekrans JA. Overview, prevention, and treatment of rabies. *Mayo Clin Proc*. 2004;79(5):671–6.
13. Leibovici L, Gafter-Gvili M, Paul M, Almanasreh N, Tacconelli E, Andreassen S, Nielsen AD, Frank U, Cauda R. Relative tachycardia in patients with sepsis: an independent risk factor for mortality. *Q J Med*. 2007;100(10):629–34.
14. Miner J, Heegaard W, Mapes A, Biros M. Presentation time to antibiotics, and mortality of patients with bacterial meningitis at an urban county medical center. *J Emerg Med*. 2001;21(4):387–92.

15. Michael B, Menezes BF, Cunniffe J, Miller A, Kneen R, Francis G, Beeching NJ, Solomon T. Effect of delayed lumbar punctures on the diagnosis of acute bacterial meningitis in adults. *Emerg Med J*. 2010;27(6):433–8.
16. Mung'Ala-Odera V, Snow RW, Newton CR. The burden of the neurocognitive impairment associated with plasmodium falciparum malaria in sub-Saharan Africa. *Am J Trop Med Hygiene*. 2004;71(2 suppl):64–70.
17. Rady MY, Smithline HA, Blake H, Nowak R, Rivers E. A comparison of the shock index and conventional vital signs to identify acute, critical illness in the ED. *Ann Emerg Med*. 1994;24(4):685–90.
18. Rasmussen HH, Sorensen HT, Moller-Petersen J, Mortensen FV, Nielsen B. Bacterial meningitis in elderly patients: clinical picture and course. *Age Ageing*. 1992;21(3):216–20.
19. Singer M, Deutschman CS, Seymour CW, et al. The third international consensus definitions for sepsis and septic shock (sepsis-3). *JAMA*. 2016;315(8):801–10.
20. Thomas KE, Hasbun TR, Jekel J, Quagliarello VJ. The diagnostic accuracy of Kernig's sign, Brudzinski's sign, and nuchal rigidity in adults with suspected meningitis. *Clin Infect Dis*. 2002;35(1):46–52.
21. Tunkel AR, Hartman BJ, Kaplan SL, Kaufman KA, Roos KL, Scheld WM, Whitley RJ. Practice guidelines for the management of bacterial meningitis. *Clin Infect Dis*. 2004;39(9):1267–84.
22. Uchihara T, Tsukagoshi H. Jolt accentuation of headache: the most sensitive sign of CSF pleocytosis. *Headache*. 1991;31(3):167–71.
23. Van de Beek D, de Gans J, Spanjaard L, Weisfelt M, Reitsma JB, Vermeulen M. Clinical features and prognostic factors in adults with bacterial meningitis. *N Engl J Med*. 2004;351(18):1849–59.
24. Wira C, Francis MW, Bhat S, et al. The shock index as a predictor of vasopressor use in ED patients with severe sepsis. *WJEM*. 2014;15(1):60–6.
25. World Health Organization. Guidelines for treatment of Malaria. 2015 [cited 2016 Apr 29]. 3rd ed. Geneva. http://apps.who.int/iris/bitstream/10665/162441/1/9789241549127_eng.pdf.
26. Centers for Disease Control and Prevention. Control and Prevention of Meningococcal Disease: Recommendations of the Advisory Committee on Immunization Practices (ACIP). Atlanta, GA. 1997 [cited 2016 Apr 29]. <http://www.cdc.gov/mmwr/preview/mmwrhtml/00046263.htm>.
27. Centers for Disease Control and Prevention. Rabies in the U.S. Atlanta, GA. 2011 [cited 2016 Apr 29]. <http://www.cdc.gov/rabies/location/index.html>.

Latha Ganti and Javier Rosario

Case Presentation

A 35-year-old female patient was brought into the emergency department by EMS one weekend morning after being found down by her parents, with a chief complaint of altered mental status, confusion, and somnolence. Upon arrival the patient was drowsy but arousable and able to converse. She admitted to taking a handful of her muscle relaxant medicine (cyclobenzaprine) with some alcohol that prior evening when she had an argument with her boyfriend. Her past medical history included depression, for which she took escitalopram 10 mg daily. The muscle relaxant was given to her recently for an acute muscle spasm of her lower back. She denied any other drugs or medications.

Soon after her initial assessment, the patient became lethargic, opening her eyes only to pain, having incomprehensible conversations, and using her extremities only to localize to painful stimuli. Her vital signs included a temperature of 101.7 F, a heart rate of 127 bpm, a blood pressure of 147/75, a respiratory rate of 26, and a pulse oximetry of 95% on 4 L/min of oxygen by nasal cannula. On physical exam she was diaphoretic, with skin flushing, horizontal nystagmus, tremors, and rigid muscle tone which was more notable in the lower extremities, accompanied by hyperreflexia. She was intubated due to her altered sensorium and was rapidly sedated to control her tremors and rigidity. Her blood work showed no electrolyte abnormalities, an elevated creatine kinase at 4730 U/L, an alcohol level of 78 mg/dL, and a positive opiate screen.

L. Ganti, M.D., M.S., M.B.A., F.A.C.E.P. (✉) • J. Rosario, M.D., F.A.A.E.M., F.A.C.E.P.
University of Central Florida College of Medicine,
Orlando, FL, USA
e-mail: Latha.ganti@ucf.edu; javirosariomd@gmail.com

Introduction

One does not usually think of movement disorders being an emergency, because indeed, these conditions are predominantly managed in the outpatient setting. However, certain conditions can present emergently where a missed diagnosis can result in unnecessary morbidity and mortality for the patient. Most movement disorder emergencies evolve over hours to days [1]. While the fine nuances of movement disorders and their overall management are complex and out of scope for emergency medicine physicians, the effects they can produce when uncontrolled such as rhabdomyolysis, trauma from falls, and autonomic dysfunction are not uncommon presentations to the emergency department.

Movement disorders can loosely be classified as too much (hyperkinetic) or too little (hypokinetic or Parkinsonian movement, Fig. 14.1). Hypokinetic disorders are characterized by akinesia or bradykinesia—the absence or paucity of movement. The earliest signs of parkinsonism include loss of arm swing, followed by decreased facial movement. The hyperkinetic disorders can be broken down into five categories, including dystonia, chorea, tics, myoclonus, and tremor.

Hypokinetic Emergencies

Acute Parkinsonism

Parkinsonism is a feature of Parkinson's disease seen with other movement disorders, most commonly Lewy body dementia, multiple system atrophy, progressive supranuclear palsy, corticobasal degeneration, and frontotemporal dementias. Unlike Parkinson's disease, parkinsonism is commonly associated with autonomic dysfunction and cerebellar ataxia. Also, unlike Parkinson's disease, parkinsonism generally has a poor response to levodopa.

The primary form of acute parkinsonism results from the loss of dopaminergic neurons from the substantia nigra and accumulation of Lewy bodies within the remaining neurons [1]. Secondary parkinsonism can result from drugs, toxins, post encephalopathy, and vascular causes (Table 14.1).

To make the diagnosis of parkinsonism, either bradykinesia or rest tremor must be present, along with at least one of the other six cardinal features (Table 14.2).

The most common cause of acute parkinsonism is exposure to dopamine-blocking drugs. Drug-induced parkinsonism is seen in 7% of those with parkinsonism [2] and can be caused by both neuroleptic and non-neuroleptic drugs (Table 14.3). The underlying mechanism is dopamine depletion. Of particular note to the emergency physician is the presence of two very common antiemetics, prochlorperazine and metoclopramide, on this list. In patients with parkinsonism, a better antiemetic is ondansetron, which would not cause or exacerbate parkinsonism. Drug-induced parkinsonism is more likely to be symmetrical (on both sides of the body) and less likely to be associated with tremor, although it can sometimes present asymmetrically and with a tremor [2]. Risk factors for drug-induced parkinsonism include

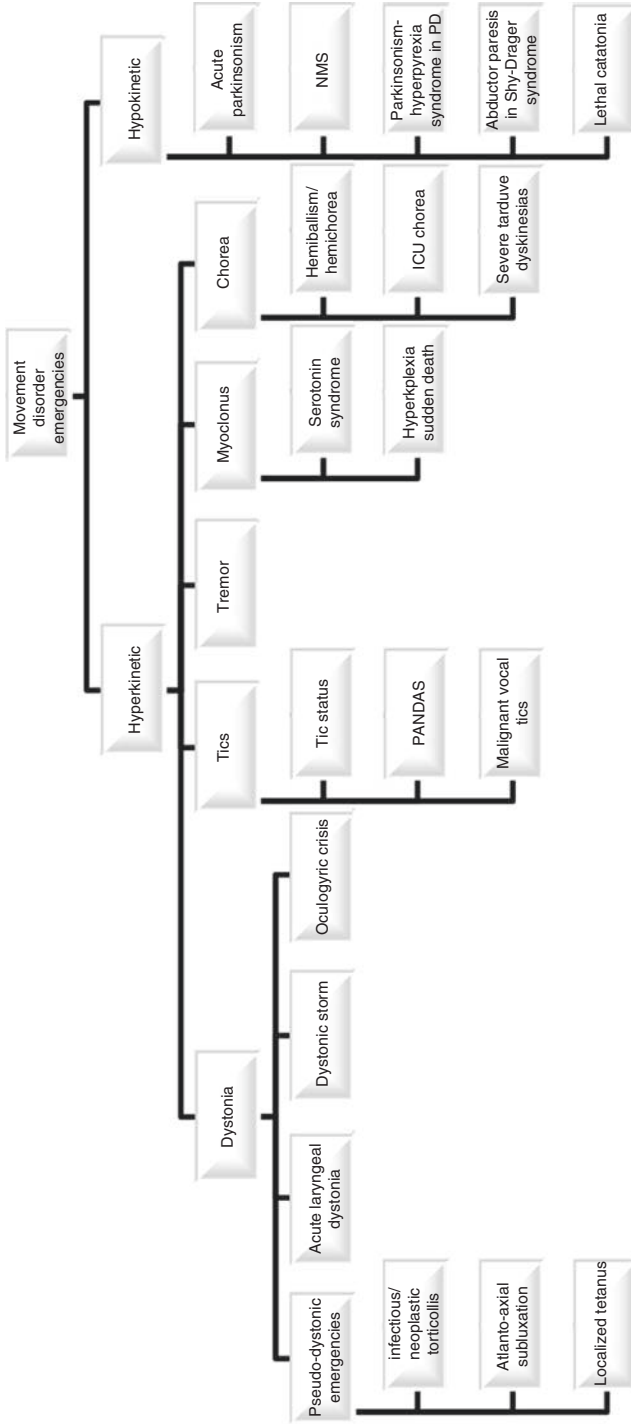


Fig. 14.1 Classification of movement disorders based on whether movements are slow or fast

Table 14.1 Causes of secondary parkinsonism

<i>Toxic/metabolic</i>
• Carbon monoxide
• Cadmium
• 1-methyl-4-phenyl-1,2,3,6-tetrahydropyridine (MPTP)
• Ethanol withdrawal (rare)
• Methanol
• Disulfiram
• Bone marrow transplantation
• Wasp stings (rare)
<i>Structural</i>
• Stroke
• Subdural hematoma
• Central and extrapontine myelinolysis (rare)
• Tumor
• Hydrocephalus (obstructive > normal pressure)
<i>Psychiatric</i>
• Catatonia
• Conversion
• Obsessive-compulsive disorder (obsessive slowness)—rare
• Malingering
<i>Infectious/postinfectious</i>
<i>Autoimmune (lupus)</i>
<i>Drugs (see Table 14.3)</i>

Adapted from Frucht [1]

Table 14.2 Cardinal features of parkinsonism

• Rest tremor
• Bradykinesia
• Rigidity
• Flexed posture
• Freezing
• Loss of postural reflexes

older age, female gender, and comorbid affective disorders. Drug-induced parkinsonism most frequently occurs after a new drug has been on board for a month, although it can be seen as early as a few days or even after a single dose. When the offending drug is stopped, approximately 2/3 of patients will recover within a month.

Neuroleptic Malignant Syndrome

Neuroleptic malignant syndrome (NMS) is a severe disorder caused by an adverse reaction to medications with dopamine receptor-antagonist properties or the rapid withdrawal of dopaminergic medications. The first reported case of NMS was in 1956, in response to the antipsychotic drug chlorpromazine (Thorazine) [3]. NMS

Table 14.3 Drugs that can cause parkinsonism

<i>Neuroleptics</i>
• Chlorpromazine
• Flupenthixol
• Haloperidol
• Fluphenazine
• Methotrimeprazine/levomepromazine
• Olanzapine
• Oxypertine
• Pericyazine
• Perphenazine
• Pimozide
• Pipotiazine
• Prochlorperazine
• Promazine
• Quetiapine
• Risperidone
• Sulpiride
• Thioridazine
• Trifluoperazine
• Zotepine
<i>Non-neuroleptics</i>
• Amiodarone
• Cinnarizine
• Lithium
• Valproic acid
• Methyl dopa
• Metoclopramide
• Prochlorperazine
• Tranlycypromin

Adapted from Parkinson's Disease Society of the United Kingdom [2]

is characterized by mental status changes, rigidity, hyperpyrexia, and dysautonomia, typically in that order. The dysautonomia can manifest as nausea, vomiting, labile blood pressure, diaphoresis, and occasionally cardiac dysrhythmias (Fig. 14.2). The mental state will initially present as anxiety and agitation and then delirium and coma as the condition worsens. NMS is sometimes accompanied with sialorrhea, which can lead to aspiration pneumonia [4]. NMS typically develops over a 24–72 h period post-neuroleptics and can last up to 20 days after oral neuroleptics are discontinued and even longer when associated with depot forms of the drugs [5]. NMS diagnostic criteria developed by an expert panel of the American College of Emergency Physicians (ACEP) are summarized in Table 14.4 [6]. Systemic risk factors for NMS include exhaustion, agitation, and dehydration [7]. Diagnosing NMS requires a high index of suspicion, and with a mortality of 10–20%, it is a high-stakes diagnosis [8]. Associated laboratory abnormalities include leukocytosis and elevated creatine phosphokinase and hepatic transaminases, which are nonspecific. The CT and CSF will generally be normal. EEG may show non-generalized slowing in 50% of cases [7].

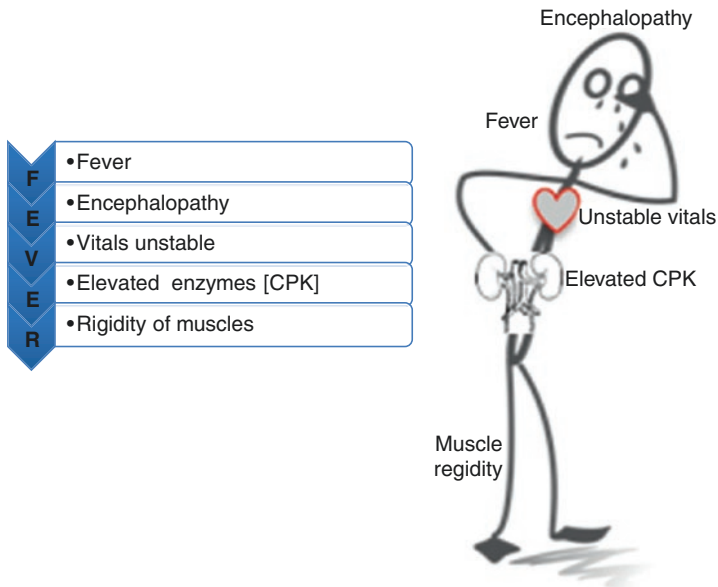


Fig. 14.2 Neuroleptic malignant syndrome: FEVER (NMS man)

Table 14.4 ACEP diagnostic criteria for NMS [6]

- | |
|--|
| • Exposure to a dopamine agonist, or dopamine-agonist withdrawal, within the past 72 h |
| • Hyperthermia |
| • Rigidity |
| • Mental status alteration |
| • Elevated creatine phosphokinase |
| • Sympathetic nervous system lability, defined as the presence of two or more of these features: elevated blood pressure, blood pressure fluctuation, diaphoresis, or urinary incontinence |
| • Tachycardia and tachypnea |
| • Negative workup for infectious, toxic, metabolic, and neurologic causes |

NMS is treated by immediate withdrawal of the offending agent, administration of a dopamine agonist, temperature control (antipyretics and external cooling methods), correction of electrolyte abnormalities, and supportive care, preferably in an intensive care unit. Significant metabolic acidosis may be present, for which bicarbonate loading should be considered [9]. Benzodiazepines can be helpful to control agitation and provide anxiolysis. For NMS associated with psychosis, electroconvulsive treatment (ECT) has been shown to be beneficial [10]. Other pharmacologic therapies, considered adjunctive, include bromocriptine, dantrolene, and amantadine. Bromocriptine is given to reverse the hypodopaminergic state and is administered orally (or via nasogastric tube), starting with 2.5 mg two or three times daily and increasing doses by 2.5 mg every 24 h until a response or until reaching a

maximum dose of 45 mg/day. Dantrolene can be administered intravenously starting with an initial bolus dose of 1–2.5 mg/kg followed by 1 mg/kg every 6 h up to a maximum dose of 10 mg/kg/day [9, 11–13]. Oral dantrolene is used in less severe cases or to taper down from the intravenous form after a few days with doses that range from 50 to 200 mg/day. Due to a risk of hepatotoxicity, dantrolene is typically discontinued once symptoms begin to resolve. Bromocriptine, however, is generally maintained for at least 10 days for NMS related to oral neuroleptics and 2–3 weeks for depot neuroleptics [4]. Amantadine is also sometimes used in the treatment of NMS. Amantadine functions through a presynaptic mechanism to counteract neuroleptic dopaminergic inhibition, with similar end results as bromocriptine [14].

NMS may present similarly to malignant hyperthermia (MH), but is distinguished by the setting (MH occurs after exposure to inhalational anesthetics), and response to dopamine agonists (MH does not respond). NMS also shares many features with serotonin syndrome (SS) and a few with the anticholinergic toxidrome (Table 14.5).

Table 14.5 NMS vs. serotonin syndrome vs. anticholinergic toxidrome vs. malignant hyperthermia

	NMS	SS	Anticholinergic OD	MH
Trigger	D2 blocking antipsychotics, antiemetics	SSRIs, SNRIs, TAs, MAOIs	Antinicotinic and antimuscarinic agents	Volatile anesthetics, succinylcholine
Onset	Gradual > abrupt	Abrupt > gradual	Abrupt	Abrupt
Course	Prolonged, days to weeks	Rapidly resolving	Rapidly resolving	
Neuromuscular findings	“Lead-pipe rigidity”	Myoclonus , tremor, shivering increased tone in lower extremities	Normal or relaxed muscle tone, occasional myoclonic jerking	“Rigor mortis” rigidity of the entire body
Reflexes	↓	↑	Normal	↓
Pupils	Mydriasis	Normal	Mydriasis “blind as bat”	Normal
BP	↑	↑	↑	↑
Mental status	Restlessness, agitation		Confusion, visual, auditory, and sensory hallucinations, “mad as a hatter”	
Skin	Diaphoretic	Diaphoretic	“Dry as a bone”	Diaphoretic
Bowel sounds	↑	Normal	↓ ileus	↓
Adjunct pharmacologic treatment	Cyproheptadine, methysergide	Bromocriptine, amantadine, dantrolene, ECT	Physostigmine	Dantrolene, azumolene

Parkinsonism Hyperpyrexia Syndrome

Parkinsonism hyperpyrexia syndrome is clinically indistinguishable from NMS and is thought to occur due to central dopamine deficiency. It was first discovered in the 1960s after the practice of “levodopa holidays” resulted in deaths [7]. It is seen when patients discontinue their dopamine agonist medications (including levodopa and amantadine), in the premenstrual period and also during times of warm weather which suggests dehydration may also be a risk factor. Treatment with steroids has been shown to be beneficial in Parkinson’s disease patients afflicted with this syndrome [15].

Lethal (Malignant) Catatonia

Lethal or malignant catatonia (MC) is characterized by initial intense agitation, followed by catatonia, stereotypies, psychosis, and autonomic instability. It lasts an average of 8 days, and the fever may get as high as 110 °F. This is followed by severe parkinsonism, stupor, and eventual death. Mortality can be as high as 60% [16]. It can be indistinguishable from NMS clinically; the only difference being it occurs in the absence of exposure to dopamine-blocking medications. In this sense, NMS can be thought of as a form or variant of MC. Emergency department management consists of intravenous lorazepam and withholding antipsychotic drugs, in addition to temperature regulation, and supportive care in the intensive care unit. The challenge for the emergency physician is to recognize MC and not administer antipsychotics, even though the condition often presents in those with preexisting psychiatric illness. Withholding of antipsychotic drugs is imperative, as their anti-dopaminergic properties can result in *death* from MC. If intravenous benzodiazepine administration does not promptly correct the catatonia, ECT should be instituted. While not done in the emergency department, it does need to be started as soon as possible and before the MC symptom severity progresses beyond return (within a few days).

Abductor Paresis in Multiple System Atrophy

Multiple system atrophy (MSA), formerly known as Shy-Drager syndrome, is a rare, sporadic, degenerative disorder of adult onset between ages 30 and 75 years. It is characterized by cell loss in the striatonigral and olivopontocerebellar structures of the brain, resulting in parkinsonism features. One of the emergencies associated with this movement disorder is dysfunction of the posterior cricoarytenoid muscles, the sole abductors of the vocal cords. This compromise initially presents with a history of loud nighttime snoring, followed by daytime inspiratory stridor. These patients are at risk of sudden death due to upper airway obstruction [7]. Signs of laryngeal dysfunction such as hoarseness and dysarthria are usually absent. Definitive diagnosis is made by fiber-optic laryngoscopy during wakefulness and

sleep. Emergency department management consists of airway protection and prompt ENT consultation [7, 17].

Hyperkinetic Emergencies

Chorea, Ballismus, and Athetosis

Chorea, athetosis, and ballismus are hyperkinetic movements along a continuum. Chorea is an abnormal involuntary movement derived from the Greek word “dance.” It is characterized by brief, abrupt, irregular, unpredictable, *fast*, non-stereotyped movements that are purposeless. When chorea becomes more extreme and involves the abdomen or proximal muscles, it is termed ballismus. Ballismus consists of repetitive, but constantly varying, large amplitude involuntary movements of the proximal parts of the limbs. This activity is almost ceaseless and movements are often complex and combined. By contrast, athetosis is a symptom characterized by *slow*, involuntary, convoluted, writhing movements of the fingers, hands, toes, and feet and in some cases, arms, legs, neck, and tongue.

Hemichorea-hemiballismus (HH) is a violent and distressing movement disorder characterized by high amplitude, flinging movements of limbs on one side of the body in which ballismus and chorea represent a continuum of hyperkinetic movements with different velocity and amplitude [18]. The most common cause of HH is vascular, typically associated with an ischemic or hemorrhagic lesion to the contralateral subthalamic area [19]. Ballismus can also be seen with nonketotic hyperosmolar coma or as the initial presentation of diabetes. In such cases, correction of the electrolyte abnormalities usually results in vast improvement of the ballistic movements.

Serotonin Syndrome

Serotonin syndrome is a potentially life-threatening emergency that classically presents as the triad of autonomic dysfunction, neuromuscular excitation, and altered mental status. These symptoms result from increased serotonin levels affecting the central and peripheral nervous systems precipitated by the use of serotonergic drugs. These drugs result in an over-activation of 5HT-1A and 5HT-2A receptors. This syndrome classically is the result of a complex interaction between two therapeutic serotonergic drugs that work by different mechanisms but also can occur from normal therapeutic use of a single agent or intentional overdoses [20]. Multiple drug combinations can result in serotonin syndrome (Table 14.6), many of which are used or encountered in daily basis by emergency physicians. Many physicians are not aware of the presentation and management of serotonin excess [21]. This may particularly be a challenge in less severe presentations of this syndrome. Patients may deteriorate slowly and become critically ill after an initial benign presentation.

Table 14.6 Some drugs associated with serotonin toxicity

Increased synthesis	Increased release
L-Tryptophan	Amphetamines Methamphetamines “Ecstasy” Cocaine Codeine Dextromethorphan Levodopa Reserpine
<i>Decreased serotonin degradation (MAO-I)</i>	<i>Decreased serotonin reuptake</i>
Amphetamine metabolites Selegiline Isocarboxazid Pargyline	Amphetamines Carbamazepine Citalopram Cocaine Cyclic antidepressants Fluoxetine Paroxetine Meperidine Methadone Sertraline Trazodone Venlafaxine Cyclobenzaprine
<i>Direct or indirect serotonin receptor agonists</i>	
Buspirone Electroconvulsive therapy Lithium LSD Sumatriptan	

Adapted from Rosen's Emergency Medicine 7th Ed. Chapter 149/Antidepressants; Serotonin Syndrome p.1971

Because of the long-acting effects of many of these medications, this syndrome can occur days or weeks after any of these active agents are ingested or even discontinued. It is important to gather history of medication dose increases, changes, or illicit drug exposures while on these medications. It may be difficult to distinguish serotonin syndrome from an overdose of cocaine, lithium, MAOIs, neuroleptic malignant syndrome, acute opioid withdrawal, or thyroid storm. Physicians are encouraged to consider the possibility of serotonin syndrome in patients who use serotonergic medications and present with altered mental status, fever, agitation, tremors, myoclonus, hyperreflexia, hyperthermia, ataxia, incoordination, diaphoresis, shivering, and diarrhea [22]. The Hunter criteria [23] may help in diagnosis of this syndrome.

Hunter criteria

In the presence of one or more serotonergic agents in the past 5 weeks	Yes, patient has serotonin syndrome or toxicity
Spontaneous myoclonus	Yes
Inducible myoclonus and agitation or diaphoresis	Yes
Ocular clonus and agitation or diaphoresis	Yes
Tremor and hyperreflexia	Yes
Hypertonic and temp >38 °C and ocular clonus or inducible clonus	Yes

From Dunkley EJC, et al.; The Hunter serotonin toxicity criteria: Simple and accurate diagnostic decision rules serotonin toxicity. QJM 96:635, 2003

The management of this syndrome can be difficult and challenging. Discontinuation of suspected causal agent is important. For treatment initiation and for neurologic complications like agitation, seizures, and/or tremors, benzodiazepines are recommended. There is no consensus in global therapy, but cyproheptadine seems to be a well-tolerated and accepted option in treatment continuation or when benzodiazepines are contraindicated or fail. Adults receive 4–8 mg orally followed by 4 mg doses every 1–4 h as needed until a maximum of 32 mg/day. Children may receive 0.25 mg/kg/day divided in doses and given every 6 h to a maximum of 16 mg/day.

Myoclonus Status

Myoclonus can be described as a sudden, brief, involuntary muscle jerk. Some types of dementia associated with myoclonus include Parkinson's disease, Creutzfeldt-Jakob disease, Alzheimer's disease, and Huntington's disease [24]. Myoclonus status, seen in many anoxic brain injuries, renal failure, hepatic failure, glycemic disturbances, electrolytic disturbances, hyperthyroidism, metabolic alkalosis or acidosis, vitamin deficiencies, or encephalopathy [25], is a non-resolving period of involuntary muscle jerks. There are two types described: positive myoclonus, the more common form, is caused by abrupt muscle contraction; negative myoclonus is caused by sudden cessation of ongoing muscular activity. A combination of both forms may be present in the same disease. There are multiple reasons for myoclonus to happen; a good history is of necessity to characterize myoclonus and to effectively treat the underlying cause. Multiple drugs may cause myoclonus including levodopa, bismuth subsalicylate, antidepressants, lithium, quinolone antibiotics, clozapine, opioids, gabapentin, lamotrigine, phenytoin, phenobarbital, propofol, and calcium channel blockers [26]. It is important to determine the time of onset, the type of myoclonus, precipitating or alleviating factors, family history, and associated symptoms. Determination of when the myoclonus appears (at rest, on posture, or during movements) will help in characterization and management. Electrophysiological tests are very helpful in determining the origin of myoclonus onset [26].

Controlling myoclonus status can be challenging; typically a single pharmacological agent can rarely control myoclonus, and a combination of drugs, often in large dosages, will be needed. Focal and segmental myoclonus may be treated with botulinum toxin injections. Antiepileptic drugs such as valproate, levetiracetam, and clonazepam may be helpful with variable results depending on origin of myoclonus (cortical, subcortical, spinal, or peripheral) [27].

Tardive Dyskinesias

Tardive dyskinesias embrace a gamma of iatrogenic hyperkinetic and hypokinetic movement disorders caused by blocking dopamine receptors induced by prolonged use of antipsychotic and antiemetic medications (Table 14.7). Typical signs include rapid, involuntary movements (or tics) of the extremities, trunk, or most commonly the face (i.e., blinking, grimacing, tongue movements, or chewing) [28]. Other symptoms and complications may include tremors, akathisia, dystonia, paresthesias, and pain. A variant and possible complication of tardive dyskinesia is respiratory dyskinesia, characterized by dyspnea, dysphonia, respiratory alkalosis, and recurrent aspiration pneumonia. Tardive dyskinesia can be difficult to treat and can sometimes be permanent. Risk of development can be decreased by reducing dose of antipsychotic or changing to an atypical agent.

The treatment of tardive dyskinesia can be difficult to approach. Acute management should include slow taper off and removal of causal agent. The treatment of tardive dyskinesia can include multiple medications and may vary depending on severity of presentation, causal agent, or response to treatment initiated. Proposed alternatives include tetrabenazine, reserpine, amantadine, clonazepam, and valproic acid. Other medications that have been considered are donepezil, lithium, pyridoxine, melatonin, propranolol, botulinum toxin injections, or deep brain stimulation. The table below outlines different alternatives and dosing regimens to be considered [28].

Table 14.7 Medications with potential of causing tardive dyskinesia

Ziprasidone	Risperidone
Haloperidol	Aripiprazole
Droperidol	Metoclopramide
Clozapine	Duloxetine
Quetiapine	Citalopram
Lithium	Olanzapine
Chlorpromazine	
Prochlorperazine	

Adapted from: Waln O, Jankovic J. An Update on Tardive Dyskinesia: From Phenomenology to Treatment. Louis ED, ed. Tremor and Other Hyperkinetic Movements. 2013;3:tre-03-161-4138-1

Treatment tardive dyskinesia

Medication	Starting dose (mg)	Daily dose range (mg)
<i>Dopamine-depleting medications</i>		
Tetrabenazine	12.5–25	25–200
Reserpine	0.25	0.75–8
Amantadine	100	100–300
<i>GABA agonist medications</i>		
Clonazepam	0.5	1–4
Baclofen	10	20–120
Valproic acid	500	900–1500
<i>Anticholinergic medications</i>		
Trihexyphenidyl	1	4–20

Adapted from Waln O, Jankovic J. [30]

Hyperekplexia Sudden Death

Hyperekplexia (“exaggerated surprise”) is characterized by pronounced startle responses to tactile or acoustic stimuli and hypertonia [29]. It is a rare genetic disorder, related to abnormal metabolism of glycine, mostly seen in infants but also in children and adults. It has been associated with sudden death. Typically, there is generalized stiffness, excessive startle beginning at birth, and a short period of generalized stiffness following the startle reflex. The extreme hypertonia prevents voluntary movement and can cause the patient to fall stiffly, like a log, without loss of consciousness [30]. Hyperreflexia and unsteady gait may also be noted. The frequency and severity of the startle response can be increased by emotional tension, stress, or fatigue. Hyperekplexia is frequently misdiagnosed as a form of epilepsy. Fortunately, the treatment is fairly straightforward and consists of the antianxiety and antispasmodic drug clonazepam.

Tic Status

Tics are repetitive, involuntary movements or vocalizations. Tic status is an extremely rare condition, characterized by frequent and severe motor tics that result in long-lasting physical exhaustion, cardiovascular demand, and pain interfering with sleep. It is generally noted in patients who have an existing tic disorder such as Gilles de la Tourette syndrome. As is true for many conditions, tic status is seen when patients discontinue or decrease the dose of their medication, are unable to take their medication due to prolonged vomiting, or have increased demand due to acute illness making the medication less effective. In tic status, hyperkinetic movements tend to dominate the clinical picture resulting in severe systematic effects such as cardiorespiratory difficulties, dysautonomia, and rhabdomyolysis [31].

Suggested criteria [31] for tic status include:

- Tics occur in one or more groups of muscles in a stereotyped and repetitive manner.
- The episode is sustained for at least several minutes or hours.
- During the episode, the patient is unable to suppress the tics, and they intrude into normal activities.
- The episode is in clear consciousness.

Management of tic status is not well established due to its rare occurrence, but a report of an extreme case [33] notes that sedation, intubation, and mechanical ventilation over the course of days, along with the addition of medications to control tics, are warranted.

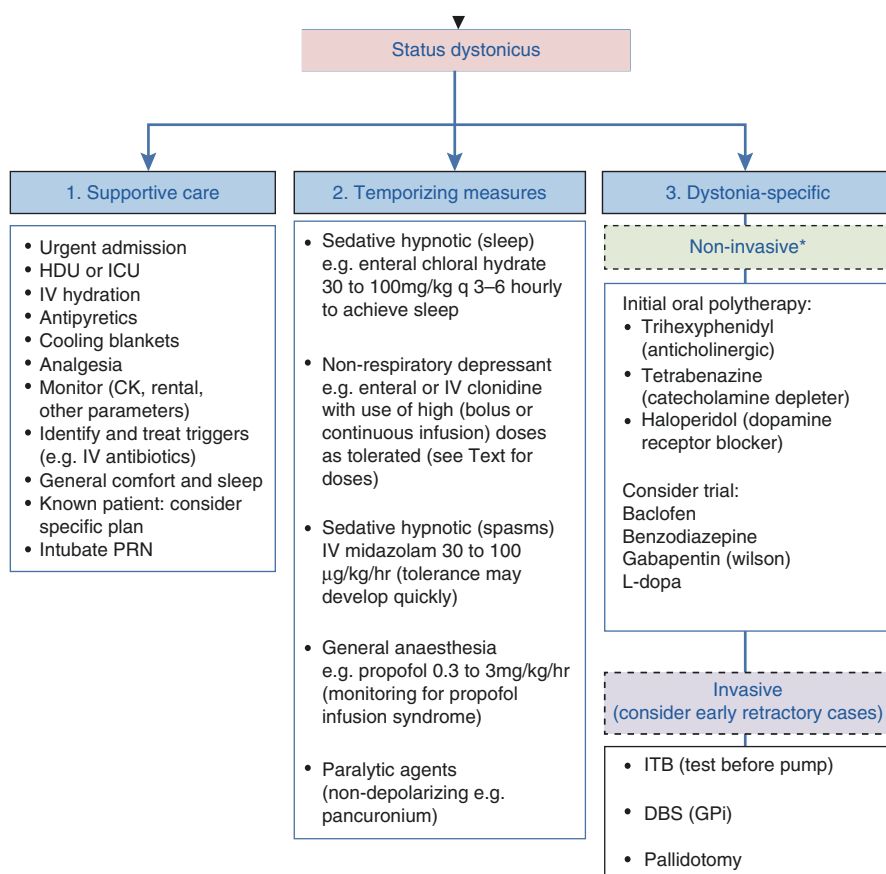
Acute Dystonia

Dystonia consists of involuntary sustained or spasmodic muscle contractions involving contraction of both the agonist and the antagonist muscles, often resulting in a painful, contorted position. In contrast to chorea, the movements are usually slow and sustained and occur in a repetitive and patterned manner. Unlike athetosis, they are generally not fluid. Dystonia can involve specific muscle groups, such as the eyes in oculogyric crisis or the neck in torticollis. A characteristic feature of dystonia is the presence of muscle co-contraction, exacerbation with the intention to move and/or nonspecific afferent stimuli, and complete resolution of dystonia by sleep, irrespective of the mechanism of dystonia. The most common cause of acute dystonia is medication. High-potency dopamine D2 receptor antagonists such as fluphenazine and haloperidol are the most likely causative drugs [32], but acute dystonic reactions can be seen with numerous drugs. Notably for the ED, metoclopramide is a common culprit for acute dystonic reactions, particularly when the dose exceeds 30 mg. Drug-related dystonic reactions can occur after a single dose of the drug or after repeated use. The symptoms are often erratic and idiosyncratic, and most resolve with reassurance. In the ED, intravenous diphenhydramine is sometimes given either as a treatment for when a dystonic reaction occurs or “prophylactically” to prevent one. While such practice is commonplace, there is no evidence to support such “prophylaxis” [33]. Risk factors for dystonic reactions secondary to drugs include younger age, male gender, history of prior similar reactions, recent cocaine use, history of mood disorders, and metabolic issues such as dehydration and electrolyte abnormalities [27, 34].

Dystonic Storm and Status Dystonicus

Dystonic storms are episodes of a rare condition called status dystonicus where people develop frequent and intense episodes of severe generalized dystonia. A single episode of this severe dystonia may be referred to as a “dystonic storm” or “dystonic attack.” They usually occur in individuals who already have dystonia

affecting a lot of the body. Dystonic storm or status dystonicus manifests with acute onset severe generalized dystonia. It presents with continuous unremitting generalized dystonic spasms. It is a terrifying entity for patients and also frightening for physicians managing such unstable patients. Level of consciousness is preserved, so patients are fully aware of their surroundings, but patients may not be able to communicate due to laryngeal and facial muscle involvement. This is an emergency, as respiratory muscles can become compromised, necessitating vigilance and prompt intubation when appropriate. Triggers for status dystonicus include infection, trauma, and neuroleptic drugs. Since sustained spasms can be life-threatening, intensive care unit admission is necessary, as well as prompt treatment with anticholinergics, dopamine depletors, baclofen, and sedatives. Supportive care includes IV fluid hydration, antipyretics, analgesics, cooling blankets, and monitoring of electrolytes and creatine kinase. In cases refractory to oral treatment, urgent deep brain stimulation [DBS] is now considered the treatment of choice by many experts [35].



ITB intrathecal baclofen, DBS deep brain stimulation, GPi globus pallidus pars interna.

Adapted from *Developmental Medicine & Child Neurology* Volume 56, Issue 2, pages 105–112, 4 Dec 2013. doi: [10.1111/dmcn.12339](https://doi.org/10.1111/dmcn.12339).

<http://onlinelibrary.wiley.com/doi/10.1111/dmcn.12339/full#dmcn12339-fig-0001>

Oculogyric Crisis

Oculogyric crisis (OGC) is an acute dystonic reaction of the ocular muscles characterized by bilateral dystonic elevation of visual gaze lasting from seconds to hours [36]. There is sustained conjugate upward and lateral deviation of the eyes that results in diplopia. OGC is a rare but characteristic ocular manifestation of dystonia. It is associated with a number of conditions, including drug-induced reactions (most common), hereditary and sporadic movement disorders, and focal brain lesions. Like other forms of dystonia, disruption of dopaminergic pathways lies at the core of the pathophysiology [37]. OGC is treated with dopaminergic and anticholinergic agents.

Pearls and Pitfalls

- The most common culprit behind acute movement disorder emergencies is a neuroleptic drug reaction.
- Most movement disorder emergencies are *hypo*- rather than *hyperkinetic*.
- The most common cause of myoclonus is anoxic-ischemic brain injury.
- Movement disorders can be exacerbated by infection and stress.
- Movement disorder emergencies often warrant ICU admission to monitor for rosepsis, aspiration pneumonia, adynamic ileus, and rhabdomyolysis.

References

1. Frucht SJ. Movement disorders emergencies. 2nd ed. New York: Humana Press; 2013.
2. Drug Induced Parkinsonism. https://www.parkinsons.org.uk/sites/default/files/publications/download/english/fs38_druginducedparkinsonism.pdf. Accessed 20 Feb 2017.
3. Oruch R, Pryme IF, Engelsen BA, Lund A. Neuroleptic malignant syndrome: an easily overlooked neurologic emergency. *Neuropsychiatr Dis Treat*. 2017;13:161–75. doi:10.2147/NDT.S118438.
4. Berman BD. Neuroleptic malignant syndrome: a review for neurohospitalists. *Neurohospitalist*. 2011;1(1):41–7. doi:10.1177/1941875210386491.
5. Adnet P, Lestavel P, Krivosic-Horber R. Neuroleptic malignant syndrome. *Br J Anaesth*. 2000;85(1):129–35. doi:10.1093/bja/85.1.129.
6. Criteria Developed for Neuroleptic Malignant Syndrome. <https://www.acep.org/content.aspx?id=79747>. Accessed 20 Feb 2017.
7. Poston KL, Frucht SJ. Movement disorders emergencies. *J Neurol*. 2008;255(Suppl 4):2–13. doi:10.1007/s00415-008-4002-9.
8. Shalev A, Hermesh H, Munitz H. Mortality from neuroleptic malignant syndrome. *J Clin Psychiatry*. 1989;50(1):18.
9. Strawn JR, Keck PE Jr. Early bicarbonate loading and dantrolene for ziprasidone/haloperidol-induced neuroleptic malignant syndrome. *J Clin Psychiatry*. 2006;67(4):677.
10. Addonizio G, Susman VL. ECT as a treatment alternative for patients with symptoms of neuroleptic malignant syndrome. *J Clin Psychol*. 1987;48:102–5.
11. Bhanushali MJ, Tuite PJ. The evaluation and management of patients with neuroleptic malignant syndrome. *Neurol Clin*. 2004;22(2):389–411.
12. Rosenberg MR, Green M. Neuroleptic malignant syndrome. Review of response to therapy. *Arch Intern Med*. 1989;149(9):1927–31.

13. Sakkas P, Davis JM, Janicak PG, Wang ZY. Drug-treatment of the neuroleptic malignant syndrome. *Psychopharmacol Bull.* 1991;27(3):381–4.
14. McCarron MM, Boettger ML, Peck JJ. A case of neuroleptic malignant syndrome successfully treated with amantadine. *J Clin Psychiatry.* 1982;43(9):381–2.
15. Sato Y, Asoh T, Metoki N, Satoh K. Efficacy of methylprednisolone pulse therapy on neuroleptic malignant syndrome in Parkinson's disease. *J Neurol Neurosurg Psychiatry.* 2004;74:574–6.
16. Mann SC, Caroff SN, Bleier HR, et al. Lethal catatonia. *Am J Psychiatry.* 1986;143:1374–81.
17. Munhoz RP, Moscovich M, Araujo PD, Teive HA. Movement disorders emergencies: a review. *Arq Neuropsiquiatr.* 2012;70(6):453–61.
18. Giovanni C, Carlo C. Hyperkinetic movement disorder emergencies. *Curr Neurol Neurosci Rep.* 2017;17:6. doi:[10.1007/s11910-017-0712-7](https://doi.org/10.1007/s11910-017-0712-7).
19. Bansil S, Prakash N, Kaje J et al. Movement disorders after stroke in adults: a review. *Tremor Other Hyperkinet Mov (N Y).* 2012;2. doi:[10.7916/D86W98TB](https://doi.org/10.7916/D86W98TB).
20. Volpi-Abadie J, Kaye AM, Kaye AD. Serotonin syndrome. *Ochsner J.* 2013;13(4):533–40.
21. Mackay FJ, Dunn NR, Mann RD. Antidepressants and the serotonin syndrome in general practice. *Br J Gen Pract.* 1999;49(448):871–4.
22. Frank C. Recognition and treatment of serotonin syndrome. *Can Fam Physician.* 2008;54(7):988–92.
23. Dunkley EJC, et al. The hunter serotonin toxicity criteria: simple and accurate diagnostic decision rules serotonin toxicity. *QJM.* 2003;96:635.
24. Kojovic M, Cordivari C, Bhatia K. Myoclonic disorders: a practical approach for diagnosis and treatment. *Ther Adv Neurol Disord.* 2011;4(1):47–62. doi:[10.1177/1756285610395653](https://doi.org/10.1177/1756285610395653).
25. Caviness JN. Parkinsonism and related disorders. Myoclonus. *Parkinsonism Relat Disord.* 2007;13(Suppl. 3):S375–84.
26. Borg M. Symptomatic myoclonus. *Neurophysiol Clin.* 2006;36:309–18.
27. Robottom BJ, Factor SA, Weiner WJ. Movement disorders emergencies. Part 2: hyperkinetic disorders. *Arch Neurol.* 2011;68(6):719–24.
28. Waln O, Jankovic J. An update on tardive dyskinesia: from phenomenology to treatment. *Tremor Other Hyperkinet Mov (N Y).* 2013;3:tre-03-161-4138-1.
29. Mariani LL, Hainque E, Mongin M, Apartis E, Roze E. Teaching Video NeuroImages: Hyperekplexia: a syndrome of pathologic startle responses. *Neurology.* 2017;88(13):e126–7. doi:[10.1212/WNL.0000000000003766](https://doi.org/10.1212/WNL.0000000000003766).
30. Frucht SJ. Movement disorders emergencies. *Curr Neurol Neurosci Rep.* 2005;5:284–93.
31. Kovacs N, Herold R, Janszky J, Komoly S, Ferenc N. Tics status: a movement disorder emergency. *J Neurol.* 2011;258:143–5. doi:[10.1007/s00415-010-5680-7](https://doi.org/10.1007/s00415-010-5680-7).
32. Derinöz O, Caglar AA. Drug-induced movement disorders in children at paediatric emergency department: 'dystonia'. *Emerg Med J.* 2013. doi:[10.1136/emered-2011-200691](https://doi.org/10.1136/emered-2011-200691).
33. Digby G, Jalini S, Taylor S. Medication-induced acute dystonic reaction: the challenge of diagnosing movement disorders in the intensive care unit. *BMJ Case Rep.* 2015. doi:[10.1136/bcr-2014-207215](https://doi.org/10.1136/bcr-2014-207215).
34. Allen NM, Lin JP, Lynch T, King MD. Status dystonicus: a practice guide. *Dev Med Child Neurol.* 2014;56(2):105–12. doi:[10.1111/dmcn.12339](https://doi.org/10.1111/dmcn.12339). Epub 2013 Dec 4.
35. Fang JY, Tolleson C. The role of deep brain stimulation in Parkinson's disease: an overview and update on new developments. *Neuropsychiatr Dis Treat.* 2017;13:723–32. doi:[10.2147/NDT.S113998](https://doi.org/10.2147/NDT.S113998). eCollection 2017.
36. Koban Y, Ekinci M, Cagatay HH, Yazar Z. Oculogyric crisis in a patient taking metoclopramide. *Clinical Ophthalmology (Auckland, NZ).* 2014;8:567–9. doi:[10.2147/OPHT.S60041](https://doi.org/10.2147/OPHT.S60041).
37. Barow E, et al. Oculogyric crises: etiology, pathophysiology and therapeutic approaches. *Parkinsonism Relat Disord.* 2016;36:3–9.

Christopher Horn

Introduction

The patient presenting with acute neurological complaints can consume substantial time and cognitive energy due to the potential complexity of the neurological exam, the variability of care and expertise at any given facility, and the plethora of imaging possibilities. The goal of this chapter is to streamline decision-making for emergency neuroimaging, allowing for early diagnosis and initial therapy.

When a patient presents with symptoms suggestive of acute neurological injury to the emergency department, there are two major goals:

1. Stabilization of the patient
2. Determination of the need for emergent time-dependent intervention (such as medical therapy, surgical decompression, hematoma evacuation, thrombectomy, etc.)

Stabilization of the patient refers to the ABCs, which is outside the scope of this chapter, other than highlighting that neurologically injured patients can be exquisitely sensitive to hypoxia and hypotension and that mean arterial pressure (MAP) goals may be partially determined by the results of neuroimaging [1–5].

C. Horn, M.D.

Director of Neurocritical Care, Department of Neurosciences, Wellstar Kennestone Hospital, Marietta, Georgia, USA

e-mail: Christopher.Horn@wellstar.org

The determination for intervention is based on the neurological exam and results of neuroimaging. The neurological exam in emergent situations can often be scaled down to Glasgow Coma Scale (GCS) and National Institute of Health Stroke Scale (NIHSS), for example. The repertoire of surgical intervention has recently expanded to include thrombectomy in patients suffering from ischemic stroke secondary to large vessel occlusions. The addition of these interventions now requires the exclusion of large vessel occlusion [6].

When attempting to achieve these two goals outlined above, there are two dictums to keep in mind:

1. Clinical exam and presenting symptoms are of the utmost importance.
2. Time matters.

What dictates the neuroimaging and to significant degree the medical plan is the history and presentation of the patient. Based on a predominating pattern of symptoms or clinical signs, there are roughly three different themes or categories:

1. *Focal brain presentation*: These patients have more commonly unilateral symptoms and signs such as hemiplegia, hemiparesis, hemisensory loss, aphasia, and visual field cut (homonymous hemianopsia or quadrantanopsia).
2. *Generalized brain presentation*: These presentations are hallmarked by a significant impairment of consciousness.
3. *Malignant headache presentation*: These patients present with intense acute-onset headache. The headache at times can be paired with focal findings that can be subtle, limited to eye movement or visual obscurations, but the overwhelming complaint is the headache.

The above themes are broad generalizations and can be fine-tuned with knowing more collateral information, which may or may not be readably available. Realistically these generalizations will also have overlap when it comes to etiology, but they can be used for determining initial diagnostic testing.

Since time is of the utmost importance in caring for this patient population, the correct imaging selection plays a vital role expediting correct care. The test that holds the most information and is the quickest typically to obtain is the head CT without contrast. CT scanners are typically ubiquitous and can identify a majority of hemorrhages rapidly as well as early signs of ischemia. Downsides include radiation exposure, early ischemia is not always visible and also that streak artifact throughout the posterior fossa makes it difficult to determine changes in the brainstem and the cerebellum. Because of the ubiquity and speed of CT, it is typically the most common emergent neuro image obtained.

Below is a basic algorithm based on the use of CT scan to help illustrate a basic decision process. At its most elemental, this algorithm helps achieve the second major goal, which is to identify patients for emergent surgical intervention.

Cortical Algorithm

Part One (Fig. 15.1)/Part A (Fig. 15.2)

The first part of the algorithm is the non-contrast head CT. The immediate question that should be asked is “Does the CT explain the patient’s presentation?” If the head CT and the exam correlate, the next branch point is whether emergent intervention is indicated. The following cases illustrate scenarios when exam and initial non-contrasted head CT are compatible.

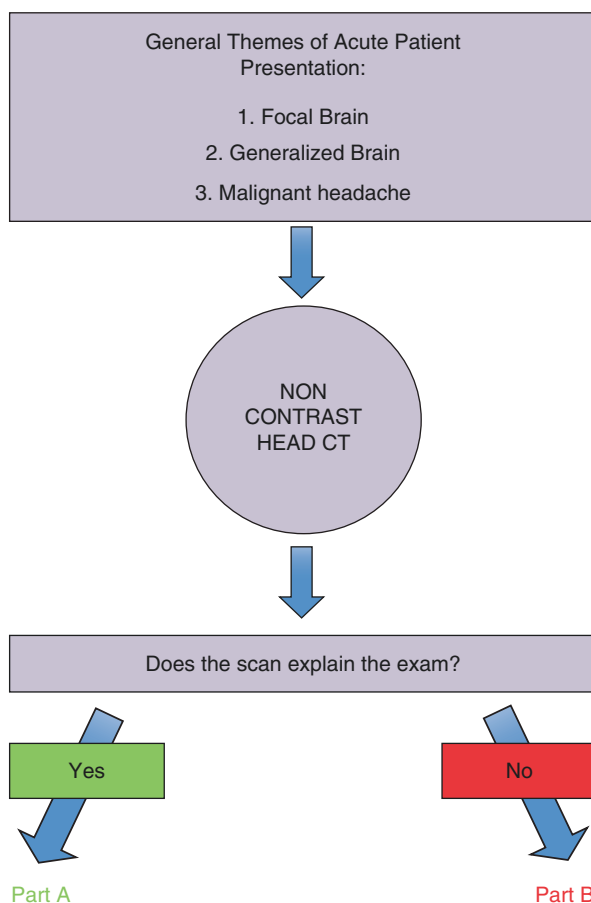


Fig. 15.1 This figure is a graphical representation of the initial question of the algorithm which is “Does the presentation and neurological examination fit with the neurological imaging obtained (in these examples CT)?”

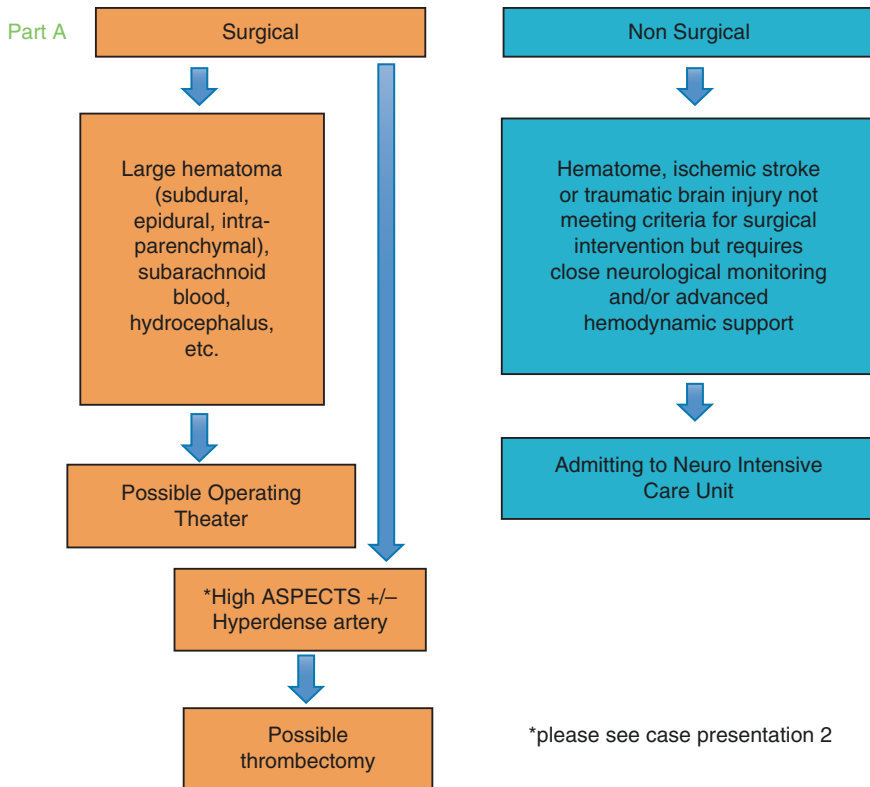


Fig. 15.2 Part A of the algorithm occurs when the patient’s clinical presentation is explained by the initial imaging, in this case non contrasted head CT. The etiologies are subdivided into surgical and non surgical possibilities

Case Presentation 1

A 54-year-old Mexican American woman with history of atrial fibrillation, mechanical mitral valve replacement secondary to rheumatic valve disease on rivaroxaban and with recent history of endocarditis treated with full course of antibiotics, presents with acute-onset left-sided weakness and slurred speech.

Her family witnessed the acute neurological change. She arrived to ED by EMS 45 min after onset. Vitals on arrival were Tmax 37.5 C, BP 165/95, HR 94, RR 18, and pulse ox 98% on 2L NC.

Essential exam findings included a SEM murmur and + click over the left lower sternal border. Neurological exam showed GCS of 15 and NIHSS 15 with extraocular muscles intact, left partial facial droop, left hemiplegia, left hemisensory loss, and mild dysarthria.

Labs are pertinent for a serum creatinine of 1.7 mg/dL, normal platelet count and normal aPTT, PT, INR. STAT head CT obtained and relevant images are shown below (Fig. 15.3).

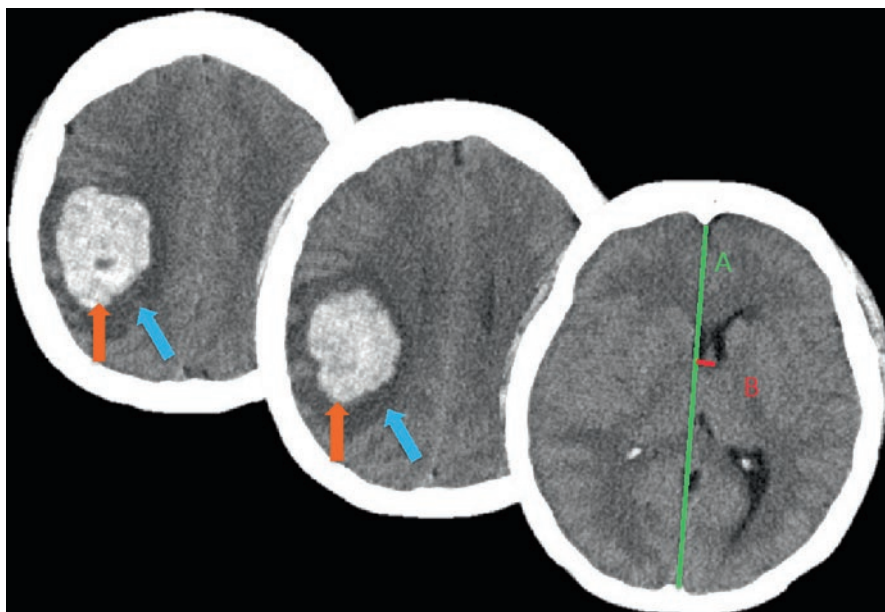


Fig. 15.3 Relevant axial non-contrast head CT images for Case 1 are shown. Left image and middle image characterize the hematoma. *Orange arrows* identify the hyper density, which is the acute hematoma. *Blue arrows* identify a hypo dense rim around the hematoma, which is perihematomal edema. Right image identifies how midline shift can be measured. *Green line* marked “A” represents midline. *Red line* marked “B” represents how far central structures (in this case the septum pellucidum) have been pushed from midline, hence midline shift. This measurement is typically expressed in millimeters

Her clinical appearance fits with a focal brain presentation. Her scan shows acute blood (orange arrow) involving the right frontal and parietal lobes, involving precentral gyrus (primary motor cortex) and postcentral gyrus (primary sensory cortex). What can also be seen is a few millimeters of perihematomal edema forming (blue arrow) as well as 3 mm of midline shift identified in the image on the right portion of the figure.

Midline shift signifies how far to the right or the left midline structures have been pushed. Midline structures that are used are the pineal gland and, more commonly, the septum pellucidum (the tissue that separates the lateral ventricles). This shift is measured by first drawing a line connecting the anterior and posterior attachments of the falx cerebri (thick dura that separates the two hemispheres). This is shown as green line A. Second is to draw a perpendicular line from the line A to the septum pellucidum, which is represented by red line B. The length of line B in millimeters equals the amount of midline shift. Midline shift directly correlates with level of consciousness [7].

These radiographic findings are consistent with her exam. Her age, comorbidities, and location of the clot dictate that she will likely undergo further imaging but that this is unlikely to change her care in the emergency department. Management includes prompt reversal of her coagulopathy and blood pressure control [1]. Neurosurgical evaluation is also reasonable to obtain in the ED. Table 15.1 highlights some of the imaging and clinical findings that suggest those who may benefit from surgery.

Table 15.1 Considerations for emergent surgery based on pathology

Pathology	Considerations for emergent surgical intervention
1. Acute intraparenchymal hematoma [1]	
A. Supratentorial	The usefulness of surgery is not well established [1]. Some limited evidence of possible benefit of surgical evacuation of lobar clot within 1 cm of the surface and GCS 9–12 [11]
B. Cerebellar	>3 cm in diameter and one or more of the following... <ol style="list-style-type: none"> 1. Deteriorating 2. Brainstem compression 3. Hydrocephalus
2. Acute subdural hematoma [12]	A. Clot thickness >10 mm or Midline shift >5 mm regardless of GCS B. GCS <9, Clot thickness <10 mm and midline shift <5 mm plus one or more of the following... <ol style="list-style-type: none"> 1. Clinical deterioration (decrease of GCS by >1) from injury to time of hospitalization 2. Patient with asymmetric or fixed or dilated pupils 3. ICP > 20 mm Hg
3. Acute epidural hematoma [13]	A. Hematoma volume >30 cm ³ regardless of GCS B. GCS <9 with pupillary abnormality
4. Acute ischemic stroke [6]	Endovascular therapy indicated if... <ol style="list-style-type: none"> 1. mRS 0-1 2. Causative occlusion of the ICA or proximal MCA 3. NIHSS ≥ 6 4. ASPECTS ≥ 6 5. ≤6 h from onset

A patient with acute spontaneous intracerebral hemorrhage typically require ICU (neurological intensive care unit if possible) admission. There are several reasons for the critical level of care. Maintaining oxygenation, cerebral perfusion, hemostasis, and tight blood pressure control are only a few of the measures undertaken in the ICU to minimize secondary injury [1].

Case Presentation 2

A 39-year-old Caucasian mother of four with recent left sprained ankle requiring a walking cast was noted to have left-sided weakness and slurred speech while walking with her husband around the block.

She arrived by EMS 30 min from onset.

Initial vitals are temperature 36.8C, BP 154/82, HR 95, RR 16, and pulse ox 100% on 2L. Her exam shows RRR no murmurs, no carotid bruits, left ankle with minimal swelling, GCS 15, NIHSS 16 consistent with left hemiplegia, left hemisensory loss, dysarthria, right gaze preference, and no blink to threat on the right.

Labs were unremarkable.

A STAT head CT was obtained and pertinent images were shown below (Fig. 15.4).

Her clinical appearance fits with a focal brain presentation. The two important things about this CT include that the tissue looks well preserved highlighted by the

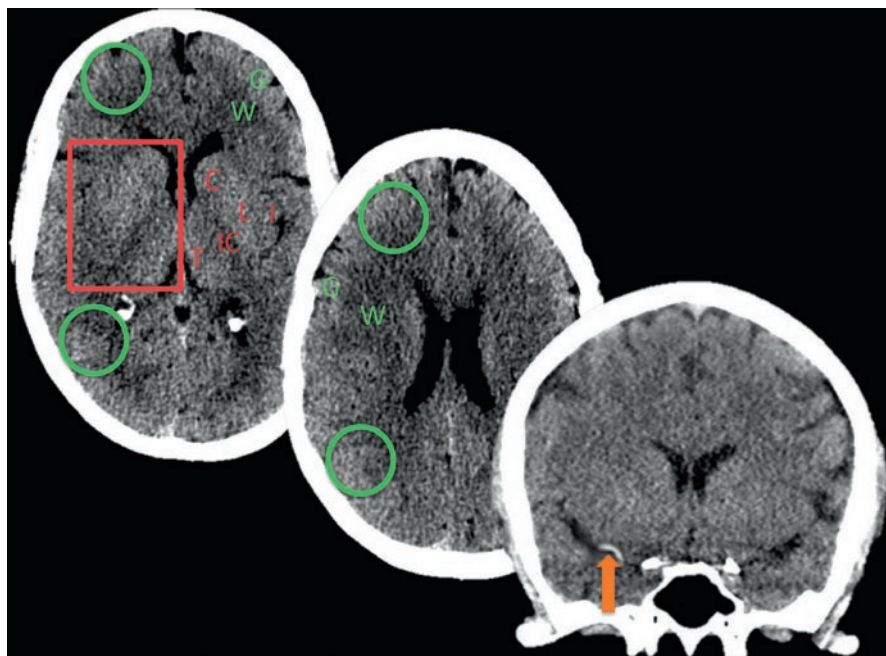


Fig. 15.4 Relevant non-contrasted CT images for Case 2. The axial images (left and middle) reveal normal appearing brain tissue. *G* gray matter, *W* white matter, *C* caudate head, *L* lentiform nucleus, *I* insula, *IC* internal capsule, *T* thalamus. *Green circles* intact gray white differentiation, *red box* intact distinctions of the basal ganglia. The coronal image on the right displays a hyper dense right middle cerebral artery (*orange arrow*) which is suggestive of acute clot

green circles identifying intact gray-white differentiation (*G* = gray matter, *W* = white matter) and the red box outlining the preserved basal ganglia (*C* = caudate, *L* = lentiform nucleus, *IC* = posterior limb of the internal capsule, *T* = thalamus) and the hyperdense artery which can represent acute clot within the right middle cerebral artery (MCA) (*orange arrow*, which is clearly seen on the coronal sections). Her scan does fit her clinical presentation secondary to the hyperdense MCA artery suggesting an MCA ischemic stroke.

Based on time, presentation, and lack of hemorrhage or significant ischemic change (hypodensity over one-third of a hemisphere), this patient appears to be a candidate for IV thrombolytics. The next question is whether to consider her for thrombectomy. To address this, there should be quantification of any ischemic change on her head CT using the Alberta Stroke Program Early CT Score (ASPECTS), confirming the large vessel occlusion with vascular imaging and quantifying the severity of symptoms.

Ischemic change can be quantified by using ASPECTS which is a 10-point score based on identifying early ischemic changes within the MCA circulation on a standard head CT without contrast. An ASPECTS score of 10 is reflective of no change, while a score of 0 suggests ischemic change through the entire MCA distribution. Typically patients with an ASPECTS of ≥ 6 should be considered for thrombectomy [6, 8–10].

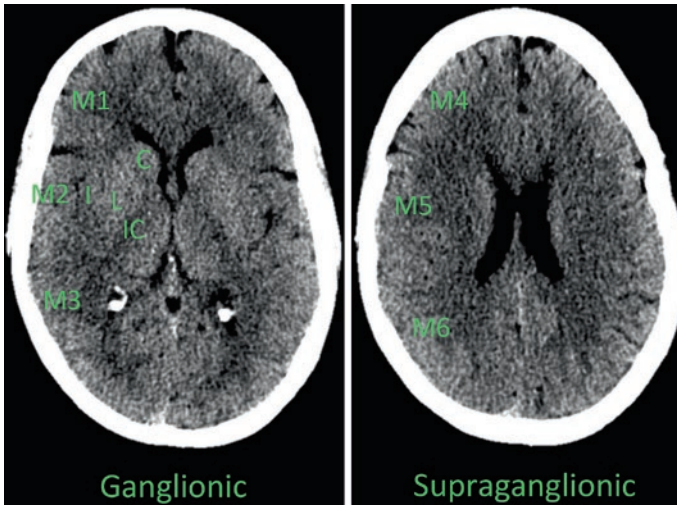
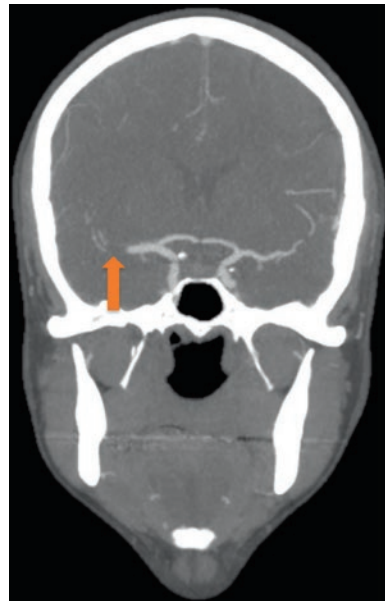

Fig. 15.5 Normal axial images of a non contrasted head CT which identifies the 10 sections of the MCA artery for calculating ASPECTS

Fig. 15.6 Coronal CT angiogram of the head identifying a clot in the right MCA (*orange arrow*). Confirming the hyperdense sign on the noncontrast head CT (Fig. 15.4)



To calculate the ASPECTS score, the non-contrast head CT is split it into two levels: the ganglionic (CT slices identifying any part of the basal ganglia) and supraganglionic (slices above the basal ganglia). Then based on the levels, the MCA territory is divided into ten areas, seven at the ganglionic and three at the supraganglionic levels (Fig. 15.5). All CT slices should be reviewed; only two slices are shown for examples of the ganglionic and supraganglionic levels [8–10].

Our patients' ASPECTS is 10. CT angiogram of her head is also shown (Fig. 15.6).

The clot is clearly seen on the coronal view of the CT angiogram (orange arrow). Given her clinical presentation, she is a prime candidate for thrombectomy and should receive emergent neuro interventional consultation.

Case Presentation 3

A 49-year-old African-American man with no significant past medical history other than not seeing a physician in the last 15 years developed acute-onset holocephalic headache associated with nausea and vomiting. He arrived via EMS 3 h after initial onset of the headache.

Initial vitals in the ED were temp 37.9, BP 184/91, HR 98, RR 20, and pulse oximetry 98% on 2L.

Exam shows a GCS of 12 (E2V4M6). He did not have any significant appendicular weakness or sensory deficit or cranial nerve deficit. A non-contrast head CT was obtained (Fig. 15.7).

His clinical presentation is a malignant headache. Although his overall sensorium is depressed, the initial complaint was that of an intense headache. His scan fits with his clinical examination. He has blood in the basal cisterns (red arrow), as well

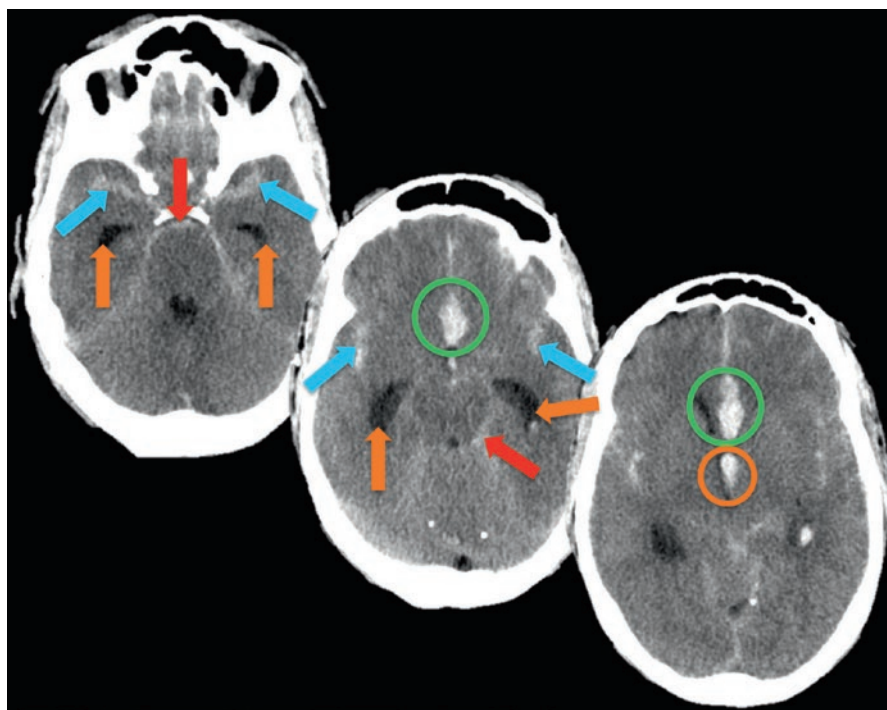
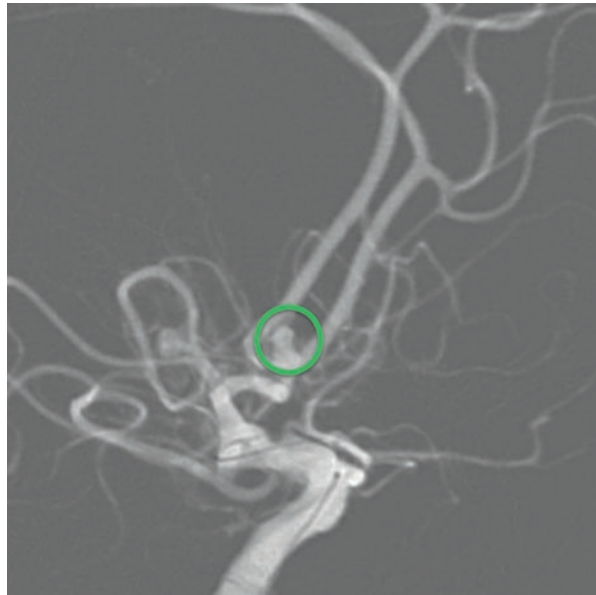


Fig. 15.7 Axial non contrasted head CT identifying acute blood within the basal cisterns (red arrow), sylvian fissure (blue arrows), intra hemispheric fissure (green circle), and 3rd ventricle (orange circle). The temporal horns of the lateral ventricles are also enlarged (orange arrows) suggestive of obstructive hydrocephalus

Fig. 15.8 Oblique view of the catheter based cerebral angiogram. The anterior communicating aneurysm is highlighted by the *green circle*



as Sylvian fissures (blue arrow) and intrahemispheric (green circle) and intraventricular space (orange circle). He also has dilated temporal horns (orange arrows) which in conjunction with his decreased mentation is reflective of obstructive hydrocephalus.

This patient needs an emergent external ventricular drain, blood pressure control, and admission to ICU (neurological intensive care unit if possible). He needs vascular imaging, typically a CT angiogram of the head to help identify the location and best option for securing the aneurysm. In this case, given the blood pattern on the initial head CT, he went directly to catheter based cerebral angiogram, which confirmed the suspicion of a ruptured anterior communicating aneurysm (Fig. 15.8).

Cortical Algorithm

Part B (Fig. 15.9)

The second part of the algorithm focuses on those whose scan does not fit their clinical presentation. The most crucial and devastating etiology to miss is typically vascular in origin. Determination of onset is very important in the focal and generalized brain presentations given the fact that most treatments in regard to vascular compromise are time based. The vascular etiology that is concerning for the patient with generalized brain presentation is that of basilar artery occlusion, which can have variable initial symptoms and devastating outcomes.

To discover vascular etiologies, we need a thorough evaluation of the vascular supply of the brain including neck vasculature and origins of those arteries. The two

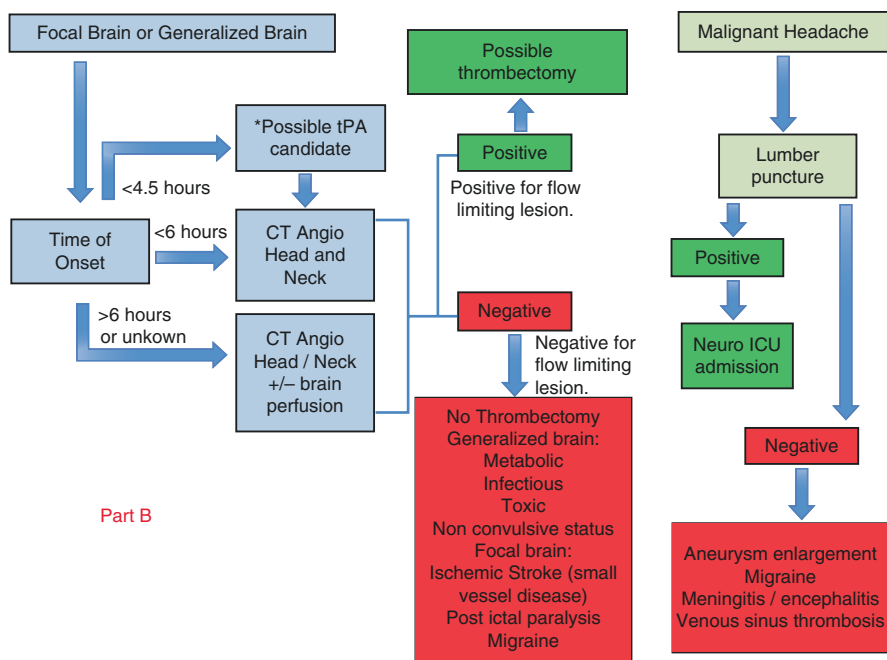


Fig. 15.9 Part B of the algorithm occurs when the initial imaging, in this case CT scan does not explain the patient's clinical presentation

modalities to consider are CT angiogram of the head and neck and MR angiogram of the head and neck. For simplicity, this algorithm uses CT angiogram because of accessibility at all times and speed at which it can be done.

Perfusion imaging may also play a role in decision-making for patients with neurological emergencies especially when ischemic injury is in the differential. These types of images can be obtained either with MR or CT. Because of accessibility and speed, we have focused on the use CT perfusion. Theoretically perfusion imaging allows us to evaluate the area of penumbra or brain tissue that remains salvageable.

Once a causative vascular lesion is ruled out, the initial patient presentation can help steer the differential diagnosis. The following cases highlight Part B (Fig. 15.9) of the algorithm.

Case Presentation 4

A 51-year-old Caucasian man who is a one-pack-per-day smoker and obese, with no primary care doctor, presents with witnessed acute onset of right-sided weakness and inability to speak while eating breakfast with family. He was brought in by

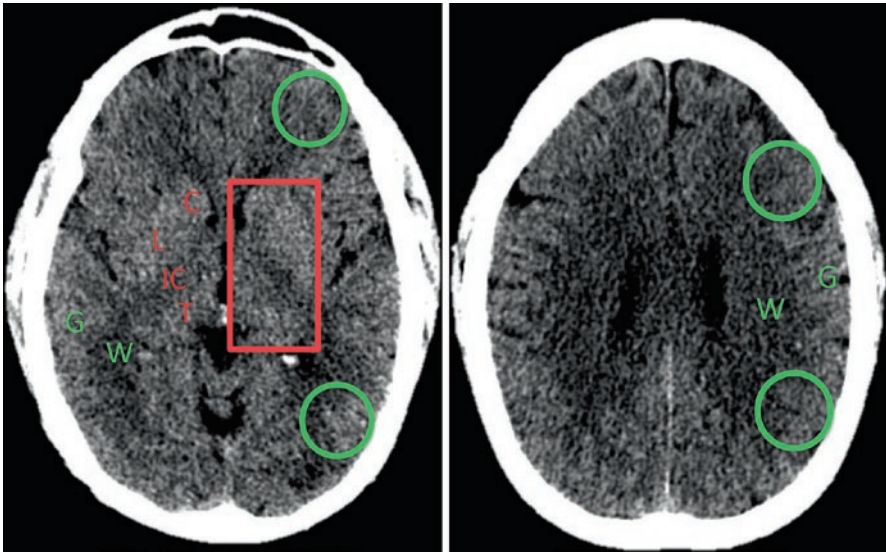


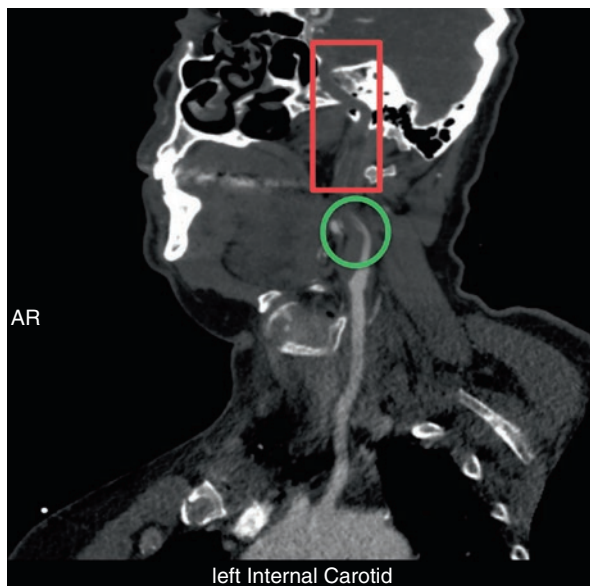
Fig. 15.10 Relevant axial non-contrast head CT images for Case 4. The images reveal normal appearing brain tissue. ASPECTS would be 10. *G* gray matter, *W* white matter, *C* caudate head, *L* lentiform nucleus, *I* insula, *IC* internal capsule, *T* thalamus. *Green circles* intact gray white differentiation, *red box* intact distinctions of the basal ganglia

EMS 45 min from onset. Vitals upon arrival to ED were temp 36.9C, BP 175/97, HR 87, RR 18, and pulse ox 100% on 2L NC. He is alert, with global aphasia; his eyes deviated to the left and do not blink to threat in the right temporal field; he has right hemiplegia and cannot sense being touched over the right arm and leg; and his NIHSS is 25. Labs show a normal platelet count and blood glucose. He is taken for emergent head CT (Fig. 15.10).

Following the algorithm the first step is to determine if the initial imaging helps explain the patients presentation. His CT scan looks normal (Fig. 15.11). His ASPECTS is 10. His presentation fits a focal brain presentation but is not explained by his CT scan. His time of last known normal is less than 3 hours. His presentation and exam findings are highly suggestive of ischemic injury, and he appears to be a candidate for intravenous thrombolysis. The next step is to quickly evaluate the vasculature of the head and neck. Unlike Case 2, where a hyperdense MCA was suggestive of an acute clot, the etiology of the neurological changes in Case 4 is not yet identified. A STAT CTA of his head and neck are then completed (Fig. 15.11).

CTA of his head and neck show that there is a possible ICA occlusion (green circle) and no apparent flow through the carotid in the skull (red box). Given his high NIHSS, high ASPECT score, short time from onset, and a large vessel occlusion, this patient is a intravenous thrombolytic candidate as well a thrombectomy candidate. He will require emergent neuro interventional consult and will ultimately require ICU admission.

Fig. 15.11 Oblique view of the left internal carotid artery via CT angiogram of the head and neck. The *green circle* is highlighting the loss of contrast opacification in the left internal carotid artery suggestive of occlusion and the *red box* is highlighting no contrast opacification within of the left internal carotid artery from the mid neck to the intracranial portion



Case Presentation 5

A 66-year-old Caucasian woman with history of HTN and previous sinus surgery 5 years ago presents from home with acute-onset headache which has been persistent for the last 3 days. The headache has been associated with nausea and vomiting and was preceded by subjective temperature elevations and fatigue. She has been taking over-the-counter pain medications, and her primary care doctor had started her on antibiotics for suspected sinus infection, neither of which has been helping. What was concerning to the family was that headache was unrelenting and she had started confusing her speech the day of presentation.

Her vitals in the ED were BP163/87, HR 105, RR 12, and Sat 98% RA. Her exam showed a woman that looked younger than stated age, normal heart and breath sounds, and GCS 13 (E3V4M6). Neurologically she would open her eyes to verbal stimulus but would drift back to sleep without stimulation. She would make intermittent paraphasic errors. There were no cranial nerve issues or appendicular weakness and no rashes noted. A STAT head CT without contrast was performed (Fig. 15.12).

Looking at the non contrasted head CT, there is a hyperdensity within the left sylvian fissure which is highly suggestive of an MCA aneurysm. The other things to note about the CT are that it is devoid of subarachnoid blood and no ventriculomegaly (not shown). Her presentation fits with a malignant headache presentation. Her initial head CT does have an obvious abnormality, which is likely an aneurysm but by itself does not fully explain the clinical signs that she is manifesting. Although the next step on the algorithm (Fig. 15.9) would be to pursue a lumbar puncture (LP) a CTA of the head (Fig. 15.12) was completed in the ED. It does confirm the left

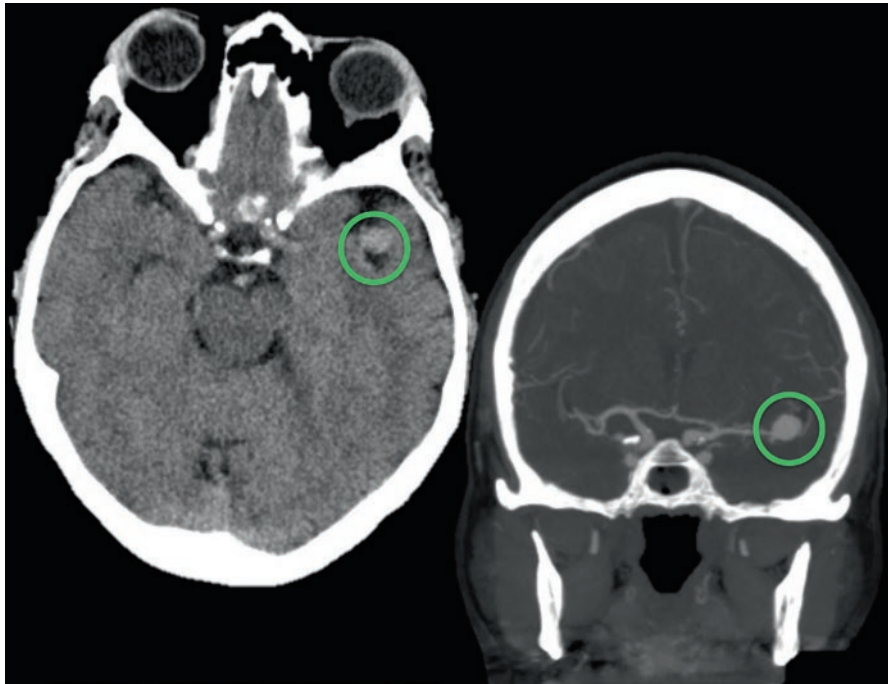


Fig. 15.12 Left side image is an axial image of a non contrasted head CT. A hyperdensity is noted with the left sylvian fissure and is likely to be an aneurysm (*green circle*). Right side image is a coronal image of a CT angiogram of the head which clearly identifies a sizeable left middle cerebral artery aneurysm (*green circle*)

MCA aneurysm but still has not given a further explanation of the patient's presentation.

The question remains: does her history fit with a ruptured aneurysm 3 days ago? The answer: possibly. The most efficient way of determining this is by doing a LP. A positive LP in the algorithm (Fig. 15.9) will identify blood and/or blood breakdown products in the CSF and help differentiate whether this aneurysm is an incidental finding. The rate of RBC change from tube 1 to 4 as well as the quantity of red cells in tube 4 has been shown to help differentiate true subarachnoid blood from a traumatic tap. The rate of increase of RBC roughly 60% is concerning, as well as a quantity of RBC >10,000 can be suggestive of true subarachnoid blood [14].

Blood breakdown products can be distinguished in two different ways: visual inspection for xanthochromia and spectrophotometry. The latter may provide higher sensitivity and specificity depending on timing of LP from ictus [15–17]. There remains debate about using lumbar puncture in excluding aneurysmal subarachnoid hemorrhage when the head CT is negative. The yield for LP within 6 h of onset, in the setting of negative head CT, will likely be low [18]. After 6 h the sensitivity of head CT decreases making the determination of blood being present more challenging. Irrespective of this, there remains potentially important information that can be

Table 15.2 Cerebrospinal fluid results. Pertinent for hypoglycorrhachia and lymphocytic pleocytosis

Test	Tube 1	Tube 4
RBC	105	77
WBC	923	1065
Lymphocytes	90%	93%
Glucose		33 (peripheral 108)
Protein		310

gathered from a lumbar puncture in patients with acute apoplectic headaches and unclear diagnosis.

Our patient's LP was negative for subarachnoid hemorrhage but suspicious for a meningoencephalitis (Table 15.2). This is likely viral, but given the hypoglycorrhachia (low glucose in the CSF) and recent antibiotics, a partially treated bacterial meningoencephalitis remains on the differential.

The aneurysm in this case is an incidental finding but still important. Because of the location and size of the aneurysm it will still require surgical intervention eventually, but her emergent management will be very different than if the aneurysm had been deemed ruptured. The LP remains an important diagnostic procedure and at times is the only way to determine if an aneurysm has ruptured. The information from the LP is also helpful in triaging patients. In this case if an LP was performed in the ED and the determination of the incidental nature of the aneurysm was made earlier then the patient may not have required ICU admission or emergent neurosurgical consultation.

Case Presentation 6

A 21-year-old Caucasian woman was in a motor vehicle accident in which she was struck from the rear of her car. She underwent a prolonged extrication. In the field she was noted to have a scalp laceration and a GCS of 3, with SBP in the 90s. She was intubated in the field and brought to the ED.

Upon arrival vitals were temp 37.8 C, BP 83/49, MAP 60, HR 105, RR 18, FiO2 40%, and Sat 98%. Her primary evaluation was remarkable for a bleeding scalp laceration over the occiput, minimal scrapes along arms and back, neck immobilized with a cervical collar, GCS 3T (E1, VT, M2) pupils equal and reactive, +corneal reflex, weak cough, and extensor posturing. Her labs were unremarkable except for an elevated WBC 16. She underwent emergent CT imaging. Non contrast head CT is shown in Figure 15.13. CT imaging of her chest, abdomen, pelvis and cervical spine were all negative.

In regard to her neurological findings, she would fit a global presentation. Her CT of the head (Fig. 15.13) shows either mild compression of some of the basal cisterns (orange arrow) or normal variant of a young and healthy brain. What definitively is seen are the few areas of hyperdensity in both the subarachnoid space and at the gray-white differentiation (blue arrows). The hyperdensities likely represent small areas of acute blood and likely contusion.

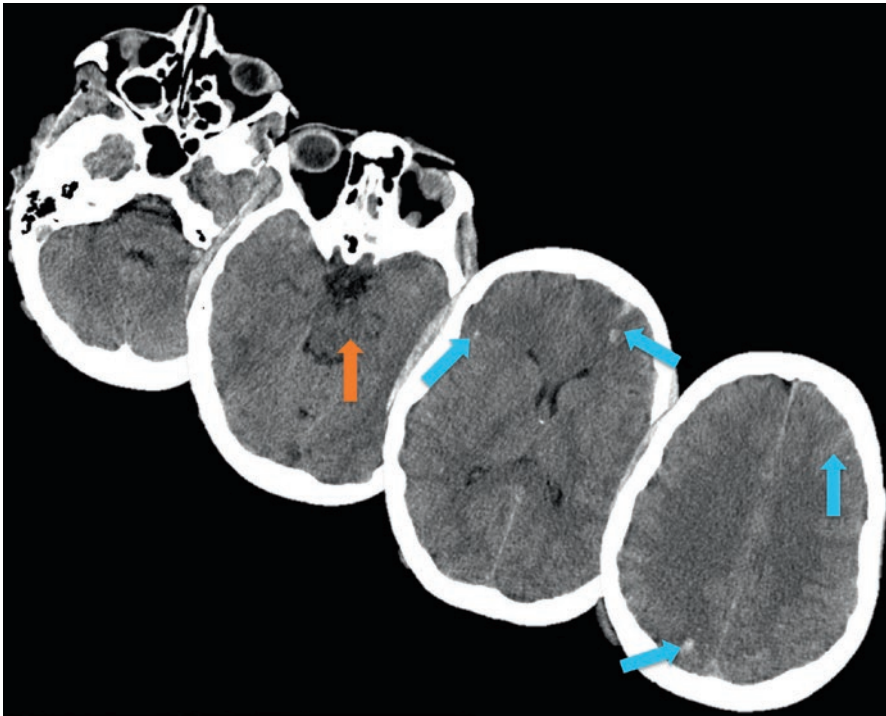


Fig. 15.13 Non contrasted axial CT of the head. Relevant findings are mild compression of the basal cisterns (*orange arrow*) and small areas of hyperdensity in the subarachnoid space and also intra parenchymal area suggestive of contusions

Although her initial head CT has some abnormalities, her neurological deficits are out of proportion to her CT findings. If we follow the algorithm it would place us in the area of considering tPA for acute ischemic stroke. Given the mechanism of the injury and the hyperdensities on CT thrombolytics are obviously contraindicated but there is a possibility of vascular injury of her head and neck can be contributing to her neurological deficits. In fact there are several issues that may be impacting her neurological function, including reduced cerebral perfusion pressure (CPP; $CPP = \text{Mean Arterial Pressure (MAP)} - \text{Intracranial Pressure (ICP)}$), diffuse axonal injury (DAI), and/or ischemia from vascular injury.

The latter type of injury tends to be rare but can be associated with a high level of morbidity and mortality if not found and treated accordingly. The best way of screening patients for blunt vascular injury is still debated, but studies suggest that 64 channel CTA can be used as a screening tool in patients with significant mechanism of injury [19–25]. This patient underwent CTA of the head and neck, which showed no abnormality.

While her CT findings were reported to be suggestive of diffuse axonal injury, CT is limited in accurately identifying diffuse axonal injury. The CT finding that directly correlates with the diagnosis of diffuse axonal injury made on MRI is the severity of intraventricular hemorrhage (IVH) [26, 27]. Our patient has no IVH on her initial head CT.

The most likely explanation of her discordant clinical findings and imaging results, which is always of concern in severe traumatic brain injury, is low CPP. This

concern makes hypotension and or elevated intracranial pressure a major issue in this patient. She needs resuscitation and, in parallel, neurosurgical evaluation for a means of determining her ICP [28]. An external ventricular drain was placed revealing an ICP of 32 mm Hg and hence a low CPP. She underwent aggressive resuscitation and some basic initial maneuvers to reduce ICP while in the ED. Her mean arterial pressure improved as did her ICP. She required ICU admission. Her MRI showed no evidence of DAI. She had a protracted ICU stay and was discharged to long term acute care facility and by 6 months from the accident was starting back at work.

Case Presentation 7

A 75-year-old African-American man with history of hypertension, hyperlipidemia, and atrial fibrillation on Coumadin presented with left-sided weakness and slurred speech. His wife found him after he fell out of bed. She states that the last time he was known to be normal was about 10 h before presentation.

Vitals are afebrile, heart rate is 105 bpm, BP is 175/90, respiratory rate is 18, and oxygen saturation is 95% on RA. His exam shows an NIHSS 18 for paralysis of the left face, arm, and leg; dysarthria; left visual field cut; and unable to identify his left arm. His labs are remarkable only for an INR 1.7. A STAT non contrasted head CT was completed and shown below (Fig. 15.14).

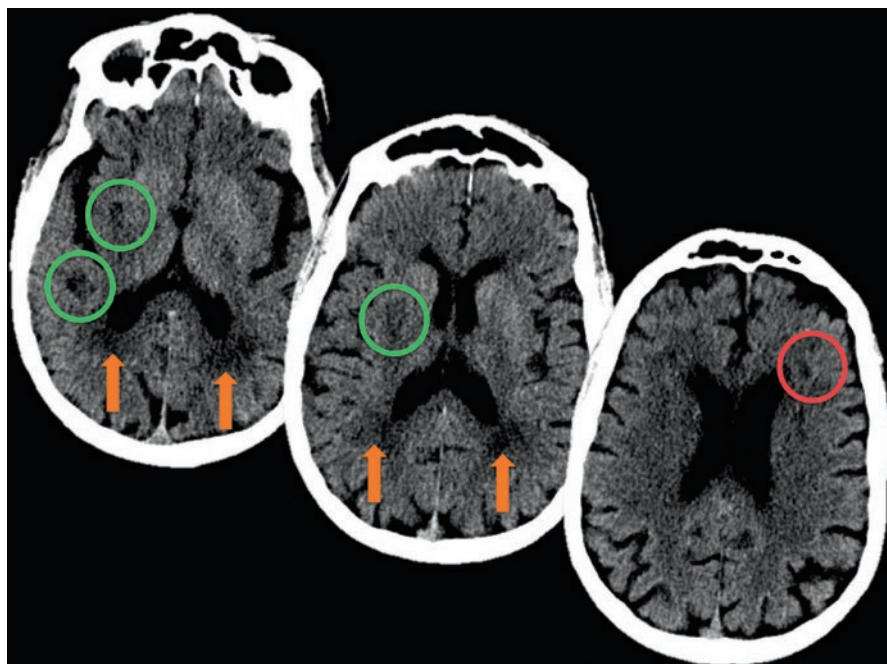
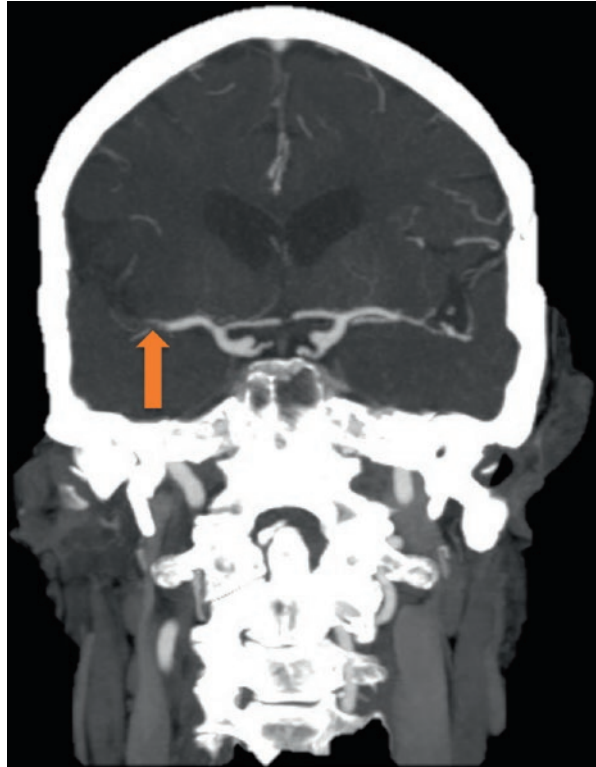


Fig. 15.14 Pertinent axial images of noncontrast head CT. *Orange arrows* highlight hypodensities around the lateral ventricles more prominently in the occipital horn areas. *Green circles* highlight hypodensities of unclear time in and surrounding the right basal ganglia. *Red circle* highlights hypodensities in the left frontal lobe, also of unclear timing

Fig. 15.15 Coronal image of a CTA of the head. *Orange arrow* identifies loss of flow in the proximal portion of the left MCA. Given the presentation this is likely to represent acute clot obstructing blood flow



His head CT is consistent with multiple changes old and new (Fig. 15.14). What we should be most concerned about are the changes in the right basal ganglia (green circles). It is hard to isolate time of these hypodensities in the right hemisphere especially in light of his microvascular changes (orange arrows) and other hypodensities seen in the left hemisphere (red circle). If we take the changes in his right hemisphere as being acute, his ASPECTS would be 8.

Although some abnormalities are identified on his head CT his clinical signs are not fully explained by the initial imaging. His exam is more consistent with a larger cortical injury given the visual field changes and neglect. There are several possible reasons for the discordance between his initial imaging and his neurological findings. Based on part B of the algorithm the two that require immediate determination are either he has likely suffered an ischemic stroke that is not obvious on this CT or his brain tissue is in a state of ischemia but has not yet gone on to complete infarction. He is outside the window for tPA and formal criteria for endovascular therapy. However, many endovascular centers consider patients with large vessel occlusion and potentially reversible ischemia, based on perfusion imaging, with longer time windows as candidates for thrombectomy. Given his high ASPECTS and high NIHSS, he underwent a CTA of his head and neck as well as a CT perfusion of his brain (Figs. 15.15 and 15.16).

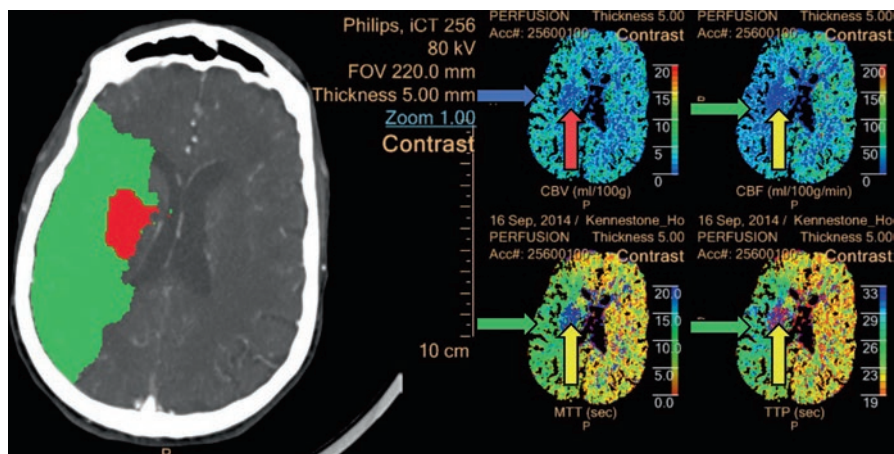


Fig. 15.16 Relevant images of CT perfusion of the head. Left image is a computer reconstruction of the images seen on the left. Green area suggests area of salvageable tissue or penumbra and the red area suggests the area that has already gone to infarction and represents core infarct. Images on the right clockwise starting on the upper left corner: (Cerebral blood volume (CBV), Cerebral blood flow (CBF), Time To Peak (TTP) and Mean Transit Time (MTT)). Core infarct is identified as increase in TTP, MTT and a decrease in CBF (yellow arrows) as well as a decrease in CBV (red arrow). Penumbra is shown with increased TTP, MTT and a decrease in CBF (green arrows) as well as a stable CBV (blue arrow)

The CTA (Fig. 15.15) identifies an occlusion of the right MCA (orange arrow). The reconstructed CT perfusion image (Fig. 15.16) on the left suggests that there may be a significant penumbral area (green area, consistent with tissue that is ischemic and causing symptoms but not yet infarcted). In comparison, the core infarct (red area, consistent with tissue that is infarcted and unsalvageable) in the right hemisphere is much smaller. The perfusion maps (on the right of the figure, clockwise starting in the upper left corner) represent cerebral blood volume (CBV in mL/100 g), cerebral blood flow (CBF in mL/100 g/min), time to peak (TTP in seconds), and mean transit time (MTT in seconds). These maps show a prolonged MTT and TTP, reduced CBF (yellow arrows), and a reduced CBV (red arrow) identifying the core infarct. The maps also show the penumbral area with prolonged TTP, MTT, and reduced CBF (green arrows) but a preserved CBV (blue arrows). This finding of a small core infarct but relatively large penumbra suggests that most of this patient's acute symptoms are from a large area of tissue that can be salvaged. It may suggest that reperfusion, via thrombectomy, can reestablish cerebral blood flow to still viable neuronal tissue.

The research for this particular patient population is still at the fledgling stage but does suggest that infarction growth is variable, allowing for some patients to have viable tissue even after 6 h, and perfusion imaging, either CT or MRI, may allow for identifying these patients [29–31]. At this time CT perfusion imaging is often used to help make clinical decisions regarding thrombectomy when a patient has a large vessel occlusion and severe symptoms, and timing of ictus is in question.

Case Presentation 8

A 64-year-old Caucasian man with obesity, hypertension, dyslipidemia, type 2 diabetes, and hepatitis C presented with acute onset of dizziness and vomiting. His family noted that he was not moving his right side which then became obtunded. He was brought into the ED via EMS 90 min after the confusion developed.

Vitals on arrival to the ED were temp 37.5C, HR 110, BP 135/92, RR 30, and pulse ox 85% on NRB. Exam showed an obese man with dark vomitus around his mouth, in respiratory distress with coarse breath sounds bilaterally, and a GCS of 7 (E1V1M5). Initially he would localize briskly on the left and withdraw on the right upper extremity, moving only to pain and not following commands or responding to questions. NIHSS was 17. Patient underwent emergent tracheal intubation and also had nasogastric tube placed for decompression of stomach contents which appeared coffee ground in character. Point-of-care labs were significant for a hemoglobin of 10 and INR of 1.8 but no previous hematology values to compare to. A STAT head CT was completed (Fig. 15.17).

His initial presentation is consistent with generalized brain dysfunction. Upon review of his head CT, it is apparent that the patient's exam is discordant with the CT. He may have some minimal changes in the left frontal lobe (green circle), but upon review of the entire CT, it is only on one slice, making it less likely an explanation for his neurological symptoms.

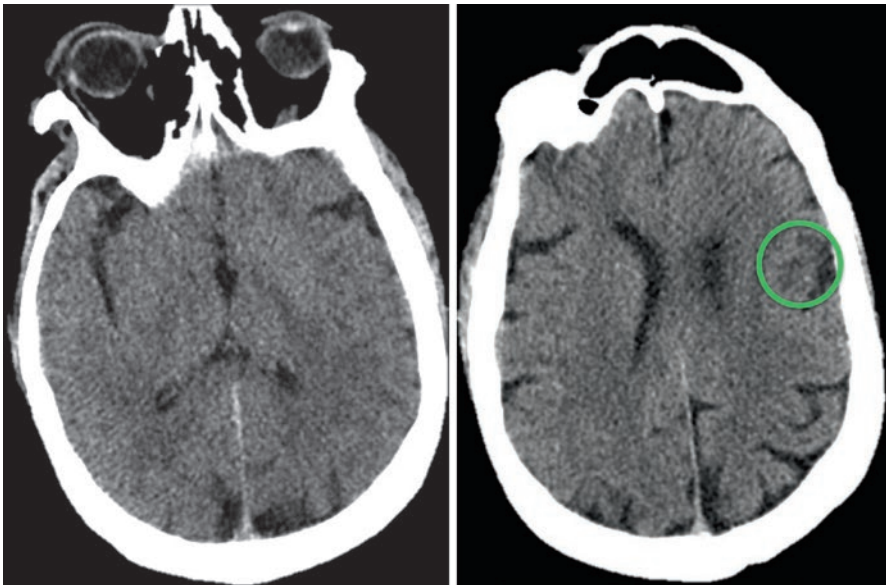


Fig. 15.17 Axial images of non contrasted head CT. *Green circle* highlights small area of hypodensity in the left frontal lobe. There are several possibilities as to the etiology of the hypodensity. None of which can explain the patient's presentation

His past medical history, initial dizziness and vomiting, and current poor level of consciousness can still suggest brain ischemia involving the basilar artery and could possibly be a candidate for thrombectomy. Based on his presentation and unremarkable head CT part B of the algorithm would suggest considering thrombolytics and possibly look for a large vessel occlusion. Patient is not an IV tPA candidate given the coffee-ground emesis and elevated INR. CTA of his head and neck was completed and showed no large vessel occlusion or flow limitation. This does not guarantee that patient has not had an ischemic stroke, but he is not a candidate for emergent intervention. Upon further workup he was found to have a hyperammonemia and elevated BUN, suggestive of hepatic encephalopathy in the setting of likely upper GI bleed.

Conclusion

The acutely neurological injured patient is highly dependent on rapid and accurate diagnosis, and medical imaging plays a significant role in determining this. No matter what modality of imaging is initially acquired (MRI or CT), the most important fact that needs to be reconciled is if the patient's radiographic findings explain their signs and symptoms. If this is not achieved, then further imaging should be pursued to identify possible etiologies that may require emergent intervention.

References

1. Hemphill JC, Greenberg SM, Anderson CS, Becker K, Bendok BR, Cushman M, Fung GL, Goldstein JN, Macdonald RL, Mitchell PH, Scott PA. Guidelines for the management of spontaneous intracerebral hemorrhage a guideline for healthcare professionals from the American Heart Association/American Stroke Association. *Stroke*. 2015;46(7):2032–60.
2. Jauch EC, Saver JL, Adams HP, Bruno A, Demaerschalk BM, Khatri P, McMullan PW, Qureshi AI, Rosenfield K, Scott PA, Summers DR. Guidelines for the early management of patients with acute ischemic stroke a guideline for healthcare professionals from the American Heart Association/American Stroke Association. *Stroke*. 2013;44(3):870–947.
3. Diringer MN, Bleck TP, Hemphill JC III, Menon D, Shutter L, Vespa P, Bruder N, Connolly ES Jr, Citerio G, Gress D, Hänggi D. Critical care management of patients following aneurysmal subarachnoid hemorrhage: recommendations from the Neurocritical Care Society's Multidisciplinary Consensus Conference. *Neurocrit Care*. 2011;15(2):211–40.
4. Connolly ES, Rabinstein AA, Carhuapoma JR, Derdeyn CP, Dion J, Higashida RT, Hoh BL, Kirkness CJ, Naidech AM, Ogilvy CS, Patel AB. Guidelines for the management of aneurysmal subarachnoid hemorrhage a guideline for healthcare professionals from the American Heart Association/American stroke association. *Stroke*. 2012;43(6):1711–37.
5. Bratton SL, Chestnut RM, Ghajar J, McConnell HF, Harris OA, Hartl R, Manley GT, Nemecek A, Newell DW, Rosenthal G, Schouten J. Guidelines for the management of severe traumatic brain injury. I. Blood pressure and oxygenation. *J Neurotrauma*. 2006;24:S7–13.
6. Powers WJ, Derdeyn CP, Biller J, Coffey CS, Hoh BL, Jauch EC, Johnston KC, Johnston SC, Khalessi AA, Kidwell CS, Meschia JF. 2015 American Heart Association/American Stroke Association focused update of the 2013 guidelines for the early management of patients with acute ischemic stroke regarding endovascular treatment a guideline for healthcare professionals from the American Heart Association/American Stroke Association. *Stroke*. 2015;46(10):3020–35.

7. Ropper AH. Lateral displacement of the brain and level of consciousness in patients with an acute hemispherical mass. *N Engl J Med.* 1986;314(15):953–8.
8. Soize S, Barbe C, Kadziolka K, Estrade L, Serre I, Pierot L. Predictive factors of outcome and hemorrhage after acute ischemic stroke treated by mechanical thrombectomy with a stent-retriever. *Neuroradiology.* 2013;55(8):977–87.
9. Barber PA, Demchuk AM, Zhang J, Buchan AM, ASPECTS Study Group. Validity and reliability of a quantitative computed tomography score in predicting outcome of hyperacute stroke before thrombolytic therapy. *Lancet.* 2000;355(9216):1670–4.
10. Alberta Health Services and University of Calgary, Understanding Alberta Stroke Program Early CT Score (ASPECTS), Cited July 2016. <http://www.aspectsinstroke.com>.
11. Mendelow AD, Gregson BA, Rowan EN, Murray GD, Gholkar A, Mitchell PM, STICH II Investigators. Early surgery versus initial conservative treatment in patients with spontaneous supratentorial lobar intracerebral haematomas (STICH II): a randomised trial. *Lancet.* 2013;382(9890):397–408.
12. Bullock MR, Chesnut R, Ghajar J, Gordon D, Hartl R, Newell DW. Surgical management of acute subdural hematomas. *Neurosurgery.* 2006;58(3 Suppl):S16–24.
13. Bullock MR, Chesnut R, Ghajar J, Gordon D, Hartl R, Newell DW, Servadei F, Walters BC, Wilberger JE. Surgical management of acute epidural hematomas. *Neurosurgery.* 2006;58(3):S2–7.
14. Czuczman AD, Thomas LE, Boulanger AB, Peak DA, Senecal EL, Brown DF, Marill KA. Interpreting red blood cells in lumbar puncture: distinguishing true subarachnoid hemorrhage from traumatic tap. *Acad Emerg Med.* 2013;20(3):247–56.
15. Petzold A, Keir G, Sharpe LT. Spectrophotometry for xanthochromia. *N Engl J Med.* 2004;351(16):1695–6.
16. Petzold A, Sharpe LT, Keir G. Spectrophotometry for cerebrospinal fluid pigment analysis. *Neurocrit Care.* 2006;4(2):153–62.
17. Nagy K, Skagervik I, Tumani H, Petzold A, Wick M, Kühn HJ, Uhr M, Regeniter A, Bretschneider J, Otto M, Kraus J. Cerebrospinal fluid analyses for the diagnosis of subarachnoid haemorrhage and experience from a Swedish study. What method is preferable when diagnosing a subarachnoid haemorrhage? *Clin Chem Lab Med.* 2013;51(11):2073–86.
18. Perry JJ, Stiell IG, Sivilotti ML, Bullard MJ, Émond M, Symington C, Sutherland J, Worster A, Hohl C, Lee JS, Eisenhauer MA. Sensitivity of computed tomography performed within six hours of onset of headache for diagnosis of subarachnoid haemorrhage: prospective cohort study. *BMJ.* 2011;343.
19. Harrigan MR, Weinberg JA, Peaks YS, Taylor SM, Cava LP, Richman J, Walters BC. Management of blunt extracranial traumatic cerebrovascular injury: a multidisciplinary survey of current practice. *World Journal of Emergency Surgery.* 2011;6(1):1.
20. Emmett KP, Fabian TC, DiCocco JM, Zarzaur BL, Croce MA. Improving the screening criteria for blunt cerebrovascular injury: the appropriate role for computed tomography angiography. *J Trauma Acute Care Surg.* 2011;70(5):1058–65.
21. Roberts DJ, Chaubey VP, Zygun DA, Lorenzetti D, Faris PD, Ball CG, Kirkpatrick AW, James MT. Diagnostic accuracy of computed tomographic angiography for blunt cerebrovascular injury detection in trauma patients: a systematic review and meta-analysis. *Ann Surg.* 2013;257(4):621–32.
22. Paulus EM, Fabian TC, Savage SA, Zarzaur BL, Botta V, Dutton W, Croce MA. Blunt cerebrovascular injury screening with 64-channel multidetector computed tomography: more slices finally cut it. *J Trauma Acute Care Surg.* 2014;76(2):279–85.
23. Bruns BR, Tesoriero R, Kufera J, Sliker C, Laser A, Scalea TM, Stein DM. Blunt cerebrovascular injury screening guidelines: what are we willing to miss? *J Trauma Acute Care Surg.* 2014;76(3):691–5.
24. Jacobson LE, Ziembra-Davis M, Herrera AJ. The limitations of using risk factors to screen for blunt cerebrovascular injuries: the harder you look, the more you find. *World Journal of Emergency Surgery.* 2015;10(1):1.
25. Shahan CP, Magnotti LJ, Stickley SM, Weinberg JA, Hendrick LE, Uhlmann RA, Schroepfel TJ, Hoit DA, Croce MA, Fabian TC. A safe and effective management strategy for blunt cere-

- brovascular injury: avoiding unnecessary anticoagulation and eliminating stroke. *J Trauma Acute Care Surg.* 2016;80(6):915–22.
26. Mata-Mbemba D, Mugikura S, Nakagawa A, Murata T, Kato Y, Tatewaki Y, Li L, Takase K, Ishii K, Kushimoto S, Tominaga T. Intraventricular hemorrhage on initial computed tomography as marker of diffuse axonal injury after traumatic brain injury. *J Neurotrauma.* 2015;32(5):359–65.
 27. Matsukawa H, Shinoda M, Fujii M, Takahashi O, Murakata A, Yamamoto D, Sumiyoshi S, Ishikawa R. Intraventricular hemorrhage on computed tomography and corpus callosum injury on magnetic resonance imaging in patients with isolated blunt traumatic brain injury: clinical article. *J Neurosurg.* 2012;117(2):334–9.
 28. Bratton SL, Chestnut RM, Ghajar J, McConnell HF, Harris OA, Hartl R, Manley GT, Nemecek A, Newell DW, Rosenthal G, Schouten J. Guidelines for the management of severe traumatic brain injury. IX. Cerebral perfusion thresholds. *J Neurotrauma.* 2006;24:S59–64.
 29. Lansberg MG, Straka M, Kemp S, Mlynash M, Wechsler LR, Jovin TG, Wilder MJ, Lutsep HL, Czartoski TJ, Bernstein RA, Chang CW. MRI profile and response to endovascular reperfusion after stroke (DEFUSE 2): a prospective cohort study. *The Lancet Neurology.* 2012;11(10):860–7.
 30. Lansberg MG, Cereda CW, Mlynash M, Mishra NK, Inoue M, Kemp S, Christensen S, Straka M, Zaharchuk G, Marks MP, Bammer R. Response to endovascular reperfusion is not time-dependent in patients with salvageable tissue. *Neurology.* 2015;85(8):708–14.
 31. Wheeler HM, Mlynash M, Inoue M, Tipirnini A, Liggins J, Bammer R, Lansberg MG, Kemp S, Zaharchuk G, Straka M, Albers GW. The growth rate of early DWI lesions is highly variable and associated with penumbral salvage and clinical outcomes following endovascular reperfusion. *Int J Stroke.* 2015;10(5):723–9.

Index

A

- Abducens (CN VI) nerves, 9
- Abducens nerve palsy, 139
- Absence seizures, 61
- Accessory nerve (CN XI), 11
- Acoustic nerve (CN VIII), 10
- Acute angle-closure glaucoma, 160
- Acute back pain, 176–179
 - differential diagnosis
 - metastatic involvement, 179
 - spinal cord, 176
 - spinal epidural abscess, 178
 - vascular catastrophe, 177
 - emergency department, 175, 183
 - history, 180
 - neuroimaging, 184–185
 - physical examination, 181–183
 - red flag signs, 180
- Acute brain dysfunction, 212
- Acute dystonia, 284
- Acute head injury, *see* Traumatic brain injury (TBI)
- Acute neck pain, 185–189
 - causes
 - cervical artery dissection, 186
 - cervical radiculopathy, 186
 - cervical strain, 185
 - meningitis, 186
 - disposition, 189–190
 - emergency department, 176, 185, 188
 - history, 187
 - neuroimaging
 - cervical arterial dissection, 188
 - cervical mass lesion, 189
 - cervical strain and radiculopathy, 188
 - CT, 188
 - meningitis, 189
 - MRI, 188
 - physical examination, 187
 - cervical cord compression, 188
 - cervical radiculopathy, 187
 - meningitis, 188
 - significant disease, 185
- Acute neurological injury, 289
- Acute vestibular syndrome (AVS)
 - cerebellar stroke, 114
 - counterintuitive, 114
 - definition, 111
 - features, 111
 - HINTS, 112
 - nystagmus, 112, 113
 - oculomotor physical findings, 113
 - physical examination, 112
 - posterior fossa strokes, 111
 - skew deviation, 113
 - vestibular neuritis, 111
- Acute vision loss, 129–131, 133–135
 - binocular visual loss
 - cerebral blindness, 135
 - migraine, 135
 - optic chiasm, 134
 - PRES, 135
 - case presentation, 127
 - eye emergence approach, 127–128
 - persistent monocular
 - acute angle-closure glaucoma, 131
 - CRAO, 129–130
 - CRVO, 130
 - ischemic optic neuropathy, 134
 - optic neuritis, 133
 - retinal detachment, 131
 - transient monocular, 128
- Adrenal insufficiency, 215
- AED, side effects and indicated labs, 71–72

- Altered mental status (AMS), 214–216,
219–227
definition, 211
differential diagnosis, 213, 222
infection, 215
metabolic abnormalities, 214–215
neurologic cause, 215
psychiatric cause, 216
toxin, 214
vital sign abnormalities, 214
vulnerability risk factors, 214
disposition, 227–228
ED, 209–211
history, 219
associated symptoms, 219
medications, 220
social, 220
surgical, 220
timing, 219
initial evaluation, 216
initial stabilization, 216–218
laboratory evaluation, 210, 224
BMP, 224
CBC, 224
ECG, 226
EEG, 226
endocrine studies, 225
LFTs, 224
lipase, 224
lumbar puncture, 225
radiography, 225
UDS, 225
urinalysis, 225
management, of combative patients,
218–219
medical cause, 216
neuroimaging, 226
CT angiography, 227
modalities and indications, 226
MRI, 227
non-contrast head CT, 226
physical examination
abdomen, 223
after first 5 min, 221
cardiopulmonary, 223
first 5 min, 220
genitourinary, 223
head, 222
neck, 222
neurologic, 223
skin, 223
precipitating factors, 213
vulnerability factors, 214
Amaurosis fugax, 128
American College of Emergency Physicians
(ACEP), 153
Amyotrophic lateral sclerosis (ALS), 247
Aseptic meningitis, 263
Athetosis, 279
Atonic seizures, 61
AVS, *see* Acute vestibular syndrome (AVS)
- B**
Ballismus, 279
Basic metabolic profile (BMP), 224
Benign intracranial hypertension, 159
Bicarbonate, 215
Binocular diplopia, 138
Binocular visual loss
cerebral blindness, 135
migraine, 135
optic chiasm, 134
PRES, 135
Blood urea nitrogen (BUN), 215
Botulism, 243–244
Brudzinski's sign, 188
- C**
Calcium, 215
Canadian Assessment of Tomography for
Childhood Injury (CATCH)
decision rule, 45
Canadian CT Head Rule (CCHR), 44, 46, 48
Carbamates, 245
Carbon monoxide poisoning, 161
Cauda equina syndrome, 176
Central nervous system (CNS), 257–261,
263–267
aseptic meningitis, 263
cerebral abscess, 267
clinical features, 267
imaging, 267
progression, 267
prophylaxis/treatment, 267
differential diagnosis, 252–254
disposition, 262
ED, 251
clinical investigations, 257
vital sign risk stratification, 257
encephalitis
causes, 263
clinical features, 264
imaging, 264
infection, 263
prevention, 265
rabies, 264

- treatment, 264
 - history, 254–255
 - malaria, 265
 - clinical features, 265
 - imaging, 266
 - laboratory test, 265
 - treatment, 266
 - meningitis
 - cause, 260
 - incidence, 260
 - treatment, 261
 - neuroimaging, 258
 - lumbar puncture, 258
 - neurocritical care management, 259
 - neurosyphilis, 266
 - physical examination, 252, 255–257
 - spinal epidural abscess, 268
 - treatment, 261–262
- Central retinal artery occlusion (CRAO), 129
- Central retinal vein occlusion (CRVO), 130
- Cerebral abscess, 267
 - clinical features, 267
 - progression, 267
- Cerebral blindness, 135
- Cerebral contusions, 41
- Cerebral venous sinus thrombosis (CVST), 156–157
- Cervical arterial dissection, 157, 186, 188
- Cervical neck pain, 157
- Cervical radiculopathy, 186, 187
- Cervical strain, 185
- Chest x-ray, 225
- Children’s Head Injury Algorithm for the Prediction of Important Clinical Events (CHALICE), 45
- Chorea, 279
- Cluster headache, 151–152
- Comatose, 212
- Complete blood count (CBC), 224
- Complex partial seizure, 61
- Computed tomography (CT)
 - cerebral abscess, 267
 - TBI, 50–51
 - headache, 154
- Computed tomography angiogram (CTA), 307
 - acute back pain, 185
 - AMS, 227
- Concurrent analgesia, 145
- Concussion, 42
- Conversion disorder, 198, 199
 - clinical investigation, 201
 - differential diagnosis, 196
 - disposition, 204
- ED workup, 201
- functional imaging, 202–204
- history, 196
- neuroimaging, 201–204
- physical examination, 197
 - co-contraction test, 199
 - Hoover’s sign, 198
 - motor testing, 199
 - sensory testing, 199
 - Sonoo abductor sign, 199
 - sternocleidomastoid test, 199
- principal presentations of, 197
- Convulsive seizures, 70
- Cortical algorithm, case study, 291–309
- Corticosteroids, 261
- Cranial nerve exam, 8
- CRAO, *see* central retinal artery occlusion (CRAO)
- CRVO, *see* Central retinal vein occlusion (CRVO)
- CTA, *see* Computed tomography angiogram (CTA)
- CVST, *see* Cerebral venous sinus thrombosis (CVST)
- D**
- Deep venous thrombosis (DVT), 156
- Delirium, 211–213
- Diffuse axonal injury (DAI), 42–43
- Diplopia
 - approach, 137–138
 - case presentation, 137
 - cranial nerve palsies, 138–140
 - orbital disease, 140
- Dizziness, 111–117, 120
 - ATTEST, 109–110
 - AVS, 111–115
 - overarching algorithm, 120
 - s-EVS, 117
 - t-EVS, 115–117
- case presentation, 103
- differential diagnosis, 104–105
- misdiagnosis, 104, 108, 109
- overarching algorithm, 120
- resource utilization, 108
- retrospective studies, 105
- risk factors, 106
- symptom quality, 106–108
- vestibular^a syndromes, 110
- Dural puncture headache, 161
- Dystonia, 284
- Dystonic storms, 284–286

E

- Eaton-Lambert syndrome (ELS), 243
- ECG, *see* Electrocardiogram (ECG)
- Echocardiogram, 97
- EEG, *see* Electroencephalography (EEG)
- Electrocardiogram (ECG), 93, 226
- Electroencephalography (EEG), 73, 226
- Electrolytes, 214–215
- ELS, *see* Eaton-Lambert syndrome (ELS)
- Emergency department (ED), 1
 - dizziness, 103
 - by EMS, 86
 - seizures, 69
 - syncope, 91
 - TBI, 39
- Emergency medical services (EMS), 86
- Emergent initial therapy, 76–77
- Encephalitis, 158
 - causes, 263
 - clinical features, 264
 - imaging, 264
 - infection, 263
 - rabies, 264
 - treatment, 264
- Endotracheal intubation (ETI), 78
- Epidural abscess, 178
- Epidural hematomas (EPH), 41, 42
- Epilepsy, 60
- European Society of Cardiology, 93
- Exudative retinal detachment, 131

F

- Facial nerve (CN VII), 10
- False localizing signs, 6
- Familial periodic paralyses, 244
- Focal brain presentation, 290
- Focal localizing signs, 6
- Focal seizures, 61

G

- GBS, *see* Guillain-Barré syndrome (GBS)
- Generalized brain presentation, 290
- Generalized seizures, 61
- Generalized tonic-clonic seizures (GTC), 61
- Giant cell arteritis (GCA), 157
- Glasgow Coma Scale, 2, 3
- Glasgow Coma Score (GCS), 40
- Glossopharyngeal (CN IX), 10
- Glucose, 214
- Guillain-Barré syndrome (GBS), 241

H

- Head impulse test, 10
- Headache, 150–162, 165–167
 - causes, 143, 144
 - clinical investigations, 162–164
 - concurrent analgesia, 145
 - differential diagnosis
 - primary headache disorders, 150–152
 - secondary headache disorders, 150–162
 - emergency department, 143
 - history, 145–147
 - neuroimaging
 - disposition, 166
 - indications and caveats, 165
 - treatment, 166–167
 - pathological etiology, 147
 - physical examination, 147
 - red flags, 146
- Hemichorea-hemiballismus (HH), 279
- Hepatic encephalopathy, 215
- Hoover's sign, 198
- Horizontal diplopia, 138
- Hydrocephalus, 158–159
- Hyperekplexia sudden death, 283
- Hypertension, 26
- Hypertensive headache, 158
- Hyperthyroidism, 215
- Hypoglossal nerve (CN XII), 11
- Hypothyroidism, 215

I

- Idiopathic intracranial hypertension, 159–160
- Idiopathic orbital inflammation, 140
- International Headache Society, 152
- International League Against Epilepsy (ILAE), 60
- Intracranial hemorrhage, 40
- Intramuscular ketamine, 218
- Intraparenchymal hemorrhage, 41
- Intravenous immunoglobulins (IVIG), 241
- Ischemic optic neuropathy, 134

K

- Kernig's sign, 188

L

- Levetiracetam, 77
- Liver function tests (LFT), 224
- Los Angeles Motor Scale (LAMS), 3
- Lou Gehrig's disease, 247
- Lower motor neurons (LMNs), 236
- Lumbar puncture (LP), 72

M

- Magnetic resonance imaging (MRI)
 - acute back pain, 184
 - AMS, 227
 - cerebral abscess, 267
 - TBI, 51
- Malaria, 265
 - clinical features, 265
 - imaging, 266
 - laboratory test, 265
 - treatment, 266
- Malignant catatonia (MC), 278
- Malignant headache presentation, 290
- Manual distraction test, 187
- Meningitis, 161–162
 - acute neck pain, 186, 188, 189
 - CNS, 260
- Metabolic perturbations, 20
- Migraine, 64, 135
- Migraine headache, 151
- Monocular diplopia, 138
- Movement disorders, 64, 272, 274, 278, 279, 281–284, 286
 - classification, 272
 - emergency department, 271
 - hyperkinetic emergencies
 - acute dystonia, 284
 - chorea, athetosis, and ballismus, 279
 - dystonic storm and status dystonicus, 284
 - hyperekplexia sudden death, 283
 - myoclonus, 281
 - OGC, 286
 - serotonin syndrome, 279
 - tardive dyskinesias, 282
 - tics, 283
 - hypokinetic emergencies
 - acute parkinsonism, 272
 - MC, 278
 - MSA, 278
 - NMS, 274
 - parkinsonism hyperpyrexia syndrome, 278
- MRI, *see* Magnetic resonance imaging (MRI)
- Multiple system atrophy (MSA), 278
- Myasthenia gravis, 140
- Myasthenia gravis (MG), 241–243
- Myoclonic epilepsy, 61
- Myoclonus, 281–282

N

- National Institutes of Health Stroke Scale (NIHSS), 3, 4
- Neurocritical Care Society (NCS) 2012 guidelines, 75

- Neuroleptic malignant syndrome (NMS), 274
- Neurological examination, 7–12, 290
 - clinical practice, 13–14
 - complaints, 2
 - emergency department, 1
 - history, 5–7
 - initial assessment, 2–5
 - principles, 1–2
 - screening, 7
 - coordination and gait, 12
 - cranial nerve, 8–11
 - higher cortical function, 7–8
 - mental status, 7
 - motor function, 11–12
 - reflexes, 12
 - sensory function, 11
- Neurosyphilis, 266–267
- New Orleans Criteria (NOC), 44
- NHAMCS study, 104
- NIH Stroke Scale (NIHSS), 23
- Nonconvulsive status epilepticus (NCSE), 226
- Nystagmus, 9

O

- Oculogyric crisis (OGC), 286
- Oculomotor (CN III), 9
- Oculomotor nerve palsy, 139
- Optic chiasm, 134
- Optic nerve (CN II), 8
- Optic neuritis, 133–134
- Orbital disease, 140
- Orbital neoplasm, 140
- Organophosphates (OP), 245–246
- Orthostatic hypotension, 116
- Oxford scale, 12

P

- Parkinsonism, 272–275
- Parkinsonism hyperpyrexia syndrome, 278
- Partial status epilepticus, 78
- PCS, *see* Post-concussion syndrome (PCS)
- Pediatric Emergency Care Applied Research Network (PECARN), 46
- Pentobarbital, 78
- Perfusion imaging, 31
- Persistent monocular vision loss
 - acute angle-closure glaucoma, 131–133
 - CRAO, 129, 130
 - ischemic optic neuropathy, 134
 - optic neuritis, 133
 - retinal detachment, 131–132
- Pituitary apoplexy, 158

- Poliovirus, 245
 Polymerase chain reaction (PCR)
 amplification, 245
 Polypharmacy, 88
 Post-concussion syndrome (PCS), 51–53
 Posterior reversible encephalopathy syndrome (PRES), 135
 Pralidoxime, 246
 Presyncope, 63
 Primary headache disorders
 cluster headache, 151
 migraine headache, 151
 tension-type headache, 151
 Propofol, 50
 Provoked seizures, 61
 Pseudoseizures, 63
 Pseudotumor cerebri, 159
 Psychogenic non-epileptic seizures (PNES), 63
 Psychogenic syndromes, *see* Conversion disorder
- R**
 Rabies encephalitis, 264
 Radiculopathy, 188
 Recombinant tissue plasminogen activator (rtPA), 32–35
 Reflex syncope, 118
 Refractory status epilepticus (RSE), 62, 78
 Retinal detachment, 131
 Rhegmatogenous retinal detachment, 131
 Rigidity, 238
 RSE, *see* refractory status epilepticus (RSE)
 rtPA, *see* Recombinant tissue plasminogen activator (rtPA)
 Ruptured abdominal aortic aneurysm (rAAA), 177
- S**
 Secondary headache disorders, 152–161
 nonvascular/intracranial etiology
 acute angle-closure glaucoma, 160
 carbon monoxide poisoning, 161
 dural puncture headache, 161
 hydrocephalus, 158
 idiopathic intracranial hypertension, 159
 meningitis, 161
 space-occupying lesion, 159
 vascular etiology
 cervical artery dissection, 157
 CVST, 156
 giant cell arteritis, 157
 hypertensive headache/encephalitis, 158
 pituitary apoplexy, 158
 subarachnoid hemorrhage, 152–154
 subdural hematomas, 154–155
- Seizures, 60, 75, 76, 98
 classification, 60
 clinical symptoms and presentation, 60
 differential diagnosis, 62–64
 EEG, 73, 74, 98
 emergency department workup, 69–70
 emergent initial therapy, 76
 ETI, 78
 first-time, 73–75
 history, 64
 loss of consciousness, 61
 neuroimaging, 70–73
 physical examination, 68–69
 safety counseling, 81–82
 SE
 pharmacological management, 75
 pharmacological treatment, 76
 triggers, 66
 urgent control therapy, 77
 Serotonin syndrome, 279–281
 s-EVS, *see* Spontaneous episodic vestibular syndrome (s-EVS)
 Shy-Drager syndrome, 278
 Simple partial seizure, 61
 Skull fractures, 43–45
 Sleep disorders, 64
 Sodium, 214
 Sonoabductor sign, 199
 Spasticity, 238
 Spinal cord compression, 184
 Spinal epidural abscess, 268
 Spontaneous episodic vestibular syndrome (s-EVS), 117–119
 Spurling maneuver, 187
 Status dystonicus, 285
 Status epilepticus (SE), 62
 pharmacological management, 75
 pharmacological treatment, 76
 Stretch reflexes, 12
 Stroke, 63
 algorithm, 19
 blood pressure parameters, 27
 clinical investigations, 27–28
 definition, 18
 differential diagnosis, 18, 22
 disposition, 35–36
 ED workup, 25–27
 history, 21–23
 immediate diagnostic studies, 33
 neuroimaging, 28–32
 physical examination, 23–24

recognition and severity assessment tools, 3
 Stroke chameleons, 19
 Stroke mimics, 19, 20
 Stupor, 211
 Subarachnoid hemorrhage (SAH)
 ACEP clinical guidelines, 153
 description, 152
 diagnostic considerations, for workup,
 153–154
 features, 152
 genetic factors, 153
 Subdural hematomas (SDH), 40, 41, 154
 Syncope, 63, 87–91
 clinical investigation, 92–97
 differential diagnosis
 cardiac causes, 87, 88
 historical features, 89–90
 imitators, 88–89
 neurocardiogenic-mediated, 87
 neurologic causes, 88–89
 physical examination, 90–91
 disposition, 98–99
 ED workup, 91–92
 neuroimaging, 97–98

T

Tardive dyskinesias, 282–283
 TBI, *see* Traumatic brain injury (TBI)
 Telemetry, 96
 Tension-type headache, 151
 t-EVS, *see* Triggered episodic vestibular
 syndrome (t-EVS)
 Tick paralysis, 246
 Tics status, 283
 Tractional retinal detachment, 131
 Transient global amnesia (TGA), 63–64
 Transient ischemic attack (TIA), 19, 63, 135
 Transverse myelitis, 246
 Traumatic brain injury (TBI), 40–43, 50–52
 case presentation, 39
 clinical investigations, 50
 differential diagnosis
 cerebral contusions, 41
 concussion, 42
 DAI, 42
 delayed intracranial bleed, 43
 EPH, 41, 42
 intracranial hemorrhage, 40
 intraparenchymal hemorrhage, 41
 SDH, 40, 41
 skull fractures, 43
 subarachnoid hemorrhage, 41
 disposition, 53
 emergency department workup, 46–49

neuroimaging
 CT, 50
 MRI, 51–52
 PCS, 51
 pediatric population, 45–46
 pediatrics, 49
 severity, 40
 treatment, 49–50
 Trigeminal nerve (CN V), 10
 Triggered episodic vestibular syndrome
 (t-EVS), 115–117
 Trochlear (CN IV), 9
 Trochlear nerve palsy, 139

U

Urgent control therapy, 77
 Urine drug screen (UDS), 225

V

Vagus (CN X) nerves, 10
 Vertebral artery dissection, 186
 Vertical diplopia, 138
 Viral meningitis, 161

W

Waddell's signs, 183, 184
 Weakness, 234–240
 acute life-threatening causes, 239
 ALS, 247
 botulism, 243
 cause, 234
 ED, 233
 management, 239–240
 ELS, 243
 familial periodic paralyses, 244
 GBS, 241
 history
 comorbidities, 235
 description, 234
 family, 235
 medications, 235
 onset, 234
 MG, 241
 organophosphate and carbamate poisoning,
 245
 physical examination
 elements of motor, 238
 motor nervous system, 236–238
 poliovirus, 245
 prospective observational study, 233
 tick paralysis, 246
 transverse myelitis, 246