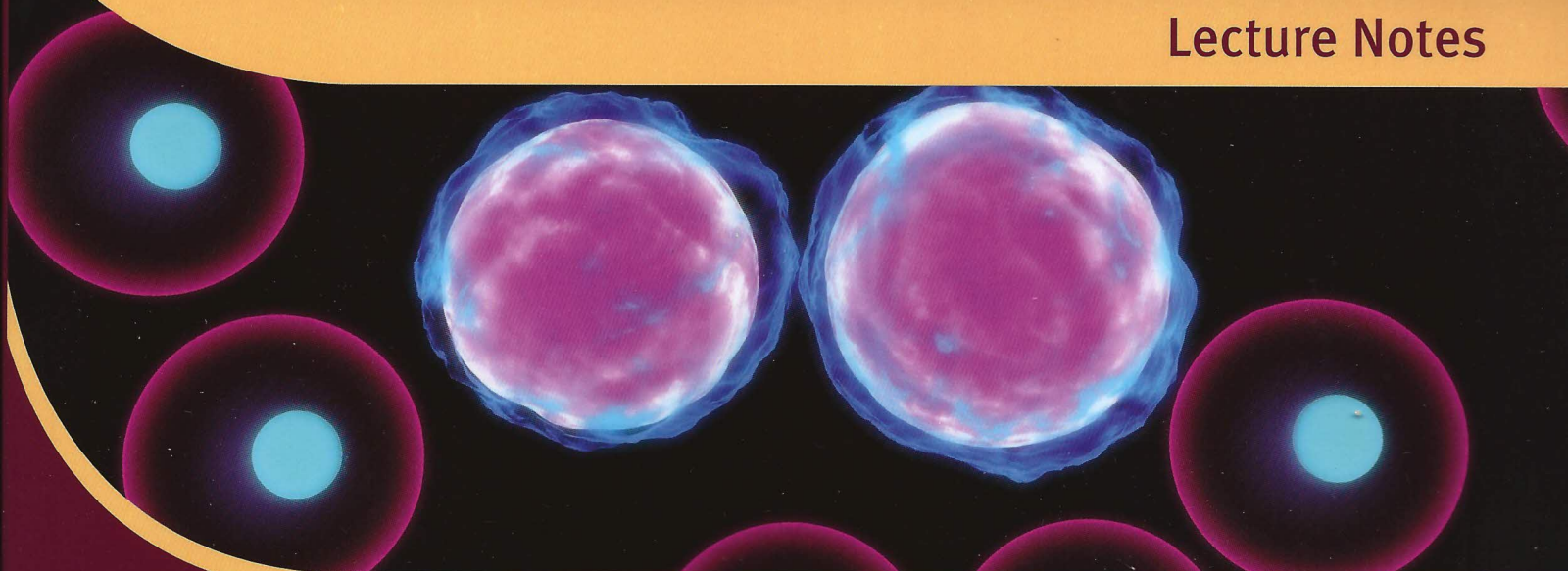


KAPLAN
MEDICAL

USMLE^{TM*} Step 1

Pathology

Lecture Notes





USMLE^{TM*} Step 1

Pathology

Lecture Notes

©2013 Kaplan, Inc.

All rights reserved. No part of this book may be reproduced in any form, by photostat, microfilm, xerography or any other means, or incorporated into any information retrieval system, electronic or mechanical, without the written permission of Kaplan, Inc.

Not for resale.

Authors

Henry Sanchez, M.D.
Professor of Clinical Pathology
University of California, San Francisco
San Francisco, CA

John Barone, M.D.
Anatomic and Clinical Pathologist
Beverly Hills, CA

Contributors

Michael S. Manley, M.D.
Department of Neurosciences
University of California, San Diego
Senior Director, Step 1 Curriculum
Kaplan Medical

Nancy Standler, M.D., Ph.D.
Department of Pathology
Valley View Medical Center
Intermountain Health Care

Contents

Preface	vii
Chapter 1: Fundamentals of Pathology	1
Chapter 2: Cellular Injury and Adaptation	5
Chapter 3: Inflammation	15
Chapter 4: Tissue Repair	25
Chapter 5: Circulatory Pathology	29
Chapter 6: Genetic Disorders	43
Chapter 7: Immunopathology	59
Chapter 8: Amyloidosis	69
Chapter 9: Principles of Neoplasia	73
Chapter 10: Environment- and Lifestyle-Related Pathology	83
Chapter 11: Skin Pathology	89
Chapter 12: Red Blood Cell Pathology: Anemias	97
Chapter 13: Vascular Pathology	109
Chapter 14: Cardiac Pathology	119
Chapter 15: Respiratory Pathology	131
Chapter 16: Renal Pathology	147
Chapter 17: Gastrointestinal Tract Pathology	163
Chapter 18: Pancreatic Pathology	177
Chapter 19: Gallbladder and Biliary Tract Pathology	183

Chapter 20: Liver Pathology	187
Chapter 21: Central Nervous System Pathology	197
Chapter 22: Hematopoetic Pathology–White Blood Cell Disorders & Lymphoid and Myeloid Neoplasms	219
Chapter 23: Female Genital Pathology	233
Chapter 24: Breast Pathology	241
Chapter 25: Male Pathology	247
Chapter 26: Endocrine Pathology	253
Chapter 27: Bone Pathology	261
Chapter 28: Joint Pathology	271
Chapter 29: Skeletal Muscle and Peripheral Nerve Pathology	277
Index	283

Preface

These 7 volumes of Lecture Notes represent the most-likely-to-be-tested material on the current USMLE Step 1 exam. Please note that these are Lecture Notes, not review books. The Notes were designed to be accompanied by faculty lectures—live, on video, or on the web. Reading them without accessing the accompanying lectures is not an effective way to review for the USMLE.

To maximize the effectiveness of these Notes, annotate them as you listen to lectures. To facilitate this process, we've created wide, blank margins. While these margins are occasionally punctuated by faculty high-yield “margin notes,” they are, for the most part, left blank for your notations.

Many students find that previewing the Notes prior to the lecture is a very effective way to prepare for class. This allows you to anticipate the areas where you'll need to pay particular attention. It also affords you the opportunity to map out how the information is going to be presented and what sort of study aids (charts, diagrams, etc.) you might want to add. This strategy works regardless of whether you're attending a live lecture or watching one on video or the web.

Finally, we want to hear what you think. What do you like about the Notes? What could be improved? Please share your feedback by e-mailing us at medfeedback@kaplan.com.

Thank you for joining Kaplan Medical, and best of luck on your Step 1 exam!

Kaplan Medical

Fundamentals of Pathology

1

DEFINITIONS OF PATHOLOGY

1. The study of the essential nature of disease, including symptoms/signs, pathogenesis, complications, and morphologic consequences including structural and functional alterations in cells, tissues, and organs.
2. The study of all aspects of the disease process focusing on the pathogenesis leading to classical structural changes (gross and histopathology) as well as molecular alterations.

OVERVIEW OF PATHOLOGY

1. The **etiology** (cause) of a disease may be genetic or acquired.
2. The **pathogenesis** of a disease defines the temporal sequence and the patterns of cellular injury that lead to disease.
3. **Morphologic** changes of the disease process include both gross changes and microscopic changes.
4. The **clinical significance** of a disease relates to its signs and symptoms, disease course including complications, and prognosis.

METHODS USED IN PATHOLOGY

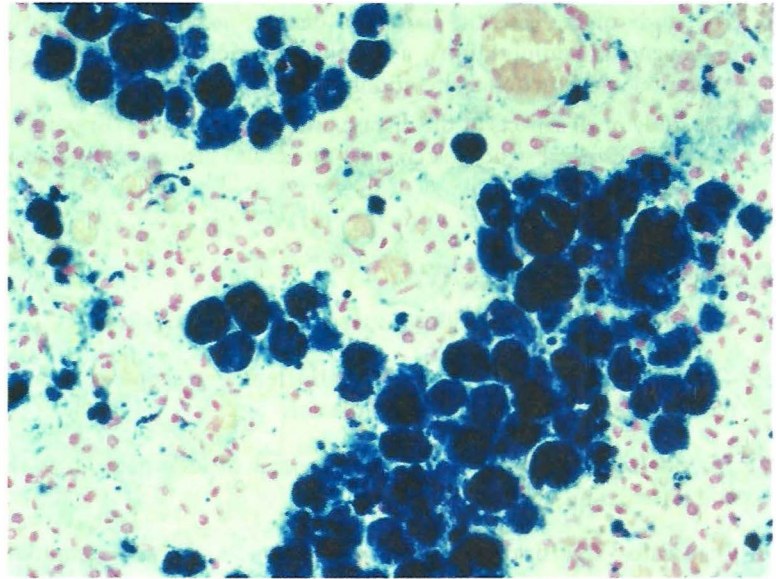
1. **Gross examination** of organs on USMLE questions has two major components: identifying the organ and identifying the pathology. Useful gross features include size, shape, consistency, and color.
2. **Microscopic examination** of tissue
 - a. In light microscopic examination of tissue, **hematoxylin and eosin (H&E)** is considered the gold standard stain and is used routinely in the initial microscopic examination of pathologic specimens.

Table 1-1. Structures Stained by Hematoxylin and Eosin

Hematoxylin	Eosin
Stains blue to purple	Stains pink to red
<ul style="list-style-type: none">● Nuclei	<ul style="list-style-type: none">● Cytoplasm
<ul style="list-style-type: none">● Nucleoli	<ul style="list-style-type: none">● Collagen
<ul style="list-style-type: none">● Bacteria	<ul style="list-style-type: none">● Fibrin
<ul style="list-style-type: none">● Calcium	<ul style="list-style-type: none">● RBCs
<ul style="list-style-type: none">● Many others	<ul style="list-style-type: none">● Thyroid colloid
	<ul style="list-style-type: none">● Many others

The common denominator of the features shown in Table 1-1 is that hematoxylin binds nucleic acids and calcium salts, while eosin stains the majority of proteins (both extracellular and intracellular).

- b. **Other histochemical stains** (chemical reactions): Prussian blue (stains iron), Congo red (stains amyloid), acid fast (Ziehl-Neelson, Fite) (stains acid-fast bacilli), periodic acid-Schiff (PAS, stains high carbohydrate content molecules), Gram stain (stains bacteria), trichrome (stains cells and connective tissue), and reticulin (stains collagen type III molecules).



© Katsumi M. Miyai, M.D., Ph.D.; Regents of the University of California. Used with permission.

Figure 1-1. Prussian blue stain showing hemosiderin, which results from RBC breakdown within macrophages

- c. **Immunohistochemical (antibody) stains** include cytokeratin (stains epithelial cells), vimentin (stains cells of mesenchymal origin except the 3 muscle types; stains many sarcomas), desmin (stains smooth, cardiac, and skeletal myosin), prostate specific antigen, and many others.

3. Ancillary techniques

- a. **Immunofluorescence microscopy (IFM)** is typically used for renal and autoimmune disease.
- b. **Transmission electron microscopy (EM)** is typically used for renal disease, neoplasms, infections, and genetic disorders.

- 4. **Molecular techniques** include protein electrophoresis, Southern and Western blots, polymerase chain reaction (PCR), and cytogenetic analysis (karyotyping, in situ hybridization studies).

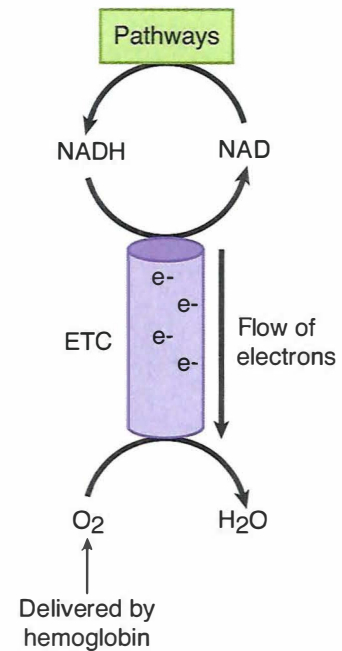
Chapter Summary

- Pathology is the study of disease and concerns itself with the etiology, pathogenesis, morphologic changes, and clinical significance of different diseases.
- Gross examination of organs involves identifying pathologic lesions by evaluating abnormalities of size, shape, consistency, and color.
- Tissue sections stained with hematoxylin (nucleic acids and calcium salts) and eosin (most proteins) are used for routine light microscopic examination.
- Additional techniques that are used to clarify diagnoses in particular settings include histochemical stains, immunohistochemical stains, immunofluorescence microscopy, transmission electron microscopy, and molecular techniques.

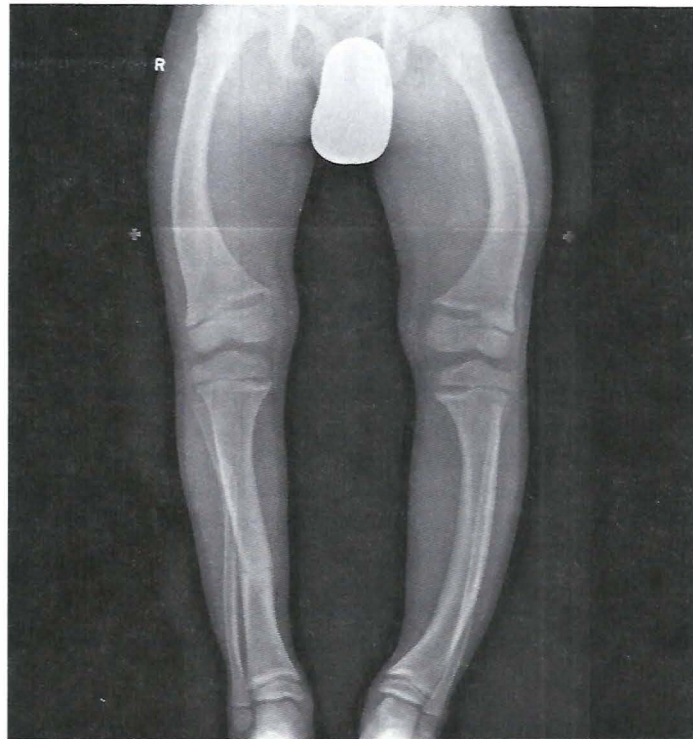CAUSES OF CELLULAR INJURY

1. **Hypoxia** is the most common cause of injury; it occurs when lack of oxygen prevents the cell from synthesizing sufficient ATP by aerobic oxidation. Major mechanisms leading to hypoxia are ischemia, cardiopulmonary failure, and decreased oxygen-carrying capacity of the blood (e.g., anemia). Ischemia, due to a loss of blood supply, is the most common cause of hypoxia, and is typically related to decreased arterial flow or decreased venous outflow (e.g., atherosclerosis, thrombus, thromboembolus).
2. **Infections** (viruses, bacteria, parasites, fungi, and prions) can injure the body by direct infection of cells, production of toxins, or host inflammatory response.
3. **Immunologic reactions** include hypersensitivity reactions and autoimmune diseases.
4. **Congenital disorders** are inherited genetic mutations (e.g., inborn errors of metabolism) [see Chapter 6 for a more detailed discussion of specific genetic disorders]).
5. **Chemical injury** can occur with drugs, poisons (cyanide, arsenic, mercury, etc.), pollution, occupational exposure (CCl_4 , asbestosis, carbon monoxide, etc.), and social/lifestyle choices (alcohol, cigarette smoking, intravenous drug abuse [IVDA], etc.)
6. **Physical forms of injury** include trauma (blunt/penetrating/crush injuries, gunshot wounds, etc.), burns, frostbite, radiation, and pressure changes.
7. **Nutritional or vitamin imbalance**
 - a. **Inadequate calorie/protein intake** can cause marasmus (decrease in total caloric intake), kwashiorkor (decrease in total protein intake), and anorexia nervosa.
 - b. **Excess caloric intake** can cause obesity (second leading cause of premature preventable death in the United States) and atherosclerosis.
 - c. **Vitamin deficiencies** can be seen with vitamin A (night blindness, squamous metaplasia, immune deficiency), vitamin C (scurvy), vitamin D (rickets and osteomalacia), vitamin K (bleeding diathesis), vitamin B12 (megaloblastic anemia, neuropathy, and spinal cord degeneration), folate (megaloblastic anemia and neural tube defects), and niacin (pellagra [diarrhea, dermatitis, and dementia]).
 - d. **Hypervitaminosis** is less commonly a problem.

Note



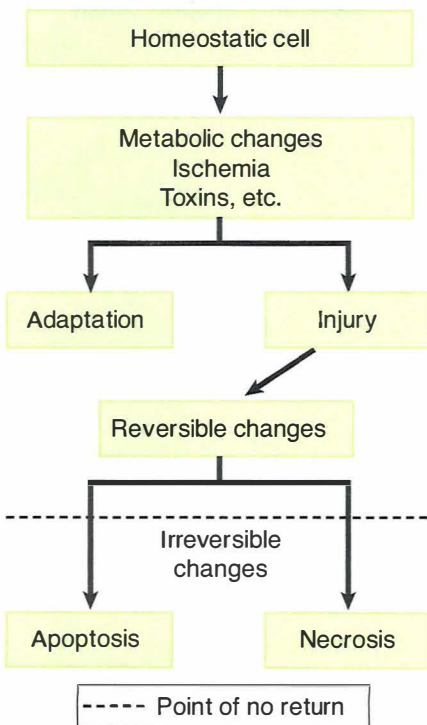
Overview of the Electron Transport Chain



Source: Dr. Angela Byrne, used with permission, Radiopaedia.org.

Figure 2-1. Lack of Vitamin D can cause impaired bone calcification, leading to rickets

In a Nutshell



CELLULAR CHANGES DURING INJURY

1. General

- a. Cellular responses to injury include adaptation, reversible injury, and irreversible injury and cell death (necrosis/apoptosis).

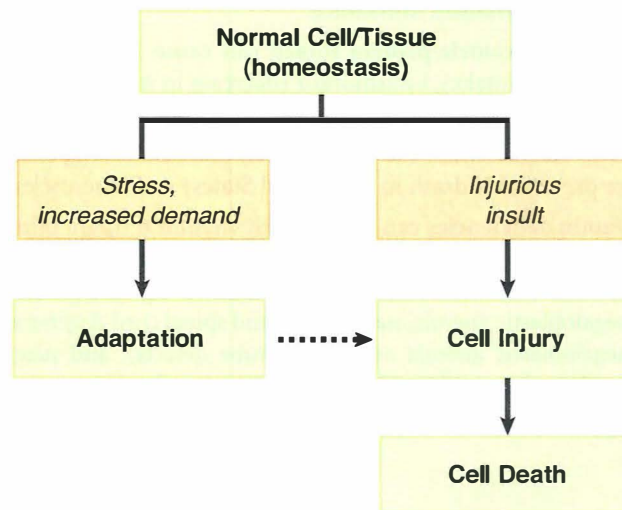


Figure 2-2. Cellular Response to Stress and Injurious Stimuli

- b. The **cellular response to injury depends on several important factors**, including the type of injury, duration (including pattern) of injury, severity and intensity of injury, type of cell injured, the cell's metabolic state, and the cell's ability to adapt.
- c. The **critical intracellular systems that are susceptible to injury** are DNA, production of ATP via aerobic respiration, cell membranes, and protein synthesis.
- d. **Important mechanisms of cell injury**
- Damage to DNA, proteins, lipid membranes, and circulating lipids (LDL) can be caused by oxygen-derived free radicals, including superoxide anion ($O_2^{\bullet -}$), hydroxyl radical (OH^{\bullet}), and hydrogen peroxide (H_2O_2).
 - ATP depletion: due to the cell's dependence on ATP, several important changes (damage to Na^+/K^+ pumps, to mitochondria, etc.) disrupt the production of ATP, which is then rapidly depleted by other cellular processes.
 - Increased cell membrane permeability: several defects can lead to movement of fluids into the cell, including formation of the membrane attack complex via complement, breakdown of Na^+/K^+ gradients (i.e., causing sodium to enter or potassium to leave the cell), etc.
 - Influx of calcium can cause problems because calcium is a second messenger, which can activate a wide spectrum of enzymes. These enzymes include proteases (protein breakdown), ATPases (contributes to ATP depletion), phospholipases (cell membrane injury), and endonucleases (DNA damage).
 - Mitochondrial dysfunction causes decreased oxidative phosphorylation and ATP production, formation of mitochondrial permeability transition (MPT) channels, and release of cytochrome c (a trigger for apoptosis).

Note

Protective Factors against Free Radicals

- Antioxidants
Vitamins A, E, and C
- Superoxide dismutase
Superoxide \rightarrow hydrogen peroxide
- Glutathione peroxidase
Hydroxyl ions or hydrogen peroxide \rightarrow water
- Catalase
Hydrogen peroxide \rightarrow oxygen and water

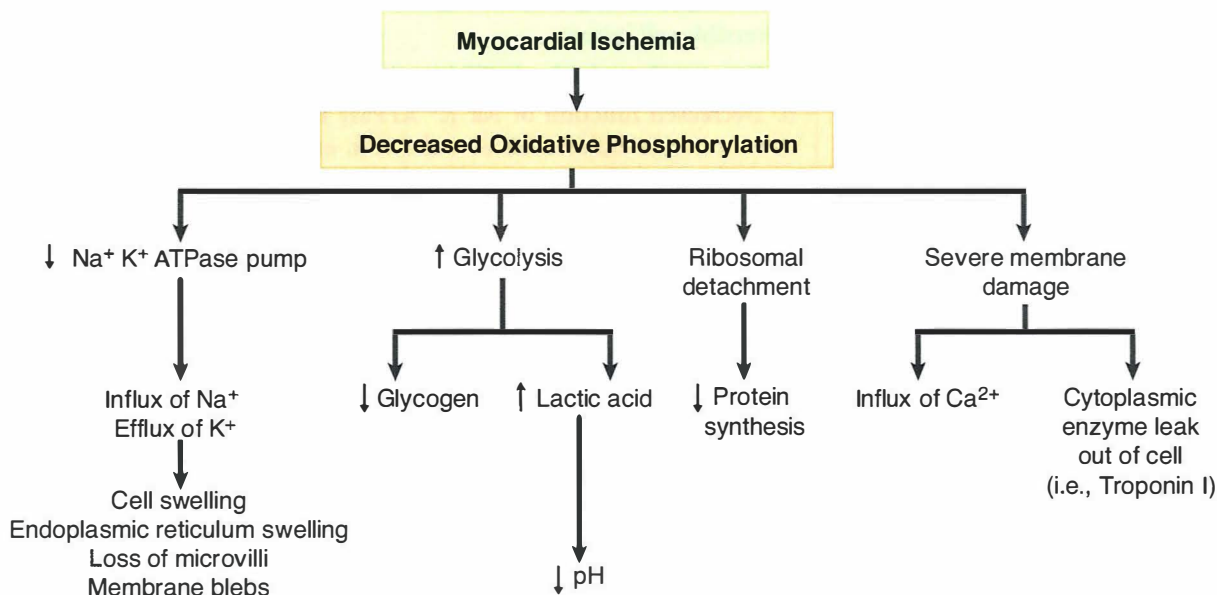


Figure 2-3. Classic Example of Cellular Injury Caused by Hypoxia

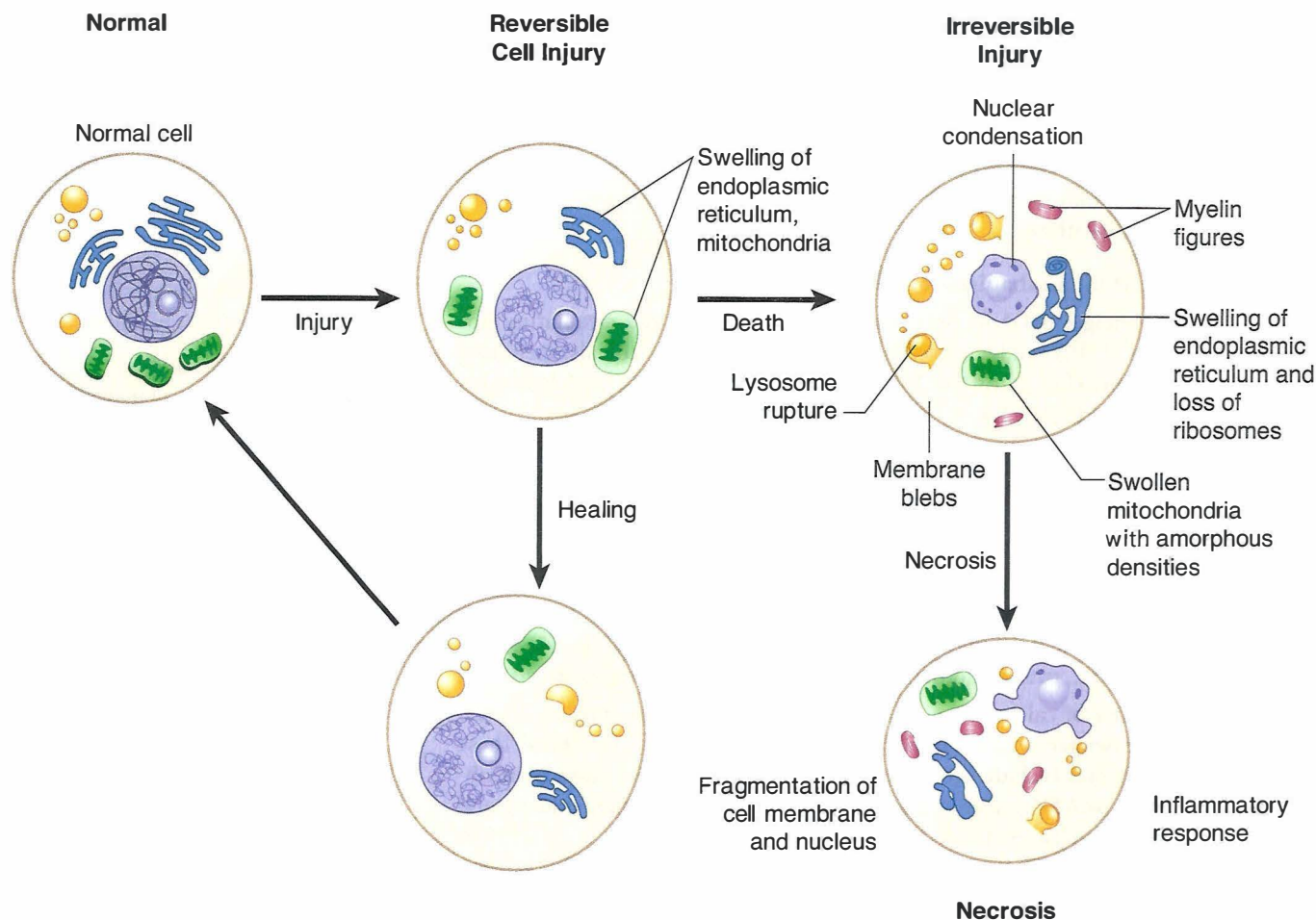


Figure 2-4. Cell Injury

Note

Reversible and irreversible changes represent a spectrum. Keep in mind that any of the reversible changes can become irreversible.

Clinical Correlate

The loss of membrane integrity (cell death) allows intracellular enzymes to leak out, which can then be measured in the blood. Detection of these proteins in the circulation serves as a clinical marker of cell death and organ injury. Clinically important examples:

- Myocardial injury: troponin (most specific), CPK-MB, lactate dehydrogenase (LDH)
- Hepatitis: transaminases
- Pancreatitis: amylase and lipase
- Biliary tract obstruction: alkaline phosphatase

2. Reversible cell injury

- a. **Decreased synthesis of ATP** by oxidative phosphorylation.
- b. **Decreased function of Na⁺K⁺ ATPase membrane pumps**, which in turn causes influx of Na⁺ and water, efflux of K⁺, cellular swelling (hydropic swelling), and swelling of the endoplasmic reticulum.
- c. The **switch to glycolysis** results in depletion of cytoplasmic glycogen, increased lactic acid production, and decreased intracellular pH.
- d. **Decreased protein synthesis** leads to detachment of ribosomes from the rough endoplasmic reticulum.
- e. **Plasma-membrane blebs and myelin figures** may be seen.

3. Irreversible cell injury

- a. **Severe membrane damage** plays a critical role in irreversible injury, allows a massive influx of calcium into the cell, and allows efflux of intracellular enzymes and proteins into the circulation.
- b. **Marked mitochondrial dysfunction** produces mitochondrial swelling, large densities seen within the mitochondrial matrix, irreparable damage of the oxidative phosphorylation pathway, and an inability to produce ATP.
- c. **Rupture of the lysosomes** causes release of lysosomal digestive enzymes into the cytosol and activation of acid hydrolases followed by autolysis.

- d. **Nuclear changes** (see figure below) can include pyknosis (degeneration and condensation of nuclear chromatin), karyorrhexis (nuclear fragmentation), and karyolysis (dissolution of the nucleus).

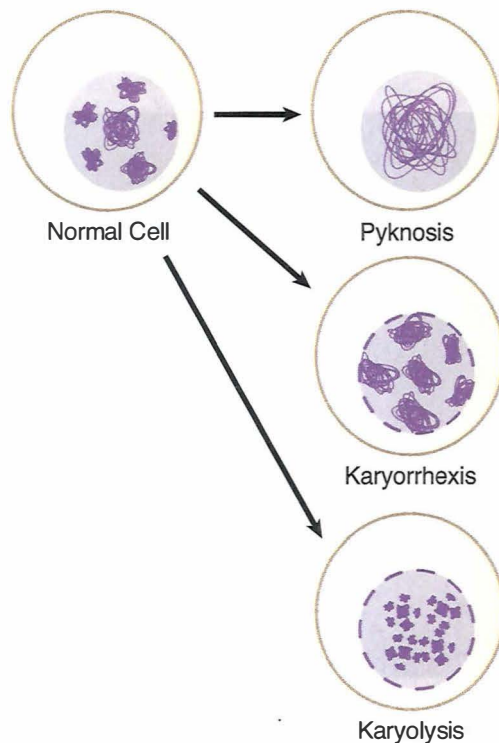


Figure 2-5. Nuclear Changes in Irreversible Cell Injury

CELL DEATH

1. **Morphologic types of necrosis (cell death in living tissue, often with an inflammatory response)**
 - a. **Coagulative necrosis**, the most common form of necrosis, is most often due to ischemic injury (infarct). It is caused by the denaturing and coagulation of proteins within the cytoplasm. Microscopic examination shows loss of the nucleus but preservation of cellular shape. Coagulative necrosis is common in most organs, including the heart, liver, and kidney.
 - b. **Liquefaction necrosis** results from cellular destruction by hydrolytic enzymes, leading to autolysis (release of proteolytic enzymes from injured cells) and heterolysis (release of proteolytic enzymes from inflammatory cells). Liquefaction necrosis occurs in abscesses, brain infarcts, and pancreatic necrosis.
 - c. **Caseous necrosis** is a combination of coagulation and liquefaction necrosis. The gross appearance is soft, friable, and “cottage cheese–like.” Caseous necrosis is characteristic of granulomatous diseases, including tuberculosis
 - d. **Fat necrosis** is caused by the action of lipases on adipocytes. On gross examination fat necrosis has a chalky white appearance.
 - e. **Fibrinoid necrosis** is a form of necrotic connective tissue that histologically resembles fibrin. On microscopic examination fibrinoid necrosis has an eosinophilic (pink) homogeneous appearance. It is often due to acute

Note

Liquefaction by leukocyte enzymes is called suppuration, and the resultant fluid is called pus.

Bridge to Biochemistry

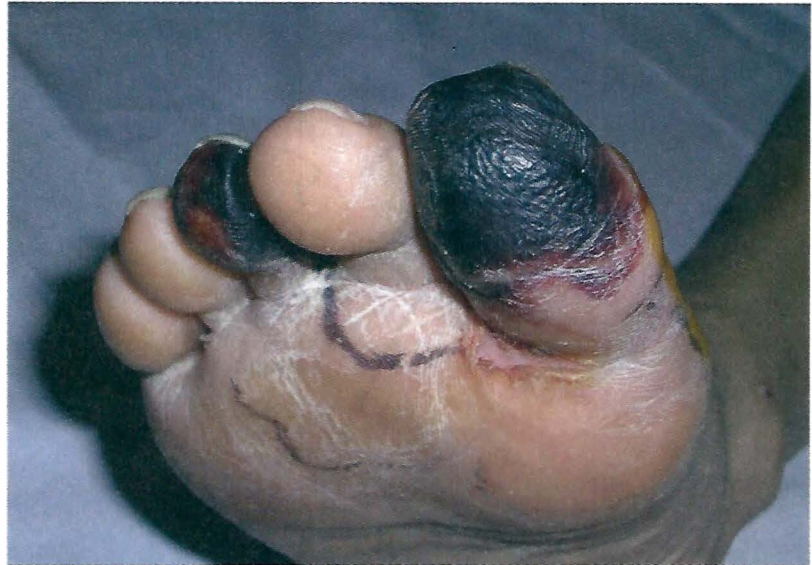Damage to fat cells releases triglycerides. The triglycerides are broken down by the action of lipases to fatty acids. The fatty acids may associate with calcium and form calcium soaps (saponification).

Note

Necrotic tissue within the body evokes an inflammatory response that removes the dead tissue and is followed by healing and tissue repair. Necrotic debris may also undergo dystrophic calcification.

immunologic injury (e.g., hypersensitivity type reactions II and III) and vascular hypertensive damage.

- f. **Gangrenous necrosis** is a gross term used to describe dead tissue. Common sites of involvement include lower limbs, gallbladder, GI tract, and testes. Dry gangrene has coagulative necrosis for the microscopic pattern, while wet gangrene has liquefactive necrosis.



© Richard P. Usatine, M.D. Used with permission.

Figure 2-6. Gangrenous necrosis affects the first and third toes of a diabetic foot.

Clinical Correlate

If the cells in the interdigital space fail to undergo apoptosis, the fetus will be born with webbed hands and/or webbed feet, a condition known as *syndactyly*. Another example is the hormone-dependent apoptosis prior to menstruation; this occurs as the body withdraws from estrogen and LH surges, signaling the endometrial cells to undergo apoptosis.

2. Apoptosis

- a. Apoptosis is a specialized form of programmed cell death without an inflammatory response. It is an active process regulated by genes and involves RNA and protein synthesis that often affects only single cells or small groups of cells.
- b. In **morphologic appearance**, the cell shrinks in size and has dense eosinophilic cytoplasm. Next, nuclear chromatin condensation is seen that is followed by fragmentation of the nucleus. Cytoplasmic membrane blebs form next, leading eventually to a breakdown of the cell into fragments (apoptotic bodies). Phagocytosis of apoptotic bodies is by adjacent cells or macrophages. There is characteristically a lack of an inflammatory response.
- c. **Stimuli for apoptosis** include cell injury and DNA damage, lack of hormones, cytokines, or growth factors, and receptor-ligand signals such as Fas binding to the Fas ligand and Tumor necrosis factor (TNF) binding to TNF receptor 1 (TNFR1).
- d. **Apoptosis is regulated by genes.** bcl-2 (which inhibits apoptosis) prevents release of cytochrome c from mitochondria and binds pro-apoptotic protease activating factor (Apaf-1). p53 (which stimulates apoptosis) is elevated by DNA injury and arrests the cell cycle. If DNA repair is impossible, p53 stimulates apoptosis.
- e. **Execution of apoptosis** is mediated by a cascade of caspases. The caspases digest nuclear and cytoskeletal proteins and also activate endonucleases.
- f. **Physiologic examples of apoptosis** include embryogenesis (organogenesis

and development), hormone-dependent apoptosis (menstrual cycle), thymus (selective death of lymphocytes).

g. **Pathologic examples of apoptosis** include viral diseases (viral hepatitis [Councilman body]), graft versus host disease, and cystic fibrosis (duct obstruction and pancreatic atrophy).

3. Serum enzyme markers of cell damage you should remember include aspartate aminotransferase (AST) (liver injury), alanine aminotransferase (ALT) (liver injury), creatine kinase (CK-MB) (heart injury), and amylase and lipase (pancreatic injury; amylase also rises with salivary gland injury).

CELLULAR ADAPTIVE RESPONSES TO INJURY

1. In general, cellular adaptation is the result of a persistent stress or injury. Adaptive responses are potentially reversible once the stress has been removed. Some forms of adaptation may precede or progress to neoplasia.

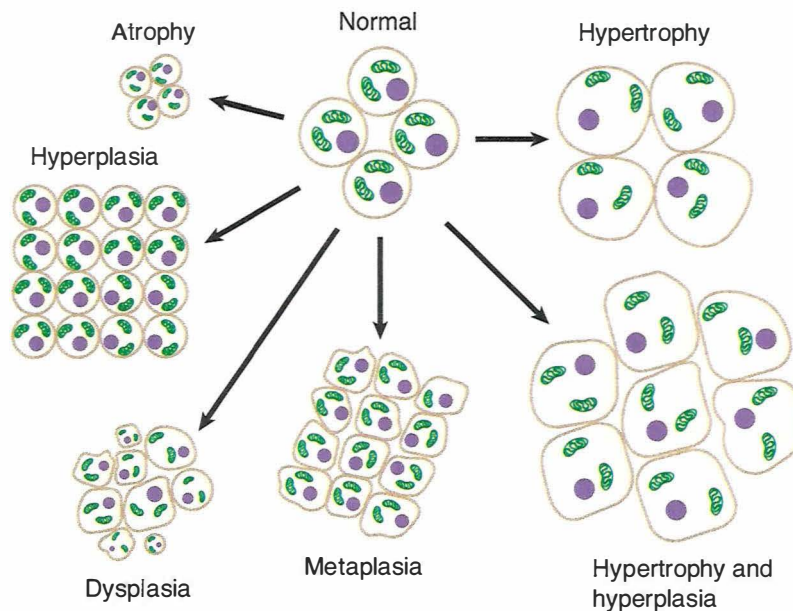


Figure 2-7. Cellular Adaptive Responses to Cell Injury

2. Atrophy

- a. Atrophy is a decrease in cell/organ size and functional ability.
- b. Causes of atrophy include decreased workload/disuse (immobilization); ischemia (atherosclerosis); lack of hormonal or neural stimulation, malnutrition, and aging.
- c. Light microscopic examination shows small shrunken cells with lipofuscin granules.
- d. Electron microscopy shows decreased intracellular components and autophagosomes.

3. Hypertrophy

- a. Hypertrophy is an increase in cell size and functional ability due to increased synthesis of intracellular components.
- b. Causes of hypertrophy

Clinical Correlate

Graft-versus-host disease (GVHD) is an example of pathogenic apoptosis which occurs in allogeneic bone marrow transplant recipients. The transplanted marrow has cytotoxic T-cells which recognize the new host proteins (usually HLA) as foreign, and it signals the cells to undergo apoptosis while releasing TNF-alpha and interferon-gamma. Organs typically involved include the skin, mucosa, liver, and GI tract. Pathological samples from patients with GVHD will show single-cell apoptosis occurring in affected organs and adjacent T-cells.

Clinical Correlate

Residence at high altitude, where oxygen content of air is relatively low, leads to compensatory hyperplasia of red blood cell precursors in the bone marrow and an increase in the number of circulating red blood cells (secondary polycythemia).

Clinical Correlate

Barrett's esophagus is a classic example of metaplasia. The esophageal epithelium is normally squamous, but it undergoes a change to intestinal epithelium (columnar) when it is under constant contact with gastric acid.

- i. Increased mechanical demand can be physiologic (striated muscle of weight lifters) or pathologic (cardiac muscle in hypertension).
 - ii. Increased endocrine stimulation plays a role in puberty (growth hormone, androgens/estrogens, etc.), gravid uterus (estrogen), and lactating breast (prolactin and estrogen).
 - c. Hypertrophy is mediated by growth factors, cytokines, and other trophic stimuli and leads to increased expression of genes and increased protein synthesis.
 - d. Hypertrophy and hyperplasia often occur together.
4. **Hyperplasia**
- a. Hyperplasia is an increase in the number of cells in a tissue or organ.
 - b. Some cell types are unable to exhibit hyperplasia (e.g., nerve, cardiac, skeletal muscle cells).
 - c. Physiologic causes of hyperplasia include compensatory mechanisms (e.g., after partial hepatectomy), hormonal stimulation (e.g., breast development at puberty), and antigenic stimulation (e.g., lymphoid hyperplasia).
 - d. Pathologic causes of hyperplasia include endometrial hyperplasia and prostatic hyperplasia of aging.
 - e. Hyperplasia is mediated by growth factors, cytokines, and other trophic stimuli; increased expression of growth-promoting genes (protooncogenes); and increased DNA synthesis and cell division.
5. **Metaplasia**
- a. Metaplasia is a reversible change of one cell type to another, usually in response to irritation. It has been suggested that the replacement cell is better able to tolerate the environmental stresses. For example, bronchial epithelium undergoes squamous metaplasia in response to the chronic irritation of tobacco smoke.
 - b. The proposed mechanism is that the reserve cells (or stem cells) of the irritated tissue differentiate into a more protective cell type due to the influence of growth factors, cytokines, and matrix components.
6. **Dysplasia**
- a. Dysplasia is an abnormal proliferation of cells that is characterized by changes in cell size, shape, and loss of cellular organization. Dysplasia is not cancer but may progress to cancer (preneoplastic lesion). Examples include cervical dysplasia, actinic (solar) keratosis, and oral leukoplakia.

OTHER CELLULAR ALTERATIONS DURING INJURY

- a. Lipids that can accumulate intracellularly include triglycerides (e.g., fatty change in liver cells), cholesterol (e.g., atherosclerosis, xanthomas), and complex lipids (e.g., sphingolipid accumulation).
- b. Proteins can accumulate in proximal renal tubules in proteinuria and can form Russell bodies (intracytoplasmic accumulation of immunoglobulins) in plasma cells.
- c. **Glycogen storage diseases (see Chapter 6)**
- d. Exogenous pigments include anthracotic pigmentation of the lung (secondary to the inhalation of carbon dust), tattoos, and lead that has been ingested (e.g., gingival lead line, renal tubular lead deposits).

- e. Endogenous pigments
- i. Lipofuscin is a wear-and-tear pigment that is seen as perinuclear yellow-brown pigment. It is due to indigestible material within lysosomes and is common in the liver and heart.
 - ii. Melanin is a black-brown pigment derived from tyrosine found in melanocytes and substantia nigra.
 - iii. Hemosiderin is a golden yellow-brown granular pigment found in areas of hemorrhage or bruises. Systemic iron overload can lead to hemosiderosis (increase in total body iron stores without tissue injury) or hemochromatosis (increase in total body iron stores with tissue injury). Prussian blue stain can identify the iron in the hemosiderin.
 - iv. Bilirubin accumulates in newborns in the basal ganglia, causing permanent damage (kernicterus).

2. Hyaline change

- a. Hyaline change is a nonspecific term used to describe any intracellular or extracellular alteration that has a pink homogenous appearance (proteins) on H&E stains.
- b. Examples of intracellular hyaline include renal proximal tubule protein reabsorption droplets, Russell bodies, and alcoholic hyaline.
- c. Examples of extracellular hyaline include hyaline arteriosclerosis, amyloid, and hyaline membrane disease of the newborn.

3. Pathologic forms of calcification

- a. Dystrophic calcification is the precipitation of calcium phosphate in dying or necrotic tissues. Examples include fat necrosis (saponification), psammoma bodies (laminated calcifications that occur in meningiomas and papillary carcinomas of the thyroid and ovary), Mönckeberg medial calcific sclerosis in arterial walls, and atherosclerotic plaques.
- b. **Metastatic calcification** is the precipitation of calcium phosphate in normal tissue due to hypercalcemia (supersaturated solution). The many causes include hyperparathyroidism, parathyroid adenomas, renal failure, paraneoplastic syndrome, vitamin D intoxication, Milk-alkali syndrome, sarcoidosis, paget disease, multiple myeloma, metastatic cancer to the bone. The calcifications are located in the interstitial tissues of the stomach, kidneys, lungs, and blood vessels.

Chapter Summary

- Cells can be damaged by a variety of mechanisms.
- Hypoxia causes a loss of ATP production secondary to oxygen deficiency and can be caused by ischemia, cardiopulmonary failure, or decreased oxygen-carrying capacity of the blood.
- Infections can injure cells directly, or indirectly, via toxin production or host inflammatory response.
- Hypersensitivity reactions and autoimmune diseases may kill or injure cells.
- Congenital causes of cellular injury include enzyme defects, structural protein defects, chromosomal disorders, and congenital malformations.
- Chemical agents, physical agents, and nutritional imbalances can also injure cells.
- The response of cells to an insult depends on both the state of the cell and the type of insult. The response can range from adaptation to reversible injury to irreversible injury with cell death.
- Intracellular sites and systems particularly vulnerable to injury include DNA, ATP production, cell membranes, and protein synthesis.
- Reversible cell injury is primarily related to decreased ATP synthesis by oxidative phosphorylation, leading to cellular swelling and inadequate protein synthesis.
- Irreversible cell injury often additionally involves severe damage to membranes, mitochondria, lysosomes, and nucleus.
- Death of tissues (necrosis) can produce a variety of histologic patterns, including coagulative necrosis, liquefaction necrosis, caseous necrosis, fibrinoid necrosis, and gangrenous necrosis, often with an inflammatory response.
- Apoptosis is a specialized form of programmed cell death that can be regulated genetically or by cellular or tissue triggers without an inflammatory response.

ACUTE INFLAMMATION

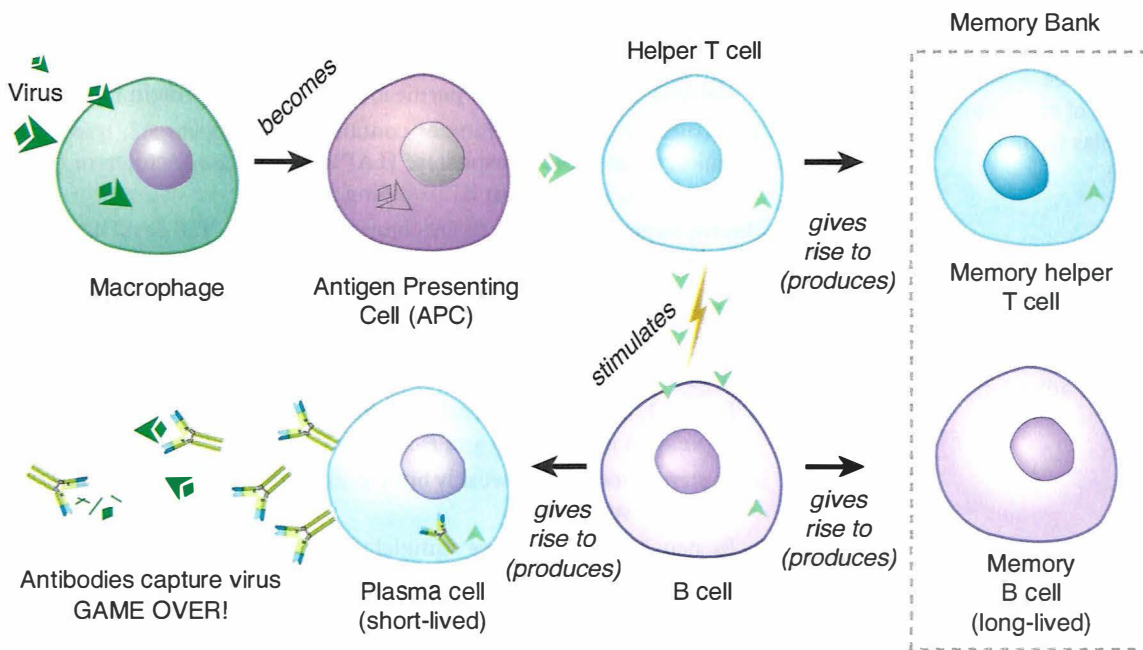
1. General

- a. Acute inflammation is an immediate response to injury, which is part of innate immunity.
- b. Short duration in normal host
- c. Cardinal signs of inflammation include rubor (redness); calor (heat); tumor (swelling); dolor (pain); functio laesa (loss of function).

Note

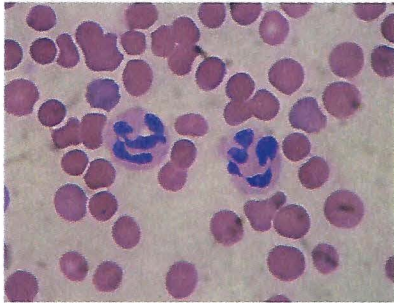
Important components of acute inflammation

- Hemodynamic changes
- Neutrophils
- Chemical mediators



Copyright quest.nasa.gov. Used with permission.

Figure 3-1. Adaptive Immunity



Source: commons.wikimedia.org (Mgiganteus)

Lobed nucleus, small granules

Neutrophil

Clinical Correlate

A normal mature neutrophil has a segmented nucleus (3–4 segments). Hypersegmented neutrophils (more than 5) are usually thought to be pathognomonic of the class of anemias called megaloblastic anemias (vitamin B12 or folate deficiencies).

Note

Selectins: weak binding; initiate rolling

Integrins: stable binding and adhesion

2. Hemodynamic changes

- a. Initial transient vasoconstriction
- b. Massive vasodilatation mediated by histamine, bradykinin, and prostaglandins
- c. Increased vascular permeability
 - i. Chemical mediators of increased permeability include vasoactive amines (histamine, and serotonin), bradykinin (an end-product of the kinin cascade), leukotrienes (e.g., LTC4, LTD4, LTE4).
 - ii. The mechanism of increased vascular permeability involves endothelial cell and pericyte contraction; direct endothelial cell injury; and leukocyte injury of endothelium.
- d. Blood flow slows (stasis) due to increased viscosity, allows neutrophils to marginate

NEUTROPHILS

1. Important cells in acute inflammation

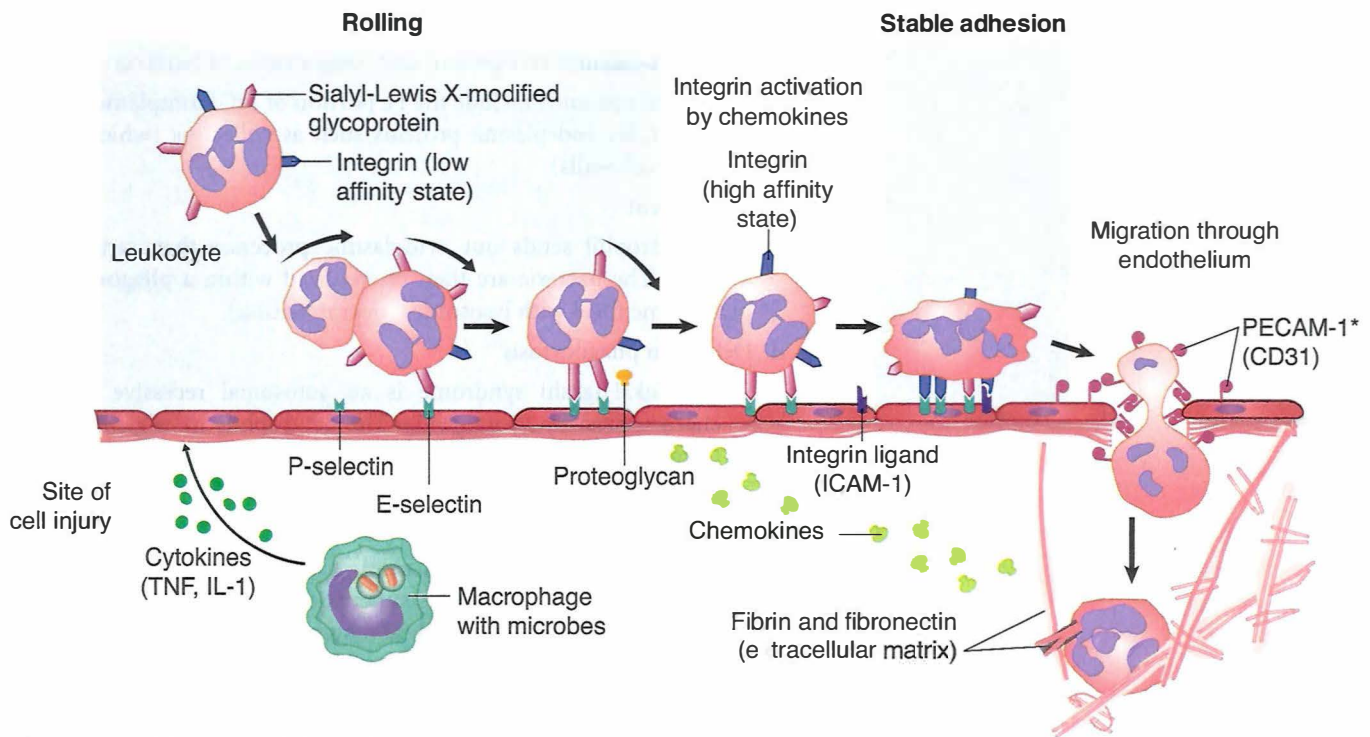
- a. **Neutrophils** (life span in tissue 1–2 days)
 - i. Synonyms: segmented neutrophils, polymorphonuclear leukocytes (PMN)
 - ii. Primary (azurophilic) granules contain myeloperoxidase, phospholipase A2, lysozyme (damages bacterial cell walls by catalyzing hydrolysis of 1,4-beta- linkages), and acid hydrolases. Also present are elastase, defensins (microbicidal peptides active against many gram-negative and gram-positive bacteria, fungi, and enveloped viruses), and bactericidal permeability increasing protein (BPI).
 - iii. Secondary (specific) granules contain phospholipase A2, lysozyme, leukocyte alkaline phosphatase (LAP), collagenase, lactoferrin (chelates iron), and vitamin B12-binding proteins.
- b. **Macrophages** (life span in tissue compartment is 60–120 days) have acid hydrolases, elastase, and collagenase.

2. Neutrophil margination and adhesion

- a. Adhesion is mediated by complementary molecules on the surface of neutrophils and endothelium.
 - i. In step 1, the endothelial cells at sites of inflammation have increased expression of *E-selectin* and *P-selectin*.
 - ii. In step 2, neutrophils weakly bind to the endothelial selectins and roll along the surface.
 - iii. In step 3, neutrophils are stimulated by chemokines to express their integrins.
 - iv. In step 4, binding of the integrins firmly adheres the neutrophil to the endothelial cell.

Table 3-1. Selectin and Integrin Distribution in the Endothelium and Leukocyte

	Endothelium	Leukocyte
Selectins	P-Selectin	Sialyl-Lewis X & PSGL-1
	E-Selectin	Sialyl-Lewis X & PSGL-1
	GlyCam-1/CD34	L-Selectin
Integrins	ICAM-1	LFA-1 & MAC-1
	VCAM-1	VLA-4



*PECAM-1 is platelet endothelial cell adhesion molecule 1.

Figure 3-2. Adhesion and Migration

b. Modulation of adhesion molecules in inflammation

The fastest step involves redistribution of adhesion molecules to the surface; for example, P-selectin is normally present in the Weibel-Palade bodies of endothelial cells and can be redistributed to the cell surface with exposure to inflammatory mediators such as histamine and thrombin. Additionally, synthesis of adhesion molecules occurs. For example, cytokines IL-1 and TNF induce production of E-selectin, ICAM-1, and VCAM-1 in endothelial cells. There can also be increased binding affinity, as when chemotactic agents cause a conformational change in the leukocyte integrin LFA-1, which is converted to a high-affinity binding state.

c. **Defects in adhesion** can be seen in diabetes mellitus, corticosteroid use, acute alcohol intoxication, and leukocyte adhesion deficiency (autosomal recessive condition with recurrent bacterial infections).

3. Emigration (diapedesis)

Leukocytes emigrate from the vasculature (postcapillary venule) by extending pseudopods between the endothelial cells. They then move between the endothelial cells, migrating through the basement membrane toward the inflammatory stimulus.

4. Chemotaxis

- Chemotaxis is the attraction of cells toward a chemical mediator that is released in the area of inflammation.
- Important chemotactic factors for neutrophils include bacterial products such as *N*-formyl-methionine, leukotriene B₄ (LTB₄), complement system product C5a, and α -chemokines (IL-8).

Clinical Correlate

Leukocyte adhesion deficiency:

- Autosomal recessive
- Deficiency of β 2 integrin subunit (CD18)
- Recurrent bacterial infection
- Delay in umbilical cord sloughing

5. Phagocytosis and degranulation

- a. Opsonins enhance recognition and phagocytosis of bacteria
- b. Important opsonins include the Fc portion of IgG, complement system product C3b, and plasma proteins such as collectins (which bind to bacterial cell walls)
- c. Engulfment

The neutrophil sends out cytoplasmic processes that surround the bacteria. The bacteria are then internalized within a phagosome. The phagosome fuses with lysosomes (degranulation).

- d. Defects in phagocytosis
 - i. Chediak-Higashi syndrome is an autosomal recessive condition characterized by neutropenia. The neutrophils have giant granules (lysosomes) and there is a defect in chemotaxis and degranulation.

6. Intracellular killing

- a. In **oxygen-dependent killing**, respiratory burst requires oxygen and NADPH oxidase and produces superoxide, hydroxyl radicals, and hydrogen peroxide. Myeloperoxidase requires hydrogen peroxide and halide (Cl^-) and produces HOCl (hypochlorous acid).

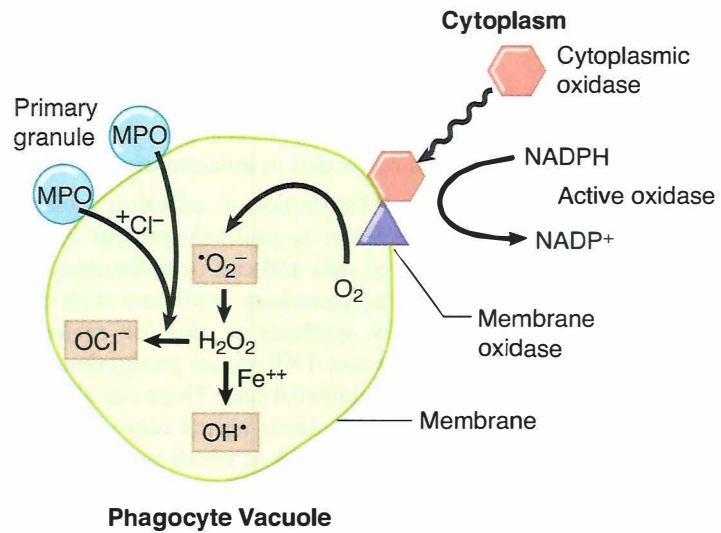
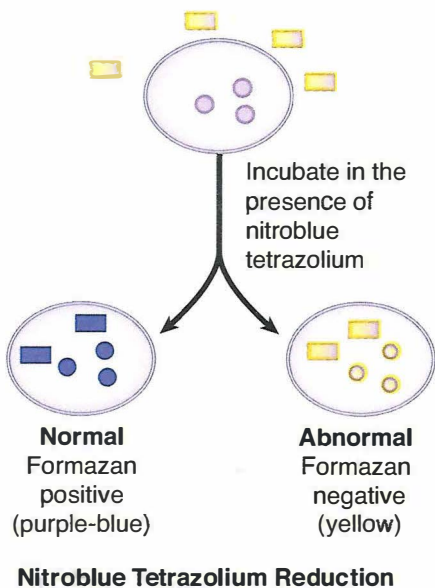


Figure 3-3. Oxygen-Dependent Killing

- b. **Oxygen-independent killing** involves lysozyme, lactoferrin, acid hydrolases, bactericidal permeability increasing protein (BPI), and defensins.
- c. Deficiency of oxygen-dependent killing
 - i. Chronic granulomatous disease of childhood can be X-linked or autosomal recessive. It is characterized by a deficiency of NADPH oxidase, lack of superoxide and hydrogen peroxide, and recurrent bacterial infections with catalase-positive organisms (*S. aureus*). The nitroblue tetrazolium test will be negative.
 - ii. Myeloperoxidase deficiency is an autosomal recessive condition characterized by infections with *Candida*.



Nitroblue Tetrazolium Reduction

CHEMICAL MEDIATORS OF INFLAMMATION

1. Vasoactive amines

- a. **Histamine** is produced by basophils, platelets, and mast cells. It causes vasodilation and increased vascular permeability. Triggers for release include IgE-mediated mast cell reactions, physical injury, anaphylatoxins (C3a and C5a), and cytokines (IL-1).
- b. **Serotonin** is produced by platelets and causes vasodilation and increased vascular permeability.

2. The kinin system

- a. Activated Hageman factor (factor XII) converts prekallikrein → kallikrein
- b. Kallikrein cleaves high molecular weight kininogen (HMWK) → bradykinin
- c. Effects of bradykinin include increased vascular permeability, pain, vasodilation, and bronchoconstriction.

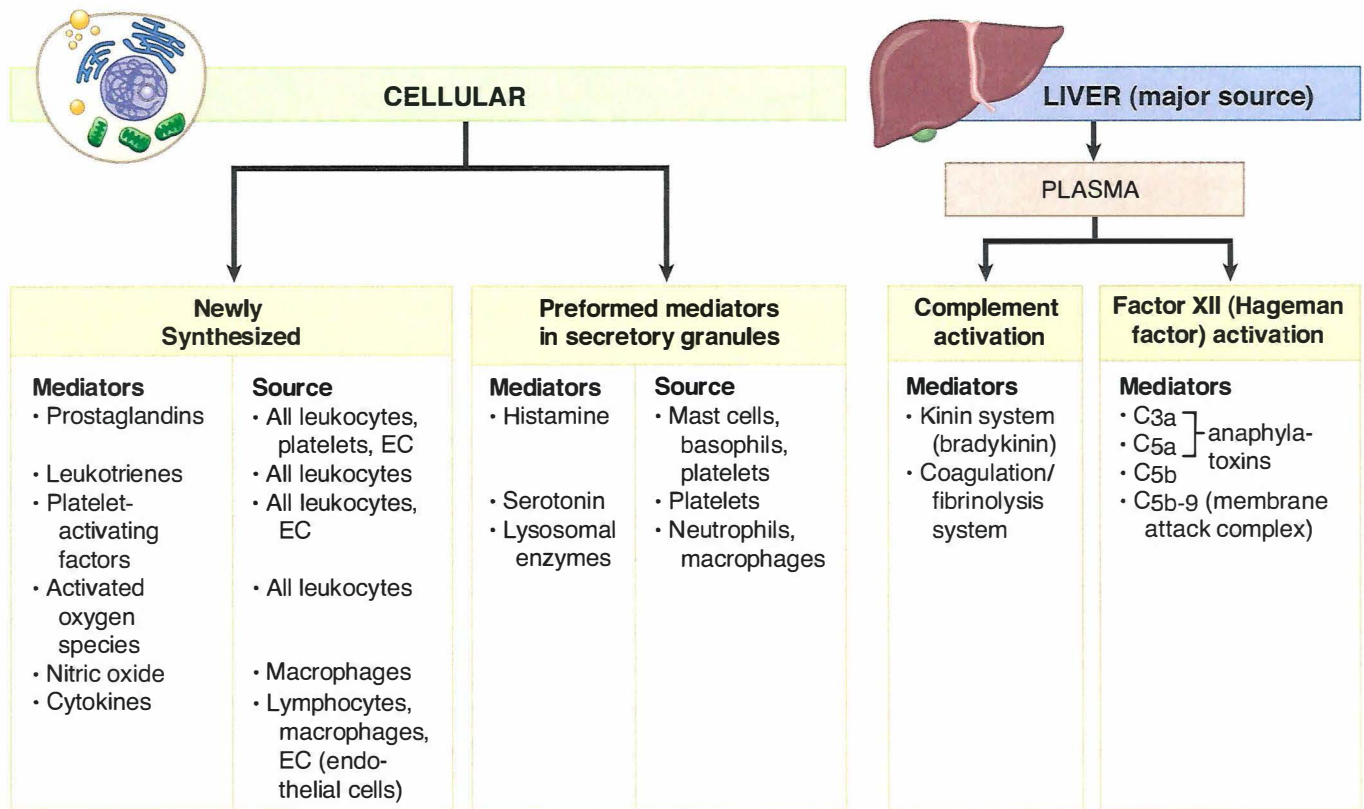


Figure 3-4. Sources of Chemical Mediators of Inflammation

3. Arachidonic acid products

a. Cyclooxygenase pathway

- i. Thromboxane A2 is produced by platelets and causes vasoconstriction and platelet aggregation.

In a Nutshell

Mediators of Pain

- Bradykinin
- Prostaglandins (E₂)

In a Nutshell

Mediators of Fever

- Cytokines IL-1, IL-6, and TNF- α
- Prostaglandins

- ii. Prostacyclin (PGI₂) is produced by vascular endothelium and causes vasodilation and inhibition of platelet aggregation.
- iii. Prostaglandin E₂ causes pain.
- iv. Prostaglandins PGE₂, PGD₂, and PGF₂ cause vasodilatation.

b. Lipoxygenase pathway

Leukotriene B₄ (LTB₄) causes neutrophil chemotaxis, while leukotriene C₄, D₄, E₄ cause vasoconstriction.

4. **Important products in the complement cascade include** C5b-C9 (membrane attack complex), C3a, C5a (anaphylotoxins stimulate the release of histamine), C5a (leukocyte chemotactic factor), and C3b (opsonin for phagocytosis).

5. Cytokines

- a. IL-1 and TNF cause fever and acute phase reactants; enhance adhesion molecules; and stimulate and activate fibroblasts, endothelial cells, and neutrophils.
- b. IL-8 is a neutrophil chemoattractant produced by macrophages.

FOUR OUTCOMES OF ACUTE INFLAMMATION

1. Complete resolution with regeneration
2. Complete resolution with scarring
3. Abscess formation
4. Transition to chronic inflammation

CHRONIC INFLAMMATION

1. Causes of chronic inflammation

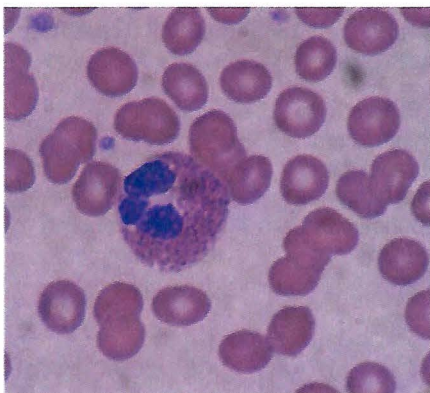
- a. Following a bout of acute inflammation
- b. Persistent infections
- c. Infections with certain organisms, including viral infections, mycobacteria, parasitic infections, and fungal infections
- d. Autoimmune diseases
- e. Response to foreign material
- f. Response to malignant tumors

2. Important cells in chronic inflammation

a. Macrophages

- i. Macrophages are derived from blood monocytes.
- ii. Tissue-based macrophages (life span in connective tissue compartment is 60–120 days) are found in connective tissue (histiocyte), lung (pulmonary alveolar macrophages), liver (Kupffer cells), bone (osteoclasts), and brain (microglia).
- iii. During inflammation macrophages are mainly recruited from the blood (circulating monocytes).
- iv. Chemotactic factors: C5a, MCP-1, MIP-1 α , PDGF, TGF- β
- v. Secrete a wide variety of active products (monokines)
- vi. May be modified into epithelioid cells in granulomatous processes

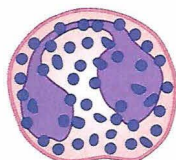
b. **Lymphocytes** include B cells and plasma cells, as well as T cells. Lymphotaxin is the lymphocyte chemokine.



Source: commons.wikimedia.org (Bobjgalindo)

Bilobed nucleus, large granules (pink)

Eosinophil



Bilobed nucleus, large granules (blue)

Basophil

- c. **Eosinophils** play an important role in parasitic infections and IgE-mediated allergic reactions. The eosinophilic chemokine is eotaxin. Eosinophil granules contain major basic protein, which is toxic to parasites.
- d. **Basophils** contain similar chemical mediators as mast cells in their granules. Mast cells are present in high numbers in the lung and skin. Both basophils and mast cells play an important role in IgE-mediated reactions (allergies and anaphylaxis) and can release histamine.
3. **Chronic granulomatous inflammation**
- a. Definition: specialized form of chronic inflammation characterized by small aggregates of modified macrophages (epithelioid cells and multinucleated giant cells) usually populated by CD4+ Th1 lymphocytes
- b. **Composition of a granuloma**
- Epithelioid cells, located centrally, form when IFN- γ transforms macrophages to epithelioid cells. They are enlarged cells with abundant pink cytoplasm.
 - Multinucleated giant cells, located centrally, are formed by the fusion of epithelioid cells. Types include Langhans-type giant cell (peripheral arrangement of nuclei) and foreign body type giant cell (haphazard arrangement of nuclei).
 - Lymphocytes and plasma cells at the periphery
 - Central necrosis occurs in granulomata due to excessive enzymatic breakdown and is commonly seen in *Mycobacterium tuberculosis* infection as well as fungal infections and a few bacterial infections. Because of the public health risk of tuberculosis, necrotizing granulomas should be considered tuberculosis until proven otherwise.

Clinical Correlate

Patients who are to be placed on tumor necrosis factor (TNF) inhibitors such as infliximab must undergo a PPD test before starting therapy. The PPD checks for latent tuberculosis infection, which can be reactivated by the TNF alpha inhibitor.

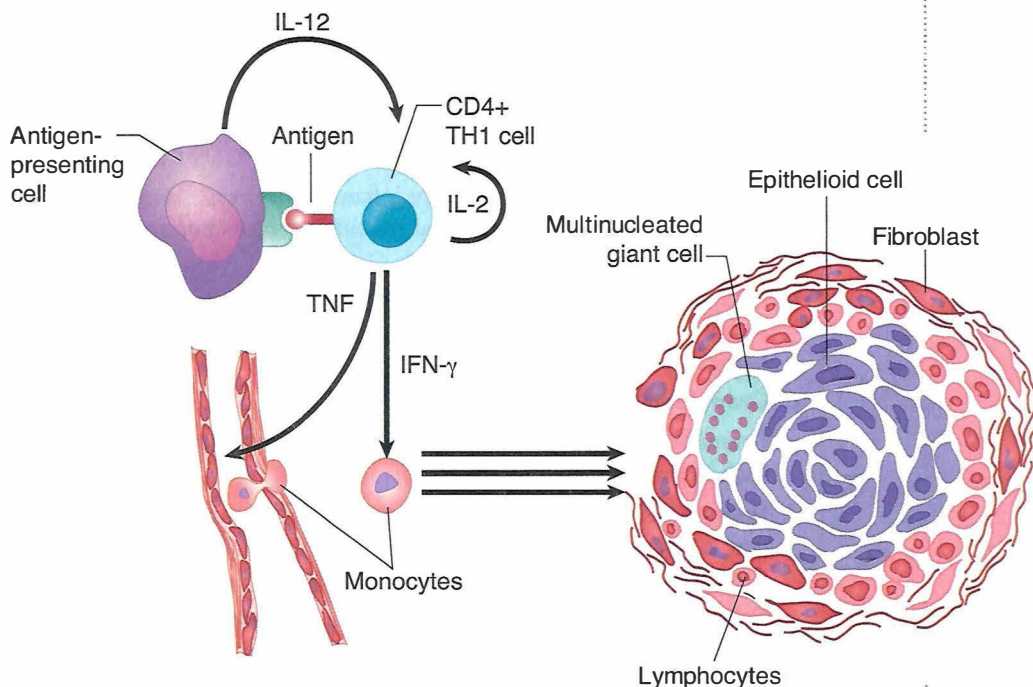
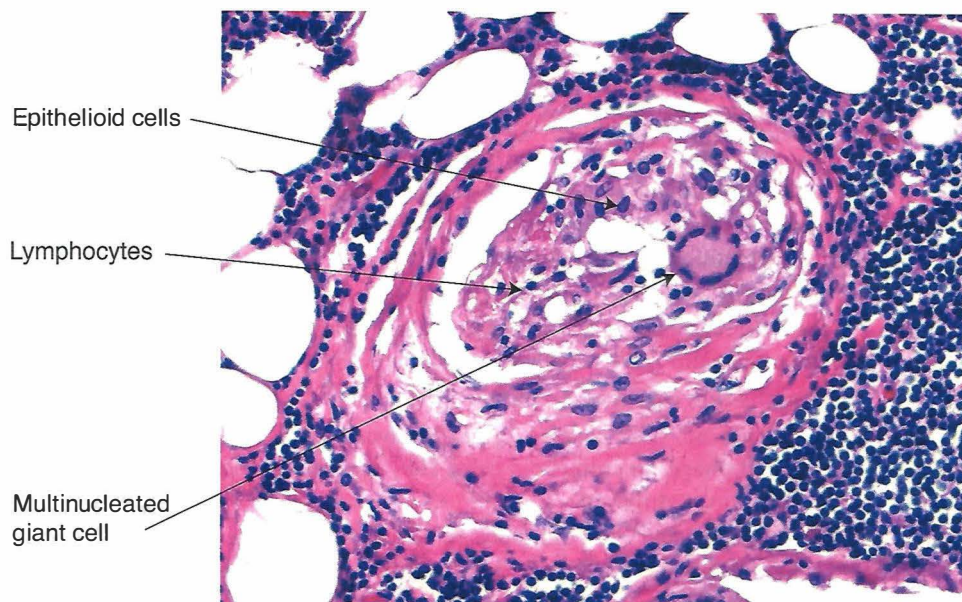


Figure 3-5. Granuloma Formulation

- c. **Granulomatous diseases** of which you should be aware include tuberculosis (caseating granulomas), cat-scratch fever, syphilis, leprosy, fungal infections (e.g., coccidioidomycosis), parasitic infections (e.g., schistosomiasis), foreign bodies, beryllium, and sarcoidosis.



© Henry Sanchez, M.D. Used with permission.

Figure 3-6. A Granuloma Is Seen in the Large, Poorly Circumscribed Nodule in the Center of the Field

TISSUE RESPONSES TO INFECTIOUS AGENTS

1. General

Infectious diseases are very prevalent worldwide and are a major cause of morbidity and mortality. Infectious agents tend to have **tropism** for specific tissues and organs.

2. Six major histologic patterns

- a. **Exudative inflammation** is acute inflammatory response with neutrophils. Examples include bacterial meningitis, bronchopneumonia, and abscess.
- b. **Necrotizing inflammation** occurs when a virulent organism produces severe tissue damage and extensive cell death. Examples include necrotizing fasciitis and necrotizing pharyngitis.
- c. **Granulomatous inflammation**
Granulomatous response predominates with slow-growing organisms such as mycobacteria, fungi, and parasites.
- d. **Interstitial inflammation** is a diffuse mononuclear interstitial infiltrate that is a common response to viral infectious agents. Examples include myocarditis (Coxsackie virus) and viral hepatitis.
- e. **Cytopathic/cytoproliferative** inflammation refers to inflammation in which the infected/injured cell is altered. The changes may include intranuclear/cytoplasmic inclusions (cytomegalic inclusion disease, rabies [Negri body]); syncytia formation (respiratory syncytial virus and herpes virus); and apoptosis (Councilman body in viral hepatitis).
- f. **No inflammation**
 - i. No evidence of an inflammatory response to presence of microbes can occur in severely immunosuppressed individuals due to primary immunodeficiencies or acquired immunodeficient states (e.g., AIDS).

Chapter Summary

- Acute inflammation is an immediate response to injury that can cause redness, heat, swelling, pain, and loss of function.
- Hemodynamic changes in acute inflammation are mediated by vasoactive chemicals and, after a transient initial vasoconstriction, produce massive dilation with increased vascular permeability.
- Neutrophils are important white blood cells in acute inflammation that contain granules with many degradative enzymes.
- Neutrophils leave the bloodstream in a highly regulated process involving margination (moving toward the vessel wall), adhesion (binding to the endothelium), and emigration (moving between endothelial cells to leave the postcapillary venule). Defects in adhesion can contribute to the immunosuppression seen in diabetes mellitus and corticosteroid use.
- Chemotaxis is the attraction of cells toward a chemical mediator, which is released in the area of inflammation.
- The phagocytosis of bacteria by neutrophils is improved if opsonins, such as the Fc portion of immunoglobulin (Ig) G or the complement product C3B, are bound to the surface of the bacteria. Chediak-Higashi syndrome is an example of a genetic disease with defective neutrophil phagocytosis.
- Once a bacterium has been phagocytized, both oxygen-requiring and oxygen-independent enzymes can contribute to the killing of the bacteria. Chronic granulomatous disease of childhood and myeloperoxidase deficiency are genetic immunodeficiencies related to a deficiency of oxygen-dependent killing.
- Chemical mediators of inflammation include vasoactive amines, the kinin system, arachidonic acid products, the complement cascade, coagulation/fibrinolytic cascade, and cytokines.
- Acute inflammation may lead to tissue regeneration, scarring, abscess formation, or chronic inflammation.
- Cells important in chronic inflammation include macrophages, lymphocytes, eosinophils, and basophils.
- Chronic granulomatous inflammation is a specialized form of chronic inflammation with modified macrophages (epithelioid cells and multinucleated giant cells) usually surrounded by a rim of lymphocytes. A wide variety of diseases can cause chronic granulomatous inflammation, most notably tuberculosis, syphilis, leprosy, and fungal infections.
- Patterns of tissue response to infectious agents can include exudative inflammation, necrotizing inflammation, granulomatous inflammation, interstitial inflammation, cytopathic/cytoproliferative inflammation, and no inflammatory response.

REGENERATION AND HEALING

1. Tissue repair

- a. Regeneration and healing of damaged cells and tissues starts almost as soon as the inflammatory process begins.
- b. Tissue repair involves five overlapping processes: hemostasis (coagulation, platelets); inflammation (neutrophils, macrophages, lymphocytes, mast cells); regeneration (stem cells and differentiated cells); fibrosis (macrophages, granulation tissue [fibroblasts, angiogenesis], type III collagen); and remodeling (macrophages, fibroblasts, converting collagen III to I).

2. Regeneration

- a. Different tissues have different regenerative capacities.
- b. Labile cells (primarily stem cells) regenerate throughout life. Examples include surface epithelial cells (skin and mucosal lining cells), hematopoietic cells, stem cells, etc.
- c. Stable cells (stem cells and differentiated cells) replicate at a low level throughout life and have the capacity to divide if stimulated by some initiating event. Examples include hepatocytes, proximal tubule cells, endothelium, etc.
- d. Permanent cells (few stem cells and/or differentiated cells with the capacity to replicate) have a very low level of replicative capacity. Examples include neurons and cardiac muscle.

3. Fibrosis and remodeling phases

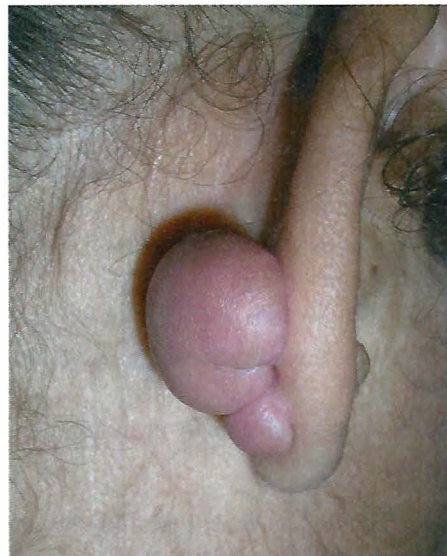- a. Replacement of a damaged area by a connective tissue scar
- b. Tissue repair is mediated by various growth factors and cytokines. Examples include transforming growth factor (TGF- β), platelet-derived growth factor (PDGF), fibroblast growth factor (FGF), vascular endothelial growth factor (VEGF), epidermal growth factor (EGF), tumor necrosis factor (TNF- α) and IL-1.
 - i. TGF- β and EGF are involved in wound healing and regeneration. Both bind to the EGF receptor.
 - ii. VEGFs are important in inducing new vessel growth during growth, repair, and regeneration
 - iii. TNF- α and IL-1 are both important in wound healing
- c. Granulation tissue shows synthetically active fibroblasts and capillary proliferation.
- d. Wound contraction is mediated by myofibroblasts.
- e. Scar formation

4. **Primary union (healing by first intention)** occurs with clean wounds when there has been little tissue damage and the wound edges are closely approximated; the classic example is a surgical incision.

5. **Secondary union (healing by secondary intention)** occurs in wounds that have large tissue defects and when the two edges of the wound are not in contact. Requiring larger amounts of granulation tissue to fill in the defect, it is often accompanied by significant wound contraction and can cause larger residual scars.
6. **Repair in specific organs**
 - a. Liver: Mild injury is repaired by regeneration of hepatocytes, sometimes with restoration to normal pathology. Severe or persistent injury causes formation of regenerative nodules that may be surrounded by fibrosis, leading to hepatic cirrhosis.
 - b. In the brain, neurons do not regenerate, but microglia remove debris and astrocytes proliferate, causing gliosis.
 - c. Damaged heart muscle cannot regenerate, so the heart heals by fibrosis.
 - d. In the lung, type II pneumocytes replace both type I and type II pneumocytes after injury.
 - e. In peripheral nerves, the distal part of the axon degenerates while the proximal part regrows slowly, using axonal sprouts to follow Schwann cells to the muscle.

ABERRATIONS IN WOUND HEALING

1. **Delayed wound healing** may be seen in wounds complicated by foreign bodies, infection, ischemia, diabetes, malnutrition, scurvy, etc.
2. **Hypertrophic scar** results in a prominent scar that is localized to the wound, due to excess production of granulation tissue and collagen.
3. Keloid formation is a genetic predisposition that is more common in African Americans. It tends to affect the earlobes, face, neck, sternum, and forearms, and it may produce large tumor-like scars, which often extend beyond the injury site. There is excess production of collagen that is predominantly type III.



© Richard P. Usatine, M.D. Used with permission.

Figure 4-1. Keloid on posterior surface of ear (auricle)

Table 4-1-1. Factors Inhibiting Tissue Repair

Diabetes
Diseases affecting collagen and elastic fibers
Foreign bodies
Inadequate blood supply
Infection
Large size or extent of damage
Mechanical disruption of healing wound
Malnutrition or specific nutrient deficiency
Malignancy
Medications including glucocorticoids
Obesity
Old age

CONNECTIVE TISSUE COMPONENTS

1. Collagen (over 29 types)
 - a. Type I collagen is the most common, has high tensile strength, and is found in skin, bone, tendons, and most organs.
 - b. Type II is found in cartilage and vitreous humor.
 - c. Type III is found in granulation tissue, embryonic tissue, uterus, and keloids.
 - d. Type IV is found in basement membranes.
 - e. Hydroxylation of collagen is mediated by vitamin C.
 - f. Cross-linking of collagen is performed by lysyl oxidase. Copper is a required cofactor.
2. **Other extracellular matrix components**
 - a. Elastic fibers are formed when elastin proteins are aligned on a fibrillin framework. Defects in fibrillin are found in Marfan syndrome.
 - b. Adhesion molecules include fibronectin and laminin.
 - c. Proteoglycans and glycosaminoglycans include heparan sulfate and chondroitin sulfate.
3. **Basement membranes** have a net *negative charge*. The composition of basement membranes includes collagen type IV, proteoglycans (heparan sulfate), laminin, fibronectin, and entactin.

Clinical Correlate

Scurvy:

- Vitamin C deficiency first affects collagen with highest hydroxyproline content, such as that found in blood vessels
- Thus, an early symptom is bleeding gums

Ehlers-Danlos (ED) Syndrome:

- Defect in collagen synthesis or structure
- 9 defects known
- Type IV is a defect in type III collagen

Osteogenesis Imperfecta:

- Defect in collagen type I

Clinical Correlate

Marfan Syndrome:

- Defect in fibrillin gene, leading to laxity of tissues (long, lanky frame; lens subluxation; aortic aneurysms)

Clinical Correlate

Loss of negative charge (proteoglycan) of the renal glomerular basement membrane may cause proteinuria (nephrotic syndrome).

Chapter Summary

- Tissue repair involves regeneration of the damaged tissue by cells of the same type and healing with replacement by connective tissue.
- Tissue repair involves five overlapping processes including hemostasis, inflammation, regeneration, fibrosis, and remodeling.
- Tissues vary in their regenerative capacities. Labile cell populations that regenerate throughout life include surface epithelial cells, hematopoietic cells, and stem cells. Stable cells that replicate at a low level through life, but can divide if stimulated, include hepatocytes, proximal tubule cells, and endothelial cells. Permanent cells that cannot replicate in adult life include neurons and cardiac muscle.
- Healing with replacement of a damaged area by a connective tissue scar is mediated by many growth factors and cytokines, primarily from macrophages. Initially granulation tissue forms, which later undergoes wound contraction mediated by myofibroblasts, eventually resulting in true scar formation.
- Wound healing by first intention (primary union) occurs after clean wounds have been closely approximated. Wound healing by second intention (secondary union) occurs in wounds with larger defects in which the edges cannot be closely approximated.
- Problems that can occur with wound healing include delayed wound healing, hypertrophic scar formation, and keloid formation.
- Different types of collagen are found in different body sites.
 - Type I collagen is the most common form.
 - Type II collagen is found in cartilage.
 - Type III collagen is an immature form found in granulation tissue.
 - Type IV collagen is found in basement membranes.Collagen production requires vitamin C and copper.
- Other extracellular matrix components include elastic fibers, adhesion molecules, and proteoglycans and glycosaminoglycans.
- Basement membranes have a net negative charge and are composed of collagen and other extracellular matrix components.

EDEMA

1. Edema is the presence of excess fluid in the intercellular space.
2. There are many causes of edema.
 - a. **Increased hydrostatic pressure** causes edema in congestive heart failure (generalized edema), portal hypertension, renal retention of salt and water, and venous thrombosis (local edema).
 - b. **Hypoalbuminemia and decreased colloid osmotic pressure** cause edema in liver disease, nephrotic syndrome, and protein deficiency (e.g., kwashiorkor).
 - c. **Lymphatic obstruction** (lymphedema) causes edema in tumor, following surgical removal of lymph node drainage, and in parasitic infestation (filariasis → elephantiasis).
 - d. **Increased endothelial permeability** causes edema in inflammation, type I hypersensitivity reactions, and with some drugs (e.g., bleomycin, heroin, etc.).
 - e. **Increased interstitial sodium** causes edema when there is increased sodium intake, primary hyperaldosteronism, and renal failure.
 - f. Specialized forms of tissue swelling due to **increased extracellular glycosaminoglycans** also occur, notably in pretibial myxedema and exophthalmos (Graves disease).
3. **Anasarca** is severe generalized edema.
4. **Effusion** is fluid within the body cavities.
5. Types of edema fluid:
 - a. **Transudate** is edema fluid with low protein content; the specific gravity is less than 1.020.
 - b. **Exudate** is edema fluid with high protein content and cells. The specific gravity is greater than 1.020. Types of exudates include purulent (pus), fibrinous, eosinophilic, and hemorrhagic.
 - c. **Lymphedema** related to lymphatic obstruction leads to accumulation of protein-rich fluid which produces a non-pitting edema.
 - d. **Glycosaminoglycan-rich** edema fluid shows increased hyaluronic acid and chondroitin sulfate, and causes myxedema.
6. Active hyperemia versus congestion (passive hyperemia): an excessive amount of blood in a tissue or organ can accumulate secondary to vasodilatation (active) or diminished venous outflow (passive).

Note

Edema can be localized or generalized, depending on the etiology and severity.

Table 5-1. Properties of Active Hyperemia and Congestion (Passive Hyperemia)

	Active Hyperemia	Congestion (Passive Hyperemia)
Type	Active process	Passive process
Mechanism	Vasodilatation mediated by <ul style="list-style-type: none"> • Vasoactive mediators • Hormones • Neurogenic reflexes 	Decreased venous outflow
Examples	Inflammation Exercise Blushing	Congestive heart failure Deep venous thrombosis Budd-Chiari syndrome

Note

Clotting is a balance between two opposing forces: those favoring the formation of a stable thrombus versus those factors causing fibrinolysis of the clot.

Bridge to Pharmacology

Aspirin irreversibly acetylates cyclooxygenase, preventing platelet production of thromboxane A₂.

In a Nutshell

Bernard-Soulier Syndrome

- Autosomal recessive
- Deficiency of platelet GPIb
- Defective platelet adhesion

In a Nutshell

Glanzmann Thrombasthenia

- Autosomal recessive
- Deficiency of GPIIb-IIIa
- Defective platelet aggregation

HEMOSTASIS AND BLEEDING DISORDERS

1. **Hemostasis** is a sequence of events leading to the cessation of bleeding by the formation of a stable fibrin-platelet hemostatic plug. Hemostasis involves interactions between the vascular wall, platelets, and the coagulation system.
2. Vascular wall injury
 - a. Transient vasoconstriction is mediated by endothelin-1.
 - b. Thrombogenic factors include a variety of processes:

Changes in blood flow cause turbulence and stasis, which favors clot formation. Release of tissue factor from injured cells activates factor VII (extrinsic pathway). Exposure of thrombogenic subendothelial collagen activates factor XII (intrinsic pathway). Release of von Willebrand factor (vWF), which binds to exposed collagen and facilitates platelet adhesion. Decreased endothelial synthesis of antithrombogenic substances (prostacyclin, nitric oxide [NO₂], tissue plasminogen activator, and thrombomodulin).
3. **Platelets** are derived from megakaryocytes in the bone marrow.
 - a. **Step 1: platelet adhesion** occurs when vWF adheres to subendothelial collagen and then platelets adhere to vWF by glycoprotein Ib.
 - b. **Step 2: platelet activation** occurs when platelets undergo a shape change and degranulation occurs. Platelets synthesize thromboxane A₂. Platelets also show membrane expression of the phospholipid complex, which is an important substrate for the coagulation cascade.

Table 5-2. Contents of Platelet Alpha Granules and Dense Bodies

Alpha Granules	Dense Bodies
• Fibrinogen	• ADP (potent platelet aggregator)
• Fibronectin	• Calcium
• Factor V and vWF	• Histamine and serotonin
• Platelet factor 4	• Epinephrine
• Platelet-derived growth factor (PDGF)	

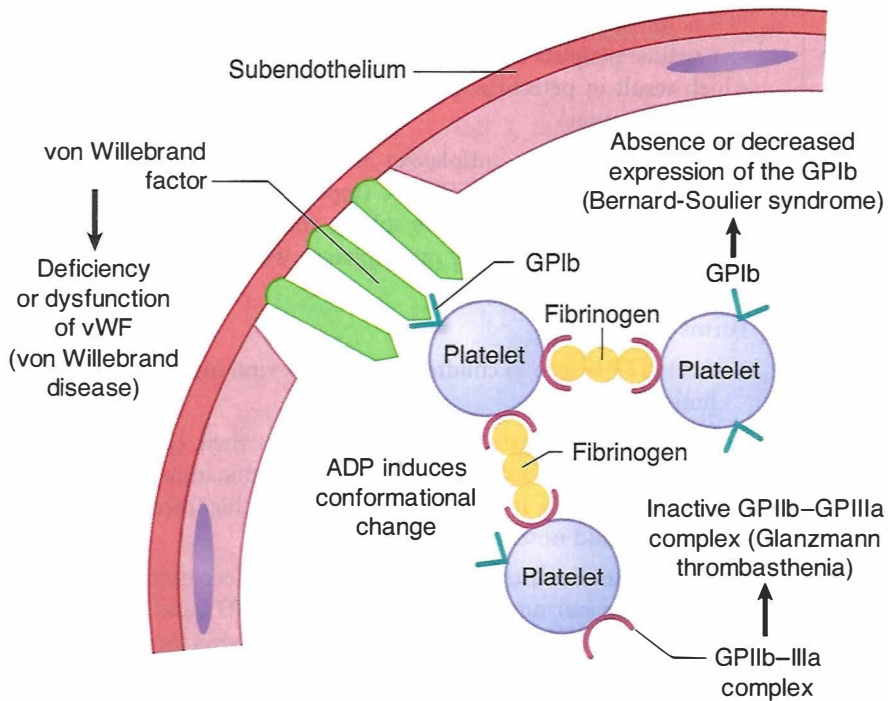


Figure 5-1. Platelet Aggregation

- c. **Step 3: platelet aggregation** occurs when additional platelets are recruited from the bloodstream. ADP and thromboxane A₂ are potent mediators of aggregation. Platelets bind to each other by binding to fibrinogen using GPIIb-IIIa.
- d. Laboratory tests for platelets include platelet count (normal: 150,000 to 400,000) and platelet aggregometry

Table 5-3. Common Platelet Disorders

Thrombocytopenia	Qualitative Defects
Decreased production <ul style="list-style-type: none"> ● Aplastic anemia (drugs, virus, etc.) ● Tumor 	<ul style="list-style-type: none"> ● von Willebrand disease ● Bernard-Soulier syndrome ● Glanzmann thrombasthenia ● Drugs (aspirin) ● Uremia
Increased destruction <ul style="list-style-type: none"> ● Immune thrombocytopenia (ITP) ● Thrombotic thrombocytopenic purpura (TTP) ● Disseminated intravascular coagulation (DIC) ● Hypersplenism 	

4. Immune thrombocytopenia purpura (ITP)

- a. ITP is an immune-mediated attack (usually IgG antiplatelet antibodies) against platelets leading to decreased platelets (thrombocytopenia) which result in petechiae, purpura (bruises), and a bleeding diathesis (e.g., hematomas)
- b. The etiology involves antiplatelet antibodies against platelet antigens such as GPIIb-IIIa and GPIb-IX (type II hypersensitivity reaction), the antibodies are made in the spleen, and the platelets are destroyed peripherally in the spleen by macrophages, which have Fc receptors that bind IgG-coated platelets.
- c. Forms of ITP
 - i. Acute ITP is seen in children following a viral infection and is a self-limited disorder.
 - ii. Chronic ITP is usually seen in women in their childbearing years and may be the first manifestation of systemic lupus erythematosus (SLE). Clinically, it is characterized by petechiae, ecchymoses, menorrhagia, and nosebleeds.
- d. Laboratory studies usually show decreased platelet count and prolonged bleeding time but normal prothrombin time (PT) and partial thromboplastin time (PTT). Peripheral blood smear shows thrombocytopenia with enlarged immature platelets (megathrombocytes). Bone marrow biopsy shows increased numbers of megakaryocytes with immature forms.
- e. The treatment can be with corticosteroids, which decrease antibody production; immunoglobulin therapy, which floods Fc receptors on splenic macrophages; and/or splenectomy, which removes the site of platelet destruction and antibody production.

5. Thrombotic thrombocytopenic purpura (TTP)

- a. Definition: a rare disorder of hemostasis where there is widespread intravascular formation of fibrin-platelet thrombi due to a deficiency/inhibition of the enzyme ADAMTS13, which is responsible for cleaving large multimers of von Willebrand factor.
- b. Clinically, TTP most often affects adult women. The characteristic pentad of signs includes fever, thrombocytopenia, microangiopathic hemolytic anemia (intravascular hemolysis), neurologic symptoms, and renal failure.
- c. Pathology includes widespread formation of platelet thrombi with fibrin (hyaline thrombi) leading to intravascular hemolysis (thrombotic microangiopathy).
- d. Laboratory studies typically show decreased platelet count and prolonged bleeding time but normal PT and PTT. Peripheral blood smear shows thrombocytopenia, schistocytes, and reticulocytosis.

6. **Hemolytic uremic syndrome (HUS)** is a form of thrombotic microangiopathy due to endothelial cell damage that occurs most commonly in children. It typically follows a gastroenteritis (typically due to verotoxin-producing *E. coli* 0157:H7) with bloody diarrhea and has a clinical pentad similar to TTP.

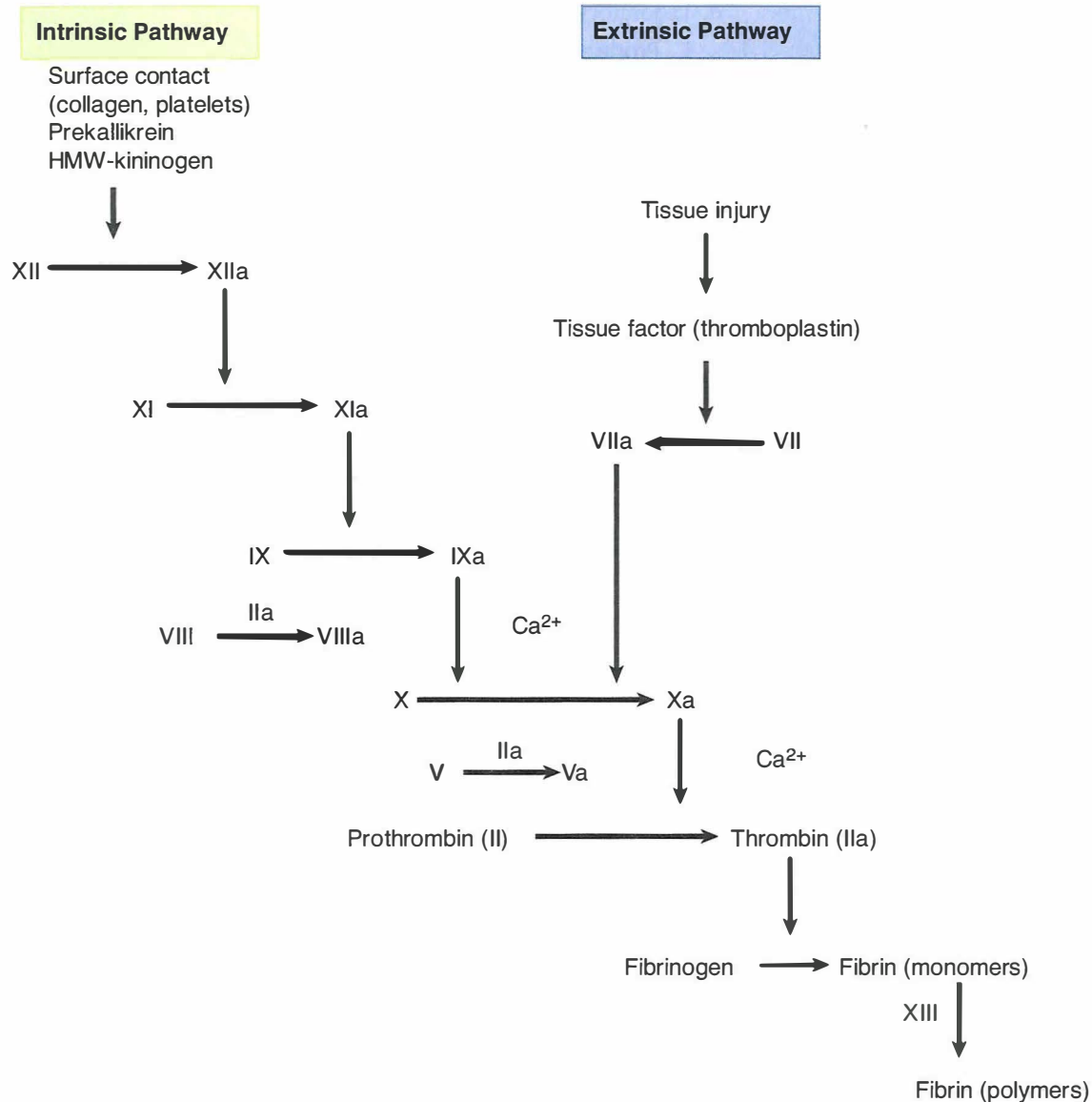


Figure 5-2. Coagulation Cascade

7. Coagulation

a. Coagulation factors

The majority of the clotting factors are produced by the liver. The factors are proenzymes that must be converted to the active form. Some conversions occur on a phospholipid surface, and some conversions require calcium.

- The **intrinsic coagulation pathway** is activated by the contact factors, which include contact with subendothelial collagen, high molecular weight kininogen (HMWK), and kallikrein.
- The **extrinsic coagulation pathway** is activated by the release of tissue factor.

Note

Patients on warfarin therapy should be monitored using prothrombin time (WEPT = warfarin, extrinsic PT), whereas patients on heparin therapy should be monitored using the partial thromboplastin time (HIPTT = heparin, intrinsic PTT).

- d. Laboratory tests for coagulation
 - i. Prothrombin time (PT)

PT tests the extrinsic and common coagulation pathways; more specifically, it tests factors VII, X, V, prothrombin, and fibrinogen. The international normalized ratio (INR) standardizes the PT test so that results throughout the world can be compared.
 - ii. Partial thromboplastin time (PTT)

PTT tests the intrinsic and common coagulation pathways; more specifically, it tests factors XII, XI, IX, VIII, X, V, prothrombin, and fibrinogen.
 - iii. Thrombin time (TT) tests for adequate fibrinogen levels.
 - iv. Fibrin degradation products (FDP) tests the fibrinolytic system (increased with DIC).
8. **Hemophilia A (classic hemophilia)** is an X-linked recessive condition that is due to a deficiency of factor VIII.
 - a. Clinically, hemophilia A predominately affects males. Symptoms are variable dependent on the degree of deficiency. Newborns may develop bleeding at the time of circumcision. Other problems include spontaneous hemorrhage into joints (hemarthrosis), easy bruising and hematoma formation after minor trauma, and severe prolonged bleeding after surgery or lacerations.
 - b. Laboratory studies typically show normal platelet count and normal bleeding time, normal PT and prolonged PTT.
 - c. Treatment: factor VIII concentrate
 9. **Hemophilia B (Christmas disease)** is an X-linked recessive condition due to deficiency of factor IX that is clinically identical to hemophilia A.
 10. **Acquired coagulopathies** include vitamin K deficiency (decreased synthesis of factors II, VII, IX, X, and protein C & S) and *liver disease* (decreased synthesis of virtually all clotting factors).
 11. **Von Willebrand disease** is an inherited bleeding disorder characterized by either a deficiency or qualitative defect in von Willebrand factor.
 - a. vWF is normally produced by endothelial cells and megakaryocytes.
 - b. Clinical features include spontaneous bleeding from mucous membranes, prolonged bleeding from wounds, and menorrhagia in young females, though bleeding into joints is uncommon.
 - c. Laboratory studies show normal platelet count, a prolonged bleeding time, normal PT and often a prolonged PTT. Abnormal platelet response to ristocetin (adhesion defect) is an important diagnostic test.
 - d. Treatment: treat mild cases (type I) with desmopressin (an antidiuretic hormone [ADH] analog), which releases vWF from Weibel-Palade bodies of endothelial cells.
 12. **Disseminated intravascular coagulation (DIC)**
 - a. DIC is always secondary to another disorder.
 - b. Causes are diverse. Obstetric complications can cause DIC because placental tissue factor activates clotting; Gram-negative sepsis can cause DIC because tumor necrosis factor [TNF] activates clotting. Other causes include microorganisms (especially meningococcus and rickettsiae), AML M3 (cytoplasmic granules in neoplastic promyelocytes activate clotting), and adenocarcinomas (mucin activates clotting).

- c. DIC results in widespread microthrombi with consumption of platelets and clotting factors causing hemorrhage.
- d. Laboratory studies show decreased platelet count, prolonged PT/PTT, decreased fibrinogen, and elevated fibrin split products (D-dimers).
- e. Treatment: treat the underlying disorder

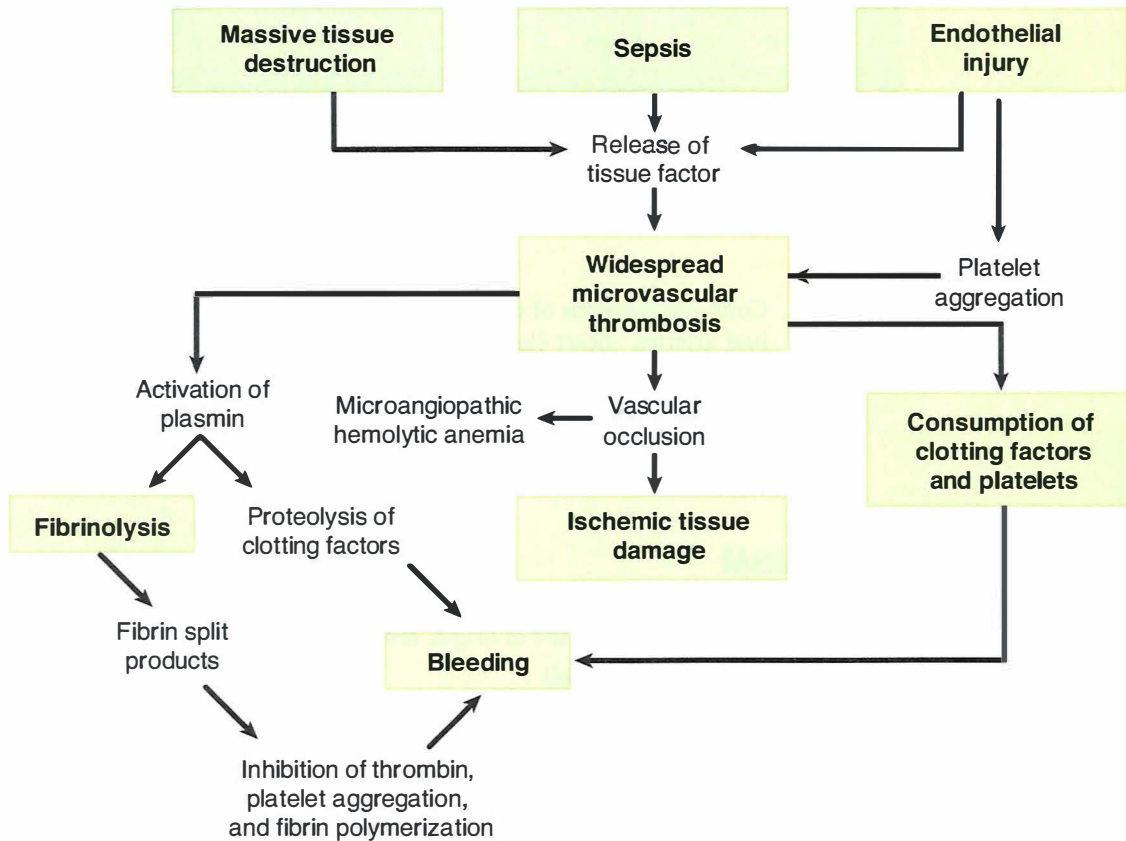


Figure 5-3. Disseminated Intravascular Coagulation

THROMBOSIS

1. General

- a. Thrombosis is the pathologic formation of an intravascular fibrin-platelet thrombus during life.
- b. Factors involved in thrombus formation (**Virchow's triad**)
 - i. Endothelial injury can be due to atherosclerosis, vasculitis, or many other causes.
 - ii. Alterations in laminar blood flow predisposing for DIC occur with stasis of blood (e.g., immobilization); turbulence (e.g., aneurysms); and hyperviscosity of blood (e.g., polycythemia vera).
 - iii. Hypercoagulability of blood can be seen with clotting disorders (factor V Leiden; deficiency of antithrombin III, protein C, or protein S); tissue injury (postoperative and trauma); neoplasia; nephrotic syndrome; advanced age; pregnancy; and oral contraceptives (estrogen increases synthetic activity of the liver, including clotting factors).

Table 5-4. Comparison of a Thrombus with a Blood Clot

	Thrombus	Blood Clot
Location	Intravascular	Extravascular or intravascular (postmortem)
Composition	Platelets	Lacks platelets
	Fibrin	Fibrin
	RBCs and WBCs	RBCs and WBCs
Lines of Zahn	Present	Absent
Shape	Has shape	Lacks shape

- c. Common locations of thrombus formation include coronary and cerebral arteries; heart chambers in atrial fibrillation or post-MI (mural thrombus); aortic aneurysms; heart valves (vegetations); and deep leg veins (DVTs).
- d. Outcomes of thrombosis include vascular occlusion and infarctions; embolism; thrombolysis; and organization and recanalization.

EMBOLISM

1. An embolism is any intravascular mass that has been carried down the bloodstream from its site of origin, resulting in the occlusion of a vessel.
2. **Composition of emboli**
There are many types of emboli. Thromboemboli are most common (98%). Other types include atheromatous emboli (severe atherosclerosis), fat emboli (bone fractures and soft-tissue trauma), and bone marrow emboli (bone fractures and cardiopulmonary resuscitation [CPR]). Gas emboli cause decompression sickness (“the bends” and Caisson disease) when rapid ascent results in nitrogen gas bubbles in the blood vessels. Amniotic fluid emboli are a complication of labor that may result in DIC. Fetal squamous cells are seen in the maternal pulmonary vessels. A few more types of emboli include tumor emboli (metastasis), talc emboli (intravenous drug abuse), and bacterial/septic emboli (infectious endocarditis).
3. **Pulmonary emboli (PE)**
 - a. Pulmonary emboli are often clinically silent and are the most commonly missed diagnosis in hospitalized patients. They are found in almost half of all hospital autopsies.
 - b. Most (95%) pulmonary emboli arise from deep leg vein thrombosis (DVT) in the leg; other sources include the right side of the heart and the pelvic venous plexuses of the prostate and uterus.
 - c. Diagnosis of a pulmonary embolus can be established when \dot{V}/\dot{Q} lung shows a scan \dot{V}/\dot{Q} mismatch. Doppler ultrasound of the leg veins can be used to detect a DVT. Additionally, plasma D-dimer ELISA test is elevated.
 - d. Potential outcomes of PEs
 - i. No sequelae (75%) is the most common outcome and PEs can be asymptomatic or have transient dyspnea/tachypnea. No infarction (dual blood supply) is seen and there is complete resolution in such cases.

Bridge to Anatomy

The dual blood supply to the lungs is from the pulmonary artery and the bronchial arteries.

Clinical Correlate

The classic presentation of pulmonary embolism, which occurs in fewer than 20% of patients, includes hemoptysis, dyspnea, and chest pain.

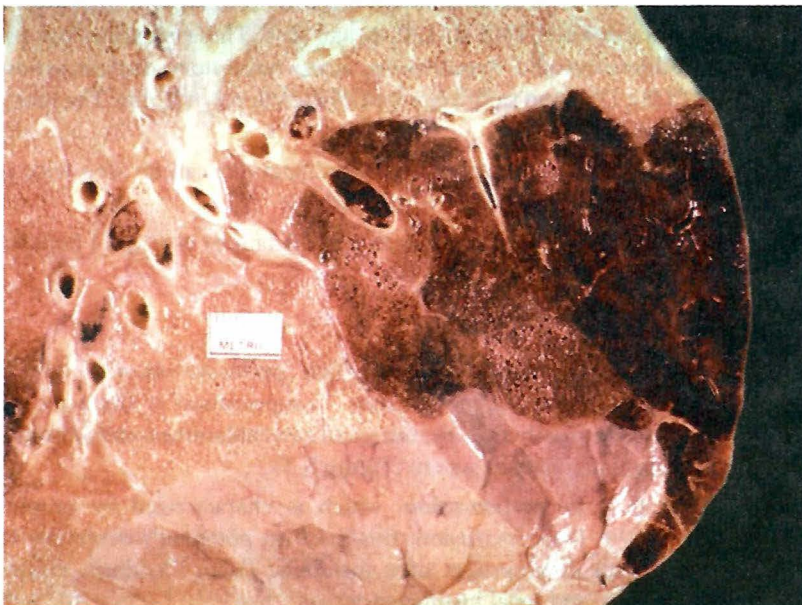- ii. Infarction (15%) is more common in patients with cardiopulmonary compromise. Symptoms include shortness of breath (SOB), hemoptysis, pleuritic chest pain, and pleural effusion. On gross examination, there is typically a hemorrhagic wedge-shaped infarct. The infarction heals by regeneration or scar formation.
- iii. Sudden death (5%) can occur when large emboli lodge in the bifurcation (saddle embolus) or large pulmonary artery branches and obstruct more than 50% of the pulmonary circulation.
- iv. Chronic secondary pulmonary hypertension (3%) is caused by recurrent PEs, which increase pulmonary resistance and lead to secondary pulmonary hypertension.

4. Systemic arterial emboli

Systemic arterial emboli mostly arise in the heart. Most arterial emboli cause infarction, with common sites of infarction including the lower extremities, brain, intestine, kidney, and spleen. **Paradoxical emboli** is the term used for any venous embolus that gains access to the systemic circulation by crossing over from the right to the left side of the heart through a septal defect, most commonly through a patent foramen ovale.

INFARCTION

1. **Infarction** is a localized area of necrosis secondary to ischemia.
 - a. Infarcts have multiple causes. Most infarcts (99%) result from thrombotic or embolic occlusion of an artery or vein. Less common causes include vasospasm and torsion of arteries and veins (e.g., volvulus, ovarian, and testicular torsion).
 - b. Factors that predict the development of an infarct include vulnerability of the tissue to hypoxia, degree of occlusion, rate of occlusion, presence of a dual blood supply or collateral circulation, and oxygen-carrying capacity of the blood (anemia, carbon monoxide poisoning, etc.).
 - c. Common sites of infarction include heart, brain, lungs, intestines, kidneys.



© Katsumi M. Miyai, M.D., Ph.D.; Regents of the University of California.
Used with permission.

Figure 5-4. Wedge-shaped pulmonary infarction

2. On gross examination Infarctions typically have a wedge shape, with the apex of the wedge tending to point to the occlusion.
 - a. **Anemic infarcts** (pale or white color) occur in solid organs with a single blood supply such as the spleen, kidney, and heart.
 - b. **Hemorrhagic infarcts** (red color) occur in organs with a dual blood supply or collateral circulation, such as the lung and intestines, and can also occur with venous occlusion (e.g., testicular torsion).
3. **Microscopic pathology of infarction** can show either coagulative necrosis (most organs) or liquifactive necrosis (brain). The general sequence of tissue changes after infarction is:

ischemia → coagulative necrosis → inflammation → granulation tissue → fibrous scar

SHOCK

1. General

Shock is characterized by vascular collapse and widespread hypoperfusion of cells and tissue due to reduced blood volume, cardiac output, or vascular tone. The cellular injury is initially reversible; if the hypoxia persists, the cellular injury becomes irreversible, leading to the death of cells and the patient.

2. Major causes of shock

- a. **Cardiogenic shock** (pump failure) can be due to myocardial infarction, cardiac arrhythmias, pulmonary embolism, and cardiac tamponade.
- b. **Hypovolemic shock** (reduced blood volume) can be due to hemorrhage, fluid loss secondary to severe burns, and severe dehydration.
- c. **Septic shock** (bacterial infection) is due to Gram-negative septicemia which causes the release of endotoxins (bacterial wall lipopolysaccharides) into the circulation. High levels of endotoxin result in production of cytokines TNF, IL-1, IL-6, and IL-8. These cytokines can trigger vasodilatation and hypotension, acute respiratory distress syndrome (ARDS), DIC, and multiple organ dysfunction syndrome. The mortality rate is 50%.
- d. **Neurogenic shock** (generalized vasodilatation) can be seen with anesthesia and brain or spinal cord injury.
- e. **Anaphylactic shock** (generalized vasodilatation) is a type I hypersensitivity reaction.

3. Stages of shock

- a. Stage I is **compensation**, in which perfusion to vital organs is maintained by reflex mechanisms. Compensation is characterized by increased sympathetic tone, release of catecholamines, and activation of the renin-angiotensin system (Figure 5-5).
- b. Stage II is **decompensation**, which is characterized by progressive decrease in tissue perfusion; this leads to potentially reversible tissue injury with development of a metabolic (lactic) acidosis, electrolyte imbalances, and renal insufficiency.
- c. Stage III is **irreversible** tissue injury and organ failure, ultimately resulting in death.

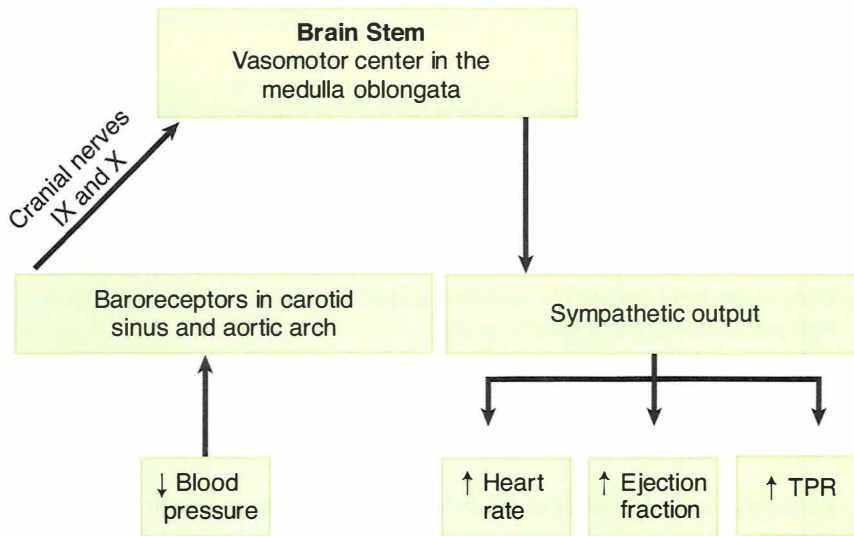


Figure 5-5. Activation of the Baroreceptor Reflex in Shock

4. Pathology

- a. Kidneys in shock show acute tubular necrosis (acute renal failure), which causes oliguria and electrolyte imbalances.
- b. Lungs undergo diffuse alveolar damage (“shock lung”).
- c. Intestines show superficial mucosal ischemic necrosis and hemorrhages, and with prolonged injury may develop sepsis with bowel flora.
- d. The liver undergoes centrilobular necrosis (“shock liver”).
- e. The adrenals undergo the Waterhouse-Friderichsen syndrome, which is commonly associated with meningococcal septic shock and which causes bilateral hemorrhagic infarction and acute adrenal insufficiency.

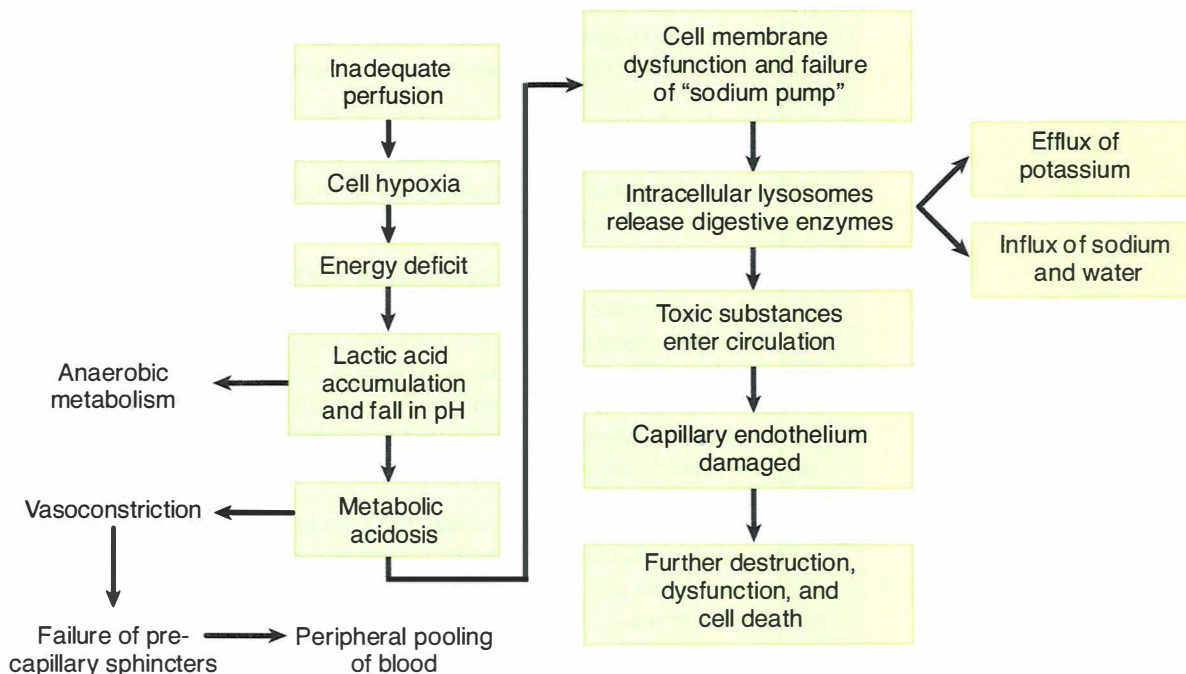


Figure 5-6. Pathophysiology of Shock

Chapter Summary

- Edema is the presence of excess fluid in the intercellular space. Causes of edema include increased hydrostatic pressure, increased interstitial sodium, hypoalbuminemia and decreased colloid pressure, lymphatic obstruction, and increased endothelial permeability. Anasarca is the term used for severe generalized edema.
- Transudates have low protein content and specific gravity, while exudates have high protein content and specific gravity.
- Hyperemia is an excessive amount of blood in a tissue or organ and can be due either to vasodilation (active hyperemia) or diminished venous outflow (passive hyperemia or congestion).
- Hemostasis is the sequence of events leading to cessation of bleeding by the formation of a stable fibrin-platelet hemostatic plug. Vascular wall injury triggers transient vasoconstriction, facilitation of platelet adhesion, and activation of both the extrinsic and intrinsic clotting pathways. Formation of a platelet thrombus occurs when platelets adhere to von Willebrand factor attached to subendothelial collagen, undergo shape change and degranulation, and then aggregate with additional platelets.
- Causes of thrombocytopenia due to decreased platelet production include aplastic anemia and tumor. Causes of thrombocytopenia due to increased platelet destruction include immune thrombocytopenic purpura (ITP), thrombotic thrombocytopenic purpura (TTP), disseminated intravascular coagulation (DIC), and hypersplenism. Causes of qualitative platelet defects include von Willebrand disease, Bernard-Soulier syndrome, Glanzmann thrombasthenia, aspirin, and uremia.
- In immune thrombocytopenic purpura (ITP), antiplatelet antibodies destroy platelets, primarily in the spleen. In thrombotic thrombocytopenic purpura (TTP), there is widespread formation of platelet thrombi with fibrin but without activation of the coagulation system. Hemolytic uremic syndrome (HUS) can clinically resemble TTP and is triggered by *E. coli* strain 0157:H7.
- The intrinsic coagulation pathway is activated by contact factors and is clinically tested with the partial thromboplastin time (PTT). The extrinsic coagulation pathway is activated by the release of tissue factor, and is tested with the prothrombin time (PT), which also tests the common coagulation pathway.
- Hemophilia A is an X-linked recessive deficiency of factor VIII, which is clinically characterized by hemarthrosis, easy bruising, and severe prolonged bleeding after surgery or lacerations. Clinically, hemophilia B closely resembles hemophilia A but is due to deficiency of factor IX. Acquired coagulopathies can be due to vitamin K deficiency and liver disease. Von Willebrand disease is an inherited bleeding disorder characterized by a deficiency or qualitative defect in von Willebrand factor, which facilitates formation of platelet clots.
- Disseminated intravascular coagulation (DIC) can be triggered by a variety of severe medical conditions and results in formation of many microthrombi that consume platelets and clotting factors, leading, in turn, to a superimposed bleeding tendency.

(Continued)

Chapter Summary (*cont'd*)

- Factors involved in thrombus formation include endothelial injury, alterations in laminar blood flow, and hypercoagulability of blood. Thrombi can lead to a spectrum of outcomes, including vascular occlusion and infarction, embolism, thrombolysis, and organization and recanalization.
- The term *embolism* is used for any intravascular mass (solid, liquid, or gas) that has been carried downstream from its site of origin, resulting in occlusion of a vessel. Ninety-eight percent of emboli are thromboemboli, but many other materials have also formed emboli. Pulmonary emboli are a common form of emboli that are often clinically silent but can cause infarction or sudden death. Most pulmonary emboli arise from deep vein thromboses. Systemic arterial emboli usually arise in the heart and may cause infarction in a variety of sites, depending upon where they lodge.
- Infarction is a localized area of necrosis secondary to ischemia. Ninety-nine percent of infarcts result from thrombotic occlusion of an artery or vein. Anemic infarcts occur in organs with a single blood supply, whereas hemorrhagic infarcts occur in organs with a dual blood supply or secondary to venous occlusion. The general sequence of tissue changes after infarction is: ischemia leads to coagulative necrosis, which leads to inflammation, which leads to granulation tissue, which leads to fibrous scar.
- Shock is characterized by vascular collapse and widespread hypoperfusion of cells and tissues due to reduced blood volume, cardiac output, or vascular tone. Major forms of shock include cardiogenic shock, hypovolemic shock, septic shock, and neurogenic shock. Shock has been clinically divided into compensated shock (stage I), decompensated shock (stage II), and irreversible injury (stage III). Different organs show distinctive microscopic patterns in shock.

DISORDERS INVOLVING AN EXTRA AUTOSOME

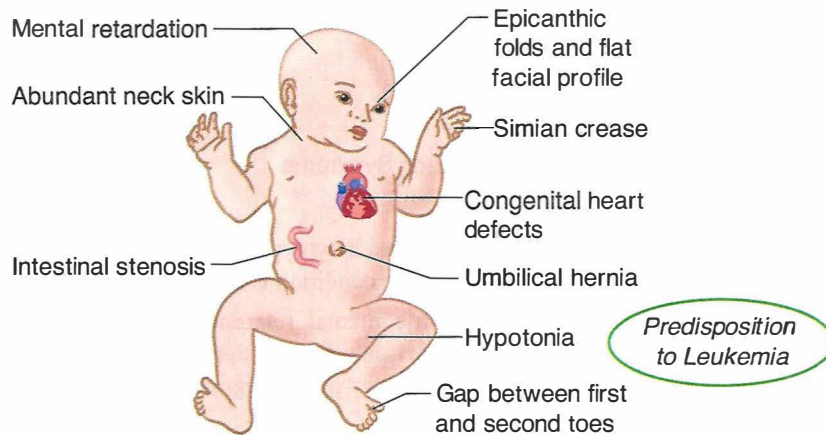


Figure 6-1. Down Syndrome

1. Down syndrome (trisomy 21).

- a. The **karyotype** is 47 XX or XY +21 and Down's syndrome is the most common of the chromosomal disorders (incidence: 1 in 700 births). The risk increases with maternal age. The pathogenesis involves meiotic nondisjunction (95%), Robertsonian translocation (4%), or mosaicism due to mitotic nondisjunction during embryogenesis (1%).
- b. **Clinical findings** can include severe mental retardation (most common cause of genetic mental retardation); mongoloid facial features (flat face, low-bridged nose, and epicanthal folds); Brushfield spots (speckled appearance of the iris); muscular hypotonia; broad short neck; palmar (simian) crease; and congenital heart defects. Endocardial cushion defect, if present, leads to the formation of an atrioventricular canal (a common connection between all 4 chambers of the heart). Additional clinical problems that can develop include duodenal atresia ("double-bubble" sign); Hirschsprung disease; increased risk (15–20 fold) of acute lymphoblastic leukemia (ALL); and Alzheimer disease (by age 40 virtually all will develop Alzheimer disease).
- c. Down syndrome can be **screened prenatally** by assaying maternal serum levels of α -fetoprotein, chorionic gonadotropin, and unconjugated estriol.

Note

Robertsonian Translocation

Defined as a translocation involving two acrocentric chromosomes with the break points occurring close to the centromeres. This results in an extremely large chromosome and a tiny one, which is typically lost.

Note

Mosaicism is defined as the presence of two or more populations of cells within an individual.

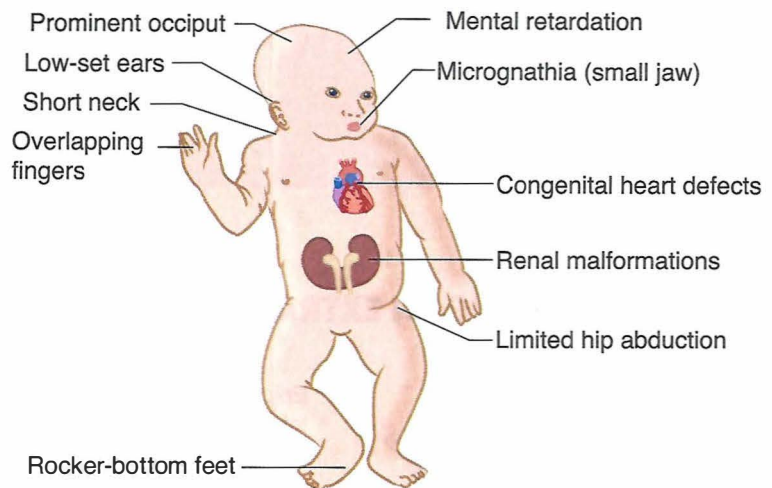


Figure 6-2. Edwards Syndrome

2. **Edwards syndrome** (trisomy 18) has karyotype 47 XX or XY +18; the risk increases with maternal age; and the condition is caused by nondisjunction.
 - a. **Clinical findings** can include mental retardation; low-set ears and micrognathia; congenital heart defects; overlapping flexed fingers; and rocker-bottom feet. There is a very poor prognosis due to severe congenital malformations.

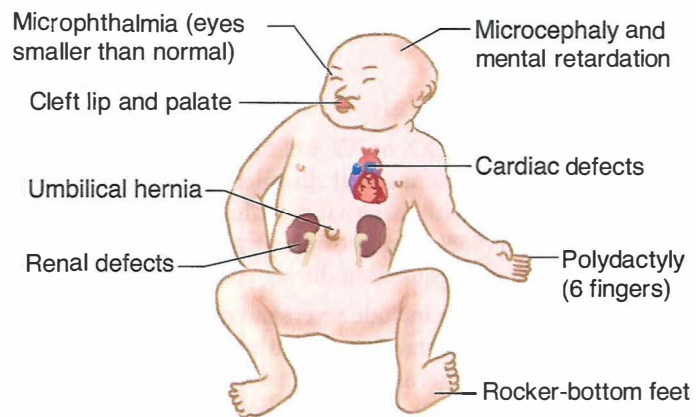


Figure 6-3. Patau Syndrome

3. **Patau syndrome** (trisomy 13) has karyotype 47 XX or XY +13; the risk increases with maternal age; and the condition is caused by nondisjunction.
 - a. **Clinical findings** can include mental retardation; cleft lip and/or palate; cardiac defects; renal abnormalities; microcephaly; holoprosencephaly; and polydactyly. The very poor prognosis is due to severe congenital malformations.

DISORDERS INVOLVING CHROMOSOMAL DELETIONS

1. **Cri du chat syndrome** has karyotype 46 XX or XY, 5p– and is due to deletion of the short arm of chromosome 5.
 - a. **Clinical findings** include a characteristic high-pitched catlike cry; mental retardation; congenital heart disease; and microcephaly.
2. **Microdeletions** of which you should be aware include 13q14 (the retinoblastoma gene) and 11p13 (WAGR complex [Wilms tumor, Aniridia, Genitourinary anomalies, and mental Retardation]).

DISORDERS INVOLVING SEX CHROMOSOMES

The following conditions involving sex chromosomes are now called disorders of sexual development (differentiation).

1. **Klinefelter syndrome** has karyotype 47 XXY; is caused by meiotic nondisjunction; and is a common cause of male hypogonadism.
 - a. **Laboratory studies** show elevated FSH and LH with low levels of testosterone.
 - b. **Clinical findings** include testicular atrophy, infertility due to azoospermia, eunuchoid body habitus, high-pitched voice; female distribution of hair; and gynecomastia.
2. **Turner syndrome** has karyotype 45 XO and is a common cause of female hypogonadism. The second X chromosome is necessary for oogenesis and normal development of the ovary. No Barr body is present on histological examination of cells.
 - a. **Clinically**, Turner syndrome patients fail to develop secondary sex characteristics and have short stature with widely spaced nipples. Other features related to the abnormal sexuality include gonadal dysgenesis with atrophic “streaked” ovaries; primary amenorrhea; and infertility. Clinical features involving other organ systems include cystic hygroma and webbing of the neck; hypothyroidism; congenital heart disease (preductal coarctation of the aorta and bicuspid aortic valve); and hydrops fetalis. Females with 45,X; 46,XY mosaicism are at risk for gonadoblastoma.

Note

The presence of a Y chromosome determines male phenotype due to the presence of the testes-determining factor gene (also called the sex-determining region Y [SRY]) on the Y chromosome.

In a Nutshell

Lyon's Hypothesis of X-Inactivation

- Only one X is genetically active.
- The other X chromosome is inactivated (becomes the Barr body) in the blastocyst stage of development.
- Females are mosaics.
- Either the maternal or paternal X chromosome is inactivated at random.

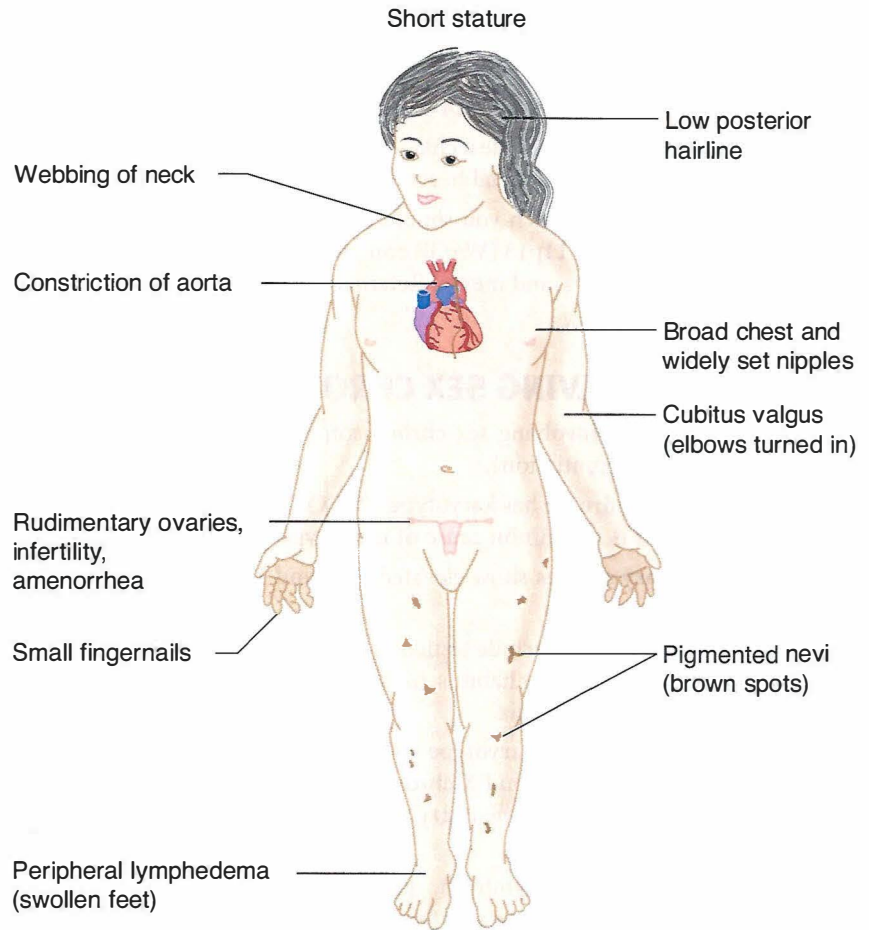


Figure 6-4. Turner Syndrome

HERMAPHRODITISM

The preferred term for hermaphroditism is **intersex disorders/conditions**.

1. **Determination of sex** can be established by a variety of methods that do not necessarily completely agree.
 - a. **Karyotypic** (genetic) sex refers to which sex chromosomes an individual has; the presence of a Y chromosome results in testicular development.
 - b. **Gonadal** sex refers to the presence of ovarian or testicular tissue.
 - c. **Ductal sex** refers to the presence of Müllerian (female – Fallopian tube, uterus, cervix, and upper portion of vagina) or Wolffian (male – epididymis, vas deferens, seminal vesicles, and ejaculatory ducts) duct adult derivatives.
 - d. **Phenotypic** (genital) sex refers to the external appearance of the genitalia.
2. A **true hermaphrodite** is someone who has both ovarian and testicular tissue, which is an extremely rare condition. The genetic sex of a true hermaphrodite may be 46 XX, 46 XY, 45 X/XY (mosaics). The gonadal sex can be either an ovary on one side and testis on the other, or ovotestes, in which there is a gonad with both testicular and ovarian tissue. The ductal sex is often mixed, and the phenotypic sex shows ambiguous genitalia.
3. **Female pseudohermaphroditism** refers to an individual with normal female (46 XX) genetic sex; normal female internal organs, implying

normal gonadal and ductal sex; and abnormal phenotypic sex due to ambiguous or virilized external genitalia. Female pseudohermaphroditism occurs with exposure of a female fetus to androgens in utero, by congenital adrenal hyperplasia; androgen-producing tumors (ovarian Sertoli-Leydig cell tumor); or exogenous androgens.

4. **Male pseudohermaphroditism** has normal male (46 XY) genetic sex; male gonadal and ductal sex because testes are present; abnormal phenotypic sex with ambiguous or female genitalia. Testicular feminization (complete androgen insensitivity syndrome) is the most common cause of male pseudohermaphroditism and is due to mutation of the androgen receptor (Xq11-12).

MENDELIAN DISORDERS

1. **Mendelian disorders** are characterized by single gene mutations. Common types of mutations include point mutations and frameshift mutations.
 - a. **Point mutations** occur with a single nucleotide base substitution, which may produce a variety of effects. The form of point mutation called synonymous mutation (silent mutation) occurs when a base substitution results in a codon that codes for the same amino acid. The form of point mutation called missense mutation occurs when a base substitution results in a new codon and a change in amino acids. The form of point mutation called a nonsense mutation occurs when a base substitution produces a stop codon and therefore produces a truncated protein.
 - b. **Frameshift mutations** occur when insertion or deletion of bases leads to a shift in the reading frame of the DNA.
 - c. The **location of a mutation** will alter its potential effects. Mutations involving coding regions of DNA may result in abnormal amino acid sequences; decreased production of the protein; truncated or abnormally folded protein; or altered or lost function of the protein. Mutations of promoter or enhancer regions may interfere with transcription factors, resulting in decreased transcription of the gene.
 - d. **Patterns of inheritance** for genetic diseases show wide variation, and the genetic pattern of a disease may be classified as autosomal dominant; autosomal recessive; X-linked recessive; X-linked dominant; triplet repeat mutations; genetic imprinting; mitochondrial; or multifactorial.

Table 6-1. General Characteristics of Autosomal Dominant and Recessive Diseases

	Autosomal Recessive	Autosomal Dominant
Onset	Early uniform onset (infancy/childhood)	Variable onset (may be delayed into adulthood)
Penetrance	Complete penetrance	Incomplete penetrance with variable expression
Mutation	Usually an enzyme protein	Usually a structural protein or receptor
Requires	Mutation of both alleles	Mutation of one allele

Bridge to Biochemistry

The majority of cystic fibrosis cases result from deletion of phenylalanine at position 508 (Delta F508), which interferes with proper protein folding and the post-translational processing of oligosaccharide side chains. The abnormal chloride channel protein is degraded by the cytosolic proteasome complex rather than translocated to the cell membrane.

AUTOSOMAL RECESSIVE DISORDERS

1. **Cystic fibrosis** (mucoviscidosis) is the most common lethal genetic disorder in Caucasians. It is due to mutation of the chloride channel protein, cystic fibrosis transmembrane conductance regulator (CFTR), whose CFTR gene is located on chromosome 7 and most commonly has been damaged by a deletion of the amino acid phenylalanine at position 508 ($\Delta F508$). The defective chloride channel protein leads to abnormally thick viscous mucous, which obstructs the ducts of exocrine organs.
 - a. The **distribution of disease** reflects the distribution of eccrine sweat glands and exocrine glands. In the lungs, cystic fibrosis may cause recurrent pulmonary infections with *P. aeruginosa* and *S. aureus*; chronic bronchitis; and bronchiectasis. In the pancreas; cystic fibrosis may cause plugging of pancreatic ducts resulting in atrophy and fibrosis; and pancreatic insufficiency leading to fat malabsorption, malodorous steatorrhea, and deficiency of fat-soluble vitamins. In the male reproductive system, cystic fibrosis may be associated with absence or obstruction of the vas deferens and epididymis, which often leads to male infertility. In the liver, plugging of the biliary canaliculi may result in biliary cirrhosis. In the GI tract, the thick secretions may cause small intestinal obstruction (meconium ileus). The salivary glands do not appear to be significantly affected in cystic fibrosis, except for more mucus in the ducts.
 - b. The **diagnosis** of cystic fibrosis can be established with a sweat test (elevated NaCl) or DNA probes. The mean survival in cystic fibrosis is 30 years, with the most common cause of death being pulmonary infections.

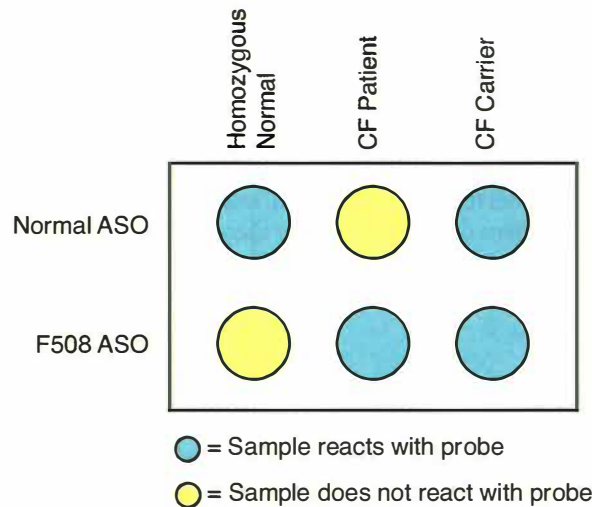


Figure 6-5. The Use of Allele-Specific Oligonucleotide (ASO) Probes for Cystic Fibrosis

Bridge to Biochemistry

Phenylalanine hydroxylase converts phenylalanine into tyrosine.

2. **Phenylketonuria** (PKU) is due to deficiency of phenylalanine hydroxylase, resulting in toxic levels of phenylalanine.
 - a. **Clinically**, affected children are normal at birth but, if undiagnosed and untreated, develop profound mental retardation by 6 months of age. The lack of tyrosine causes light-colored skin and hair, since melanin is a tyrosine derivative. Affected children may have a mousy or musty odor to the sweat and urine (secondary to metabolite [phenylacetate] accumulation).

- b. **Screening** for phenylketonuria is done at birth and treatment is with dietary restriction of phenylalanine, including avoidance of the artificial sweetener aspartame.
- c. A genetic variant, **benign hyperphenylalaninemia**, has partial enzyme deficiency with mildly increased levels of phenylalanine which are insufficient to cause mental retardation.
3. **Alkaptonuria** (ochronosis) occurs when deficiency of homogentisic acid oxidase results in the accumulation of homogentisic acid. The homogentisic acid has an affinity for connective tissues (especially cartilage), resulting in a black discoloration (as a consequence of oxidation of homogentisic acid).
- a. **Clinical features** include urine that is initially pale yellow, but which turns black upon standing, and black-stained cartilage, which causes discoloration of the nose and ears, and also predisposes for early onset of degenerative arthritis.
4. **Albinism** is due to a lack of the enzyme tyrosinase that is needed for melanin production. Affected individuals show deficiency of melanin pigmentation in the skin, hair follicles, and eyes (oculocutaneous albinism), with resulting increased risk of basal cell and squamous cell carcinomas.
5. The **glycogen storage diseases** are a group of rare diseases that have in common a deficiency in an enzyme necessary for the metabolism of glycogen, which results in the accumulation of glycogen in the liver, heart, and skeletal muscle.
- a. **Type I** (von Gierke disease) is due to a deficiency of *glucose-6-phosphatase*, and is characterized clinically by hepatomegaly and hypoglycemia.
- b. **Type II** (Pompe disease) is due to a deficiency of *lysosomal α -1,4-glucosidase (acid maltase)*, and is characterized clinically by hepatomegaly, skeletal muscle hypotonia, cardiomegaly, and death from cardiac failure by age 2 years.
- c. **Type V** (McArdle syndrome) is due to a deficiency of *muscle glycogen phosphorylase*, and is characterized clinically by exercise-induced muscle cramps.
6. **Tay-Sachs disease** is due to a deficiency of hexosaminidase A (due to mutation of HEXA gene on chromosome 15), which leads to the accumulation of GM2 ganglioside in the lysosomes of the CNS and retina. Tay-Sachs disease is common in Ashkenazi Jews (1 in 30 carrier rate).
- a. The **distribution of disease** involves the retina (cherry-red spot due to accentuation of the macula) and central nervous system (dilated neurons with cytoplasmic vacuoles). Affected children are normal at birth, but by 6 months show onset of symptoms (progressive mental deterioration and motor incoordination) that progress to death by age 2–3 years.
- b. **Electron microscopy** shows distended lysosomes with whorled membranes; the diagnosis can also be established with enzyme assays and DNA probes.

Note

Lysosomal Storage Diseases

Defined as a deficiency of a lysosomal enzyme (acid hydrolase), which leads to the accumulation of a complex substrate within the lysosome leading to enlarged cells that become dysfunctional

- Tay-Sachs
- Niemann-Pick
- Gaucher
- Mucopolysaccharidosis
- Fabry
- Metachromatic leukodystrophy

Table 6-2. Lysosomal Storage Diseases

Disease	Enzyme Deficiency	Accumulating Substance
Tay-Sachs disease	Hexosaminidase A	GM ₂ ganglioside
Niemann-Pick disease	Sphingomyelinase	Sphingomyelin
Gaucher disease	Glucocerebrosidase	Glucocerebroside
Fabry disease	α-galactosidase A	Ceramide trihexoside
Metachromatic leukodystrophy	Aryl sulfatase A	Sulfatide
Hurler syndrome	α-L-iduronidase	Dermatan sulfate Heparan sulfate
Hunter syndrome	L-iduronosulfate sulfatase	Dermatan sulfate Heparan sulfate

7. **Niemann-Pick disease** is due to a deficiency of sphingomyelinase, which leads to the accumulation of sphingomyelin within the lysosomes of the CNS and reticuloendothelial system (monocytes and macrophages located in reticular connective tissue). Niemann-Pick is common in Ashkenazi Jews (note similarity to Tay-Sachs disease).
 - a. The **distribution of disease** involves the retina (cherry-red spot, note similarity to Tay-Sachs disease), central nervous system (distended neurons with a foamy cytoplasmic vacuolization; note similarity to Tay-Sachs disease); and reticuloendothelial system (hepatosplenomegaly, lymphadenopathy, and bone marrow involvement; note difference from Tay-Sachs disease).
 - b. **Affected children** are normal at birth, but have onset of symptoms (massive splenomegaly and lymphadenopathy; progressive mental and motor manifestations) by 6 months, with death by age 2 years.
 - c. **Electron microscopy** shows distended lysosomes containing lamellated figures (“zebra bodies”), and the diagnosis can also be established with biochemical assay of sphingomyelinase activity and DNA probes.
8. **Gaucher disease** is the most common lysosomal storage disorder. Deficiency of glucocerebrosidase leads to the accumulation of glucocerebroside, predominately in the lysosomes of the reticuloendothelial system (monocytes and macrophages located in reticular connective tissue).
 - a. **Type I** represents 99% of cases and presents in adulthood with hepatosplenomegaly; thrombocytopenia/pancytopenia secondary to hypersplenism; lymphadenopathy; and bone marrow involvement that may lead to bone pain, deformities, and fractures. Central nervous system manifestations occur in **types II and III**.
 - b. The characteristic **Gaucher cells** are enlarged macrophages with a fibrillary (tissue-paper-like) cytoplasm. The diagnosis can be established with biochemical enzyme assay of glucocerebrosidase activity.
9. **Mucopolysaccharidosis (MPS)** is a group of lysosomal storage disorders characterized by deficiencies in the lysosomal enzymes required for the degradation of mucopolysaccharides (glycosaminoglycans).
 - a. **Clinical features** include mental retardation, cloudy cornea; hepatosplenomegaly, skeletal deformities and coarse facial features, joint abnormalities, and cardiac lesions. MPS I (Hurler syndrome) is the severe form and is due to deficiency of α-L-iduronidase. MPS II (Hunter syndrome) is a milder form; it shows X-linked recessive inheritance and is due to a deficiency of L-iduronosulfate sulfatase.

AUTOSOMAL DOMINANT DISORDERS

1. **Familial hypercholesterolemia** is the most common inherited disorder (with incidence of 1 in 500) and is due to a mutation in the low density lipoprotein (LDL) receptor gene on chromosome 19.
 - a. There are five major **classes of mutations**.
 - Class I has no LDL receptor synthesis.
 - Class II has a defect in transport out of the endoplasmic reticulum.
 - Class III has a defect in LDL receptor binding.
 - Class IV has a defect in ability to internalize bound LDL.
 - Class V has a defect in the recycling of the LDL receptor. The mutations in the LDL receptor cause increased levels of circulating cholesterol, loss of feedback inhibition of HMG-coenzyme A (HMG-CoA) reductase, and increased phagocytosis of LDL by macrophages.
 - b. **Clinical features** include elevated serum cholesterol (heterozygotes have elevations of 2 to 3 times the normal level and homozygotes have elevations of 5 to 6 times the normal level), skin xanthomas (collections of lipid-laden macrophages), xanthelasma around the eyes, and premature atherosclerosis (homozygotes often develop myocardial infarctions in late teens and twenties).
2. **Marfan syndrome** is due to a mutation of the **fibrillin** gene (FBN1) on chromosome 15q21. Fibrillin is a glycoprotein that functions as a scaffold for the alignment of elastic fibers.
 - a. **Clinical features** include skeletal changes (tall, thin build with long extremities, hyperextensible joints, pectus excavatum [inwardly depressed sternum], and pectus carinatum [pigeon breast]) and abnormal eyes (ectopia lentis, characterized by bilateral subluxation of the lens). The cardiovascular system is also particularly vulnerable; it may show cystic medial degeneration of the media of elastic arteries with a loss of elastic fibers and smooth muscle cells with increased risk of dissecting aortic aneurysm (a major cause of death), dilatation of the aortic ring potentially leading to aortic valve insufficiency, and/or mitral valve prolapse.
3. **Ehlers-Danlos syndrome** (EDS) is a group of inherited connective tissue diseases that have in common a defect in collagen structure or synthesis. Clinically, the disease causes hyperextensible skin that is easily traumatized and hyperextensible joints secondary to effects on the joints and adjacent ligaments.
 - a. There are **10 variants** with different modes of inheritance, of which the most important are:
 - EDS Type 3 (autosomal dominant with unknown genetic defect; most common type)
 - EDS Type 4 (autosomal dominant defect in the type III collagen gene)
 - EDS Type 6 (autosomal dominant defect in the lysyl hydroxylase gene, which is the enzyme responsible for hydroxylation of lysine residues)
 - EDS Type 9 (X-linked recessive mutation of copper-binding protein on X chromosome, leading to low levels of ceruloplasmin and serum copper; and to decreased activity of lysyl oxidase, which is copper dependent and necessary for cross-linking of collagen fibers).
 - b. **Complications** of Ehlers-Danlos include poor wound healing, joint dislocations; diaphragmatic hernias (EDS Type 1), retinal detachment and kyphoscoliosis (EDS Type 6), and arterial or colonic rupture (EDS Type 4).

Bridge to Biochemistry

HMG-CoA reductase is the rate-limiting enzyme in the synthesis of cholesterol. Normally, cholesterol represses the expression of the HMG-CoA reductase gene (negative feedback).

Note

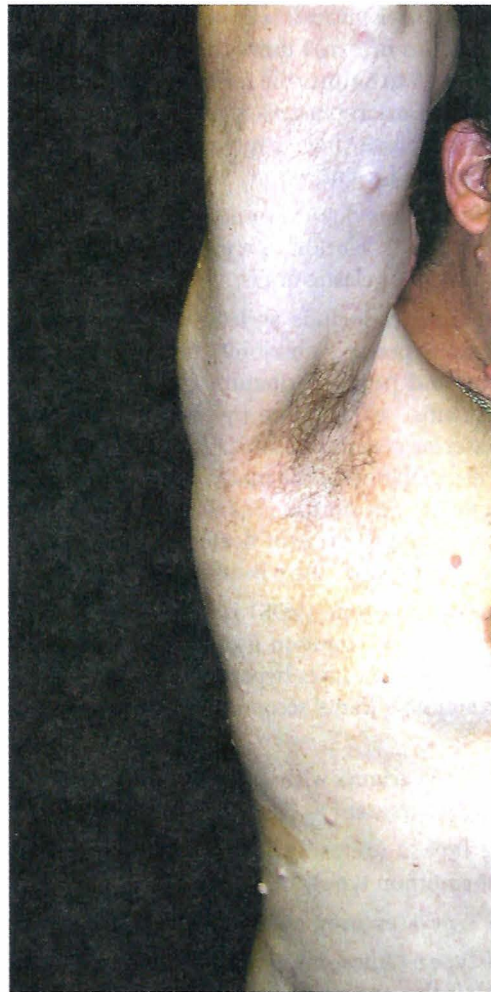Disorders of collagen biosynthesis include scurvy, osteogenesis imperfecta, Ehlers-Danlos syndrome, Alport syndrome, and Menkes disease.

Clinical Correlate

Menkes disease is an X-linked recessive condition that is caused by mutations in the gene encoding a Cu^{2+} efflux protein. Cells from an affected individual accumulate high concentrations of Cu^{2+} that cannot be released.

4. Neurofibromatosis

- a. Type 1 (**von Recklinghausen disease**) neurofibromatosis accounts for 90% of cases of neurofibromatosis, with an incidence of 1 in 3,000. The condition is due to a mutation of the tumor suppressor gene NF-1 located on chromosome 17 (17q11.2). The normal gene product (neurofibromin) inhibits p21 ras oncoprotein. Type 1 neurofibromatosis characteristically has multiple neurofibromas, benign tumors of peripheral nerves that are often numerous and may be disfiguring. The plexiform variant of the neurofibromas are diagnostic. Rarely (3%), malignant transformation of a neurofibroma may occur. Other clinical features include pigmented skin lesions (6 or more “cafe-au-lait spots” that are light brown macules usually located over nerves); pigmented iris hamartomas (Lisch nodule); and increased risk of meningiomas and pheochromocytoma (dark/dusky-colored tumor).



© Richard P. Usatine, M.D. Used with permission.

Figure 6-6. Multiple Subcutaneous Neural Tumors of Neurofibromatosis

- b. Type 2 (**bilateral acoustic**) neurofibromatosis accounts for 10% of cases of neurofibromatosis, with an incidence of 1 in 45,000. In this form of neurofibromatosis, the tumor suppressor gene: is NF-2 (22q12.2) located on chromosome 22. The normal gene product (merlin) is a critical regulator of contact-dependent inhibition of proliferation. Clinical features include bilateral acoustic neuromas; neurofibromas

and cafe-au-lait spots (usually both in smaller numbers than in type 1), and increased risk of meningioma and ependymomas.

5. **von Hippel-Lindau disease** is due to a mutation of the tumor suppressor gene *VHL*, which is located on chromosome 3p (3p26-p25). The normal gene product's main action is to tag proteins (e.g., hypoxia inducible factor 1a [a transcription factor that induces the expression of angiogenesis factors]) with ubiquitin for degradation.
 - a. **Clinical manifestations** can include retinal hemangioblastoma (von Hippel tumor); hemangioblastomas of the cerebellum, brain stem, and spinal cord (Lindau tumor); cysts of the liver, pancreas, and kidneys; and multiple bilateral renal cell carcinomas.

X-LINKED RECESSIVE CONDITIONS

1. In **X-linked recessive conditions**, males with a mutant recessive gene on the X chromosome have the condition while daughters of affected males are obligate carriers, who in many situations are asymptomatic. Sons of affected males do not carry the mutation. Daughters of carrier females may be either normal or carriers. Sons of carrier females may be affected or normal (because males are hemizygous for the X chromosome).
2. **Lesch-Nyhan syndrome** results from deficiency of hypoxanthine-guanine phosphoribosyltransferase (HGPRT), which impairs salvaging of the purines hypoxanthine and guanine. Clinical features include mental retardation, hyperuricemia, and self-mutilation.
3. **Testicular feminization** is an androgen insensitivity that causes failure of normal masculinization of external genitalia of XY males.
4. In **chronic granulomatous disease**, a defective NADPH oxidase enzyme complex prevents phagocytes from producing superoxide bursts to kill bacteria. Clinical features include recurrent infections, hypergammaglobulinemia, hepatosplenomegaly, and lymphadenopathy.
5. In **Bruton agammaglobulinemia**, defective Bruton tyrosine kinase (Btk) at band Xq21.3 causes complete failure of immunoglobulin production characterized clinically by complete absence of antibodies in serum and recurrent bacterial infections.

X-LINKED DOMINANT CONDITIONS

1. **X-linked dominant conditions** are similar to X-linked recessive, but both males and females show disease. An example is Alport syndrome, which is a hereditary glomerulonephritis with nerve deafness.

TRIPLET REPEAT MUTATIONS

1. **Fragile X syndrome** is due to triplet nucleotide repeat mutations, so that the nucleotide sequence CGG repeats typically hundreds to thousands of times. The mutation occurs in the FMR-1 gene (familial mental retardation-1 gene) on the X chromosome (Xq27.3), and the disease behaves as an X-linked dominant disease that causes mental retardation in all affected males and 50% of female carriers. The characteristic phenotype includes elongated face with a large jaw, large everted ears, and macroorchidism. The condition can be diagnosed with DNA probe analysis.
2. **Huntington disease** is due to a triplet repeat mutation (CAG) of the Huntington gene that produces an abnormal protein (huntingtin), which is

Note

Most common genetic causes of mental retardation:

- Down syndrome
- Fragile X syndrome

Note

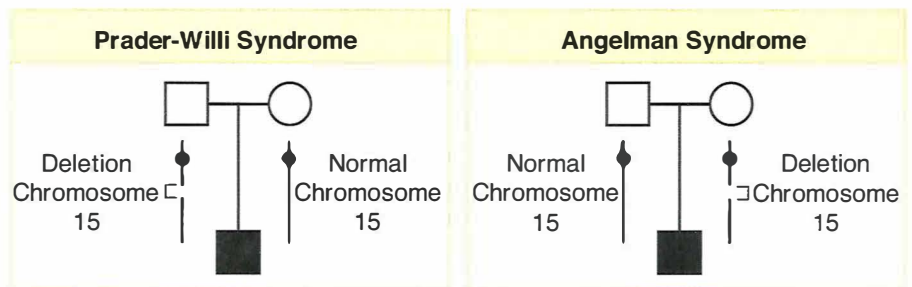
Triplet repeat expansion can occur in a coding region (Huntington and spinobulbar muscular atrophy) or in an untranslated region of the gene (fragile X and myotonic dystrophy).

neurotoxic and causes atrophy of caudate nucleus. Huntington disease has an early onset (age range: 20–50 years) of progressive dementia with choreiform movements.

GENOMIC IMPRINTING

1. **Genomic imprinting** refers to differential expression of genes based on chromosomal inheritance from maternal versus paternal origin. In Prader-Willi syndrome, microdeletion on paternal chromosome 15 {del(15)(q11;q13)} causes mental retardation, obesity, hypogonadism, and hypotonia. In contrast, in Angelman syndrome (“happy puppet” syndrome), microdeletion on maternal chromosome 15 {del(15)(q11;q13)} causes mental retardation, seizures, ataxia, and inappropriate laughter.

Genomic imprinting is thought to also potentially play a role in Huntington disease, neurofibromatosis, and myotonic dystrophy.



The inheritance of a deletion on chromosome 15 from a male produces Prader-Willi syndrome, whereas inheritance of the same deletion from a female produces Angelman syndrome.

Figure 6-7. Genomic Imprinting

MITOCHONDRIAL DNA DISORDERS

Mitochondrial DNA codes for mitochondrial oxidative phosphorylation enzymes; inheritance is only from mother to child, because only the ovum contributes mitochondria to the zygote. You should be aware of 2 examples of mitochondrial DNA disorders:

- **Leber hereditary optic neuropathy** causes loss of retinal cells, which leads to central vision loss.
- **Myoclonic epilepsy** has a pattern of seizures with abrupt jerks.

MULTIFACTORIAL INHERITANCE

1. **Multifactorial inheritance** refers to disease caused by a combination of multiple minor gene mutations and environmental factors. Examples include open neural tube defects and type 2 diabetes mellitus.

Chapter Summary

- Disorders involving an extra autosomal chromosome include Down syndrome, Edwards syndrome, and Patau syndrome. Down syndrome (trisomy 21) is the most common of the chromosomal disorders and is characterized by severe mental retardation, mongoloid facial features, hypotonia, and palmar creases. Serious complications of Down syndrome include congenital heart disease (endocardial cushion defects), duodenal atresia, Hirschsprung disease, acute lymphoblastic leukemia, and early onset of Alzheimer disease. Edwards syndrome (trisomy 18) is characterized by mental retardation, low-set ears, micrognathia, congenital heart defects, overlapping flexed fingers, and rocker-bottom feet. Patau syndrome (trisomy 13) is characterized by mental retardation, cleft lip and/or palate, cardiac defects, renal abnormalities, microcephaly, and polydactyly.
- Chromosomal deletions can also cause genetic disease. Cri du chat syndrome (5p-) is a chromosomal deletion syndrome characterized by a high-pitched, catlike cry; mental retardation; congenital heart disease, and microcephaly. Microdeletions are associated with retinoblastoma and Wilms tumor.
- Klinefelter syndrome and Turner syndrome are important disorders of sex chromosomes. Klinefelter syndrome (47 XXY) is a common cause of male hypogonadism and is characterized by testicular atrophy, infertility due to azoospermia, eunuchoid body habitus, high-pitched voice, female distribution of hair, and gynecomastia. Turner syndrome (45 XO) is a common cause of female hypogonadism and is characterized by absent Barr bodies, failure to develop secondary sex characteristics, short stature, atrophic “streak” ovaries, primary amenorrhea, infertility, cystic hygroma and webbing of the neck, hypothyroidism, congenital heart disease (preductal coarctation of the aorta, bicuspid aortic valve), and hydrops fetalis.
- True hermaphrodites have both ovarian and testicular tissue and are exceptionally rare. Female pseudohermaphrodites are genetically normal females with normal female internal organs but ambiguous or virilized external genitalia, usually as a result of exposure to endogenous or exogenous androgens. Male pseudohermaphrodites are genetically normal males with testes and ambiguous or female external genitalia; the most common cause is testicular feminization, due to a genetically defective androgen receptor.
- Mendelian disorders are characterized by single gene mutations, which may be either point mutations or frameshift mutations. These mutations may produce autosomal dominant, autosomal recessive, or X-linked diseases.
- Cystic fibrosis is a common autosomal recessive disorder due to a defect in the chloride channel protein, the cystic fibrosis transmembrane conductance regulator (CFTR), and can be diagnosed when elevated NaCl is identified in sweat. Cystic fibrosis now has mean survival of 30 years and is characterized clinically by recurrent severe pulmonary infections and pancreatic insufficiency.
- Phenylketonuria (PKU) is an autosomal recessive disease due to deficiency of phenylalanine hydroxylase, which can cause severe mental retardation if not identified by biochemical screening at birth.
- Alkaptonuria is an autosomal recessive disease due to deficiency of homogentisic acid, which is characterized clinically by degenerative arthritis, black discoloration of cartilage (including that in the nose and ears), and urine that turns black on standing.

(Continued)

Chapter Summary (*cont'd*)

- Albinism is an autosomal recessive deficiency of melanin pigmentation in the skin, hair follicles, and eyes that occurs secondary to tyrosinase deficiency and is associated with an increased risk of basal cell and squamous cell skin cancers.
- Glycogen storage diseases are rare diseases due to abnormalities of glycogen metabolism that result in accumulation of glycogen in liver, heart, and skeletal muscle. Important subtypes include von Gierke disease, Pompe disease, and McArdle syndrome.
- Tay-Sachs disease is an autosomal recessive disease seen in Ashkenazi Jews, which is due to deficiency of hexosaminidase A, leading to GM₂ ganglioside deposition with progressive mental deterioration, culminating in death by age 2–3.
- Niemann-Pick disease is an autosomal recessive deficiency of sphingomyelinase, leading to accumulation of sphingomyelin with hepatosplenomegaly, mental deterioration, and death by age 2.
- Gaucher disease is an autosomal recessive deficiency of glucocerebrosidase, leading to accumulation of glucocerebroside, with hepatosplenomegaly and bone marrow involvement. Most cases present in adulthood; cases presenting at younger ages may have CNS manifestations.
- The mucopolysaccharidoses (MPS) are lysosomal storage disorders characterized by deficiencies in the lysosomal enzymes required for the degradation of mucopolysaccharides (glycosaminoglycans). Mental retardation, hepatosplenomegaly, and skeletal deformities occur in this group; Hunter syndrome (MPS II) is less severe than Hurler syndrome (MPS I).
- Familial hypercholesterolemia is a common autosomal dominant disorder with atherosclerotic manifestations (worst in homozygotes) due to genetic defects of several forms involving the low density lipoprotein (LDL) receptor gene.
- Marfan syndrome is an autosomal dominant disorder due to mutation of the fibrillin gene (FBN1) characterized by skeletal abnormalities (tall build with hyperextensible joints and chest abnormalities), subluxation of the lens, and cardiovascular system problems (cystic medial necrosis, dissecting aortic aneurysm, valvular insufficiency).
- Ehlers-Danlos syndrome is a group of inherited connective tissue diseases that have in common a defect in collagen structure or synthesis and are characterized clinically by hyperextensible skin and joints with complications including poor wound healing, joint dislocations, diaphragmatic hernias, retinal detachment, kyphoscoliosis, and arterial or colonic rupture.
- Von Recklinghausen disease (neurofibromatosis type 1) is an autosomal dominant defect in the tumor suppressor gene NF-1, which is characterized clinically by multiple neurofibromas, café-au-lait spots of the skin, Lisch nodules of the iris, and an increased risk of meningiomas and pheochromocytomas. Bilateral acoustic neurofibromatosis (neurofibromatosis type 2) is less common than von Recklinghausen disease and due to a defect in tumor suppressor gene NF-2. It is characterized clinically by bilateral acoustic neuromas, neurofibromas, café-au-lait spots, and an increased risk of meningiomas and ependymomas.

(Continued)

Chapter Summary (*cont'd*)

- Von Hippel-Lindau disease is due to an abnormality of a tumor suppressor gene of chromosome 3p and is characterized clinically by hemangioblastomas in the central nervous system and retina, renal-cell carcinoma, and cysts of internal organs.
- Fragile X syndrome is an important cause of familial mental retardation and is due to a triple nucleotide repeat mutation in the FMR-1 gene on the X chromosome. It is characterized clinically by mental retardation (affected males more severe than female carriers), elongated face, large ears, and macro-orchidism.
- Huntington disease is due to a triple repeat mutation of the Huntingtin gene, which clinically produces atrophy of the caudate nucleus with choreiform movements and progressive dementia.
- Genomic imprinting refers to differential expression of genes based on chromosomal inheritance from maternal versus paternal origin. The classic examples are the mental retardation syndromes Prader-Willi syndrome (paternal deletion of chromosome 15 with obesity and hypogonadism) and Angelman syndrome (maternal deletion of chromosome 15 producing ataxia and inappropriate laughter characterized as “happy puppet”).
- Most X-linked disorders are recessive, with males expressing the disease and producing daughter carriers; examples include Lesch-Nyhan syndrome (hyperuricemia, mental retardation, and self-mutilation due to impaired purine salvage), testicular feminization (androgen insensitivity leads to failure of normal masculinization), chronic granulomatous disease (impaired killing of bacteria by neutrophils leads to repeated infections), and Bruton agammaglobulinemia (lack of immunoglobulin production causes recurrent bacterial infections).
- Rare X-linked disorders are dominant, causing disease in both daughters and sons. Alport disease (hereditary glomerulonephritis with nerve deafness) is an example.
- Mitochondrial DNA disorders are transmitted from the mother, but not the father, to the offspring. These include Leber hereditary optic neuropathy and myoclonic epilepsy.
- Multifactorial inheritance occurs when disease is caused by multiple gene mutations and environmental factors; examples include open neural tube defects and type 2 diabetes mellitus.

HYPERSENSITIVITY REACTIONS

1. **Type I (immediate) hypersensitivity reactions (anaphylactic type)** are characterized by IgE-related release of chemical mediators from mast cells and basophils. The release is triggered by exposure to an antigen and requires prior sensitization to the antigen. The reaction mechanism requires cross-linking of IgE bound to antigen to IgE Fc receptors on the surface of mast cells and basophils. This binding triggers release from mast cells and basophils of chemical mediators that include histamine and heparin; eosinophil chemotactic factor; leukotriene B4 and neutrophil chemotactic factor; and prostaglandin D4, platelet-activating factor (PAF), and leukotrienes C4 and D4. Influx of eosinophils amplifies and perpetuates the reaction. Effects may be systemic (anaphylaxis, as for example due to bee stings or drugs) or localized (food allergies, atopy, and asthma).

2. **Type II hypersensitivity reactions (antibody-mediated)** are characterized by production of an IgG or IgM antibody directed against a specific target cell or tissue. These reactions can take several forms. In complement-dependent cytotoxicity, fixation of complement results in osmotic lysis or opsonization of antibody-coated cells; examples include autoimmune hemolytic anemia, transfusion reactions, and erythroblastosis fetalis.

In antibody-dependent cell-mediated cytotoxicity (ADCC), cytotoxic killing of an antibody-coated cell occurs; an example is pernicious anemia. Antireceptor antibodies can activate or interfere with receptors; examples include Graves disease and myasthenia gravis.

3. **Type III hypersensitivity reactions (immune complex disease)** are characterized by the formation of in situ or circulating antibody-antigen immune complexes, which deposit in tissue resulting in inflammation and tissue injury. Examples include serum sickness, systemic lupus erythematosus (SLE), and glomerulonephritis.

4. **Type IV hypersensitivity reactions (cell-mediated type)** are mediated by sensitized T lymphocytes. In delayed type hypersensitivity, CD4+ TH1-cell lymphocytes mediate granuloma formation; examples include the PPD skin test and tuberculosis.

In cytotoxic T-cell-mediated hypersensitivity, CD8+ T-cell lymphocytes destroy antigen-containing cells; examples include viral infections, immune reaction to tumors, contact dermatitis, and graft rejection.

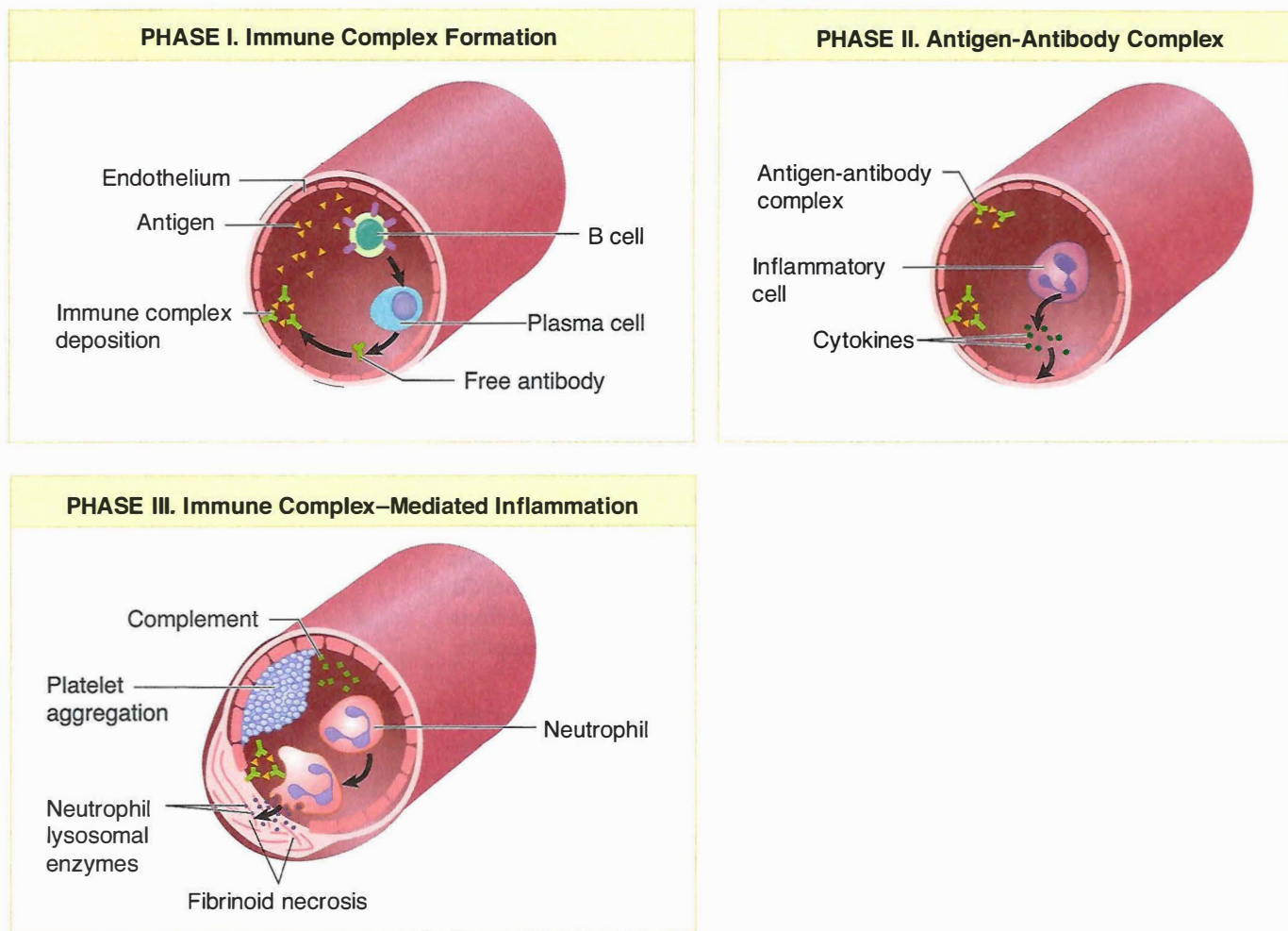


Figure 7-1. Type III Hypersensitivity

Note

Multiple autoantibodies may be produced and are commonly directed against nuclear antigens (DNA, histones, nonhistone nuclear RNA proteins) and blood cells.

Clinical Correlate

Antihistone antibodies: Hydralazine, isonizide, and procainamide can cause a lupus-like syndrome with antihistone antibodies.

AUTOIMMUNE DISEASES

1. **Systemic lupus erythematosus (SLE)** is a chronic systemic autoimmune disease characterized by loss of self-tolerance and production of autoantibodies. Pertinent features of the epidemiology of systemic lupus erythematosus are that females are affected much more often than males (M:F = 1:9); the peak incidence is age 20–45 years; and African Americans are affected more often than Caucasians. The mechanism of injury in lupus is a mix of type II and III hypersensitivity reactions.
 - a. Important **autoantibodies** that may be detected in the sera from lupus patients include antinuclear antibody (ANA) (>95%); anti-dsDNA (40–60%); anti-Sm (20–30%); antihistone antibodies; nonhistone nuclear RNA proteins; and blood cells.
 - b. Systemic lupus erythematosus affects **many organ systems**. Hematologic (type II hypersensitivity reaction) manifestations can include hemolytic anemia, thrombocytopenia, neutropenia, and lymphopenia. Skeletal manifestations include an arthritis characterized by polyarthralgia and synovitis without joint deformity (type III hypersensitivity reaction).

Skin (type III hypersensitivity reaction) manifestations can include a malar “butterfly” rash; maculopapular rash; and ulcerations and bullae formation.

Serosal surfaces may also be affected, with resulting pericarditis, pleuritis, or pleural effusions (type III hypersensitivity reaction).


Central nervous system manifestations include focal neurologic symptoms, seizures, and psychosis (type III hypersensitivity reaction).

Cardiac manifestations include Libman-Sacks endocarditis (nonbacterial verrucous endocarditis) (type III hypersensitivity reaction).

Of particular importance are the **renal manifestations**, which can be diverse. The WHO classification of kidney manifestations (type III hypersensitivity reaction) is as follows:

- Class I: Normal
- Class II: Mesangial lupus nephritis
- Class III: Focal proliferative glomerulonephritis
- Class IV: Diffuse proliferative glomerulonephritis (most common and severe)
- Class V: Membranous glomerulonephritis

- d. Lupus is treated with **steroids** and **immunosuppressive agents**. It tends to have a chronic, unpredictable course with remissions and relapses. The 10-year survival is 85%, with death frequently being due to renal failure or infections.
2. **Sjögren syndrome** (sicca syndrome) is an autoimmune disease characterized by destruction of the lacrimal and salivary glands, resulting in the inability to produce saliva and tears. Females are affected more often than males, with typical age range of 30 to 50 years.
 - a. **Clinical manifestations** include keratoconjunctivitis sicca (dry eyes) and corneal ulcers; xerostomia (dry mouth); and Mikulicz syndrome (enlargement of the salivary and lacrimal glands). Sjögren syndrome is often associated with rheumatoid arthritis and other autoimmune diseases. The characteristic autoantibodies are the anti-ribonucleoprotein antibodies SS-A (Ro) and SS-B (La). There is an increased risk of developing non-Hodgkin lymphoma.
 3. **Scleroderma** (progressive systemic sclerosis) is an autoimmune disease characterized by fibroblast stimulation and deposition of collagen in the skin and internal organs. It affects females more than males, with typical age range of 20 to 55 years. The pathogenesis involves activation of fibroblasts by cytokines interleukin 1 (IL-1), platelet-derived growth factor (PDGF), and/or fibroblast growth factor (FGF) with the resulting activated fibroblasts causing fibrosis.
 - a. **Diffuse scleroderma** has anti-DNA topoisomerase I antibodies (Scl-70) (70%), widespread skin involvement, and early involvement of the visceral organs. Organs that can be affected include the esophagus (dysphagia), GI tract (malabsorption), lungs (pulmonary fibrosis which causes dyspnea on exertion), heart (cardiac fibrosis which may manifest as arrhythmias), and kidney (fibrosis that may manifest as renal insufficiency).
 - b. **Localized scleroderma** (CREST syndrome) has anti-centromere antibodies, skin involvement of the face and hands, late involvement of visceral organs, and a relatively benign clinical course.
 4. **Dermatomyositis and polymyositis** are closely related conditions with immune-mediated muscle damage. Dermatomyositis has skin involvement (purple-red [heliotrope] rash on eyelids) and is due to antibody-mediated damage, while polymyositis does not have skin involvement and is due to



Butterfly Rash

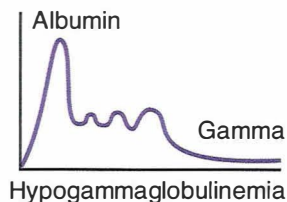
Clinical Correlate

Anti-Ro antibodies: Maternal anti-Ro (SS-A) antibodies have been implicated in the pathogenesis of congenital complete heart block.

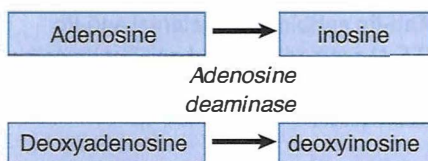
In a Nutshell

CREST Syndrome

- Calcinosis
- Raynaud phenomenon
- Esophageal dysmotility
- Sclerodactyly
- Telangiectasia



Note



Adenosine deaminase is an important enzyme in purine metabolism; **deficiency of adenosine deaminase** results in accumulation of deoxyadenosine within lymphoid stem cells.

T cell–mediated damage. Both conditions most often occur in 40- to 60-year-old women who have muscle pain and atrophy, particularly involving shoulders. Both have increased serum creatine kinase and sometimes positive ANA.

5. **Mixed connective tissue disease** is an overlap condition with features of systemic lupus erythematosus, systemic sclerosis, and polymyositis. Antinucleoprotein antibodies are nearly always positive.

PRIMARY IMMUNE DEFICIENCY SYNDROMES

1. **X-linked agammaglobulinemia of Bruton** is an inherited immunodeficiency characterized by a developmental failure to produce mature B cells and plasma cells, resulting in agammaglobulinemia. The condition occurs because of a mutation of B-cell Bruton tyrosine kinase (*btk*). Clinically, the disease affects male infants who have recurrent infections beginning at 6 months of life due to the loss of passive maternal immunity. Common infections include pharyngitis, otitis media, bronchitis, and pneumonia; common infecting organisms include *H. influenza*, *S. pneumococcus*, and *S. aureus*.
2. **Common variable immunodeficiency** is a group of disorders characterized by a B-cell maturation defect and hypogammaglobulinemia. Clinically, both sexes are affected with onset in childhood of recurrent bacterial infections and with increased susceptibility to *Giardia lamblia*. Complications include increased frequency of developing autoimmune diseases and increased risk of non-Hodgkin lymphoma and gastric cancer.
3. **DiGeorge syndrome** is an embryologic failure to develop the 3rd and 4th pharyngeal pouches, resulting in the absence of the parathyroid glands and thymus. Clinical findings can include hypocalcemia and tetany, T-cell deficiency, and recurrent infections with viral and fungal organisms.
4. **Severe combined immunodeficiency (SCID)** is a combined deficiency of cell-mediated and humoral immunity that is often caused by a stem-cell defect. The modes of inheritance are variable and can include X-linked (mutation of the common γ chain of the interleukin receptors shared by IL-2, IL-4, IL-7, IL-9, IL-15, and IL-21) and autosomal recessive (deficiency of adenosine deaminase). Clinical features include recurrent infections with bacteria, fungi, viruses, and protozoa; susceptibility to *Candida*, cytomegalovirus (CMV), and *Pneumocystis jirovecii* infections, and adverse reactions to live virus immunizations. Severe combined immunodeficiency is treated with stem cell transplant, since the prognosis without treatment is that most infants die of infection within a year.
5. **Wiskott-Aldrich syndrome** is an X-linked recessive disease with mutation in the gene for Wiskott-Aldrich syndrome protein (WASP). The disease has a clinical triad of recurrent infections, severe thrombocytopenia, and eczema (chronic spongiform dermatitis). Treatment is with bone marrow transplantation. Complications include increased risk of non-Hodgkin lymphoma and death due to infection or hemorrhage.
6. **Complement system disorders** can involve a variety of factors, with deficiencies of different factors producing different clinical patterns. With respect to factors in both the classical and alternate pathways, C3 deficiency causes both recurrent bacterial infections and immune complex disease, while C5, C6, C7, and C8 deficiencies cause recurrent meningococcal and gonococcal infections. With respect to factors in **classical pathway only**, C1q, C1r, C1s, C2, and C4 deficiencies cause marked increases in immune complex diseases, including infections with pyogenic bacteria. With respect to factors in **alternate pathway only**, Factor B and properdin deficiencies cause increased neisserial infections. Deficiencies in complement regulatory proteins can cause C1-INH deficiency (hereditary angioedema), which is characterized clinically by edema at mucosal surfaces with low C2 and C4 levels.

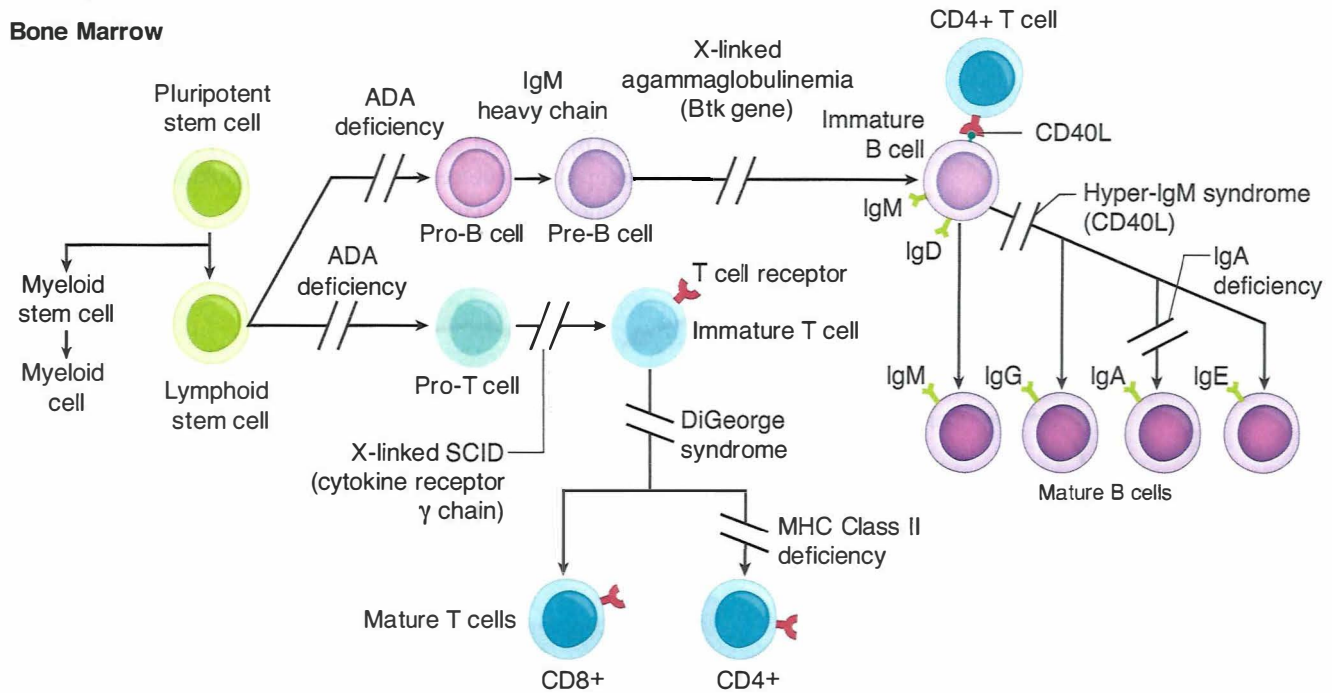


Figure 7-2. Primary Immune Deficiency Syndromes


SECONDARY IMMUNE DEFICIENCY SYNDROMES

- Systemic diseases** that can cause secondary immunodeficiency include diabetes mellitus, collagen vascular disease (e.g., systemic lupus erythematosus), and chronic alcoholism.
- In **renal transplantation**, patients are immunocompromised due to the immunosuppressive drugs required to prevent rejection of the transplanted organ. Hyperacute rejection is mediated by preformed antibodies; occurs immediately after transplantation; and is characterized microscopically by neutrophilic vasculitis with thrombosis.
 - Acute rejection occurs weeks or up to 6 months after organ transplantation; presents with abrupt onset of oliguria and azotemia; is characterized microscopically by neutrophilic vasculitis and interstitial lymphocytes; and is treated with increased doses of immunosuppressive drugs.
 - Chronic rejection occurs greater than 6 months or years after organ transplantation; presents with gradual onset of oliguria, hypertension (HTN), and azotemia; is characterized microscopically by intimal fibrosis of vessels and interstitial lymphocytes; and shows a poor response to treatment.
- Acquired immunodeficiency syndrome (AIDS)** can be diagnosed when a person is HIV-positive and has CD4 count <200 cells/mL, or when a person is HIV-positive and has an AIDS-defining disease. Males are affected more frequently than females, and AIDS can occur in all ages and ethnic groups, with all areas of the country being affected.
 - Transmission of HIV** can occur by many mechanisms, including sexual contact (most common mode, including both homosexual transmission and an increasing rate of heterosexual transmission, with important cofactors including herpes and syphilis infection); parenteral transmission; IV drug use; blood transfusions (including those done in hemophiliacs); accidental needle sticks in hospital workers; and vertical transmission.

Note

Cardiac Transplantation

The major complication in long-term cardiac transplant patients is accelerated graft arteriosclerosis.



Retrovirus

b. The *human immunodeficiency virus* (HIV) is an enveloped RNA retrovirus that contains reverse transcriptase. HIV infects CD4+ T-cell lymphocytes, all macrophages, lymph node follicular dendritic cells, and Langerhans cells. The mechanism of infection is by binding of CD4 by the viral gp120, followed by entry into cell by fusion, which requires gp41 and coreceptors CCR5 (β -chemokine receptor 5) and CXCR4 (α -chemokine receptor).

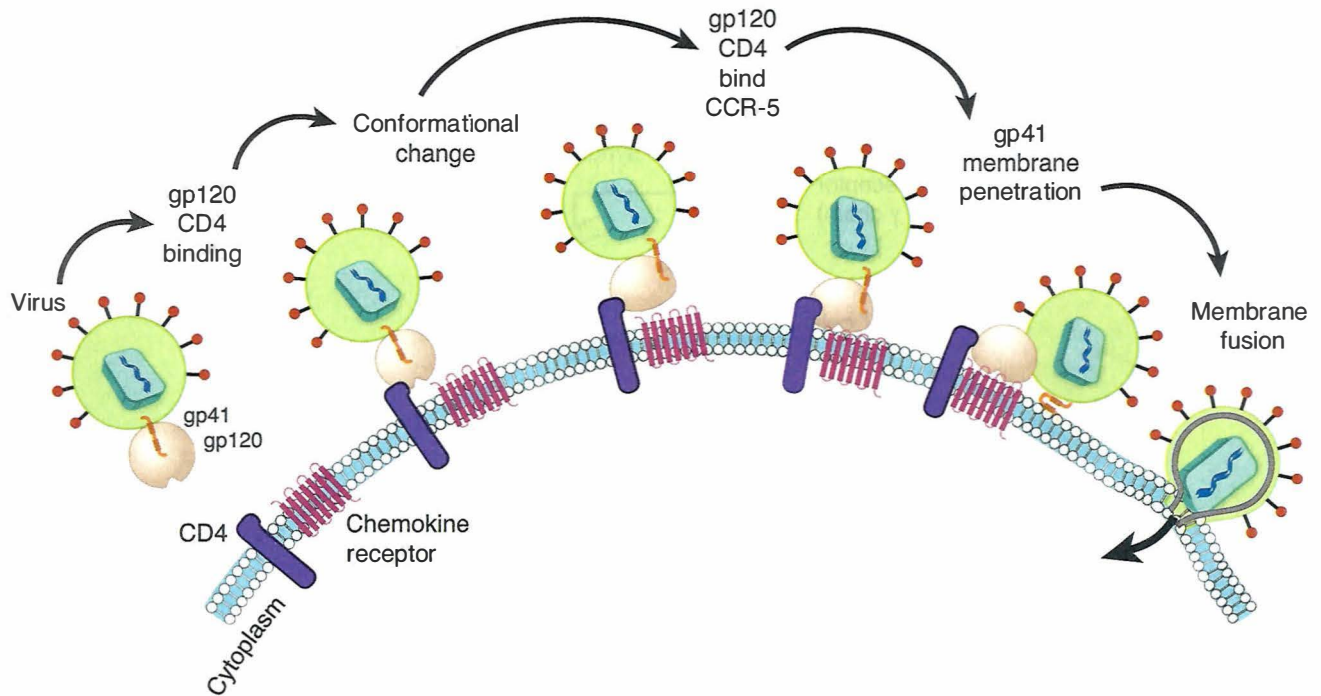


Figure 7-3. Mechanisms of HIV Infection

Note

Macrophages and follicular dendritic cells are reservoirs for the virus.

c. **Diagnosis** is suspected based on HIV-antibody ELISA test and confirmed with Western blot. CD4 count and HIV-1 RNA viral load by PCR are used for monitoring. **Treatment** varies, and can include combination antiretroviral treatment, reverse transcriptase inhibitors, protease inhibitors, and prophylaxis for opportunistic infections based on CD4 count.

Table 7-1. Important CD4 Count Levels

CD4 Count (cells/ μ L)	
700–1,500	Normal
200–500	Oral thrush, Kaposi sarcoma, tuberculosis, zoster
100–200	<i>Pneumocystis carinii</i> pneumonia, dementia
<100	Toxoplasmosis, cryptococcus, cryptosporidiosis
<50	<i>Cytomegalovirus</i> , <i>Mycobacterium-avium</i> complex, progressive multifocal leukoencephalopathy

The **clinical manifestations** of HIV infection vary over time.

The **acute phase** is the initial infection, which shows viremia with a reduction in CD4 count, mononucleosis-like viral symptoms and lymphadenopathy, and seroconversion.

The **latent phase** is characterized by asymptomatic or persistent generalized lymphadenopathy with continued viral replication in reservoir sites, low level of virus in the blood, and minor opportunistic infections including oral thrush (candidiasis) and herpes zoster. The average duration of latent phase is 10 years.

Progression to AIDS occurs with reduction of CD4 count to <200 cells/ μ L, which is accompanied by reemergence of viremia and development of AIDS-defining diseases, leading possibly to eventual death.

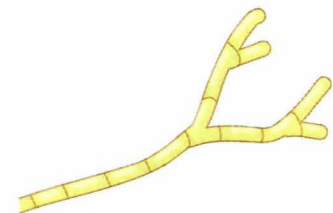
Table 7-2. Opportunistic Infection and Common Sites of Infection in AIDS Patients

Opportunistic Infection	Common Sites of Infection
<i>Pneumocystis jiroveci</i>	Lung (pneumonia), bone marrow
<i>Mycobacterium tuberculosis</i>	Lung, disseminated
<i>Mycobacterium avium-intracellulare</i>	Lung, GI tract, disseminated
Coccidioidomycosis	Lung, disseminated
Histoplasmosis	Lung, disseminated
Cytomegalovirus	Lung, retina, adrenals, and GI tract
<i>Giardia lamblia</i>	GI tract
Cryptosporidium	GI tract
Herpes simplex virus	Esophagus and CNS (encephalitis)
<i>Candida</i>	Oral pharynx and esophagus
<i>Aspergillus</i>	CNS, lungs, blood vessels
Toxoplasmosis	CNS
<i>Cryptococcus</i>	CNS (meningitis)
JC virus	CNS (progressive multifocal leukoencephalopathy)
<i>Bartonella spp.</i>	Skin, mucosa, bone (bacillary angiomatosis)

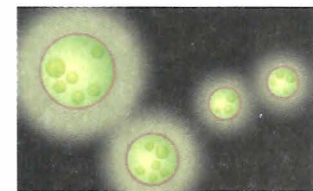
AIDS-defining diseases.

Hairy leukoplakia is an Epstein-Barr virus (EBV)-associated condition due to infection of squamous cells.

Kaposi sarcoma is common in homosexual males and is associated with human herpes virus 8 (HHV8, which has cellular tropism for endothelial cells, B cells, T cells, and monocytes). It commonly involves skin, GI tract, lymph nodes, and lungs.



Septate Hyphae
(*Aspergillus*)

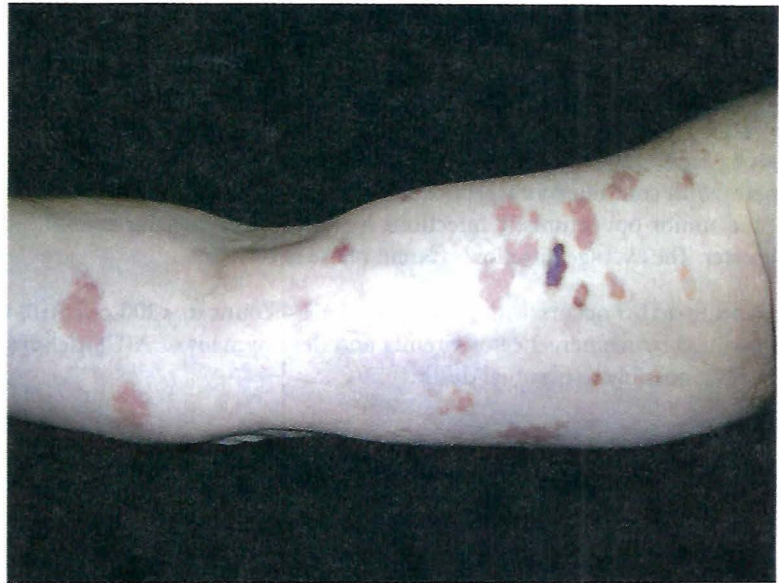

Cryptococcus neoformans

Note

Other entities associated with HHV8:

- Castleman disease
- Body cavity lymphoma



© Richard P. Usatine, M.D. Used with permission.

Figure 7-4. Kaposi Sarcoma in an AIDS patient

Non-Hodgkin lymphomas tend to be high-grade B-cell lymphomas; extranodal CNS lymphomas are common.

Other AIDS-defining diseases include cervical cancer, HIV-wasting syndrome, AIDS nephropathy, and AIDS dementia complex.

Chapter Summary

- Type I hypersensitivity (anaphylactic type) reactions are characterized by IgE-related release of chemical mediators from mast cells and basophils following exposure to an antigen. Examples include systemic anaphylaxis following bee stings and drugs. Localized forms of anaphylactic reaction include food allergies, atopy, and asthma.
- Type II hypersensitivity (cytotoxic type) reactions are characterized by production of an IgG or IgM antibody directed against a specific target cell or tissue. Examples include the complement-dependent cytotoxicity of autoimmune hemolytic anemia, the antibody-dependent cell-mediated cytotoxicity of pernicious anemia, and the antireceptor antibodies of Graves disease.
- Type III hypersensitivity (immune complex disease) reactions are characterized by the formation of *in situ* or circulating antibody-antigen complexes that deposit in tissue, resulting in inflammation and tissue injury. Examples include serum sickness, systemic lupus erythematosus, and glomerulonephritis.
- Type IV hypersensitivity (cell-mediated type) reactions are mediated by sensitized T lymphocytes. Examples include the delayed hypersensitivity of PPD skin tests and tuberculosis and the cytotoxic T-cell-mediated destruction of antigen-containing cells in viral infections, immune reaction to tumors, contact dermatitis, and graft rejection.
- Systemic lupus erythematosus is a chronic systemic autoimmune disease characterized by a loss of self-tolerance and production of autoantibodies. Clinical manifestations include hemolytic anemia and other autoimmune hematologic manifestations, arthritis, skin rashes, and involvement of the renal, cardiovascular, and neurologic systems.
- Sjögren syndrome (sicca syndrome) is an autoimmune disease characterized by destruction of the lacrimal and salivary glands resulting in the inability to produce saliva and tears. Sjögren syndrome is associated with the antiribonucleoprotein antibodies SS-A and SS-B, and also with other autoimmune diseases such as systemic lupus erythematosus.
- Scleroderma (progressive systemic sclerosis) is an autoimmune disease characterized by fibroblast stimulation and deposition of collagen in the skin and internal organs. Scleroderma can have anti-DNA topoisomerase I antibodies (Scl-70), widespread skin involvement, and early involvement of the esophagus, GI tract, lung, heart, and kidney. Localized forms have a more benign course.
- X-linked agammaglobulinemia of Bruton is an inherited immunodeficiency characterized by a developmental failure to produce mature B cells and plasma cells, resulting in agammaglobulinemia with recurrent bacterial infections.
- Common variable immunodeficiency is a group of disorders characterized by a B-cell maturation defect and hypogammaglobulinemia expressed as increased susceptibility to bacterial infections, *Giardia lamblia*, autoimmune diseases, lymphoma, and gastric cancer.
- DiGeorge syndrome is an embryologic failure to develop the third and fourth pharyngeal pouches, resulting in the absence of the parathyroid glands and thymus, leading to hypocalcemia with tetany, T-cell deficiency, and recurrent infections with viral and fungal organisms.

(Continued)

Chapter Summary (*cont'd*)

- Severe combined immunodeficiency (SCID) is a combined deficiency of cell-mediated and humoral immunity often caused by a stem cell defect that, without treatment, causes death by infection within 1 year. Affected infants are susceptible to recurrent infections by bacteria, fungi, viruses, and protozoa.
- Wiskott-Aldrich syndrome is an X-linked condition characterized by recurrent infections, severe thrombocytopenia, and eczema.
- Secondary immune deficiency syndromes can be caused by systemic diseases such as diabetes mellitus, collagen vascular disease (i.e., SLE), and chronic alcoholism.
- Rejection following renal transplantation can occur in three patterns: hyperacute rejection due to preformed antibodies that trigger vascular thrombosis, acute rejection characterized by neutrophilic vasculitis, and chronic rejection characterized by intimal fibrosis of vessels.
- Acquired immunodeficiency syndrome (AIDS) is said to be present when a patient is HIV positive with CD4 count less than 200 or HIV positive with an AIDS-defining disease. HIV can be spread by sexual contact, parenteral transmission, or vertical transmission. The virus is an RNA retrovirus with reverse transcriptase and a predilection for infecting CD4⁺ cells. Diagnosis is by HIV-antibody ELISA test followed by Western blot confirmation. A variety of drugs are now available for treatment.
- HIV infection produces a mononucleosis-like acute phase, an asymptomatic latent phase, and then progression to AIDS. Clinical AIDS is characterized by susceptibility to a wide variety of opportunistic infections. AIDS patients are also prone to develop hairy leukoplakia, Kaposi sarcoma, high-grade B-cell lymphomas, cervical cancer, a wasting syndrome, nephropathy, and dementia.

DEFINITION

Amyloidosis is a group of diseases characterized by the deposition of an extracellular protein that has specific properties.

COMMON FEATURES OF AMYLOID

Individual molecular subunits form β -pleated sheets. Amorphous eosinophilic extracellular deposits of amyloid are seen on the H&E stain. These deposits stain red with the Congo red stain, and apple green birefringence of the amyloid is seen on the Congo red stain under polarized light.

COMPOSITION OF AMYLOID

The fibrillary protein of amyloid varies with each disease. Also present in amyloid are an amyloid P (AP) component and glycosaminoglycans (heparan sulfate).

SYSTEMIC TYPES OF AMYLOID

1. **Primary amyloidosis** has amyloid light chain (AL) amyloid, whose fibrillary protein is made of kappa or lambda light chains. Primary amyloidosis is seen in plasma cell disorders (multiple myeloma, B-cell lymphomas, etc.).
2. **Reactive systemic amyloidosis** (secondary amyloidosis) has amyloid-associated (AA) amyloid, whose fibrillary protein is serum amyloid A (SAA), an acute phase reactant produced by the liver which is elevated with ongoing chronic inflammation and neoplasia. Reactive systemic amyloidosis can be seen with a wide variety of chronic diseases, including rheumatoid arthritis, systemic lupus erythematosus, tuberculosis, bronchiectasis, osteomyelitis, Crohn's disease, and cancer.
3. **Familial Mediterranean fever** has AA type amyloid with fibrillary protein composed of serum amyloid A (SAA). This autosomal recessive disease is characterized by recurrent inflammation, fever, and neutrophil dysfunction.
4. **Hemodialysis-associated amyloidosis** has $A\beta_2M$ type amyloid with fibrillary protein composed of β_2 -microglobulin. This form of amyloidosis may cause carpal tunnel syndrome and joint disease.

Clinical Correlate

Carpal tunnel syndrome is caused when fibrosis, edema, or another pathologic process compresses and damages the median nerve within the tunnel formed by the carpal bones and flexor retinaculum.

ATTR = transporter of thyroxine as well as retinal (vitamin A) or retinol

LOCALIZED TYPES OF AMYLOID

1. **Senile cerebral amyloidosis** (Alzheimer disease) has A β type amyloid with fibrillary protein composed of β -amyloid precursor protein (β APP). It is found in Alzheimer plaques and in cerebral vessels. The gene for β APP is located on chromosome 21.
2. **Senile cardiac/systemic amyloidosis** has ATTR type amyloid with fibrillary protein composed of transthyretin. This type of amyloidosis is seen in men older than 70 years and may cause heart failure as a result of restrictive/infiltrative cardiomyopathy. Four percent of African Americans have a transthyretin (TTR) V122I mutation with 1% being homozygous, serving as a risk for cardiac disease.
3. **Endocrine type amyloidosis** is seen in medullary carcinoma of the thyroid (procalcitonin), adult-onset diabetes (amylin), and pancreatic islet cell tumors (amylin).

CLINICAL FEATURES

1. In **systemic forms** of amyloidosis, the kidney is the most commonly involved organ, and patients may experience nephrotic syndrome and/or progressive renal failure. Cardiac involvement may cause restrictive cardiomyopathy, low voltage EKG, cardiac arrhythmias, and congestive heart failure. Other clinical features include hepatosplenomegaly and involvement of the gastrointestinal tract, which may produce tongue enlargement (macroglossia, primarily in AL type) and malabsorption.
2. **Diagnosis** in systemic forms of amyloidosis can be established with biopsy of the rectal mucosa, gingiva, or the abdominal fat pad; Congo red stain shows apple green birefringence under polarized light of amyloid deposits. The prognosis of systemic amyloidosis is poor.

Chapter Summary

- Amyloidosis is a group of diseases characterized by the deposition of an extracellular protein that tends to form β -pleated sheets and stain red with apple green birefringence with Congo red stain.
- Amyloid is composed of a fibrillary protein, amyloid P component, and glycosaminoglycans. The specific composition of the protein varies with each disease producing amyloidosis.
- In primary amyloidosis, which can complicate plasma cell disorders, the amyloid protein is AL, and the fibrillary protein is kappa or lambda light chains.
- Reactive systemic amyloidosis (secondary amyloidosis) can complicate neoplasia and ongoing inflammation due to many chronic diseases (macrophages) including rheumatoid arthritis, systemic lupus erythematosus, tuberculosis, osteomyelitis, and Crohn disease. The amyloid protein in reactive systemic amyloidosis is AA, and the fibrillary protein is serum amyloid A (SAA), which is an acute phase reactant produced by the liver.
- Familial Mediterranean fever is an autosomal recessive inflammatory disease with amyloid protein AA and fibrillary protein SAA.
- Hemodialysis-associated amyloidosis is associated with amyloid protein A β 2M and fibrillary protein β 2-microglobulin.
- Localized forms of amyloidosis are seen in senile cerebral amyloidosis (amyloid protein A β and fibrillary protein β -amyloid precursor protein); senile cardiac/systemic amyloidosis (amyloid protein ATTR and fibrillary protein transtretin); and in some endocrine diseases, including medullary carcinoma of the thyroid (procalcitonin), adult-onset diabetes (amylin), and pancreatic islet cell tumors (amylin).
- Systemic amyloidosis has a poor prognosis and tends to involve the kidney, heart, liver, spleen, and GI tract.

Principles of Neoplasia

9

DEFINITION

In **neoplasia**, an abnormal cell or tissue grows more rapidly than normal cells or tissue; it does so by acquiring multiple genetic changes over time and by continuing to grow after the stimuli that initiated the new growth have been removed.

EPIDEMIOLOGY

1. Cancer is the **second leading cause of death** in the United States. In 2009, the estimated number of new cancers diagnosed was 1,479,350 and the estimated number of deaths from cancer was 562,340.

Table 9-1. Fifteen Leading Causes of Death in the United States, 2008*

Rank	Cause of Death	Number of Deaths [†]	Percentage of Total Deaths
1	Heart diseases	652,091	26.6
2	Cancer	559,312	22.8
3	Cerebrovascular diseases (stroke)	143,579	5.9
4	Chronic lower respiratory diseases (COPD)	130,933	5.3
5	Accidents (unintentional injuries)	117,809	4.8
6	Diabetes mellitus	75,119	3.1
7	Pneumonia and influenza	71,599	2.9
8	Alzheimer disease	63,001	2.6
9	Nephritis, nephrotic syndrome, and nephrosis	43,901	1.8
10	Septicemia	34,136	1.4
11	Suicide	32,637	1.3
12	Cirrhosis and chronic liver disease	27,530	1.1
13	Hypertension and hypertensive renal disease	24,902	1.0
14	Homicide (assault)	19,544	0.8
15	Parkinson disease	18,124	0.7

*CDC National Vital Statistics Reports, Vol 56, No. 10, April 24, 2008.

[†]Out of a total of 2,448,017 deaths.

Table 9-2. Leading Causes of Death in Children Ages 1–14 in the U.S., 2001*

Rank	Cause of Death	Percentage of Total Deaths
1	Accidents	37.3
2	Cancer	11.7
3	Congenital anomalies	7.6
4	Homicide	6.0
5	Heart disease	4.1
6	Suicide	2.3
7	Pneumonia and influenza	1.7
8	Septicemia	1.5
9	In situ/Benign/Unknown neoplasms	1.3
10	Chronic lower respiratory disease	1.2

* Data borrowed with permission from Lippincott Williams & Wilkins, "Cancer Statistics" by Ahmedin Jemal, D.V.M, Ph.D., et al.; *CA Cancer J Clin* 2004;(vol 1):28).

Table 9-3. Estimated New Cancer Cases by Site and Sex* in the U.S., 2008†

Males		Females	
Site	Percentage	Site	Percentage
Prostate	25	Breast	26
Lung and bronchus	15	Lung and bronchus	14
Colon and rectum	10	Colon and rectum	10
Urinary bladder	7	Uterine corpus	6
Melanoma of skin	5	Non-Hodgkin lymphoma	4
Non-Hodgkin lymphoma	5	Melanoma of the skin	4
Kidney & renal pelvis	4	Thyroid	4
Leukemia	3	Ovary	3
Oral cavity	3	Kidney & renal pelvis	3
Pancreas	3	Leukemia	3

*Excludes basal and squamous cell skin cancers and in situ carcinomas, except urinary bladder

†Cancer Facts & Figures 2008 American Cancer Society, Inc., Surveillance Research.

Table 9-4. Estimated New Cancer Mortality by Site and Sex in the U.S., 2008*

Males		Females	
Site	Percentage	Site	Percentage
Lung and bronchus	31	Lung and bronchus	26
Prostate	10	Breast	15
Colon and rectum	8	Colon and rectum	9
Pancreas	6	Ovary	6
Leukemia	4	Pancreas	6
Esophagus	4	Leukemia	3
Liver & intrahepatic bile duct	4	Non-Hodgkin lymphoma	3
Non-Hodgkin lymphoma	3	Uterine corpus	3
Kidney & renal pelvis	3	Brain & other nervous system	2

* Cancer Facts & Figures 2008 American Cancer Society, Inc. Surveillance Research.

Predisposition to cancer involves many factors. Geographic and racial factors can be important:

- Stomach cancer is *much* more prevalent in Japan than in the United States.
- Breast cancer is *much* more prevalent in the United States than in Japan.
- Liver hepatoma is *much* more prevalent in Asia than in the United States.
- Prostate cancer is more prevalent in African Americans than in Caucasians.

Occupational exposures and age also affect prevalence.

Heredity predisposition can be seen in many cancers, including familial retinoblastoma, multiple endocrine neoplasia, and familial polyposis coli.

Acquired preneoplastic disorders also affect cancer incidence, with examples including cervical dysplasia, endometrial hyperplasia, cirrhosis, ulcerative colitis, and chronic atrophic gastritis.

CARCINOGENIC AGENTS

1. **Chemical carcinogens.** Carcinogenesis is a multistep process involving a sequence of initiation (mutation) followed by promotion (proliferation). Initiators can be either direct-acting chemical carcinogens (mutagens which cause cancer directly by modifying DNA) or indirect-acting chemical carcinogens (procarcinogens which require metabolic conversion to form active carcinogens). Promoters cause cellular proliferation of mutated (initiated) cells, which may lead to accumulation of additional mutations.
 - a. **Clinically important chemical carcinogens** are numerous, and include nitrosamines (gastric cancer), cigarette smoke (multiple malignancies), polycyclic aromatic hydrocarbons (bronchogenic carcinoma), asbestos (bronchogenic carcinoma, mesothelioma), chromium and nickel (bronchogenic carcinoma), arsenic (squamous cell carcinomas of skin and lung, angiosarcoma of liver), vinyl chloride (angiosarcoma of liver), aromatic amines and azo dyes (hepatocellular carcinoma), alkylating

Bridge to Biochemistry

Diseases associated with DNA repair include xeroderma pigmentosum and hereditary nonpolyposis colorectal cancer.

agents (leukemia, lymphoma, other cancers), benzene (leukemia), and naphthylamine (bladder cancer). Potential carcinogens are screened by the Ames test, which detects any mutagenic effects of potential carcinogens on bacterial cells in culture; mutagenicity *in vitro* correlates well with carcinogenicity *in vivo*.

2. **Radiation.** Ultraviolet B sunlight is the most carcinogenic because it produces pyrimidine dimers in DNA, leading to transcriptional errors and mutations of oncogenes and tumor suppressor genes, thereby increasing the risk of skin cancer. Xeroderma pigmentosum is an autosomal recessive inherited defect in DNA repair, in which the pyrimidine dimers formed with ultraviolet B sunlight cannot be repaired; this leads to the patient's having a strong disposition for forming skin cancer. Ionizing radiation includes x-rays and gamma rays, alpha and beta particles, protons, and neutrons. Cells in mitosis or the G2 phase of the cell cycle are most sensitive to radiation. Radiation causes cross-linking and chain breaks in nucleic acids. Atomic bomb survivors experienced an increased incidence of leukemias, thyroid cancer, and other cancers. Uranium miners historically had increased lung cancer, related to inhalation of radioactive radon, which is a decay product of uranium.
3. **Oncogenic viruses.** The only RNA oncogenic virus you will need to remember is the human T-cell leukemia virus (HTLV-1), which causes adult T-cell leukemia/lymphoma. DNA oncogenic viruses are diverse, and include the following:
 - Hepatitis B virus (hepatocellular carcinoma)
 - Epstein-Barr virus (EBV), which has been implicated in Burkitt lymphoma, B-cell lymphomas in immunosuppressed patients, nasopharyngeal carcinoma
 - Human papilloma virus (HPV), which causes benign squamous papillomas (warts-condyloma acuminatum) and a variety of carcinomas (cervical, vulvar, vaginal, penile, and anal)
 - Kaposi-sarcoma-associated herpesvirus (HHV8) which causes Kaposi sarcoma.
4. **Loss of immune regulation.** Immunosurveillance normally destroys neoplastic cells via recognition of "non-self" antigens, and both humoral and cell-mediated immune responses play a role. Patients with immune system dysfunction have an increased number of neoplasms, especially malignant lymphomas.

CARCINOGENESIS

1. **Carcinogenesis** is a multistep process, and development of all human cancers appears to require the accumulation of multiple genetic changes. These changes can involve either inherited germ-line mutations or acquired mutations. Once a single severely mutated cell forms, monoclonal expansion of the cell's line can cause a tumor. Most important mutations in tumorigenesis involve growth promoting genes (protooncogenes), growth inhibiting tumor suppressor genes, or the genes regulating apoptosis and senescence.
2. **Activation of growth promoting oncogenes.** Protooncogenes are normal cellular genes involved with growth and cellular differentiation. Oncogenes are derived from protooncogenes by either a change in the gene sequence, resulting in a new gene product (oncoprotein), or a loss of gene regulation resulting in overexpression of the normal gene product. Mechanisms of oncogene activation include point mutations, chromosomal translocations, gene amplifica-

tion, and insertional mutagenesis. Activated oncogenes lack regulatory control and are overexpressed, resulting in unregulated cellular proliferation.

Table 9-5. Clinically Important Oncogenes

Oncogene	Tumor	Gene Product	Mechanism of Activation
hst-1 & int-2	Cancer of the stomach, breast, bladder, and melanoma	Growth factors Fibroblast growth factor	Overexpression
sis	Astrocytoma	Platelet-derived growth factor	Overexpression
erb-B1	SCC of lung	Growth factor receptors Epidermal growth factor receptor	Overexpression
erb-B2	Breast, ovary, lung	Epidermal growth factor receptor	Amplification
erb-B3	Breast	Epidermal growth factor receptor	Overexpression
ret	MEN II & III, familial thyroid (medullary) cancer	Glial neurotrophic factor receptor	Point mutation
abl	CML, ALL	Signal transduction proteins bcr-abl fusion protein with tyrosine kinase activity	Translocation t(9;22)
Ki-ras	Lung, pancreas, and colon	GTP binding protein	Point mutation
c-myc	Burkitt lymphoma	Nuclear regulatory protein	Translocation t(8;14)
L-myc	Small cell lung carcinoma	Nuclear regulatory protein	Amplification
N-myc	Neuroblastoma	Nuclear regulatory protein	Amplification
bcl-1	Mantle cell lymphoma	Cell cycle regulatory proteins Cyclin D protein	Translocation t(11;14)
CDK4	Melanoma, GBM	Cyclin dependent kinase	Amplification

3. **Inactivation of tumor suppressor genes.** Tumor suppressor genes encode proteins that regulate and suppress cell proliferation by inhibiting progression of the cell through the cell cycle. The mechanism of action of tumor suppressor genes may vary. As examples, p53 prevents a cell with damaged DNA from entering S-phase, while Rb prevents the cell from entering S-phase until the appropriate growth signals are present.
 - a. **Knudson's "two hit hypothesis"** states that at least 2 tumor suppressor genes must be inactivated for oncogenesis. In cancers arising in individuals with inherited germ-line mutations, the "first hit" is the inherited germ-line mutation and the "second hit" is an acquired somatic mutation. Examples of inherited germ-line mutations include familial retinoblastoma (in which germ-line mutation of Rb on chromosome 13 is associated with a high rate of retinoblastoma and osteosarcoma) and Li-Fraumini syndrome (in which germ-line mutation of p53 on chromosome 17 is associated with a high rate of many types of tumors).

Table 9-6. Clinically Important Tumor Suppressor Genes

Chromosome	Gene	Tumors
3p25	VHL	von Hippel-Lindau disease, renal cell carcinoma
11p13	WT-1	Wilms tumor
11p15	WT-2	Wilms tumor
13q14	Rb	Retinoblastoma, osteosarcoma
17p13.1	p53	Lung, breast, colon, etc.
17q12-21	BRCA-1	Hereditary breast and ovary cancer
13q12-13	BRCA-2	Hereditary breast cancer
5q21	APC	Adenomatous polyps and colon cancer
18q21	DCC	Colon cancer
17q11.2	NF-1	Neurofibromas
22q12	NF-2	Acoustic neuromas, meningiomas

4. **Regulation of apoptosis.** Tumor genesis related to changes in regulation of apoptosis occurs in the follicular lymphomas that have the translocation t(14;18). Normally, bcl-2 prevents apoptosis (programmed cell death). In the follicular lymphomas with this translocation, the bcl-2 regulator of apoptosis is overexpressed, because the translocation connects the immunoglobulin heavy chain gene on chromosome 14 (which turns on easily in B lymphocytes) to the bcl-2 gene on chromosome 18, thereby leading to a situation in which lymphocytes fail to die as expected and instead produce a tumor.

Other examples of apoptosis regulators include bax, bad, bcl-xS, and bid; p53 promotes apoptosis in mutated cells by stimulating bax synthesis. c-myc promotes cellular proliferation and when associated with p53 leads to apoptosis and when associated with bcl-2 inhibits apoptosis.

DIAGNOSIS OF CANCER

Table 9-7. General Features of Benign versus Malignant Neoplasms

	Benign	Malignant
Gross	<ul style="list-style-type: none"> • Small size • Slow growing • Encapsulated or well-demarcated borders 	<ul style="list-style-type: none"> • Larger in size • Rapid growth • Necrosis and hemorrhage are commonly seen • Poorly demarcated
Micro	<ul style="list-style-type: none"> • Expansile growth with well-circumscribed borders • Tend to be well differentiated • Resemble the normal tissue counterpart from which they arise • Noninvasive and never metastasize 	<ul style="list-style-type: none"> • Vary from well to poorly (anaplastic) differentiated • Tumor cells vary in size and shape (pleomorphism) • Increased nuclear to cytoplasmic ratios • Nuclear hyperchromasia and prominent nucleoli • High mitotic activity with abnormal mitotic figures • <i>Invasive growth pattern</i> • <i>Has potential to metastasize</i>

1. **Histologic diagnosis of cancer.** Microscopic examination of tissue or cells is required to make the diagnosis of cancer. Material suitable for diagnosis of a tumor may be obtained by complete excision, biopsy, fine needle aspiration, or cytologic smears (Pap smear).
 - a. **Immunohistochemistry** may be helpful in confirming the tissue of origin of metastatic or poorly differentiated tumors. The technique uses monoclonal antibodies that are specific for a cellular component. Among the many antibodies that are clinically useful are all of the serum tumor markers; thyroglobulin (thyroid cancers); S100 (melanoma and neural tumors); actin (smooth and skeletal muscle); CD markers (lymphomas/leukemias); estrogen receptors (breast cancer); and intermediate filaments (see Table 9-8).

Note

Most neoplasms (90%) arise from epithelium, with the remainder from mesenchymal cells.

Table 9-8. Expression of Intermediate Filaments by Normal and Malignant Cells

Intermediate Filament	Normal Tissue Expression	Tumor
Keratin	All epithelial cells	Carcinomas
Vimentin	Mesenchymal cells	Sarcomas
Desmin	Muscle cells	Uterine leiomyoma Rhabdomyosarcoma
Neurofilament	CNS and PNS neurons Neural crest derivatives	Pheochromocytoma Neuroblastoma
Glial fibrillary acidic protein (GFAP)	Glial cells	Astrocytomas Ependymomas

- b. **Ancillary tests** for the diagnosis of cancer include electron microscopy, flow cytometry, cytogenetics, and PCR/DNA probes.
- 2. **Serum tumor markers.** Tumor markers are usually normal cellular components that are increased in neoplasms but may also be elevated in non-neoplastic conditions. Serum tumor markers are used for screening (e.g., prostate specific antigen [PSA]) for cancer, monitoring treatment efficacy, and detecting recurrence of cancers.
 - a. **Clinically useful tumor markers** include alpha-fetoprotein (AFP, used for hepatoma, nonseminomatous testicular germ-cell tumors); beta human chorionic gonadotropin (hCG, used for trophoblastic tumors, choriocarcinoma); calcitonin (used for medullary carcinoma of the thyroid); carcinoembryonic antigen (CEA, used for carcinomas of the lung, pancreas, stomach, breast, and colon); CA-125 (used for malignant ovarian epithelial tumors); CA19-9 (used for malignant pancreatic adenocarcinoma); placental alkaline phosphatase (used for seminoma); and prostate specific antigen (PSA, used for prostate cancer).
- 3. **Grading and staging.** Tumor grade is a histologic estimate of the malignancy of a tumor, and typically uses criteria such as the degree of differentiation from low grade (well-differentiated) to high grade (poorly differentiated/anaplastic) and the number of mitoses.

Tumor stage is a clinical estimate of the extent of tumor spread. TNM staging system criteria is used for most tumor types:

- T indicates the size of the primary tumor
- N indicates extent of regional lymph node spread
- M indicates the presence or absence of metastatic disease.

In general, staging is a better predictor of prognosis than tumor grade.

- 4. **Tumor progression** refers to the tendency of a tumor to become more malignant over time. This progression can be related to both natural selection (evolution of a more malignant clone over time due to a selective growth advantage) and genetic instability (malignant cells are more prone to mutate and accumulate additional genetic defects).
- 5. **Metastasis.** Lymphatic spread is the most common initial route of spread for epithelial carcinomas. Early hematogenous spread is typically seen with most sarcomas (e.g., osteogenic sarcoma), renal cell carcinoma (because of

the proximity of the large renal vein), hepatocellular carcinoma (because of the presence of the hepatic sinusoids), follicular carcinoma of the thyroid, and choriocarcinoma (because of its propensity to seek vessels). Seeding of body cavities and surfaces occurs in ovarian carcinoma. Transplantation via mechanical manipulation (e.g., surgical incision, needle tracts) may occur but is relatively rare.

Chapter Summary

- Cancer is the second leading cause of death in the United States in both adults and children. In men, the sites with the highest new cancer rates are (in order of decreasing frequency): prostate, lung and bronchus, and colon and rectum. These same sites have the highest mortality rate, although lung and bronchus cancers more commonly cause death than prostate cancer. In women, the sites with the highest new cancer rate are (in order of decreasing frequency): breast, lung and bronchus, and colon and rectum. These same sites have the highest mortality rate, although lung and bronchus cancers more commonly cause death than breast cancer.
- The incidence of different cancers can vary with geographic site, racial factors, occupational exposures, age, hereditary predisposition, and acquired preneoplastic disorders.
- A variety of chemical carcinogens have been identified that can act as initiators or promoters of specific cancers. Ultraviolet light and ionizing radiation are also carcinogenic. A relatively small number of cancers have been linked to infection with specific viruses. Patients with immune system dysfunction also have an increased number of neoplasms.
- Carcinogenesis is a multistep process requiring the accumulation of multiple genetic changes as the result of either inherited germ-line mutations or acquired mutations, leading to the monoclonal expansion of a mutated cell.
- Cancer growth can involve either activation of growth promoting oncogenes or inactivation of tumor suppressor genes.
- Activated oncogenes lack regulatory control and are overexpressed, resulting in unregulated cellular proliferation. Examples of clinically important oncogenes include *erb*, *ras*, and *myc*.
- Tumor suppressor genes encode proteins that regulate and suppress cell proliferation by inhibiting progression of the cell through the cell cycle. Inactivation of these genes leads to uncontrolled cellular proliferation with tumor formation. Examples of clinically important tumor suppressor genes include VHL, p53, Rb, APC, DCC, and NF-1.
- Cancers can also develop if apoptosis (programmed cell death) is prevented by mutations in genes such as *bcl-2*, *bax*, *bad*, and *bcl-xS*.
- When compared with similar benign lesions, malignant neoplasms tend to be more rapidly growing due to a greater portion of cells that are in mitosis; tend to have areas of necrosis and hemorrhage; tend to have invasive growth pattern; tend to have the potential to metastasize; tend to have high mitotic activity with abnormal mitotic figures; and tend to have pleomorphic cells with increased nuclear to cytoplasmic ratio, nuclear hyperchromasia, and prominent nucleoli.

(Continued)

Chapter Summary (*cont'd*)

- A diagnosis of cancer requires the examination of cells and/or tissue that may be obtained by complete excision or biopsy of the lesion, fine needle aspiration, or cytologic smears. Immunohistochemistry can be helpful in confirming the tissue of origin of metastatic or poorly differentiated tumors.
- Serum tumor markers are usually normal cellular components that are increased in neoplasms but may also be elevated in non-neoplastic conditions. They can be used for screening, monitoring of treatment efficacy, and detecting recurrence. Examples include AFP, hCG, CEA, CA-125, and PSA.
- Tumor grade is a histologic estimate of the malignancy of a tumor. Tumor stage is a clinical estimate of the extent of tumor spread.
- Many tumors tend to become more malignant over time as a result of natural selection of more malignant clones and genetic instability of malignant cells.
- Lymphatic spread is the most common route of spread for epithelial carcinomas. Hematogenous spread is most likely to be seen with sarcomas, renal-cell carcinoma, hepatocellular carcinoma, follicular carcinoma of the thyroid, and choriocarcinoma. Tumors are also less commonly spread by seeding of body cavities and surfaces and via mechanical manipulations such as surgical incisions and needle tracts.

Environment- and Lifestyle-Related Pathology

10

POISONING AND TOXINS

1. **Carbon monoxide** is an odorless, colorless gas with a high affinity for hemoglobin (200x the affinity for hemoglobin compared with oxygen). When combined with hemoglobin, carbon monoxide forms carboxyhemoglobin, which shifts the oxygen dissociation curve to the left, leading to decreased delivery of oxygen to tissues and causing systemic hypoxia. Sources of carbon monoxide include auto emissions, home heaters, fires, and cigarette smoking.
 - a. **Symptoms** depend on the **carboxyhemoglobin concentration**: 10% of hemoglobin as carboxyhemoglobin is asymptomatic; 30% causes headache and shortness of breath on exertion; 50% causes loss of consciousness, convulsions, and coma; and 60% causes death. Clinically, the carboxyhemoglobin causes bright “cherry-red” color of skin, mucosal membranes, and blood. Treatment involves removing the patient from the source of exposure followed by 100% oxygen or, if available, hyperbaric oxygen.
2. **Mushroom poisoning.** *Amanita muscaria* mushroom poisoning is typically followed by recovery with supportive therapy and is only rarely lethal. The more poisonous *Amanita phalloides* has a toxin (amanitin) that inhibits RNA polymerase, thereby clinically causing abdominal pain, vomiting, and diarrhea that may progress to fulminant hepatitis with extensive liver necrosis leading to coma and death.
3. **Arsenic poisoning.** Arsenic can be detected in hair and nails long after exposure due to the binding to disulfide groups in proteins. Acute poisoning causes hemorrhagic gastroenteritis, central nervous system toxicity potentially producing coma and seizures, and “garlic-scented” breath. Chronic poisoning causes malaise and abdominal pain, peripheral neuropathy and muscular weakness, skin changes (hyperpigmentation and dermatitis), and Mees lines (transverse bands on the fingernails). Complications include squamous cell carcinomas (skin and lung) and angiosarcoma (liver).
4. **Lead poisoning** (plumbism) is the most common type of chronic metal poisoning in the United States. It primarily affects children, with sources including lead paint, lead plumbing, and lead pots.
 - a. **Clinically**, central nervous system toxicity is prominent, and may cause lethargy and somnolence, cognitive impairment and behavioral problems, mental retardation, and cerebral edema, which may progress to encephalopathy. Wrist and foot drop occur in adults due to peripheral motor nerve demyelination. Other clinical features include abdominal pain (lead colic), renal tubular acidosis and renal failure, microcytic anemia with basophilic stippling, deposition of lead at the gingivodental line (“lead line”), and lead lines (increased bone density) visible on x-ray at the epiphyseal growth plates of long bones.
 - b. Diagnosis is established by measuring blood lead levels and demonstrating increased free erythrocyte protoporphyrin. Treatment is to stop the exposure and administer chelating drugs.

Bridge to Biochemistry

The microcytic anemia of lead poisoning is a result of decreased heme synthesis through inhibition of ferrochelatase and δ -aminolevulinic acid dehydrase. Basophilic stippling is due to inhibition of pyrimidine 5' nucleotidase.

5. **Mercury poisoning** causes neurotoxicity (intention tremors; dementia and delirium [“mad as a hatter”]) and nephrotoxicity (acute tubular necrosis); treatment is to stop the exposure and administer chelating drugs.
6. **Cyanide poisoning** causes toxicity when cyanide blocks cellular respiration by binding to mitochondrial cytochrome oxidase (cytochrome a3), thereby acting as a systemic asphyxiant; a characteristic clinical finding is “bitter almond-scented” breath.

Table 10-1. Industrial Toxins

Industrial Toxin	Occupation	Pathology
Soot (polycyclic aromatic hydrocarbons)	English chimney sweeps	Scrotal cancer
Vinyl chloride	Plastic industry	Angiosarcoma of the liver
Uranium and radon gas	Miners	Lung cancer
β-Naphthylamine	Dye makers and rubber workers	Bladder cancer
Benzo[a]pyrene	Steel mills and cigarette smoke	Lung and bladder cancer
Carbon tetrachloride	Dry cleaners	Liver and kidney toxicity
Organophosphates	Farmers	Irreversible cholinesterase inhibitors

Clinical Correlate

The dose of exposure is measured in terms of “pack years.”

Smoking cessation for 15 years reduces the overall risk of dying—almost to the level of nonsmokers. It’s never too late to quit.

Clinical Correlate

Top 3 Causes of Death in Smokers

- Heart disease
- Lung cancer
- COPD

LIFESTYLE CHOICES

1. **Smoking** is the number 1 cause of preventable premature death in the United States, with the percentage of the U.S. population that smokes being ~25% (males > females). There is a high rate of smoking in female teenagers.
 - a. **Types of smoke** to which an individual may be exposed include mainstream smoke (smoke inhaled by the smoker) and sidestream smoke (passive smoke inhalation). Smoke contains over 4,000 components and over 40 known carcinogens, with important components including carbon monoxide, arsenic, formaldehyde, hydrogen cyanide, and nicotine (addictive component).
 - b. **Cancers** in which cigarette use has been implicated include lung cancer (number 1 cause of cancer death in the United States); cancers of the oral cavity, pharynx, and larynx; cancers of the esophagus and stomach; cervical cancer; pancreatic cancer; cancers of the kidney, ureter, and bladder; and leukemia (benzene).
 - c. **Other clinical problems** may also occur. Cigarette smoking causes cardiovascular disease, being a major risk factor for atherosclerosis with resulting coronary artery disease, myocardial infarctions, peripheral vascular disease, aortic aneurysms, and stroke. Cigarette use may also induce coronary vasospasm and Buerger disease. Respiratory diseases associated with cigarette use include chronic bronchitis, emphysema, asthma, and increased pulmonary infections. Women smokers often develop early menopause and have an increased rate of postmenopausal osteoporosis. Pregnant women smokers have increased risk of spontaneous abortions and stillbirths, and infants of woman smokers may have intrauterine growth retardation or be at increased risk of sudden infant death syndrome (SIDS). Children of smokers have an increased number of otitis media and upper respiratory infections, and an increased incidence of asthma.

2. **Ethyl alcohol** (ethanol).
 - a. **Acute alcohol** acts as a central nervous system depressant that can produce inebriation, coma, and respiratory arrest.
 - b. **Chronic alcoholism** damages the liver, potentially causing fatty change, alcoholic hepatitis, and micronodular cirrhosis. Other organs that can be damaged include stomach (acute gastritis and Mallory-Weiss syndrome), pancreas (acute and chronic pancreatitis), blood (megaloblastic anemia), and heart (dilated cardiomyopathy). Damage to the central nervous system can cause Wernicke syndrome (ataxia, nystagmus, ophthalmoplegia) and Korsakoff syndrome (confabulation, psychosis). Newborns may have fetal alcohol syndrome. Cancers associated with alcohol use include hepatocellular carcinoma due to cirrhosis and cancers of the oropharynx, larynx, and esophagus due to smoking and drinking alcohol.
3. **Methyl alcohol** (methanol, wood alcohol) is metabolized to formaldehyde (by alcohol dehydrogenase) and formic acid; it is present in solvents, paint remover, and other household chemicals. The chemical is toxic to retina (necrosis of retinal ganglion cells results in blindness) and central nervous system (inebriation, coma, and death).

Treatment is with ethyl alcohol, which competes for the enzyme that metabolizes methanol to the more toxic formaldehyde. Fomepizole is an alternative.

DRUGS OF ABUSE

1. **Heroin** overdose can cause cardiopulmonary arrest and sudden death. Infections associated with heroin injection include skin abscesses and cellulitis; bacterial endocarditis (*S. aureus*); and increased risk of contracting HIV and hepatitis viruses. Pulmonary pathology that may occur includes foreign body granuloma, pulmonary abscesses, and pulmonary edema. Heroin use can also cause focal segmental glomerulosclerosis and secondary amyloidosis. Naloxone (an opiate antagonist) is used for reversal of heroin overdose.
2. **Cocaine** directly prevents the reuptake of dopamine, serotonin, and norepinephrine into presynaptic neurons, which can clinically cause euphoria, seizures, cardiac arrhythmias potentially leading to sudden death, hypertension, and stroke. Chronic use may result in perforation of the nasal septum and dilated cardiomyopathy.
3. **Marijuana** is a commonly used illicit drug whose activity is based on the presence of naturally occurring cannabinoids. Acute intoxication usually causes euphoria, but may sometimes lead to dysphoria, diminished coordination, altered time sense, perceptual changes, and injected conjunctivae. Severe acute intoxication may rarely cause feelings of panic, paranoia, frank hallucinations, depersonalization, and recurrence of psychosis in schizophrenic patients. These effects are especially seen with smoking mixtures containing synthetic cannabinoids, available in some areas as “legal smoke” or “spice,” which are often used as an alternative to marijuana by young people. Chronic use of cannabis may predispose to airway disease.
4. **Hallucinogens.** Lysergic acid diethylamide (LSD) causes increased heart rate and blood pressure, acute panic reaction and visual hallucinations, and behavior-related trauma with possibly impulsive or irrational behavior. Mescaline (in peyote) is similar to LSD, and may also cause nausea/vomiting. MDMA (ecstasy) can cause hypertension, tachycardia, diaphoresis, and dehydration; hyperthermia, rhabdomyolysis, and myoglobinuric renal failure; disseminated intravascular coagulation; and depletion of brain serotonin.
5. **Benzodiazepines.** Acute toxicity is characterized by drowsiness, impaired judgment, impaired motor skills, slurred speech. More serious toxicity produces hypothermia, hypotension, and respiratory depression. There is

Bridge to Biochemistry

Alcohol induces the cytochrome P-450 enzymes, resulting in increased metabolism of other drugs.

Clinical Correlate

The telltale sign of IVDA is “track marks” in the antecubital fossa, which are produced from the healing of skin abscesses and/or phlebosclerosis.

a dependency risk for benzodiazepines related to a cycle of withdrawal and symptom recurrence.

6. **Amphetamines**, including methamphetamine, cause the release of norepinephrine, dopamine, and to an extent, serotonin. Clinically, they produce effects similar to those of cocaine but are orally active. Acute toxicity can produce disorientation, agitation, hypertension, chest pain, palpitations, dry mouth, nausea and vomiting, diaphoresis, and mydriasis. Chronic effects may include anorexia, pulmonary edema, stroke, eroded teeth, cellulitis, and psychotic reactions. Cathinone derivatives (“bath salts”) are designer drugs that reproduce many or all of the effects of amphetamines with a significant potential for addiction and psychotic reactions. They may be present in quasi-legal “party pills” or powders.

PHYSICAL INJURIES

1. **Mechanical injuries.** Contusions result from blunt force injury to deeper tissues with resulting hemorrhage. Abrasions are due to superficial damage to the skin. Lacerations are jagged wounds through the full thickness of the skin.
2. **Burns.** First degree burns are partial thickness burns that heal without scarring. Second degree burns damage the whole epidermis, cause blistering, and usually heal without scarring. Third degree burns are full thickness burns that can cause extensive necrosis of epidermis and adnexal structures. Third degree burns are vulnerable to infection and healing occurs with **scarring**.
3. In **electrical injury**, tissue damage under the skin surface is often far worse than superficial damage. Both AC and DC currents cause damage.
4. **Drowning** is an important cause of death in children. Aspiration of fresh or salt water damages type II pneumocytes and causes diffuse alveolar damage.
5. **Radiation injury.** Ionizing radiation (x-rays; gamma rays) can damage DNA and other cellular components, with the most sensitive tissues including those with the highest mitotic activity: lymphoid tissue, bone marrow, gastrointestinal mucosa, and germinal tissue. Nonionizing radiation (ultraviolet light B) damages pairs of adjacent pyrimidines in DNA and can cause sunburn, actinic keratoses, and skin cancers (basal cell carcinoma, squamous cell carcinoma, and melanoma).

Chapter Summary

- Acute aspirin toxicity can cause coma and death secondary to respiratory alkalosis and metabolic acidosis; chronic aspirin toxicity impairs platelet function and can cause gastritis.
- Unopposed estrogens are associated with an increased risk of endometrial and breast cancer. Oral contraceptives are associated with an increased risk of deep vein thrombosis in smokers.
- Carbon monoxide poisoning causes systemic hypoxia that may lead to death. Mushroom poisoning can cause fulminant hepatitis. Acute arsenic poisoning can cause hemorrhagic gastritis and coma; chronic arsenic poisoning causes abdominal pain and neuromuscular problems. Lead poisoning can cause mental impairment, peripheral nerve damage, abdominal pain, renal failure, and anemia. Mercury damages the brain and kidney. Cyanide is a systemic asphyxiant.
- A variety of organic and inorganic industrial toxins have been associated with specific cancers.
- Smoking is the number one cause of preventable premature death in the United States. It is associated with cancers in many sites, cardiovascular disease, respiratory disease, early menopause, osteoporosis, and prenatal problems. Infants and children exposed to smoking have an increased incidence of sudden infant death syndrome, upper respiratory infections, otitis media, and asthma.
- Acute alcohol intoxication causes central nervous system depression which, if severe enough, can lead to coma and respiratory arrest. Chronic alcoholism can cause cirrhosis, gastritis, pancreatitis, anemia, fetal alcohol syndrome, cardiomyopathy, Wernicke and Korsakoff syndromes, and cancers of the liver due to alcoholic cirrhosis, and cancers of the oropharynx, larynx, and esophagus (alcohol acts synergistically with carcinogens in cigarette smoke). Methyl alcohol poisoning can cause blindness, coma, and death.
- Heroin abuse can cause sudden death, skin abscesses, endocarditis, increased risk of contracting HIV and viral hepatitis, pulmonary complications, focal segmental glomerulosclerosis, and secondary amyloidosis. Cocaine abuse can produce seizures, cardiac arrhythmias that may lead to sudden death, hypertension, stroke, cardiomyopathy, and perforated nasal septum. Marijuana is the most commonly used illicit drug. It can produce mild to profound intoxication and may be associated with long-term effects from chronic use. Other commonly abused drugs include hallucinogens (LSD, mescaline, MDMA), benzodiazepines, and amphetamines.
- Other causes of injury include physical trauma, thermal injury (burns), electrical injury, drowning, and radiation injury.

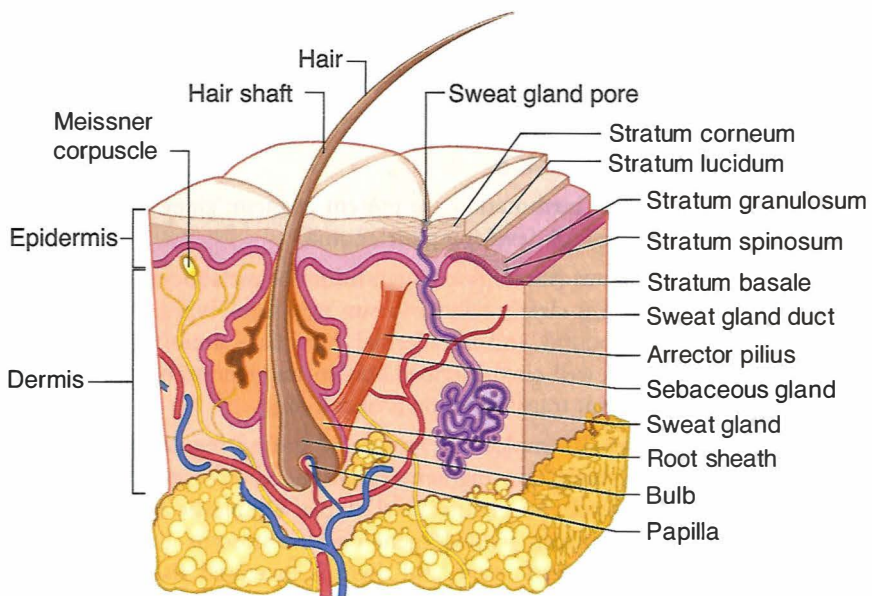
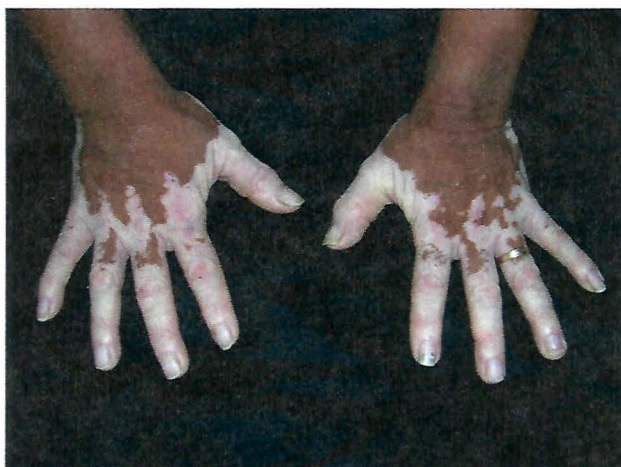

Figure 11-1. Skin

DISORDERS OF PIGMENTATION

1. **Vitiligo** causes irregular, completely depigmented skin patches. It is common and can affect any race; there may also be a familial predisposition. The disease has an unknown etiology that is possibly autoimmune. Microscopically, affected areas are devoid of melanocytes.



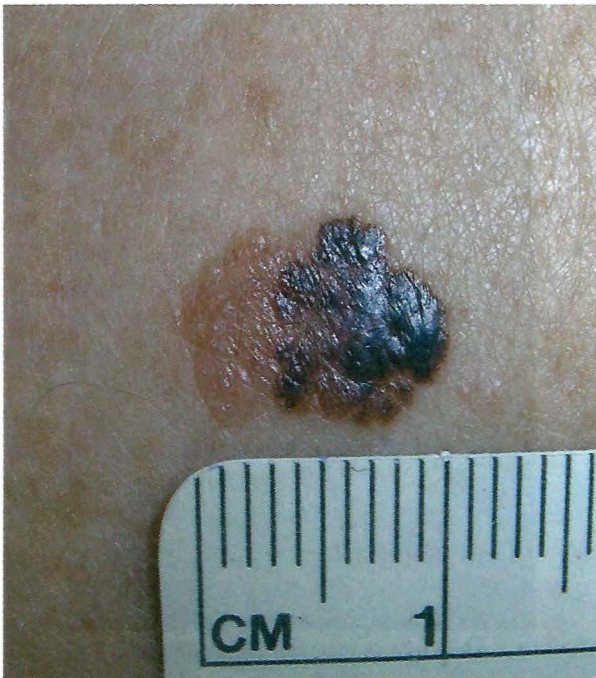© Richard P. Usatine, M.D. Used with permission.

Figure 11-2. Vitiligo

2. **Melasma** causes irregular blotchy patches of hyperpigmentation on the face; it is associated with oral contraceptive use and pregnancy (“mask of pregnancy”) and may regress after pregnancy.
3. **Freckles** (ephelides) are light brown macules on the face, shoulders, and chest. They are common in fair-skinned children; and tend to darken and fade with the seasons due to sunlight exposure. Microscopically, freckles are characterized by increased melanin deposition in the basal cell layer of the epidermis with a normal number of melanocytes.
4. Benign **lentigo** is a localized proliferation of melanocytes which cause small, oval, light brown macules. Microscopically, benign lentigos show linear melanocytic hyperplasia.

MELANOCYTIC TUMORS

1. **Congenital nevi** (birthmarks) are present at birth; giant congenital nevi have increased risk of developing melanoma.
2. **Nevocellular nevus** (mole) is a benign tumor of melanocytes (melanocytic nevus cells) that is clearly related to sun exposure. Types of nevi include junctional, compound, and intradermal. Nevi have uniform tan to brown color with sharp, well-circumscribed borders and tend to be stable in shape and size. Malignant transformation is uncommon.
3. **Dysplastic nevi** (BK moles) are larger and more irregular than common nevi, and they may have pigment variation. Microscopically, the nevus exhibits cytological and architectural atypia. Dysplastic nevus syndrome is autosomal dominant (CMM1 gene on chromosome 1); patients often have multiple dysplastic nevi; and there is increased risk of developing melanoma.
4. **Malignant melanoma** is a malignancy of melanocytes whose incidence is increasing at a rapid rate, with peak in ages 40–70. Risk factors include chronic sun exposure, sunburn, fair skin, dysplastic nevus syndrome, and familial melanoma (associated with loss of function mutation of the p16 tumor suppressor gene on chromosome 9). Melanomas characteristically form skin lesions of large diameter with asymmetric and irregular borders and variegated color; the lesions may be macules, papules, or nodule. Melanomas on males have increased frequency on the upper back; females have increased frequency on the back and legs.
 - a. Several **types of melanomas** occur:
 - Lentigo maligna melanoma is usually located on the face or neck of older individuals and has the best prognosis.
 - Superficial spreading melanoma is the most common type of melanoma and has a primarily horizontal growth pattern.
 - Acral lentiginous melanoma is the most common melanoma in dark-skinned individuals; it affects palms, soles, and subungual area.
 - Nodular melanoma is a nodular tumor with a vertical growth pattern that has the worst prognosis of the melanomas.



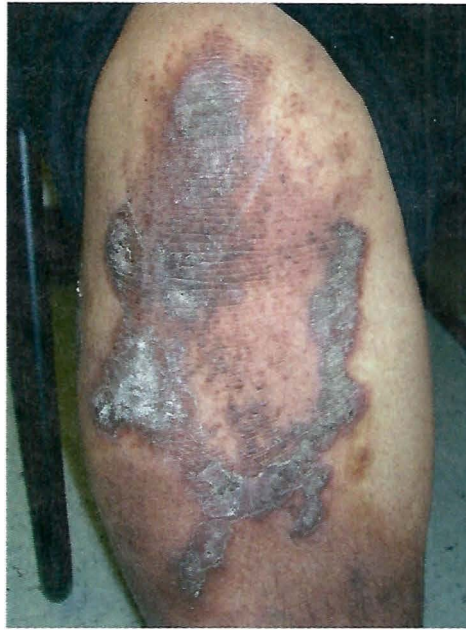© Richard P. Usatine, M.D. Used with permission.

Figure 11-3. Melanoma

- b. The **prognosis** of melanomas is determined by staging based on the depth of invasion (vertical growth, Breslow's thickness, or Clark's levels). Local treatment is with wide surgical excision; systemic disease is treated with chemotherapy or immunotherapy. A few melanomas may resolve spontaneously.

EPIDERMAL AND DERMAL LESIONS

1. **Acanthosis nigricans** causes thickened, hyperpigmented skin in axillae and groin; it is often associated with obesity and hyperinsulinism. On rare occasions it is associated with internal malignancy (stomach and other gastrointestinal malignancies).
2. **Seborrheic keratoses** are benign squamoproliferative neoplasms that are very common in middle-aged and elderly individuals; they may occur on the trunk, head, neck, and the extremities. The lesions are tan to brown coin-shaped plaques that have a granular surface with a "stuck on" appearance, characterized microscopically by basaloid epidermal hyperplasia and "horn cysts" (keratin-filled epidermal pseudocysts). They are usually left untreated, but may be removed if they become irritated or for cosmetic purposes. The sign of Leser-Trélat (paraneoplastic syndrome) is the sudden development of multiple lesions which may accompany an underlying malignancy.
3. **Psoriasis** is an autoimmune disorder with a clear genetic component that causes increased proliferation and turnover of epidermal keratinocytes; it affects 1% of the U.S. population. The most common form is psoriasis vulgaris. Common sites of involvement include the knees, elbows, and scalp; the classic skin lesion is a well-demarcated erythematous plaque with a silvery scale. Removal of scale results in pinpoint bleeding (Auspitz sign). Nail beds show pitting and discoloration. Psoriasis may be associated with arthritis, enteropathy, and myopathy.



© Richard P. Usatine, M.D. Used with permission.

Figure 11-4. The silvery plaques of psoriasis

- a. **Microscopically**, the lesions show epidermal hyperplasia (acanthosis), patchy hyperkeratinization with parakeratosis, uniform elongation and thickening of the rete ridges, thinning of the epidermis over the dermal papillae, and Munro microabscesses.
 - b. **Treatment** is with topical steroids and ultraviolet irradiation; severe systemic disease may be treated with methotrexate.
4. **Pemphigus** is a rare, potentially fatal autoimmune disorder that is characterized by intraepidermal blister formation. Pemphigus vulgaris is the most common form. The pathogenesis involves the production of autoantibodies directed against a part of the keratinocyte desmosome called *desmoglein 3*, with resulting loss of intercellular adhesion (acantholysis) and blister formation. Classically, pemphigus causes easily ruptured, flaccid blisters.
 - a. **Microscopic examination** shows intraepidermal acantholysis; the acantholysis leaves behind a basal layer of keratinocytes, which has a tombstone-like arrangement. Immunofluorescence shows a net-like pattern of IgG staining between the epidermal keratinocytes that create bullae.
 5. **Bullous pemphigoid** is a relatively common autoimmune disorder of older individuals characterized by subepidermal blister formation with tense bullae that do not rupture easily. The condition results from production of autoantibodies directed against a part of the keratinocyte hemidesmosome called *bullous pemphigoid antigens 1 and 2*. Immunofluorescence shows linear deposits of IgG at the epidermal-dermal junction.
 6. **Dermatitis herpetiformis** is a rare immune disorder that is often associated with celiac sprue; it is characterized by subepidermal blister formation with itchy, grouped vesicles and occasional bullae on the extensor surfaces. Production of IgA antibodies directed against gliadin and other antigens deposit in the tips of the dermal papillae and result in subepidermal blister formation. Routine microscopy shows microabscesses at the tips of the dermal papillae that can lead to eventual subepidermal separation results in blister formation; immunofluorescence shows granular IgA deposits at the tips of the dermal papillae. Dermatitis herpetiformis often responds to a gluten-free diet.

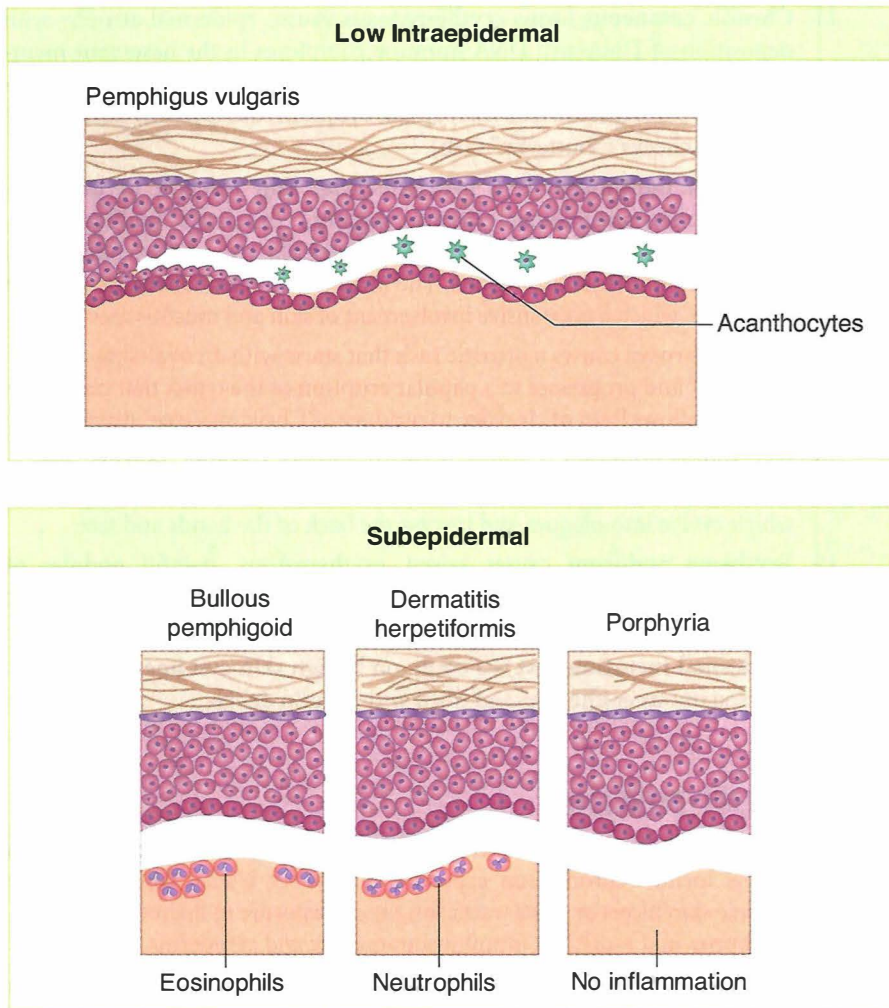


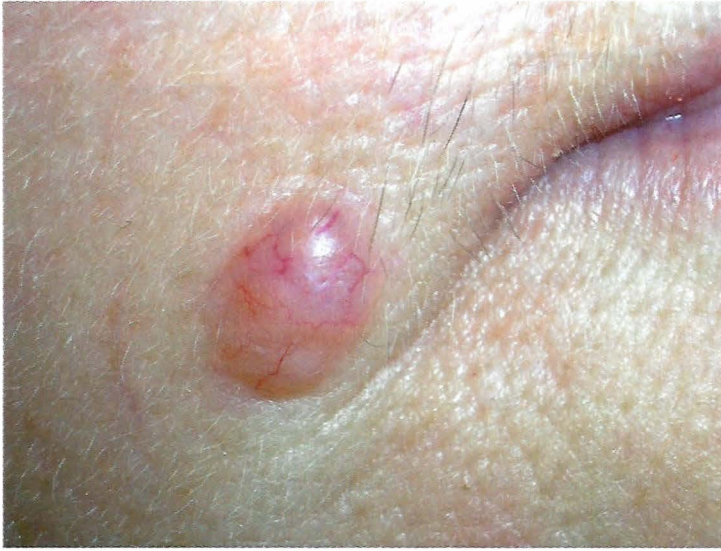Figure 11-5. Intraepidermal and Subepidermal Blisters

7. **Ichthyosis vulgaris** is a common inherited (autosomal dominant) skin disorder characterized by a thickened stratum corneum with absent stratum granulosum. Patients have hyperkeratotic, dry skin that particularly involves palms, soles, and extensor areas.
8. **Xerosis** is a common cause of pruritus and dry skin in the elderly that is due to decreased skin lipids.
9. **Eczema** is a group of related inflammatory skin diseases characterized by pruritus:
 - Acute eczema causes a vesicular, erythematous rash.
 - Chronic eczema develops following chronic scratching, and is characterized by dry, thickened, hyperkeratotic skin.
 - Atopic dermatitis is due to an IgE-mediated hypersensitivity reaction and causes dry skin and eczema.
 - Contact dermatitis can be either allergic type (poison ivy, nickel in jewelry) or photodermatitis type (such as photosensitivity reaction after tetracycline).
10. **Polymorphous light eruption** is the most common form of photodermatitis and causes erythematous macules, papules, plaques, or vesicles on exposure to sunlight.

11. **Chronic cutaneous lupus erythematosus** causes epidermal atrophy with deposition of DNA-anti DNA immune complexes in the basement membrane of the epidermis. Clinically, chronic cutaneous lupus erythematosus causes an erythematous maculopapular eruption that typically involves the nose and cheeks (“butterfly” rash).
12. **Erythema multiforme** is a hypersensitivity skin reaction to infections (*Mycoplasma pneumoniae*, herpes simplex) or drugs (sulfonamides, penicillin, barbiturates, phenytoin) characterized by vesicles, bullae, and “targetoid” erythematous lesions. The most severe form is Stevens-Johnson syndrome, which has extensive involvement of skin and mucous membranes.
13. **Pityriasis rosea** causes a pruritic rash that starts with an oval-shaped “herald patch” and progresses to a papular eruption of the trunk that characteristically follows lines of cleavage to produce a “Christmas tree” distribution.
14. **Granuloma annulare** is a chronic inflammatory disorder, possibly associated with diabetes mellitus, that causes formation of erythematous papules, which evolve into plaques and involve the back of the hands and feet.
15. **Erythema nodosum** causes raised, erythematous, painful nodules of subcutaneous adipose tissue, typically on the anterior shins, which can be associated with granulomatous diseases and streptococcal infection.
16. **Epidermal inclusion cyst** is a common benign skin cyst lined with stratified squamous epithelium and filled with keratin debris.

MALIGNANT TUMORS

1. **Squamous cell carcinoma (SCC)** has peak incidence at 60 years of age. Risk factors include chronic sun exposure (ultraviolet UVB); fair complexion; chronic skin ulcers or sinus tracts; long-term exposure to hydrocarbons, arsenic, burns, and radiation; immunosuppression; and xeroderma pigmentosa.
 - a. **Precursors** include actinic keratosis (a sun-induced dysplasia of the keratinocytes that causes rough, red papules on the face, arms, and hands) and Bowen disease (squamous cell carcinoma *in situ*).
 - b. **Squamous cell carcinoma** occurs on sun-exposed areas (face and hands) and causes a tan nodular mass which commonly ulcerates. Microscopic examination shows nests of atypical keratinocytes that invade the dermis, (oftentimes) formation of keratin pearls, and intercellular bridges (desmosomes) between tumor cells. Squamous cell carcinoma of the skin rarely metastasizes and complete excision is usually curative.
 - c. A variant is **keratoacanthoma** (well differentiated SCC), which causes rapidly growing, dome-shaped nodules with a central keratin-filled crater; these are often self-limited and may regress spontaneously.
2. **Basal cell carcinoma** is the most common tumor in adults in the Western world; it is most common in middle-aged or elderly individuals and arises from the basal cells of hair follicles. Risk factors include chronic sun exposure, fair complexion, immunosuppression, and xeroderma pigmentosum. Basal cell carcinomas occur on sun-exposed, hair-bearing areas (face), and may form pearly papules; nodules with heaped-up, translucent borders, telangiectasia, or ulcers (rodent ulcer). Microscopically, basal cell carcinomas show invasive nests of basaloid cells with a palisading growth pattern. These tumors grow slowly and rarely metastasize, but may be locally aggressive. Shave biopsies have a 50% recurrence rate, but complete excision is usually curative.



© Richard P. Usatine, M.D. Used with permission.

Figure 11-6. Pearly papule characteristic of a basal cell carcinoma

3. **Histiocytosis X** (Langerhans cell histiocytosis) is a proliferation of Langerhans cells (histiocytes), which are normally found within the epidermis. The three clinical variants are:
- Unifocal histiocytosis X (eosinophilic granuloma)
 - Multifocal histiocytosis X (Hand-Schüller-Christian disease)
 - Acute disseminated histiocytosis X (Letterer-Siwe syndrome).

The Langerhans cells are CD 1a positive and on electron microscopy show cytoplasmic Birbeck granules (tennis-racket-shaped).

Chapter Summary

- Disorders of skin pigmentation include vitiligo (irregular depigmented patches due to lack of melanocytes of possibly autoimmune etiology), melasma (“mask of pregnancy”), ephelides (freckles), and benign lentigos (like freckles but not under control of sun exposure).
- Melanocytic tumors include congenital nevi (birthmarks, giant ones have increased risk of melanoma), nevocellular nevi (common moles with proliferating nevus cells; subclassified as junctional, compound, and intradermal), dysplastic nevi (larger, more irregular, and with more pigment variation than common moles, cytological and architectural atypia, may be part of autosomal dominant nevus syndrome with increased risk of melanoma if multiple), and malignant melanoma.
- Malignant melanoma (risk factors: sun exposure, fair skin, dysplastic nevus syndrome) has a rapidly increasing incidence (peak middle age and older) and prognosis ranging from excellent (thin lesions that can be completely excised) to poor (metastatic lesions, often arising in primary sites with tumor thickness greater than 1 mm). In general melanomas cause asymmetric, irregular, large-diameter macules, papules, or nodules with variegated color, found most often on the upper back of men and the back and legs of women. Subtypes include lentigo maligna (best prognosis, face or neck of older individuals), superficial spreading (most common type, horizontal growth pattern), acral-lentiginous (palms, soles, and subungual area of dark-skinned individuals), and nodular melanoma (vertical growth pattern with worst prognosis).
- Benign epidermal and dermal lesions include acanthosis nigricans (thickened, hyperpigmented skin in axillae and groin that may be associated with internal malignancy), seborrheic keratoses (very common benign squamo-proliferative tan to brown coin-shaped plaques that appear “stuck on” the trunk, head, neck, and extremities of middle-aged and elderly people), and psoriasis (well-demarcated erythematous plaques with silvery scale and pinpoint bleeding after scale removal commonly involving knees, elbows, and scalp; micro shows epidermal hyperplasia, parakeratosis, and Munro abscesses; genetic component and associations with arthritis, enteropathy, and myopathy).

Other skin lesions include ichthyosis vulgaris, xerosis, eczema, polymorphous light eruption, cutaneous lupus erythematosus, erythema multiforme, pityriasis rosea, granuloma annulare, erythema nodosum, and epidermal inclusion cysts.

- Malignant tumors of the skin in addition to melanoma include squamous cell carcinoma (peak at age 60; sun and other risk factors; precursor lesions actinic keratosis and Bowen disease; excision usually curative; variant keratoacanthoma may resolve spontaneously), basal cell carcinoma (most common tumor of adults in the United States; middle-aged or older; sun exposure and other risk factors; variable appearance including pearly papules, nodules, telangiectasia, and ulceration; rarely metastasize but may be locally aggressive), histiocytosis X (proliferation of Birbeck granule-containing Langerhans cells of skin; unifocal variant: eosinophilic granuloma, multifocal variant: Hand-Schüller-Christian disease, acute disseminated: Letterer-Siwe syndrome).

RED BLOOD CELL MORPHOLOGY

1. **Red cell shapes.** Abnormal size is called anisocytosis (*aniso* means unequal). Abnormal shape is called poikilocytosis (*poikilo* means various). **Elliptocytes** may be seen in hereditary elliptocytosis. **Spherocytes** result from decreased erythrocyte membrane, and they may be seen in hereditary spherocytosis and in autoimmune hemolytic anemia. **Target cells** result from increased erythrocyte membrane, and they may be seen in hemoglobinopathies, thalassemia, and liver disease. **Acanthocytes** have irregular spicules on their surfaces; numerous acanthocytes can be seen in abetalipoproteinemia. **Echinocytes** (burr cells) have smooth undulations on their surface; they may be seen in uremia or more commonly as an artifact.

Schistocytes are erythrocyte fragments (helmet cells are a type of schistocyte); they can be seen in microangiopathic hemolytic anemias or traumatic hemolysis. **Bite cells** are erythrocytes with “bites” of cytoplasm being removed by splenic macrophages; they may be seen in G6PD deficiency. **Teardrop cells** (dacryocytes) may be seen in thalassemia and myelofibrosis. **Sickle cells** (drepanocytes) are seen in sickle cell anemia. **Rouleaux** (“stack of coins”) refers to erythrocytes lining up in a row. Rouleaux are characteristic of multiple myeloma.

2. **Red cell inclusions.** **Basophilic stippling** results from cytoplasmic remnants of RNA; it may indicate reticulocytosis or lead poisoning. **Howell-Jolly bodies** are remnants of nuclear chromatin that may occur in severe anemias or patients without spleens. **Pappenheimer bodies** are composed of iron, and they may be found in the peripheral blood following splenectomy. **Ring sideroblasts** have iron trapped abnormally in mitochondria, forming a ring around nucleus; they can be seen in sideroblastic anemia. **Heinz bodies** result from denatured hemoglobin; they can be seen with glucose-6-phosphate dehydrogenase deficiency.

ANEMIAS

1. **Anemia** is a reduction below normal limits of the total circulating red cell mass. Signs of anemia include palpitations, dizziness, angina, pallor of skin and nails, weakness, claudication, fatigue, and lethargy.
 - a. **Laboratory terms** that are used with respect to the population of erythrocytes include **mean corpuscular volume** (MCV, which is the average volume of a red blood cell); **mean corpuscular hemoglobin** (MCH, which is the average content (mass) of hemoglobin per cell); **mean corpuscular hemoglobin concentration** (MCHC, which is the average concentration of hemoglobin in a given volume of packed erythrocytes); and **red cell distribution width** (RDW, which is the coefficient of variation of red blood cell volume and is a measure of anisocytosis).
 - b. **Reticulocytes** are immature, larger red cells (macrocytic cells) that are spherical and have a bluish color (polychromasia) due to free ribosomal RNA. Reticulocytes do not have a nucleus; note that any erythrocyte with a nucleus (nRBC) in peripheral blood is abnormal. Reticulocyte

Bridge to Physiology

Patients with anemia have normal SaO_2 and PaO_2 , but they have reduced oxygen content due to the low level of hemoglobin.

maturation to a mature erythrocyte takes about 1 day. The reticulocyte count is the percentage of red immature cells present in peripheral blood (normal = 0.5% to 1.5%).

The corrected reticulocyte count takes into consideration the degree of anemia and is calculated as $(\text{patient's hct}/45) \times (\text{reticulocyte count})$; the idea behind the calculation is to scale the reticulocyte count by multiplying by the ratio of the patient's hematocrit to "normal" hematocrit of 45%. When interpreting the corrected reticulocyte count, $<2\%$ indicates poor bone marrow response and $>3\%$ indicates good bone marrow response.

The reticulocyte production index is the corrected reticulocyte count/2; use this measure if bone marrow reticulocytes (shift cells) are present (polychromasia). The division by 2 is because shift cells take twice as long as reticulocytes to mature (2 days versus 1 day).

- c. **Classification of anemia** can be based on color: normochromic anemias have normal red cell color (central pallor of about a third the diameter of the erythrocyte); hypochromic anemias have decreased color (seen as an increased central pallor of erythrocyte); and hyperchromic anemias, while theoretically possible, are usually instead called spherocytosis and have increased color (loss of central pallor of erythrocyte). Classification of anemia can also be based on size (MCV); see Figure 12-1 for details.

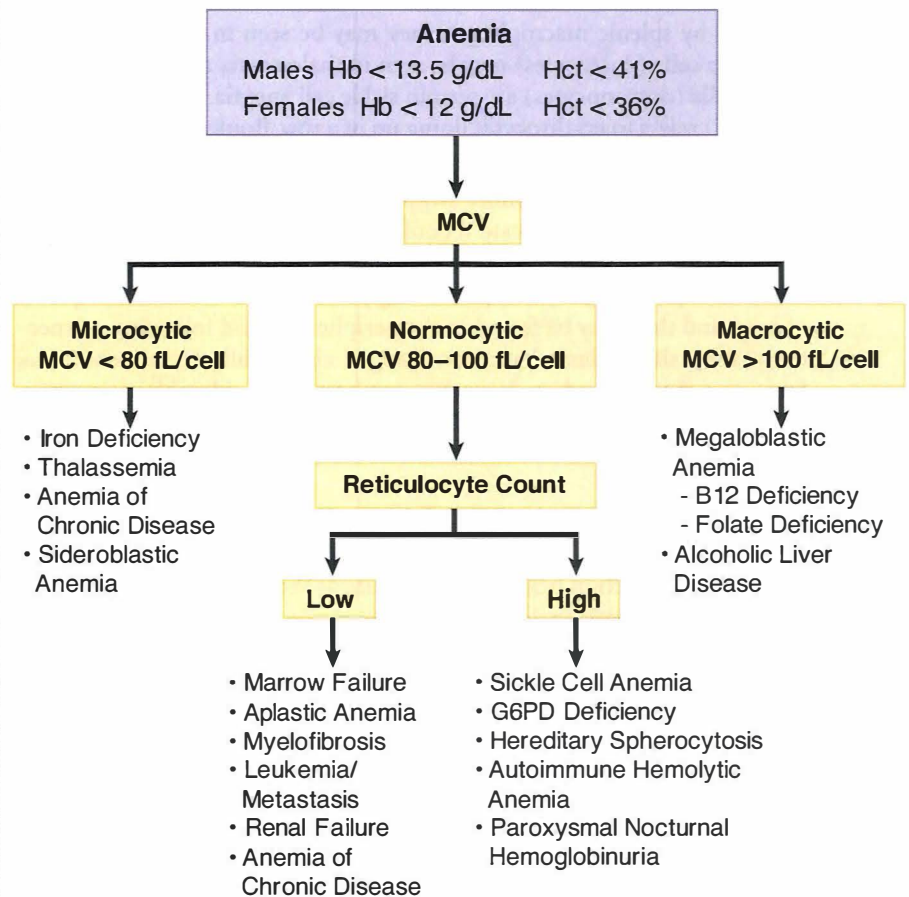


Figure 12-1. Classification of Anemias Based on MCV

2. The **pathogenesis of anemia** varies with the underlying disease. Blood loss can cause anemia. **Hemolytic anemias** are also important, and include hereditary spherocytosis, glucose-6-phosphate dehydrogenase deficiency, sickle cell disease, hemoglobin C disease, thalassemia, and paroxysmal nocturnal hemoglobinuria. **Immuno-hemolytic anemias**, which are hemolytic anemias with an immune component to the pathology, include autoimmune hemolytic anemia (AIHA), cold AIHA, incompatible blood transfusions, and hemolytic disease of the newborn. **Anemias of diminished erythropoiesis** include megaloblastic anemia (B12 and folate deficiencies), iron deficiency anemia, anemia of chronic disease, aplastic anemia, myelophthisic anemia, and sideroblastic anemia.

MICROCYTIC ANEMIAS

1. Iron deficiency anemia.

- a. **Iron physiology.** Functionally available iron is normally found in hemoglobin, myoglobin, and enzymes (catalase and cytochromes). Additionally, ferritin is the physiological storage form (plasma ferritin is normally close to the total body Fe), and hemosiderin (Prussian blue positive) is iron precipitated in tissues in the form of degraded ferritin mixed with lysosomal debris.

Iron is transported in the blood stream by transferrin. Transferrin levels are measured as total iron-binding capacity (TIBC) (normal = 300 mg/dL), with the normal % saturation being one-third saturation (as normal serum iron is 100 mg/dL).

- b. **Causes of iron deficiency.** Dietary deficiency of iron is seen in elderly populations and in children and the poor. Increased demand for iron is seen in children and pregnant women. Additionally, iron deficiency can develop because of decreased absorption, either due to generalized malabsorption or more specifically after gastrectomy (due to decreased acid, which is needed for ferrous absorption) or when there is decreased small intestinal transit time (causing “dumping syndrome”). Iron deficiency can also be due to chronic blood loss due to gynecologic (menstrual bleeding) or gastrointestinal causes (in the United States, think carcinoma; in the rest of the world, think hookworm).
- c. **Sequence of events during iron deficiency.** **Initially**, decreased storage iron produces decreased serum ferritin and decreased bone marrow iron on Prussian blue stains. The **next stage** in iron deficiency has decreased circulating iron, which causes decreased serum iron, increased total iron binding capacity, and decreased % saturation. The **last stage** is formation of microcytic/hypochromic anemia, with decreased mean corpuscular volume (MCV), decreased mean corpuscular hemoglobin concentration (MCHC), and high red blood cell distribution width (RDW).
- d. **Other clinical features of iron deficiency** include increased free erythrocyte protoporphyrin (FEP), epithelial atrophy if Plummer-Vinson syndrome is present, koilonychia (concave nails [spoon nails] with abnormal ridging and splitting), and pica (eating unusual things, e.g. dirt).

Clinical Correlate

Ferritin is an acute-phase reactant and may be non-specifically elevated in inflammatory states.

Table 12-1. Iron Panel for Microcytic Anemias

	Iron Deficiency	AOCD	Thalassemia Minor	Sideroblastic Anemia
Serum iron	↓	↓	Normal	↑
TIBC	↑	↓	Normal	↓
% saturation	↓	↓	Normal	↑
Serum ferritin	↓	↑	Normal	↑

Note**Composition of hemoglobins:**

- HbA (2 alpha, 2 gamma)
- HbA₂ (2 alpha, 2 delta)
- HbF (2 alpha, 2 gamma)
- Hb Barts (4 gamma)
- Hb H (4 beta)

2. **Anemia of chronic disease (AOCD)** is characterized by iron being trapped in bone marrow macrophages, leading to decreased utilization of endogenous iron stores. Laboratory studies show increased serum ferritin with decreased total iron binding capacity. Chronic inflammatory disorders may be associated with increased IL-1, and hepcidin, produced by the liver, prevents the release of iron stores, trapping it in bone marrow macrophages, leading to the anemia of chronic disease.
3. **Thalassemia syndromes** are quantitative, not qualitative, abnormalities of hemoglobin. α -thalassemia has decreased α -globin chains with relative excess β chains, while β -thalassemia has decreased β -globin chains with relative excess α chains. It is hypothesized that the thalassemia genes have been selectively preserved in the human genome because the thalassemias provide a protective advantage to carriers exposed to diseases such as malaria.
4. **α -thalassemia.** There are a total of 4 α -globin chain genes, 2 from each parent. α -Thalassemia is due to gene deletions in the α -globin chain genes, and the clinical manifestations depend upon the number of genes that are affected. α chains are normally expressed prenatally and postnatally; therefore, there is prenatal and postnatal disease. In normal individuals, 4 α genes ($\alpha\alpha/\alpha\alpha$) are present and 100% of the α chains are normal.
 - a. In the **silent carrier state**, one deletion is present, and the total number of α genes available is 3 ($-\alpha/\alpha\alpha$), which produce 75% of the needed α chains. Individuals with the silent carrier state are completely asymptomatic and all lab tests are normal.
 - b. In **α -thalassemia trait**, 2 deletions are present, and the total number of available α genes is 2, which produce 50% of the needed α chains. The genotype cis ($- -/\alpha\alpha$) is seen in Asians, while the genotype trans ($-\alpha/-\alpha$) is seen in African Americans (offspring don't develop hemoglobin H disease or hydrops fetalis).
 - c. **Hemoglobin H disease** is characterized by 3 deletions, with the number of α genes being 1 ($- -/-\alpha$), which produces 25% of the normal α chains. There is increased Hb H (β_4), which forms Heinz bodies that can be seen with crystal blue stain.
 - d. **Hydrops fetalis** has 4 deletions and is lethal in utero, because the number of α genes is 0 ($- -/- -$), producing 0% α chains.
5. **β -thalassemia.** There are a total of 2 β -globin chain genes. In contrast to the α -globin chain genes, the 2 β -globin chain genes are expressed postnatally only, and therefore there is only postnatal disease and not prenatal disease. The damage to the genes is mainly by point mutations, which form either some β chains (β^+) or none (β^0).

- a. **β -thalassemia minor** is seen when one of the β -globin chain genes has been damaged. The condition is asymptomatic, and characterized on laboratory studies by increased hemoglobin A2 (8%) and increased hemoglobin F (5%).
 - b. **β -thalassemia intermedia** has a severe anemia, but no transfusions are needed.
 - c. **β -thalassemia major** (Cooley anemia). Patients are normal at birth, and symptoms develop at about 6 months as hemoglobin F levels decline. Severe hemolytic anemia results from decreased erythrocyte life span. This severe anemia causes multiple problems:
 - Intramedullary destruction results in “ineffective erythropoiesis.”
 - Hemolysis causes jaundice and an increased risk of pigment (bilirubin) gallstones.
 - Lifelong transfusions are required, which result in secondary hemochromatosis.
 - Congestive heart failure (CHF) is the most common cause of death.

Erythroid hyperplasia in the bone marrow causes “crewcut” skull x-ray and increased size of maxilla (“chipmunk face”). The peripheral blood shows microcytic/hypochromic anemia with numerous target cells and increased reticulocytes. Hemoglobin electrophoresis shows increased hemoglobin F (90%), increased hemoglobin A2, and decreased hemoglobin A.
6. **Sideroblastic anemia** is a disorder in which the body has adequate iron stores, but is unable to incorporate the iron into hemoglobin. It is associated with ring sideroblasts (accumulated iron in mitochondria of erythroblasts) in bone marrow. Sideroblastic anemia may be either pyridoxine (vitamin B6) responsive or pyridoxine unresponsive; the latter is a form of myelodysplastic syndrome (refractory anemia with ring sideroblasts). The peripheral blood may show a dimorphic erythrocyte population. Laboratory studies show increased serum iron, ferritin, FEP, and % saturation of TIBC, with decreased TIBC.

NORMOCYTIC ANEMIAS

1. **Anemias of blood loss.** Acute blood loss may cause shock or death. If the patient survives, the resulting hemodilution caused by shift of water from the interstitium will lower the hematocrit. There will be a marked reticulocytosis in 5–7 days. Chronic blood loss, such as from the gastrointestinal tract or from the gynecologic system, may result in iron deficiency anemia.
2. **Hemolytic anemias.**
 - a. In **intravascular (IV) hemolysis**, release of hemoglobin into the blood causes hemoglobinemia and hemoglobinuria; increased bilirubin from erythrocytes causes jaundice and an increased risk of pigment (bilirubin) gallstones. The hemoglobin may be oxidized to methemoglobin, which causes methemoglobinemia and methemoglobinuria. Markedly decreased (because they have been used up) hemoglobin-binding proteins in the blood, such as haptoglobin and hemopexin, are characteristic. No splenomegaly is seen.
 - b. In contrast, in **extravascular (EV) hemolysis**, splenomegaly results if the EV hemolysis occurs in the spleen and hepatomegaly results if the EV hemolysis occurs in the liver. EV hemolysis shows increased bilirubin and decreased haptoglobin, but not to the degree with intravascular hemolysis. In EV hemolysis, there is an absence of hemoglobinemia, hemoglobinuria, and methemoglobin formation.

Note

Disseminated intravascular coagulation (DIC) is a syndrome of global intravascular coagulation which occurs as a result of an imbalance between systemic procoagulant and anticoagulant mechanisms. Common precipitants include tissue and endothelial cell injury and systemic infection. The common pathophysiologic factor is the introduction of tissue factor into the circulation. This initiates a self-potentiating cycle of activation of platelets, inflammatory cells, and cytokines which leads to consumptive coagulation and microvascular thromboses. It manifests clinically as bleeding and multi-organ dysfunction, which may progress to failure. Microangiopathic hemolytic anemia also occurs as a result of blood cells passing through vessels that are partially occluded by thrombi.



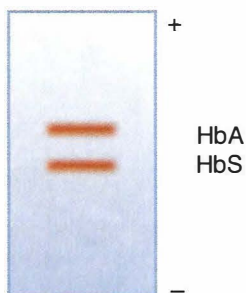
Parvovirus

- ssDNA (linear)
- Naked icosahedral

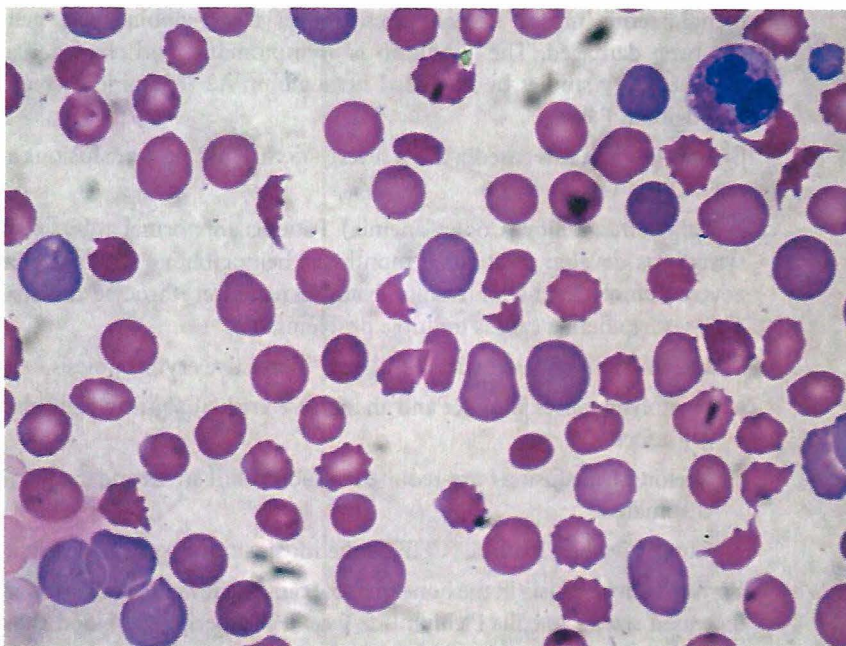
Note

Hemoglobin electrophoresis

takes advantage of the differences in pH values between HbA and HbS (Glu6Val; glutamate at position 6 has been replaced by valine).



Hemoglobin electrophoresis at pH 8.4



© commons.wikimedia.org. Used with permission.

Figure 12-2. DIC with Microangiopathic Hemolytic Anemia as Evidenced by Helmet Cells/Schistocytes

3. **Sickle cell disease** is an inherited blood disorder leading to the formation of hemoglobin S and increased propensity for the affected red blood cells to become sickle-shaped and occlude small vessels. The genetic abnormality is a single nucleotide change that causes valine (neutral) to replace normal glutamic acid (acidic) at the sixth position of the β -globin chain. This biochemical change then makes a critical point on the surface of the hemoglobin molecule become hydrophobic, making it feel “sticky” to an adjacent hemoglobin molecule, thereby favoring hemoglobin precipitation in crystalline form.

Heterozygous (AS) genome causes sickle cell trait. About 8% of African Americans are heterozygous for hemoglobin S. Patients with sickle trait have fewer symptoms than those with sickle disease, and also have resistance to *Plasmodium falciparum* infection (malaria), which may be why the disease has remained in the human genetic pool. Homozygous (SS) genome causes clinical disease (sickle cell anemia).

- Factors affecting formation of irreversibly sickled red blood cells.** **Increased concentration** (dehydration) makes symptoms worse; decreased concentration of sickled hemoglobin (as is seen if a sickle cell patient also has a thalassemia) makes symptoms better. **Decreased pH** decreases oxygen affinity and makes symptoms worse. **Increased hemoglobin F** makes symptoms better (rationale for therapy with hydroxyurea, which increases blood hemoglobin F levels). The **presence of hemoglobin C** (SC: double-heterozygote individual) makes symptoms better.
- Clinical features.** Increased erythrocyte destruction causes a severe hemolytic anemia, which is accompanied by erythroid hyperplasia in the bone marrow and increased bilirubin leading to jaundice and gallstone (pigment) formation. Capillary thrombi result from sickle cells blocking small vessels and may cause vaso-occlusive (painful) crisis; hand-foot syndrome (swelling) in children; and autosplenectomy, which is seen in older children and adults. Howell-Jolly bodies will appear in peripheral blood after autosplenectomy, and the lack of a functional spleen predisposes for increased incidence of infections (encapsulated organisms), increased

incidence of *Salmonella* osteomyelitis (leg pain), leg ulcers, and risk of aplastic crisis (especially with *parvovirus B19* infection). Emergencies that may occur include priapism and acute chest syndrome.

- c. **Laboratory tests** for hemoglobin S include the sickling test (metabisulfite test, which can't tell sickle cell disease from sickle cell trait) and hemoglobin electrophoresis. Prenatal diagnosis is with genetic testing (MstII endonuclease). Therapy includes hydroxyurea, which increases hemoglobin F.
4. **Hemoglobin C disease** occurs when a single nucleotide change in a codon causes lysine (basic) to replace normal glutamic acid (acidic) at the beta 6 position. Hemoglobin C disease is characterized by mild normochromic-normocytic anemia, splenomegaly, target cells, and rod-shaped crystals in erythrocytes (the latter being characteristic).
5. **Glucose-6-phosphate dehydrogenase deficiency (G6PD)** is a genetic disorder affecting the hexose monophosphate shunt pathway. It results in decreased levels of the antioxidant glutathione (GSH), leaving erythrocytes sensitive to injury by oxidant stresses leading to hemolysis. G6PD is not due to decreased synthesis but rather to defective protein folding, resulting in a protein having a decreased half-life. The condition has X-linked inheritance.
 - a. In **African Americans (A⁻ type)** with G6PD, the hemolysis is secondary to acute oxidative stress, such as oxidative drugs (primaquine, sulfonamides, anti-tuberculosis drugs), and more typically by viral or bacterial infections. The hemolysis is intermittent (even if the offending drug is continued) because only older erythrocytes have decreased levels of glucose-6-phosphate dehydrogenase.
 - b. In contrast, in individuals with G6PD of **Mediterranean type**, the disease is associated with favism due to ingestion of fava beans; more severe hemolysis occurs because all erythrocytes have decreased glucose-6-phosphate dehydrogenase activity in that there is both decreased synthesis and decreased stability.
 - c. In **both forms**, the oxidation of hemoglobin forms **Heinz bodies**; these cannot be seen with normal peripheral blood stains (Wright-Giemsa) but can be visualized with supravital stains (methylene blue and crystal violet). The Heinz bodies are "eaten" by splenic macrophages (extravascular hemolysis), which may form "bite cell" erythrocytes that are visible on routine peripheral blood smears.
6. **Hereditary spherocytosis (HS)** is an autosomal dominant disorder that is due to a defect involving ankyrin and spectrin (most commonly affecting the ankyrin molecule) in the erythrocyte membrane; this causes a decrease in the erythrocyte surface membrane (spherocytosis). Spherocytes are not flexible and are removed in the spleen by macrophages (i.e., extravascular hemolysis); this causes multiple problems, including splenomegaly with a mild to moderate hemolytic anemia, increased bilirubin and an increased risk for jaundice and pigment gallstones secondary to chronic hemolysis, and increased risk for acute red-cell aplasia due to parvovirus B19 infection. Laboratory testing shows increased osmotic fragility and normal MCH with increased MCHC. Treatment is with splenectomy.
7. **Autoimmune hemolytic anemia (AIHA)** is most commonly warm AIHA, in which the antibodies are IgG that are usually against Rh antigens and are active at 37°C. Erythrocytes to which the antibodies attach are removed by splenic macrophages, which tends to induce splenomegaly as the spleen responds to the perceived need for increased phagocytosis.

The etiology varies; most cases are idiopathic, but some cases are related to autoimmune diseases such as systemic lupus erythematosus, chronic lymphocytic leukemia (CLL), small lymphocytic lymphoma (WDL), or medications (penicillin). The peripheral blood smear typically shows micro-

Bridge to Biochemistry

G6PD is the rate-limiting enzyme in the hexose-monophosphate shunt (HMP).

G6PD normally produces NADPH, which keeps glutathione reduced.

Glutathione protects by breaking down hydrogen peroxide.

Clinical Correlate

The differential diagnosis of spherocytes in the peripheral blood includes warm AIHA and hereditary spherocytosis. Use the osmotic fragility test (HS) and direct Coombs' test (AIHA) to tell them apart.

Clinical Correlate

Aplastic anemic crisis or bone marrow irradiation leads to a loss of bone marrow mass. As stem cells replace the damaged marrow, clones lacking a GPI anchor on all hematopoietic cells may arise. For red blood cells, the lack of CD55 and CD59 (both GPI-linked) leads to the inability to inhibit complement and thus, lysis of red blood cells.

Clinical Correlate

Increased levels of 2,3-bisphosphoglycerate (2,3 BPG) in cells can be seen in pyruvate kinase deficiency, which may affect tissue oxygenation. This will cause a "right shift" in the hemoglobin oxygen saturation curve, implying a decreased oxygen affinity for hemoglobin.

Note

Normal Sequence of B₁₂ Absorption

1. Dietary B₁₂ binds to salivary R-binders.
2. B₁₂-R complex is broken by pancreatic proteases.
3. Free B₁₂ binds to IF, which is secreted by gastric parietal cells.
4. B₁₂-IF complex is absorbed by ileal mucosal epithelial cells.
5. B₁₂ is transported in blood bound to transcobalamin II.

spherocytes, and laboratory confirmation can be obtained by demonstrating a positive direct Coombs test (direct antiglobulin test [DAT]).

8. **Paroxysmal nocturnal hemoglobinuria (PNH)** is a hemolytic anemia caused by an acquired intrinsic defect in the cell membrane, especially in red cells, white cells, and platelets. The abnormality is decreased glycosyl phosphatidyl inositol (GPI)-linked proteins, especially decay accelerating factor (DAF). The function of DAF is to inhibit the activation of the complement cascade by breaking down C3 convertase, and deficiency of DAF results in increased complement activity. All cells in blood have increased sensitivity to the lytic actions of complement. The condition causes episodes (paroxysms) of hemolysis at night.

Acidosis *in vivo* occurs during sleep (breathing slowly retains CO₂) and exercise (lactic acidosis), and the acidosis in turn causes activation of complement. PNH is a clonal stem cell disorder that affects all blood cell lines, leading to pancytopenia (anemia, leukopenia, and thrombocytopenia) that is apparent in the peripheral blood. Complications include increased risks for aplastic anemia, leukemia, and venous thrombosis. Laboratory tests for PNH include sucrose hemolysis of erythrocytes *in vitro* (sucrose lysis test) and acid hydrolysis of erythrocytes *in vitro* (Ham test).

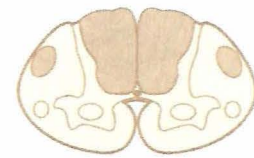
9. **Pyruvate kinase deficiency** is the most common enzyme deficiency in the glycolytic pathway and involves the enzyme that normally converts phosphoenolpyruvate to pyruvate. Deficiency leads to decreased ATP with resulting damage to the erythrocyte membrane. Clinically, there is a hemolytic anemia with jaundice from birth.
10. **Hereditary elliptocytosis** is a mild, hereditary, hemolytic anemia caused by a defect in spectrin. It is characterized by osmotically fragile ovoid erythrocytes ("elliptocytes").
11. **Aplastic anemia** is the term used when marrow failure causes a pancytopenia of the blood. Idiopathic causes for aplastic anemia are most commonly seen; when the etiology is known, the aplastic anemia may be due to medications (alkylating agents, chloramphenicol), chemical agents (benzene, insecticides), infection (EBV, CMV, parvovirus, hepatitis), or whole body radiation (therapeutic or nuclear exposure).

MACROCYTIC ANEMIAS

1. The basic cause of **megaloblastic anemias** is impaired DNA synthesis (delayed mitoses) without impairment of RNA synthesis; this produces a nuclear-cytoplasmic asynchrony that affects all rapidly proliferating cell lines, including cells of the bone marrow, gastrointestinal tract, and gynecologic system. The erythrocytes are the most obvious rapidly proliferating cells that exhibit these changes, and specifically show megaloblastic maturation, with megaloblasts in bone marrow forming macro-ovalocytes in peripheral blood. Autohemolysis of the affected megaloblasts in bone marrow (ineffective erythropoiesis) will cause increased bilirubin and increased lactate dehydrogenase (LDH). White blood cell changes include giant metamyelocytes in bone marrow and hypersegmented neutrophils (>5 lobes) in peripheral blood. Note that platelets are not increased in size.
2. **Megaloblastic anemia due to vitamin B₁₂ (cobalamin) deficiency**
 - a. Several processes can cause B₁₂ deficiency. Dietary deficiency is rare because B₁₂ is stored in the liver and it takes years to develop dietary deficiency; severe enough dietary deficiency is usually seen only in strict vegetarians (diet with no animal protein, milk, or eggs). Decreased absorption of vitamin B₁₂ is more common and may be caused by decreased intrinsic factor associated with gastrectomy or pernicious anemia; pancreatic insufficiency (pancreatic proteases nor-

mally breakdown B₁₂-R complexes in duodenum); or intestinal malabsorption due to parasites (fish tapeworm [*Diphyllobothrium latum*]), bacteria (blind-loop syndrome), or Crohn's disease of the ileum.

- b. **Clinically**, B₁₂ deficiency causes weakness due to anemia (megaloblastic anemia) and sore ("beefy") tongue due to generalized epithelial atrophy. Unlike folate deficiency, vitamin B₁₂ deficiency can also cause the central nervous system effects of subacute combined degeneration of the spinal cord, characterized by demyelination of the posterior and lateral portion of the spinal cord; the posterior (sensory) tract damage causes loss of vibration and position, while the lateral cord damage involves dorsal spinocerebellar tracts (arm and leg dystaxia) and corticospinal tracts (spastic paralysis).
 - c. **Laboratory tests** show low serum B₁₂, increased serum homocysteine, and increased methylmalonic acid in urine. In the Schilling test for pernicious anemia, the test is initially abnormal but corrects with intrinsic factor. This test is performed by giving intramuscular vitamin B₁₂, followed by oral radioactive vitamin B₁₂, and measuring radioactive vitamin B₁₂ in urine. Treatment of vitamin B₁₂ deficiency is with intramuscular vitamin B₁₂, which will cause increased reticulocytes in about 5 days.
3. **Megaloblastic anemia due to folate deficiency** can be caused by multiple processes:
 - a. **Causes**
 - **Decreased intake** (dietary deficiency takes only months to develop and is typically seen in chronic alcoholics and the elderly on "tea and toast" diet)
 - **Decreased absorption** (typically due to intestinal malabsorption; folate is absorbed in the upper small intestine)
 - **Increased requirement for folate** during pregnancy and infancy (folate deficiency during pregnancy is an important cause of neural tube defects)
 - **Decreased utilization of folate** can occur with folate antagonists used in chemotherapy, such as methotrexate.
 - b. **Clinically**, folate deficiency produces megaloblastic anemia without neurologic symptoms (i.e., no SCDS). Laboratory tests typically demonstrate low serum folate levels and increased serum homocysteine. Treatment is with folate replacement.



Subacute combined degeneration

POLYCYTHEMIA VERA

1. **Polycythemia vera** is due to a clonal expansion of a multipotent myeloid stem cell that primarily produces extra erythrocytes. Polycythemia vera also produces lesser degrees of excess granulocytes (neutrophils, eosinophils, basophils), mast cells, and platelets. It is characterized clinically by increased erythrocyte mass, absolute leukocytosis, thrombocytosis, decreased erythropoietin, splenomegaly, hypercellular marrow, thrombotic events (related to blood viscosity), and gout (related to increased blood cell turnover).
2. **Secondary polycythemia** refers to increased red cell mass due to compromised ability of blood to supply oxygen to tissues. Causes include chronic obstructive pulmonary disease and cyanotic congenital heart disease. Erythropoietin levels can be appropriately high. Secondary polycythemia may also be caused by inappropriately high erythropoietin levels, with renal cell carcinoma excreting erythropoietin being the typical cause.
3. **Relative polycythemia** refers to an increased red cell count secondary to decreased plasma volume (typically due to dehydration). Red cell mass, erythropoietin, and blood oxygen content are normal.

Chapter Summary

- Red blood cells can have a variety of abnormal shapes or contain inclusions, either of which may suggest particular diagnoses.
- Anemia is the reduction below normal limits of the total circulating red cell mass, which may lead to palpitations, dizziness, angina, skin pallor, weakness, or other symptoms. Laboratory measures used in the evaluation of anemia include MCV, MCH, MCHC, RDW, and reticulocyte count.
- Anemias can be classified based on size and red cell color. They can also be classified based on pathogenesis, including broad categories of blood loss, hemolytic anemias, and anemias of diminished erythropoiesis.
- Iron deficiency anemia is a microcytic anemia seen most often in the elderly and poor populations, children, pregnant women, and patients with chronic blood loss. Iron deficiency anemia is characterized by decreased serum iron, increased TIBC, decreased percentage saturation, and decreased serum ferritin.
- Anemia of chronic disease can be seen in patients with a variety of chronic systemic diseases and is characterized by decreased serum iron, decreased TIBC, decreased percentage saturation, and increased serum ferritin.
- Thalassemias are anemias due to quantitative abnormalities of synthesis of hemoglobin chains, and are subclassified as alpha thalassemias and beta thalassemias. Alpha-thalassemia has four clinical forms depending upon the number of alpha-globin genes affected: silent carrier, alpha-thalassemia trait, HbH disease, and hydrops fetalis. Beta-thalassemia has three clinical presentations: minor, intermedia, and major.
- Sideroblastic anemias characteristically have ringed sideroblasts in the bone marrow; some cases are a form of myelodysplastic syndrome.
- Anemia of blood loss occurs when a patient survives acute blood loss and undergoes hemodilution that lowers the hematocrit. Chronic cases may develop superimposed iron deficiency anemia.
- Hemolytic anemias can be due to either intravascular or extravascular hemolysis.
- Sickle cell anemia is due to a single nucleotide change in the beta-globin chain and is an important disease of African Americans; it clinically presents as either sickle cell trait or sickle cell anemia. Patients with sickle cell anemia are vulnerable to a variety of complications related to sickled cells blocking small blood vessels.
- Hemoglobin C disease is also related to a single nucleotide change in a globin gene but produces milder disease than sickle cell anemia.
- Glucose-6-phosphate dehydrogenase deficiency is an enzyme deficiency that causes red cells to lyse under oxidant stresses.
- Hereditary spherocytosis is an autosomal dominant disorder due to an abnormal membrane-associated protein, spectrin, which leads to spherical erythrocyte morphology with mild to moderate hemolytic anemia.
- Autoimmune hemolytic anemias can be idiopathic or related to other autoimmune diseases, leukemias and lymphomas, or medications.

(Continued)

Chapter Summary (cont'd)

- Paroxysmal nocturnal hemoglobinuria produces episodic hemolysis as a result of increased red-cell sensitivity to the lytic actions of complement. Pyruvate kinase deficiency is a hereditary cause of hemolytic anemia due a deficiency of a glycolytic pathway enzyme, leading to decreased ATP and resulting in erythrocyte membrane damage. Hereditary elliptocytosis causes mild anemia. Aplastic anemia is a common end pathway of many different disease processes that destroy the marrow's ability to produce blood cells.
- Megaloblastic anemias occur when there is impaired DNA synthesis, which leads to delayed mitoses. Important causes include vitamin B₁₂ deficiency and folate deficiency.
- Polycythemia vera is a clonal disease leading to increased red cells (dominant process) accompanied by lesser degrees of increased granulocytes and platelets. Secondary polycythemia is polycythemia due to increased erythropoietin, which can be either "appropriate" if it helps for a tissue oxygenation problem, or "inappropriate" if the erythropoietin is high because it is secreted by a tumor. Relative polycythemia is the term used for increased hematocrit in the absence of increased red cell mass and is usually due to decreased plasma volume (as in dehydration).

VASCULITIS

1. **Polyarteritis nodosa (PAN)** is a segmental necrotizing vasculitis that typically affects young adults, with males being more often affected than females. The distribution of disease is surprisingly broad, with any organ (kidney, heart, GI tract, muscle, etc.) *except lung* being potentially involved. The vasculitis characteristically affects small and medium size arteries.
 - a. Clinically, **symptoms are varied** and depend on the system involved. Clusters of related symptoms and signs include low-grade fever (fever of unknown origin [FUO]), weight loss, and malaise; hematuria, renal failure, and hypertension; abdominal pain, diarrhea, and GI bleeding; and myalgia and arthralgia.
 - b. The pathology is of a **segmental necrotizing vasculitis** that develops in three stages:
 - Acute lesions show fibrinoid necrosis and neutrophils
 - Healing lesions show prominent fibroblast proliferation
 - Healed lesions show nodular fibrosis and loss of internal elastic lamina

Sequelae following the vascular damage include thrombosis (that may lead to infarction) and aneurysms (particularly in kidneys, heart, and GI tract).
 - c. **Laboratory findings.** Hepatitis B antigen (HBsAg) is positive in 30% of cases, indicating that many cases of polyarteritis nodosa are linked to hepatitis HBV. Perinuclear antineutrophil cytoplasmic autoantibodies (P-ANCA) are only found in the microscopic form of polyarteritis (microscopic polyangiitis); these antibodies are autoantibodies directed against myeloperoxidase, and their presence correlates with disease activity. Arterial biopsy of an apparently affected vessel can confirm the diagnosis.
 - d. The **prognosis** is dismal (fatal in most cases) in untreated patients, but those treated with corticosteroids and cyclophosphamide have a 90% long-term remission.
2. **Churg-Strauss syndrome** (allergic granulomatosis and angiitis) is a variant of polyarteritis nodosa that is associated with bronchial asthma; it causes systemic vasculitis with granulomas and eosinophilia, and involves the lung, spleen, kidney, etc. P-ANCA may be present.
3. **Wegener granulomatosis** is a rare necrotizing vasculitis with granulomas that affects males more than females, with peak incidence at ages 40–60. The disease classically involves nose, sinuses, lungs, and kidneys, with small-sized arteries, capillaries, and veins being damaged.
 - a. **Clinical features** include bilateral pneumonitis with nodular and cavitary pulmonary infiltrates, chronic sinusitis, nasopharyngeal ulcerations, and renal disease (either focal necrotizing or crescentic glomerulonephritis). The diagnosis can be established with biopsy that demonstrates vascular involvement (fibrinoid necrosis, neutrophils) and granulomas. Presence of cytoplasmic antineutrophil cytoplasmic autoantibody

(C-ANCA), an autoantibody directed against proteinase 3, correlates with disease activity.

- b. Untreated cases have an 80% 1-year mortality rate, but **treatment** with immunosuppressive drugs (cyclophosphamide) can yield 90% long-term remission.
4. **Temporal arteritis** (giant cell arteritis) is the most common form of vasculitis; it affects females more than males, and primarily affects the elderly population. It is associated with HLA-DR4.
 - a. The **distribution of disease** includes small and medium-sized arteries, particularly including cranial arteries (temporal, facial, and ophthalmic arteries), and uncommonly the aortic arch (giant cell aortitis).
 - b. **Clinical features** include throbbing headache with tender, firm temporal arteries; visual disturbances that may include blurred vision, double vision, or visual loss; facial pain; fever, malaise, weight loss, muscle aches, and anemia; and polymyalgia rheumatica (systemic flu-like symptoms and joint involvement). Laboratory studies may show an elevated erythrocyte sedimentation rate.
 - c. The **pathology** is a segmental granulomatous vasculitis with multinucleated giant cells and fragmentation of the internal elastic lamina that may lead to intimal fibrosis with luminal narrowing. The diagnosis can be established with temporal arterial biopsy.
 - d. Either the classic presentation or a rapid onset variant may be treated empirically with corticosteroids, which can cause a dramatic response to steroids. Untreated cases may lead to blindness due to occlusion of the ophthalmic artery.
5. **Takayasu arteritis** (pulseless disease) is a granulomatous vasculitis of medium- to large-sized arteries (particularly the aortic arch and its major branches), it is most common in Asia and affects young and middle-aged women (ages 15–45). The disease causes a granulomatous vasculitis with extensive intimal fibrosis of the affected medium-sized arteries, irregular fibrous thickening of the wall of the aortic arch, and narrowing of the orifices of the major arterial branches. Clinically, patients may have loss of pulse in the upper extremities, ocular manifestations (visual loss, field defects, or retinal hemorrhages), and neurologic abnormalities. Treatment is with steroids; the prognosis is variable.
6. **Buerger disease** (thromboangiitis obliterans) is a form of vasculitis that occurs in young males (usually under age 40); it is associated with heavy cigarette smoking and is common in Israel, India, Japan, and South America. The disease affects small and medium-sized arteries and veins, particularly in the extremities. The **pathology** is a recurrent neutrophilic vasculitis with microabscesses; segmental thrombosis of inflamed vessels leads to vascular insufficiency. Clinical features include severe pain (claudication) in the affected extremity, thrombophlebitis, secondary Raynaud phenomenon, and ulceration and gangrene. The most effective treatment is smoking cessation.
7. **Kawasaki disease** (mucocutaneous lymph node syndrome) is a form of segmental necrotizing vasculitis that commonly affects infants and young children (age <4), particularly in Japan, Hawaii, and U.S. mainland. The disease causes an acute febrile illness, conjunctivitis, erythema and erosions of the oral mucosa, generalized maculopapular skin rash, and lymphadenopathy. The vasculitis affects large, medium- and small-sized arteries, with the coronary arteries being most commonly affected (70%). The segmental necrotizing vasculitis may damage an affected vessel enough that the weakened vascular wall may undergo aneurysm formation. Kawasaki disease has a self-limited course, but does have a mortality rate of 1–2% due to rupture of a coronary aneurysm or coronary thrombosis.

RAYNAUD DISEASE VERSUS PHENOMENON

1. **Primary Raynaud phenomenon** (Raynaud disease) usually occurs in young women who experience episodic small artery vasospasm in the extremities, nose, or ears; it results in blanching and cyanosis of the fingers or toes. Raynaud phenomenon may be precipitated by cold temperature and emotions; there is no underlying disease or pathology.
2. **Secondary Raynaud phenomenon** is due to arterial insufficiency secondary to an underlying disease such as scleroderma (CREST), SLE, Buerger disease, atherosclerosis, etc.

ARTERIOSCLEROSIS

1. **Mönckeberg medial calcific sclerosis** is a medial calcification of medium-sized (muscular) arteries, such as femoral, tibial, radial, and ulnar arteries. It is asymptomatic, but may be detected by x-ray.
2. **Arteriolosclerosis** refers to sclerosis of arterioles; it affects small arteries and arterioles. Microscopically, either hyaline arteriolosclerosis (pink, glassy arterial wall thickening with luminal narrowing seen in benign hypertension, diabetes, and aging) or hyperplastic arteriolosclerosis (smooth-muscle proliferation resulting in concentric [“onion skin”] wall thickening and luminal narrowing seen in malignant hypertension) may occur.
3. **Atherosclerosis** is a very common vascular disorder characterized by lipid deposition and intimal thickening of large and medium-sized (elastic and muscular) arteries, resulting in fatty streaks and atheromatous plaques over a period of decades (a type of chronic inflammatory condition). Particularly likely to be affected are the aorta and a number of important muscular arteries (coronary, carotid, cerebral, renal, iliac, and popliteal arteries).

In a Nutshell

Arteriosclerosis is a group of diseases that results in arterial wall thickening (“hardening of the arteries”)

- Mönckeberg
- Arteriolosclerosis
- Atherosclerosis

Table 13-1. Major and Minor Risk Factors for Atherosclerosis

Major Risk Factors	Minor Risk Factors
Hyperlipidemia	Male gender
Hypertension	Sedentary lifestyle
Smoking	Stress (type A personality)
Diabetes	Elevated homocysteine
Obesity	Oral contraceptive use
	Increasing age
	Familial/genetic factors

- a. The earliest (clinically reversible) stage in atherosclerosis is the **fatty streak**, which is seen grossly as a flat, yellow intimal streak and is characterized microscopically by lipid-laden macrophages (foam cells).
- b. The (uncomplicated) **atheromatous plaque** (possibly partially reversible if small enough) grossly appears as a raised, yellow-white plaque; microscopically, it is characterized by a fibrous cap (composed of collagen, smooth muscle, lymphocytes, and foam cells) which overlies a necrotic core called an atheroma (composed of cholesterol clefts, lipid, foam cells, and necrotic debris).

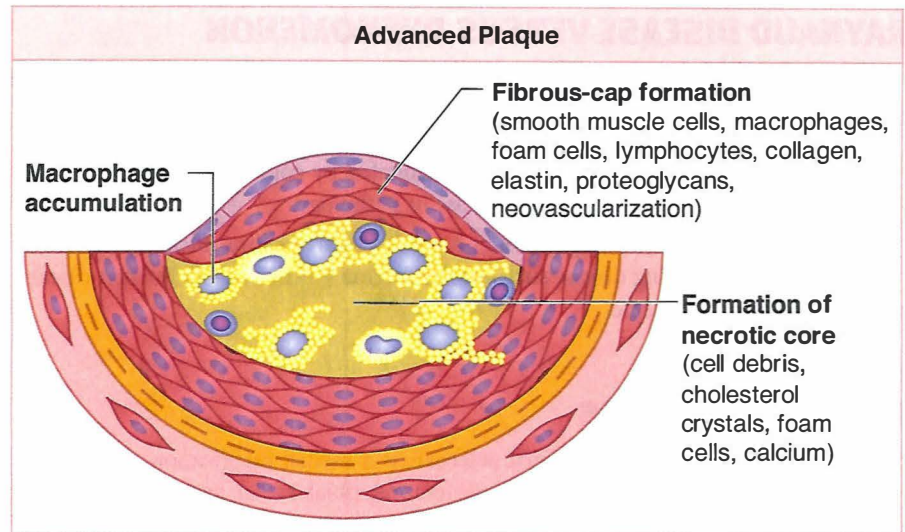


Figure 13-1. Atheromatous Plaque

- c. **Complicated atheromatous plaques** (clinically irreversible) can show dystrophic calcification (brittle eggshell quality), ulceration potentially with production of atheroemboli, and plaque rupture with superimposed thrombus.
- d. **Clinical complications** of atherosclerosis are protean; these complications include ischemic heart disease (myocardial infarctions); cerebrovascular accidents (CVA); atheroemboli (transient ischemic attacks [TIAs] and renal infarcts); aneurysm formation; peripheral vascular disease; and mesenteric artery occlusion.

HYPERTENSION (HTN)

1. **Hypertension** is an elevated blood pressure leading to end-organ damage, or a sustained diastolic pressure >90 mm Hg and/or a systolic pressure >140 mm Hg.

Table 13-2. Classification of Hypertension

JNC7 defines blood pressure for adults as:	Systolic Blood Pressure (mm Hg)	Diastolic Blood Pressure (mm Hg)
Normal	<120	and <80
Prehypertension	120–139	or 80–89
Stage I Hypertension	140–159	or 90–99
Stage II Hypertension	≥160	or ≥100

Source: The Seventh Report of the Joint National Committee on Prevention, Detection, Evaluation, and Treatment of High Blood Pressure (JNC7)

2. **Hypertension is very common**, affecting 25% of the U.S. population. African Americans tend to be more seriously affected than Caucasians, and the risk increases with age. Approximately 95% of cases of hypertension are idiopathic (essential); the remainder are due to secondary hypertension related to renal disease, pheochromocytoma, or other disease processes.

3. **Benign hypertension** accounts for 95% of the hypertension cases and is an asymptomatic silent disease that spares no organ. Mild to moderate elevations in blood pressure cause end-organ damage by damaging arterioles with hyaline arteriosclerosis. Late manifestations of benign hypertension include concentric left ventricular hypertrophy; congestive heart failure; accelerated atherosclerosis (major risk factor); myocardial infarction; aneurysm formation, rupture, and dissection; intracerebral hemorrhage (major risk factor); and chronic renal failure.
4. **Malignant (accelerated) hypertension** accounts for 5% of the cases and is characterized by markedly elevated pressures (e.g., systolic pressure >180 mm Hg and/or diastolic >120 mm Hg), which can rapidly cause end-organ damage. Fundoscopic examination may demonstrate retinal hemorrhages, exudates, and papilledema. The kidney characteristically develops petechial hemorrhages (“flea-bitten” appearance). Microscopic examination of tissue such as a renal biopsy may show hyperplastic arteriosclerosis (“onion skin”) and necrotizing arteriolitis (fibrinoid necrosis of vessel walls). Malignant hypertension is a medical emergency: if untreated, most patients will die within 2 years from renal failure, intracerebral hemorrhage, or chronic heart failure.

ANEURYSMS AND ARTERIOVENOUS FISTULAS

1. **Aneurysms** are congenital or acquired weakness of the vessel wall media, resulting in a localized dilatation or outpouching. Complications include thrombus formation, thromboembolism, and compression of nearby structures. Rupture or dissection may cause sudden death.

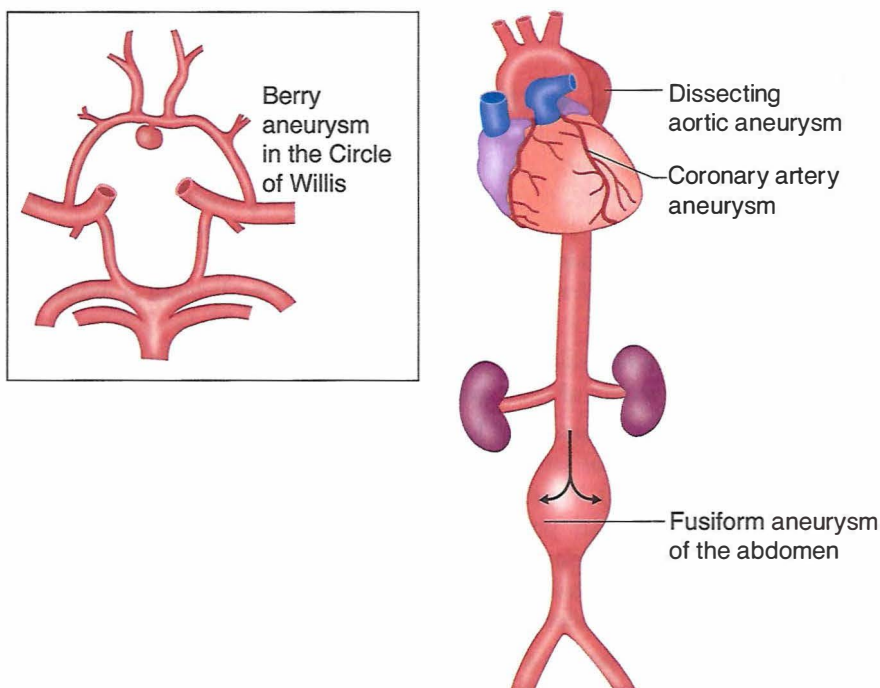


Figure 13-2. Location of Aneurysms

2. **Atherosclerotic aneurysms** are due to weakening of the media secondary to atheroma formation, and typically occur in the abdominal aorta below the renal arteries. Atherosclerotic aneurysms are associated with hypertension. Half of aortic aneurysms greater than 6 cm in diameter will rupture within 10 years.
3. **Syphilitic aneurysms** involve the ascending aorta in tertiary syphilis (late stage). Syphilitic (luetic) aortitis causes an obliterative endarteritis of the vasa vasorum, leading to ischemia and smooth-muscle atrophy of the aortic media. Syphilitic aneurysms may dilate the aortic valve ring, causing aortic insufficiency.
4. **Aortic dissecting aneurysm** occurs when blood from the vessel lumen enters an intimal tear and dissects through the layers of the media. The etiology usually involves degeneration (cystic medial degeneration) of the tunica media. Aortic dissecting aneurysm presents with severe tearing pain. The dissecting aneurysm may compress and obstruct the aortic branches (e.g., renal or coronary arteries). Hypertension and Marfan syndrome are predisposing factors.
5. **Berry aneurysm** is a congenital aneurysm of the circle of Willis.
6. **Microaneurysms** are small aneurysms commonly seen in hypertension and diabetes.
7. **Mycotic aneurysms** are aneurysms usually due to bacterial or fungal infections.
8. **Arteriovenous (AV) fistulas** are a direct communication between a vein and an artery without an intervening capillary bed. They may be congenital or acquired (e.g., trauma). Potential complications include shunting of blood which may lead to high output heart failure and risk of rupture and hemorrhage.

In a Nutshell

Venous Thrombosis

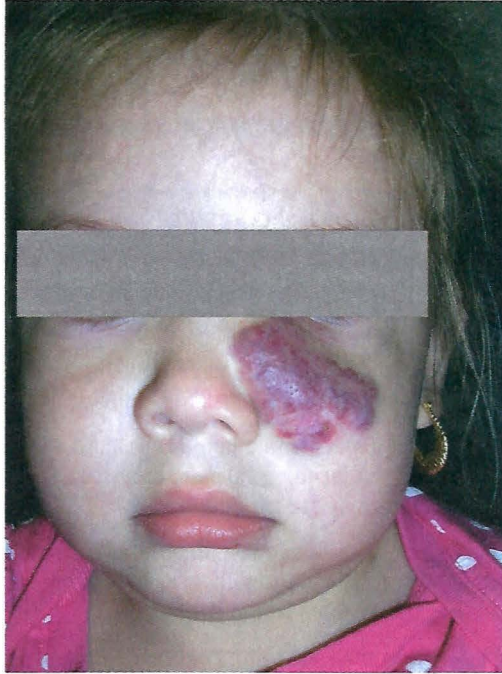- Phlethrombosis: venous thrombosis without inflammation or infection
- Thrombophlebitis: venous thrombosis due to inflammation and bacterial infection

VENOUS DISEASE

1. **Deep vein thrombosis (DVT)** usually affects deep leg veins (90%), with iliac, femoral, and popliteal veins being particularly commonly affected. It is often asymptomatic and is consequently a commonly missed diagnosis. When symptomatic, it can produce unilateral leg swelling with warmth, erythema, and positive Homan sign (increased resistance to passive dorsiflexion of the ankle by the examiner). The **diagnosis** can be established with doppler “duplex” ultrasound. The major complication is pulmonary embolus.
2. **Varicose veins** are dilated, tortuous veins caused by increased intraluminal pressure. A variety of veins can be affected.
 - a. **Superficial veins of the lower extremities** are particularly vulnerable due to a lack of structural support from superficial fat and/or incompetent valve(s). Varicosities of these superficial veins are very common (15% of the U.S. population); occur more frequently in females than males; and are common in pregnancy. This type of varicose vein is aggravated by prolonged standing or sitting; causes edema, thrombosis, stasis dermatitis, and ulceration; and is only rarely a source of emboli.
 - b. **Esophageal varices** are due to portal hypertension (usually caused by cirrhosis) and may be a source of life-threatening hemorrhage.
 - c. Varices of the anal region are commonly called **hemorrhoids**; are associated with constipation and pregnancy; and may be complicated by either bleeding (streaks of red blood on hard stools) or thrombosis (painful).

VASCULAR NEOPLASMS

1. **Hemangiomas** are extremely common, benign vascular tumors. They are the most common tumor in infants. Hemangiomas occur on the skin, mucous membranes, or internal organs. The major types are capillary and cavernous hemangiomas. Hemangiomas may spontaneously regress.



© Richard P. Usatine, M.D. Used with permission.

Figure 13-3. Hemangioma

2. **Hemangioblastomas** are associated with von Hippel-Lindau disease, which may cause multiple hemangioblastomas involving the cerebellum, brain stem, spinal cord, and retina, as well as renal cell carcinoma.
3. **Glomus tumors** (glomangioma) are benign, small, painful tumors of the glomus body that usually occur under fingernails.
4. **Kaposi sarcoma** is a malignant tumor of endothelial cells associated with Kaposi-sarcoma–associated virus (HHV8). The condition causes multiple red-purple patches, plaques, or nodules that may remain confined to the skin or may disseminate. Microscopically, there is a proliferation of spindle-shaped endothelial cells with slit-like vascular spaces and extravasated erythrocytes.
 - a. The **classic European form** occurs in older men of Eastern European or Mediterranean origin, who develop red-purple skin plaques on the lower extremities.
 - b. The **transplant-associated form** occurs in patients on immunosuppression for organ transplants; involves skin and viscera; and may regress with reduction of immunosuppression.
 - c. The **African form** occurs in African children and young men in whom generalized lymphatic spread is common.

Clinical Correlate

Port wine stains are large, flat, vascular malformations that are closely related to hemangiomas and are often seen on the head in the trigeminal nerve distribution.

- d. The **AIDS-associated form** is most common in homosexual male AIDS patients; it is an aggressive form with frequent widespread visceral dissemination. Common sites of involvement include skin, GI tract, lymph nodes, and lungs. This form of Kaposi sarcoma is responsive to chemotherapy and interferon-alpha, and only rarely causes death.
5. **Angiosarcoma** (hemangiosarcoma) is a malignant vascular tumor with a high mortality that most commonly occurs in skin, breast, liver, and soft tissues. Liver angiosarcomas are associated with vinyl chloride, arsenic, and thorotrast.

Chapter Summary

- Polyarteritis nodosa is a segmental necrotizing vasculitis that can affect any organ, except the lung. The symptoms vary with the organ involved.
- Churg-Strauss syndrome is a variant of polyarteritis nodosa with associated bronchial asthma, granuloma formation, and eosinophilia.
- Wegener granulomatosis is a necrotizing vasculitis with granulomas that classically involves the nose, sinuses, lungs, and kidneys.
- Temporal arteritis is a segmental granulomatous vasculitis with a predilection for involving cranial arteries. Headache, facial pain, and visual disturbances occur. Untreated temporal arteritis may cause blindness.
- Takayasu arteritis is a granulomatous vasculitis with massive intimal fibrosis that tends to involve the aortic arch and its major branches. It may produce blindness or loss of pulse in the upper extremities.
- Buerger disease is a neutrophilic vasculitis that tends to involve the extremities (potentially causing gangrene) of young men who smoke heavily.
- Kawasaki disease is a febrile lymphadenopathy with rash with an associated segmental necrotizing vasculitis with a predilection for the coronary arteries.
- Raynaud disease is an idiopathic small artery vasospasm that causes blanching and cyanosis of the fingers and toes; the term secondary Raynaud phenomenon is used when similar changes are observed secondary to a systemic disease such as scleroderma or systemic lupus erythematosus.
- Mönckeberg medial calcific sclerosis is an asymptomatic medial calcification of medium-sized arteries.
- Arteriolosclerosis refers to small artery and arteriolar changes leading to luminal narrowing, most often seen in patients with diabetes, hypertension, and aging.
- Atherosclerosis is lipid deposition and intimal thickening of large and medium-sized arteries, resulting in fatty streaks and atheromatous plaques. Clinical complications of atherosclerosis include ischemic heart disease, cerebrovascular accidents, atheroemboli, aneurysm formation, peripheral vascular disease, and mesenteric artery occlusion.
- Hypertension is defined as an elevated blood pressure leading to end-organ damage, or sustained diastolic pressure >90 mm Hg and/or systolic pressure >140 mm Hg. Benign hypertension is a common, initially silent, disease that may eventually produce cardiac disease, accelerated atherosclerosis, aneurysm formation, and renal and CNS damage. Malignant hypertension is much less common than benign hypertension and is defined as markedly elevated pressures (e.g., systolic pressure greater than 180 mm Hg, or diastolic >120 mm Hg) causing rapid end-organ damage. Untreated patients often die within 2 years from renal failure, intracerebral hemorrhage, or chronic heart failure.

(Continued)

Chapter Summary (*cont'd*)

- An aneurysm is defined as a congenital or acquired weakness of the vessel wall media, resulting in a localized dilation or outpouching. Complications of aneurysms include thrombus formation, compression of adjacent structures, and rupture with risk of sudden death.
- Atherosclerotic aneurysms are associated with hypertension and tend to involve the abdominal aorta.
- Syphilitic aneurysms tend to involve the ascending aorta and develop secondary to an obliterative endarteritis of the vasa vasorum, which is the blood supply of the aortic media.
- Aortic dissecting aneurysms occur when blood from the vessel lumen enters an intimal tear and dissects through the layers of the media, which have often previously been damaged by cystic medial degeneration.
- Berry aneurysms are congenital aneurysms of the vessels near the circle of Willis. Rupture of these aneurysms may cause subarachnoid hemorrhage.
- Deep vein thrombosis usually involves the deep leg veins and may be asymptomatic. The major complication is pulmonary embolus.
- Varicose veins are dilated, tortuous veins caused by increased intraluminal pressure. Common sites include the superficial veins of the lower extremities, esophageal varices, and hemorrhoids.
- Hemangiomas are extremely common, benign vascular tumors that may involve the skin, mucous membranes, or internal organs.
- Hemangioblastomas are vascular tumors associated with von Hippel-Lindau disease that tend to involve the central nervous system and retina.
- Glomus tumors are small, painful vascular tumors most often found under the fingernails.
- Kaposi sarcoma is a low-grade malignant tumor of endothelial cells that appears to have a viral etiology (HHV8) and in the United States is found most often in AIDS patients.
- Angiosarcoma is a malignant vascular tumor with a high mortality that occurs most commonly in skin, breast, liver, and soft tissues.

ISCHEMIC HEART DISEASE

1. **Cardiac ischemia** is usually secondary to coronary artery disease (CAD); it is the most common cause of death in the United States; and is most common in middle-age men and postmenopausal women.
2. **Angina pectoris** is due to transient cardiac ischemia without cell death resulting in substernal chest pain.
 - a. **Stable angina** is the most common type of angina, and is caused by coronary artery atherosclerosis with luminal narrowing greater than 75%. Chest pain is brought on by increased cardiac demand (exertional or emotional), and is relieved by rest or nitroglycerin (vasodilation). Electrocardiogram shows ST segment depression (sub-endocardial ischemia).
 - b. **Prinzmetal variant angina** is caused by coronary artery vasospasm and produces episodic chest pain often at rest; it is relieved by nitroglycerin (vasodilatation). Electrocardiogram shows transient ST segment elevation (transmural ischemia).
 - c. **Unstable or crescendo angina** is caused by formation of a nonocclusive thrombus in an area of coronary atherosclerosis, and is characterized by increasing frequency, intensity, and duration of episodes; episodes typically occur at rest. This form of angina has a high risk for myocardial infarction.
3. **Myocardial infarction (MI)** occurs when a localized area of cardiac muscle undergoes coagulative necrosis due to ischemia. It is the most common cause of death in the United States. The mechanism leading to infarction may be either coronary artery atherosclerosis with plaque rupture and superimposed thrombus formation *or* coronary artery spasm.

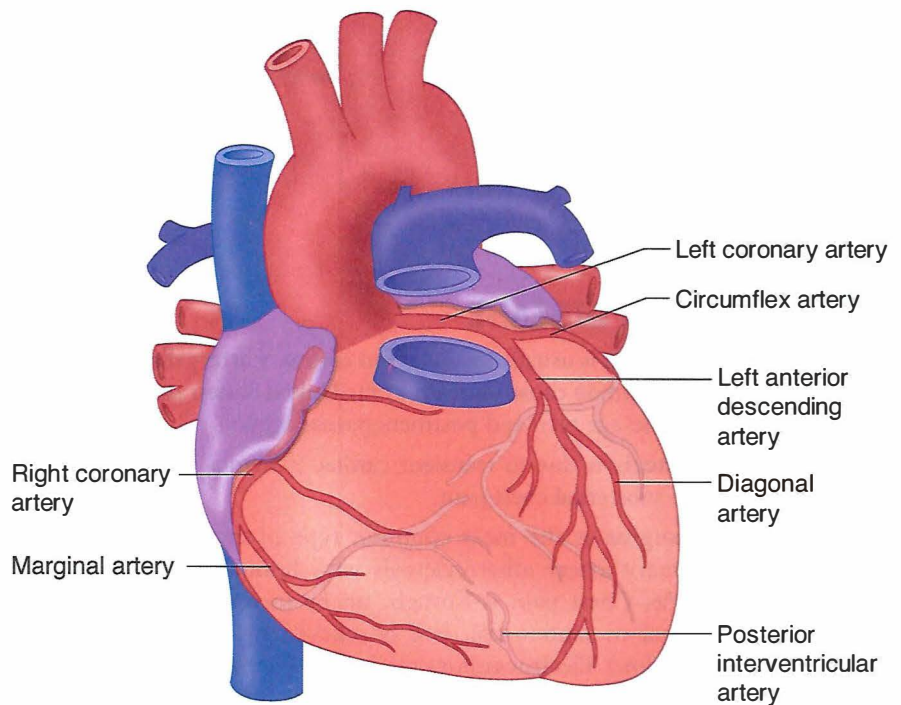


Figure 14-1. Arterial Supply to the Heart

- a. **Distribution of coronary artery thrombosis.** The left anterior descending artery (LAD) is involved in 45% of cases; the right coronary artery (RCA) is involved in 35% of cases; and the left circumflex coronary artery (LCA) is involved in 15% of cases.
- b. Infarctions are **classified** as transmural or subendocardial. **Transmural** is the most common type, and is considered to have occurred when ischemic necrosis involves more than 50% of myocardial wall. It is associated with regional vascular occlusion by thrombus. **Subendocardial** is considered to have occurred when ischemic necrosis involves less than 50% of myocardial wall. It is associated with hypoperfusion due to shock.
- c. The **clinical presentation** of myocardial infarction is classically with sudden onset of severe “crushing” substernal chest pain that often radiates to the left arm, jaw, and neck. The pain may be accompanied by chest heaviness, tightness, and shortness of breath; diaphoresis, nausea, and vomiting; jugular venous distension (JVD); anxiety and often “feeling of impending doom.” Electrocardiogram initially shows ST segment elevation. Q waves representing myocardial coagulative necrosis develop in 24 to 48 hours.

Clinical Correlate

Atypical presentations of MI with little or no chest pain are seen most frequently in elderly patients, diabetics, women, and postsurgical patients.

Table 14-1. Serum Markers Used to Diagnose Myocardial Infarctions

	Elevated by	Peak	Returns to Normal by
CK-MB	4–8 h	18 h	2–3 days
Cardiac-specific troponin I & T	3–6 h	16 h	7–10 days
LDH	24 h	3–6 days	8–14 days

- d. **Gross and microscopic sequence of changes.** The microscopic and gross changes represent a spectrum that is preceded by biochemical changes going from aerobic metabolism to anaerobic metabolism within minutes. The time intervals are variable and depend on the size of the infarct, as well as other factors.

Table 14-2. Gross Sequence of Changes

Time Post-Infarction	Gross Appearance
0–18 h	No visible gross change
18–24 h	Vague pallor and softening
1–7 days	Yellow pallor
7–28 days	Central pallor with a red border
Months	White, firm scar

Table 14-3. Microscopic Sequence of Changes

Time Post-Infarction	Gross Appearance
1–4 h	Wavy myocyte fibers and contraction bands
4–24 h	Coagulative necrosis
1–3 days	Neutrophilic infiltrate
3–7 days	Macrophages
7–28 days	Granulation tissue
6 weeks +	Fibrotic scar

- e. **Complications** of MI include cardiac arrhythmias that may lead to sudden cardiac death; congestive heart failure; cardiogenic shock (>40–50% myocardium is necrotic); mural thrombus and thromboembolism; fibrinous pericarditis; ventricular aneurysm; and cardiac rupture. Cardiac rupture most commonly occurs 4–7 days after MI, and has effects that vary with the site of rupture: ventricular free wall rupture causes cardiac tamponade; interventricular septum rupture causes left to right shunt; and papillary muscle rupture causes mitral insufficiency.
4. **Sudden cardiac death** is defined to be death within 1 hour of the onset of symptoms. The mechanism is typically a fatal cardiac arrhythmia (usually ventricular fibrillation).
Coronary artery disease is the most common underlying cause (80%); other causes of sudden cardiac death include hypertrophic cardiomyopathy, mitral valve prolapse, aortic valve stenosis, congenital heart abnormalities, and myocarditis.
5. **Chronic ischemic heart disease** is the insidious onset of progressive congestive heart failure with no history of angina pectoris or myocardial infarction. It is characterized by diffuse myocardial fibrosis due to chronic ischemic injury from severe atherosclerotic coronary artery disease.

Clinical Correlate

Auscultation of a friction rub is characteristic of pericarditis. Pericarditis is most common 2–3 days after infarction but may also occur several weeks later (Dressler syndrome—a rare autoimmune reaction (type II) where the necrotic heart muscle induces the immune system to generate autoantibodies to cardiac self-antigens).

Clinical Correlate

Clinically, the degree of orthopnea is often quantified in terms of the number of pillows the patient needs in order to sleep comfortably (e.g., “three-pillow orthopnea”).

Note

Cor pulmonale = Right-sided heart failure caused by pulmonary hypertension from intrinsic lung disease:

Lung disease → pulmonary HTN → ↑ right ventricular pressure → right ventricular hypertrophy (RVH) → right-sided heart failure.

CONGESTIVE HEART FAILURE

1. **Congestive heart failure** (CHF) refers to the presence of insufficient cardiac output to meet the metabolic demand of the body’s tissues and organs. It is the final common pathway for many cardiac diseases and has an increasing incidence in the United States. Complications include both **forward failure** (decreased organ perfusion) and **backward failure** (passive congestion of organs). Right- and left-sided heart failure often occur together.
2. **Left heart failure** can be caused by ischemic heart disease, hypertension, myocardial diseases, and aortic or mitral valve disease. The heart has increased heart weight and shows left ventricular hypertrophy and dilatation. The lungs are heavy and edematous. Left heart failure presents with dyspnea, orthopnea, paroxysmal nocturnal dyspnea, rales, and S3 gallop. Microscopically, the heart shows cardiac myocyte hypertrophy with “enlarged pleiotropic nuclei,” while the lung shows pulmonary capillary congestion and alveolar edema with intra-alveolar hemosiderin-laden macrophages (“heart failure cells”). Complications include passive pulmonary congestion and edema, activation of the renin-angiotensin-aldosterone system leading to secondary hyperaldosteronism, and cardiogenic shock.
3. **Right heart failure** is most commonly caused by left-sided heart failure, with other causes including pulmonary or tricuspid valve disease and *cor pulmonale*. Right heart failure presents with jugular venous distention (JVD), hepatosplenomegaly, dependent edema, ascites, weight gain, and pleural and pericardial effusions. Grossly, right ventricular hypertrophy and dilatation develop. Chronic passive congestion of the liver may develop and may progress to cardiac sclerosis/cirrhosis (only with long-standing congestion).

VALVULAR HEART DISEASE

1. **Degenerative calcific aortic valve stenosis** is a common valvular abnormality that is characterized by age-related dystrophic calcification, degeneration, and stenosis of the aortic valve. It is common in congenital bicuspid aortic valves. Degenerative calcific aortic valve stenosis leads to concentric left ventricular hypertrophy (LVH) and congestive heart failure with increased risk of sudden death. Treatment is with aortic valve replacement.
2. **Mitral valve prolapse** has enlarged, floppy mitral valve leaflets that prolapse into the left atrium and microscopically show myxomatous degeneration. The condition affects Marfan syndrome. Patients are asymptomatic and a mid-systolic click can be heard on auscultation. Complications include infectious endocarditis and septic emboli, rupture of chordae tendineae with resulting mitral insufficiency, and rarely sudden death.
3. **Rheumatic valvular heart disease/acute rheumatic fever**
 - a. **Rheumatic fever** is a systemic recurrent inflammatory disease, triggered by a pharyngeal infection with Group A β -hemolytic streptococci. In genetically susceptible individuals, the infection results in production of antibodies that cross-react with cardiac antigens (type II hypersensitivity reaction). Rheumatic fever affects children (ages 5–15 years), and there is a decreasing incidence in the United States. Symptoms occur 2–3 weeks after a pharyngeal infection; laboratory studies show elevated antistreptolysin O (ASO) titers. The Jones criteria are illustrated in Table 14-4.

Table 14-4. Jones Criteria of Rheumatic Fever

Major Criteria	Minor Criteria
Migratory polyarthritis	Fever
Pancarditis	Arthralgias
Subcutaneous nodules	Elevated acute-phase reactants
Skin rash (erythema marginatum)	
Movement disorders (Sydenham chorea)	
Diagnosis of rheumatic fever requires: two major or one major and two minor	

- b. **Acute rheumatic heart disease** affects myocardium, endocardium, and pericardium. The myocardium can develop myocarditis, whose most distinctive feature is the Aschoff body, in which fibrinoid necrosis is surrounded by macrophages (Anitschkow cells), lymphocytes, and plasma cells. Fibrinous pericarditis may be present. Endocarditis may be a prominent feature that typically involves mitral and aortic valves (forming fibrin vegetations along the lines of closure) and may also cause left atrial endocardial thickening (MacCallum plaques).
- c. **Chronic rheumatic heart disease** is characterized by mitral and aortic valvular fibrosis, characterized by valve thickening and calcification; fusion of the valve commissures; and damaged chordae tendineae (short, thickened, and fused). Complications can include mitral stenosis and/or regurgitation, aortic stenosis and/or regurgitation, congestive heart failure, and infective endocarditis.
4. **Infectious bacterial endocarditis** refers to bacterial infection of the cardiac valves, characterized by vegetations on the valve leaflets. Risk factors include rheumatic heart disease, mitral valve prolapse, bicuspid aortic valve, degenerative calcific aortic stenosis, congenital heart disease, artificial valves, indwelling catheters, dental procedures, immunosuppression, and intravenous drug use.
- a. **Acute endocarditis** is typically due to a *high virulence organism* that can colonize a normal valve, such as *Staphylococcus aureus*. Acute endocarditis produces large destructive vegetations (fibrin, platelets, bacteria, and neutrophils). The prognosis is poor, with mortality of 50%.
- b. **Subacute endocarditis** is typically due to a low virulence organism, such as *Streptococcus group viridians*, which usually colonizes a previously damaged valve.
- c. **Clinically**, endocarditis presents with fever, chills, weight loss, and cardiac murmur. Embolic phenomena may occur, and may affect systemic organs; retina (Roth spots); and distal extremities (Osler nodes [painful, red subcutaneous nodules on the fingers and toes], Janeway lesions [painless, red lesions on the palms and soles], and splinter fingernail hemorrhages). Diagnosis is by serial blood cultures. Complications include septic emboli, valve damage resulting in insufficiency and congestive heart failure, myocardial abscess, and dehiscence of an artificial heart valve.
5. **Marantic endocarditis** (nonbacterial thrombotic endocarditis [NBTE]) is characterized by small, sterile vegetations along the valve leaflet line of closure in patients with a debilitating disease. The major complications are embolism and secondary infection of the vegetations.

Clinical Correlate

Endocarditis involving the right side of the heart is highly suggestive of IV drug use.

Bridge to Microbiology

Viridans streptococci

- Alpha-hemolytic
- Bile-resistant
- Optochin-resistant

Clinical Correlate

S. bovis bacteremia—with or without endocarditis—is strongly associated with an underlying malignancy or premalignant lesions of the colon.

Colonoscopy should be performed in all patients with *S. Bovis* bacteremia or endocarditis.

CONGENITAL HEART DISEASE

1. **Congenital heart disease** is the most common cause of childhood heart disease in the United States. 90% of cases are idiopathic, with the remainder being associated with genetic disease (trisomies, Cri du chat, Turner syndrome, etc.), viral infection (especially congenital rubella), or drugs and alcohol.
2. **Coarctation of the aorta** is a segmental narrowing of the aorta.

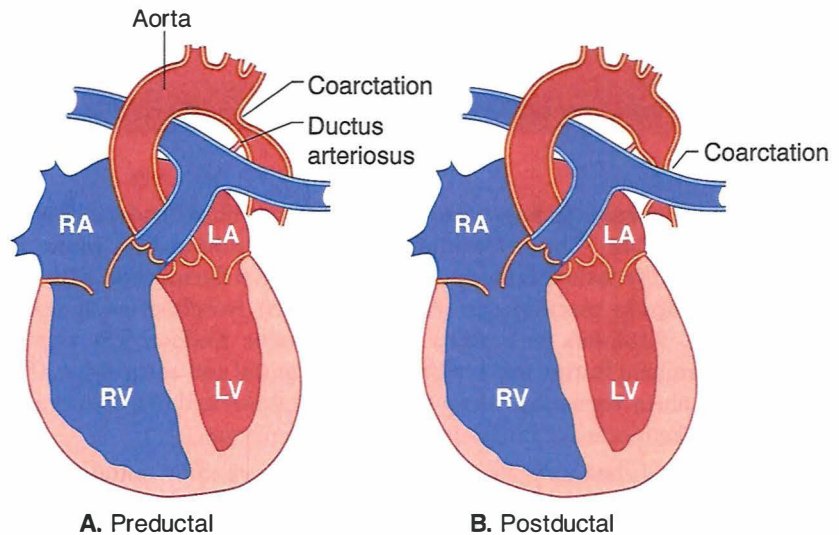


Figure 14-2. Coarctation of the Aorta

- a. **Preductal coarctation** (infantile-type) is associated with Turner syndrome and causes severe narrowing of aorta proximal to the ductus arteriosus. It is usually associated with a patent ductus arteriosus (PDA), which supplies blood to aorta distal to the narrowing, and right ventricular hypertrophy (secondary to the need for the right ventricle to supply the aorta through the patent ductus arteriosus). Preductal coarctation presents in infancy with congestive heart failure that is accompanied by weak pulses and cyanosis in the lower extremities; the prognosis is poor without surgical correction.
- b. **Postductal coarctation** (adult-type) causes narrowing of the aorta distal to the ductus arteriosus. It can present in a child or an adult with hypertension in the upper extremities, and hypotension and weak pulses in the lower extremities. Some collateral circulation may be supplied via the internal mammary and intercostal arteries; the effects of this collateral circulation may be visible on chest x-ray with notching of the ribs due to bone remodeling as a consequence of increased blood flow through the intercostal arteries. Complications of postductal coarctation can include congestive heart failure (the heart is trying too hard), intracerebral hemorrhage (the blood pressure in the carotid arteries is too high), and dissecting aortic aneurysm (the blood pressure in the aortic route is too high).

Table 14-5. Left Versus Right Shunt Congenital Disease

Right → Left Shunt	Left → Right Shunt
Early cyanosis (blue babies)	Late cyanosis (blue kids)
Blood shunted past the lungs	Secondary pulmonary HTN → reversal of shunt (Eisenmenger syndrome)
<ul style="list-style-type: none"> • Tetralogy of Fallot • Transposition of the great vessels • Truncus arteriosus • Tricuspid atresia 	<ul style="list-style-type: none"> • Ventricular septal defect (VSD) • Atrial septal defect (ASD) • Patent ductus arteriosus (PDA)

3. **Tetralogy of Fallot** is the most common cause of cyanotic heart disease. The classic tetrad includes **pulmonary outflow obstruction/stenosis; right ventricular hypertrophy; ventricular septal defect; and overriding aorta**. Clinical findings include cyanosis, shortness of breath (SOB), digital clubbing, and polycythemia. Progressive pulmonary outflow stenosis and cyanosis develop over time; treatment is by surgical correction.

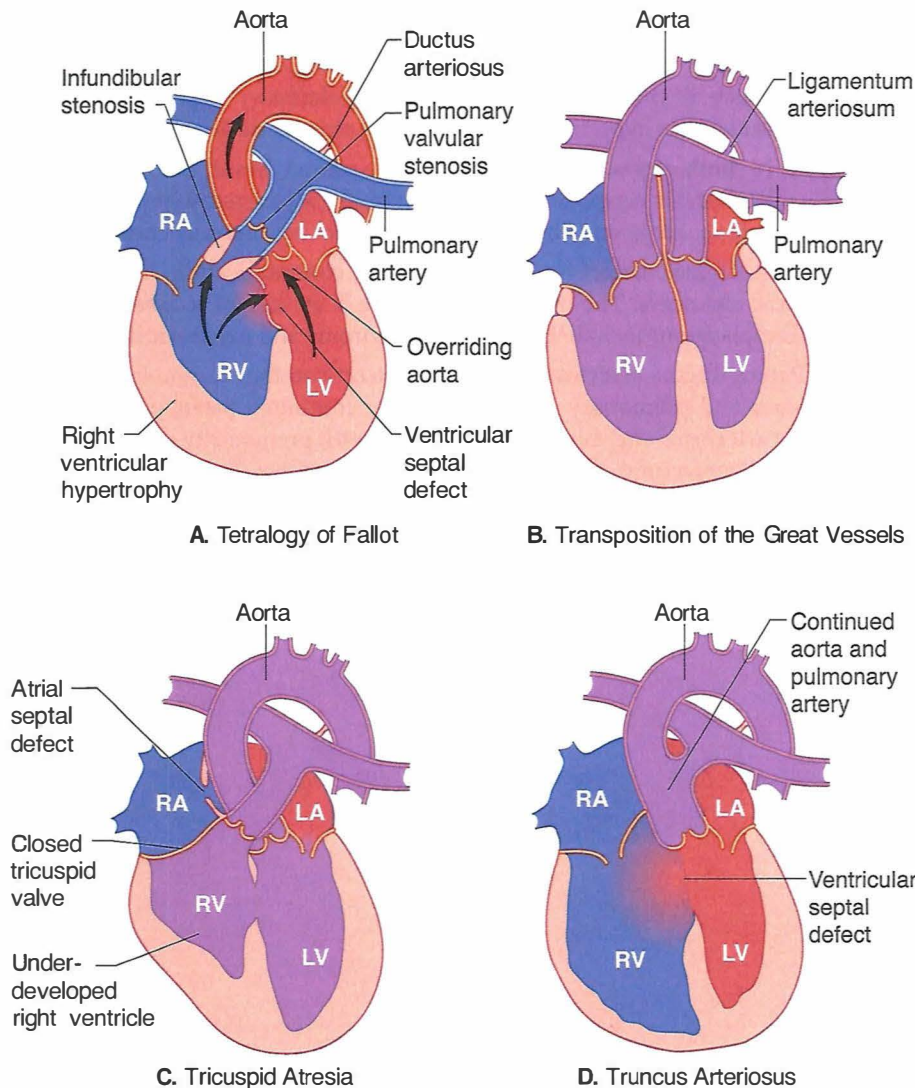


Figure 14-3. Common Forms of Cyanotic Congenital Heart Disease

Bridge to Embryology

In utero the ductus arteriosus is kept open by low arterial oxygen saturation and elevated prostaglandin E₂ (PGE₂) levels. Functional closure occurs in the first 2 days of life due to increased oxygen saturation and decreased PGE₂. The ductus arteriosus becomes the ligamentum arteriosum.

4. **Transposition of the great arteries** is an abnormal development of the truncocoanal septum that results in inversion of the aorta and pulmonary arteries with respect to the ventricles. The risk is increased in infants of diabetic mothers. Affected babies develop early cyanosis and right ventricular hypertrophy. To survive, infants must have mixing of blood by a VSD, ASD, or PDA. The prognosis is poor without surgery.
5. **Truncus arteriosus** is a failure to develop a dividing septum between the aorta and pulmonary artery, resulting in a common trunk. Blood flows from the pulmonary trunk to the aorta. Truncus arteriosus causes early cyanosis and congestive heart failure, with a poor prognosis without surgery.
6. **Tricuspid atresia** refers to the absence of a communication between the right atrium and ventricle due to developmental failure to form the tricuspid valve. Associated defects include right ventricular hypoplasia and an ASD. The prognosis is poor without surgery.
7. **Ventricular septal defect (VSD)**, which consists of a direct communication between the ventricular chambers, is the second most common congenital heart defect (the most common is a bicuspid aortic valve).
 - a. A **small ventricular septal defect** may be asymptomatic and close spontaneously, or it may produce a jet stream that damages the endocardium and increases the risk of infective endocarditis.
 - b. A **large ventricular septal defect** may cause Eisenmenger complex, which is characterized by secondary pulmonary hypertension, right ventricular hypertrophy, reversal of the shunt, and late cyanosis.
 - c. In **both types**, a systolic murmur can be heard on auscultation. Ventricular septal defects are commonly associated with other heart defects. Large ventricular septal defects can be surgically corrected.
8. **Atrial septal defect (ASD)** is a direct communication between the atrial chambers. The most common type is an ostium secundum defect. Complications include Eisenmenger syndrome and paradoxical emboli.
9. **Patent ductus arteriosus (PDA)** is a direct communication between the aorta and pulmonary artery due to the continued patency of the ductus arteriosus after birth. It is associated with prematurity and congenital rubella infections. Clinical findings include machinery murmur, late cyanosis, and congestive heart failure. Eisenmenger syndrome may develop as a complication.

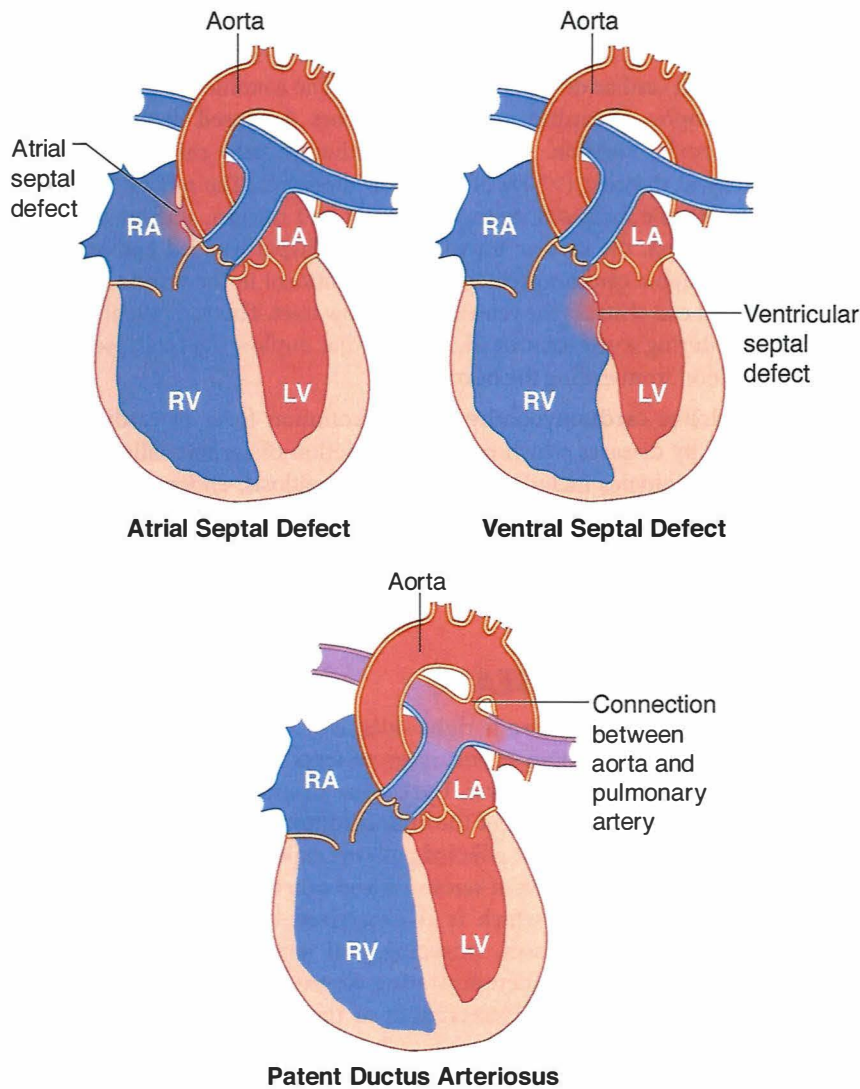


Figure 14-4. Common Forms of Acyanotic Congenital Heart Disease

PRIMARY CARDIOMYOPATHIES (DIAGNOSIS OF EXCLUSION)

1. **Dilated cardiomyopathy** is the most common form of cardiomyopathy. It is cardiac enlargement with dilatation of all four chambers, resulting in progressive congestive heart failure (the typical mode of presentation). In most cases the etiology is idiopathic, but some cases are related to alcohol, medications (Adriamycin [doxorubicin]), cocaine, viral myocarditis (Coxsackievirus B and enteroviruses), parasitic infections (Chagas disease), or pregnancy. In cases of all types, the underlying etiology leads to destruction of myocardial contractility, which affects systolic function. Echocardiogram typically shows decreased ejection fraction. Complications include mural thrombi and cardiac arrhythmias; prognosis is poor with 5-year survival of 25% and with the only truly effective therapy of established disease being heart transplantation.

Bridge to Pharmacology

To keep PDA open: prostaglandin E₂

To close PDA: indomethacin

2. **Hypertrophic cardiomyopathy** (also called asymmetrical septal hypertrophy, and idiopathic hypertrophic subaortic stenosis [IHSS]) is a common cause of sudden cardiac death in young athletes. The condition is an asymmetrical hypertrophy of cardiac muscle that causes decreased compliance affecting diastolic function. Hypertrophic cardiomyopathy can be an autosomal dominant disorder (>50% of cases) or idiopathic. The muscle hypertrophy is due to the increased synthesis of actin and myosin, and on microscopic examination, the cardiac muscle fibers are hypertrophied and in disarray. Hypertrophic cardiomyopathy is most prominent in the ventricular septum, where it can obstruct the ventricular outflow tract. This can potentially lead to death during severe exercise when the cardiac outflow tract collapses, preventing blood from exiting the heart.
3. **Restrictive cardiomyopathy** is an uncommon form of cardiomyopathy caused by diseases which produce restriction of cardiac filling during diastole; etiologies include amyloidosis, sarcoidosis, endomyocardial fibroelastosis, and Loeffler endomyocarditis. In all of these diseases, increased deposition of material leads to decreased compliance, affecting diastolic function.

CARCINOID HEART DISEASE

1. **Carcinoid heart disease** is right-sided endocardial and valvular fibrosis secondary to serotonin exposure in patients with carcinoid tumors that have metastasized to the liver. The cardiac disease is a plaque-like thickening (endocardial fibrosis) of the endocardium and valves of the right side of the heart. Many of the affected patients experience carcinoid syndrome (also related to secretion of serotonin and other metabolically active products of the tumors), which is characterized by skin flushing, diarrhea, cramping, bronchospasm, wheezing, and telangiectasias. The **diagnosis** can be established by demonstrating elevated urinary 5-hydroxyindoleacetic acid (5-HIAA), a metabolite of the breakdown of serotonin via monoamine oxidase.

In a Nutshell

Tuberous Sclerosis Complex

- Autosomal dominant
- Mutation in TSC1 (hamartin) and TSC2 (tuberin) genes, which are tumor suppressor proteins
- Multiple hamartomas
- Cortical tubers
- Renal angiomyolipomas
- Cardiac rhabdomyomas
- Pulmonary hamartomas

CARDIAC TUMORS

1. **Cardiac myxoma** is a benign tumor usually arising within the left atrium near the fossa ovalis; it is characterized microscopically by stellate-shaped cells within a myxoid background. Complications include tumor emboli and “ball-valve” obstruction of the valves.
2. **Cardiac rhabdomyoma** is a benign tumor usually arising within the myocardium that is associated with tuberous sclerosis.

Chapter Summary

- Ischemic heart disease, the most common cause of death in the United States, is usually secondary to coronary artery disease.
- Angina pectoris refers to transient cardiac ischemia (without cell death) resulting in substernal pain. Variants of angina include stable angina, Prinzmetal variant angina, and unstable angina.
- Myocardial infarction is a localized area of cardiac muscle coagulative necrosis due to ischemia. It often presents with sudden onset of severe “crushing” substernal chest pain that may radiate to the left arm, jaw, and neck. EKG changes and elevation of cardiac-specific troponin I/T in the serum to confirm the diagnosis.
- Congestive heart failure is insufficient cardiac output to meet the metabolic demands of the body’s tissues and organs. Left heart failure can complicate ischemic heart disease, hypertension, myocardial diseases, and aortic or mitral valve disease. It is associated with left ventricular hypertrophy and dilatation, passive pulmonary congestion and edema, activation of the renin-angiotensin-aldosterone system leading to hyperaldosteronism, and cardiogenic shock. Right heart failure can complicate left heart failure, pulmonary or tricuspid valvular disease, and cor pulmonale. It causes jugular venous distension, hepatosplenomegaly, dependent edema, and ascites.
- Degenerative calcific aortic valve stenosis, the most common valvular abnormality, is an age-related dystrophic calcification, degeneration, and stenosis of the aortic valve that can cause concentric left ventricular hypertrophy, congestive heart failure, and an increased risk of sudden death.
- Mitral valve prolapse is a myxomatous degeneration of the mitral valve that causes the valve leaflets to become enlarged and floppy.
- Rheumatic fever is a systemic inflammatory disease, triggered by a pharyngeal infection with Group A beta-hemolytic streptococci, that in genetically susceptible individuals results in the production of antibodies that cross-react with cardiac antigens. Acute rheumatic heart disease can produce myocarditis, pericarditis, and endocarditis. Chronic rheumatic heart disease can damage the mitral and aortic valves, secondarily predisposing for mitral stenosis, congestive heart disease, and infective endocarditis.
- Infective bacterial endocarditis is a bacterial infection of the cardiac valves, characterized by vegetations on the valve leaflets. Acute endocarditis is caused by high-virulence organisms, notably *Staphylococcus aureus*, and produces large destructive lesions with a high mortality rate. Subacute endocarditis is caused by low-virulence organisms, notably *Viridans streptococci*, and usually involves previously damaged valves.
- Marantic endocarditis refers to the formation of small, sterile fibrin vegetations along the valve leaflet line of closure in patients with debilitating diseases.
- Congenital heart disease is the most common cause of childhood heart disease in the United States and may be idiopathic or associated with genetic disease, infection, or drug and alcohol use.
- Coarctation of the aorta is a segmental narrowing of the aorta that is subclassified, depending upon the level at which the narrowing occurs, into preductal coarctation (poorer prognosis, association with Turner syndrome) and postductal coarctation (late onset).

(Continued)

Chapter Summary (cont'd)

- Tetralogy of Fallot is the most common cause of cyanotic heart disease and is characterized by a classic tetrad of pulmonary outflow obstruction/stenosis, right ventricular hypertrophy, ventricular septal defect, and overriding aorta.
- Transposition of the great arteries is an abnormal development of the truncocoal septum that results in inversion of the aorta and pulmonary arteries with respect to the ventricles. Transposition of the great arteries has a poor prognosis without surgery.
- Truncus arteriosus is a failure to develop a dividing septum between the aorta and the pulmonary artery, resulting in a common trunk. Truncus arteriosus has a poor prognosis without surgery.
- Tricuspid atresia is the absence of a communication between the right atrium and ventricle due to developmental failure to form the tricuspid valve. Tricuspid atresia has a poor prognosis without surgery.
- Ventricular septal defect is the second most common congenital heart defect and consists of a direct communication between the ventricular chambers. The prognosis varies with the size of the defect.
- Atrial septal defect is a direct communication between the atrial chambers whose most common type involves the ostium secundum.
- Patent ductus arteriosus is a direct communication between the aorta and pulmonary artery due to the continued patency of the ductus arteriosus after birth.
- Dilated cardiomyopathy is the most common form of primary cardiomyopathy and consists of cardiac enlargement with dilatation of all four chambers due to diminished contractility, resulting in progressive congestive heart failure and/or arrhythmias. The 5-year survival rate is 25%.
- Hypertrophic cardiomyopathy is an asymmetric cardiac hypertrophy that is most prominent in the ventricular septum, where it may obstruct the ventricular outflow tract, with resulting increased risk of sudden cardiac death, particularly in young athletes.
- Restrictive cardiomyopathy is an uncommon form of cardiomyopathy caused by diseases such as amyloidosis and sarcoidosis that produce restriction of cardiac filling during diastole.
- Carcinoid heart disease is a right-sided endocardial and valvular fibrosis secondary to exposure to serotonin in patients with carcinoid tumors that have metastasized to the liver.
- Cardiac myxoma is a benign tumor, usually arising within the left atrium near the fossa ovalis. It can cause tumor emboli and ball-valve obstruction of valves.
- Cardiac rhabdomyoma is a benign tumor, usually arising within the myocardium. It is associated with tuberous sclerosis.

ATELECTASIS


1. **Atelectasis** refers to an area of collapsed or nonexpanded lung. Atelectasis is a reversible disorder, but areas of atelectasis predispose for infection due to decreased mucociliary clearance.
2. **Major types:**
 - a. **Obstruction/resorption atelectasis** is the term used for collapse of lung due to resorption of air distal to an obstruction; examples include aspiration of a foreign body, chronic obstructive pulmonary disease (COPD), and postoperative atelectasis.
 - b. **Compression atelectasis** is the term used for atelectasis due to fluid, air, blood, or tumor in the pleural space.
 - c. **Contraction (scar) atelectasis** is due to fibrosis and scarring of the lung.
 - d. **Patchy atelectasis** is due to a lack of surfactant, as occurs in hyaline membrane disease of newborn or acute (adult) respiratory distress syndrome (ARDS).

PULMONARY INFECTIONS

1. In **bacterial pneumonia**, acute inflammation and consolidation (solidification) of the lung are due to a bacterial agent.
 - a. **Clinical signs and symptoms** include fever and chills; productive cough with yellow-green (pus) or rusty (bloody) sputum; tachypnea; pleuritic chest pain; and decreased breath sounds, rales, and dullness to percussion.
 - b. **Other clinical features.**
 - i. **Laboratory studies** typically show elevated white blood cell count with a left shift (more immature band neutrophils).
 - ii. **Chest x-ray** for lobar pneumonia typically shows lobar or segmental consolidation (opacification), and for bronchopneumonia typically shows patchy opacification. Pleural effusion may also be picked up on chest x-ray.
 - iii. In general, the keys to effective **therapy** are identification of the organism and early treatment with antibiotics.
 - c. **Lobar pneumonia** is characterized by consolidation of an entire lobe. The infecting organism is typically *Streptococcus pneumoniae* (95%) or *Klebsiella*.
 - i. Microbiologic characteristics of the lancet-shaped diplococcus *Streptococcus pneumoniae* include being alpha-hemolytic, bile soluble, and optochin sensitive.
 - ii. The **four classic phases** of lobar pneumonia are **congestion** (active hyperemia and edema); **red hepatization** (neutrophils and hemorrhage); **grey hepatization** (degradation of red blood cells); and **resolution** (healing). Most tissue examined microscopically for lobar pneumonia is in the red or grey hepatization stage, and shows intra-alveolar suppurative inflammation (neutrophils) and edema.

Bridge to Anatomy

Pores of Kohn are collateral connections between air spaces through which infections and neoplastic cells can spread.



Streptococcus pneumoniae

- d. **Bronchopneumonia** is characterized by scattered patchy consolidation centered on bronchioles; the inflammation tends to be bilateral, multilobar, and basilar, and particularly susceptible populations include the young, old, and terminally ill. Infecting organisms exhibit more variation than in lobar pneumonia, and include *Staphylococci*, *Streptococci*, *Haemophilus influenzae*, *Pseudomonas aeruginosa*, etc. Microscopic examination of tissue shows acute inflammation of bronchioles and surrounding alveoli. The diagnosis can often be established with sputum gram stain and sputum culture, but will sometimes require blood cultures.
 - e. **Treatment** of pneumonia is in general with initial empiric antibiotic treatment that is modified by the results of cultures and organism sensitivities.
 - f. **Complications** of pneumonia include fibrous scarring and pleural adhesions, lung abscess, empyema (pus in a body cavity), and sepsis.
2. **Lung abscess** is a localized collection of neutrophils (pus) and necrotic pulmonary parenchyma.
 - a. The **etiology** varies with the clinical setting.
 - i. **Aspiration** is the most common cause. It tends to involve right lower lobe and typically has mixed oral flora (often both anaerobic and aerobic) for infecting organisms.
 - ii. Lung abscess may also occur following a pneumonia, especially one due to *S. aureus* or *Klebsiella*. Lung abscesses may also occur following airway obstruction (postobstructive) or deposition of septic emboli in the lung.
 - b. **Complications** of lung abscess include empyema, pulmonary hemorrhage, and secondary amyloidosis.
 3. **Atypical pneumonia** is the term used for interstitial pneumonitis without consolidation.
 - a. **Infecting organisms** that can cause atypical pneumonia include *Mycoplasma pneumoniae*, *influenza virus*, *parainfluenza virus*, *respiratory syncytial virus* (RSV) which is especially important in young children), *adenovirus*, *cytomegalovirus* (CMV) which is especially important in the immunocompromised), *varicella virus*, and many others.
 - b. **Clinically**, atypical pneumonia is more common in children and young adults.
 - i. **Diagnosis.** Chest x-ray typically shows diffuse interstitial infiltrates. An elevated cold agglutinin titer specifically suggests *Mycoplasma* as a cause, which is important to identify since antibiotic therapy for *Mycoplasma* exists. Lung biopsy, if performed, typically shows lymphoplasmacytic inflammation within the alveolar septum.
 - c. **Complications** include superimposed bacterial infections and Reye syndrome (potentially triggered by viral illness [influenza/varicella] treated with aspirin).
 4. **Tuberculosis** has an increasing incidence in the United States, predominantly in immigrants. Patients who have HIV/AIDS are vulnerable to the infection. The infection is usually acquired by inhalation of aerosolized bacilli.

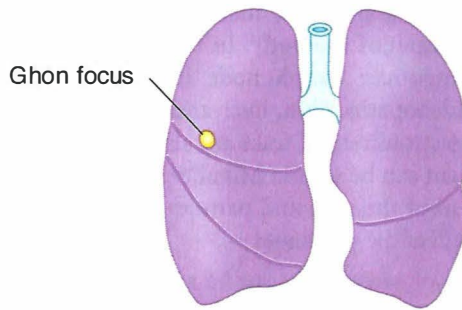


Figure 15-1. Tuberculosis

Note

BCG (Bacillus Calmette-Guérin) is a tuberculosis vaccine prepared from a strain of attenuated live bovine tuberculosis bacillus, *Mycobacterium bovis*.

- a. The **clinical presentation** includes fevers and night sweats, weight loss, cough, and hemoptysis. In this clinical setting, a positive PPD skin test may demonstrate that the person has been exposed to the mycobacterial antigens. Individuals who have received the BCG vaccine in some foreign countries may have a positive PPD test without being infected. In such cases chest x-ray and sputum work-up are done. Biopsy of affected tissues will typically show caseating granulomas with acid-fast bacilli.
- b. **Primary pulmonary tuberculosis** refers to the form of tuberculosis that develops on initial exposure to the disease. The Ghon focus of primary tuberculosis is characterized by subpleural caseous granuloma formation, either above or below the interlobar fissure. The term *Ghon complex* refers to the combination of the Ghon focus and secondarily-involved hilar lymph nodes with granulomas. Most primary pulmonary tuberculosis lesions (95%) will undergo fibrosis and calcification.
- c. **Secondary pulmonary tuberculosis** occurs either with reactivation of an old, previously quiescent infection or with reinfection secondary to a second exposure to the mycobacteria. In secondary pulmonary tuberculosis, the infection often produces a granuloma at the lung apex (Simon focus) secondary to the high oxygen concentration present at that site, since the upper parts of the lung typically ventilate more efficiently than the lower parts.
- d. **Progressive pulmonary tuberculosis** can take several forms, including cavitory tuberculosis, miliary pulmonary tuberculosis, and tuberculous bronchopneumonia.
- e. Additionally, **dissemination to other organ systems** can occur in advanced tuberculosis via a hematogenous route that often results in a miliary pattern within each affected organ. Sites that may become involved include meninges; cervical lymph nodes (scrofula) and larynx; liver/spleen, kidneys, adrenals, and ileum; lumbar vertebrae bone marrow (Pott disease); and fallopian tubes and epididymis.

SARCOIDOSIS

1. **Sarcoidosis** is a systemic granulomatous disease of uncertain etiology, and it is a diagnosis of exclusion. The disease affects females more than males and has typical age range of 20 to 60 years. It is most common in African American women.
2. The **clinical presentation** of sarcoidosis varies. The disease may be asymptomatic, or presenting symptoms may include cough and shortness of breath; fatigue and malaise; skin lesions; eye irritation or pain; and fever or night sweats.

3. The noncaseating granulomas that are characteristic of sarcoidosis may occur in **any organ of the body**. In the lung, they typically form diffuse scattered granulomas; lymph node involvement may cause hilar and mediastinal adenopathy. Skin, liver and/or spleen, heart, central nervous system, and gastrointestinal tract are also frequent targets of the disease. Eye involvement can be seen in Mikulicz syndrome, which is characterized by involvement of the uvea and parotid. Bone marrow involvement tends to especially affect the phalanges.
4. The **diagnosis** of sarcoidosis can be suggested by clinical studies. In the laboratory, serum angiotensin converting enzyme (ACE), which is synthesized by endothelial cells and macrophages, may be elevated. X-ray studies frequently show bilateral hilar lymphadenopathy.
5. Sarcoidosis is considered to be a **diagnosis of exclusion**. In practice, this means that the diagnosis is considered when a biopsy shows features characteristic of sarcoidosis (such as noncaseating granulomas, Schaumann bodies [laminated dystrophic calcification], and asteroid bodies [stellate giant-cell cytoplasmic inclusions]). However, most pathologists will not specifically suggest the diagnosis until they have ordered special stains for mycobacteria (e.g. acid fast stains) and fungi (typically either PAS or silver-based stains), and have not identified any of these organisms in the granulomas.
6. The **prognosis** is favorable with a variable clinical course.

OBSTRUCTIVE VERSUS RESTRICTIVE LUNG DISEASE

Table 15-1. Obstructive Versus Restrictive Lung Disease

Obstructive Airway Disease	Restrictive Lung Disease
Definition: Increased resistance to airflow secondary to obstruction of airways	Decreased lung volume and capacity
Pulmonary function tests (spirometry) FEV ₁ /FVC ratio is decreased	Decreased TLC and VC
Examples: <u>Chronic obstructive airway disease</u> <ul style="list-style-type: none"> ● Asthma ● Chronic bronchitis ● Emphysema ● Bronchiectasis 	<u>Chest wall disorders</u> <ul style="list-style-type: none"> ● Obesity, kyphoscoliosis, polio, etc. <u>Interstitial/infiltrative diseases</u> <ul style="list-style-type: none"> ● ARDS, pneumoconiosis ● Pulmonary fibrosis

Table 15-2. Summary of Obstructive Versus Restrictive Pattern

Variable	Obstructive Pattern, e.g., Emphysema	Restrictive Pattern, e.g., Fibrosis
Total lung capacity	↑	↓
FEV ₁	↓	↓
Forced vital capacity	↓	↓
FEV ₁ /FVC	↓	↑ or normal
Peak flow	↓	↓
Functional residual capacity	↑	↓
Residual volume	↑	↓

OBSTRUCTIVE PULMONARY DISEASE

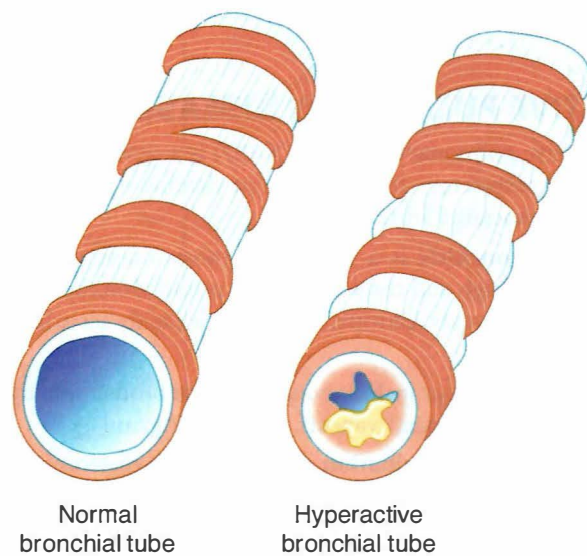
Chronic obstructive pulmonary disease (COPD) is a general term used to indicate chronic decreased respiratory function due to chronic bronchitis or emphysema. Both diseases are associated with smoking.

1. **Chronic bronchitis** is a clinical diagnosis made when a patient has a persistent cough and copious sputum production for at least 3 months in 2 consecutive years. Chronic bronchitis is highly associated with smoking (90%).
 - a. **Clinical findings** include cough, sputum production, dyspnea, frequent infections, hypoxia, cyanosis, and weight gain.
 - b. **Microscopic examination** demonstrates hypertrophy and hyperplasia of bronchial mucous glands (Reid index equals the submucosal gland thickness divided by the bronchial wall thickness between the ciliated pseudostratified columnar epithelium and the perichondrium; normal ratio is 0.4 or less); increased numbers of goblet cells; hypersecretion of mucus; and bronchial squamous metaplasia and dysplasia (smokers).
 - c. **Complications** include increased risk for recurrent infections; secondary pulmonary hypertension leading to right heart failure (cor pulmonale); and lung cancer.
2. **Emphysema** is the term used when destruction of alveolar septa results in enlarged air spaces and a loss of elastic recoil.
 - a. The etiology of emphysema involves a **protease/antiprotease imbalance**. The proteases (including elastase) are produced by neutrophils and macrophages, which are stimulated by smoke and pollution. The antiproteases include α -1-antitrypsin, α -1-macroglobulin, and secretory leukoprotease inhibitor.
 - b. On **gross examination**, the lungs are overinflated and enlarged, and have enlarged, grossly visible air spaces. They also show formation of apical blebs and bullae (centriacinar type).
 - c. **Clinical findings** include progressive dyspnea, pursing of lips and use of accessory respiratory muscles to breathe, barrel chest (increased anterior-posterior diameter), and weight loss.

Table 15-3. Manifestations Related to Area of Involvement

Centriacinar (Centrilobular)	Panacinar (Panlobular)
Proximal respiratory bronchioles involved, distal alveoli spared	Entire acinus involved
Most common type (95%)	
Associated with smoking, air pollution	α -1-antitrypsin deficiency
Distribution: worst in apical segments of upper lobes	Distribution: entire lung; worse in bases of lower lobes

3. **Asthma** is due to hyperreactive airways, which undergo episodic broncho-spasm when triggered by certain stimuli.

**Figure 15-2.** Bronchial changes in asthma

- a. **Extrinsic (type I hypersensitivity reaction) asthma** is the allergic (atopic) type; it is the most common form of asthma and usually affects children and young adults. It often has a positive family history. The involved allergens may be pollen, dust, food, molds, animal dander, or other substances. Additionally, extrinsic asthma may be a reaction to occupational exposure to fumes, gases, or chemicals.
- b. **Intrinsic (unknown mechanism) asthma** is triggered by processes including respiratory infections (usually viral), stress, exercise, cold temperatures, or medications (notably aspirin).
- c. An **asthma attack** is characterized by wheezing, severe dyspnea, and coughing. Status asthmaticus is a potentially fatal unrelenting attack of asthma.
- d. **Microscopic examination** of sputum cytology may show Curschmann spirals (twisted mucus plugs admixed with sloughed epithelium), eosinophils, or Charcot-Leyden crystals (composed of eosinophil membrane protein). Microscopic examination of a bronchial biopsy may show mucus plugs, hypertrophy of mucous glands with goblet cell

hyperplasia, inflammation (especially with eosinophils), edema; hypertrophy and hyperplasia of bronchial wall smooth muscle, and thickened basement membranes.

4. **Bronchiectasis** is an abnormal permanent airway dilatation due to chronic necrotizing inflammation. Clinical findings include cough, fever, malodorous purulent sputum, and dyspnea.
 - a. **Causes** of bronchiectasis are diverse, and include bronchial obstruction by foreign body, mucus, or tumor, necrotizing pneumonias, cystic fibrosis, and Kartagener syndrome.
 - i. **Kartagener syndrome** is an autosomal recessive condition caused by immotile cilia due to a defect of dynein arms (primary ciliary dyskinesia). It is characterized clinically by bronchiectasis, chronic sinusitis, and situs inversus (a congenital condition where the major visceral organs are anatomically reversed compared with their normal anatomical positions).
 - b. On **gross examination**, bronchiectasis shows dilated bronchi and bronchioles extending out to the pleura. These may also be appreciated on chest x-ray.
 - c. **Complications** of bronchiectasis include abscess, septic emboli, cor pulmonale, and secondary amyloidosis.

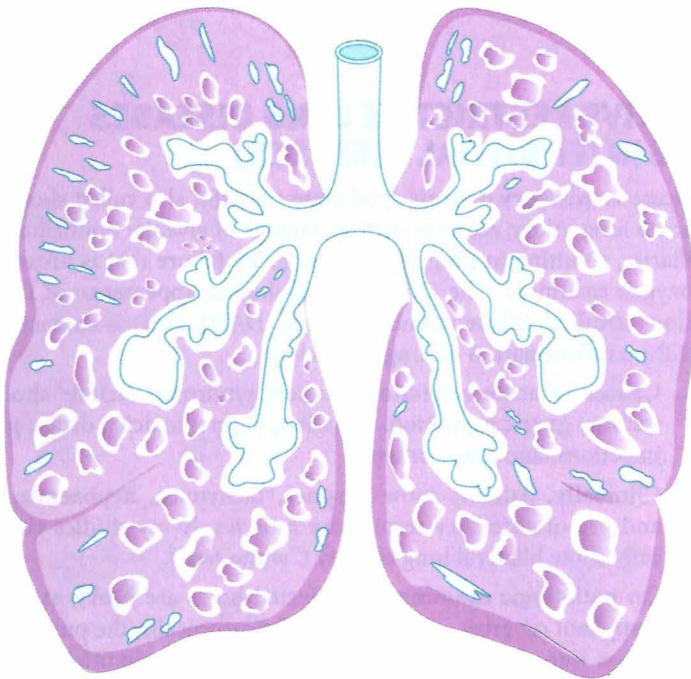


Figure 15-3. Cross-Section of Bronchiectasis

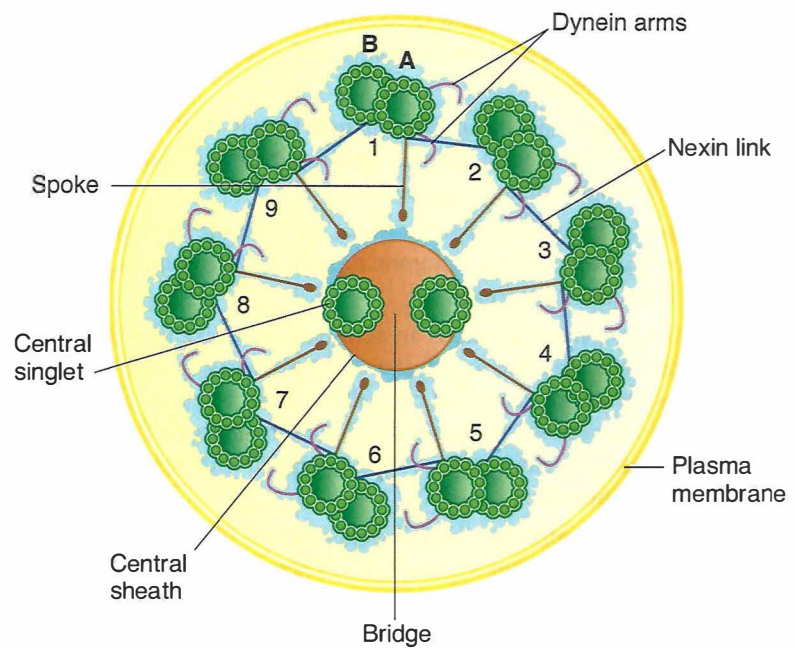


Figure 15-4. Structure of the Axoneme of a Cilium

INFILTRATIVE RESTRICTIVE LUNG DISEASES (DIFFUSE INTERSTITIAL DISEASES)

1. **Acute respiratory distress syndrome (ARDS)**, also called shock lung and acute lung injury, refers to diffuse damage of alveolar epithelium and capillaries, resulting in progressive respiratory failure that is unresponsive to oxygen treatment. The gross and histological appearance of these conditions is called diffuse alveolar damage (DAD). DAD is characterized by a diffuse inflammation of lung parenchyma.
 - a. **Causes** of acute respiratory distress syndrome include shock, sepsis, trauma, gastric aspiration, radiation, oxygen toxicity, drugs, pulmonary infections, and many others.
 - b. **Clinically**, patients show dyspnea, tachypnea, hypoxemia, cyanosis, and use of accessory respiratory muscles. X-ray studies characteristically show bilateral lung opacity (“white out”).
 - c. On **pathologic examination**, affected lungs are heavy, stiff, and non-compliant on gross examination. Microscopically, the pulmonary tissue shows interstitial and intra-alveolar edema; interstitial inflammation; loss of type I pneumocytes; and hyaline membrane formation (composed of cellular debris of dead pneumocytes, and fibrin-rich edema).
 - d. **Treatment** is based on treating the underlying cause and on supporting respiration with oxygen, positive end-expiratory pressure (PEEP), and mechanical ventilation. The prognosis is problematic even with good care, with overall mortality of 50%.
2. **Respiratory distress syndrome of the newborn** (hyaline membrane disease of newborns) is due to a deficiency of surfactant. It is associated with prematurity (gestational age of <28 weeks has a 60% incidence); maternal diabetes; multiple births; and Cesarean section delivery.
 - a. **Clinically**, the infants are typically normal at birth, but within a few hours develop increasing respiratory effort, tachypnea, nasal flaring, use of accessory muscles of respiration, an expiratory grunt, and cyanosis.

Bridge to Anatomy

Type II pneumocytes play an important role in repair in lung injury.

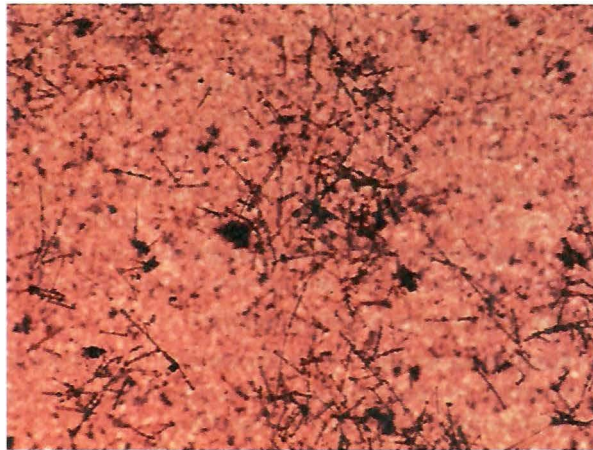
- b. **Evaluation** may demonstrate “ground-glass” reticulogranular densities on x-ray; lecithin:sphingomyelin ratio <2 on laboratory study; and atelectasis and hyaline membrane formation if biopsy is performed.
- c. **Treatment** is with surfactant replacement and oxygen; the overall mortality is ~30% and complications of oxygen treatment in newborns include bronchopulmonary dysplasia and retrolental fibroplasia (retinopathy of prematurity). Respiratory distress syndrome of the newborn can sometimes be prevented if labor can be delayed and if corticosteroids are used to mature the lung.
3. **Occupation-associated pneumoconiosis.**
- a. **Pneumoconioses** are fibrosing pulmonary diseases caused by inhalation of an aerosol (mineral dusts, particles, vapors, or fumes). Key factors affecting their development include the type of aerosol and its ability to stimulate fibrosis; the dose and duration of exposure; and the size of the particle, with only particles less than 10 microns entering the alveolar sac.
- b. **Coal worker’s pneumoconiosis** is an important pneumoconiosis that is due to anthracosis, in which carbon pigment (anthracotic pigment) from coal mining accumulates in macrophages along the pleural lymphatics and interstitium. Clinically, the disease may progress through several stages.
- The earliest stage is **asymptomatic**.
 - Simple coal worker’s pneumoconiosis** (black lung disease) is characterized by coal-dust macules and nodules in the upper lobes that produce little pulmonary dysfunction.
 - Complicated coal worker’s pneumoconiosis** is characterized by progressive massive fibrosis that is accompanied by increasing respiratory distress, secondary pulmonary hypertension, and cor pulmonale.
 - Caplan syndrome** is the term used for pneumoconiosis (can be of types other than coal worker’s) accompanied by rheumatoid arthritis.
- c. **Asbestosis** is due to members of a family of crystalline silicates. Occupations in which asbestos exposure may occur include shipyard work, insulation and construction industries, brake-lining manufacture.
- Serpentine asbestos** is composed of curved, flexible fibers, with the most common type of serpentine asbestos being chrysotile.
 - Amphibole asbestos** is composed of straight, brittle fibers, with important types of amphibole asbestos including crocidolite, tremolite, and amosite. Amphibole asbestos is more pathogenic than serpentine asbestos and is highly associated with mesotheliomas.
 - The **pulmonary pathology** of asbestosis is a diffuse interstitial fibrosis, which is most severe in the lower lobes; it causes slowly progressive dyspnea which may eventually be complicated by secondary pulmonary hypertension and cor pulmonale. Pulmonary biopsy may demonstrate asbestos bodies that have become coated with iron (ferruginous bodies).
 - Pleural involvement** may take the form of parietal pleural plaques (acellular type I collagen deposition) in a symmetrical distribution involving the domes of the diaphragm and anteriolateral chest walls, as well as fibrous pleural adhesions.
 - Bronchogenic carcinoma** is the most common tumor in asbestos-exposed individuals; the etiology shows a strong synergistic effect between smoking and asbestos exposure.
 - Malignant mesotheliomas** are rare, highly malignant neoplasms that are associated with occupational exposure to asbestos in 90% of cases. Mesothelioma presents with recurrent pleural effusions, dyspnea, and chest pain. The tumor grossly encases and compresses

Clinical Correlate

Dietary drugs fenfluramine and phentermine have been associated with primary pulmonary hypertension.

the lung; microscopic examination exhibits carcinomatous and sarcomatous elements (biphasic pattern); while electron microscopy shows long, thin microvilli on some tumor cells. The prognosis of mesothelioma is poor.

- viii. **Other problems** include increased risk of laryngeal, stomach, and colon cancers. Family members also have increased risk of cancer due to the worker bringing home clothing covered with asbestos fibers. Caplan syndrome (in this case due to asbestosis with rheumatoid arthritis) may also occur.



© Colin M. Bloor, M.D. Used with permission.

Figure 15-5. Asbestos fibers in lung tissue

- d. **Silicosis** is due to exposure to silicon dioxide (silica), and is seen most frequently with occupational exposure (sandblasters, metal grinders, miners).
- i. The **pulmonary pathology** shows dense nodular fibrosis of the upper lobes which may progress to massive fibrosis; birefringent silica particles can be seen with polarized light.
 - ii. **Clinically**, patients present with insidious onset of dyspnea that is slowly progressive despite cessation of exposure. X-ray shows fibrotic nodules in the upper zones of the lungs. There is an increased risk of secondary tuberculosis, and Caplan syndrome (in this case due to silicosis and rheumatoid arthritis) can also occur.
- e. **Berylliosis**, due to beryllium exposure, is acquired from occupation exposure, typically from the aerospace industry and nuclear reactors. Genetic susceptibility appears to play a role, as does a type IV hypersensitivity reaction, resulting in granuloma formation.
- i. **Clinically**, acute exposure causes acute pneumonitis, while chronic exposure causes pulmonary noncaseating granulomas and fibrosis, hilar lymph node granulomas, and systemic granulomas

VASCULAR DISORDERS

1. **Pulmonary edema** is fluid accumulation within the lungs, usually due to disruption of Starling forces or endothelial injury.
 - a. Pulmonary edema due to **increased hydrostatic pressure** can be seen in left-sided heart failure, mitral valve stenosis, and fluid overload.
 - b. Pulmonary edema due to **decreased oncotic pressure** can be seen in nephrotic syndrome and liver disease.

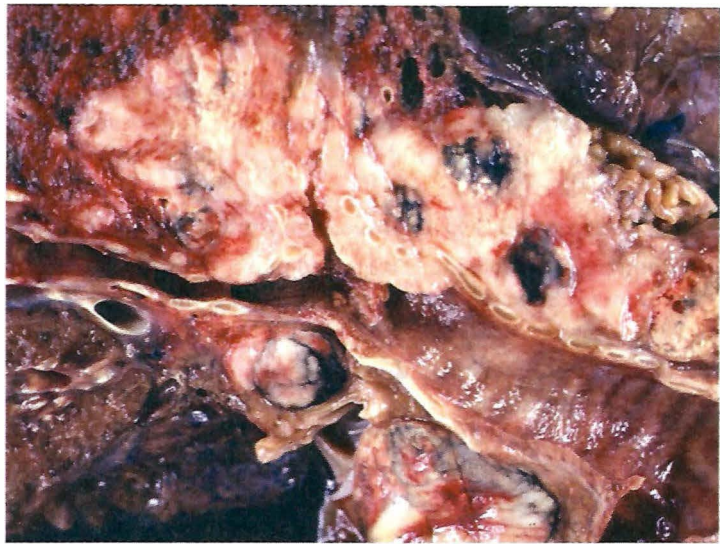
- c. Pulmonary edema due to **increased capillary permeability** can be due to infections, drugs (bleomycin, heroin), shock, and radiation.
 - d. The **pathology** grossly shows wet, heavy lungs (usually worse in lower lobes), while microscopic examination shows intraalveolar fluid, engorged capillaries, and hemosiderin-laden macrophages (heart-failure cells).
2. **Pulmonary emboli (PE) and pulmonary infarction** (see chapter 5)
 3. **Pulmonary hypertension** is increased pulmonary artery pressure, usually due to increased vascular resistance or blood flow.
 - a. The **etiology** varies, and can include chronic obstructive pulmonary disease and interstitial disease (hypoxic vasoconstriction); multiple ongoing pulmonary emboli; mitral stenosis and left heart failure; congenital heart disease with left to right shunts (atrial septal defect, ventricular septal defect, patent ductus arteriosus); and primary (idiopathic) pulmonary hypertension, typically in young women.
 - b. The **pathology** includes pulmonary artery atherosclerosis, small artery medial hypertrophy and intimal fibrosis, and plexogenic pulmonary arteriopathy. Pulmonary hypertension may also damage the heart, leading to right ventricular hypertrophy and then failure (cor pulmonale).

PULMONARY NEOPLASIA

1. **Bronchogenic carcinoma** is the leading cause of cancer death among both men and women. It occurs most commonly from ages 50 to 80 years and has been increasing in women (increased smoking) in the past few decades.
 - a. Major **risk factors** include cigarette smoking, occupational exposure (asbestosis, uranium mining, radiation, etc.), air pollution, and chronic pulmonary fibrosing conditions (e.g., idiopathic pulmonary fibrosis, nonspecific interstitial pneumonia, cryptogenic organizing pneumonia, collagen vascular diseases [e.g., systemic lupus erythematosus, rheumatoid arthritis], pneumoconioses).
 - b. Common **genetic mutations** involve the oncogenes L-myc (small cell carcinomas) and K-ras (adenocarcinomas); tumor suppressor genes: p53 and retinoblastoma.
 - c. **Clinical features** include cough, sputum production, weight loss, anorexia, fatigue, dyspnea, hemoptysis, and chest pain. Obstruction may produce focal emphysema, atelectasis, bronchiectasis, or pneumonia.
 - d. **Adenocarcinoma** (35%) is more commonly seen in women and is less closely associated with smoking than squamous cell carcinoma. Adenocarcinoma grossly causes peripheral gray-white mass with pleural puckering, and the tumor may develop in areas of parenchymal scarring (scar carcinoma). Microscopically, the tumor forms glands and may produce mucin.
 - e. **Bronchioloalveolar carcinoma** (5%) is a subset of adenocarcinoma that arises from terminal bronchioles or alveolar walls. Bronchioloalveolar carcinoma grossly causes peripheral mucinous gray-white nodules. Microscopically, columnar tumor cells grow along the walls of pre-existing alveoli.
 - f. **Squamous cell carcinoma** (30%) is strongly related to smoking and affects males more than females. Squamous cell carcinoma arises from bronchial epithelium after a progression: metaplasia → dysplasia → carcinoma *in situ* → invasive carcinoma.

Bridge to Pharmacology

Erlotinib (Tarceva™) is used to treat non-small cell lung cancer, pancreatic cancer, and other types of cancers that have failed a prior trial of chemotherapy. It is a tyrosine-kinase inhibitor which inhibits the epidermal growth factor receptor (EGFR). The drug targets EGFR tyrosine kinase which is highly expressed and sometimes mutated in various forms of cancer.



© Katsumi M. Miyai, M.D., Ph.D.; Regents of the University of California. Used with permission.

Figure 15-6. Squamous Cell Carcinoma of the Lung

- i. **Pathology.** The tumor grossly causes a gray-white bronchial mass, usually centrally located. Microscopically, the tumor shows invasive nests of squamous cells with intercellular bridges (desmosomes) and keratin production (“squamous pearls”).
- g. **Small cell (oat cell) carcinoma** (20%) has a strong association with smoking, and affects males more than females. The tumor is very aggressive, with rapid growth and early dissemination. Small cell carcinoma is commonly associated with paraneoplastic syndromes.
 - i. **Pathology.** Gross examination demonstrates central, gray-white masses. Microscopic examination shows small round or polygonal cells in clusters, and electron microscopy shows cytoplasmic dense-core neurosecretory granules.
- h. **Large cell carcinoma** (10%) has large anaplastic cells without evidence of differentiation.
- i. **Intrathoracic spread** of lung cancer is to lymph nodes (50%), particularly hilar, bronchial, tracheal, and mediastinal; pleura (adenocarcinoma); and lung apex causing Horner syndrome (Pancoast tumor).
 - i. Obstruction of the superior vena cava by tumor causes **superior vena cava syndrome**, which is characterized by distended head and neck veins, plethora, and facial and upper arm edema.
 - ii. **Esophageal obstruction** can cause dysphagia.
 - iii. Recurrent laryngeal **nerve involvement** causes hoarseness, while phrenic nerve damage causes diaphragmatic paralysis.
- j. **Extrathoracic sites of metastasis** include adrenal (>50%), liver, brain, and bone.
- k. **Paraneoplastic syndromes.**
 - i. **Endocrine/metabolic syndromes** include Cushing syndrome secondary to ACTH production, SIADH secondary to ADH production, and hypercalcemia secondary to PTH production (squamous cell carcinoma).
 - ii. **Eaton-Lambert syndrome** (See Skeletal Muscle and Peripheral Nerve Pathology Chapter 29).
 - iii. **Acanthosis nigricans** (See Skin Pathology Chapter 11).

In a Nutshell

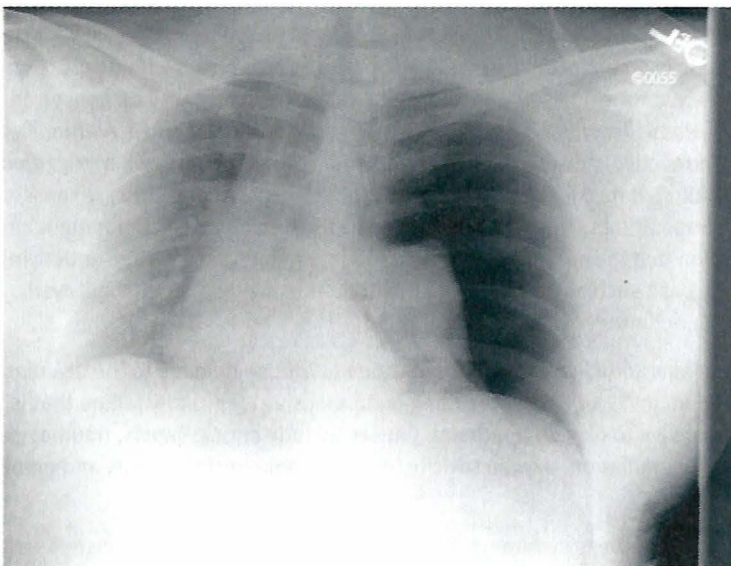
Horner Syndrome

- Ptosis
- Miosis
- Anhidrosis
- Enophthalmos

- iv. **Hypertrophic pulmonary osteoarthropathy** is characterized by periosteal new bone formation with clubbing and arthritis.
 - m. **Treatment** of non-small cell lung cancer is with surgery, and treatment of small cell lung cancer is with chemotherapy and radiation. Despite treatment, the prognosis is poor, with overall 5-year survival of 10%.
2. **Bronchial carcinoids** occur in a younger age group (age <40) and typically produce a polypoid intrabronchial mass; it is characterized on light microscopy by small, round, uniform cells growing in nests (organoid pattern), and on electron microscopy by cytoplasmic dense core neurosecretory granules.
 3. **Laryngeal squamous cell carcinoma** causes hoarseness, difficulty swallowing, pain, hemoptysis, and eventual respiratory compromise. Risk factors include smoking, alcohol, and frequent cord irritation (professional singing or lecturing). Complications include direct extension, metastases, and infection.
 4. **Metastatic carcinoma** is the most common malignant neoplasm in the lung. It typically causes multiple, bilateral, scattered nodules; common primary sites include breast, stomach, pancreas, and colon.

DISEASES OF THE PLEURAL CAVITY

1. **Pleural effusion** is the accumulation of fluid in the pleural cavity. *Empyema* refers to pus in pleural space. *Chylothorax* refers to chylous fluid in the pleural space secondary to obstruction of the thoracic duct, usually by tumor.
2. **Pneumothorax** is the term used for air in the pleural cavity. It can be due to traumatic penetrating chest wall injuries or spontaneous rupture of apical blebs in typically tall young adults (spontaneous pneumothorax). The term *tension* pneumothorax is used if a life-threatening shift of thoracic organs across midline occurs.



© James G. Smirniotopoulos, M.D.:
Uniformed Services University. Used with permission.

Figure 15-7. Densely black appearance on chest x-ray of a pneumothorax

3. **Mesothelioma** (see section on asbestosis earlier in this chapter).

Chapter Summary

- Atelectasis is an area of collapsed or unexpanded lung and can occur secondary to obstruction, compression, contraction, or lack of surfactant.
- Bacterial pneumonia is an acute inflammation and consolidation (solidification) of the lung due to a bacterial agent. Lobar pneumonia causes consolidation of an entire lobe and is most commonly caused by infection with *Streptococcus pneumoniae*. Bronchopneumonia causes scattered patchy consolidation centered around bronchioles and can be due to a wide variety of bacterial agents.
- Lung abscess is a localized collection of neutrophils (pus) and necrotic pulmonary parenchyma and may occur following aspiration, pneumonia, obstruction, or septic emboli.
- Atypical pneumonia causes interstitial pneumonitis without consolidation and can be due to viral agents and *Mycoplasma pneumoniae*.
- Tuberculosis causes caseating granulomas containing acid-fast mycobacteria. Primary tuberculosis can produce a Ghon complex, characterized by a subpleural caseous granuloma above or below the lobar fissure accompanied by hilar lymph node granulomatous inflammation. Secondary tuberculosis tends to involve the lung apex. Progressive pulmonary tuberculosis can take the forms of cavitory tuberculosis, miliary pulmonary tuberculosis, and tuberculous bronchopneumonia. Miliary tuberculosis can also spread to involve other body sites.
- Sarcoidosis is a granulomatous disease of unknown etiology that produces clinical disease somewhat resembling tuberculosis.
- Obstructive airway disease is characterized by increased resistance to airflow secondary to obstruction of airways, whereas restrictive lung disease is characterized by decreased lung volume and capacity.
- Chronic obstructive pulmonary disease includes chronic bronchitis, emphysema, asthma, and bronchiectasis. Chronic bronchitis is a clinical diagnosis made when persistent cough and copious sputum production have been present for at least 3 months in 2 consecutive years. Emphysema is associated with destruction of respiratory bronchioles or alveolar septa, resulting in enlarged air spaces and a loss of elastic recoil, and producing overinflated, enlarged lungs. Asthma is due to hyperreactive airways, resulting in episodic bronchospasm when triggered by stimuli that may include allergens, respiratory infections, stress, exercise, cold temperatures, and drugs. Bronchiectasis is an abnormal permanent airway dilatation due to chronic necrotizing infection; most patients have underlying lung disease such as bronchial obstruction, necrotizing pneumonias, cystic fibrosis, or Kartagener syndrome.
- Acute respiratory distress syndrome is due to diffuse damage to the alveolar epithelium and capillaries, resulting in progressive respiratory failure that is unresponsive to oxygen treatment. Causes include shock, sepsis, trauma, gastric aspiration, radiation, oxygen toxicity, drugs, pulmonary infections, and many others.
- Respiratory distress syndrome of the newborn causes respiratory distress within hours of birth and is seen in infants with deficiency of surfactant secondary to prematurity, maternal diabetes, multiple births, or c-section delivery.
- Pulmonary edema is fluid accumulation within the lungs that can be due to many causes, including left-sided heart failure, mitral valve stenosis, fluid overload, nephrotic syndrome, liver disease, infections, drugs, shock, and radiation.

(Continued)

Chapter Summary (*cont'd*)

- Most pulmonary emboli arise from deep vein thrombosis in the leg and may be asymptomatic, cause pulmonary infarction, or cause sudden death.
- Pulmonary hypertension is increased pulmonary artery pressure, usually due to increased vascular resistance or blood flow. Pulmonary hypertension can be primary (idiopathic) or related to underlying COPD, interstitial disease, pulmonary emboli, mitral stenosis, left heart failure, and congenital heart disease with left to right shunt.
- Bronchogenic carcinoma is the leading cause of cancer deaths among both men and women. Major risk factors are cigarette smoking, occupational exposures, air pollution, and “scarring.” Histologic types include adenocarcinoma, bronchioalveolar carcinoma, squamous-cell carcinoma, small-cell carcinoma, and large-cell carcinoma. Other tumors of importance include bronchial carcinoids, metastatic carcinoma to the lung, and laryngeal squamous cell carcinoma.
- Pleural effusion is the accumulation of fluid in the pleural cavity. Pneumothorax is air in the pleural cavity.
- Mesotheliomas are rare, highly malignant neoplasms that can involve the pleura and are closely related to prior asbestos exposure.
- Pneumoconiosis is a fibrosing pulmonary disease caused by inhalation of an aerosol, such as mineral dust, particles, vapors, or fumes.
- Coal worker’s pneumoconiosis (black lung disease) can range in severity from slight pulmonary dysfunction to progressive massive fibrosis leading to increasing respiratory distress and cor pulmonale. Caplan syndrome is the term used for the combination of pneumoconiosis (due to many different agents) and rheumatoid arthritis.
- Asbestosis can cause pulmonary fibrosis, bronchogenic carcinoma, and malignant mesotheliomas. Silicosis can cause pulmonary fibrosis and an increased risk of tuberculosis. Berylliosis can cause either an acute pneumonitis or granulomatous disease with fibrosis of the lungs.

CONGENITAL ANOMALIES OF THE KIDNEY

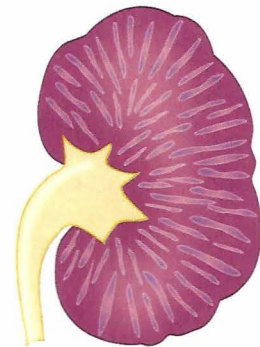
1. **Renal agenesis**
 - a. **Bilateral agenesis** is incompatible with life. Ultrasound shows oligohydramnios. Affected fetuses typically also have Potter facies (flattened nose, low-set ears, and recessed chin); talipes equinovarus (talus [ankle] + pes [foot] and equino [heel] + varus [turned upward] = clubfoot); and pulmonary hypoplasia.
 - b. In **unilateral agenesis**, the remaining kidney undergoes compensatory hypertrophy. Patients often have adequate renal function, but they may develop progressive glomerular sclerosis.
2. **Hypoplasia** refers to failure of a kidney (usually unilateral) to develop to normal weight; the hypoplastic kidney has a decreased number of calyces and lobes.
3. **Horseshoe kidney** is a common congenital anomaly that is found in 1 in 750 autopsies. The kidneys show fusion, usually at the lower pole; affected individuals have normal renal function but may be predisposed to renal calculi.
4. **Abnormal locations.** The most common abnormal location is a pelvic kidney. The ectopic kidney usually has normal function. Tortuosity of ureters may predispose to pyelonephritis.

CYSTIC DISEASE

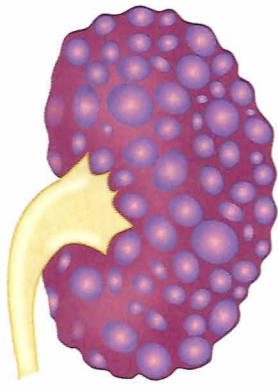
1. **Autosomal recessive polycystic kidney disease** (also called *childhood* polycystic kidney disease) is a rare autosomal recessive disease that presents in infancy with progressive and often fatal renal failure.
 - a. The **kidneys** are bilaterally enlarged and have multiple small cysts in the cortex and medulla. The cysts occur in the collecting ducts of the nephron and are consequently oriented in a radial fashion with their long axis at right angles to the renal capsule.
 - b. In the **liver**, patients may also have multiple hepatic cysts and congenital hepatic fibrosis.
2. **Autosomal dominant polycystic kidney disease** (also called *adult* polycystic kidney disease) is an autosomal dominant disease that affects 1 in 1,000 people. There is most frequently a mutation of the PKD1 gene on chromosome 16 that produces a transmembrane protein called polycystin 1. Other mutations involve PKD2 and PKD3 genes.
 - a. **Clinically**, patients are asymptomatic with normal renal function until middle age, and then present with renal insufficiency, hematuria, and hypertension or with abdominal masses and flank pain. The diagnosis is established with ultrasound and CT scans. Most patients develop end-stage renal failure by their seventh decade.

Clinical Correlate

The central portion of a horseshoe kidney may be found just inferior to the inferior mesenteric artery because its embryologic ascent is arrested by the artery's presence.



**Infantile
Polycystic Disease**

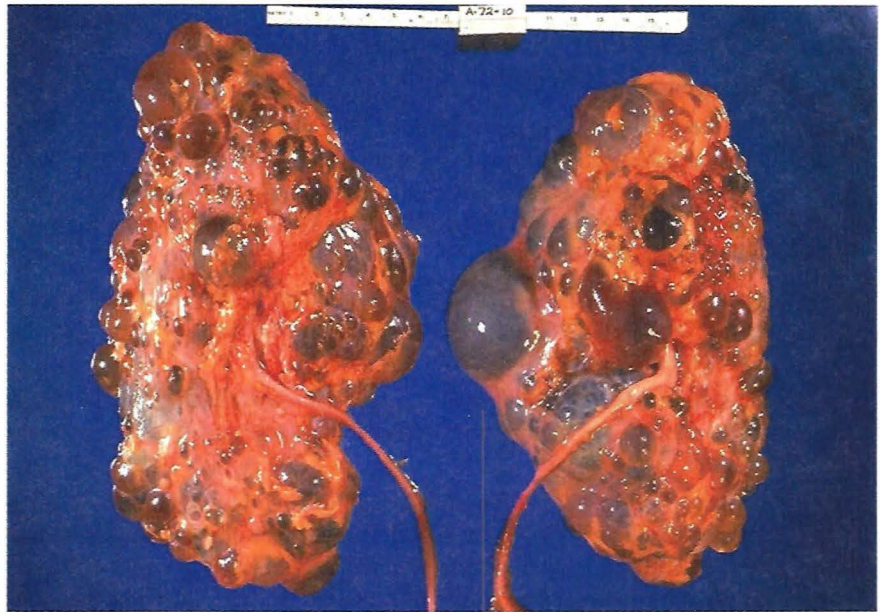


Adult Polycystic Disease

Clinical Correlate

The cysts in autosomal dominant (adult) PKD involve less than 10% of nephrons, but they gradually expand and compress the rest of the kidney, interfering with its function. This is the reason why kidney function can remain normal for many years.

- b. On gross **pathologic examination**, the kidneys have massive bilateral enlargement with large bulging cysts filled with serous, turbid, or hemorrhagic fluid. Microscopic examination shows functioning nephrons present between the cysts; the cysts arise from the tubular structures of the nephron.
- c. **Extrarenal manifestations** include liver cysts, berry aneurysms of the circle of Willis, mitral valve prolapse, and colonic diverticula.



© cdc.gov. Used with permission.

Figure 16-1. Gross Pathology of Polycystic Kidneys

- 3. **Renal dysplasia** is the most common renal cystic disease in children, in whom it causes an enlarged renal mass with cartilage and immature collecting ducts. It may progress clinically to renal failure.
- 4. **Medullary sponge kidney disease** causes multiple cysts of collecting ducts with a “Swiss cheese” appearance. It may predispose to recurrent urinary tract infections, hematuria, and renal stones.
- 5. **Acquired polycystic disease** is seen in renal dialysis patients and is associated with a small risk of developing renal cell carcinoma.
- 6. **Simple retention cysts** of the kidney are common in adults and occasionally cause hematuria.

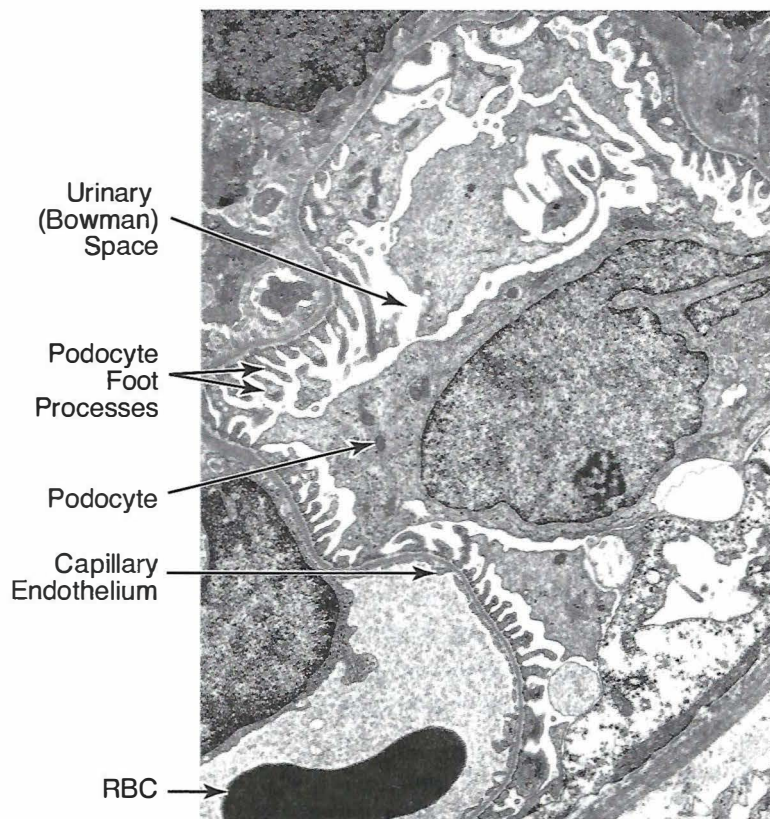
GLOMERULAR DISEASES

1. Diagnosis of glomerular diseases
 - a. Clinical syndrome

Table 16-1. Clinical Syndromes in Glomerular Disease

Nephritic Syndrome	Nephrotic Syndrome
Hematuria (RBC casts)	Severe proteinuria (>3.5 g/day)
Hypertension	Hypoalbuminemia (<3 g/dl)
Azotemia	Generalized edema
Oliguria	Hypertlipidemia
Proteinuria (<3.5 g/day)	Lipiduria

- b. Renal biopsy
 - i. Light microscopy (LM)
 - ii. Immunofluorescence (IF)
 - iii. Electron microscopy (EM)



© Gold Standard Multimedia, Inc. Used with permission.

Figure 16-2. Transmission Electron Micrograph Demonstrating Podocytes

Clinical Correlate

The classic presentation of APSGN is a young child with fever, malaise, periorbital edema, hypertension, smoky urine, and oliguria, beginning approximately 2 weeks after a streptococcal throat infection.

PRIMARY GLOMERULOPATHIES (NEPHRITIC)

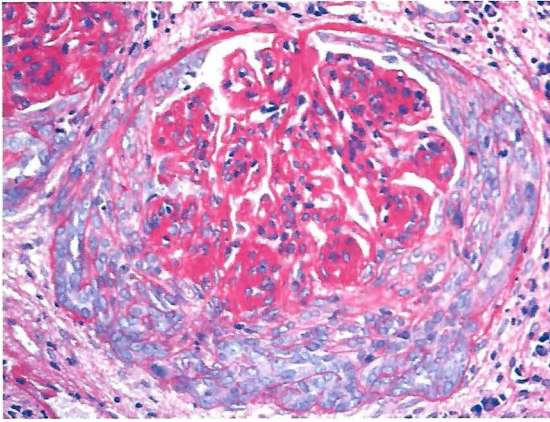
1. **Acute poststreptococcal glomerulonephritis (APSGN)**, (also called acute proliferative glomerulonephritis or postinfectious glomerulonephritis), typically occurs 2–4 weeks after a streptococcal infection of the throat or skin. There is a decreasing incidence in the United States; children are affected more frequently than adults.
 - a. The infecting **organism** is most commonly β -hemolytic group A *streptococci*, but acute proliferative glomerulonephritis can also be caused by other bacteria, viruses, and parasites, and even systemic diseases (SLE and polyarteritis nodosa).
 - b. **Clinically**, the condition presents with nephritic syndrome with elevated antistreptolysin O (ASO) titers (when related to streptococcal infection) and low serum complement.
 - c. **Renal biopsy.** Light microscopy shows hypercellular glomeruli with neutrophils and monocytes; there are also red cell casts in the renal tubules. Immunofluorescence shows granular deposits of IgG, IgM, and C3 throughout the glomerulus. Electron microscopy shows subepithelial immune complex deposits (humps).
 - d. **Clinical course.** The treatment is with conservative fluid management. Most children have a good prognosis, with complete recovery in >95% of cases, but severe disease (RPGN in 1% of cases and chronic glomerulonephritis in 2%) can also occur. Adults completely recover in 60% of cases, but develop either RPGN or chronic renal disease in the remaining 40%.
2. **Goodpasture syndrome** (anti-GBM disease) is due to the production of antibodies directed against basement membrane (anti-GBM antibodies), which results in damage of the lungs and the kidneys. The Goodpasture antigen is the noncollagenous component of type IV collagen.
 - a. **Clinical features.** The peak incidence of Goodpasture is ages 20 to 40, and males are affected more frequently than females. Pulmonary involvement typically precedes the renal disease, typically presenting with pulmonary hemorrhage and recurrent hemoptysis. Most patients will also later develop RPGN.
 - b. **Renal biopsy findings.** Light microscopy shows hypercellularity, crescents, and fibrin deposition in glomeruli. Immunofluorescence shows a smooth and linear pattern of IgG and C3 in the glomerular basement membrane (GBM). By electron microscopy, there are no deposits, but there is glomerular basement membrane disruption.
 - c. Even with **treatment** (plasma exchange, steroids, and cytotoxic drugs), the prognosis is poor, because of risks of severe and life-threatening pulmonary hemorrhage and of RPGN leading to renal failure. Early aggressive treatment may prevent end-stage renal failure.
3. **Rapidly progressive glomerulonephritis (RPGN)**, also called crescentic glomerulonephritis, causes rapid progression to severe renal failure in weeks or months
 - a. **Clinical settings.** RPGN can occur following Goodpasture syndrome; following other forms of glomerulonephritis (post-streptococcal, SLE, Berger disease); in association with vasculitis (i.e., Wegner granulomatosis); or be idiopathic.
 - b. **Renal biopsy.** Light microscopy shows hypercellular glomeruli with crescent formation in Bowman space. Immunofluorescence may show variable results, including granular or linear deposits of immunoglobulin and

Note

The characteristic finding in RPGN is the formation of crescents within Bowman space. The crescents are composed of fibrin, parietal epithelial cells, monocytes, and macrophages.

complement. Electron microscopy may also have variable results, which may or may not include electron-dense deposits; glomerular basement membrane disruption and discontinuity are commonly seen.

- c. The **prognosis** is poor with rapid progression to acute renal failure and end-stage renal disease.



© Katsumi M. Miyai, M.D., Ph.D.;
Reagents of the University of California. Used with permission.

Figure 16-3. Crescent formation in rapidly progressive glomerulonephritis, as seen with trichrome stain

4. **IgA nephropathy** (Berger disease) is the most common cause of glomerulonephritis in the world, being particularly common in France, Japan, Italy, and Austria. It affects children and young adults (mostly males).
- Clinical features.** IgA nephropathy is characterized by recurrent gross hematuria (a predominately nephritic presentation), whose onset may follow a respiratory infection. IgA nephropathy can be associated with celiac sprue and Henoch-Schönlein purpura.
 - The **pathogenesis** is unknown, but may be related to a possible entrapment of circulating immune complexes with activation of the alternate complement pathway; it may also be related to a genetic predisposition.
 - Renal biopsy.** Light microscopy may show normal glomeruli or mesangial proliferation. Immunofluorescence shows mesangial deposits of IgA and C3. Electron microscopy shows mesangial immune complex deposits.
 - Prognosis.** Many cases slowly progress to renal failure over 25 years.
5. **Membranoproliferative glomerulonephritis** (MPGN) is a form of glomerular disease that affects both the glomerular mesangium and the basement membranes; it occurs in two types, Type I and Type II (dense deposit disease).
- The **clinical presentation** is variable, and may be nephritic, nephrotic, or mixed. MPGN may be secondary to many systemic disorders (systemic lupus erythematosus, endocarditis), chronic infections (HBV, HCV, HIV), and malignancies (chronic lymphocytic leukemia).
 - Laboratory studies** show decreased serum C3 and the presence of C3 nephritic factor (MPGN type II).
 - Light microscopy** demonstrates a lobulated appearance of the glomeruli due to mesangial and endothelial cell proliferation and/or deposition of subendothelial immune complex deposits. Splitting of the basement membrane (“tram-tracking”) may be seen with a silver or periodic acid-Schiff (PAS) stain.

In a Nutshell

Henoch-Schönlein Purpura

- Systemic childhood disorder
- Onset often follows URI
- IgA nephropathy
- Abdominal pain
- GI bleeding
- Arthralgia
- Palpable purpura on legs and buttock

Note

Most patients with MPGN type II disease have an autoantibody called C3 nephritic factor. This antibody stabilizes C3 convertase, which leads to enhanced degradation and low serum levels of C3.

Note**“Tram-Tracking”**

This double contour appearance is caused by the splitting of the GBM by extension of the mesangial cell processes into the capillary loop.

- d. **Immunofluorescence** in type I MPGN shows a granular pattern of C3 often with IgG, C1q, and C4; in type II, immunofluorescence shows a granular and linear pattern of C3.
 - e. **Electron microscopy** in type I shows subendothelial and mesangial immune complex deposits, and in type II shows dense deposits within the glomerular basement membrane.
 - f. **Prognosis.** MPGN typically has a slowly progressive course, resulting in chronic renal failure over the course of 10 years. There is a high incidence of recurrence in transplants.
6. **Alport syndrome** is a rare X-linked disorder caused by a defect in type IV collagen that is characterized by hereditary nephritis, hearing loss, and ocular abnormalities. The most common mutation causing Alport syndrome is in the COL4A5 gene coding for the alpha-5 chain of type 4 collagen.
- a. **Clinical features.** Gross or microscopic hematuria begins in childhood. Hearing loss (leading to sensorineural deafness) and various ocular abnormalities of the lens and cornea can occur. Alport syndrome is a progressive disease that ultimately results in renal failure.
 - b. **Electron microscopy** shows alternating thickening and thinning of basement membrane with splitting of the lamina densa.

PRIMARY GLOMERULOPATHIES (NEPHROTIC)

1. **Membranous glomerulonephritis** is a common cause of nephrotic syndrome in adults.
 - a. **Etiology.** Most cases (85%) are idiopathic. Membranous glomerulonephritis may also be caused by drugs (penicillamine), infections (hepatitis virus B and C, syphilis, etc.), and systemic diseases (SLE, diabetes mellitus, etc.). It has also been associated with malignant carcinomas of the lung and colon, and there may be a genetic predisposition.
 - b. **Renal biopsy.** Light microscopy shows diffuse thickening of the capillary walls. Basement membrane projections (“spikes”) are seen on silver stains. Immunofluorescence shows a granular and linear pattern of IgG and C3. Electron microscopy shows subepithelial deposits along the basement membranes with effacement of podocyte foot processes.
 - c. The **clinical course** is variable, and may lead to spontaneous remission; persistent proteinuria; or end-stage renal disease.
2. **Minimal change disease** (also called lipid nephrosis and nil disease) is the most common cause of nephrotic syndrome in children. The disease has peak incidence at ages 2 to 6.
 - a. The **diagnosis** is one of exclusion. Light microscopy shows normal glomeruli with lipid accumulation in proximal tubule cells (lipoid nephrosis). Immunofluorescence is negative, with no immune deposits being visualized. Electron microscopy shows effacement of epithelial (podocyte) foot processes, microvillous transformation, and no immune complex deposits.
 - b. **Clinical course.** The prognosis is excellent because treatment with corticosteroids produces a dramatic response in children. The majority have a complete recovery.
3. **Focal segmental glomerulosclerosis** is a very common cause of nephrotic syndrome that occurs in all ages, with African Americans being affected more frequently than Caucasians.
 - a. **Etiology.** The condition may be idiopathic (primary), or it may be related to a wide variety of predisposing conditions including loss of renal tissue;

pre-existing other glomerular diseases (such as IgA nephropathy); sickle cell anemia; heroin use; AIDS; or morbid obesity.

- b. **Renal biopsy.** Light microscopy shows focal segmental sclerosis and hyalinization of glomeruli; focal segmental glomerulosclerosis initially affects the glomeruli along the medullary border. Immunofluorescence shows IgM and C3 deposits in the sclerotic segments. Electron microscopy shows effacement of foot processes in nonsclerotic regions and increased mesangial matrix in sclerotic segments.
- c. **Clinical course.** There is frequently a poor response to steroids, with the overall prognosis being poor (most progressing to chronic renal failure), though children do better than adults. There is a high rate of recurrence in renal transplants.

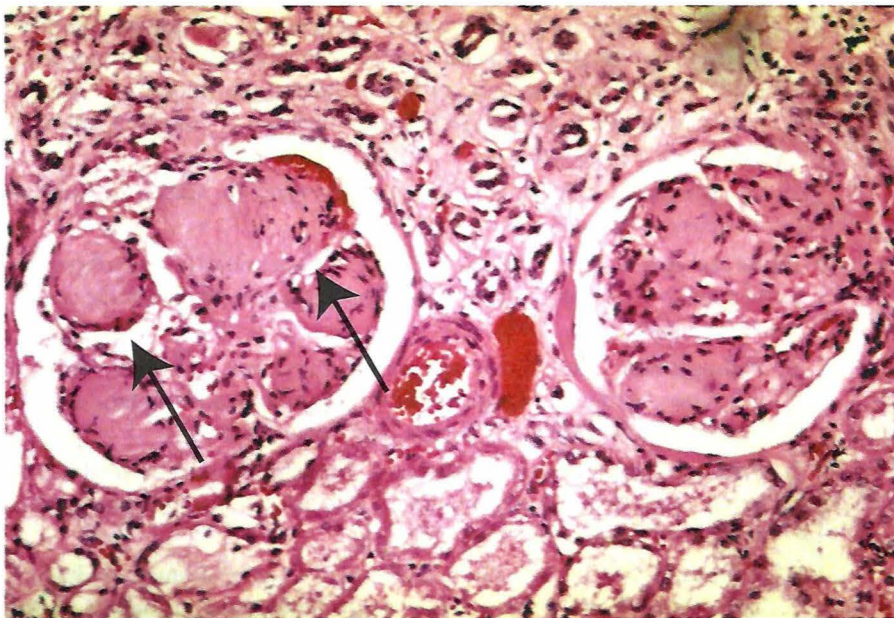
Note

Focal: only some of the glomeruli are affected

Segmental: only a portion of the glomerular tuft exhibits sclerosis

SECONDARY GLOMERULONEPHRITIS

1. **Secondary glomerulonephritis** refers to glomerular disease that is secondary to other disease processes.
2. **Diabetes** causes nodular glomerulosclerosis, hyaline arteriosclerosis, and diabetic microangiopathy. Clinically, diabetic patients may develop microalbuminuria that can progress to nephrotic syndrome.



© cdc.gov. Used with permission.

Figure 16-4. Sclerotic nodules (arrows) of nodular glomerulosclerosis (Kimmelstiel-Wilson syndrome), kidney

3. **Systemic lupus erythematosus** can cause a wide variety of patterns of damage to the kidney with clinical features that can include hematuria, nephritic syndrome, nephrotic syndrome, hypertension, and renal failure.

CHRONIC GLOMERULONEPHRITIS

1. **End-stage renal disease** is the final stage of many forms of glomerular disease and is characterized by progressive renal failure, uremia, and ultimately death.

2. **Clinical features** include anemia, anorexia, and malaise; and proteinuria, hypertension, and azotemia. Urinalysis shows broad, waxy casts.
3. On **pathologic examination**, the kidneys are grossly small and shrunken; microscopic examination shows hyalinization of glomeruli, interstitial fibrosis, atrophy of tubules, and a lymphocytic infiltrate.
4. **Treatment** is with dialysis and renal transplantation.

DISEASES OF THE TUBULES AND INTERSTITIUM

1. **Acute tubular necrosis (ATN)** is acute renal failure associated with potentially reversible injury to the tubular epithelium.
 - a. **Clinical features.** ATN is the most common cause of acute renal failure in the United States. It is characterized by oliguria with elevation of blood urea nitrogen (BUN) and creatinine; metabolic acidosis and hyperkalemia; and dirty brown granular casts and epithelial casts on urinalysis.
 - b. **Ischemic acute tubular necrosis** is the most common cause of acute tubular necrosis. The condition is due to decreased blood flow caused by severe hemorrhage, severe renal vasoconstriction, hypotension, dehydration, or shock.
 - c. **Nephrotoxic acute tubular necrosis** has a large number of causes, including drugs (e.g., polymyxin, methicillin, gentamicin, sulfonamides); radiographic contrast agents; heavy metals (e.g., mercury, lead, gold); organic solvents (e.g., carbon tetrachloride, chloroform, methyl alcohol); ethylene glycol (antifreeze); mushroom poisoning; phenol; pesticides; and myoglobin.
 - d. The **prognosis** is excellent if the patient survives the disease responsible for causing the necrosis.
2. **Acute and chronic pyelonephritis** refer to bacterial infections involving the renal pelvis, tubules, and interstitium. Pyelonephritis affects females much more than males.
 - a. **Pathogenesis.** Ascending infection is the most common route of infection. Causative organisms include gram-negative enteric bacilli, *Escherichia coli*, *Proteus*, *Klebsiella*, and *Enterobacter*.
 - b. **Predisposing factors** include urinary obstruction, vesicoureteral reflux, pregnancy, urethral instrumentation, diabetes mellitus, benign prostatic hypertrophy, and other renal pathology.
 - c. **Symptoms** can include fever, chills, and malaise; dysuria, frequency, and urgency; and costovertebral angle tenderness. Urinalysis shows pyuria and white blood cell casts.
 - d. **Microscopically**, the kidney shows acute inflammation of the interstitium and tubules, or chronic inflammation with fibrosis (which may progress to renal failure).
3. **Tubulointerstitial nephritis** is an acute or chronic inflammation of tubules and interstitium. It can be due to many causes, including medications, infections, acute pyelonephritis, systemic lupus erythematosus, lead poisoning, urate nephropathy, or multiple myeloma.
4. **Analgesic nephropathy** is the most common cause of chronic drug-induced tubular interstitial nephritis. It may cause renal papillary necrosis, hypertension, chronic renal failure, and transitional cell carcinoma of the renal pelvis and bladder.

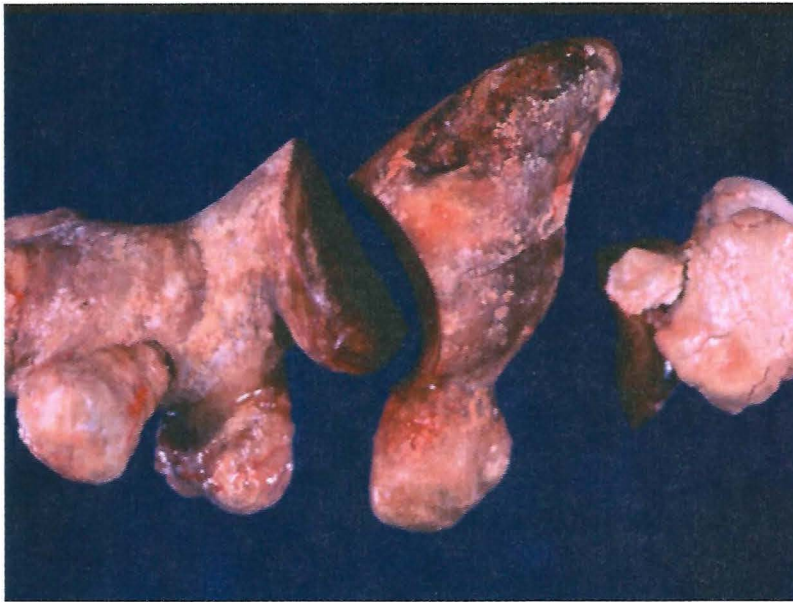Clinical Correlate

It may be difficult to distinguish cystitis from pyelonephritis. The presence of fever, costovertebral angle tenderness, and WBC casts in the urine are helpful clues to the diagnosis of pyelonephritis.

5. **Urate nephropathy** is due to a deposition of urate crystals (secondary to leukemia treatment, lead poisoning, and gout) in renal tubules and interstitium. It may produce acute renal failure.

UROLITHIASIS

1. **Renal calculi** occur in up to 6% of the population; men are affected more often than women.
 - a. **Stone composition.** Most (75%) stones are calcium oxalate stones. Magnesium ammonium phosphate (“struvite”) stones are associated with infection by urea-splitting bacteria (proteus), and these stones often form large staghorn calculi. Uric acid stones are seen in gout, leukemia, and in patients with acidic urine. Cystine stones are uncommon.



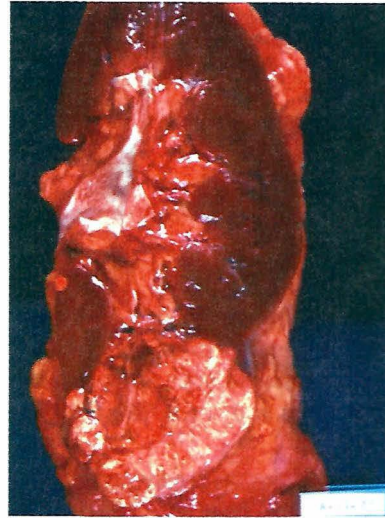
© Katsumi M. Miyai, M.D., Ph.D.; Regents of the University of California.
Used with permission.

Figure 16-5. Struvite stone forming staghorn calculi

- b. **Pathology.** Most stones are unilateral stones that are formed in the calyx, pelvis, and urinary bladder.
- c. **Clinical features.** Calcium stones are radiopaque and can be seen on x-ray. Renal colic may occur if small stones pass into the ureters. Stones may cause hematuria, urinary obstruction, and predispose to infection.
- d. **Treatment of stones** is with lithotripsy or endoscopic removal.

TUMORS OF THE KIDNEY

1. **Benign tumors** of the kidney.
 - a. **Cortical adenomas** are small, encapsulated cortical nodules measuring less than 3 cm; they are a common finding at autopsy.
 - b. **Angiomyolipomas** are hamartomas composed of fat, smooth muscle, and blood vessels, common in patients with tuberous sclerosis.
2. **Renal cell carcinoma (RCC)**, also called hypernephroma, is most common in ages 50 to 70, with males being affected more than females.



© Katsumi M. Miyai, M.D., Ph.D.;
Regents of the University of California.
Used with permission.

Figure 16-6. Renal Cell Carcinoma

- a. **Risk factors** include cigarette smoking; chronic analgesic use; asbestos exposure; chronic renal failure and acquired cystic disease; and von Hippel-Lindau disease (VHL tumor suppressor gene).
 - b. **Gross examination** typically demonstrates a large, solitary yellow mass found most commonly in the upper pole. Areas of necrosis and hemorrhage are commonly present. The tumor often invades the renal vein and may extend into the inferior vena cava and heart.
 - c. **Microscopically**, several histologic variants can occur, including clear cell carcinoma (most common type, polygonal cells with clear cytoplasm), papillary carcinoma, chromophobe carcinoma, and sarcomatoid renal cell carcinoma (poor prognosis).
 - d. **Clinical features.** The “classic” triad (10%) includes hematuria, palpable mass, and flank pain. A variety of paraneoplastic syndromes from ectopic hormone production can occur, including polycythemia (erythropoietin production), hypertension (renin production), Cushing syndrome (corticosteroid synthesis), hypercalcemia (PTH-like hormone), and feminization or masculinization (gonadotropin release). Renal cell carcinoma may also cause secondary amyloidosis, a leukemoid reaction, or eosinophilia.
 - e. There is a high incidence of **metastasis** on initial presentation.
3. **Wilms tumor** (nephroblastoma) typically presents as a large abdominal mass with peak age 2 to 5.
 - a. **Risk factors.** WAGR syndrome is the cluster of Wilms tumor, aniridia, genital anomalies, and mental retardation. Beckwith-Wiedemann syndrome has increased risk of childhood cancers (e.g., Wilms tumor, hepatoblastoma) and congenital anomalies (e.g., macroglossia, macrosomia, midline abdominal wall defects [e.g., omphalocele, umbilical hernia], ear creases or ear pits, neonatal hypoglycemia, and hemihypertrophy).
 - b. **Tumor suppressor genes** that are implicated in Wilms tumor include WT-1 (11p13) and WT-2 (11p15).
 - c. **Pathologically**, Wilms tumor grossly causes a large, solitary tan mass. Microscopic examination reveals a tumor containing three elements: metanephric blastema, epithelial elements (immature glomeruli and tubules), and stroma.

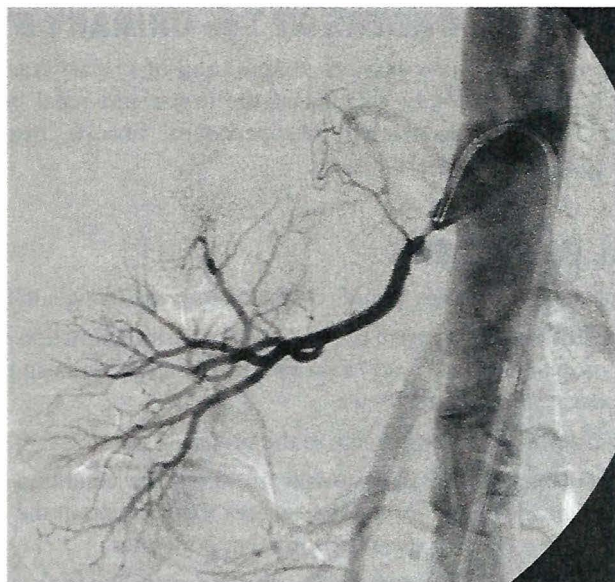
- d. **Treatment** is with surgery, chemotherapy, and radiation; this combination therapy yields an excellent prognosis, with long-term survival rate of 90%.
4. **Transitional cell carcinomas** can involve the renal pelvis as well as the urinary bladder.

CHRONIC RENAL FAILURE

1. **Chronic renal failure** is the end stage of many different renal diseases. It is characterized pathologically by bilaterally shrunken kidneys. Clinically, it causes progressive irreversible azotemia, normocytic anemia, platelet dysfunction, renal osteodystrophy, and hypertension.

VASCULAR DISORDERS OF THE KIDNEY

1. **Renal artery stenosis** of any etiology causes decreased blood flow to the involved kidney, with resulting secondary hypertension that is often not responsive to antihypertensive medications; treatment is usually surgical.



© Lily Chu - National Naval Medical Center Bethesda.
Used with permission.

Figure 16-7. Renal artery stenosis as demonstrated by angiogram

- a. **Atheromatous plaque** is the most common cause of renal artery stenosis.
- b. **Dysplastic lesions** (“fibromuscular dysplasia”) are an important additional cause of renal artery stenosis. The most common of these lesions include medial fibroplasia with aneurysms (most common form, causing alternating stenosis and aneurysms in “string of beads” pattern), perimedial fibroplasia (involves the outer media), and medial dissection (medial fibrosis with dissecting aneurysms); all three occur in middle-aged adults.
- c. **Miscellaneous diseases** that can affect the renal arteries (with or without stenosis) include congenital anomalies, Takayasu arteritis, and radiation injuries.

2. **Benign nephrosclerosis** is due to hypertension, and is characterized microscopically by hyaline arteriolosclerosis, tubular atrophy, interstitial fibrosis, and glomerulosclerosis. Laboratory findings include mild proteinuria, hematuria, and azotemia.
3. **Malignant (accelerated) hypertension** can damage the kidney, causing fibrinoid necrosis of arterioles, glomerulitis, and hyperplastic arteriosclerosis. Clinically, malignant hypertension causes cerebral edema, papilledema, retinal hemorrhage, intracerebral hemorrhage, and oliguric acute renal failure.
4. **Renal infarction** can be due to thrombi from the left side of the heart, atheroembolic disease, and vasculitis. Renal infarctions presents with sudden onset of flank pain and hematuria.
5. **Sickle cell anemia** can cause medullary infarctions due to blockage of blood flow in the medullary vessels, which can result in asymptomatic hematuria, loss of urine concentrating ability, renal papillary necrosis, and pyelonephritis.
6. **Diffuse cortical necrosis** can cause anuria; the condition can occur with obstetric emergencies and disseminated intravascular coagulation.

OBSTRUCTIVE DISORDERS OF THE URINARY SYSTEM

1. **Hydronephrosis** is a common complication of urinary tract obstruction that is characterized by dilation of the ureter and renal pelvis. Specific causes include renal stones, retroperitoneal fibrosis, benign prostatic hyperplasia, and cervical cancer.

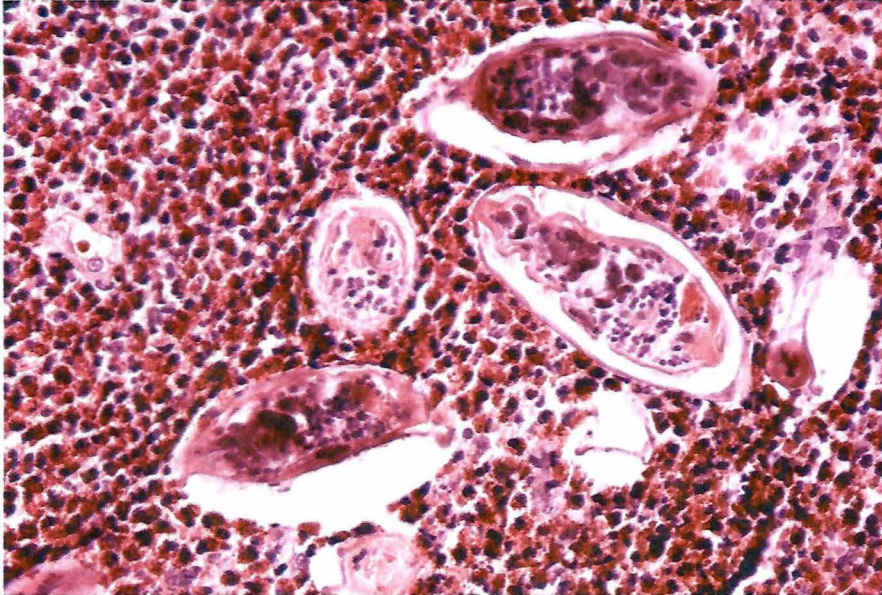
URETERAL DISORDERS

1. **Congenital anomalies** include double ureters and congenital megaureter.
2. **Ureteritis cystica** is a term used when chronic inflammation causes formation of small mucosal cysts in the ureter. This condition can predispose for adenocarcinoma of the ureter.
3. **Renal stones** commonly lodge in the ureters.
4. **Retroperitoneal fibrosis** is usually an idiopathic condition which causes severe fibrosis of the retroperitoneal area that can entrap the ureters. Some cases show sclerosing conditions in other body sites.
5. **Transitional cell carcinoma** is the most common ureteral carcinoma.

URINARY BLADDER PATHOLOGY

1. **Cystitis**
 - a. The **etiology** of cystitis varies, with important causes including organisms, notably from fecal flora (*Escherichia coli*, *Proteus*, *Klebsiella*, *Enterobacter*); radiation cystitis (may follow radiation therapy); and chemotherapy agents such as cyclophosphamide (hemorrhagic cystitis).
 - b. **Clinically**, cystitis affects females far more than males. Symptoms include frequency, urgency, dysuria, and suprapubic pain; systemic signs (e.g., fever, chills, malaise) are uncommon.
 - c. **Predisposing factors** include benign prostatic hypertrophy, bladder calculi, and cystocele.
2. **Urinary bladder tumors** are most commonly due to transitional cell carcinoma. There is an increasing incidence of urinary bladder tumors; males are affected more than females, and the peak incidence is between ages 40 and 60.

- a. **Risk factors** for bladder tumors include cigarette smoking and occupational exposure to azo dye production for transitional cell carcinoma (both due to 2-naphthylamine) as well as chronic bladder infection with *Schistosoma haematobium* for squamous cell carcinoma (Africa including Egypt and the Middle East).
- b. **Clinically**, bladder cancer usually presents with painless hematuria, but it may also cause dysuria, urgency, frequency, hydronephrosis, and pyelonephritis.



© cdc.gov. Used with permission.

Figure 16-8. Migratory eggs of *Schistosoma haematobium* surrounded by dense inflammation in the bladder wall, which predisposes to squamous cell carcinoma

- c. Bladder cancer has a high incidence of recurrence, and the **prognosis** depends on the tumor grade and stage.
 - d. **Other bladder tumors** include papillomas, adenocarcinoma, and embryonal rhabdomyosarcoma.
3. **Congenital anomalies of the bladder.** Exstrophy of the bladder is a developmental failure of the formation of the abdominal wall and bladder which leaves the bladder open at the body surface. Urachal cyst remnants may permit drainage of urine from a newborn's umbilicus, and may also be a cause of bladder adenocarcinoma.
 4. **Miscellaneous bladder conditions.**
 - a. **Acquired diverticuli** can complicate urinary tract outlet obstruction due to benign prostatic hyperplasia or other causes.
 - b. **Cystocele** is the term used for prolapse of the bladder into the vagina. It is common in middle-aged to elderly women.
 - c. **Cystitis cystica and glandularis** cause formation of small cysts and glands in the bladder mucosa related to chronic inflammation. It is associated with an increased risk of adenocarcinoma.

Chapter Summary

- Renal agenesis is the failure of one or both kidneys to develop. Bilateral renal agenesis is incompatible with life, but persons with unilateral agenesis may have adequate renal function. Other congenital anomalies of the kidney include hypoplasia, horseshoe kidney, and abnormal locations.
- Autosomal recessive polycystic kidney disease presents in infancy with progressive renal failure. Autosomal dominant polycystic kidney disease presents in adulthood with renal insufficiency, hematuria, and hypertension. The kidneys may be massively enlarged by the time of diagnosis. Renal dysplasia is the most common renal cystic disease in children and may cause a renal mass and renal failure. Medullary sponge kidney may cause a “Swiss cheese” appearance to the kidney and predisposes for infection, hematuria, and stones. Acquired polycystic disease is seen in renal dialysis patients. Simple retention cysts are common in adult kidneys.
- Glomerular diseases can present with either nephritic syndrome or nephrotic syndrome. Nephritic syndrome is characterized by hematuria, hypertension, azotemia, oliguria, and proteinuria less than 3.5 g/day. Nephrotic syndrome is characterized by severe proteinuria greater than 3.5 g/day, hypoalbuminemia, generalized edema, hyperlipidemia, and lipiduria.
- Acute post-streptococcal glomerulonephritis is associated with subepithelial immune complex deposits (subepithelial humps) by electron microscopy, occurs 2–4 weeks after a streptococcal infection of the throat or skin, and usually causes nephritic syndrome in children.
- Goodpasture syndrome is characterized by a smooth and linear pattern of IgG and C3 by immunofluorescence. It is the result of damage by autoantibodies to the basement membranes of the lungs and kidneys and is characterized clinically by pulmonary hemorrhage and rapidly progressive glomerulonephritis.
- Rapidly progressive glomerulonephritis is characterized microscopically by hypercellular glomeruli with crescent formation in Bowman space. Clinically, it features rapid progression to severe renal failure in weeks or months. It can be seen idiopathically or as a complication of renal disease due to Goodpasture syndrome, other forms of glomerulonephritis, or vasculitis.
- IgA nephropathy is characterized by mesangial deposits of IgA and C3, is the most common cause of glomerulonephritis worldwide, and tends to produce recurrent gross hematuria in children and young adults.
- Membranoproliferative glomerulonephritis is characterized microscopically by mesangial proliferation and basement membrane splitting and clinically may produce a nephritic pattern, a nephrotic pattern, or a mixed pattern.
- Membranous glomerulonephritis is characterized by diffuse thickening of capillary walls and basement membrane projections (spikes) visible with silver stains and is a common cause of nephrotic syndrome in adults.
- Minimal change disease is characterized by effacement of epithelial (podocyte) foot processes visible with electron microscopy and is the most common cause of nephrotic syndrome in children.

(Continued)

Chapter Summary (cont'd)

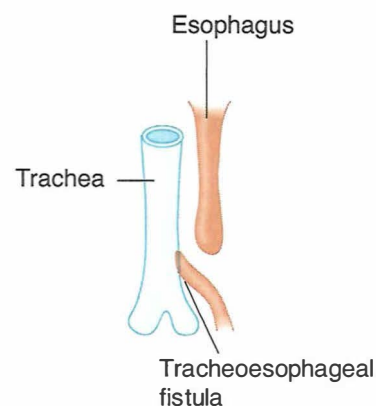
- Focal segmental glomerulosclerosis is characterized by focal segmental sclerosis and hyalinization of glomeruli and is a cause of nephrotic syndrome that can occur idiopathically or secondary to other glomerular diseases, sickle cell anemia, heroin use, AIDS, and morbid obesity.
- Secondary glomerulonephritis can be caused by diabetes mellitus and systemic lupus erythematosus.
- Chronic glomerulonephritis with small, shrunken kidneys is the final stage of many forms of glomerular diseases and is characterized by progressive renal failure, uremia, and ultimately death.
- Acute tubular necrosis is acute renal failure associated with reversible injury to the tubular epithelium and can be due to ischemia or nephrotoxins.
- Acute and chronic pyelonephritis is a bacterial infection involving the renal pelvis, tubules, and interstitium and is most commonly due to *Escherichia coli*, *Proteus*, *Klebsiella*, or *Enterobacter*.
- Renal calculi are common and may be composed of calcium oxalate, struvite, uric acid, or cystine. Clinically, stones may cause renal colic, hematuria, urinary obstruction, and a predisposition for infection.
- Benign tumors of the kidney include cortical adenomas and angiomyolipomas. Renal cell carcinoma tends to produce a large solitary renal mass in middle-aged to older adults and may cause hematuria, palpable mass, flank pain, and paraneoplastic syndromes.
- Wilms tumor is a childhood malignancy that presents with a large abdominal mass. It now has an excellent long-term prognosis.
- Vascular diseases of the kidney include renal artery stenosis (decreased blood flow to the kidney leading to secondary hypertension), benign nephrosclerosis (which develops secondary to ordinary hypertension), hyperplastic arteriosclerosis (which develops secondary to malignant hypertension), renal infarction (from emboli from the left side of the heart and secondary to sickle cell anemia), and diffuse cortical necrosis (secondary to obstetric emergencies and DIC).
- Ureteral disorders include congenital anomalies, ureteritis, cystic disease, stones lodged in a ureter, retroperitoneal fibrosis, and transitional cell carcinoma.
- Cystitis, or urinary bladder inflammation, can be due to bacterial infection, radiation, or chemotherapy; cystitis clinically produces frequency, urgency, dysuria, and suprapubic pain.
- Transitional cell carcinoma is the most common type of bladder tumor and usually presents with painless hematuria. Other bladder tumors include papillomas, adenocarcinoma, and embryonal rhabdomyosarcoma.
- Congenital anomalies of the bladder include exstrophy and urachal cyst remnants.
- Other bladder conditions include acquired diverticuli, cystocele, and cystitis cystica and glandularis.

ESOPHAGUS

1. **Congenital and mechanical disorders**
 - a. **Tracheoesophageal fistula** is a congenital connection between the esophagus and trachea that is often associated with esophageal atresia. It is often discovered soon after birth because of aspiration.
 - b. **Esophageal webs** are web-like protrusions of the esophageal mucosa into the lumen which typically present with dysphagia. Plummer-Vinson syndrome is a disease of middle-aged women characterized by esophageal webs, iron deficiency anemia, and increased risk of carcinoma. Schatzki rings are web-like narrowings at the gastroesophageal junction.
 - c. **Achalasia** is a failure of the lower esophageal sphincter (LES) to relax with swallowing. The etiology is unknown in most cases; in South America, achalasia may be caused by Chagas disease.
 - i. **Clinically**, the presentation is with progressive dysphagia. The esophagus is characteristically dilated proximal to the lower esophageal sphincter; barium swallow shows a “bird-beak” sign. Microscopically, there is a loss of ganglion cells in the myenteric plexus. Treatment is with lower esophageal sphincter balloon dilation or myotomy. There is an increased risk of esophageal carcinoma.
2. **Hematemesis and esophageal bleeding**
 - a. **Mallory-Weiss syndrome** has linear lacerations at the gastroesophageal junction that are produced by severe prolonged vomiting; the most common cause is acute alcohol ingestion and/or chronic alcoholism. Mallory-Weiss syndrome presents with hematemesis; it can be rarely complicated by esophageal rupture (Boerhaave syndrome).
 - b. **Esophageal varices** are dilated submucosal veins in the lower third of the esophagus, usually secondary to portal hypertension. The most common cause is cirrhosis. Clinically, the **presentation** is asymptomatic, though there is massive hematemesis when the varices are ruptured. Complications include potentially fatal hemorrhage. Treatment is generally with band ligation, sclerotherapy, or balloon tamponade.
3. **Esophagitis**
 - a. **Gastroesophageal reflux disease** (reflux esophagitis) is esophageal irritation and inflammation due to reflux of gastric secretions into the esophagus. Reflux typically presents with heartburn and regurgitation. Complications include bleeding; stricture; bronchospasm and asthma; and Barrett esophagus.
 - b. **Barrett esophagus** is a metaplasia of the squamous esophageal mucosa to a more protective columnar type (intestinal metaplasia). It occurs because of chronic exposure to gastric secretions, usually in the setting of gastroesophageal reflux disease (GERD). The incidence of Barrett esophagus is increasing, and there is an increased risk of dysplasia and esophageal adenocarcinoma.

Clinical Correlate

The most common type of tracheoesophageal fistula:



Clinical Correlate

Chagas disease: This tropical parasitic disease, common in South America, is caused by *Trypanosoma cruzi* and is transmitted by reduviid or “kissing” bugs. Chagas disease can cause:

- Romaña’s sign (swelling of the eyelids)
- Cardiomyopathy
- Megaesophagus and megacolon

In a Nutshell

Mallory-Weiss tears vs. esophageal varices:

Although both are associated with alcohol abuse and can present with hematemesis, Mallory-Weiss tears typically occur acutely as a result of retching/vomiting. Esophageal varices result from portal hypertension and will usually present with a more significant bleeding episode.

- i. The **endoscopic appearance** is of an irregular gastroesophageal (GE) junction with tongues of red granular mucosa extending up into the esophagus.

4. Esophageal carcinoma

- a. **Squamous cell carcinoma (SCC)** of the esophagus is the most common type of esophageal cancer in the world, but not in the United States. SCC affects males more than females, and African Americans more than Caucasians; the typical age is usually older than 50 years.
 - i. **Risk factors** are numerous, and include heavy smoking and alcohol use, achalasia, Plummer-Vinson syndrome, tylosis, and prior lye ingestion.
 - ii. The **presentation** varies. SCC of the esophagus is often asymptomatic until late in the course. When symptoms do develop, they may include progressive dysphagia; weight loss and anorexia; bleeding; or hoarseness or cough (advanced cancers).
 - iii. **Diagnosis** is by endoscopy with biopsy; treatment is with surgery, with the prognosis being poor.
- b. **Adenocarcinoma** of the esophagus is more common than SCC in the United States, and affects Caucasians more than African Americans. Adenocarcinoma arises in the distal esophagus; is associated with Barrett esophagus and dysplasia. The prognosis is poor.

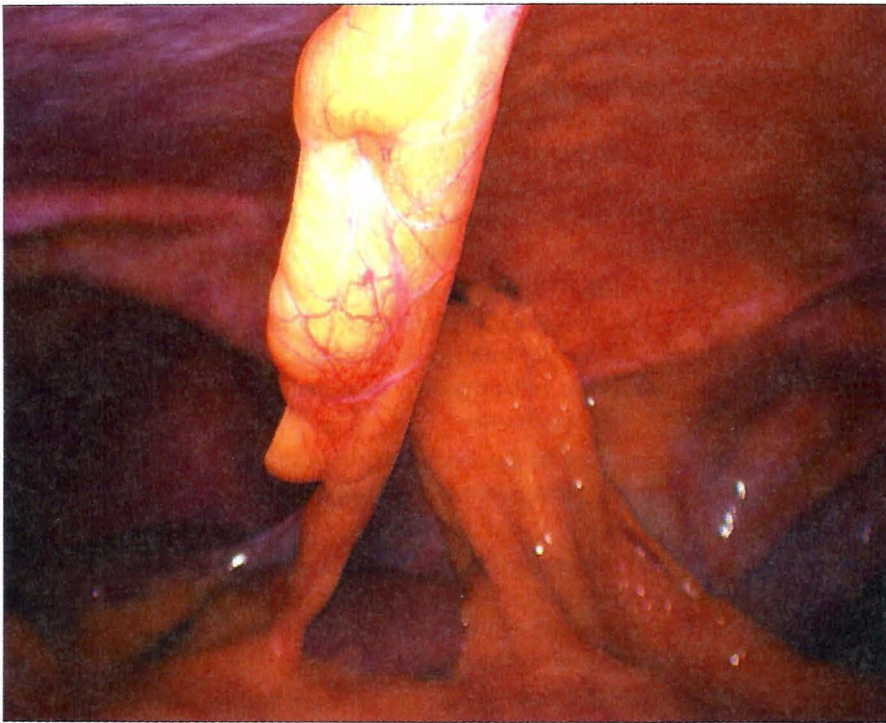
Clinical Correlate

Pyloric stenosis is congenital hypertrophy of the pylorus, which presents with projectile vomiting and a palpable abdominal “olive.”

STOMACH

1. Congenital disorders

- a. **Pyloric stenosis** is a congenital stenosis of the pylorus due to marked muscular hypertrophy of the pyloric sphincter, resulting in gastric outlet obstruction. It affects male infants more than females. It is associated with Turner and Edwards syndromes.
 - i. The **presentation** is with the onset of regurgitation and vomiting in the second week of life; waves of peristalsis are visible on the abdomen and there is a palpable oval abdominal mass. Treatment is surgical.
- b. **Congenital diaphragmatic hernia** occurs when a congenital defect is present in the diaphragm, resulting in herniation of the abdominal organs into the thoracic cavity. The stomach is the most commonly herniated organ due to left-sided congenital diaphragmatic hernia. Congenital diaphragmatic hernia is often associated with intestinal malrotation. It may be complicated by significant lung hypoplasia.



© wikimedia.org. Used with permission.

Figure 17-1. Omentum (background) pushed through a foramen of Morgagni (small parasternal openings) seen incidentally during laproscopic surgery (round ligament, foreground)

2. Hypertrophic gastropathy

- a. **Ménétrier disease** is a disease of middle-aged men characterized by enlarged rugal folds in the body and fundus; it is due to profound hyperplasia of surface mucous cells that is accompanied by glandular atrophy. Clinically, patients experience decreased acid production, protein-losing enteropathy, and increased risk of gastric cancer.
- b. **Zollinger-Ellison syndrome** occurs when a pancreatic gastrinoma-producing gastrin causes enlarged rugal folds with increased acid secretion, leading to multiple intractable peptic ulcers.

3. Acute inflammation and stress ulcers

- a. **Acute hemorrhagic gastritis** causes acute inflammation, erosion, and hemorrhage of the gastric mucosa, secondary to a breakdown of the mucosal barrier and acid-induced injury.
 - i. The **etiology** is diverse, with initiating agents including chronic aspirin or NSAID use, alcohol use, smoking, recent surgery, burns, ischemia, stress, uremia, and chemotherapy.
 - ii. Patients **present** with epigastric abdominal pain, or with gastric hemorrhage, hematemesis, and melena.
- b. **Gastric stress ulcers** are multiple, small, round, superficial ulcers of the stomach and duodenum. Predisposing factors are diverse, and include NSAID use, severe stress, sepsis, shock, severe burns or trauma (Curling ulcers), and elevated intracranial pressure (Cushing ulcers). There is a high incidence of gastric stress ulcers in intensive care unit (ICU) patients. These ulcers may be complicated by bleeding.

Clinical Correlate

The ability of *H. pylori* to produce urease is clinically used for detection by the [¹³C]-urea breath test and clofazimine (CLO) tests. Other methods of detection include biopsy (histologic identification is the gold standard) and serology.

4. **Chronic gastritis** is chronic inflammation of the gastric mucosa eventually leading to atrophy (chronic atrophic gastritis).
 - a. **Fundic type (type A) chronic gastritis** is an autoimmune atrophic gastritis that involves the body and the fundus. It is due to autoantibodies directed against parietal cells and/or intrinsic factor. This leads to loss of parietal cells, decreased acid secretion, increased serum gastrin (G-cell hyperplasia), and pernicious anemia (megaloblastic anemia due to lack of intrinsic factor and B₁₂ malabsorption).
 - i. **Pathologically**, there is grossly a loss of rugal folds in the body and fundus. Microscopically, fundic type chronic gastritis is characterized by mucosal atrophy with loss of glands and parietal cells, chronic lymphoplasmacytic inflammation, intestinal metaplasia, and increased risk of gastric carcinoma.
 - b. **Antral type (type B) chronic gastritis** (also called *Helicobacter pylori* gastritis) is the most common form of chronic gastritis in the United States.
 - i. The ***Helicobacter pylori* organisms** are curved, gram-negative rods that produce urease. The risk of infection increases with age, and infection is associated with chronic gastritis (type B), duodenal and gastric peptic ulcers, and gastric carcinoma.
 - ii. **Microscopically**, *H. pylori* organisms are visible in the mucous layer of the surface epithelium. Other microscopic features include foci of acute inflammation, chronic inflammation with lymphoid follicles, and intestinal metaplasia.
 - iii. Antral-type chronic gastritis predisposes for **gastric carcinoma**.
5. **Chronic peptic ulcer** (benign ulcer)

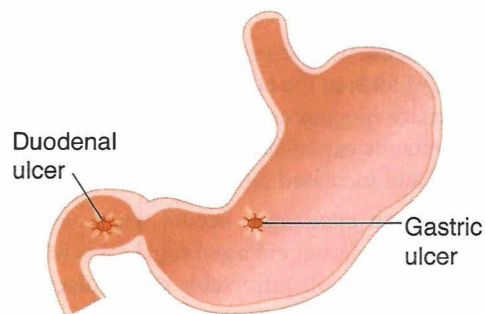


Figure 17-2. Types of ulcers

- a. **Peptic ulcers** are ulcers of the distal stomach and proximal duodenum caused by gastric secretions (hydrochloric acid and pepsin) and impaired mucosal defenses. Predisposing factors include chronic NSAID and aspirin use, steroid use, smoking, and *H. pylori* infection.
 - i. **Clinically**, diagnosis is by endoscopy with or without biopsy. Treatment includes acid suppression (H₂ blocker, proton pump inhibitor, etc.) and eradication of *H. pylori*.
 - ii. **Complications** include hemorrhage, iron deficiency anemia, penetration into adjacent organs, perforation (x-ray shows free air under the diaphragm), and pyloric obstruction.
- b. **Duodenal peptic ulcer** is more common than gastric peptic ulcer.
 - i. **Associations** include *H. pylori* (~100%); increased gastric acid secretion; increased rate of gastric emptying; blood group O; multiple

endocrine neoplasia (MEN) type I and Zollinger-Ellison syndromes; cirrhosis; and chronic obstructive pulmonary disease.

- ii. **Clinically**, most duodenal peptic ulcers are located in the anterior wall of the proximal duodenum. The classic presentation is with burning epigastric pain 1 to 3 hours after eating, which is relieved by food.
 - c. **Gastric peptic ulcer** is associated with *H. pylori* (75%). The ulcers are typically located in the lesser curvature of the antrum. Grossly, these are small (<3 cm), sharply demarcated ('punched out'), solitary ulcers with round or oval shape, overhanging margins, and radiating mucosal folds. The classic presentation is with burning epigastric pain, which worsens with eating.
6. **Gastric carcinoma** (malignant ulcer)
- a. **Epidemiology.** Gastric carcinoma is more common in Japan than in the United States, and has a decreasing incidence in the United States.
 - i. Dietary factors can be **risk factors**, and include smoked fish and meats, pickled vegetables, nitrosamines, benzpyrene, and decreased intake of fruits and vegetables. Other risk factors include *H. pylori* infection, chronic atrophic gastritis, smoking, blood type A, bacterial overgrowth in the stomach, prior subtotal gastrectomy, and Ménétrier disease.
 - ii. **Clinically**, gastric carcinoma is often (90%) asymptomatic until late in the course, when it can produce weight loss and anorexia. It can also present with epigastric abdominal pain mimicking a peptic ulcer, early satiety, and occult bleeding with iron deficiency anemia.
 - iii. **Pathology.** Gastric carcinoma is most commonly located in the lesser curvature of the antrum, and causes a large (>3 cm), irregular ulcer with heaped-up margins and a necrotic ulcer base. It may also occur as a flat or polypoid mass. Several histological types occur.
 - iv. The **intestinal histologic type** microscopically shows gland-forming adenocarcinoma.
 - v. The **diffuse type** of gastric carcinoma shows diffuse infiltration of stomach by poorly differentiated tumor cells, frequently numerous **signet-ring cells** (whose nuclei are displaced to the periphery by intracellular mucin), and **linitis plastica** (thickened "leather bottle"-like stomach) gross appearance.
 - vi. Gastric carcinomas may specifically **metastasize** to the left supraclavicular lymph node (Virchow sentinel node) and to the ovary (Krukenberg tumor).
 - vii. **Diagnosis** is by endoscopy with biopsy; treatment is with gastrectomy. The prognosis is poor, with overall 5-year survival of 20%.

SMALL AND LARGE INTESTINES

1. Mechanical obstruction

- a. **Volvulus** is a twisting of a segment of bowel on its vascular mesentery, resulting in intestinal obstruction and infarction. Volvulus is often associated with congenital abnormalities such as intestinal malrotation. Common locations include the sigmoid colon and small bowel; complications include infarction and peritonitis.
- b. **Intussusception** is the telescoping of a proximal segment of the bowel into the distal segment. It is most common in infants and children. In adults, intussusception may be associated with a mass or tumor; it presents with intestinal obstruction, abdominal pain, and "currant-jelly" stools. The intussuscepted segment can become infarcted.

Note

Acquired megacolon may be caused by Chagas disease or ulcerative colitis (toxic megacolon).

Bridge to Anatomy

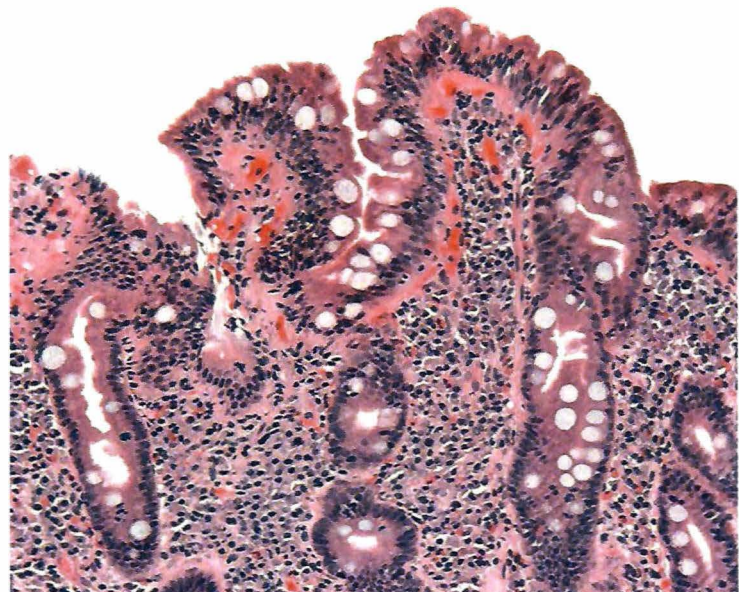
Auerbach plexus = myenteric ganglia

Meissner plexus = submucosal ganglia

- c. **Incarcerated hernia** is a segment of bowel that is imprisoned within a hernia; the condition can become complicated by intestinal obstruction and infarction.
- d. **Hirschsprung disease** (also called congenital aganglionic megacolon) is due to congenital absence of ganglion cells in the rectum and sigmoid colon, resulting in intestinal obstruction. The condition affects males more than females, and can be associated with Down syndrome.
 - i. Hirschsprung disease may **present** with delayed passage of meconium, or with constipation, abdominal distention, and vomiting.
 - ii. **Pathology.** Grossly, the affected segment is narrowed, and there is dilation proximal to the narrow segment (megacolon). Microscopically, there is an absence of ganglion cells in Auerbach and Meissner plexuses, and the diagnosis is established when rectal biopsy demonstrates the absence of ganglion cells.
 - iii. **Treatment** is by resection of the affected segment.

2. Malabsorption syndromes

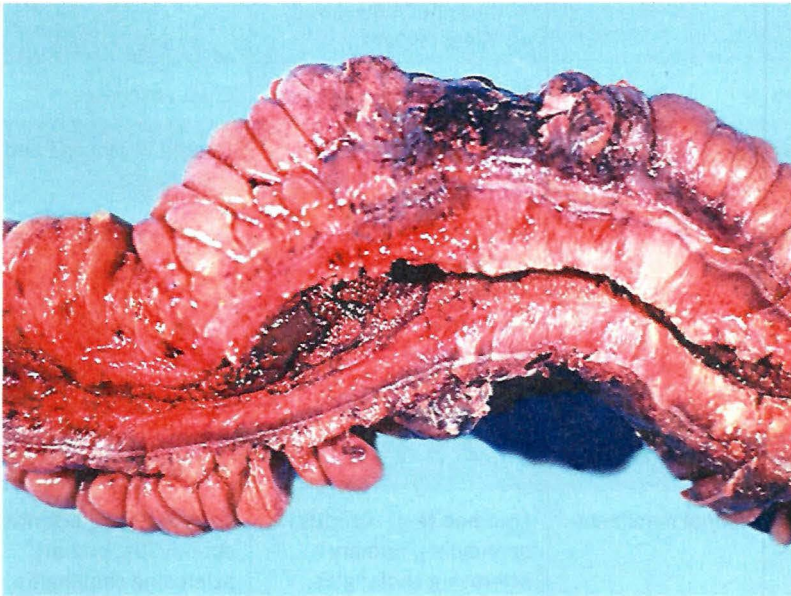
- a. **Celiac sprue** (also caused gluten-sensitive enteropathy and nontropical sprue) is due to hypersensitivity to gluten (and gliadin), resulting in loss of small bowel villi and malabsorption. HLA-B8, DR3, and DQ have been linked to celiac sprue.
 - i. **Microscopic examination** demonstrates a loss of villi, with increased intraepithelial lymphocytes and increased plasma cells in the lamina propria.
 - ii. **Clinically,** Celiac sprue usually presents in childhood with malabsorption. Symptoms can include abdominal distention, bloating, and flatulence, along with diarrhea, steatorrhea, and weight loss. The disease is associated with dermatitis herpetiformis. Treatment is dietary restriction of gluten.
- b. **Tropical sprue** is a malabsorptive disease of unknown etiology (infection and/or nutritional deficiency) affecting travelers to tropical regions, such as the Caribbean and South America. The microscopic appearance is similar to celiac sprue. Treatment is with antibiotics, vitamin B₁₂, and folate.



© wikimedia.org. Used with permission.

Figure 17-3. Celiac disease

- c. **Whipple disease** is a rare infectious disease involving many organs, including small intestines, joints, lung, heart, liver, spleen, and central nervous system. Whipple disease typically affects Caucasian males aged 30 to 50.
 - i. The infecting **organism** is *Tropheryma whipplei*, and microscopically, the small bowel lamina propria is filled with macrophages stuffed with the PAS-positive, gram-positive, rod-shaped bacilli.
 - ii. **Clinically**, patients present with malabsorption, weight loss, and diarrhea. Treatment is with antibiotics.
3. **Inflammatory bowel disease (IBD)**
- a. The **three major categories** of inflammatory bowel disease are **Crohn's disease (CD)**, also called regional enteritis, **ulcerative colitis (UC)**, and **colitis of indeterminate type**.



© Katsumi M. Miyai, M.D., Ph.D.; Regents of the University of California.
Used with permission.

Figure 17-4. Narrowed Colon Segment in Crohn's disease

- b. **Epidemiology.** Females develop IBD more frequently than males, and Caucasians more frequently than non-Caucasians. The age distribution varies with the disease; Crohn's disease has a bimodal distribution with peaks at ages 10 to 30 and 50 to 70, while ulcerative colitis peaks at ages 20 to 30. The incidence of inflammatory bowel disease is increasing; ulcerative colitis is more common than Crohn's disease.
- c. **Clinically**, the presentation of IBD can be with episodes of bloody diarrhea or stools with mucus, crampy lower abdominal pain, or fever. Crohn's disease may cause perianal fistulas, present with malabsorption, or mimic appendicitis. Extraintestinal manifestations can also be a presentation, and are seen more commonly in ulcerative colitis than in Crohn's disease.
- d. The **diagnosis** of IBD is one of exclusion, with tissue to be studied being obtained by endoscopic biopsy.

Table 17-1. Crohn's Disease Versus Ulcerative Colitis

	Crohn's Disease	Ulcerative Colitis
Most common site	Terminal ileum	Rectum
Distribution	Mouth to anus	Rectum → colon "back-wash" ileitis
Spread	Discontinuous/"skip"	Continuous
Gross features	<ul style="list-style-type: none"> ● Focal aphthous ulcers with intervening normal mucosa ● Linear fissures ● Cobblestone appearance ● Thickened bowel wall ● "Creeping fat" 	Extensive ulceration Pseudopolyps
Micro	Noncaseating granulomas	Crypt abscesses
Inflammation	Transmural	Limited to mucosa and submucosa
Complications	<ul style="list-style-type: none"> ● Strictures ● "String sign" on barium studies ● Obstruction ● Abscesses ● Fistulas ● Sinus tracts 	Toxic megacolon
Genetic association		HLA-B27
Extraintestinal manifestations	Common (e.g., arthritis, spondylitis, primary sclerosing cholangitis, erythema nodosum, pyoderma gangrenosum, uveitis)	Common (e.g., arthritis, spondylitis, primary sclerosing cholangitis, erythema nodosum, pyoderma gangrenosum, uveitis)
Cancer risk	Slight 1–3%	5–25%

Bridge to Anatomy

The splenic flexure of the colon receives blood from both the superior and inferior mesenteric arteries.

4. Miscellaneous conditions

- a. **Ischemic bowel disease** is due to decreased blood flow and ischemia of the bowel, secondary to atherosclerosis with thrombosis, thromboembolism, or reduced cardiac output from shock.
 - i. **Clinically**, ischemic bowel disease is most common in older individuals, and typically presents with abdominal pain and bloody diarrhea. The disease distribution tends to involve watershed areas (e.g., splenic flexure), and affected areas typically show hemorrhagic infarction. Treatment is with surgical resection, but the prognosis is poor, with over 50% mortality.
- b. **Hemorrhoids** are defined as tortuous, dilated submucosal veins caused by increased venous pressure. Risk factors include constipation and prolonged straining during bowel movements, pregnancy, and cirrhosis. **Complications** include painful thrombosis and streaks of bright red blood on hard stool.

- c. **Angiodysplasia** is defined as arteriovenous malformations of the intestines; it occurs in the cecum and right colon. It is common in individuals over age 55, **presenting** with multiple episodes of rectal bleeding. Angiodysplasia is associated with Osler-Weber-Rendu and CREST syndromes. Treatment is surgical resection.
- d. **Melanosis coli** is common with laxative abuse; it causes black pigmentation of the colon due to the ingestion of the laxative pigment by macrophages in the mucosal and submucosa. Melanosis coli can mimic colitis or malignancy.
- e. **Pseudomembranous colitis** (antibiotic-associated colitis) is an acute colitis characterized by the formation of inflammatory pseudomembranes in the intestines. It is usually due to *Clostridium difficile* infection (often brought on by a course of broad-spectrum antibiotics, especially clindamycin and ampicillin), but pseudomembranous colitis can also be due to ischemic bowel disease.
- Pathology.** Gross examination shows yellow-tan mucosal membranes. Microscopic examination shows superficial colonic necrosis with an overlying pseudomembranes; the pseudomembranes are mushroom-shaped inflammatory exudates composed of neutrophils, mucin, fibrin, and necrotic cellular debris.
 - Clinically,** the presentation is with diarrhea, fever, and abdominal cramps, and the diagnosis is established with detection of *C. difficile* toxin in the stool. Treatment of clostrial pseudomembranous colitis is with vancomycin or metronidazole.
- f. **Appendicitis** is most commonly caused by obstruction of the appendix by a fecalith. Appendicitis often starts with periumbilical pain that subsequently localizes to the right lower quadrant. Nausea, vomiting, and fever may also be present. Laboratory studies show an elevated white blood cell count. A complication is appendiceal rupture leading to peritonitis.
- Pathology.** Grossly, a fibrinopurulent exudate may be seen on the appendiceal serosa; microscopically, neutrophils are present within the mucosa and muscular wall (muscularis propria) of the appendix.
5. **Diverticula**
- Meckel diverticulum** is a congenital small bowel diverticulum due to persistence of a remnant of the vitelline (omphalomesenteric) duct.
 - Rule of 2s:**
 - 2% of the normal population
 - 2 feet from the ileocecal valve
 - 2 cm in length
 - 2 years old or younger at the time of diagnosis
 - 2% of carcinoid tumors occur in a Meckel diverticulum.
 - Clinically, most Meckel diverticula are asymptomatic, but they may contain rests of ectopic gastric mucosa and present with intestinal bleeding.
 - Colonic diverticulosis** refers to acquired outpouchings of the bowel wall, characterized by herniation of the mucosa and submucosa through the muscularis propria (pseudodiverticulum). Colonic diverticulosis is extremely common in the United States, and the incidence increases with age. The major risk factor is low-fiber diet, which leads to increased intraluminal pressure; the most common location is in the sigmoid colon.
 - Clinically,** the presentation varies, with many cases being asymptomatic and picked up on screening colonoscopy. When symptomatic,

In a Nutshell

Osler-Weber-Rendu Syndrome

- a.k.a. Hereditary hemorrhagic telangiectasia
- Autosomal dominant
- Telangiectasias of skin and mucous membranes
- Common on lips, tongue, and fingertips
- May develop iron deficiency anemia

Note

Given that only two layers of the bowel wall are involved, these acquired outpouchings are technically pseudodiverticula.

Clinical Correlate

It is estimated to take roughly 10 years to progress from adenoma to carcinoma, which makes colonoscopy an effective tool for identifying and removing adenomas before they progress to an invasive malignancy.

colonic diverticulosis can cause constipation alternating with diarrhea, left lower quadrant abdominal cramping and discomfort, occult bleeding and an iron deficiency anemia, or lower gastrointestinal tract hemorrhage.

ii. **Complications** include diverticulitis, fistulas, and perforation with accompanying peritonitis.

6. Neoplasia

a. **Adenomatous colonic polyps** are benign neoplasms of the colonic mucosa that have the potential to progress to colonic adenocarcinoma. They are commonly asymptomatic, but may lead to occult bleeding and iron deficiency anemia.

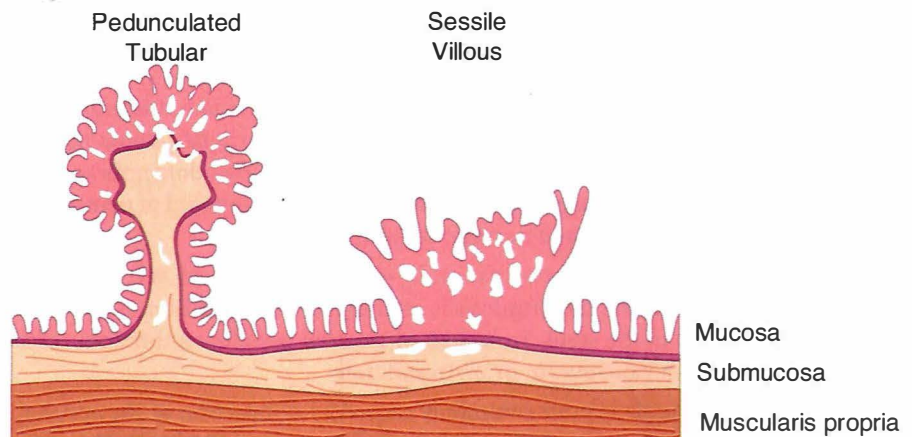


Figure 17-5. Adenomas

- i. **Prognostic features** include tubular versus villous histology, pedunculated versus sessile appearance, size of polyps, and degree of dysplasia. Diagnosis is suspected with hemoccult positive stools and is established with endoscopy.
- b. **Familial adenomatous polyposis (FAP)**, also called adenomatous polyposis coli (APC), is due to an autosomal dominant mutation of the APC gene on chromosome 5q21.
 - i. Affected individuals may develop **thousands of colonic adenomatous polyps**; the diagnosis is made with discovery of more than 100 adenomatous polyps on endoscopy. **Complications:** by age 40, virtually 100% will develop an invasive adenocarcinoma and increased risks for developing duodenal adenocarcinoma and adenocarcinoma of the papilla of Vater.
- c. **Gardner syndrome** is an autosomal dominant variant of familial adenomatous polyposis characterized by numerous colonic adenomatous polyps, multiple osteomas, fibromatosis, and epidermal inclusion cysts.
- d. **Turcot syndrome** is a rare variant of familial adenomatous polyposis characterized by numerous colonic adenomatous polyps and central nervous system tumors (gliomas).
- e. **Hereditary nonpolyposis colorectal cancer (HNPCC)**, also called Lynch syndrome is due to an autosomal dominant mutation of a DNA nucleotide mismatch repair gene that predisposes for colon cancer. It is associated with an increased risk of endometrial and ovarian carcinoma.
- f. **Peutz-Jeghers syndrome** is an autosomal dominant condition characterized by multiple hamartomatous polyps (primarily in the small

intestine); melanin pigmentation of the oral mucosa; and increased risk of cancer of the lung, pancreas, breast, and uterus.

- g. **Colonic adenocarcinoma** is the third most common tumor in terms of incidence and mortality in the United States.
- i. **Risk factors** are numerous, and include dietary factors (low fiber, low fruits/vegetables and high in red meat and animal fat); colon polyps (isolated adenomatous polyps, hereditary polyposis syndromes); and other colon disease (Lynch syndrome, ulcerative colitis).
 - ii. Multiple **mutations** are involved which may affect the APC gene, K-ras oncogene, DCC gene (deleted in colorectal cancer—a tumor suppressor gene [18q21- qter region] that is a cellular adhesion molecule), or p53 gene.

Table 17-2. Right-Sided Cancer Versus Left-Sided Cancer

	Right-Sided Cancer	Left-Sided Cancer
Gross	Polypoid mass	Circumferential growth producing a “napkin-ring” configuration
Barium studies	Polypoid mass	“Apple-core” lesion
Presentation	Bleeding <ul style="list-style-type: none"> ● Occult blood in stool ● Iron deficiency anemia 	Change in bowel habits <ul style="list-style-type: none"> ● Constipation or diarrhea ● Reduced caliber stools ● Obstruction

- iii. The **diagnosis** is suspected with hemocult positive stool, and established via endoscopy with biopsy.
- iv. **Disease management.** The pattern of spread includes lymphatic spread to mesenteric lymph nodes, with distant spread to liver, lungs, and bone. Staging is with the modified Dukes (Astler-Coller) staging system. Treatment can include surgical resection and chemotherapy (for metastatic disease); CEA levels can be used to monitor for disease recurrence.

Table 17-3. The Modified Dukes Staging System

Stage	Extent of Disease
A	Limited to the mucosa and submucosa
B1	Invasion into but not through the muscularis propria
B2	Invasion through the muscularis propria
C1	Positive lymph nodes; invasion into but not through the muscularis propria
C2	Positive lymph nodes; invasion through the muscularis propria
D	Distant metastasis

Note

Histologically, carcinoid tumors appear similar to other neuroendocrine tumors with nests of small uniform cells.

Bridge to Biochemistry

Serotonin is converted to 5-HIAA by monoamine oxidase.

- h. **Carcinoid tumors** are neuroendocrine tumors that often produce serotonin. Important locations for carcinoid tumors include the appendix (most common) and the terminal ileum. Metastasis to the liver may result in carcinoid heart disease.
- i. **Carcinoid syndrome** is characterized by diarrhea, cutaneous flushing, bronchospasm and wheezing, and fibrosis. The diagnosis is substantiated by demonstrating elevated urinary 5-HIAA (5-hydroxyindoleacetic acid).

Chapter Summary

- Congenital and mechanical disorders of the esophagus include tracheoesophageal fistula (associated with esophageal atresia and aspiration), esophageal webs (associated with iron deficiency anemia and increased risk of cancer), and achalasia (associated with increased risk of cancer). Achalasia is due to failure of the lower esophageal sphincter to relax with swallowing.
- Esophageal bleeding can be due to laceration at the gastroesophageal junction produced by severe vomiting (Mallory-Weiss syndrome), or esophageal varices that develop secondary to portal hypertension.
- Gastroesophageal reflux disease is esophageal irritation and inflammation due to reflux of gastric secretions into the esophagus. Barrett esophagus is metaplasia of the squamous esophageal mucosa to a more protective columnar type because of chronic exposure to gastric secretions.
- Esophageal carcinoma may be either squamous cell carcinoma or adenocarcinoma. Squamous cell carcinoma is the most common form in the world and is associated with heavy smoking, heavy alcohol use, achalasia, and Plummer-Vinson syndrome. Adenocarcinoma involves the distal esophagus and usually arises in areas of Barrett esophagus.
- Pyloric stenosis is a congenital stenosis of the pylorus due to marked muscular hypertrophy of the pyloric sphincter, resulting in gastric outlet obstruction. Congenital diaphragmatic hernia is a congenital defect in the diaphragm, resulting in herniation of the abdominal organs into the thoracic cavity.
- Menetrier disease is a form of hypertrophic gastropathy with enlarged rugal folds that can produce decreased acid production, a protein-losing enteropathy, and increased risk of cancer. Zollinger-Ellison syndrome is a form of hypertrophic gastropathy with enlarged rugal folds that occurs secondary to gastrin stimulation by a pancreatic gastrinoma.
- Acute hemorrhagic gastritis is acute inflammation, erosion, and hemorrhage of the gastric mucosa due to a breakdown of the mucosal barrier and acid-induced injury. Gastric stress ulcers are multiple, small, round, superficial ulcers of the stomach and duodenum.
- Chronic gastritis is a chronic inflammation of the gastric mucosa resulting in eventual atrophy. Chronic gastritis is subdivided into a fundic type, which is related to autoantibodies to parietal cells and/or intrinsic factor, and an antral type, which is related to *Helicobacter pylori* gastritis.
- Peptic ulcers are ulcers of the distal stomach and proximal duodenum caused by gastric secretions (hydrochloric acid and pepsin) and impaired mucosal defenses. Duodenal peptic ulcers are more common than gastric ulcers.
- Gastric carcinomas tend to be asymptomatic until late in their course and may show a variety of histologic patterns.

(Continued)

Chapter Summary (cont'd)

- Volvulus is twisting of a segment of bowel on its vascular mesentery, resulting in intestinal obstruction and infarction. Intussusception is telescoping of a proximal segment of bowel into the distal segment. Incarcerated hernia is a segment of bowel that becomes imprisoned within a hernia. Hirschsprung disease is a congenital absence of ganglion cells in the rectum and sigmoid colon resulting in intestinal obstruction.
- Celiac sprue is a hypersensitivity to gluten, resulting in loss of small bowel villi and malabsorption. Tropical sprue is a malabsorptive disease of unknown etiology affecting travelers to tropical regions, such as the Caribbean and South America. Whipple disease is a rare infectious disease involving many organs, including small intestines, joints, lung, heart, liver, spleen, and CNS.
- Inflammatory bowel disease includes Crohn disease, ulcerative colitis, and colitis of indeterminate type. Crohn disease has “skip” lesions, has transmural involvement with formation of granulomas, and tends to form fistulas, abscesses, and sinuses. In contrast, ulcerative colitis is confined to the rectum and colon, has inflammation limited to the mucosa and submucosa with crypt abscess, is more likely to have extraintestinal manifestations, and can cause toxic megacolon.
- Ischemic bowel disease is the result of decreased blood flow and ischemia of the bowel secondary to atherosclerosis with thrombosis, thromboembolism, or reduced cardiac output from shock. Hemorrhoids are tortuous dilated submucosal veins caused by increased venous pressure. Angiodysplasia is arteriovenous malformation of the intestines. Melanosis coli is a black pigmentation of the colon that is common with laxative abuse. Pseudomembranous colitis is characterized by formation of inflammatory pseudomembranes in the intestine following infection by *Clostridium difficile*, and/or ischemic bowel disease.
- Meckel diverticulum is a congenital small bowel diverticulum that is a remnant of the vitelline duct. Colonic diverticulosis is a common condition among the elderly population and features acquired outpouchings of the bowel wall, characterized by herniation of the mucosa and submucosa through the muscularis propria.
- Adenomatous colonic polyps are benign neoplasms of the colonic mucosa that have the potential to progress to colonic adenocarcinoma. Familial adenomatous polyposis is a genetic condition in which patients develop thousands of colonic adenomatous polyps and have a virtually 100% chance of developing colon cancer by age 40 unless the affected colon is resected. Gardner syndrome is a variant of familial adenomatous polyposis with associated osteomas, fibromatosis, and epidermal inclusion cysts. Turcot syndrome is a rare variant of familial adenomatous polyposis associated with CNS gliomas. Hereditary nonpolyposis colorectal cancer has increased risks of colon, endometrial, and ovarian cancers, but it is not associated with multiple adenomatous polyps. Peutz-Jeghers syndrome has multiple hamartomatous polyps with increased risk of cancers of the lung, pancreas, breast, and uterus, but not colon.
- Colonic adenocarcinoma is the third most common cancer and a leading cause of cancer mortality in the United States. It tends to produce a polypoid mass when it involves the right side of the colon and a napkin ring lesion when it involves the left side. The Dukes system is used for staging colon cancer.
- Carcinoid tumors are neuroendocrine tumors that can involve the appendix and terminal ileum and may produce carcinoid syndrome with diarrhea, flushing, bronchospasms, fibrosis, and sometimes carcinoid heart disease.

INFLAMMATION OF THE PANCREAS

1. **Acute pancreatitis** is an acute inflammation arising from injury to the exocrine portion of the pancreas. The etiology is diverse, and includes gallstones, alcohol, hypercalcemia, drugs, shock, infections, trauma, and scorpion stings. Pancreatic acinar cell injury results in activation of pancreatic enzymes and enzymatic destruction of the pancreatic parenchyma.
 - a. **Clinical features.** Acute pancreatitis typically presents with stabbing epigastric abdominal pain radiating to the back; it may also present with shock. Laboratory studies show elevation of serum amylase and lipase. Complications include acute respiratory distress syndrome (ARDS); disseminated intravascular coagulation (DIC); pseudocyst; pancreatic calcifications; and hypocalcemia. Severe cases have a 30% mortality rate.
 - b. On **pathologic examination**, the pancreas grossly shows focal hemorrhage and liquefaction accompanied by chalky, white-yellow fat necrosis of adjacent adipose tissue. Microscopically, the tissue shows liquefactive necrosis of the pancreatic parenchyma with acute inflammation and enzymatic fat necrosis. Necrosis of blood vessels causes hemorrhage.
2. **Chronic pancreatitis** refers to chronic inflammation, atrophy, and fibrosis of the pancreas secondary to repeated bouts of pancreatitis. Many patients are middle-age male alcoholics. On pathologic examination, the pancreas is grossly firm, white, and fibrotic. Microscopically, there is extensive fibrosis with parenchymal atrophy and chronic inflammation. Clinically, chronic pancreatitis can produce abdominal pain, pancreatic insufficiency and malabsorption, pancreatic calcifications, pseudocyst, and secondary diabetes mellitus (late complication).

DIABETES MELLITUS

1. **Diabetes mellitus** is a chronic systemic disease characterized by insulin deficiency or peripheral resistance, resulting in hyperglycemia and nonenzymatic glycosylation of proteins.
2. The **diagnosis** is established by demonstrating fasting glucose >126 mg/dL on at least two separate occasions or by a positive glucose tolerance test. HbA1c ≥ 6.5 percent.
3. **Insulin-dependent diabetes mellitus** (IDDM), also called type 1, juvenile onset diabetes, and brittle diabetes, represents 10% of cases of diabetes. It affects children and adolescents, usually younger than age 20. Risk factors include Northern European ancestry and specific HLA types (DR3, DR4, and DQ).
 - a. The **pathogenesis** is a lack of insulin due to autoimmune destruction of β cells (type IV hypersensitivity reaction). Patients are absolutely dependent on insulin to prevent ketoacidosis and coma. It is thought that this form of diabetes is caused by an autoimmune reaction triggered by an infection (Coxsackie B virus) in a genetically susceptible individual.

Clinical Correlate

Acute Respiratory Distress Syndrome:

ARDS is a life-threatening complication of acute pancreatitis due to release of phospholipase which circulates through the bloodstream and damages alveolar capillary membranes in the lungs.

Clinical Correlate

Measurement of glycosylated hemoglobin (HbA1c) is an excellent measurement of long-term exposure to hyperglycemia.

Clinical Correlate

Sulfonylureas enhance insulin secretion only in type 2 diabetes.

Clinical Correlate

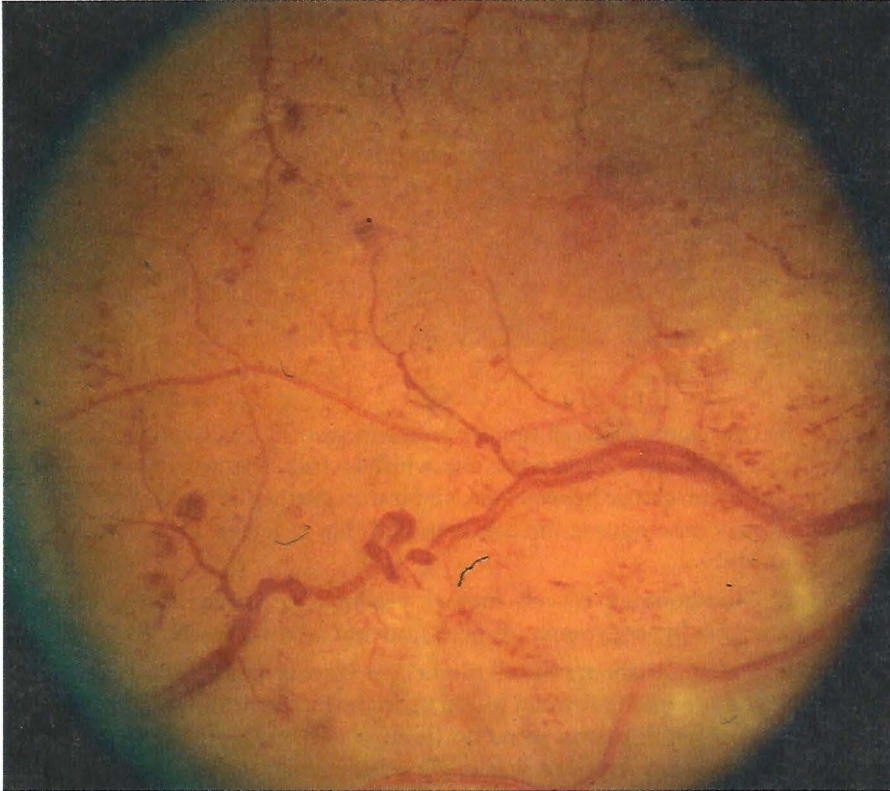Diabetic nephropathy: The first laboratory abnormality in diabetic nephropathy is a positive microalbuminuria. ACE inhibitors are often used in diabetic nephropathy because they reduce proteinuria levels and slow the progression of the nephropathy.

- b. **Clinical features.** Insulin-dependent diabetes mellitus can present with polydipsia, polyuria, and polyphagia; dehydration and electrolyte imbalance; metabolic ketoacidosis; and coma and potentially death. Treatment is with insulin.
 - c. **Microscopically,** lymphocytic inflammation involves the islets of Langerhans (insulinitis), leading to loss of β cells and fibrosis of the islets.
 4. **Non-insulin-dependent diabetes mellitus** (NIDDM, also called type 2, adult onset diabetes) represents 90% of cases of diabetes and affects obese individuals, both children and adults. Approximately 10 million people in the United States are affected (half are undiagnosed), and the incidence increases with age. Risk factors include obesity, increasing age, and genetic predisposition.
 - a. The **pathogenesis** involves relatively reduced insulin secretion; peripheral insulin resistance is the term used for reduced tissue sensitivity to insulin due to decreased numbers of insulin receptors on the cell membranes.
 - b. **Clinical features.** Non-insulin-dependent diabetes mellitus is frequently asymptomatic, but it can present with either polydipsia, polyuria, and polyphagia, or with hyperosmolar nonketotic diabetic coma. Treatment is with diet and weight loss, oral antidiabetic drugs, and sometimes insulin (more common in long-standing cases).
 - c. **Microscopically,** the changes are nonspecific, and can include focal atrophy and amyloid deposition in islets (hyalinization).
 5. **Vascular pathology.** Diabetes is a major risk factor for atherosclerosis and its complications, including myocardial infarction (most common cause of death), stroke (CVA), and peripheral vascular disease. The vascular disease can lead to atrophy of skin and loss of hair of the lower extremities, claudication, nonhealing ulcers, and gangrene of lower extremities. Microvascular disease is also a problem, and is characterized microscopically by diffuse thickening of basement membranes and hyaline arteriolosclerosis.
 6. **Diabetic nephropathy** includes renal artery atherosclerosis and hyaline arteriolosclerosis of afferent and efferent arterioles.
 - a. It can cause **diffuse glomerulosclerosis**, which can present with nephrotic syndrome and which is characterized microscopically by increased mesangial matrix, mesangial proliferation, and thickened basement membranes.
 - b. Diabetes can also cause **nodular glomerulosclerosis** (Kimmelstiel-Wilson disease), which can produce nephrotic syndrome and which is characterized microscopically by nodular PAS(+) deposits of mesangial matrix and thickened basement membranes.
 - c. **Other conditions.** Diabetic nephropathy also includes pyelonephritis and necrotizing papillitis, and renal failure.

7. **Diabetic retinopathy.** The nonproliferative phase of diabetic retinopathy is characterized by microaneurysms, retinal hemorrhages, and retinal exudates. The proliferative phase is characterized by neovascularization. The final fibrosis phase has vitreous humor fibrosis and detachment of the retina. Diabetics also have an increased rate of cataracts and glaucoma.
8. **Diabetic neuropathy** can cause peripheral neuropathy, neurogenic bladder, and sexual impotence.

Clinical Correlate

Diabetic nephropathy is the most common reason for renal transplantation in adults.



© Richard P. Usatine, M.D. / Paul D. Comeau, M.D.
Used with permission.

Figure 18-2. Diabetic retinopathy with hemorrhages, venous beading, and looping of vessels

PANCREATIC TUMORS

1. Islet cell tumors

- a. **Insulinoma** (β -cell tumor) is the most common type of islet cell tumor. Insulinomas produce insulin, and the resulting elevated insulin levels can cause hypoglycemia, sweating, hunger, confusion, and insulin coma. Laboratory studies show elevated insulin and C-peptides. Treatment is with glucose.

Table 18-1. Insulin-Related Pathophysiologic States

	Glucose	Insulin	C Peptide	Ketoacidosis
Type 2 diabetes	↑	↑, ↔	↑, ↔	–
Type 1 diabetes	↑	↓	↓	+
Insulinoma	↓	↑	↑	–
Factitious hypoglycemia (self-injection of insulin)	↓	↑	↓	–

- b. **Gastrinoma** (G-cell tumor) produces gastrin. Excess gastrin manifests as Zollinger-Ellison syndrome, which is characterized by elevated serum gastrin, gastric hyperacidity, and intractable peptic ulcers. Gastrinomas may arise outside the pancreas, and they may also be associated with MEN I.
- c. **Glucagonoma** (α -cell tumor) produces glucagon; excess glucagon causes hyperglycemia (diabetes), anemia, and skin rash.
- d. **Somatostatinoma** (δ -cell tumor) produces somatostatin. Excess somatostatin inhibits insulin secretion, leading to diabetes. These tumors can also inhibit gastrin secretion (leading to hypochlorhydria) and **cholecystokinin secretion** (leading to gallstones and steatorrhea).
- e. **VIPoma** produces vasoactive intestinal peptide (VIP); the excess vasoactive intestinal peptide causes WDHA syndrome: watery diarrhea, hypokalemia, and achlorhydria.
2. **Pancreatic carcinoma** is the fifth most common cause of cancer death in the United States and the incidence is increasing. Pancreatic carcinoma is most common between ages 60 and 80. Smoking is a risk factor.
- a. **Clinical features.** Pancreatic carcinoma presents with only vague signs and symptoms until late in the course. When more definitive symptoms develop, the symptoms can include abdominal pain, migratory thrombophlebitis, and obstructive jaundice. Treatment is by surgical excision (Whipple procedure); the prognosis is very poor, with only about 10% 1-year survival.
- b. **Pathology.** The incidence of tumor varies with the site in the pancreas: pancreatic head (60%), body (15%), and tail (5%). Microscopically, the adenocarcinoma arises from the duct epithelium. Tumor desmoplasia and perineural invasion are common. Tumor markers for pancreatic carcinoma include CEA and CA19-9.

Clinical Correlate

Trousseau Syndrome

Spontaneous venous thrombosis, which may resolve and recur in other areas (migratory thrombophlebitis), is associated with a visceral malignancy due to the release of mucin from the tumor initiating the extrinsic pathway of coagulation.

Chapter Summary

- In acute hemorrhagic pancreatitis, pancreatic acinar cell injury results in activation of pancreatic enzymes and enzymatic destruction of the pancreatic parenchyma. Acute hemorrhagic pancreatitis can be seen in a variety of clinical settings, notably associated with gallstones or alcohol use. Chronic pancreatitis is a chronic inflammation of the pancreas with atrophy and fibrosis secondary to repeated bouts of pancreatitis.
- Diabetes mellitus is a chronic systemic disease characterized by insulin deficiency or peripheral resistance, resulting in hyperglycemia and non-enzymatic glycosylation of proteins.
- Insulin-dependent diabetes mellitus usually develops in children and adolescents and is related to lack of insulin secondary to autoimmune destruction of beta cells. Non-insulin-dependent diabetes mellitus is usually a disease of obese adults and is much more common than insulin-dependent diabetes mellitus.
- Both types of diabetes may lead to long-term complications including atherosclerosis, myocardial infarction, stroke, peripheral vascular disease, diabetic nephropathy, diabetic retinopathy, and diabetic neuropathy.
- Pancreatic islet cell tumors may secrete insulin, gastrin, glucagon, somatostatin, or vasoactive intestinal peptide.
- Pancreatic carcinoma is the fifth most common cause of cancer death in the United States and has a very poor prognosis.

Gallbladder and Biliary Tract Pathology

19

GALLSTONES (CHOLELITHIASIS)

1. **Cholesterol stones** are composed of mostly cholesterol monohydrate. The incidence increases with age. Risk factors include female gender, obesity, pregnancy, oral contraceptives, and hormone replacement therapy (HRT). Native American Pima and Navajo Indians have an increased incidence of cholesterol gallstones.
2. **Pigmented bilirubinate stones** are composed of calcium salts and unconjugated bilirubin. Risk factors for developing pigmented bilirubinate stones are chronic hemolytic anemias, cirrhosis, bacterial infection, and parasites (*Ascaris* or *Clonorchis* [*Opisthorchis*] *sinensis*).
3. **Clinical features of gallstones.** Gallstones are frequently asymptomatic but can cause biliary colic (right upper quadrant pain due to impacted stones). Diagnosis is by ultrasound. Complications include cholecystitis, choledocholithiasis (calculi within the biliary tract), biliary tract obstruction, pancreatitis, and cholangitis.

INFLAMMATORY CONDITIONS

1. **Acute cholecystitis** is an acute inflammation of the gallbladder, usually caused by cystic duct obstruction by gallstones. Acute cholecystitis can present with biliary colic, right upper quadrant (RUQ) tenderness on palpation, nausea and vomiting, low-grade fever, and leukocytosis. Complications include gangrene of the gallbladder, perforation and peritonitis, fistula formation and gallstone ileus (small bowel obstruction by a large gallstone).
2. **Chronic cholecystitis** is ongoing chronic inflammation of the gallbladder, usually caused by gallstones. Microscopically, the gallbladder shows chronic inflammation and Rokitansky-Aschoff sinuses. A late complication is calcification of the gallbladder (“porcelain gallbladder”).
3. **Ascending cholangitis** is bacterial infection of the bile ducts ascending up to the liver, usually associated with obstruction of bile flow. The presentation is with biliary colic, jaundice, high fever, and chills. The infecting organisms are usually gram-negative enteric bacteria.

MISCELLANEOUS CONDITIONS

1. **Cholesterosis** refers to an accumulation of cholesterol-laden macrophages within the mucosa of the gallbladder wall. Gross examination shows yellow speckling of the red-tan mucosa (“strawberry gallbladder”), and microscopic examination shows lipid-laden macrophages within the lamina propria.
2. **Hydrops of the gallbladder** (mucocele) occurs when chronic obstruction of the cystic duct leads to the resorption of the normal gallbladder contents and enlargement of the gallbladder by the production of large amounts of clear fluid (hydrops) or mucous secretions (mucocele).

Note

Formation of cholesterol stones involves the precipitation of cholesterol from supersaturated bile.

Clinical Correlate

Murphy’s Sign

This is inspiratory arrest in response to palpation of the RUQ during deep inspiration.

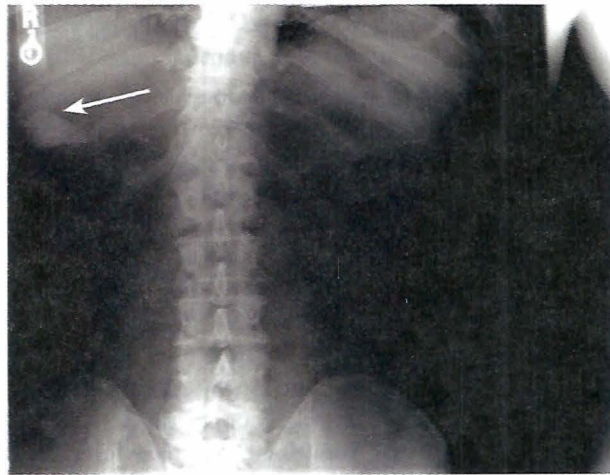
Clinical Correlate

Courvoisier law: An enlarged palpable gallbladder is more likely to be caused by obstruction due to malignancy than by stones.

“Porcelain gallbladder”: Calcification of the gallbladder due to chronic inflammation; high association with carcinoma.

BILIARY TRACT CANCER

1. **Gallbladder cancer** is frequently asymptomatic until late in the course. When the tumor does present, it may be with cholecystitis, enlarged palpable gallbladder, or biliary tract obstruction (uncommon). X-ray may show a calcified “porcelain gallbladder.” Microscopically, the tissues show adenocarcinoma. The prognosis for gallbladder cancer is poor, at only about 1% survival at 5 years.
2. **Bile duct cancer.** Bile duct carcinoma is defined as carcinoma of the *extra-hepatic* bile ducts, while cholangiocarcinoma is carcinoma of the *intra-hepatic* bile ducts. Klatskin tumor is a carcinoma of the bifurcation of the right and left hepatic bile ducts. Risk factors for bile duct cancer include *Clonorchis (Opisthorchis) sinensis* (liver fluke) in Asia and primary sclerosing cholangitis. Bile duct cancer typically presents with biliary tract obstruction. Microscopic examination shows adenocarcinoma arising from the bile duct epithelium. The prognosis for bile duct cancer is poor.



© Gloria Jicha: Tripler Army Medical Center. Used with permission.

Figure 19-1. X-ray showing calcified (porcelain) gallbladder

Chapter Summary

- Gallstones can take the form of cholesterol stones or pigmented bilirubinate stones.
- Cholesterol stones are composed of mostly cholesterol monohydrate and have as risk factors female gender, obesity, pregnancy, exogenous female hormones, increasing age, and genetics.
- Pigmented bilirubinate stones are composed of calcium salts and unconjugated bilirubin and have as risk factors chronic hemolytic anemias, cirrhosis, bacteria, and parasites.
- Gallstone disease is frequently asymptomatic, or may cause right upper quadrant pain due to impacted stones. Complications include cholecystitis, choledocholithiasis, biliary tract obstruction, and cholangitis.
- Acute cholecystitis is an acute inflammation of the gallbladder that is usually caused by cystic duct obstruction by gallstones. Complications of acute cholecystitis include gangrene of the gallbladder, peritonitis, and gallstone ileus.
- Chronic cholecystitis is ongoing chronic inflammation of the gallbladder that is usually caused by gallstones.
- Ascending cholangitis is a bacterial infection of the bile ducts ascending up to the liver and is usually associated with obstruction of bile flow.
- Cholesterosis is a clinically insignificant yellow-speckling of the gallbladder mucosa.
- Hydrops of the gallbladder occurs when chronic obstruction of the cystic duct leads to the resorption of the normal gallbladder contents and enlargement of the gallbladder, with production of large amounts of clear fluid (hydrops) or mucous secretions (mucocele).
- Gallbladder cancer has a very poor prognosis because it is frequently asymptomatic until late in the course. Bile duct cancer also has a poor prognosis.

JAUNDICE

1. **General features of jaundice.** Clinical jaundice occurs with bilirubin levels $>2-3$ mg/dL. The classic presentation is with yellow skin (jaundice) and sclera (icterus). Causes of jaundice include overproduction of bilirubin, defective hepatic bilirubin uptake, defective conjugation, and defective excretion.

Table 20-1. Unconjugated Versus Conjugated Bilirubinemia

Unconjugated (Indirect) Bilirubinemia	Conjugated (Direct) Bilirubinemia
Increased RBC turnover (hemolytic anemias)	Biliary tract obstruction
Physiologic (newborn babies)	Biliary tract disease (PSC and PBC)
Hereditary (Gilbert and Crigler-Najjar syndromes)	Hereditary (Dubin-Johnson and Rotor syndromes)
	Liver disease (cirrhosis and hepatitis)

2. **Increased red blood cell (RBC) turnover.** RBCs are the major source of bilirubin. Jaundice related to overproduction of bilirubin can be seen in hemolytic anemia and ineffective erythropoiesis (thalassemia, megaloblastic anemia, etc.). Laboratory studies show increased unconjugated bilirubin. Chronic hemolytic anemia patients often develop pigmented bilirubinate gallstones.
3. **Physiologic jaundice of the newborn** is a transient unconjugated hyperbilirubinemia due to the immaturity of the liver. Risk factors include prematurity and hemolytic disease of the newborn (erythroblastosis fetalis). Physiologic jaundice of the newborn can be complicated by kernicterus; treatment is with phototherapy.
4. **Hereditary hyperbilirubinemias.**
 - a. **Gilbert syndrome** is a common benign inherited disorder that causes unconjugated hyperbilirubinemia due to bilirubin UDP-glucuronosyltransferase (UGT) deficiency. There can be jaundice related to stress (fasting, infection, etc.), but no other clinical consequences.
 - b. **Crigler-Najjar syndrome** causes unconjugated hyperbilirubinemia due to bilirubin glucuronosyltransferase (UGT) absence or deficiency. Type I is fatal because of kernicterus. Type II causes jaundice.
 - c. **Dubin-Johnson syndrome** is a benign autosomal recessive disorder characterized by decreased bilirubin excretion due to a defect in the canalicular cationic transport protein. The condition produces conjugated hyperbilirubinemia and a distinctive black pigmentation of the liver, but has no clinical consequences.

Clinical Correlate

In infants, increased levels of unconjugated bilirubin (lipid-soluble) may cross the blood-brain barrier and deposit in the basal ganglia, causing irreversible brain damage (kernicterus).

- d. **Rotor syndrome** is an autosomal recessive conjugated hyperbilirubinemia that is similar to Dubin-Johnson syndrome, but without liver pigmentation. There are no clinical consequences.
5. **Biliary tract obstruction** may have multiple etiologies, including gallstones; tumors (pancreatic, gallbladder, and bile duct); stricture; and parasites (liver flukes—*Clonorchis* [*Opisthorchis*] *sinensis*). The presentation can include jaundice and icterus; pruritus due to increased plasma levels of bile acids; abdominal pain, fever, and chill; dark urine (bilirubinuria); and pale clay-colored stools. Laboratory studies showed elevated conjugated bilirubin, elevated alkaline phosphatase, and elevated 5'-nucleotidase.
6. **Primary biliary cirrhosis (PBC)** is a chronic liver disease of unknown etiology (autoimmune) that is characterized by inflammation and granulomatous destruction of intrahepatic bile ducts. Females have 10 times the incidence of primary biliary cirrhosis as compared to males; the peak incidence is age 30 to 65 years.
- a. **Clinical features.** The presentation of biliary cirrhosis includes obstructive jaundice and pruritus; xanthomas, xanthelasmas, and elevated serum cholesterol; fatigue; and cirrhosis (late complication). Most patients have another autoimmune disease (scleroderma, rheumatoid arthritis or systemic lupus erythematosus).
- b. **Diagnostic studies.** Laboratory studies show elevated conjugated bilirubin, elevated alkaline phosphatase, and elevated 5'-nucleotidase. **Antimitochondrial autoantibodies (AMA)** are present in more than 90% of cases. Microscopically, lymphocytic and granulomatous inflammation involves interlobular bile ducts.
7. **Primary sclerosing cholangitis (PSC)** is a chronic liver disease of unknown etiology characterized by segmental inflammation and fibrosing destruction of intrahepatic and extrahepatic bile ducts.
- a. **Clinically**, the male to female ratio is 2:1; peak age 20 is 40 years. Most cases of PSC are associated with ulcerative colitis. The presentation is similar to PBC. Complications include biliary cirrhosis and cholangiocarcinoma.
- b. **Diagnostic studies.** Microscopically, there is periductal chronic inflammation with concentric fibrosis around bile ducts and segmental stenosis of bile ducts. Cholangiogram shows “beaded appearance” of bile ducts.

CIRRHOSIS

- Cirrhosis** is end-stage liver disease characterized by disruption of the liver architecture by bands of fibrosis which divide the liver into nodules of regenerating liver parenchyma.
- Causes of cirrhosis** include alcohol, viral hepatitis, biliary tract disease, hemochromatosis, cryptogenic/idiopathic, Wilson disease, and α -1-antitrypsin deficiency.
- Gross pathology.** **Micronodular** cirrhosis has nodules <3 mm, while **macronodular** cirrhosis has nodules >3 mm; mixed micronodular and macronodular cirrhosis can also occur. At the end stage, most diseases result in a mixed pattern, and the etiology may not be distinguished based on the appearance. The mechanism by which cirrhosis is produced is fibrosis produced by the Ito cell (hepatic stellate cells).
- Cirrhosis has a multitude of **consequences**, including portal hypertension, ascites, splenomegaly/hypersplenism, esophageal varices, hemorrhoids, caput medusa, decreased detoxification, hepatic encephalopathy, spider angiomas, palmar erythema, gynecomastia, decreased synthesis, hypoalbuminemia, decreased clotting, and hepatorenal syndrome.

Clinical Correlate

The prothrombin time (PT), not the partial thromboplastin time (PTT), is used to assess the coagulopathy due to liver disease.

VIRAL HEPATITIS

1. **Hepatitis viruses.** Viral hepatitis can be asymptomatic, or it can present with malaise and weakness, nausea and anorexia, jaundice, or dark urine. Laboratory studies show markedly elevated alanine aminotransferase (ALT) and aspartate aminotransferase (AST). Diagnosis is by serology.
2. **Acute viral hepatitis** is defined to be viral hepatitis with signs and symptoms for <6 months. It can be caused by *any of the hepatitis viruses*. Microscopically, the liver shows lobular disarray, hepatocyte swelling (balloon cells), apoptotic hepatocytes (Councilman bodies), lymphocytes in portal tracts and in the lobule, hepatocyte regeneration, and cholestasis.
3. **Chronic viral hepatitis** is the term used for viral hepatitis with signs and symptoms for >6 months. It can be caused by *hepatitis viruses B, C, and D*. Microscopically, chronic persistent hepatitis shows inflammation confined to portal tracts. Chronic active hepatitis shows inflammation spilling into the parenchyma, causing interface hepatitis (piecemeal necrosis of limiting plate). Hepatitis B often has “ground glass” hepatocytes (due to cytoplasmic HBsAg).

Clinical Correlate

Non-Hepatitis Viruses Which May Infect the Liver

- *Epstein-Barr virus* (EBV)—infectious mononucleosis
- *Cytomegalovirus* (CMV)
- Herpes
- Yellow fever

Table 20-2. The Hepatitis Viruses

Common Virus Name	Hepatitis A (HAV)	Hepatitis B (HBV)	Hepatitis C (HCV)	Hepatitis D (HDV)	Hepatitis E (HEV)
Common disease name	“Infectious”	“Serum”	“Post-transfusion” or “non-A, non-B”	“Delta”	“Enteric”
Virus	<i>Picornavirus</i> naked capsid RNA	<i>Hepadnavirus</i> enveloped DNA	<i>Flavivirus</i> enveloped RNA	Defective enveloped circular RNA	<i>Hepevirus</i> naked capsid RNA
Transmission	Fecal-oral	Parenteral, sexual	Parenteral, sexual	Parenteral, sexual	Fecal-oral
Severity	Mild	Occasionally severe	Usually subclinical	Co-infection with HBV occasionally severe; super- infection with HBV often severe	Normal patients: mild; pregnant patients: severe
Chronicity or carrier state	No	Yes	Yes (high)	Yes	No
Clinical diseases	Acute hepatitis	<ul style="list-style-type: none"> • Acute hepatitis • Chronic hepatitis • Cirrhosis • Hepatocellular carcinoma (HCC) 	<ul style="list-style-type: none"> • Chronic hepatitis • Cirrhosis • HCC 	<ul style="list-style-type: none"> • Acute hepatitis • Chronic hepatitis • Cirrhosis • HCC 	Acute hepatitis
Laboratory diagnosis	Symptoms and anti-HAV IgM	Symptoms and serum levels of HBsAg, HBeAg, and anti-HBc IgM	Symptoms and anti-HCV ELISA	Anti-HDV ELISA	
Prevention	Vaccine, hygiene	Vaccine			Hygiene

Table 20-3. Hepatitis B Terminology and Markers

Abbreviation	Name and Description
HBV	Hepatitis B virus, a hepadnavirus (enveloped, partially double-stranded DNA virus); Dane particle = infectious HBV
HBsAg	Antigen found on surface of HBV; also found on spheres and filaments in patient's blood: positive during acute disease; continued presence indicates carrier state
HBsAb	Antibody to HBsAg; provides immunity to hepatitis B
HBcAg	Antigen associated with core of HBV
HBcAb	Antibody to HBcAg; positive during window phase; IgM HBcAb is an indicator of recent disease
HBeAg	A second, different antigenic determinant on the HBV core; important indicator of transmissibility
HBeAb	Antibody to e antigen; indicates low transmissibility
Delta agent	Small RNA virus with HBsAg envelope; defective virus that replicates only in HBV-infected cells

Table 20-4. Hepatitis A Serology

Acute or recent infection	anti-HAV IgM
Prior infection or immunization	anti-HAV IgG

Table 20-5. Hepatitis B Serology

	HBsAg HBeAg* HBV-DNA	HBcAb IgM	HBcAb IgG	HBsAb IgG
Acute infection	+	+	-	-
Window period	-	+	-	-
Prior infection	-	-	+	+
Immunization	-	-	-	+
Chronic infection	+	+	+	-

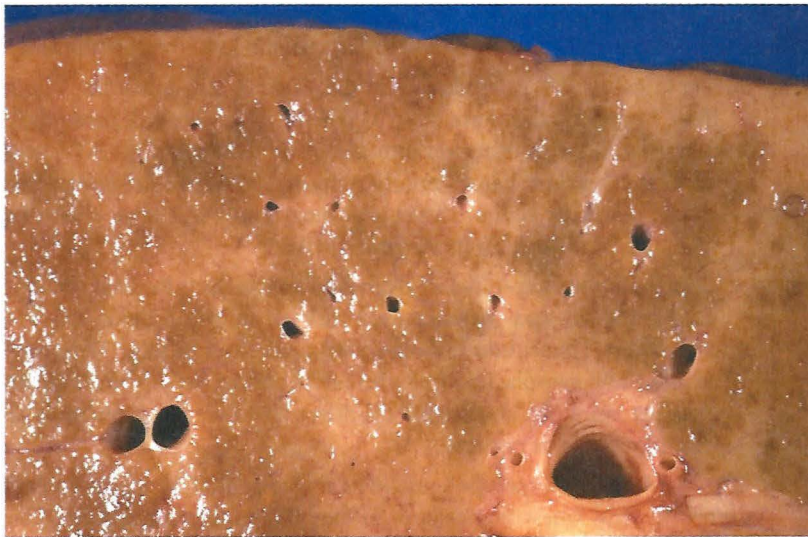*HBeAg—correlates with viral proliferation and infectivity

AMEBIC LIVER ABSCESSSES

1. **Amebic liver abscess** is rare in the United States except in recent immigrants from Mexico, South America, India, etc. The causative organism is *Entamoeba histolytica*. Amebic liver abscess produces a necrotic abscess filled with brown pastelike material (“anchovy paste”). Treatment is with antibiotics, with or without surgical drainage.

ALCOHOLIC LIVER DISEASE

1. **Fatty change** (steatosis) is reversible with abstinence. The gross appearance is of an enlarged, yellow, greasy liver. Microscopically, the liver initially shows centrilobular macrovesicular steatosis (reversible) that can eventually progress to fibrosis around the central vein (irreversible).
2. **Alcoholic hepatitis** is an acute illness that usually follows a heavy drinking binge. Alcoholic hepatitis is clinically variable; some patients have no symptoms while others develop right upper quadrant pain, hepatomegaly, jaundice, malaise, and/or anorexia. Fulminant liver failure may also occur. The prognosis can be poor, since each episode has a 20% risk of death, and repeated episodes increase the risk of developing cirrhosis.
 - a. **Microscopically**, the liver shows hepatocyte swelling (ballooning) and necrosis, Mallory bodies (cytokeratin intermediate filaments), neutrophils, fatty change, and eventual fibrosis around the central vein.
3. **Alcoholic cirrhosis** develops in 15% of alcoholics, and is typically a micronodular cirrhosis. It is the most common disease requiring liver transplantation in adults.



© cdc.gov. Used with permission.

Figure 20-1. Alcoholic Cirrhosis, Liver

METABOLIC LIVER DISEASE

1. **Wilson's disease** (hepatolenticular degeneration) is a genetic disorder of copper metabolism resulting in the accumulation of toxic levels of copper in various organs. The diagnosis is established by demonstrating decreased serum ceruloplasmin levels, increased tissue copper levels (liver biopsy), and increased urinary copper excretion. The treatment includes copper chelators (D-penicillamine); liver transplantation is curative.
 - a. **Genetics.** The disease is autosomal recessive, and the WD gene (ATP7B on chromosome 13) codes for a hepatocyte canalicular copper-transporting ATPase. Damage to the gene leads to a decreased biliary excretion of copper. Wilson's disease presents in childhood or adolescence with liver disease.

In a Nutshell

Protease-Antiprotease Imbalance

- α -1-antitrypsin is an important protease inhibitor.
- It is responsible for inhibiting neutrophil elastase.
- It also inhibits trypsin, chymotrypsin, and bacterial proteases.

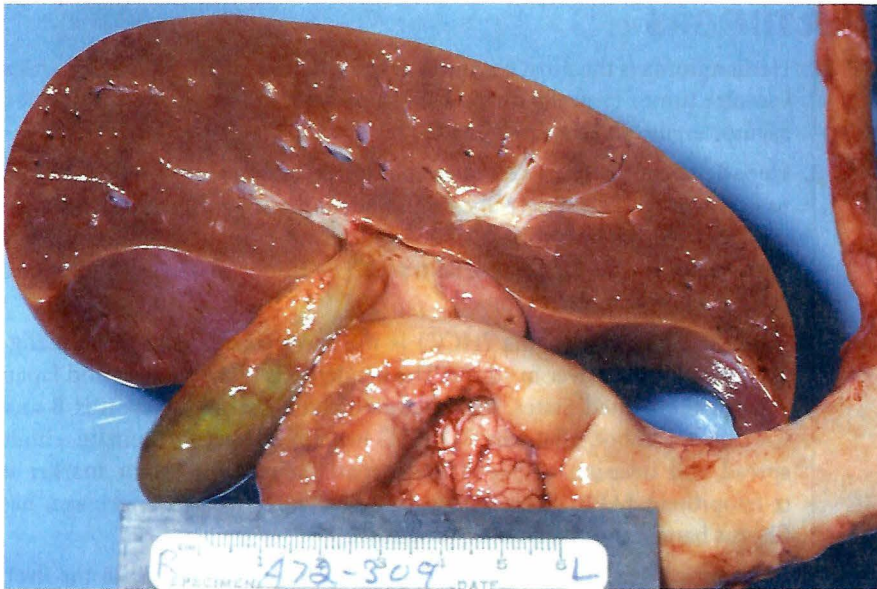Clinical Correlate

α -1-antitrypsin deficiency is the most common genetic disease requiring liver transplantation in children.

- b. **Distribution of disease.** Wilson's disease affects the liver (fatty change, chronic hepatitis, and micronodular cirrhosis), cornea (Kayser-Fleischer rings [copper deposition in Descemet's membrane]), and brain (neurological and psychiatric manifestations, movement disorder).
- Hemochromatosis** is a disease of increased levels of iron, leading to tissue injury. Hereditary (primary) hemochromatosis is a recessive disorder of the HFE gene on chromosome 6p. The most common mutation of the HFE gene is the C282Y mutation, which increases small-intestine absorption of iron. Secondary hemochromatosis can follow transfusions for chronic anemias. Hemochromatosis affects 5 times as many males as females, and the disease is common in people of Northern European descent.

 - Clinical features.** Hemochromatosis can cause micronodular cirrhosis and hepatocellular carcinoma (200 times the normal risk ratio); secondary diabetes mellitus; hyperpigmented skin ("bronzing"); congestive heart failure and cardiac arrhythmias; and hypogonadism. The diagnosis is established by demonstrating markedly elevated serum iron and ferritin or increased tissue iron levels (Prussian blue stain) on liver biopsy. Treatment is with phlebotomy.
- α -1-antitrypsin deficiency** is an autosomal recessive disorder characterized by production of defective α -1-antitrypsin (α 1-AT), which accumulates in hepatocytes and causes liver damage and low serum levels of α 1-AT.

 - Genetics.** α 1-AT is produced by the Pi gene (chromosome 14). More than 75 gene variants are described. PiM is the normal, most common form (90%). Most other variants also produce normal α 1-AT levels. **PiS deficiency variant** causes mildly reduced levels. **PiZ deficiency variant** causes markedly reduced levels. Homozygous PiZZ have severe reductions (15% of normal) in enzyme levels.
 - Clinical features.** α -1-Antitrypsin deficiency affects the liver (micronodular cirrhosis and an increased risk of hepatocellular carcinoma) and lungs (panacinar emphysema). Microscopically, PAS positive, eosinophilic cytoplasmic globules are found in hepatocytes. Treatment involves smoking abstinence/cessation to prevent emphysema. Liver transplantation is curative.
- Reye syndrome** is a rare, potentially fatal disease that occurs in young children with viral illness (varicella or influenza) treated with aspirin. The disease mechanism is unknown; mitochondrial injury and dysfunction play an important role. Reye syndrome causes hepatic fatty change (microvesicular steatosis) and cerebral edema/encephalopathy. There is complete recovery in 75% of patients, but those that do not recover may have coma, permanent neurologic deficits, and death. Treatment is supportive.



© cdc.gov. Used with permission.

Figure 20-2. Reye Syndrome

5. **Nonalcoholic fatty liver disease** is a disease of lipids accumulating in hepatocytes that is not associated with heavy alcohol use. It occurs equally in men and women, and is strongly associated with obesity, hyperinsulinemia, insulin resistance, and type 2 diabetes mellitus. The pathogenesis involves lipid accumulation in hepatocytes that can progress to steatohepatitis (NASH—nonalcoholic steatohepatitis) and finally cirrhosis. Nonalcoholic fatty liver disease is a diagnosis of exclusion.

HEMODYNAMIC LIVER DISEASES

1. **Budd-Chiari syndrome** (hepatic vein thrombosis) refers to occlusion of the hepatic vein by a thrombus, often resulting in death. While a few cases are idiopathic, there is much more often an underlying process predisposing for the thrombosis, which may include polycythemia vera, pregnancy, oral contraceptives, paroxysmal nocturnal hemoglobinuria, or hepatocellular carcinoma. Budd-Chiari syndrome causes abdominal pain, hepatomegaly, ascites, and death. Microscopically, the liver shows centrilobular congestion and necrosis.
2. **Chronic passive congestion** of the liver refers to a “backup of blood” into the liver, usually due to right-sided heart failure. Grossly, the liver characteristically has a nutmeg pattern of alternating dark (congested central areas) and light (portal tract areas) liver parenchyma. Microscopically, the liver shows centrilobular congestion. Complications include centrilobular necrosis, which is an ischemic necrosis of centrilobular hepatocytes. Long-standing congestion can lead to centrilobular fibrosis, which can eventually become cardiac cirrhosis (sclerosis).

LIVER TUMORS

1. **Hemangioma** is the most common primary tumor of the liver. This benign vascular tumor typically forms a subcapsular, red, spongy mass. It is often asymptomatic and detected incidentally.
2. **Hepatic adenoma** (liver cell adenoma) affects young women and is related to oral contraceptive use. Subcapsular adenomas may rupture, causing an intraperitoneal hemorrhage. Microscopically, the tissue resembles normal liver except for the lack of portal tracts. The tumor may regress after oral contraceptives are discontinued.
3. **Hepatocellular carcinoma** (HCC) is the most common primary malignant tumor of the liver in adults. The incidence is higher in Asia and Japan than in the United States. Risk factors include cirrhosis, hepatitis B and C viruses, alcohol, aflatoxin B1. HCC has a tendency for hematogenous spread and invasion of portal and hepatic veins. The tumor marker is α -fetoprotein (AFP). The fibrolamellar variant affects younger age, has fibrous bands, and has a better prognosis.
4. **Metastatic tumors** are the most common tumors found within the liver. Common primary sites include colon, breast, and lung. Metastatic tumors tend to occur as multiple well-circumscribed masses.

Chapter Summary

- Jaundice produces yellow skin and sclera and occurs with bilirubin levels $>2-3$ mg/dL.
- Increased red blood cell turnover, due to either hemolytic anemia or ineffective erythropoiesis, causes an unconjugated hyperbilirubinemia and may predispose for pigmented bilirubinate gallstones.
- Physiologic jaundice of the newborn is a transient unconjugated hyperbilirubinemia due to the immaturity of the liver.
- Gilbert syndrome and Crigler-Najjar syndrome are inherited causes of unconjugated hyperbilirubinemia due to bilirubin glucuronosyltransferase deficiency or absence. Gilbert disease is completely benign. Type I Crigler-Najjar syndrome is fatal in infancy secondary to kernicterus and type II Crigler-Najjar syndrome causes jaundice.
- Dubin-Johnson syndrome is a benign autosomal recessive disorder that causes conjugated hyperbilirubinemia secondary to decreased bilirubin excretion due to a defect in the canalicular transport protein. A distinctive feature of Dubin-Johnson syndrome is black pigmentation of the liver. Rotor syndrome is similar to Dubin-Johnson syndrome but does not have the liver pigmentation.
- Biliary tract obstruction can be due to gallstones, tumors, stricture, or parasite, and can present with jaundice, pruritus, abdominal pain, bilirubinuria, and pale stools.
- Primary biliary cirrhosis is a chronic liver disease of probable autoimmune etiology that is characterized by inflammation and granulomatous destruction of intrahepatic bile ducts.
- Primary sclerosing cholangitis is a chronic liver disease of unknown etiology characterized by segmental inflammation and fibrosing destruction of intrahepatic bile ducts.

(Continued)

Chapter Summary (cont'd)

- Cirrhosis is an end-stage liver disease due to many etiologies characterized by disruption of the liver architecture by bands of fibrosis that divide the liver into nodules of regenerating liver parenchyma. Complications of cirrhosis include portal hypertension, ascites, hypersplenism, esophageal varices, hemorrhoids, caput medusae, hepatic encephalopathy, spider angiomas, palmar erythema, gynecomastia, hypoalbuminemia, decreased clotting factors, and hepatorenal syndrome.
- Acute viral hepatitis can be due to any of the hepatitis viruses. Chronic viral hepatitis can be caused by hepatitis viruses B, C, and D. Hepatitis viruses vary in the nature of the virus and the manner in which they are spread. Hepatitis A virus is spread by the fecal-oral route and usually causes mild acute hepatitis. Hepatitis B virus is spread parenterally and by sexual contact and may cause acute hepatitis, chronic hepatitis, cirrhosis, and hepatocellular carcinoma. Hepatitis C is spread by the parenteral and sexual routes and may cause acute hepatitis, chronic hepatitis, cirrhosis, and hepatocellular carcinoma. Hepatitis D is a defective virus that requires Hepatitis B as a coinfection or superinfection to produce severe disease, which may take the form of acute hepatitis, chronic hepatitis, or cirrhosis. Hepatitis E virus is spread by the fecal-oral route and causes acute hepatitis that may be severe in infected pregnant women.
- Amebic liver abscess is due to infection with *Entamoeba histolytica* and requires antibiotics and surgical drainage for therapy.
- Alcoholic liver disease can produce steatosis, alcoholic hepatitis, or alcoholic cirrhosis.
- Wilson disease is a genetic disorder of copper metabolism resulting in accumulation of toxic levels of copper leading to liver disease, Kayser-Fleischer corneal rings, and neurologic and psychiatric manifestations.
- Hemochromatosis is characterized by increased levels of iron that can deposit into tissues, leading to cirrhosis, hepatocellular carcinoma, diabetes mellitus, bronze skin, congestive heart failure, cardiac arrhythmias, and hypogonadism.
- Alpha-1-antitrypsin deficiency is an autosomal recessive disorder characterized by production of defective alpha-1-antitrypsin, which accumulates in hepatocytes and causes liver damage and low serum levels of alpha-1-antitrypsin.
- Reye syndrome is a potentially fatal disease that occurs in young children with viral illnesses treated with aspirin. It can cause liver steatosis and cerebral edema.
- Nonalcoholic fatty liver disease is highly associated with obesity and type 2 diabetes mellitus leading to hepatic lipid accumulation, nonsteatohepatitis, and can progress to cirrhosis in 10–30% of patients.
- Budd-Chiari syndrome is occlusion of the hepatic vein by a thrombus, often resulting in death.
- Chronic passive congestion of the liver is a “backup of blood” into the liver, usually due to right-sided heart failure, and may, in long-standing cases, lead to cirrhosis (sclerosis).
- Benign tumors of the liver include hemangiomas and hepatic adenomas. Malignant tumors include hepatocellular carcinoma, cholangiocarcinoma, angiosarcoma, and metastatic tumors.

INFECTIONS

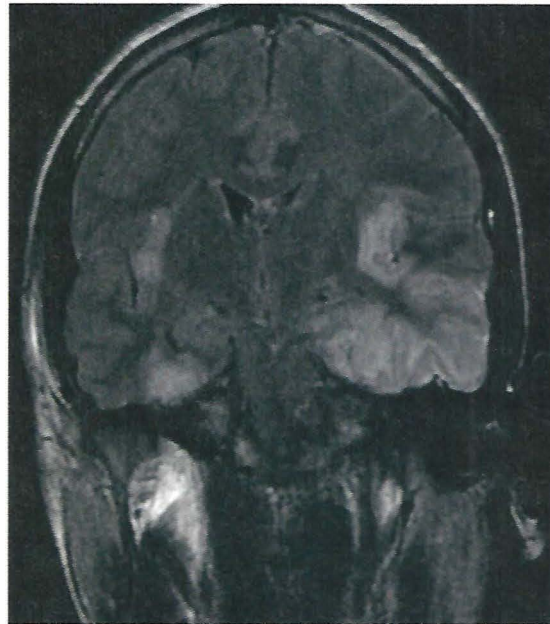
1. Acute meningitis

- a. **Acute aseptic (viral) meningitis** results from leptomeningeal inflammation due to viruses (enterovirus most frequent); this inflammation produces a lymphocytic infiltration of leptomeninges and superficial cortex. Clinically, patients have fever, signs of meningeal irritation, and depressed consciousness. The mortality is low.
 - b. **Acute purulent meningitis** is a purulent leptomeningeal inflammation due to bacteria. The infecting organisms vary with age.
 - Neonates are infected most frequently with group B streptococci and *Escherichia coli*.
 - Infants and children are infected most frequently with *Haemophilus influenza*.
 - Adolescents and young adults are infected most frequently with *Neisseria meningitides*.
 - The elderly are infected most frequently with *Streptococcus pneumoniae* and *Listeria monocytogenes*.
 - i. **Pathology.** The leptomeninges are opaque. Microscopic examination shows neutrophilic infiltration of the leptomeninges, extending variably to cortex. Diffuse cerebral edema carries a risk of fatal herniations.
 - ii. **Clinical features** include headache, fever, nuchal rigidity, cloudy sensorium, coma, and death. There can be sequelae due to organization of purulent exudate and fibrosis. Hydrocephalus and cranial nerve impairment (neural deafness) may occur.
2. **Mycobacterial meningoencephalitis** can be caused by *Mycobacterium tuberculosis* or atypical mycobacteria. It usually involves the basal surface of the brain, and may cause characteristic tuberculomas within the brain and dura mater. Mycobacterial meningoencephalitis is frequent in AIDS patients, particularly by *Mycobacterium avium-intracellulare*.

Table 21-1. CSF Parameters in Different Forms of Meningitis

Condition	Cells/ μ L	Glucose (μ g/dL)	Proteins (mg/dL)	Pressure (mm H ₂ O)
Normal values	<5 lymphocytes	45–85 (50–70% glycemia)	15–45	70–180
Purulent (bacterial)	Up to 90,000 neutrophils	Decreased (<45)	Increased (>50)	Markedly elevated
Aseptic (viral)	100–1,000 most lymphocytes	Normal	Increased (>50)	Slightly elevated
Granulomatous (mycobacterial/fungal)	100–1,000 most lymphocytes	Decreased (<45)	Increased (>50)	Moderately elevated

3. **Viral encephalitides.** Common features of the viral encephalitides include perivascular cuffs, microglial nodules, neuron loss, and neuronophagia. Clinical manifestations are variable, and can include mental status change, fever, and headache, often progressing to coma.



© Paul J. Shogan - National Capital Consortium.
Used with permission.

Figure 21-1. CT scan showing edema of bilateral temporal lobes, related to herpes simplex encephalitis



Rhabdovirus

- Rabies virus
- ss (-) RNA
- Bullet-shaped
- Enveloped

- a. **Specific forms.** Arthropod-borne forms can be due to St. Louis, California, Eastern and Western equine, and Venezuelan encephalitides. Herpes simplex type 1 produces a characteristic **hemorrhagic necrosis of temporal lobes**. Rabies has characteristic Negri bodies in hippocampal and Purkinje neurons.
- b. **HIV** shows frequent cerebral involvement that may lead to AIDS-dementia complex, characterized by dementia and other neurological abnormalities. The histopathology shows microglial nodules and diagnostic multinucleated giant cells. Spinal involvement leads to vacuolar myelopathy, which is similar to vitamin B12 deficiency-associated subacute combined degeneration.
- c. **Progressive multifocal leukoencephalopathy (PML)** is related to *JC virus* (a polyomavirus). *JC virus* causes progressive multifocal leukoencephalopathy in immunocompromised patients (especially AIDS). Histopathology shows demyelination, lymphohistiocytosis, and astrogliosis. The astrocytes acquire bizarre shapes. Oligodendrocytes in active lesions contain viral intranuclear inclusions.
4. **Fungal meningoencephalitides.** *Candida*, *Aspergillus*, *Cryptococcus*, and *Mucor* species are the most frequent agents. *Aspergillus* and *Mucor* have a marked tropism for blood vessels, which leads to vasculitis, rupture of blood vessels, and hemorrhage. *Cryptococcus* causes diffuse meningoencephalitis, which leads to invasion of the brain through the Virchow-Robin space (a continuation of the subarachnoid space around blood vessels entering the neuropil) and soap bubble lesions.

5. **Toxoplasmosis** is frequent in AIDS patients, and the condition causes cerebral abscess with central necrosis and chronic inflammation. MRI/CT scan shows a characteristic ring-enhancing lesion.
6. **Cerebral abscess** can occur as a result of either hematogenous dissemination or direct spread from contiguous foci. **Systemic predisposing conditions** include acute bacterial endocarditis, cyanotic heart disease (right-to-left shunt), and chronic pulmonary abscesses. **Local predisposing conditions** include mastoiditis, paranasal sinusitis, acute otitis, open fracture, and previous neurosurgery. CT/MRI scan characteristically shows a ring-enhancing lesion.
 - a. **Clinical manifestations** include signs of increased intracranial pressure (headache, vomiting, and papilledema). Focal neurological deficits vary depending on the site of lesion.
7. **Subacute sclerosing panencephalitis** is a rare complication of measles (rubeola) virus infection. Persistent immune-resistant measles virus infection causes slow-virus encephalitis. The typical scenario is a child who had measles before age 2 and then 6 to 15 years later develops progressive mental deterioration with seizures. Subacute sclerosing panencephalitis may be fatal in 1 to 2 years once it develops.
8. **Creutzfeldt-Jakob disease (CJD)** is the most common human transmissible spongiform encephalopathy due to a prion (a protein with the capacity to be an infectious agent) that can change the conformation of normal prion protein(s). This can lead to rapidly progressive dementia, memory loss, personality changes, and hallucinations.
 - a. The **prion protein (PrP)** is a 30-kD protein normally present in neurons. It is encoded by a single-exon gene on chromosome 20. Its normal conformation is an α -helix: **PrP^c**. In disease states, PrP^c changes to a β -pleated sheet conformation: **PrP^{sc}**. A low rate of spontaneous change results in sporadic cases of CJD. Mutations of PrP result in hereditary cases of CJD. PrP^{sc} facilitates conformational change of other PrP^c molecules into PrP^{sc}.
 - b. PrP^{sc} is responsible for **cerebral pathologic changes**, characteristically resulting in spongiform change. This change is a fine vacuolization of the neuropil in the gray matter (especially cortex), which is due to large membrane-bound vacuoles within neuronal processes. There is an associated neuronal loss and astrogliosis. Kuru plaques are deposits of amyloid composed of altered PrP protein.
 - c. **Clinical features.** 85% of Creutzfeldt-Jakob cases are sporadic, and 15% are familial. Affected patients are typically middle-age to elderly patients who develop rapidly progressive dementia and memory loss with startle myoclonus or other involuntary movements. Typical EEG changes may be diagnostic. Death occurs within 6–12 months.

Table 21-2. Prion Diseases

Disease	Infectious Agent	Host	Comments
Kuru	Prion	Human	Subacute spongiform encephalopathy (SSE); Fore Tribe in New Guinea; consuming infected brains
Creutzfeldt-Jakob	Prion	Human	SSE Genetic predisposition
Gerstmann-Straussler	Prion	Human	SSE
Fatal familial insomnia	Prion	Human	SSE
Scrapie	Prion	Sheep	SSE—scraping their wool off on fences

Bridge to Anatomy

The brain is highly dependent on a constant supply of oxygen and glucose from the cerebral arteries, which have collateral blood flow at the circle of Willis.

Clinical Correlate

Strokes frequently occur in the middle cerebral artery territory.

CEREBROVASCULAR DISEASE

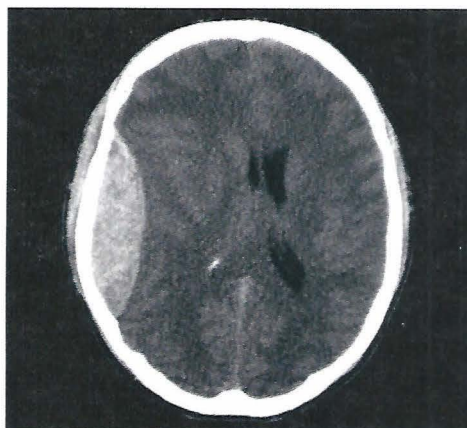- Cerebrovascular disease** is the third most frequent cause of death in industrialized countries, and it is the leading cause of serious disability in the United States. Risk factors are similar to coronary artery disease.
- Clinicopathological forms.**
 - Global cerebral ischemia** (diffuse ischemic encephalopathy) is caused by a fall in blood flow to the brain, due to processes such as shock, cardiac arrest, and hypotensive episodes. While the entire brain can be damaged, some regions have selective vulnerability, including Purkinje neurons, hippocampus, CA1 (Sommer sector), and pyramidal neurons of cortex.
 - The **pathology** often includes infarcts in watershed areas, cortical laminar necrosis, and diffuse ischemic necrosis of neocortex. Global cerebral ischemia may lead to brain death.
 - Transient ischemic attack (TIA)** is due to small platelet thrombi or atheroemboli and is characteristically reversible, with symptoms lasting less than 24 hours.
 - Stroke** can be due to either infarction (85% of all stroke cases) or hemorrhage (15% of all stroke cases).
 - Infarction.** Infarction causes 85% of all stroke cases.
 - It can be due to **thrombotic occlusion** in the setting of atherosclerosis of the cerebral arteries, and the thrombotic infarction is characteristically an anemic (white) infarct.
 - Infarction can also be due to **embolic occlusion**, most often due to thromboemboli from cardiac chambers and less frequently due to atheroemboli. Embolic infarction produces a hemorrhagic infarct. Small-vessel disease is a cause of small, lacunar infarcts or lacunae, and it is related to hypertension, resulting in hyaline arteriolosclerosis.
 - The **pathology** (i.e., morphological features of brain infarcts) of infarction is illustrated in Table 21-3. Clinical manifestations depend on the affected arterial distribution.

Table 21-3. Gross and Microscopic Changes Associated with Cerebral Infarction

Time	Gross Changes	Microscopic Changes
0–12 h	No changes	Minimal or no changes
12–24 h	Minimal changes	Red (hypereosinophilic) neurons with pyknotic nuclei
24–48 h	Indistinct gray-white matter junction	Neutrophilic infiltration
2–10 d	Friable tissue with marked edema	Histiocytic infiltration; neurons disappear
2–3 wk	Tissue liquefies	Liquefactive necrosis; histiocytes filled with products of myelin breakdown
3 wk–mo	Fluid-filled cavity demarcated by gliotic scar	Fluid-filled cavity; reactive astrocytes and lipid-laden macrophages
Years	Old cyst surrounded by gliotic scar	Astrogliosis surrounding a cyst

Note: Hemorrhagic infarct leads to erythrocyte degradation and hemosiderin deposition.

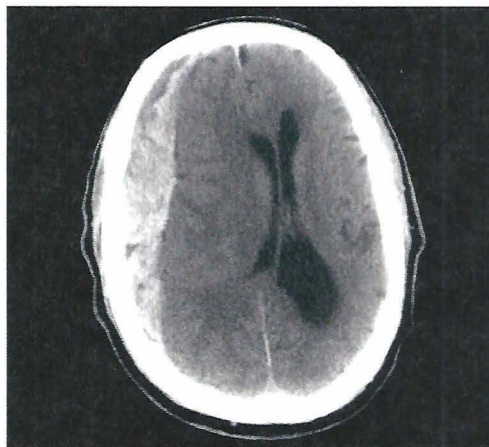- e. **Hemorrhage** causes 15% of strokes.
- i. **Intracerebral (intraparenchymal) hemorrhage** is most frequently due to hypertension, and in those instances, it most commonly involves the basal ganglia, cerebellum, pons, and centrum semiovale. Other causes of intracerebral hemorrhage include vascular malformations (especially arteriovenous malformations), cerebral amyloid angiopathy, neoplasms, vasculitides, abnormal hemostasis, hematological malignancies, infections, and diabetes mellitus. Intracerebral hemorrhage causes severe headache, frequent nausea/vomiting, steady progression of symptoms over 15–20 minutes, and coma.
 - ii. **Epidural hemorrhage** is virtually always traumatic, being usually associated with skull fracture; this produces a tearing of dural arteries, most frequently the middle meningeal artery. Epidural hemorrhage leads to cerebral herniation (usually subfalcine) if not promptly evacuated. There is often a lucid interval before loss of consciousness (“talk and die syndrome”).



© Andrew Mullins, National Naval Medical Center.
Used with permission.

Figure 21-2. Epidural Hematoma

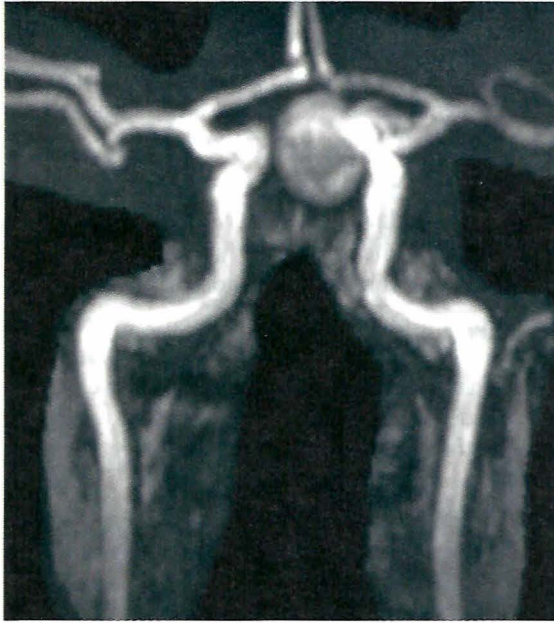- iii. **Subdural hemorrhage** is usually traumatic in older individuals, and is caused by the rupture of bridging veins (from the cerebral convexities to the sagittal sinus). Predisposing conditions include brain atrophy (due simply to aging) and abnormal hemostasis. Subdural hemorrhage causes headache, drowsiness, focal neurological deficits, and sometimes dementia. It recurs frequently.



© Brendan T Doherty, National Capital Consortium.
Used with permission.

Figure 21-3. Subdural Hematoma

- iv. **Subarachnoid hemorrhage** is most frequently caused by ruptured berry aneurysm. Less frequent causes include extension of an intracerebral or subdural hematoma, vascular malformations, trauma, abnormal hemostasis, and tumors. Subarachnoid hemorrhage causes sudden (“thunderclap”) headache, nuchal rigidity, neurological deficits on one side, and stupor.
- f. **Berry aneurysms** are thin-walled saccular outpouchings, consisting of intima and adventitia only. They are the most frequent cause of subarachnoid hemorrhage. The most frequent sites are on the anterior circle of Willis at branching points. Rupture is precipitated by a sudden increase in blood pressure; the prognosis after rupture is that one-third die, one-third recover, and one-third rebleed.



© Charles Gould - National Capital Consortium.
Used with permission.

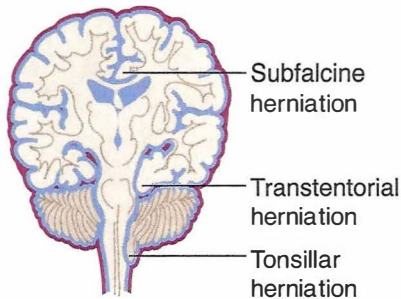
Figure 21-4. Large berry aneurysm seen on angiography of circle of Willis.

- i. The **pathogenesis** involves a congenital focal weakness of artery that is not identifiable at birth. Associated disorders include Marfan syndrome, Ehlers-Danlos type 4, and adult polycystic kidney disease. Hypertension and cigarette smoking predispose to formation.

CNS TRAUMA

1. Cranial cavity and brain

- a. **Concussion** is mild traumatic brain injury with a transient loss of brain function. The trauma is commonly due to a change in the momentum of the head (impact against a rigid surface). Concussion causes loss of consciousness and reflexes, temporary respiratory arrest, and amnesia for the event. The pathogenesis is uncertain. Parenchymal injuries may or may not be evident at autopsy.
- b. **Contusions** are bruises of the brain tissue. Common sites of injury include crests of orbital gyri in frontal and temporal poles, in addition to *coup* (site of injury) and *contrecoup* (site diametrically opposite) injuries. Coup and contrecoup develop when the head is mobile at the time of impact.
 - i. **Pathology.** **Acute contusion** is characterized by hemorrhage of brain tissue in a wedge-shaped area. **Subacute** contusion shows necrosis and liquefaction of brain. **Remote contusion** causes a depressed area of cortex with yellow discoloration (“*plaque jaune*”).
- c. **Diffuse axonal injury** refers to damage to axons at nodes of Ranvier with impairment of axoplasmic flow. It causes coma after trauma without evidence of direct parenchymal injuries. There is a poor prognosis, related to duration of coma. The injury to the white matter is due to acceleration/deceleration.
 - i. The **histopathology** shows axonal swellings appreciable in the white matter. It is diffuse, but with a predilection for the corpus callosum, periventricular white matter, and hippocampus, as well as cerebral and cerebellar peduncles.



Cerebral Herniations

Note

Open neural tube defects (not spina bifida occulta) lead to increased alpha-fetoprotein during pregnancy, which, in conjunction with ultrasound, allows prenatal diagnosis.

2. **Spinal cord injuries** are usually traumatic, due to vertebral displacement. Symptomatology depends on the interruption of ascending and descending tracts. Lesions to thoracic segments or below cause **paraplegia**. Lesions to cervical segments cause **tetraplegia**. Lesions above C4 cause respiratory arrest due to paralysis of the diaphragm.
3. **Cerebral herniations.**
 - a. **Subfalcine (cingulate gyrus) herniation** occurs when the cingulate gyrus is displaced underneath the falx to the opposite side. Compression of the anterior cerebral artery can occur.
 - b. **Transtentorial (uncal) herniation** occurs when the uncus of the temporal lobe is displaced over the free edge of the tentorium. Clinical features include compression of the third nerve, pupillary dilatation on the same side, and infarctions in dependent territory. Advanced stages of transtentorial herniation can cause Duret hemorrhage within the central pons and midbrain.
 - c. **Cerebellar tonsillar herniation** occurs when there is displacement of cerebellar tonsils through the foramen magnum. Compression of the medulla leading to cardiorespiratory arrest can occur.

DEVELOPMENTAL ABNORMALITIES

1. **Neural tube defects** are the most common developmental central nervous system abnormalities. They result from defective closure of the neural tube, and they tend to occur at the two extremities of the neuraxis. Folate deficiency is involved in pathogenesis.
 - a. **Anencephaly** is the absence of cranial vault. Anencephaly is incompatible with life; babies die soon after birth.
 - b. **Neural tube defects of the spinal cord** may take a variety of forms. Significant defects lead to paraplegia and urinary incontinence from birth.
 - **Spina bifida occulta** is a bony defect of the vertebral arch.
 - **Meningocele** is a bony defect with outpouching of meninges.
 - **Meningomyelocele** is a defective formation of the bony arch with cystic outpouching of meninges, spinal cord, and spinal roots.
 - **Myelocele** is a defective bony arch with complete exposure of the spinal cord.

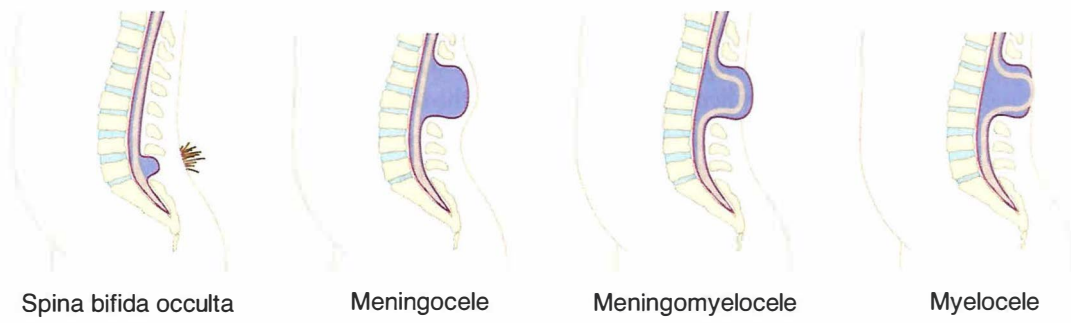
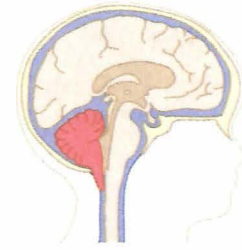


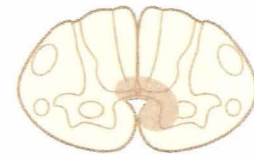
Figure 21-5. Neural Tube Defects of the Spinal Cord

2. Arnold-Chiari malformations.

- a. **Type 1** is a downward displacement of cerebellar tonsils and the medulla through the foramen magnum. This lesion is common, but mostly asymptomatic.
 - b. **Type 2** is due to a faulty craniospinal junction, resulting in a small posterior fossa, with abnormal development of the cerebellar vermis and medulla leading to downward displacement. This type of malformation is most often symptomatic, because of compression of the fourth ventricle with obstructive hydrocephalus. There are frequently also other related manifestations, such as syringomyelia and lumbar meningocele.
3. **Syringomyelia** refers to an ependymal-lined, CSF-filled channel parallel to and connected with central canal in the spinal cord. (*Hydromyelia* means the central canal is simply dilated.) 90% of cases are associated with Arnold-Chiari type 2; the remaining cases are post-traumatic or associated with intraspinal tumors. *Syrinx* (the cyst) enlarges progressively and destroys the spinal parenchyma. Symptoms include paralysis and loss of sensory functions.
 4. **Perinatal brain injury** is injury to the brain during prenatal or immediately postnatal period. This is the most common cause of cerebral palsy, and it occurs most frequently in premature babies. **Germinal matrix hemorrhage** is hemorrhage localized in the germinal matrix due to its fragile vessels. **Periventricular leukomalacia** causes infarcts in watershed areas (periventricular white matter in the fetus). **Multicystic encephalopathy** refers to multiple brain infarcts occurring early in pregnancy.
 5. **Dandy-Walker malformation** is a non-communicating hydrocephalus with dilation of the fourth ventricle and hypoplasia of the cerebellar vermis.



Arnold-Chiari Malformation



Syringomyelia

DEMYELINATING DISORDERS

1. **Multiple sclerosis (MS)** is a chronic relapsing-remitting disorder of probable autoimmune origin characterized by recurrent episodes of demyelination in the brain (including optic nerves) and spinal cord; it results in progressive neurological deficits.
 - a. **Epidemiology.** The overall prevalence is 1/1,000, with higher prevalence in northern countries. Persons who emigrate after age 15 from areas of high prevalence to areas of low prevalence maintain their original risk. Women have double the risk of men. The clinical onset is typically in the third or fourth decade.
 - b. The **etiopathogenesis** (the cause and development of a disease or abnormal condition) is multifactorial.
 - i. **Genetic factors** appear to be important, as there is a familial propensity, with concordance rate in twins being 25% in monozygotic twins and 2% in dizygotic twins. There is also a strong association with HLA-DR2.
 - ii. **Immune factors** are also known to be important, and the CD4 lymphocytic infiltrate in lesions is known to be oligoclonal. Experimental allergic encephalitis (EAE), an experimental model for MS, can be obtained by injection of myelin basic protein (MBP). T_{H1} cytokines (IF- γ and TNF) facilitate experimental allergic encephalitis; T_{H2} cytokines (IL-4 and IL-10) retard it. Infectious agents that are suspected but not proven to trigger MS include mumps, rubella, Herpes simplex, measles, and JC virus.

- c. **Pathology.** Acute lesions form well-circumscribed plaques, with loss of myelin.
 - i. **Acute lesions** on gross examination show well circumscribed gray lesions (the same color as gray matter), with bilateral distribution that is frequently periventricular. Histology shows chronic inflammation with phagocytosis of myelin by macrophages; axons are initially preserved.
 - ii. **Chronic lesions** have no inflammation, with axons showing remyelination. Remyelination is defective because myelin sheaths are thinner with shorter internodes.
 - d. **Pathophysiology.** During an acute attack, nerve conduction is entirely blocked, leading to acute neurological deficits. Chronic plaques are associated with slower nerve conduction, allowing for partial recovery. Recurrent attacks cause progressive neurological deterioration.
 - e. **Clinical course.** 85% of cases show a relapsing-remitting course. A minority of cases show primary progressive (slow deterioration) or progressive-relapsing (slow progression punctuated by acute exacerbations) course. Recovery from each episode of demyelination occurs in weeks or months.
 - f. **Symptomatology.** Symptoms vary with the plaque location, and may include blurred vision or loss of vision in one eye (optic nerve involvement); diplopia and vertigo (brain stem involvement); loss of sensation or weakness in one leg (spinal cord involvement); and hemiparesis or loss of sensation in half of the body (cerebral white matter involvement). Many other symptoms may also occur, sometimes of neuropsychiatric nature.
 - g. **Treatment.** During an acute attack, high-dose steroids facilitate recovery. Chronic treatment slows progression of disease. Interferon- β and copolymer 1 (Copaxone) are sometimes used.
2. **Central pontine myelinolysis (CPM)** is a focal demyelination of central area of the *basis pontis*. Patients at risk include the severely malnourished and alcoholics with liver disease. CPM probably derives from rapid correction of hyponatremia, and the condition is very often fatal.

DEGENERATIVE AND DEMENTING DISORDERS

1. **Parkinson disease and syndrome.** These conditions are both due to loss of dopaminergic neurons in the substantia nigra, leading to tremor, rigidity, and akinesia. Parkinson disease is the idiopathic form. Parkinson syndrome is secondary to known injuries to the substantia nigra (e.g., infections, vascular conditions, toxic insults).
 - a. **Epidemiology.** Parkinson disease is a common disease that affects 2% of the population. It arises in the fifth to eighth decade of life, and does not have any known genetic-familial, sex, or race predisposition.
 - b. **Etiopathogenesis.** Loss of dopaminergic neurons is still unexplained in Parkinson disease. Theories emphasize oxidative stress. Accidental exposure to 1-methyl-4-phenyl-1,2,3,6-tetrahydropyridine (MPTP) (a by-product of illicit synthesis of a meperidine [Demerol] analogue) causes death of dopaminergic neurons in substantia nigra.
 - c. **Pathology.** Grossly, there is pallor of the substantia nigra. Histology shows loss of pigmented (dopaminergic) neurons in the substantia nigra. Other features include Lewy bodies, which are intracytoplasmic round eosinophilic inclusions that contain α -synuclein; electron microscopy shows filaments most likely of cytoskeletal origin. There is also a secondary degeneration of dopaminergic axons in the striatum.

- d. **Pathophysiology.** Loss of the extrapyramidal *nigrostriatal pathway* leads to inhibition of movement of proximal muscles and disruption of fine regulation of distal muscles. The pathophysiologic basis of Parkinson disease-associated dementia is not clear.
- e. **Clinically,** there is slowing of all voluntary movements; tremor at rest which disappears during movement; expressionless face; and rigidity of limbs and trunk accompanied by an inability to initiate voluntary movement. There is an increased incidence (20–40% of patients) of dementia and depression. Levodopa is the treatment of choice, usually combined with other drugs.
2. **Huntington disease (HD)** is an autosomal dominant disorder characterized pathologically by the degeneration of GABA-ergic neurons of the caudate nucleus, and clinically by chorea and dementia.
- a. **Epidemiology.** HD affects those of northwestern European descent and has an incidence in high-prevalence regions of 1/12,000–20,000. No cases are known due to new mutations. The HD gene is located on chromosome 4 and codes for a protein called huntingtin. Mutations are due to expansion of an unstable trinucleotide repeat. HD shows features of anticipation and genomic imprinting.
- b. **Pathology.** Gross examination shows atrophy of the caudate nucleus with secondary ventricular dilatation. Histology shows loss of small neurons in the caudate nucleus followed by loss of the larger neurons. The pathophysiology is that loss of caudate nucleus GABA-nergic neurons removes inhibitory influences on extrapyramidal circuits, thus leading to chorea.
- c. **Clinical manifestations.** The disease manifests between age 20 and 40. The chorea is characterized by sudden, unexpected, and purposeless contractions of proximal muscles. Patients may also have changes in personality, marked tendency for suicide, and dementia. Genetic diagnosis is possible but controversial. Treatment is with antipsychotic drugs (e.g., haloperidol).

Table 21-4. The Dementias

Frequent Causes	Less Frequent Causes
Alzheimer disease	Pick disease
Lewy body dementia	Primary subcortical degenerations: Parkinson disease, multiple system atrophy, Huntington disease, progressive supranuclear palsy
Vascular dementia	Prion diseases (Creutzfeldt-Jakob)
Mixed Alzheimer and vascular	Normal pressure hydrocephalus dementia

3. **Alzheimer disease (AD)** causes 60% of all cases of dementia, with incidence of 2% at 65 years and doubling every 5 years. Risk factors include aging, significant head trauma, and familiarity; aluminum is an epiphenomenon, *not a risk factor*. Protective factors include a high level of education and smoking.
- a. **Genetic factors.** 5–10% of Alzheimer disease cases are hereditary, early onset, and transmitted as an autosomal dominant trait.

Table 21-5. Genetics of Alzheimer disease

Mutations known to cause AD:

- **Amyloid precursor protein (APP) gene (chromosome 21)**

Virtually all Down syndrome patients are destined to develop AD in their 40s. Down patients have triple copies of the APP gene.

- **Presenilin-1 gene (chromosome 14): majority of hereditary AD cases**

Mutations of presenilin-2 gene (chromosome 1)

AD caused by all of the above mutations is early in onset.

- **Apolipoprotein E gene:**

There are 3 allelic forms of this gene, $\epsilon 2$, $\epsilon 3$, and $\epsilon 4$

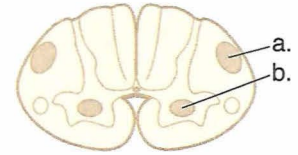
The allele $\epsilon 4$ of apolipoprotein E (ApoE) increases the risk for AD:

- $\epsilon 4$ allele is overrepresented in AD patients.
- $\epsilon 2$ is underrepresented; it confers relative protection.

AD associated with $\epsilon 4$ ApoE allele is late in onset.

- b. **Pathology.** Alzheimer disease is characterized by accumulation of abnormal proteins intracellularly and extracellularly.
 - i. **Abnormal proteins.** $A\beta$ amyloid is a 42-residue peptide derived from a normal transmembrane protein, the amyloid precursor protein (APP). There is also an abnormal *tau* (a microtubule-associated protein).
 - ii. **Neuritic plaques** have a core of $A\beta$ amyloid surrounded by dystrophic neuritic/dendritic processes and associated with microglia and astrocytes.
 - iii. **Neurofibrillary tangles** are intraneuronal aggregates of insoluble cytoskeletal elements, mainly composed of abnormally phosphorylated tau forming paired helical filaments.
 - iv. **Cerebral amyloid angiopathy** refers to accumulation of $A\beta$ amyloid within the media of small and medium-size intracortical and leptomeningeal arteries; it may occur by itself and cause intracerebral hemorrhage.
 - v. **Additional changes** include granulovacuolar degeneration and Hirano bodies, which develop in the hippocampus and are less significant diagnostically.
 - vi. **Location.** Lesions involve the neocortex, hippocampus, and several subcortical nuclei including forebrain cholinergic nuclei (i.e., basal nucleus of Meynert). Affected areas are involved in learning and memory. The earliest and most severely affected are the hippocampus and temporal lobe. Small numbers of neuritic plaques and neurofibrillary tangles also form in intellectually normal aging persons.
 - vii. **Macroscopic changes** include atrophy of affected regions, producing brains that are smaller (atrophic), with thinner gyri and wider sulci. Hippocampi and temporal lobes are markedly atrophic.
- c. **Clinical manifestations** have insidious onset, beginning usually in the seventh or eighth decade. They include progressive memory impairment, especially related to recent events; alterations in mood and behavior; progressive disorientation; and aphasia (loss of language skills) and apraxia (loss of learned motor skills). Within 5–10 years, patients become mute and bedridden. No effective treatment is available, but there is mild improvement with inhibitors of acetylcholinesterase (e.g., tacrine).

4. **Lewy body dementia** is a progressive brain disease associated with the formation of Lewy bodies in neurons involving neocortex and subcortical nuclei. The etiopathogenesis is obscure, with no known risk factors; it is the second leading cause of degenerative dementia in the elderly.
 - a. **Pathology.** The histopathological hallmark is the *Lewy body* (see Parkinson disease). Neuron loss accompanies Lewy body formation. Sites involved include the neocortex (especially the *limbic system* and *cingulate gyrus*), and subcortical nuclei, including basal nucleus of Meynert, amygdala, and substantia nigra.
 - b. **Pathophysiology.** The involvement of the neocortex and substantia nigra is responsible for cognitive deterioration and parkinsonism. Clinical manifestations include memory loss, parkinsonism, and visual hallucinations. There is a possible treatment benefit from cholinesterase inhibitors.
5. **Amyotrophic lateral sclerosis (ALS)** refers to degeneration and loss of upper and/or lower motor neurons that usually manifests in middle age. The clinical diagnosis is supported by a biopsy of muscles. The etiopathogenesis is obscure, but 5–10% of cases are hereditary, with a small number being due to mutation of the gene encoding *zinc-copper superoxide dismutase* on chromosome 21.
 - a. **Loss of upper motor neurons** produces hyperreflexia and spasticity. In some cases, involvement of cranial nerve nuclei also occurs.
 - b. Loss of **lower motor neurons** produces weakness, atrophy, and fasciculations.
6. **Friedreich ataxia** is an autosomal recessive disorder with onset in early childhood leading to degeneration of nerve tissue in the spinal cord, especially those sensory neurons connected to the cerebellum affecting muscle movement of the arms and legs.
 - a. **Genetics.** Friedreich ataxia is due to the expansion of an unstable triplet nucleotide repeat (GAA repeats in the first intron) in the *frataxin* gene on chromosome 9. The frataxin protein is essential for mitochondrial function by helping in mitochondrial iron regulation; in the absence of frataxin, mitochondrial iron builds up, leading to free radical damage and mitochondrial dysfunction.
 - b. **Pathology.** The mitochondrial dysfunction leads to degeneration involving multiple groups of neurons:
 - Dorsal root ganglia
 - Clarke column (origin of spinocerebellar tract)
 - Neurons of posterior column of spinal cord
 - Cranial nerve nuclei of VII, X, and XII
 - Dentate nucleus and Purkinje cells of cerebellum
 - Betz neurons of primary motor cortex
 - c. **Clinical manifestations** include gait ataxia, dysarthria, hand clumsiness, loss of sense of position, impaired vibratory sensation, and loss of tendon reflexes. Patients become wheelchair-bound by age 5 years.
7. **Wilson disease** is an autosomal recessive genetic abnormality of the Wilson disease protein which leads to defective synthesis of ceruloplasmin and copper accumulation in the liver and brain. Some patients develop cirrhosis as children or teenagers, while others present with neuropsychiatric symptoms and ataxia (due to basal ganglia involvement) in their 20s and 30s. Other problems that may occur include Kayser-Fleisher (golden-brown) rings in Descemet membrane of the eye, renal tubular acidosis, cardiomyopathy, and hormonal disturbances.



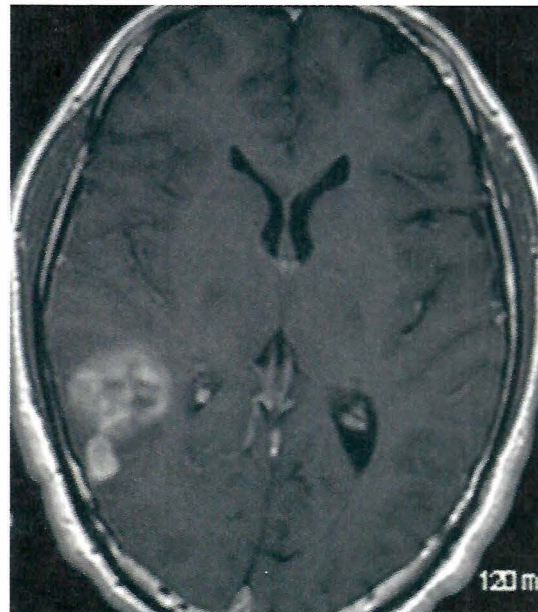
Amyotrophic Lateral Sclerosis (ALS)

- a. Primary lateral sclerosis (corticospinal tract)
- b. Progressive spinal muscular atrophy (ventral horn)

8. **Acute intermittent porphyria** is an autosomal dominant defect in porphyrin metabolism with deficient uroporphyrinogen synthase. Both porphobilinogen and aminolevulinic acid increase. Urine is initially colorless but on exposure to light turns dark red. Patients may develop recurrent severe abdominal pain, psychosis, neuropathy, and dementia.
9. **Vitamin B12 deficiency.** In addition to megaloblastic anemia, vitamin B12 deficiency causes demyelination of the spinal cord posterior columns and lateral corticospinal tracts (subacute combined degeneration of the spinal tract). Vitamin B12 deficiency also causes dementia and peripheral neuropathy.
10. **Alcohol abuse** causes generalized cortical and cerebellar atrophy, as well as Wernicke-Korsakoff syndrome. The neurologic disease is usually related to thiamine deficiency. There can be hemorrhages in mamillary bodies and walls of third and fourth ventricles. Neuronal loss and gliosis may be prominent. Wernicke encephalopathy has reversible confusion, ataxia, and nystagmus. Korsakoff psychosis is more severe and has irreversible anterograde and retrograde amnesia. Central pontine myelinolysis (see earlier section in this chapter) may cause death.

CNS TUMORS

1. **Epidemiology.** Half of all brain and spinal cord tumors are metastatic. The most frequent primary central nervous system tumors are **meningiomas** and **glioblastoma multiforme**. Primary malignant CNS tumors account for 2–3% of all cancer deaths in the United States.



© Steven J Goldstein - University of Kentucky.
Used with permission.

Figure 21-6. White mass in the cerebral cortex showing a glioblastoma multiforme

2. **Clinical manifestations** include headache (often worse at night or early morning); seizures (tumors involving cerebral cortex); and mental changes (e.g., deficits in memory, concentration, reasoning). Focal neurological symptoms are related to involvement of specific brain regions. Symptoms

related to increased intracranial pressure are due to the presence of a space-occupying mass within the cranial cavity, blockage of cerebral spinal fluid flow, and edema around the tumor (peritumoral edema).

3. **Special features of brain tumors.** The concept of benign versus malignant neoplasm must be revised; consider that **malignant CNS tumors do not metastasize outside the cranial cavity**. Clinical consequences depend on **infiltrative behavior and location**.

Table 21-6. Primary Versus Metastatic Tumors

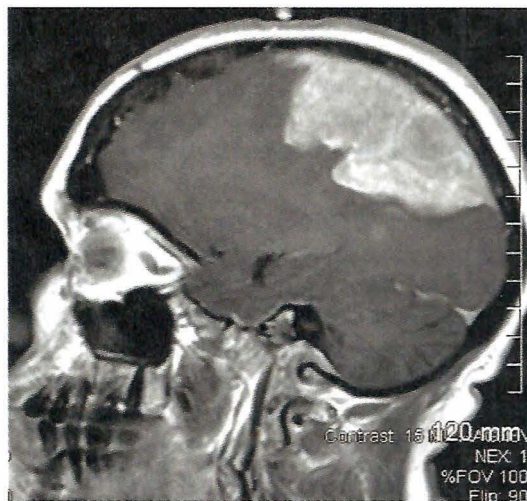
Primary	Metastatic
Poorly circumscribed	Well circumscribed
Usually single	Often multiple
Location varies according to specific type	Usually located at the junction between gray and white matter

4. **Astrocytomas** originate from astrocytes and exhibit fibrillary background, immunoreactivity for glial fibrillary acidic protein (GFAP), and diffuse (ill-demarcated) pattern of growth.
 - a. **Grading** is important for both prognosis and treatment. The most frequent systems used in the United States and Europe are the Daumas-Duport and WHO. Both systems identify 4 grades based on nuclear atypia (pleomorphism), mitoses, necrosis, and vascular endothelial hyperplasia due to increased production of vascular endothelial growth factor.
 - i. **Grade 1 pilocytic astrocytomas** are well-differentiated, benign astrocytic tumors that arise throughout the neuraxis, and are common in children and in young adults. Sites of involvement include the posterior fossa (cerebellum) and diencephalon. Pilocytic astrocytoma often presents as a cystic lesion with a mural nodule. Histology shows spindly neoplastic astrocytes with long bipolar processes. These tumors are rich in Rosenthal fibers, thick corkscrew-like eosinophilic structures that derive from hypertrophic processes of astrocytes. There is a favorable prognosis for posterior fossa tumors.
 - ii. **Grade 2 fibrillary astrocytomas** arise in the cerebral hemisphere of young to middle-aged adults and the brain stem of children.
 - iii. **Grade 3 astrocytomas** are anaplastic astrocytomas.
 - iv. **Grade 4 astrocytomas** are called *glioblastoma multiforme*, and are the most common CNS primary malignancy in adults. Histology shows marked nuclear atypia, mitoses, necrosis, and vascular endothelial hyperplasia. The characteristic histopathological feature is an area of necrosis surrounded by rows of neoplastic cells (pseudopalisading necrosis). Glioblastoma multiforme spreads through cerebrospinal fluid; vascular endothelial hyperplasia is often florid, giving rise to *glomeruloid formations*. The most common location is white matter, commonly in the centrum semiovale.
 - b. **Prognosis.** Well-differentiated astrocytomas affect younger patients and grow slowly. Anaplastic astrocytomas and glioblastoma multiforme are aggressive and affect older patients.

Note

Glioblastoma multiforme has a tendency to cross the midline by involving the corpus callosum (“butterfly glioma”).

5. **Oligodendroglioma** is a glioma of oligodendroglial origin that occurs in 30- to 50-year-old patients, typically in the white matter of cerebral hemispheres adjacent to neocortex. It often manifests with seizures. The histology characteristically shows neoplastic cells similar to oligodendroglia with pronounced perinuclear halo (“fried-egg” appearance). The capillary network shows a prominent “chicken-wire” pattern. Oligodendrogliomas are slow-growing tumors that allow long survival (average 5–10 years), but they tend to recur after surgery and eventually degenerate into high-grade gliomas over time.
6. **Ependymoma** is a glioma of ependymal origin typically located in the fourth ventricle in children and in the lateral ventricle or spinal canal in adults. It often presents with obstructive hydrocephalus, when present in the fourth ventricle. It tends to recur after surgery and to acquire more aggressive behavior.
 - a. **Pathology.** The gross appearance shows a circumscribed tumor with papillary architecture. On microscopic examination, the neoplastic cells resemble ependymal cells, and characteristically show *ependymal rosettes* (tumor cells organized around a lumen) and *perivascular pseudorosettes* (tumor cells arranged around small vessels).
7. **Meningioma** is a tumor that originates from meningotheial cells of the arachnoid. Meningiomas are tumors of adulthood (women more than men) and are rare in children, generally, they have good prognosis. Tumors in some locations may not be amenable to complete resection.



© Steven J Goldstein - University of Kentucky.
Used with permission.

Figure 21-7. Large meningioma pushing into the cerebral cortex. Note the thin dark shadow around the lesion that occurs because the tumor is not actually invading the brain.

- a. **Pathology.** Grossly, meningiomas attach to the dura, and push underlying brain without invasion. Microscopically, meningiomas are composed of spindle-shaped cells with indistinct borders (*syncytial*); the cells are arranged in whorls or fascicles, and psammoma bodies are frequent. Meningiomas may develop at any meningeal site, most frequently on the dural convexities.

8. **Primitive neuroectodermal tumors** are highly undifferentiated tumors which originate from a primordial neuroglial precursor. They are variably named, depending on location in the brain; the most frequent of these tumors are *medulloblastoma* and *retinoblastoma*. All primitive neuroectodermal tumors:

- Develop in children
- Histology: *blue, small, round cell tumors*, with *pseudorosettes*
- Highly aggressive but responsive to radiation therapy

Medulloblastoma arises in the cerebellar vermis (midline location); grows rapidly and spreads through CSF; and has a 5-year survival of 75% if treated with resection and radiation therapy.

9. **Schwannoma** is a tumor that originates from Schwann cells of cranial or spinal nerves. The most frequent location is on the eighth cranial nerve at the cerebellopontine angle (CPA). Schwannoma manifests characteristically with loss of hearing and tinnitus. There is a good prognosis after surgical resection.

a. **Microscopic features.** Schwannoma has spindly cells arranged in hypercellular Antoni A areas; alternating hypocellular Antoni B areas; and *Verocay bodies*, parallel rows of neoplastic Schwann cells. The neoplastic cells are immunoreactive for a protein called S-100 (S-100 tumor antigen is 100% soluble in ammonium sulfate at neutral pH).

10. **Craniopharyngioma** is a tumor that arises from rests of odontogenic epithelium within the suprasellar/diencephalic region. Patients affected are usually children or young adults. The tumor contains deposits of calcium, evident on x-rays. The histology resembles *adamantinoma*, a rare low-grade primary bone tumor of unknown histological origin that is the most common tumor of the tooth. Craniopharyngioma is benign but tends to recur after resection.

Note

Bilateral acoustic schwannomas are pathognomonic of neurofibromatosis type 2.

Clinical Correlate

Craniopharyngioma

The most common presenting symptoms are headache, endocrine dysfunction, and visual disturbances.

Chapter Summary

- Acute aseptic (viral, most commonly enterovirus) meningitis causes a lymphocytic infiltration of the leptomeninges with clinical features of fever, meningeal irritation, depressed consciousness, and low mortality. Acute purulent meningitis (*Escherichia coli* and group B streptococci in neonates; *Haemophilus influenzae* in infants and children; *Neisseria meningitidis* in adolescents and young adults; *Streptococcus pneumoniae* and *Listeria monocytogenes* in elderly persons) causes a neutrophilic infiltration of the leptomeninges with clinical features of diffuse cerebral edema with risk of fatal herniation, headache, fever, nuchal rigidity, cloudy sensorium, coma, late hydrocephalus, and late neural deafness or other cranial nerve impairment. Mycobacterial (either *M. tuberculosis* or atypicals such as MAI, particularly in AIDS patients) meningoencephalitis causes tuberculomas of the basal surface of the brain and dura mater.
- Viral encephalitides in general show perivascular cuffs, microglial nodules, and neuronophagia microscopically, and clinically cause mental status changes, fever, headache, and often progression to coma. Specific types include arthropod-borne (St Louis, various equine, and Venezuelan encephalitides), *Herpes simplex type 1* (predilection for hemorrhagic necrosis of temporal lobes with viral inclusions), rabies (rare, Negri bodies in hippocampal and Purkinje neurons), and HIV (AIDS-dementia complex with microglial nodules and multinucleated giant cells, vacuolar myelopathy of spinal cord). Progressive multifocal leukoencephalopathy can be considered a subtype of viral encephalitis related to *JC virus* infection in immunocompromised patients that microscopically produces demyelination, bizarre astrocytes, and oligodendrocytes with intranuclear inclusions.
- Fungal meningoencephalitis can be due to *Candida*, *Aspergillus* (vasculitis with hemorrhage), *Mucor* (vasculitis with hemorrhage), and *Cryptococcus* (invasion of brain through Virchow-Robin spaces with formation of “soap bubble lesions”). Toxoplasmosis occurs in AIDS patients and causes cerebral abscess/focal necrosis that may be seen on MRI/CT as ring-enhancing lesions. Cerebral abscess due to bacteria can complicate a variety of medical conditions (acute bacterial endocarditis, chronic pulmonary abscess, cyanotic heart disease with right-to-left shunt, mastoiditis, sinusitis, otitis, open fracture, prior neurosurgery) and causes increased intracranial pressure, focal neurologic defects, and a ring-enhancing lesion on CT/MRI.
- Subacute sclerosing panencephalitis is a potentially fatal slow-virus encephalitis that can follow measles infection.
- Creutzfeldt-Jakob disease is caused by a conformational change in a prion protein that leads to spongiform vacuolar degeneration of neurons with kuru plaques in the neuropil; rapidly progressive dementia, memory loss, and involuntary movements; death within 6 to 12 months.
- Cerebrovascular disease is the third most frequent cause of death in industrialized countries and can occur in several clinicopathological forms, including global cerebral ischemia (overall drop in blood flow/oxygenation of brain that can, if severe, cause brain death; most vulnerable sites are Purkinje neurons, hippocampus CA1, and pyramidal neurons of cortex), transient ischemic attack (reversible focal neurologic symptoms due to small platelet thrombi or atheroemboli), infarction (85% of strokes), and hemorrhage (15% of strokes).

(Continued)

Chapter Summary (*cont'd*)

- Infarctions can be due to atherosclerosis with superimposed thrombosis (anemic: white infarct), thromboemboli (hemorrhagic: red infarct), or small vessel disease (tiny lacunar infarcts). Infarcted brain tissue undergoes liquefactive necrosis (most prominent at 2–3 weeks) to produce eventual cyst formation. Common neurovascular syndromes after stroke include the anterior cerebral artery syndrome (weakness and sensory loss in contralateral leg, transient aphasia, abulia), the middle cerebral artery syndrome (contralateral hemiplegia of face and arm with gaze palsy, contralateral sensory loss, and sometimes aphasia), the posterior cerebral artery syndrome [contralateral hemianopia or total cortical blindness, alexia (inability to read), thalamic syndrome], and dementia (secondary to recurrent infarcts or small vessel disease).
- Hemorrhage causes 15% of strokes and occurs in several forms, including epidural hemorrhage (traumatic, often involves middle meningeal artery in dura, can cause subfalcine or other cerebral herniation, “talk and die syndrome”), subdural hemorrhage (traumatic, rupture of bridging veins, risk factors of cerebral atrophy and abnormal hemostasis, various neurologic symptoms, often recurs), subarachnoid hemorrhage (ruptured berry aneurysm or other causes, “thunderclap” headache, nuchal rigidity, neurologic deficits, stupor), and intracerebral hemorrhage (hypertension, vascular malformation, or less commonly, many other predisposing conditions: basal ganglia, cerebellum, pons, or centrum ovale, severe headache with rapid progression of symptoms, often to coma).
- Berry aneurysms of the circle of Willis (risk factors include hypertension, cigarette smoking, Marfan syndrome, Ehlers-Danlos type 4, and adult polycystic kidney disease) are the most frequent cause of subarachnoid hemorrhage (1/3 die, 1/3 recover, and 1/3 re-bleed with risk of death).
- CNS trauma to the cranial cavity and brain can take several forms, including concussion (transient loss of consciousness after impact against a rigid surface), contusions (brain bruises, sometimes in a coup and contrecoup pattern, can cause local infarction), and diffuse axonal injury (sudden acceleration/deceleration stretches and “pops” axons, producing little gross injury, but coma can occur, which can be permanent). CNS trauma to the spinal cord is usually due to vertebral displacement, and can cause paraplegia (thoracic segments or below), tetraplegia (cervical segments), and paralysis of the diaphragm (above C4).
- Cerebral herniations can take several forms, including subfalcine (cingulate gyrus goes under falx and can compress the anterior cerebral artery), transtentorial (temporal lobe uncus goes under the tentorium, can compress the third nerve, and cause Duret hemorrhage in brain stem), and cerebellar tonsillar (goes through the foramen magnum to compress the medulla causing cardiorespiratory arrest).
- Neural tube defects (risk factor: folate deficiency) are the most common developmental CNS abnormalities and can take several forms, including anencephaly (no cranial vault, death in infancy), spina bifida occulta (bony defect of the vertebral arch), meningocele (bony defect with outpouching of meninges), meningomyelocele (with outpouching meninges, spinal cord, and spinal roots), and myelocele (complete exposure of spinal cord). Paraplegia and urinary incontinence may complicate the more severe spinal cord defects.

(Continued)

Chapter Summary (*cont'd*)

- Arnold-Chiari malformation type I (common, often asymptomatic) is a downward displacement of the cerebellar tonsils. Type 2 (often symptomatic) has a small posterior fossa, downward displacement of cerebellar vermis and medulla, compressed fourth ventricle with obstructive hydrocephalus, and frequent lumbar meningocele and syringomyelia (CSF-filled channel near central canal; most often related to Arnold-Chiari type 2).
- Perinatal brain injury (risk factor prematurity) can cause cerebral palsy, germinal matrix hemorrhage, periventricular leukomalacia, and multicystic encephalopathy. Dandy-Walker malformation is a cause of noncommunicating hydrocephalus characterized by cerebellar vermis hypoplasia and enlarged fourth ventricle.
- Multiple sclerosis is a chronic relapsing-remitting disorder of probable autoimmune origin characterized by recurrent episodes of demyelination (causing “plaques”) and defective remyelination in the brain (including optic nerves) and spinal cord, which results in progressive (but variable in time and from person to person) neurological deficits (visual changes, sensation changes, motor changes, neuropsychiatric disturbances). Central pontine myelinosis is a rare, potentially fatal, focal demyelination of the basis pontis possibly related to over-rapid correction of hyponatremia in malnourished patients and alcoholics.
- Parkinson disease is one of the degenerative and dementing disorders of the brain and features loss of substantia nigra dopaminergic neurons with Lewy body formation, tremor, rigidity, and akinesia. Huntington disease is an autosomal dominant disorder that presents in young to middle-aged adulthood characterized pathologically by degeneration of GABAergic neurons of the caudate nucleus, and clinically by chorea and dementia.
- Alzheimer disease (60% of all cases of dementia) has increasing incidence with older age, is characterized by gross and microscopic brain abnormalities (atrophic brain with particular involvement of the hippocampus and temporal lobes, neuritic plaques, neurofibrillary tangles, and cerebral amyloid angiopathy), and clinically manifests with insidious onset, progressive memory impairment, mood alterations, disorientation, aphasia, apraxia, and progression to a bed-ridden state with eventual death. Dementia with Lewy bodies causes cognitive deterioration coupled with parkinsonism.
- Amyotrophic lateral sclerosis causes eventual generalized paralysis with earlier findings related to both upper motor neuron (hyperreflexia, fasciculations) and lower motor neuron (weakness, atrophy) loss. Friedreich ataxia is an autosomal recessive disorder related to an unstable triplet nucleotide repeat that causes multiple areas of degeneration in the cerebellum, brain stem, and spinal cord, clinically producing gait ataxia, leading to a wheelchair-bound state by age 5. Wilson disease is an abnormality of copper metabolism that can cause cirrhosis, neuropsychiatric symptoms, and ataxia. Acute intermittent porphyria is a disorder of porphyrin metabolism that can cause abdominal pain, psychosis, and dementia. Vitamin B12 deficiency can cause anemia, subacute combined degeneration of the spinal cord, dementia, and peripheral neuropathy. Alcohol abuse can cause cortical and cerebellar atrophy, Wernicke-Korsakoff syndrome, and central pontine myelinolysis.

(Continued)

Chapter Summary (*cont'd*)

- CNS tumors can be secondary to metastases (half of cases) or primary, and, in general, can produce headache, seizures, mental changes, focal neurologic symptoms, and increased intracranial pressure. Primary CNS tumors include astrocytomas [most common malignant primary tumor of brain; subtype pilocytic (grade 1), fibrillary (grade 2) is well-differentiated, anaplastic (grade 3), and aggressive glioblastoma multiforme (grade 4); subtype pilocytic astrocytoma involving cerebellum or diencephalon of children and young adults and having a particularly good prognosis], oligodendroglioma (middle-aged adults, cerebral hemispheres, “fried-egg” cells embedded in chicken-wire capillary pattern, slow growing, may eventually become high grade), ependymoma (fourth ventricle in children, lateral ventricle or spinal cord in adults, papillary tumors with ependymal rosettes and perivascular pseudorosettes, may cause hydrocephalus), meningiomas (most common benign tumor, form balls attached to meninges, whorled cells, psammoma bodies, usually good prognosis), primitive neuroectodermal tumors (aggressive but therapy-responsive small basophilic cell tumors of children including medulloblastoma and retinoblastoma), schwannomas (benign eighth nerve tumors of cerebellopontine angle that can cause hearing loss and tinnitus), and craniopharyngiomas (suprasellar/diencephalic tumors of children or young adults that histologically resemble the tooth tumor adamantinoma and arise from rests of odontogenic epithelium).

Hematopoietic Pathology— White Blood Cell Disorders & Lymphoid and Myeloid Neoplasms

22

REACTIVE CHANGES IN WHITE BLOOD CELLS

1. Leukocytosis

- a. Increased neutrophils (**neutrophilia**). Increased bone marrow production is seen with acute inflammation associated with pyogenic bacterial infection or tissue necrosis. Increased release from bone marrow storage pool may be caused by corticosteroids, stress, or endotoxin. Increased bands (“left shift”) in peripheral blood are characteristic. Reactive changes include Döhle bodies (aggregates of rough endoplasmic reticulum), toxic granulations (prominent granules), and cytoplasmic vacuoles of neutrophils.
- b. Increased eosinophils (**eosinophilia**) are seen with allergies and asthma (type I hypersensitivity reaction), parasites, drugs (especially in hospitals), and certain skin diseases and cancers (adenocarcinomas, Hodgkin disease).
- c. Increased monocytes (**monocytosis**) are seen with certain chronic diseases such as some collagen vascular diseases and inflammatory bowel disease, and with certain infections, especially tuberculosis.
- d. Increased lymphocytes (**lymphocytosis**) are seen with acute (viral) diseases and chronic inflammatory processes.
- e. **Infectious mononucleosis** is an example of a viral disease causing lymphocytosis. The most common cause is Epstein-Barr virus (a herpesvirus), but less commonly infectious mononucleosis is due to other viruses (heterophile-negative infectious mononucleosis is most likely due to cytomegalovirus).
 - i. **Sequence of events.**
 - Epstein-Barr virus invades B-lymphocytes via CD21 (CR2) receptors.
 - Cytotoxic (CD8) T-lymphocytes respond against invaded B cells and form atypical lymphocytes (Downey cells), which are enlarged lymphocytes that have abundant cytoplasm that is condensed peripherally (“ballerina skirt” appearance); they are similar in appearance to monocytes, hence the name “mononucleosis.”
 - ii. **Antibody production.** Heterophil antibodies (antibodies against other species such as red cells of sheep and horses) are the basis of the Paul-Bunnell reaction used as the monospot test (may be negative first week, so need to repeat test).
 - iii. **Clinical infectious monocytosis.** Age groups include adolescents and young adults (“kissing disease”). Symptoms of the “classic triad” include fever, sore throat with gray-white membrane on tonsils, and lymphadenitis involving the posterior auricular nodes; a fourth sign is hepatosplenomegaly. Infectious mononucleosis is an acute, self-limited disease that usually resolves in 4 to 6 weeks. Complications include hepatic dysfunction, splenic rupture, and rash if treated with ampicillin.

Note

Increased leukocyte alkaline phosphatase (LAP) is useful to differentiate benign reactions from neoplastic chronic myelocytic leukemia (CML) (which has decreased LAP).

f. **Increased basophils** are seen with chronic myeloproliferative disorders such as polycythemia vera.

2. **Leukopenia.**

- a. **Decreased neutrophils** can be due to decreased production (aplastic anemia, chemotherapy), increased destruction (infections, autoimmune disease such as systemic lupus erythematosus), and activation of neutrophil adhesion molecules on endothelium (as by endotoxins in septic shock).
- b. **Decreased eosinophils** are seen with increased cortisol, which causes sequestering of eosinophils in lymph nodes; examples include Cushing syndrome and exogenous corticosteroids.
- c. **Decreased lymphocytes** are seen with immunodeficiency syndromes such as HIV, DiGeorge syndrome (T-cell deficiency), and severe combined immunodeficiency (B- and T-cell deficiency). Decreased lymphocytes are also seen secondary to immune destruction (systemic lupus erythematosus), corticosteroids, and radiation (lymphocytes are the most sensitive cells to radiation). Atypical lymphocytes are found in the peripheral blood and T-cell areas of lymph nodes (paracortex).

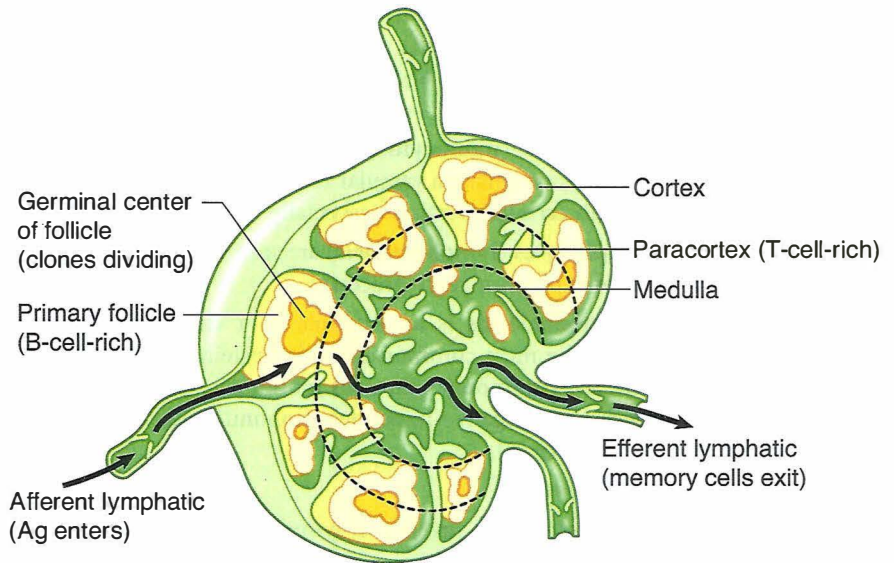


Figure 22-1. Lymph Node

3. **Lymphadenopathy** is lymph node enlargement due to reactive conditions or neoplasia.

- a. **Acute nonspecific lymphadenitis** produces tender enlargement of lymph nodes; focal involvement is seen with bacterial lymphadenitis. Microscopically, there may be neutrophils within the lymph node. Cat scratch fever (due to *Afipia felis*) causes stellate microabscesses. Generalized involvement of lymph nodes is seen with viral infections (see reactive T-cell immunoblasts in lymph nodes and peripheral blood).
- b. **Chronic nonspecific lymphadenitis** causes nontender enlargement of lymph nodes. Follicular hyperplasia involves B lymphocytes and may be seen with rheumatoid arthritis, toxoplasmosis, and early HIV infections. Paracortical lymphoid hyperplasia involves T cells and may be seen with viruses, drugs (Dilantin), and systemic lupus erythematosus. Sinus histiocytosis involves macrophages and, in most cases, is nonspecific; an example is lymph nodes draining cancers.

- c. **Neoplasia** usually causes nontender enlargement of lymph nodes. The most common tumor to involve lymph nodes is metastatic cancer (e.g., breast, lung, malignant melanoma, stomach and colon carcinoma), which is initially seen under the lymph node capsule. Malignant lymphoma and infiltration by leukemias are other important causes for lymphadenopathy.

LYMPHOID NEOPLASMS

1. General definitions, characteristics, and classifications

- a. In **acute leukemias**, the peripheral blood has decreased mature forms and increased immature forms called *blasts*, which have immature chromatin with nucleoli. The bone marrow has increased immature cells (blasts); the **diagnostic criteria are greater than 30% blasts** in the bone marrow. Acute symptoms are secondary to marrow failure, which can produce decreased erythrocytes (causing anemia and fatigue), decreased leukocytes (permitting infections and fever), and decreased platelets (inducing bleeding).
- b. **Lymphoid neoplasia** classifications are currently based on the *Revised European-American classification of Lymphomas* (REAL), and include:
- Precursor B-cell neoplasms (immature B cells)
 - Peripheral B-cell neoplasms (mature B cells)
 - Precursor T-cell neoplasms (immature T cells)
 - Peripheral T-cell neoplasms (mature T cells)

PRECURSOR B- AND T-CELL NEOPLASMS

1. Acute lymphoblastic leukemia (ALL)

- a. **Lymphoblasts** are positive for terminal deoxytransferase (TdT, which is determined by using a nuclear stain), PAS, hyperploidy (greater than 50 chromosomes), polyploidy (e.g., t(12;21), t(4;11) and t(9;22)), and acid phosphatase.
- b. The **immunologic classification** of acute lymphoblastic leukemia (at present preferred).
- i. **B-cell lineage** classification is based on presence or absence of cytoplasmic or surface markers, including surface immunoglobulin (sIg) presence (mature B-ALL) and cytoplasmic μ presence (pre-B-ALL). The B-cell tumors almost always express B-cell molecules CD19 and CD10. Early pre-B-ALL is the most common type of acute lymphoblastic leukemia and is seen primarily in children. The rapid onset of symptoms is due to marrow involvement and pancytopenia.
- ii. **T-cell lineage** (T-ALL) is associated with mediastinal mass in young (adolescent) adult male (think “T” = thymus = mediastinal).
2. **Lymphoblastic lymphoma**. The majority of cases are T cells neoplasms that are aggressive and rapidly progressive. Most patients are young males with a mediastinal mass (think thymus). The leukemic phase of lymphoblastic lymphoma is similar to T-ALL. Most cells express CD1+, CD2+, CD5+ and CD7+.

PERIPHERAL B-CELL NEOPLASMS

1. **Chronic lymphocytic leukemia (CLL) and small lymphocytic lymphoma (SLL)**. Chronic lymphocytic leukemia is very similar to small lymphocytic lymphoma, which is also called well-differentiated lymphocytic lymphoma

Clinical Correlate

ALL is associated with infiltration of the CNS and testes (*sanctuary sites*). Prophylactic radiation and/or chemotherapy to the CNS is recommended because malignant cells in the brain are protected from chemotherapy by the blood–brain barrier.

Clinical Correlate

Tumor Lysis Syndrome

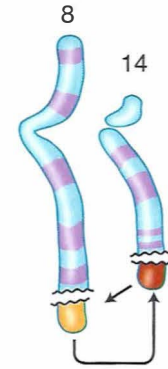
This group of metabolic complications can occur after treatment of neoplastic disorders. These complications are caused by the breakdown products of dying cancer cells, and include hyperkalemia, hyperphosphatemia, hyperuricemia, hypocalcemia, and acute renal failure. Treatment consists of hydration and allopurinol.

(WDLL). Patients who present with blood findings are classified as having chronic lymphocytic leukemia, whereas patients who present with lymph node findings are classified as having small lymphocytic lymphoma. Note that lymph node involvement is also common (50%) with chronic lymphocytic leukemia.

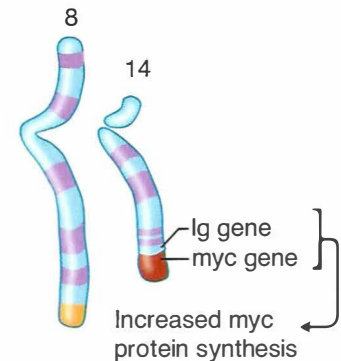
- a. **Small lymphocytic lymphoma** is a proliferation of small B-lymphocytes, which have B-cell markers and one T-cell marker (CD5), like B-chronic lymphocytic leukemia.
 - b. **B-chronic lymphocytic leukemia** cells (95% of cases) have B-cell markers, such as CD19 and CD20. One T-cell marker is also present, CD5. Also important is that the cells are CD23 positive and CD10 negative.
 - c. **T-chronic lymphocytic leukemia** cells (5% of cases) have T-cell markers. The histology of affected lymph nodes reveals only a diffuse pattern (not nodular), but proliferation centers may also be present. Peripheral blood findings show increased numbers of normal-appearing lymphocytes. Numerous smudge cells (“parachute cells”) are also present; the smudge cells result from the fact that the neoplastic lymphocytes are unusually fragile. Bone marrow shows numerous normal-appearing neoplastic lymphocytes.
 - d. **Clinical characteristics of chronic lymphocytic leukemia.** CLL is the most indolent of all of the leukemias. Mean age at time of diagnosis is 60. The malignant cells are nonfunctional, so patients develop hypogammaglobulinemia which leads to increased risk of infections. CLL is associated with warm autoimmune hemolytic anemia (AIHA) (10% of cases), which will cause spherocytes to be observed in peripheral blood. CLL rarely transforms into a worse disease such as prolymphocytic leukemia or large cell lymphoma (Richter syndrome).
2. **Hairy cell leukemia** is a rare B-cell neoplasm that causes indolent disease in middle-aged Caucasian men. There can be a “dry tap” with bone marrow aspiration. Lymphocytes have “hairlike” cytoplasmic projections; the diagnostic stain is positive tartrate-resistant acid phosphatase (TRAP). Physical examination shows a markedly enlarged spleen (splenomegaly) due to infiltration of red pulp by malignant cells. Treatment is with 2-chlorodeoxyadenosine (2-CDA), which inhibits adenosine deaminase (ADA) and increases levels of toxic deoxyadenosine.
 3. **Follicular lymphoma** is a well-differentiated B-cell lymphoma with follicular architecture. It is the most common form of non-Hodgkin lymphoma in the United States. All follicular lymphomas are derived from B lymphocytes. The characteristic translocation is $t(14;18)$. **Chromosome 14** has immunoglobulin heavy-chain genes. **Chromosome 18** has bcl-2 (activation of bcl-2 inhibits apoptosis by blocking the bax channel). Follicular lymphoma commonly presents with disseminated disease (more advanced stage). It has a better prognosis than diffuse lymphomas, but doesn’t respond to therapy (unlike the more aggressive diffuse non-Hodgkin lymphomas).
 4. **Diffuse large B-cell lymphoma** is a high grade large B-cell lymphoma with a diffuse growth pattern; it is an aggressive, rapidly proliferating tumor that may respond to therapy. Special subtypes include immunodeficiency-associated B-cell lymphomas (these are often infected with Epstein Barr virus), and body-cavity large B-cell lymphomas (some of these are associated with human herpes virus [HHV]-8).
 5. **Small noncleaved lymphoma** (Burkitt lymphoma) is a high grade B-cell lymphoma composed of intermediate-sized lymphoid cells with a “starry-sky” appearance due to numerous reactive tingible-body macrophages

(phagocytosis of apoptotic tumor cells). There is a characteristic $t(8;14)$ *translocation*. **Chromosome 14** has immunoglobulin heavy-chain genes. Chromosome 8 has oncogene *c-myc*. Both endemic and sporadic forms of Burkitt lymphoma largely occur in children and young adults.

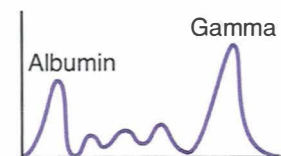
- a. **African type** is the endemic form. Involvement of mandible or maxilla is characteristic, and the lymphoma is associated with Epstein Barr virus.
 - b. **American type** is the nonendemic, sporadic form. It commonly involves the abdomen (such as bowel, retroperitoneum, or ovaries), and has a high incidence in AIDS patients.
6. In **mantle cell lymphoma (MCL)**(also called intermediate differentiated lymphocytic lymphoma), the tumor cells arise from mantle zone B lymphocytes (positive for CD19, CD20, and CD5; negative for CD23). The characteristic translocation is $t(11;14)$. **Chromosome 11** has *bcl-1* (cyclin D). **Chromosome 14** has immunoglobulin heavy-chain genes.
 7. **Marginal zone lymphoma (MALToma)** is a diverse group of B-cell neoplasms that arise within lymph nodes, spleen, or extranodal tissues. It is associated with mucosa-associated lymphoid tissue (MALTomas). The lesion begins as a reactive polyclonal reaction and may be associated with previous autoimmune disorders or infectious disease (e.g., Sjögren disease, Hashimoto thyroiditis, *Helicobacter* gastritis). The lymphoma remains localized for long periods of time.
 8. **Multiple myeloma** is a malignant neoplasm of plasma cells. It is the most common primary tumor arising in the bone marrow of adults.
 - a. **Laboratory studies** show increased serum protein with **normal serum albumin**. An M spike in serum electrophoresis is a monoclonal immunoglobulin spike, that is most commonly IgG (60%) and next most commonly IgA (20%). Bence-Jones proteins are light chains that are small and can be filtered into urine.
 - b. **Histology**. Bone marrow has increased numbers of plasma cells (>20% is characteristic). Peripheral blood may show rouleaux formation (“stack of coins”). Multiple lytic bone lesions are due to the osteoclastic activating factor. Lytic bone lesions cause hypercalcemia, bone pain, and increased risk of fracture.
 - c. **Complications**. Increased risk of infection is the most common cause of death. Other complications include renal disease (such as myeloma nephrosis) and primary amyloidosis (10% of patients) due to amyloid light (AL) chains. Increased amounts of IL-6 are associated with a poorer prognosis because survival of myeloma cells is dependent on IL-6.
 9. **Plasmacytoma** is a solitary myeloma within either bone or soft tissue. When it occurs within bone, it is a precursor lesion that can later develop into myeloma. Outside bone (extramedullary), it is usually found within the upper respiratory tract and is not a precursor lesion for myeloma.
 10. **Monoclonal gammopathy of undetermined significance (MGUS)**(an old name was benign monoclonal gammopathy). Serum M protein is found in 1–3% of asymptomatic individuals over age 50; the incidence increases with increasing age. The annual risk of developing a plasma cell dyscrasia, usually multiple myeloma, is 1–2% per year. MGUS may also evolve into Waldenström macroglobulinemia, primary amyloidosis, B-cell lymphoma, or chronic lymphocytic leukemia.
 11. **Lymphoplasmacytic lymphoma** (Waldenström macroglobulinemia) is a small lymphocytic lymphoma with plasmacytic differentiation. It is a cross between multiple myeloma and small lymphocytic lymphoma.



Normal Chromosome



Burkitt Lymphoma

IgG myeloma with γ spike and reduced albumin

- a. **Pathology.** Like myeloma, Waldenström macroglobulinemia has an M spike (IgM). Like small lymphocytic lymphoma (and unlike myeloma), the neoplastic cells infiltrate many organs, such as lymph nodes, spleen, and bone marrow. Also unlike multiple myeloma (MM), there are no lytic bone lesions and serum calcium levels do not increase. Russell bodies (cytoplasmic immunoglobulin) and Dutcher bodies (intranuclear immunoglobulin) may be present.
- b. **Clinical features.** Lymphoplasmacytic lymphoma may have hyperviscosity syndrome, because IgM is a large pentamer. Visual abnormalities may be due to vascular dilatations and hemorrhages in the retina. Neurologic symptoms include headaches and confusion. Bleeding and cryoglobulinemia can be due to abnormal globulins, which precipitate at low temperature and may cause Raynaud phenomenon.

PERIPHERAL T-CELL AND NATURAL KILLER CELL NEOPLASMS

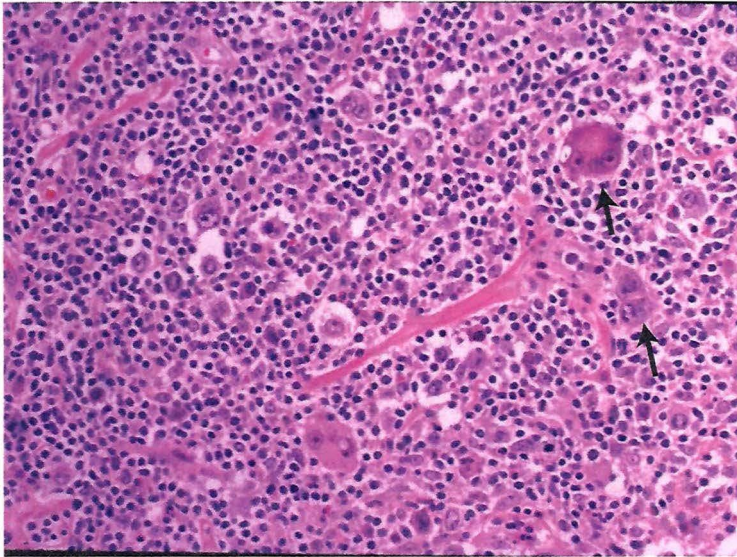
1. **Peripheral T-cell lymphoma, unspecified.** This is a “wastebasket” diagnostic category.
2. **Adult T-cell leukemia/lymphoma (ATLL)** is a malignant T-cell disorder (CD4-T cells) due to HTLV-1 infection that is found in Japan and the Caribbean. Clinical symptoms include skin lesions, hypercalcemia, enlarged lymph nodes, hepatomegaly, and splenomegaly. Microscopically, characteristic hyperlobated “4-leaf clover” lymphocytes can be found in the peripheral blood.
3. **Mycosis fungoides and Sézary syndrome.** Mycosis fungoides is a malignant T-cell disorder (post-thymic CD4 cells) that has a better prognosis than ATLL.
 - a. There can be a **generalized pruritic erythematous rash** (no hypercalcemia) in mycosis fungoides, which develops as a sequence of skin changes: inflammatory eczematous stage progresses to plaque stage, which progresses to tumor nodule stage.
 - b. **Microscopically**, atypical PAS-positive lymphocytes are present in epidermis (epidermotropism); aggregates of these cells are called Pautrier microabscesses. If cerebriform Sézary cells are present in peripheral blood, the condition is called Sézary syndrome, something also associated with a generalized exfoliative skin rash.

LYMPHOMA

1. **Hodgkin versus non-Hodgkin lymphomas.** Hodgkin lymphoma has some characteristics that are different from non-Hodgkin lymphoma. Clinically, Hodgkin lymphoma may present similar to infection (with fever), while that presentation is uncommon in non-Hodgkin lymphomas. The spread of Hodgkin lymphoma is contiguous to adjacent node groups, unlike non-Hodgkin lymphomas. Classification is based on inflammatory response and not the malignant cell. There is no leukemic state. Extranodal spread is uncommon.

2. Hodgkin lymphoma.

- a. The malignant cells are the diagnostic **Reed-Sternberg cells**; these malignant cells are intermixed with reactive inflammatory cells. The Reed-Sternberg cell is a large malignant tumor cell that has a bilobed nucleus with a prominent large inclusion-like nucleolus in each lobe. Reed-Sternberg cells are positive for CD15 (Leu-M1) and CD30 (Ki-1), except for lymphocyte-predominant Hodgkin lymphoma, in which the malignant cells stain for B-cell markers and have negative CD15 and CD30.



© Katsumi M. Miyai, M.D., Ph.D.; Regents of the University of California.
Used with permission.

Figure 22-2. Reed-Sternberg Cells (arrows) of Hodgkin Lymphoma Appear as Large Cells with a Lobed Nucleus with Large, Reddish Nucleolus in Each Lobe

- b. **Classification of Hodgkin lymphoma.**
 - i. **Lymphocyte-rich** type is a rare form, composed mainly of reactive lymphocytes; it is associated with Epstein Barr virus (40% of cases).
 - ii. **Lymphocyte-predominant** type has lympho-histocytic variants (L&H cells, called “popcorn cells”) that are negative for CD15 and CD30.
 - iii. **Mixed cellularity** type has eosinophils and plasma cells; the increased number of eosinophils is related to IL-5 secretion.
 - iv. **Lymphocyte-depleted** type has few lymphocytes, and there are many Reed-Sternberg cells.
 - v. **Nodular sclerosis** is the most common subtype (65–70% of Hodgkin lymphoma cases). It is the only type that is more common in females. The lymph node has broad collagen bands. The Reed Sternberg cell variant present in nodular sclerosis is the *lacunar cell*, which has a clear space surrounding the malignant tumor cells.
- c. **Clinical characteristics.** Hodgkin lymphoma has a bimodal age group distribution (late 20s and older than 50). Patients usually present with painless enlargement of lymph nodes. B-cell symptoms include fever (that comes and goes, being designated Pel-Ebstein fever), weight loss, and night sweats. Bad prognosis is directly proportional to the number of Reed-Sternberg cells present. Survivors of chemotherapy and radiotherapy have increased risk for secondary non-Hodgkin lymphoma or acute leukemia.

MYELOID NEOPLASMS

1. **Acute myelogenous leukemia (AML).** Myeloblasts may have intracytoplasmic rods (stain red) called *Auer rods*. Auer rods are composed of abnormal lysosomes (primary granules) that are pathognomonic of myeloblasts and not found in ALL. Auer rods also stain positive with myeloperoxidase (MPO) or Sudan-black B stain. Auer rods are most commonly found in M3 AML. The tissue form of AML is called granulocytic sarcoma (chloroma).
 - a. **French-American-British (FAB) classification of AML.**
 - i. **M0** is undifferentiated myelogenous leukemia.
 - ii. **M1** is myeloblastic leukemia without maturation.
 - iii. **M2** is myeloblastic leukemia with maturation (some promyelocytes).
 - iv. **M3** is hypergranular (microgranular) promyelocytic leukemia. Microscopically, numerous cytoplasmic granules and numerous Auer rods are seen in the cells. Promyelocytic leukemia may develop *disseminated intravascular coagulation* (DIC) due to release of thromboplastic substances in granules, especially when therapy kills the leukemic cells. The characteristic translocation is $t(15;17)$. Chromosome 15 has the polymorphonuclear leukocyte (PML) gene, whereas 17 has the retinoic acid receptor α gene (RAR- α). This translocation forms an abnormal retinoic acid receptor; therefore, therapy is with *all-trans-retinoic acid*.
 - v. **M4** is myelomonocytic leukemia that has both myeloblasts and monoblasts.
 - vi. **M5** is monocytic leukemia (may have gingival infiltrates).
 - vii. **M6** is erythroleukemia (Di Guglielmo disease), and is due to abnormal erythroid precursors that show binucleate and megaloblastic changes.
 - viii. **M7** is acute megakaryocytic leukemia and is associated with acute myelofibrosis due to the release of platelet-derived growth factor (PDGF).
2. **Myelodysplastic syndromes (MDS).** The classification of myelodysplastic syndromes is based on the number of blasts in the marrow. Dysplastic changes include Pelger-Huët cells (“aviator glasses” nuclei), ring sideroblasts, nuclear budding, and “pawn ball” megakaryocytes. Myelodysplastic syndromes are considered preleukemias, and patients have an increased risk of developing acute leukemia.
3. **Myeloproliferative syndromes (MPS)** are clonal neoplastic proliferations of multipotent myeloid stem cells. The bone marrow is usually markedly hypercellular (hence the name *myeloproliferative*). All cell lines are increased in number (erythroid, myeloid, and megakaryocytes). The various myeloproliferative disorders cannot be distinguished by the histologic appearance of the bone marrow.
 - a. **Chronic myelogenous leukemia (CML)** is a clonal proliferation of pluripotent granulocytic precursor stem cells.
 - i. **Genetics.** A unique characteristic is the chromosomal translocation, *Philadelphia (Ph) chromosome*, which has $t(9;22)$. Chromosome 9 has c-abl (an oncogene), while chromosome 22 has bcr (breakpoint cluster region). This translocation forms a new protein P210 that has tyrosine kinase activity.

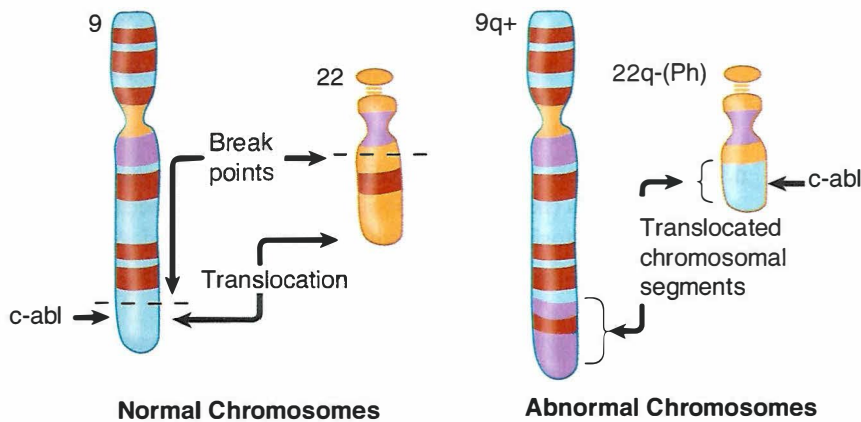


Figure 22-3. Translocation of Chromosomal Segments Between Chromosomes 9 and 22

- ii. **Clinically**, chronic myelogenous leukemia has an insidious onset (i.e., chronic) and massive splenomegaly. For treatment, imatinib mesylate blocks the P210 tyrosine kinase protein produced by the translocation. Bone marrow transplant is also used. CML typically has a slow progression (half develop accelerated phase <5 years) unless blast crisis develops (very bad prognosis; doesn't respond to chemotherapy). In blast crisis, 2/3 of cases show myeloid blasts and 1/3 show lymphoid blasts.
 - iii. **Diagnosis.** Microscopically, the bone marrow is hypercellular, with all cell lines increased in number. Peripheral leukocytosis is present, including markedly increased numbers of neutrophils (and bands and metamyelocytes), and also increased eosinophils and basophils (like the other MPSs). Decreased leukocyte alkaline phosphatase (LAP) activity is diagnostic compared with leukemoid reaction, which has increased LAP.
- b. **Polycythemia vera** characteristically shows increased erythroid precursors with increased red cell mass; increased hematocrit; increased blood viscosity; decreased erythropoietin, but erythrocytes have increased sensitivity to erythropoietin and overproliferate; and increased basophils and increased eosinophils (like all of the MPSs). Histamine release from basophils causes intense pruritus and gastric ulcers (bleeding may cause iron deficiency). LAP is increased.
 - i. **Clinical characteristics** include plethora (redness) and cyanosis (blue). Increased blood viscosity can cause deep vein thromboses and infarcts. High cell turnover can cause hyperuricemia, resulting in gout. Polycythemia vera may develop into a "spent phase" with myelofibrosis. There is an increased risk for acute leukemia.
 - c. **Essential thrombocythemia** is characterized by increased megakaryocytes (and other cell lines) in bone marrow. The peripheral blood smear shows increased number of platelets (>1,000,000), some with abnormal shapes. There are also increased numbers of leukocytes. Clinical signs include excessive bleeding and occlusion of small vessels.
 - d. **Myelofibrosis (MF) with myeloid metaplasia** has unknown etiology (agnogenic).

Note

The spleen is the most common site for extramedullary hematopoiesis.

- i. **Bone marrow aspiration** may be a “dry tap.” The biopsy specimen shows hypocellular marrow with fibrosis (increased reticulin). The fibroblasts are a polyclonal proliferation and are not neoplastic. The fibrosis is secondary to factors released from megakaryocytes, such as platelet-derived growth factor (PDGF).
- ii. **Other features.** There is an enlarged spleen due to extramedullary hematopoiesis (myeloid metaplasia). The peripheral smear shows leukoerythroblastosis (immature white cells and nucleated red cells) with *teardrop RBCs*. High cell turnover causes hyperuricemia and gout.

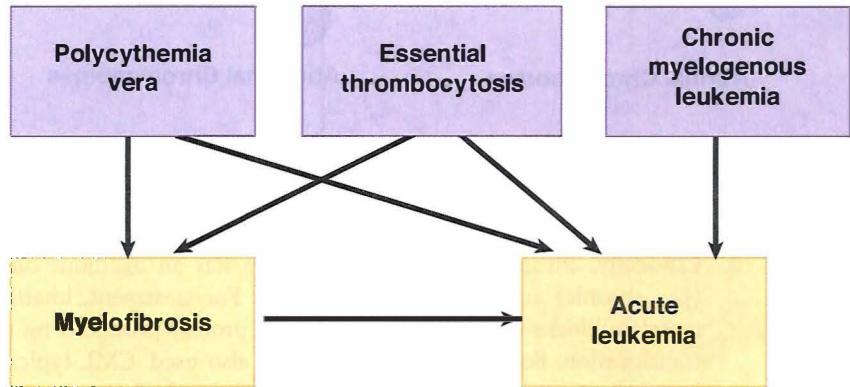


Figure 22-4. Natural History of the Myeloproliferative Syndromes

SPLEEN DISORDERS

1. **Enlarged spleen (splenomegaly)** can have multiple causes including vascular congestion (portal hypertension); reactive hyperplasia of white pulp (autoimmune disorders, infectious mononucleosis, and malaria); infiltrative diseases (metastatic non-Hodgkin lymphoma, primary amyloidosis, and leukemias); accumulated macrophages in red pulp (Gaucher disease where the macrophages have fibrillary appearance due to accumulation of glucocerebrosides; and Niemann-Pick disease where the macrophages have a soap bubble appearance due to accumulation of sphingomyelin); extravascular hemolysis; and extramedullary hematopoiesis in splenic sinusoids.
2. **Splenic dysfunction** leads to loss of ability to remove damaged red cells, which leads to Howell-Jolly bodies in peripheral red blood cells. There is a predisposition for infections (sepsis, peritonitis), particularly due to *Streptococcus*, *Haemophilus*, and *Salmonella*.

MISCELLANEOUS DISEASES AND DISEASES OF THE SPLEEN

1. **Langherhans cell histiocytosis** is a proliferation of Langerhans histiocytes (from epidermis). These cells are CD1 positive, and they contain distinctive Birbeck granules that look like tennis rackets on electron microscopy. There are three clinical presentations:
 - a. **Letterer-Siwe disease** is a malignant histiocytosis seen in children and infants younger than 2 years; it causes diffuse rash, multiple organ involvement, and cystic defects in bones, and has a 50% mortality rate.

- b. **Hand-Schüller-Christian disease** is a malignant histiocytosis that mainly affects children, has an intermediate prognosis, and causes fever, rash, cystic skull defects, and diabetes insipidus (due to involvement of the posterior pituitary).
 - c. **Eosinophilic granuloma** is a benign histiocytosis that occurs in adolescents and young adults, and causes bone pain and fractures secondary to unifocal lytic lesions in skull, ribs, or femurs.
2. **Mast cell diseases.** Mast cells have metachromatic granules that stain with toluidine blue; mast cell diseases are associated with general pruritus and swelling of tissues secondary to histamine release. There are several types of mast cell disease:
- a. **Solitary mastocytoma** occurs in infants and is characterized by localized mast cell hyperplasia with release of mediators.
 - b. **Urticaria pigmentosum** is a skin disease with increased dermal mast cells that causes multiple oval, red-brown macules that heal with hyperpigmentation; dermatographism (skin stroked with a sharp object becomes edematous); and severe pruritus.
 - c. In **systemic mastocytosis**, there are mast cell infiltrations in multiple organs, and patients can have splenomegaly, decreased marrow production of other cell lines, histamine release with food or other triggers, and increased risk of developing a myeloproliferative disorder, leukemia, or lymphoma.

Chapter Summary

- Leukocytosis and leukopenia are common reactive patterns of white cells; determining whether the leukocytosis is related to neutrophilia, eosinophilia, monocytosis, or lymphocytosis may be helpful in narrowing the diagnostic possibilities.
- Infectious mononucleosis is a common viral disease typically lasting 4 to 6 weeks that can cause lymphocytosis, fever, sore throat, lymphadenitis, and hepatosplenomegaly.
- Acute nonspecific lymphadenitis tends to cause tender lymph nodes and can be seen with bacterial or viral infections. Chronic nonspecific lymphadenitis tends to cause non-tender lymph nodes and can be seen with chronic inflammatory conditions, viral infections, medicines, and in nodes draining cancers.
- Acute leukemias are characterized by more than 30% blasts in the bone marrow, which may also be identified in the peripheral blood. Clinically, acute leukemias cause symptoms related to marrow failure, such as anemia, fatigue, increased infections, fever, and bleeding.
- Non-Hodgkin lymphomas are classified by a variety of schemes, including the REAL (most current) classification, the Working Formulation, and the Rappaport classification.
- Acute lymphoblastic leukemia (ALL) is a leukemia of precursor lymphoid cells that may be of either B-cell or T-cell lineage. The early pre-B-ALL is usually seen in children and is the most common type of ALL. T-ALL typically causes a mediastinal mass in adolescent or young adult men. A similar presentation to T-ALL is seen in lymphoblastic lymphoma, which is usually of T-cell lineage.
- Chronic lymphocytic leukemia and small lymphocytic lymphoma are very similar diseases that differ in whether they present with blood findings or lymph node findings. Both conditions are proliferations of small B cells that characteristically have B-cell markers with one T-cell marker (CD5). These are indolent diseases of the elderly.
- Hairy cell leukemia is an indolent disease of older men with characteristic lymphocytes with “hair-like” cytoplasmic projections that stain positive for TRAP.
- Follicular lymphomas are the most common form of non-Hodgkin lymphoma in the United States and are all derived from B cells. They tend to present with diffuse disease and have a better prognosis than diffuse lymphomas.
- Diffuse large B-cell lymphoma is an aggressive, rapidly proliferating tumor that may be present at extranodal sites and may be associated with EBV or HHV-8 infection.
- Small noncleaved lymphoma (Burkitt lymphoma) occurs in African type with jaw involvement and American type with involvement of the abdomen. Burkitt lymphoma has a characteristic “starry-sky” microscopic appearance and is related to a characteristic $t(8;14)$ translocation.
- Mantle cell lymphoma arises from mantle zone B lymphocytes and has a characteristic $t(11;14)$ translocation.
- Marginal zone lymphomas often involve mucosa-associated lymphoid tissue and appear to often begin as reactive polyclonal disorders.

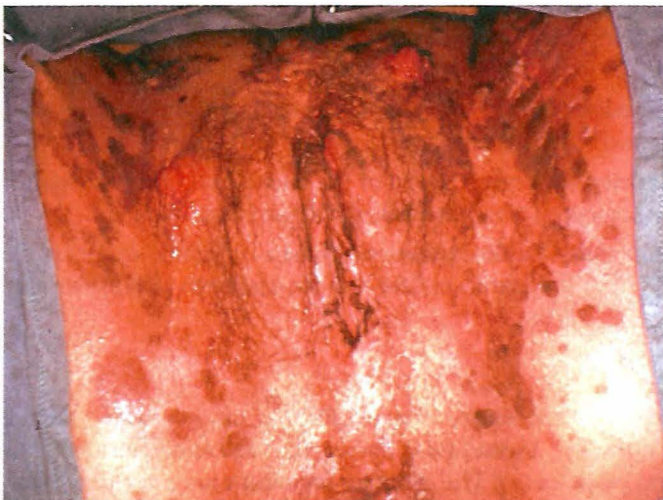(Continued)

Chapter Summary (cont'd)

- Multiple myeloma is a tumor of plasma cells that is the most common primary tumor arising in the bone marrow of adults and can be associated with production of a monoclonal immunoglobulin spike (M protein) in serum or urine. *Monoclonal gammopathy of undetermined significance* is the term used when an M protein is found in an asymptomatic individual.
- Lymphoplasmacytic lymphoma (Waldenström macroglobulinemia) is a cross between multiple myeloma and small lymphocytic lymphoma with M spike, but with neoplastic cells that tend to infiltrate many organs and do not cause lytic bone lesions.
- Adult T-cell leukemia/lymphoma is a malignant T-cell disorder due to HTLV-1 infection that is found in Japan and the Caribbean.
- Mycosis fungoides is a malignant T-cell disorder with a predilection for involving skin. The term Sezary syndrome is used if the abnormal lymphocytes are found in the blood and a generalized skin rash is present.
- In Hodgkin disease, the malignant cell is the Reed-Sternberg cell, which is positive for CD15 and CD30. Hodgkin disease is classified into lymphocyte predominant, mixed cellularity, lymphocyte depletion, and nodular sclerosing types. Hodgkin disease has a bimodal age group distribution (late 20s and >50) and usually presents with painless enlargement of lymph nodes.
- Acute myelogenous leukemia is a proliferation of nonlymphoid leukemic cells within bone marrow. The French-American-British classification of AML divides the condition into eight subtypes based on the degree and type of maturation of myeloid cells that is seen.
- Myelodysplastic syndromes are proliferations of dysplastic myeloid precursors and are associated with an increased risk of developing acute leukemias.
- Myeloproliferative syndromes are clonal neoplastic proliferations of multipotent myeloid stem cells usually seen in a setting of markedly hypercellular marrow with increases in multiple cell lines including erythroid, myeloid, and megakaryocytic.
- When neutrophils, eosinophils, and basophils predominate, the condition is called chronic myelogenous leukemia and is characterized by presence of the Philadelphia chromosome, insidious onset, and massive splenomegaly.
- When erythroid precursors predominate, the condition is called polycythemia vera and clinically produces increased hematocrit with complications of hyperviscosity and risk of progression to acute leukemia.
- When megakaryocyte proliferation dominates the marrow, the condition is called essential thrombocythemia and may produce excessive bleeding and occlusion of small vessels.
- The last of the myeloproliferative syndromes is myelofibrosis with myeloid metaplasia, which is characterized by a hypocellular marrow with fibrosis accompanied by an enlarged spleen secondary to extramedullary hematopoiesis.
- Langerhans cell histiocytosis has several clinical forms and can behave in a malignant or benign fashion.
- Splenomegaly can have many causes; splenic dysfunction manifests with erythrocyte abnormalities and predisposition for serious infections.

VULVA

1. **Condyloma acuminatum** produces verrucous, wartlike lesions that may occur on the vulva, perineum, vagina, or cervix. It is associated with human papillomavirus (HPV) *serotypes 6 and 11*. Microscopically, infected cells show koilocytosis, and the epithelium shows acanthosis, hyperkeratosis, and parakeratosis.



© Katsumi M. Miyai, M.D., Ph.D.;
Regents of the University of California. Used with permission.

Figure 23-1. Severe Case of Condyloma Acuminatum

2. **Papillary hidradenoma** is a benign tumor of modified apocrine sweat glands of the labia majora or interlabial folds. It occurs along the milk line and may ulcerate, mimicking carcinoma. Papillary hidradenoma is histologically similar to an intraductal papilloma of the breast.
3. **Extramammary Paget disease of the vulva** usually involves the labia majora, and it causes an erythematous, crusted rash that is characterized microscopically by intraepidermal malignant cells with pagetoid spread. This form of Paget disease is not usually associated with underlying tumor.
4. **Squamous cell carcinoma** is the most common malignancy of the vulva. The most common risk factors are HPV 16 infection, cigarette use, and immunodeficiencies, including AIDS.
5. **Melanoma** can occur on the vulva. Melanoma cells look similar to Paget cells but do not stain with PAS.
6. **Bartholin gland abscess** is most commonly due to *Neisseria gonorrhoeae* infection.
7. **Lichen sclerosis** is due to epidermal thinning and dermal changes that cause pale skin in postmenopausal women. There is a small risk of progression to squamous cell carcinoma.



Papovavirus

- Circular dsDNA
- Naked icosahedral

Clinical Correlate

Historically, DES was used in high-risk pregnancies from 1940 to 1970. Subsequently, vaginal adenosis and clear cell carcinoma began to be discovered in the female offspring. Vaginal adenosis is a benign condition that is thought to be a precursor of clear cell carcinoma.

Clinical Correlate

Tubal ectopic pregnancies usually occur in the ampulla of the fallopian tube. Tubal rupture results in severe, acute lower abdominal pain.

8. In lichen simplex chronicus, a chronic scratch/itch cycle produces the white plaques seen clinically. These plaques are characterized microscopically by squamous cell hyperplasia and dermal scarring. There is a small risk of progression to squamous cell carcinoma.

VAGINA

1. **Vaginal adenosis and clear cell adenocarcinoma** are rare conditions with increased risk in females exposed to diethylstilbestrol (DES) *in utero*.
2. **Embryonal rhabdomyosarcoma** (sarcoma botryoides) affects infants and young children (younger than age 4), in whom it can cause a polypoid, “grapelike,” soft tissue mass protruding from the vagina. The mass is microscopically characterized by spindle-shaped tumor cells with rare cross-striations. A cambium layer is characteristically present because of a tendency of tumor to grow beneath the vaginal epithelium. Tumor cells are positive for desmin.
3. Primary forms of **vaginal squamous cell carcinoma** are usually related to HPV infection; secondary forms are more common and are usually due to extension from a cervical cancer.
4. **Rhabdomyoma** is a benign skeletal muscle tumor that can involve the vagina.
5. **Gartner duct cyst** is a cyst of the lateral wall of the vagina that is due to persistence of a mesonephric (Wolffian) duct remnant.
6. **Rokitansky-Kuster-Hauser syndrome** is congenital absence of the upper part of vagina and uterus, and the condition presents with primary amenorrhea.

CERVIX

1. **Pelvic inflammatory disease (PID)** is an ascending infection (sexually transmitted disease) from the cervix to the endometrium, fallopian tubes, and pelvic cavity. The infecting organisms are most frequently gonorrhea and/or chlamydia.
 - a. The **distribution of disease** includes the endometrium (endometritis), fallopian tubes (salpingitis), and pelvic cavity (peritonitis and pelvic abscesses). Fitz-Hugh–Curtis syndrome (perihepatitis) can occur, and is characterized by “violin-string” adhesions between the fallopian tube and liver capsule.
 - b. The **clinical presentation** can be with vaginal discharge (cervicitis); vaginal bleeding and midline abdominal pain (endometritis); bilateral lower abdominal and pelvic pain (salpingitis); abdominal tenderness and peritoneal signs (peritonitis); or pleuritic right upper quadrant pain (perihepatitis).
 - c. **Complications** include tubo-ovarian abscess; tubal scarring, which increases risk of infertility and ectopic tubal pregnancies; and intestinal obstruction secondary to fibrous adhesions.

Table 23-1. Malignant Tumors of the Lower Female Genital Tract in the U.S.

Incidence	Mortality
1. Endometrial cancer	1. Ovarian cancer
2. Ovarian cancer	2. Endometrial cancer
3. Cervical cancer	3. Cervical cancer

2. **Cervical carcinoma** is the third most common malignant tumor of the lower female genital tract in the United States, with peak incidence in middle age (above age 40). Cervical carcinoma is most commonly squamous cell carcinoma, but can also be adenocarcinoma or small cell neuroendocrine carcinoma.
 - a. **Risk factors** include early age of first intercourse; multiple sexual partners; multiple pregnancies; oral contraceptive use; smoking; sexually transmitted diseases (including human papilloma virus); and immunosuppression. *Human papilloma virus* infection is particularly important in the development of cervical carcinoma, with high-risk types being 16, 18, 31, and 33, and having viral oncogenes E6 (binds to p53) and E7 (binds to Rb).
 - b. The **precursor lesion** is *cervical intraepithelial neoplasia* (CIN), which is increasing in incidence and occurs commonly at the squamocolumnar junction (transformation zone). Cervical intraepithelial neoplasia shows a progression of changes:
 - i. **CIN I** (mild dysplasia) corresponds to low grade SIL (squamous intraepithelial lesion).
 - ii. **CIN II** (moderate dysplasia) corresponds to high grade SIL.
 - iii. **CIN III** (severe dysplasia) also corresponds to high grade SIL.
 - iv. **CIS** (carcinoma *in situ*); and finally invasive squamous cell carcinoma.
 - c. **Clinically**, squamous cell carcinoma of the cervix may be asymptomatic, or it may present clinically with postcoital vaginal bleeding, dyspareunia, or malodorous discharge. To establish the diagnosis, the Papanicolaou (Pap) test is useful for early detection, and colposcopy with biopsy will obtain tissue for microscopic evaluation.
3. **Acute cervicitis and chronic cervicitis** are common and usually nonspecific inflammatory conditions. Important specific causes of acute cervicitis include *Chlamydia trachomatis*, *Neisseria gonorrhoeae*, *Trichomonas vaginalis*, *Candida*, and Herpes simplex II.
 - a. A specific severe form of chronic cervicitis (**follicular cervicitis**) can be due to *Chlamydia trachomatis*, and can cause neonatal conjunctivitis and pneumonia in infants delivered vaginally through an infected cervix.
4. **Cervical polyps** are common non-neoplastic polyps that can be covered with columnar or stratified squamous epithelium.

UTERUS

1. **Endometritis** can be acute or chronic. *Acute endometritis* is an ascending infection from the cervix that is associated with pregnancy or abortions. *Chronic endometritis* is associated with pelvic inflammatory disease and intrauterine devices (IUDs). Plasma cells are seen in the endometrium in chronic endometritis.
2. **Endometriosis** refers to the presence of endometrial glands and stroma outside the uterus. It most commonly affects women of reproductive age. Common sites of involvement include the ovaries, ovarian and uterine ligaments, pouch of Douglas, serosa of bowel and urinary bladder, and peritoneal cavity.
 - a. **Pathology.** Grossly, endometriosis causes red-brown serosal nodules (“powder burns”); an endometrioma is an ovarian “chocolate” (hemolyzed blood) cyst.
 - b. The **clinical presentation** can be with chronic pelvic pain, dysmenorrhea and dyspareunia, rectal pain and constipation, or infertility.

Clinical Correlate

Adenomyosis is the presence of endometrial glands and stroma within the myometrium of the uterus.

3. **Leiomyomas** (fibroids) are benign smooth muscle tumors of the myometrium and are the most common tumors of the female genital tract. These tumors have a high incidence in African Americans (but are also common generally) and are responsive to estrogen.
 - a. **Pathology.** They grossly form well-circumscribed, rubbery, white-tan masses with whorl-like trabeculated appearance on cut section. Leiomyomas are commonly multiple and may have subserosal, intramural, and submucosal location. The malignant variant is leiomyosarcoma.
 - b. The **clinical presentation** may be with menorrhagia; abdominal mass; pelvic pain, back pain, or suprapubic discomfort; or infertility and spontaneous abortion.
4. **Endometrial carcinoma** is the most common malignant tumor of the lower female genital tract, and the tumor most commonly affects postmenopausal women who typically present with vaginal bleeding.
 - a. **Risk factors** are mostly related to estrogen, and include early menarche and late menopause; nulliparity; hypertension and diabetes; obesity; chronic anovulation; estrogen-producing ovarian tumors (granulosa cell tumors); ERT and tamoxifen; endometrial hyperplasia (complex atypical hyperplasia); and Lynch syndrome (colon, endometrial, and ovarian cancers).
 - b. **Pathology.** Endometrial carcinoma typically forms a tan polypoid endometrial mass; invasion of myometrium is prognostically important. Endometrioid adenocarcinoma is the most common histological type.
5. **Less common types of uterine malignancy.** Leiomyosarcoma is a malignant smooth muscle tumor. Malignant mixed müllerian tumors contain both malignant stromal cells and endometrial adenocarcinoma.
6. **Adenomyosis** is an invagination of the deeper layers of the endometrium into the myometrium, which causes menorrhagia and dysmenorrhea.

OVARY

1. **Polycystic ovarian disease** (Stein-Leventhal syndrome) is an endocrine disorder of unknown etiology showing signs of androgen excess (clinical or biochemical), oligoovulation and/or anovulation, and polycystic ovaries. When making the diagnosis, it is important to exclude other endocrine disorders that might affect reproduction. Patients are usually young females of reproductive age who present with oligomenorrhea or secondary amenorrhea, hirsutism, infertility, or obesity. Treatment is with oral contraceptives or Provera.
 - a. **Evaluation.** Laboratory studies show elevated luteinizing hormone (LH), low follicle-stimulating hormone (FSH), and elevated testosterone. Gross examination is notable for bilaterally enlarged ovaries with multiple cysts; microscopic examination shows multiple follicle cysts.
2. **Epithelial** ovarian tumors arise from the ovarian surface epithelium and are the most common form of ovarian tumor.
 - a. **Cystadenoma** is specifically the most common benign ovarian tumor, and forms a unilocular, smooth-walled cyst that has a simple serous or mucinous lining.
 - b. **Borderline tumors** are tumors of low malignant potential.

- c. **Cystadenocarcinoma** is the most common malignant ovarian tumor. Hereditary risk factors include BRCA-1 (breast and ovarian cancers) and Lynch syndrome. CA 125 can be used as a tumor marker.
- i. **Pathology.** Cystadenocarcinoma forms a complex multiloculated cyst with nodular and solid areas. Microscopically, the tumor shows stratified serous or mucinous cyst lining with tufting, papillary structures with psammoma bodies, and stromal invasion. The disease commonly spreads by seeding the peritoneal cavity, and it is often detected at a late stage with a poor prognosis.
3. **Ovarian germ cell tumors.**
- a. **Teratoma** (dermoid cyst). The vast majority (>95%) of ovarian (but not testicular) teratomas are benign. These tumors commonly occur in the early reproductive years. Elements from *all three germ cell layers* are present, including ectoderm (skin, hair, adnexa, and neural tissue), mesoderm (bone and cartilage), and endoderm (thyroid and bronchial tissue). Complications include torsion, rupture, and malignant transformation (1%, usually squamous cell carcinoma).
 - i. The **dermoid cyst** can contain hair, teeth, and greasy material. The term *struma ovarii* is used when there is a preponderance of thyroid tissue.
 - ii. **Immature teratoma** is characterized by histologically immature tissue.
 - b. **Dysgerminoma** is a malignant germ cell tumor that is common in young adults. Risk factors include Turner syndrome and pseudohermaphroditism. Gross and microscopic features are similar to seminomas. Dysgerminomas are radiosensitive and have a good prognosis.
 - c. **Other germ cell tumors** include yolk sac tumor (endodermal sinus tumor) and choriocarcinoma.
4. **Ovarian sex cord–stromal tumors.**
- a. **Ovarian fibroma** is the most common stromal tumor, and forms a firm, white mass. *Meigs syndrome* refers to the combination of fibroma, ascites, and pleural effusion.
 - b. **Granulosa cell tumor** is a potentially malignant, *estrogen-producing tumor*.
 - i. **Clinically**, the presentation depends on age:
 - Prepubertal patients present with precocious puberty
 - Reproductive age patients present with irregular menses
 - Postmenopausal patients present with vaginal bleeding
 Complications include endometrial hyperplasia and cancer.
 - ii. **Pathology.** The tumor forms a yellow-white mass that microscopically shows polygonal tumor cells and formation of follicle-like structures (Call-Exner bodies).
 - c. **Sertoli-Leydig cell tumor** (androblastoma) is an *androgen-producing tumor* that presents with virilization; a complication is risk of female pseudohermaphroditism.
5. Primary sites for **metastatic tumor** to the ovary include breast cancer, colon cancer, endometrial cancer, and gastric “signet-ring cell” cancer (Krukenberg tumor).

Table 23-2. Origins of Common Ovarian Neoplasms

	Surface Epithelial Cells (Surface epithelial-stromal cell tumors)	Germ Cell	Sex Cord–Stroma	Metastasis to Ovaries
Age group affected	20+ years	0–25+ years	All ages	Variable
Types	<ul style="list-style-type: none"> • Serous tumor • Mucinous tumor • Endometrioid tumor • Clear cell tumor • Brenner tumor • Cystadenofibroma 	<ul style="list-style-type: none"> • Teratoma • Dysgerminoma • Endodermal sinus tumor • Choriocarcinoma 	<ul style="list-style-type: none"> • Fibroma • Granulosa–theca cell tumor • Sertoli–Leydig cell tumor 	
Overall frequency	65–70%	15–20%	5–10%	5%
Percentage of malignant ovarian tumors	90%	3–5%	2–3%	5%

GESTATIONAL TROPHOBLASTIC DISEASE AND PLACENTAL DISEASE

1. **Hydatidiform mole** (molar pregnancy) is a tumor of placental trophoblastic tissue. The incidence of hydatidiform mole in the United States is 1 per 1,000 pregnancies, with molar pregnancy being more common in Asia than in the United States. There is increased risk in women ages <15 and >40.
 - a. **Complete mole** results from fertilization of an ovum that lost all its chromosomal material, so that all chromosomal material is derived from sperm. **90%** of the time, the molar karyotype is 46,XX; **10%** of the time, the molar karyotype includes a Y chromosome. The embryo does not develop.
 - b. **Partial mole** results from fertilization of an ovum that has not lost its chromosomal material by two sperms, one 23,X and one 23,Y. This results in a triploid cell 69, XXY (23,X [maternal] + 23,X [one sperm] + 23,Y [the other sperm]). The embryo may develop for a few weeks.
 - c. **Clinically**, the presentation is typically with excessive uterine enlargement (“size greater than dates”); vaginal bleeding; passage of edematous, grapelike soft tissue; and elevated *beta-human chorionic gonadotropin* (β -HCG). Diagnosis is by ultrasound, and treatment is with endometrial curettage and following of β -HCG levels.
 - d. **Microscopically**, molar tissue will show edematous chorionic villi; trophoblast proliferation; and fetal tissue (only in partial mole).

Table 23-3. Partial Mole Versus a Complete Mole

	Partial Mole	Complete Mole
Ploidy	Triploid	Diploid
Number of chromosomes	69	46 (All paternal)
β -HCG	Elevated (+)	Elevated (+++)
Chorionic villi	Some are hydropic	All are hydropic
Trophoblast proliferation	Focal	Marked
Fetal tissue	Present	Absent
Invasive mole	10%	10%
Choriocarcinoma	Rare	2%

- Invasive mole** is a mole that invades the myometrium of the uterine wall.
- Choriocarcinoma** is a malignant germ cell tumor derived from the trophoblast that forms a necrotic and hemorrhagic mass. Microscopically, the tumor shows proliferation of cytotrophoblasts, intermediate trophoblasts, and syncytiotrophoblasts. Hematogenous spread can occur, with seeding of tumor to lungs, brain, liver, etc. Choriocarcinoma is responsive to chemotherapy.
- In **ectopic pregnancy**, the fetus implants outside the normal location, most often in the fallopian tube, and less often in the ovaries or abdominal cavity. The fetus almost never survives. The mother is at risk of potentially fatal intra-abdominal hemorrhage. Risk factors include scarring of fallopian tubes from pelvic inflammatory disease, endometriosis, and decreased tubal motility.
- Enlarged placentas** are more common with maternal diabetes mellitus, Rh hemolytic disease, and congenital syphilis.
- Succenturiate lobes** are accessory lobes of the placenta that may cause hemorrhage if they are torn away from the main part of the placenta during delivery.
- Placental abruption** refers to partial premature separation of the placenta away from the endometrium, with resulting hemorrhage and clot formation. Risk factors include hypertension, cigarette use, cocaine, and older maternal age.
- Placenta previa** is the term used when the placenta overlies the cervical os. Vaginal delivery can cause the placenta to tear, with potentially fatal maternal or fetal hemorrhage.
- In **placenta accreta**, the placenta implants directly in the myometrium rather than in endometrium. Hysterectomy is required after delivery to remove the rest of the placenta.
- Fraternal twins** always have 2 amnions and 2 chorions; placental discs are usually separate, but can grow together to appear to be a single placental disc.
- Identical twins** have a variable pattern in the number of membranes and discs due to variations in the specific point in embryonic development at which the twins separated. Twin-twin transfusion syndrome can occur if there is only one placental disc and one twin's placental vessels connect to the other twin's placental vessels. Conjoined twins are always identical twins with one amnion, one chorion, and one disc.

Chapter Summary

- Lesions of the vulva include condyloma acuminatum, papillary hidradenoma, extramammary Paget disease, squamous cell carcinoma, melanoma, Bartholin gland abscess, lichen sclerosis, and lichen simplex chronicus.
- Lesions of the vagina include vaginal adenosis, clear cell adenocarcinoma, embryonal rhabdomyosarcoma, squamous cell carcinoma, rhabdomyoma, Gartner duct cyst, and Rokitansky-Kuster-Hauser syndrome.
- Pelvic inflammatory disease is an ascending infection that is often due to gonorrhea and/or *Chlamydia*, from the cervix to the endometrium, fallopian tubes, and pelvic cavity. Pelvic inflammatory disease is an important cause of pelvic and even peritoneal inflammation, abscess formation, and scarring.
- Cervical carcinoma is the third most common malignant tumor of the female genital tract and typically arises from HPV-types 16, 18, 31, and 33. Cervical polyps and cervicitis can also affect the cervix.
- Acute endometritis is usually due to an ascending infection of the cervix, sometimes associated with pregnancy or abortions. Chronic endometritis is associated with PID and intrauterine devices.
- Endometriosis is the presence of endometrial glands and stroma outside the uterus, and may cause red-brown nodules or cysts in a wide variety of sites.
- Leiomyomas are benign smooth muscle tumors that are the most common tumors of the female tract.
- Endometrial adenocarcinoma is the most common malignant tumor of the female genital tract and usually presents as postmenopausal bleeding. Less common tumors of the uterus include leiomyosarcoma and malignant mixed müllerian tumors.
- Polycystic ovarian disease is a cause of infertility and hirsutism in young women.
- Ovarian tumors are subclassified as epithelial, germ-cell, or sex cord origin. Epithelial ovarian tumors include cystadenoma, borderline tumors, and cystadenocarcinoma. Ovarian germ-cell tumors include teratoma, dysgerminoma, yolk sac tumor, and choriocarcinoma. Ovarian sex cord–stromal tumors include ovarian fibroma, granulosa cell tumor, and Sertoli-Leydig cell tumor. The ovaries are also a site of metastatic disease, with common primary sites including breast, colon, endometrium, and stomach.
- Gestational trophoblastic disease includes benign and malignant tumors derived from trophoblast, including hydatidiform mole, invasive mole, and choriocarcinoma.
- Abnormalities of the placenta include ectopic pregnancy, enlarged placentas, succenturiate lobes, placental abruption, placenta previa, placenta accreta, and twin placentas.

Table 24-1. Anatomic Correlation to Common Breast Lesions

Normal	Lesion
Terminal duct	Cyst
Lobular unit	Sclerosing adenosis
	Small duct papilloma
	Hyperplasia
	Atypical hyperplasia
	Carcinoma
Lobular stroma	Fibroadenoma
	Phyllodes tumor
Nipple and areola:	
Large ducts and lactiferous sinuses	Duct ectasia
	Recurrent subareolar abscess
	Solitary ductal papilloma
	Paget disease
Interlobular stroma	Fat necrosis
	Lipoma
	Fibrous tumor
	PASH*
	Fibromatosis
	Sarcoma

*PASH = pseudoangiomatous stromal hyperplasia

MASTITIS

1. **Acute mastitis** is an acute inflammation of the breast, commonly occurring during lactation. The most common infecting organism is *Staphylococcus aureus*.
2. **Fat necrosis** is often related to trauma or prior surgery, and it may produce a palpable mass or a lesion visible on mammography.

FIBROCYSTIC CHANGES

1. **Fibrocystic changes** (formerly called fibrocystic disease) are a collection of benign breast tissue changes with nonproliferative and proliferative components which increase the risk of breast cancer. Fibrocystic changes are extremely common and affect primarily women age 20 to 50 years. The changes most often involve the upper outer quadrant and may produce a palpable mass or nodularity.

Note

Most Common Causes of Breast Lumps

- Fibrocystic changes
- Normal breast, no disease
- Cancer

Table 24-2. Nonproliferative Versus Proliferative Fibrocystic Changes

Nonproliferative	Proliferative Changes
Fibrosis	Ductal hyperplasia ± atypia
Cysts (blue-domed)	Sclerosing adenosis
Apocrine metaplasia	Small duct papillomas
Microcalcifications	

Table 24-3. Relative Risk of Developing Breast Cancer with Fibrocystic Change

Relative Risk	Fibrocystic Change
No increase	Fibrosis, cysts, apocrine metaplasia, adenosis
1.5–2×	Sclerosing adenosis, ductal hyperplasia, papillomas
4–5×	Atypical ductal or lobular hyperplasia

Table 24-4. Features That Distinguish Fibrocystic Change from Breast Cancer

Fibrocystic Change	Breast Cancer
Often bilateral	Often unilateral
May have multiple nodules	Usually single
Menstrual variation	No menstrual variation
Cyclic pain and engorgement	No cyclic pain or engorgement
May regress during pregnancy	Does not regress during pregnancy

BENIGN NEOPLASMS

1. **Fibroadenoma** is the most common benign breast tumor in women <35 years of age; causes a palpable, round, movable, rubbery mass that on cross-section shows small, cleft-like spaces. Microscopically, the mass shows proliferation of benign stroma, ducts, and lobules.
2. **Phyllodes tumor** (cystosarcoma phyllodes) is a fibroadenoma variant that usually involves an older patient population (50s) and may locally recur or rarely metastasize. Microscopically, the mass shows increased cellularity, stromal overgrowth, and irregular margins.
3. **Intraductal papilloma** commonly presents as a bloody nipple discharge. Microscopically, papilloma causes benign papillary growth within lactiferous ducts or sinuses.

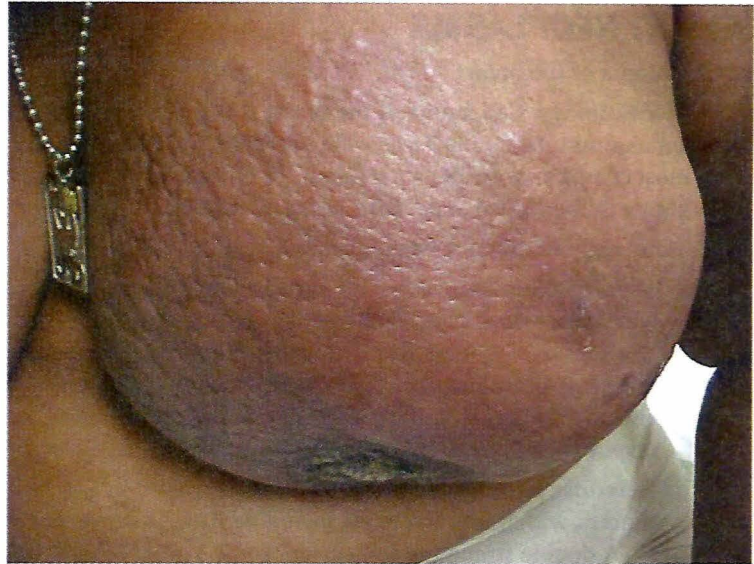
MALIGNANT NEOPLASMS

1. Carcinoma of the breast

- a. **Epidemiology.** Carcinoma of the breast is the most common cancer in females, and affects *1 in 9 women in the United States*. It is also the second most common cause of cancer death. The incidence is increasing, and is higher in the United States than in Japan.
- b. Many **risk factors** have been identified.
 - i. The **incidence** increases with age; if there are first-degree relatives with breast cancer and if the patient has had prior breast cancer. It also increases if there has been unusually long/intense exposure to estrogens (long length of reproductive life, nulliparity, obesity, exogenous estrogens) or if proliferative fibrocystic changes, especially *atypical hyperplasia*, are present.
 - ii. **Hereditary influences** are thought to be involved in 5–10% of breast cancers, with important genes including **BRCA1** (error-free repair of DNA double strand breaks) chromosome 17q21, **BRCA2** (error-free repair of DNA double strand breaks) chromosome 13q12-13, and **P53 germ-line mutation** (Li-Fraumeni syndrome).
- c. **Clinically**, breast cancer can cause mammographic calcifications or architectural distortion; palpable solitary painless mass; nipple retraction or skin dimpling; and fixation of breast tissue to the chest wall. Breast cancer is most common in the upper outer quadrant. Gross examination of a breast cancer typically shows a stellate, white-tan, gritty mass.

2. Histologic variants

- a. **Preinvasive lesions** include ductal carcinoma *in situ* (DCIS), lobular carcinoma *in situ* (LCIS), and Paget disease of the nipple (see Other Breast Conditions below).
- b. **Invasive (infiltrating) ductal carcinoma** is the most common form (>80%), and microscopically shows tumor cells forming ducts within a desmoplastic stroma.
- c. **Invasive (infiltrating) lobular carcinoma** is present in around 5–10% of cases; this form of carcinoma is characterized by small, bland tumor cells forming a single-file pattern. Invasive lobular carcinoma has a high incidence of multifocal and bilateral disease.
- d. **Mucinous (colloid) carcinoma** is a form of breast carcinoma with better prognosis that is characterized microscopically by clusters of bland tumor cells floating within pools of mucin.
- e. **Tubular carcinoma** rarely metastasizes and has an excellent prognosis.
- f. **Medullary carcinoma** is a form of breast carcinoma with a better prognosis; it is characterized microscopically by pleomorphic tumor cells forming syncytial groups surrounded by a dense lymphocytic host response.
- g. **Inflammatory carcinoma** is related to tumor invasion into the dermal lymphatics with resulting lymphatic edema; it presents clinically with red, warm, edematous skin. The term *peau d'orange* is used when the thickened skin resembles an orange peel.



© Richard P. Usatine, M.D. Used with permission.

Figure 24-1. Advanced Breast Cancer with Peau d'Orange Skin Involvement

Clinical Correlate

Causes of gynecomastia can be any of the following:

- Physiologic (newborn infants, pubescent adolescents, and elderly)
- Pathologic (Klinefelter syndrome, pituitary tumors such as prolactinomas)
- Side effects of drugs (spironolactone and ketoconazole)

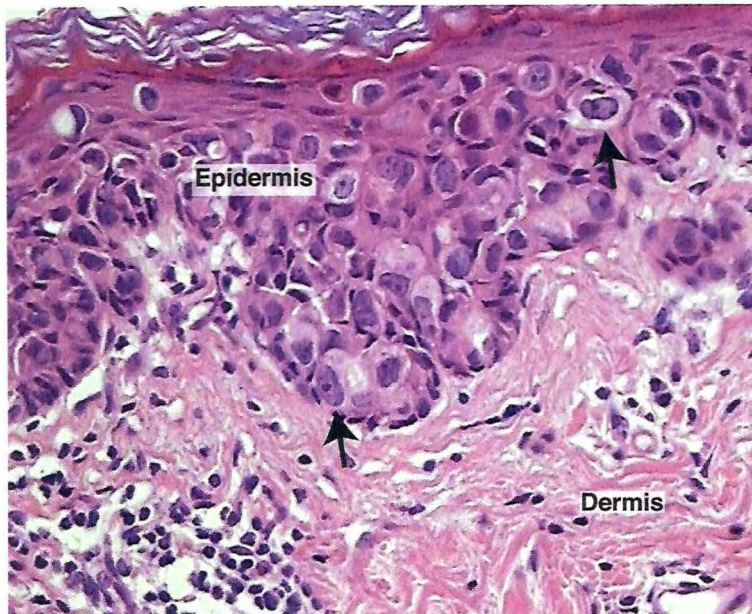
3. **Prognosis** of breast cancer depends on the following:

- Axillary lymph node status
- Size of tumor
- Histological type and grade of tumor
- ER/PR receptor status
- Overexpression of c-erbB2 (HER2/neu, overexpression is associated with more aggressive behavior than other types of breast cancer)
- Flow cytometry S-phase and DNA ploidy

4. **Treatment** of breast cancer for *local disease* includes mastectomy or lumpectomy with radiation, often with accompanying axillary dissection. For *metastatic disease*, treatment is with Tamoxifen and/or chemotherapy.

OTHER BREAST CONDITIONS

1. **Paget disease of the nipple** is characterized clinically by ulceration, oozing, crusting, and fissuring of the nipple and areola. The condition is commonly associated with an underlying invasive or *in situ* ductal carcinoma. Microscopic examination shows intraepidermal spread of tumor cells (Paget cells) with the cells occurring singly or in groups within the epidermis; there is often a clear halo surrounding the nucleus.
2. **Gynecomastia** refers to a unilateral or bilateral benign breast enlargement in a male patient, usually as the result of an altered androgen-estrogen balance that favors estrogen effect. Microscopically, gynecomastia is characterized by ductal epithelial hyperplasia, ductal elongation and branching, proliferation of periductal fibroblasts, and an increase in vascularity in the involved tissue.



© Giovannini, D'Atri, et al, World Journal of Surgical Oncology 2006. Used with permission.

Figure 24-2. Paget cells (arrows)

Chapter Summary

- Acute mastitis commonly occurs during lactation and is usually due to *Staphylococcus aureus*.
- Fibrocystic change is an extremely common condition of women 20 to 50 years of age that can produce fibrosis, cyst formation, apocrine metaplasia, microcalcifications, ductal hyperplasia with or without atypia, sclerosing adenosis, and small duct papillomas.
- Fibroadenoma is the most common benign breast tumor of women younger than 35 years of age, and produces a palpable, rubbery, movable mass.
- Cystosarcoma phyllodes is a large tumor involving both stroma and glands that behaves malignantly in 10–20% of cases.
- Carcinoma of the breast is the most common cancer in women, with a 1 in 9 incidence in the United States. Clinical features can include calcifications or architectural distortion visible by mammography, solitary painless mass, nipple retraction or skin dimpling, and fixation to the chest wall. Preinvasive lesions that may progress to breast cancer include ductal carcinoma *in situ* and lobular carcinoma *in situ*. Invasive cancer occurs in several histologic variants, including ductal carcinoma, lobular carcinoma, mucinous carcinoma, tubular carcinoma, medullary carcinoma, and inflammatory carcinoma.
- Paget disease of the nipple is an intraepidermal spread of tumor cells that is commonly associated with an underlying invasive or *in situ* ductal carcinoma.
- Gynecomastia is a benign breast enlargement in a male, usually resulting from an increased estrogen to androgen ratio.

PENIS

1. **Malformations of the penis.** Epispadias refers to a urethral opening on the dorsal surface of the penis, while hypospadias refers to a urethral opening on the ventral surface. Both malformations may be associated with undescended testes, and both have an increased risk of urinary tract infections (UTIs) and infertility.
2. **Balanitis/balanoposthitis** is the term used for inflammation of the glans penis. Causes include poor hygiene and lack of circumcision.
3. **Peyronie disease** is penile fibromatosis resulting in curvature of the penis.
4. **Condyloma acuminatum** causes warty, cauliflower-like growth, with the causative agents most frequently being Human papilloma virus (HPV) serotypes 6 and 11.
5. **Squamous cell carcinoma (SCC)** is uncommon in the United States, and is often related to infection with Human papilloma virus (HPV) serotypes 16 and 18. There is an increased risk in uncircumcised males. Precursor lesions include Bowen disease, bowenoid papulosis, and erythroplasia of Queyrat (may be regarded as synonymous with penile Bowen disease or as representative of one end of a spectrum of *in situ* penile carcinoma).
6. **Priapism** is a persistent painful erection that can be caused by sickle cell anemia (causes blood sludging in penis), trauma, and drugs (e.g., trazodone).
7. **Erectile dysfunction.** Causes of impotence include psychological factors, decreased testosterone, vascular insufficiency (most common cause over age 50), neurologic disease (multiple sclerosis, diabetic neuropathy, radical prostatectomy), some medications (leuprolide, methyl dopa, psychotropic medications), hypothyroidism, prolactinoma, and penile disorders.

Clinical Correlate

Hypospadias

Boys who are born with hypospadias must not be circumcised at birth, so that their foreskin can be used later for repair during surgery.

TESTES

1. **Varicocele** is the term used for a dilated vein within the spermatic cord that may cause infertility.

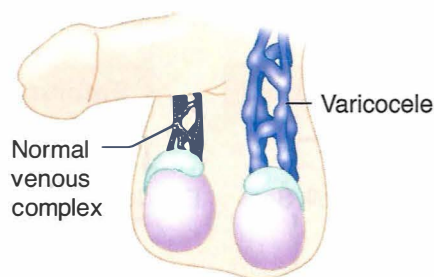


Figure 25-1. Varicocele

2. **Hydrocele** refers to fluid within the tunica vaginalis.
3. **Spermatocele** is a dilated efferent duct in the epididymus containing sperm.
4. **Epididymitis**. Acute epididymitis that affects men <35 is commonly due to *Neisseria gonorrhoeae* or *Chlamydia trachomatis*, while acute epididymitis that affects men >35 is commonly due to *Escherichia coli* or *Pseudomonas*. Chronic epididymitis can be due to tuberculosis.
5. **Orchitis** is frequently viral, particularly due to the mumps virus.
6. **Testicular torsion** is twisting of the spermatic cord; may be associated with physical activity or trauma; and is a clinical emergency that can cause painful hemorrhagic infarction leading to gangrene.
7. **Cryptorchidism** refers to a failure of one or both testes to descend; the undescended testes are most commonly found in the inguinal canal. The undescended testes have an increased risk for developing seminoma.
8. **Male infertility**. Decreased sperm count due to *primary testicular dysfunction* can be due to either Leydig cell dysfunction or seminiferous tubule dysfunction. Decreased sperm count due to *secondary hypogonadism* can be due to pituitary and hypothalamic dysfunction. Inability of sperm to exit the body in sufficient numbers may be due to *obstruction of the vas deferens* or *disordered ejaculation*.

Clinical Correlate

The most common regional metastatic lymph nodes for testicular cancer are the paraaortic lymph nodes, with lymphatic drainage following the gonadal vessels to the retroperitoneum.

TESTICULAR CANCER

1. **Testicular cancer** typically presents with a firm, painless testicular mass; nonseminomatous tumors may present with widespread metastasis.
2. **Risk factors** include cryptorchidism (5–10 times increased risk); testicular dysgenesis (testicular feminization and Klinefelter syndrome); and positive family history. Caucasians are affected more often than African Americans.
3. **Clinically**, ultrasound typically shows a hypoechoic intratesticular mass, and serum tumor marker studies can be helpful in confirming the diagnosis. Treatment is with radical orchiectomy; staging is with chest x-ray and CT scan of the abdomen and/or chest.

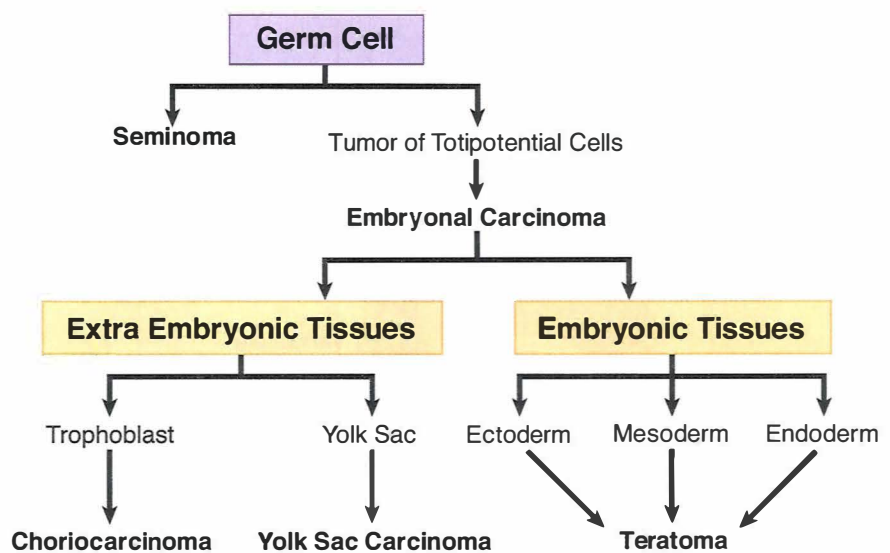


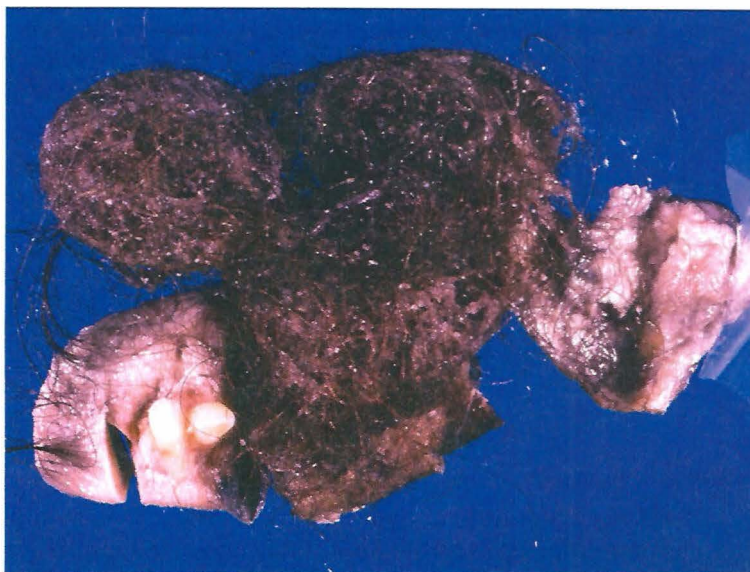Figure 25-2. Germ-Cell Malignancies

Table 25-1. Seminomas Versus Nonseminomatous Germ-Cell Tumors

Seminomas	Nonseminomatous Germ-Cell Tumors
Seminoma	Embryonal, yolk sac, choriocarcinoma, teratoma
Radiosensitive	Not radiosensitive
Chemosensitive	Chemosensitive
Late metastasis	Early metastases to retroperitoneal lymph nodes
Excellent prognosis	More aggressive

4. Germ-cell tumors

- a. **Seminoma** is the most common germ-cell tumor in adults ages 15–35. It is characteristically sensitive to both chemotherapy and radiation, and has an excellent prognosis, with early stage seminoma having a 95% cure rate. A variant is spermatocytic seminoma, a disease of older men, also with an excellent prognosis.
 - i. **Pathology.** On gross examination, the tumor forms large, grey-tan, bulky masses. Microscopic examination shows polygonal germ cells with clear cytoplasm and round nuclei that are arranged in lobules separated by fibrous septae. Lymphocytes, granulomas, and giant cells may be seen. The tumor marker for seminoma is placental alkaline phosphatase (PLAP).
- b. **Embryonal carcinoma** is more aggressive than seminoma and affects adults ages 20–40. The tumor causes bulky masses with hemorrhage and necrosis that microscopically show large primitive cells. Tumor markers for embryonal carcinoma are nonspecific, but there may be elevation of alpha-fetoprotein (AFP) and/or beta human chorionic gonadotropin (β -hCG).
- c. **Choriocarcinoma** is a highly malignant tumor that often has widespread metastasis at the time of diagnosis; hematogenous spread to lungs and liver is particularly common. The tumor often has small primaries with extensive hemorrhage and necrosis, which microscopically shows proliferation of syncytiotrophoblasts and cytotrophoblasts. The tumor marker is β -hCG.
- d. **Yolk sac tumor (endodermal sinus tumor)** is the most common germ-cell tumor in children. In those cases, the prognosis is good. In adults, the tumor is often mixed with other components so the prognosis may depend on what the other components are.
 - i. **Microscopically,** yolk sac tumor shows scattered Schiller-Duval bodies, which have a mesodermal core with a central capillary, all lined by flattened layers of both visceral and parietal cells resembling a glomerulus-like structure. The tumor marker is alpha-fetoprotein (AFP).
- e. **Teratoma** often causes cystic masses that may contain cartilage and bone. The majority (99%) of these tumors, when located in testes, are malignant. Microscopically, teratoma contains ectodermal, endodermal, and mesodermal tissue in a haphazard arrangement. Immature elements and malignant transformation are often seen.



© Katsumi M. Miyai, M.D., Ph.D.; Regents of the University of California.
Used with permission.

Figure 25-3. Teratoma of Testes, Producing Hair and Teeth

- f. **Mixed germ-cell tumors.** As many as 60% of germ-cell tumors are mixed and contain more than one component. *Teratocarcinoma* is the name used when both teratoma and embryonal carcinoma are present.
5. **Sex cord–stromal tumors**
- a. **Leydig cell tumors** cause painless testicular masses, and may affect adults age 20 to 60. The tumors may produce androgens and estrogens; in adults, the hormonal secretion can produce gynecomastia, while in children, it may produce precocious puberty. Benign tumors (90%) have an excellent prognosis, but malignant tumors (10%) can be refractory to chemotherapy and radiation therapy.
 - b. **Sertoli cell tumors** are rare.
6. **Other tumors.** Testicular lymphoma is the most common testicular tumor in men over age 50. It is most commonly non-Hodgkin lymphoma, diffuse large-cell type. Scrotal squamous cell carcinoma is associated with exposure to soot (chimney sweeps).

Note

The H in BPH more accurately represents hyperplasia than hypertrophy, although you may see either term used.

Bridge to Anatomy

Hyperplasia → transitional/periurethral zones

Carcinoma → peripheral zone

PROSTATE

1. **Benign prostatic hypertrophy** (BPH, also called nodular hyperplasia; glandular and stromal hyperplasia) is extremely common and the incidence increases with age (age 60 = 70%, age 70 = 80%). Androgens (dihydrotestosterone) play an important role in the pathogenesis, and the lesion is not premalignant.
 - a. **Clinically**, benign prostatic hypertrophy presents with decreased caliber and force of stream; trouble starting (hesitancy) and stopping the stream; postvoid dribbling, urinary retention, and incontinence; or urgency, frequency, nocturia, and dysuria. Prostate specific antigen (PSA) may be elevated but is usually <10 ng/ml.
 - b. **Complications** include urinary tract infections, urinary bladder trabeculation and diverticula formation, and hydronephrosis and renal failure (rare). Treatment varies, with available modalities including transurethral resection of prostate (TURP); the 5-alpha reductase

- inhibitor, finasteride (Proscar), and the selective alpha-1 receptor blockers, terazosin and prazosin.
- c. **Pathology.** Grossly, benign prostatic hypertrophy causes an enlarged prostate with well-demarcated nodules in the transition and central (periurethral zones), which often results in slitlike compression of the prostatic urethra. Microscopically, the lesion shows glandular and stromal hyperplasia resulting in the characteristic prostate enlargement.
2. **Prostate adenocarcinoma** is the most common cancer in men in the United States and is the second most common cause of cancer death in men. The incidence increases with age, and the highest rate is in African Americans.
 - a. **Clinical features.** Prostate adenocarcinoma is often clinically silent, but may present with lower back pain secondary to metastasis. Advanced localized disease may present with urinary tract obstruction or UTIs (uncommon). The tumor can be detected with digital rectal exam (induration), serum prostatic specific antigen (PSA) levels, and transrectal ultrasound and biopsy.
 - i. **Metastases** most commonly involve the obturator and pelvic lymph nodes. Osteoblastic bone metastasis to the lumbar spine can occur, and be associated with elevated alkaline phosphatase. Treatment of local disease is with prostatectomy and/or external beam radiation. Metastatic disease is treated with orchiectomy, estrogens, or androgen receptor blockade (flutamide or leuprolide). The disease course can be monitored with PSA levels.
 - b. **Pathology.** Prostate adenocarcinoma causes an ill-defined, firm, yellow mass that commonly arises in the posterior aspect of the peripheral zone. Microscopically, adenocarcinoma is seen, which is graded with the Gleason system.
 3. **Prostatitis.** Acute prostatitis is usually due to intraprostatic reflux of urine containing *Escherichia*, *Pseudomonas*, or *Klebsiella* pathogens. Chronic prostatitis may develop following recurrent acute prostatitis, and bacterial pathogens may not be detectable. Clinical findings can include fever (acute prostatitis), pain (lower back, perineal, or suprapubic), painful prostate on rectal exam, and dysuria (sometimes with hematuria).

Clinical Correlate

An elderly man with osteoblastic metastasis visible on x-ray should be considered as having prostate carcinoma until proven otherwise.

Chapter Summary

- Malformations of the penis related to aberrant opening of the urethra include epispadias (opening on dorsal surface) and hypospadias (opening on ventral surface). Balanitis is inflammation of the glans penis, often related to poor hygiene and lack of circumcision. Peyronie disease is penile fibromatosis resulting in curvature of the penis. Condyloma acuminatum is a warty growth related to HPV infection. Squamous cell carcinoma of the penis is uncommon in the United States but can be related to HPV infection. Priapism is a persistent painful erection. Erectile dysfunction has many causes.
- Varicocele is a dilated vein within the spermatic cord. Hydrocele is fluid within the tunica vaginalis. Spermatocele is a dilated efferent duct in the epididymis containing sperm.
- Acute epididymitis is usually caused by *Neisseria gonorrhoeae* and/or *Chlamydia trachomatis*. Chronic epididymitis is usually caused by tuberculosis. Orchitis or testicular inflammation can be caused by mumps.
- Testicular torsion is a twisting of the spermatic cord that may cause painful hemorrhagic infarction leading to gangrene.
- Testicular cancers tend to cause firm, painless masses, and occur in a wide variety of subtypes. Seminoma is a chemotherapy- and radiation therapy-sensitive cancer of young adult men that causes bulky testicular masses. Spermatocytic seminoma is a variant affecting older men. Cryptorchidism is a failure of descent of one or both testes, and is associated with an increased risk of developing seminoma. Male infertility has many causes.
- Embryonal carcinoma also affects young men and behaves more aggressively than seminoma. Choriocarcinoma is a highly malignant testicular carcinoma. Yolk sac tumor is the most common germ-cell tumor in children, in whom it has a better prognosis than in adults. Teratoma in testes (as opposed to in ovaries) is almost always malignant and aggressive. Mixed germ-cell tumors are common and usually behave aggressively.
- Most sex cord tumors of the testes are Leydig cell tumors, of which 10% are malignant. Testicular lymphoma is the most common testicular tumor in men over age 50 years.
- Benign prostatic hypertrophy (nodular hyperplasia) is an extremely common condition of older men that may alter the function of the urinary tract by compressing the urethra.
- Prostate cancer is the most common cancer in men in the United States and commonly arises in the posterior aspect of the peripheral zone of the prostate. It is often clinically silent, but may be detected by digital rectal exam, serum PSA levels, and transrectal ultrasound and biopsy.
- Prostatitis can be acute or chronic, and causes tenderness of the prostate on rectal examination.

THYROID GLAND

1. **Multinodular goiter** (nontoxic goiter) refers to an enlarged thyroid gland with multiple colloid nodules. Females are affected more frequently than males. Multinodular goiter is frequently asymptomatic, and the patient is typically euthyroid, with normal T4, T3, and TSH. Plummer syndrome is the development of hyperthyroidism (toxic multinodular goiter) late in the course.
 - a. **Microscopically**, the tissue shows nodules of varying sizes composed of colloid follicles. Calcification, hemorrhage, cystic degeneration, and fibrosis can also be present.

HYPERTHYROIDISM

1. The term **hyperthyroidism** is used when the mean metabolic rate of all cells is increased due to increased T4 or T3. Clinical features include tachycardia and palpitations; nervousness and diaphoresis; heat intolerance; weakness and tremors; diarrhea; and weight loss despite a good appetite. Laboratory studies show elevated free T4. In primary hyperthyroidism, TSH is decreased, while in secondary and tertiary hyperthyroidism, TSH is elevated.
2. **Graves disease** is an autoimmune disease characterized by production of IgG autoantibodies to the TSH receptor. Females are affected more frequently than males, with peak age 20 to 40 years. Clinical features include hyperthyroidism, diffuse goiter, ophthalmopathy (exophthalmus), and dermopathy (pretibial myxedema). Microscopically, the thyroid has hyperplastic follicles with scalloped colloid.
3. **Other causes of hyperthyroidism** include toxic multinodular goiter; toxic adenoma (functioning adenoma producing thyroid hormone); and Hashimoto and subacute thyroiditis (transient hyperthyroidism).

HYPOTHYROIDISM

1. The term **hypothyroidism** is used when the mean metabolic rate of all cells is decreased due to decreased T4 or T3.
 - a. **Clinical features** include fatigue and lethargy; sensitivity to cold temperatures; decreased cardiac output; myxedema (accumulation of proteoglycans and water); facial and periorbital edema; peripheral edema of the hands and feet; deep voice; macroglossia; constipation; and anovulatory cycles.
 - b. **Laboratory studies** show decreased free T4. In primary hypothyroidism, TSH is elevated, while in secondary and tertiary hypothyroidism, TSH is decreased.
2. **Iatrogenic hypothyroidism** is the most common cause of hypothyroidism in the United States, and is secondary to thyroidectomy or radioactive iodine treatment. Treatment is with thyroid hormone replacement.

Clinical Correlate

The most sensitive test in thyroid disease is TSH. If the TSH is normal, then the patient is euthyroid.

Note

Long-acting thyroid stimulator (LATS): original name for the autoantibodies of Graves disease

Thyroid-stimulating immunoglobulin (TSI): current name for the autoantibodies of Graves disease

3. **Congenital hypothyroidism** (cretinism) in endemic regions is due to iodine deficiency during intrauterine and neonatal life, and in nonendemic regions is due to thyroid dysgenesis. Affected individuals present with failure to thrive, stunted bone growth and dwarfism, spasticity and motor incoordination, and mental retardation. Goiter is present in endemic cretinism.
4. **Endemic goiter** is due to dietary deficiency of iodine and is uncommon in the United States.

THYROIDITIS

1. **Hashimoto thyroiditis** is a chronic autoimmune disease characterized by immune destruction of the thyroid gland and hypothyroidism. It is the most common noniatrogenic/nonidiopathic cause of hypothyroidism in the United States; it most commonly causes painless goiter in females more than males, and has peak age 40 to 65 years.
 - a. **Clinically**, Hashimoto thyroiditis most commonly causes hypothyroidism (due to destruction of thyroid tissue), but the initial inflammation may cause transient hyperthyroidism (hashitoxicosis).
 - i. Hashimoto thyroiditis may be **associated** with other autoimmune diseases (SLE, rheumatoid arthritis, Sjögren syndrome, etc.), and it has an increased risk of non-Hodgkin B-cell lymphoma.
 - b. **Pathology**. Hashimoto thyroiditis grossly produces a pale, enlarged thyroid gland, which microscopically shows lymphocytic inflammation with germinal centers and epithelial “Hürthle cell” changes.
2. **Subacute thyroiditis** (also called *de Quervain thyroiditis* and *granulomatous thyroiditis*) is the second most common form of thyroiditis; it affects females more than males and has peak age 30 to 50 years. The condition is typically preceded by a viral illness, produces a tender, firm, enlarged thyroid gland, and may be accompanied by transient hyperthyroidism. Microscopy shows granulomatous thyroiditis. The disease typically follows a self-limited course.
3. **Riedel thyroiditis** is a rare disease of unknown etiology, characterized by destruction of the thyroid gland by dense fibrosis and fibrosis of surrounding structures (trachea and esophagus). Females are affected more frequently than males, with most patients being middle-aged. Riedel thyroiditis causes an irregular, hard thyroid that is adherent to adjacent structures. The condition may clinically mimic carcinoma and present with stridor, dyspnea, or dysphagia. Microscopic examination shows dense fibrous replacement of the thyroid gland with chronic inflammation. Riedel thyroiditis is associated with retroperitoneal and mediastinal fibrosis.

Clinical Correlate

Thyroid tumors tend to be cold nodules on thyroid iodine 131 scans.

THYROID NEOPLASIA

1. **Adenomas**. Follicular adenomas are the most common. Clinically, adenomas are usually painless, solitary nodules that appear “cold” on thyroid scans. They may be functional and cause hyperthyroidism (toxic adenoma).
2. **Papillary carcinoma** accounts for 80% of malignant thyroid tumors. Females are affected more than males, with peak age 20 to 50 years. Radiation exposure is a risk factor. Resection is curative in most cases. Radiotherapy with iodine 131 is effective for metastases. The prognosis is excellent, with 20-year survival of 90% due to slow growth and metastasis to regional cervical lymph nodes.

- a. **Microscopically**, the tumor typically exhibits a papillary pattern. Occasional psammoma bodies may be seen. Characteristic nuclear features include clear “Orphan Annie eye” nuclei; nuclear grooves; and intranuclear cytoplasmic inclusions. Lymphatic spread to cervical nodes is common.
3. **Follicular carcinoma** accounts for 15% of malignant thyroid tumors. Females are affected more often than males, with peak age 40 to 60 years. Hematogenous metastasis to the bones or lungs is common.
4. **Medullary carcinoma** accounts for 5% of malignant thyroid tumors. This tumor arises from C cells (parafollicular cells) and secretes calcitonin. Microscopic examination shows nests of polygonal cells in an amyloid stroma. A minority (25%) of cases are associated with MEN II and MEN III syndromes.
5. **Anaplastic carcinoma** affects females more than males, with peak age greater than 60 years. Anaplastic carcinoma can present with a firm, enlarging, and bulky mass; or with dyspnea and dysphagia. The tumor has a tendency for early widespread metastasis and invasion of the trachea and esophagus. Microscopically, the tumor is composed of undifferentiated, anaplastic, and pleomorphic cells. This very aggressive tumor is often rapidly fatal.

PARATHYROID GLANDS

1. **Primary hyperparathyroidism.**
 - a. **Etiology.** Adenomas are the most common cause of primary hyperparathyroidism (80%), and they may be associated with MEN I. Parathyroid hyperplasia accounts for 15% of cases and is characterized by diffuse enlargement of all four glands. The enlarged glands are usually composed of chief cells. Parathyroid carcinoma is very rare. Hyperparathyroidism can also occur as a paraneoplastic syndrome of lung and renal cell carcinomas.
 - b. **Clinical features.** The excess production of parathyroid hormone (PTH) leads to hypercalcemia, with laboratory studies showing elevated serum calcium and PTH. Primary hyperparathyroidism is often asymptomatic, but may cause kidney stones; osteoporosis and osteitis fibrosa cystica, metastatic calcifications, or neurologic changes.
2. **Secondary hyperparathyroidism** is caused by any disease that results in hypocalcemia, leading to increased secretion of PTH by the parathyroid glands. The condition can result from chronic renal failure, vitamin D deficiency, or malabsorption.
3. **Hypoparathyroidism** can result from surgical removal of glands during thyroidectomy, DiGeorge syndrome, or idiopathic cause.
 - a. **Clinical features.** Laboratory studies show hypocalcemia. Treatment is with vitamin D and calcium.
 - i. **Chvostek sign** demonstrates twitching of the ipsilateral facial muscles after tapping the muscles, suggestive of neuromuscular excitability caused by hypocalcemia.
 - ii. **Trousseau sign** is performed by inflating a sphygmomanometer cuff above systolic blood pressure for several minutes so that if hypocalcemia is present, then muscular contractions, including flexion of the wrist and metacarpophalangeal joints, hyperextension of the fingers, and flexion of the thumb on the palm occur, suggesting neuromuscular excitability.
 - iii. **Clinical problems related to hypocalcemia.** The hypocalcemia may also cause psychiatric disturbances and cardiac conduction defects (ECG: prolonged QT interval).
 - b. Treatment is with vitamin D and calcium.

Clinical Correlate

Pituitary adenomas may be associated with MEN I.

PITUITARY GLAND, HYPOTHALAMUS, AND PINEAL GLAND

1. **Pituitary adenomas.**

- a. **Prolactinomas** are the most common type of pituitary adenoma. Lactotroph cells secrete prolactin, which results in hyperprolactinemia. Clinical features include galactorrhea, amenorrhea, and infertility, or decreased libido and impotence.
- b. **Growth-hormone-producing adenoma** is characterized by elevated growth hormone (GH) and elevated somatomedin C (insulin-like growth factor 1 [IGF-1]).

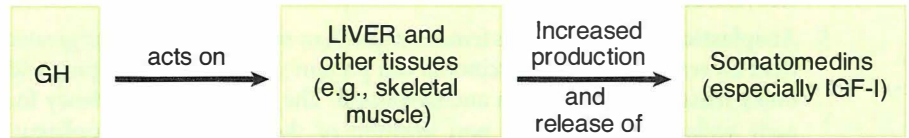
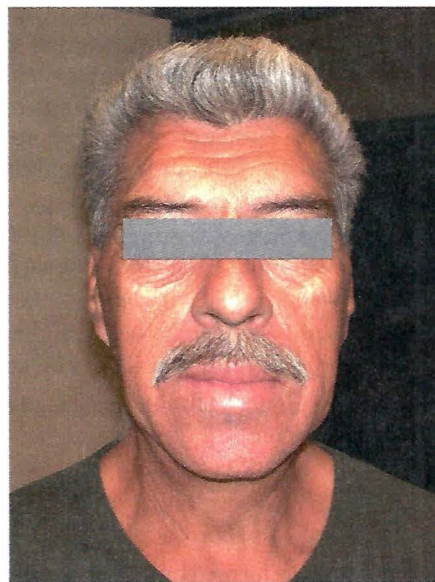


Figure 26-1

Growth-hormone-producing adenomas in children and adolescents prior to fusion of growth plates produce gigantism, which is characterized by tall stature and long extremities. These adenomas in adults after the growth plates have fused produce acromegaly, which is characterized by flat, broad forehead and enlarged hands and feet. The internal organs in acromegaly are also typically enlarged. Cardiac failure is the most common cause of death in acromegaly; headaches and visual field deficits can occur, and metabolic changes include impaired glucose tolerance and diabetes.



© Richard P. Usatine, M.D.
Used with permission.

Figure 26-2. Coarse facial features and protruding jaw seen with acromegaly

- c. **Nonfunctional adenomas** may produce hypopituitarism.
2. **Sheehan syndrome** is ischemic necrosis of the pituitary secondary to hypotension from postpartum hemorrhage resulting in panhypopituitarism.

- Diabetes insipidus.** Central diabetes insipidus is caused by ADH deficiency, which results in hypotonic polyuria, polydipsia, hypernatremia, and dehydration. Central diabetes insipidus can be due to head trauma, tumors, or other. Nephrogenic diabetes insipidus is caused by a lack of renal response to ADH.
 - Syndrome of inappropriate ADH secretion (SIADH).** SIADH is caused by excessive production of antidiuretic hormone (ADH), resulting in oliguria, water retention, hyponatremia, and cerebral edema. SIADH can be caused by paraneoplastic syndrome, head trauma, or other.
 - Craniopharyngioma** is a benign pituitary tumor derived from Rathke pouch remnants that is usually located above the sella turcica, but can extend downward to destroy the pituitary. It is the most common cause of hypopituitarism in children.
 - Hypothalamic disorders.** Disorders that can alter hypothalamic function can cause a variety of problems. **Hypopituitarism** (including dwarfism) can be due to a lack of releasing hormones from the hypothalamus. **Central diabetes insipidus** is due to lack of ADH synthesis. **Precocious puberty** is usually due to a midline hamartoma in boys. The hypothalamus can also be affected in **hydrocephalus**.
- Visual field changes** can complicate hypothalamic disorders. Masses that can affect the hypothalamus include pituitary adenoma, craniopharyngioma, midline hamartoma, and Langerhans histiocytosis. Inflammatory processes that can affect the hypothalamus include sarcoidosis and meningitis.
- Pineal diseases** include dystrophic calcification (a useful landmark for radiologists) and rarely tumors, with most being seminomas (most common) or teratomas.

Clinical Correlate

Any pituitary tumor that destroys more than 75% of the pituitary may result in panhypopituitarism, which is characterized by abnormalities of the thyroid, adrenal gland, and reproductive organs.

Common Causes of Panhypopituitarism

- Pituitary adenomas
- Sheehan syndrome
- Craniopharyngiomas

Clinical Correlate

The most common cause of ectopic ADH secretion is cancer (especially small cell lung cancer, though any lung lesion can lead to this manifestation). For this reason, SIADH may be a marker for occult malignancy. Drugs that may also lead to SIADH include chlorpropamide, carbamazepine, cyclophosphamide, tricyclic antidepressants, and SSRIs.

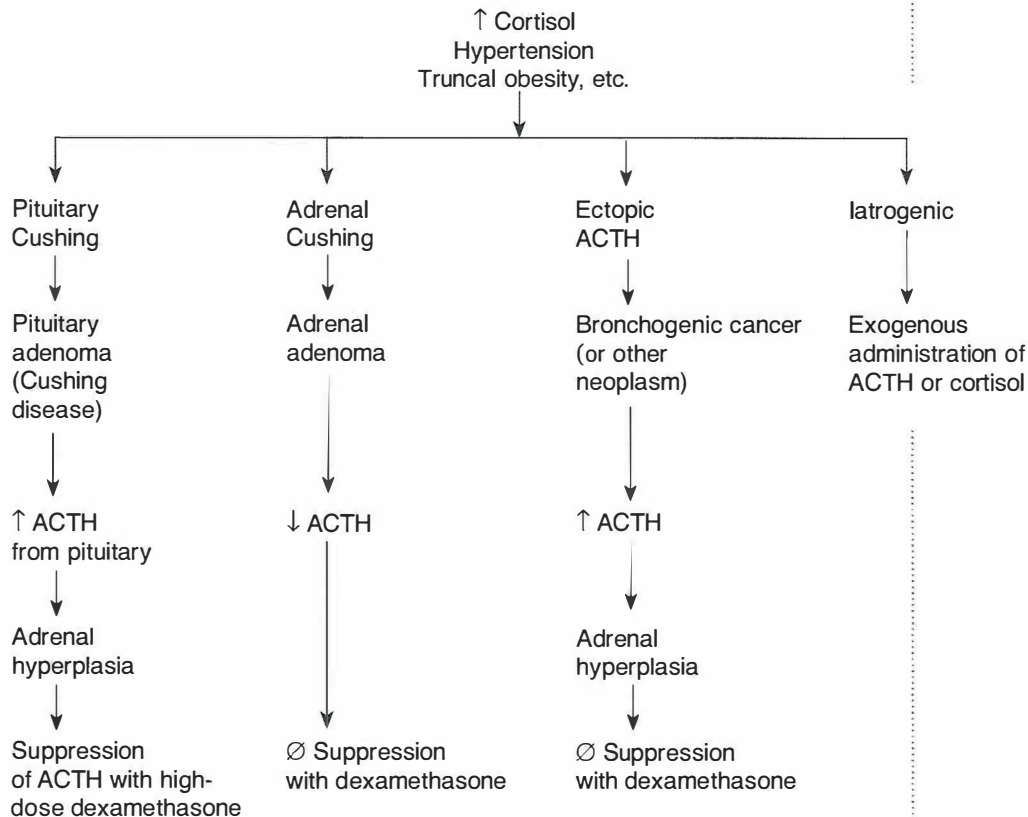


Figure 26-3. Summary of Cushing Syndrome and Its Effects

Note**Dexamethasone suppression test:**

Administration of dexamethasone (a cortisol analog) normally will suppress pituitary ACTH production, resulting in suppression of adrenal cortisol production and a decrease in urinary free cortisol.

Bridge to Embryology

The cells of the adrenal medulla are derived from neural crest cells. The cells of the adrenal cortex are derived from mesoderm.

Clinical Correlate**Pheochromocytoma**

The catecholamines produced by pheochromocytoma can affect both the alpha and beta receptors. Patients *must* have their hypertension controlled with an alpha blocker such as phenoxybenzamine prior to surgery. This control will help reduce the risk of severe intraoperative hypertension, such as might occur when the tumor is manipulated, causing release of large amounts of catecholamines.

ADRENAL GLAND

1. **Cushing syndrome** is characterized by increased levels of glucocorticoids.
2. **Primary hyperaldosteronism** (Conn syndrome) is due to an adrenocortical adenoma producing aldosterone. The elevated aldosterone causes hypertension due to retention of sodium and water. Laboratory studies show hypokalemia, elevated aldosterone, and decreased renin.
3. **Adrenogenital syndromes** are adrenal disorders characterized by excess production of androgens and virilization. These syndromes can be due either to adrenocortical adenoma/carcinoma, which produces androgens, or to congenital adrenal hyperplasia, a cluster of autosomal recessive enzyme defects (most common is 21-hydroxylase deficiency).
4. **Waterhouse-Friderichsen syndrome** (acute adrenal insufficiency) is a potentially fatal bilateral hemorrhagic infarction of the adrenal glands associated with a *Neisseria meningitidis* infection in children. It is clinically characterized by disseminated intravascular coagulation (DIC), acute respiratory distress syndrome, hypotension and shock, and acute adrenal insufficiency. Treatment is with antibiotics and steroid replacement.
5. **Addison's disease** (chronic adrenocortical insufficiency) is caused by destruction of the adrenal cortex, leading to a deficiency of glucocorticoids, mineralocorticoids, and androgens. The most common cause is autoimmune adrenalitis, though tuberculosis and metastatic cancer are other possible causes. Patients present with gradual onset of weakness, skin hyperpigmentation, hypotension, hypoglycemia, poor response to stress, and loss of libido. Treatment is with steroid replacement.
6. **Pheochromocytoma** ("dark/dusky-colored tumor") is an uncommon benign tumor of the adrenal medulla, which produces catecholamines (norepinephrine and epinephrine). It can present with severe headache, tachycardia and palpitations, diaphoresis and anxiety, or hypertensive episodes. Note the **Rule of 10s**:
 - 10% occur in children
 - 10% are bilateral
 - 10% occur outside the adrenal gland
 - 10% are malignant
 - 10% are familial (MEN II and III)

Diagnosis is by demonstrating elevated urinary vanillylmandelic acid (VMA) and catecholamines. Treatment involves controlling the patient's blood pressure and surgical removal of the tumor.

MULTIPLE ENDOCRINE NEOPLASIA (MEN) SYNDROMES

1. **Multiple endocrine neoplasia (MEN) syndromes** are autosomal dominant conditions with incomplete penetrance that are characterized by hyperplasia and tumors of endocrine glands.
2. **MEN I** (Werner syndrome) features tumors of the pituitary gland, parathyroids, and pancreas. It is associated with peptic ulcers and the Zollinger-Ellison syndrome. The affected gene is MEN I, a tumor suppressor gene that encodes a nuclear protein called menin.
3. **MEN II** (IIa or Sipple syndrome) features medullary carcinoma of the thyroid, pheochromocytoma, and parathyroid hyperplasia or adenoma. The genetic mutation involves RET proto-oncogene, which is a receptor tyrosine kinase for members of the glial cell line-derived neurotrophic factor family of extracellular signaling molecules.
4. **MEN III** (IIb) features medullary carcinoma of the thyroid, pheochromocytoma, and mucocutaneous neuromas. There is a genetic mutation of RET ("rearranged during transfection") proto-oncogene.

Chapter Summary

- Multinodular goiter is an enlarged thyroid gland with multiple colloid nodules that is frequently asymptomatic and euthyroid.
- General features of hyperthyroidism include tachycardia, nervousness, diaphoresis, heat intolerance, weakness, tremors, diarrhea, and weight loss. Free T4 is elevated and TSH is decreased in primary hyperthyroidism and increased in secondary and tertiary hyperthyroidism.
- Graves disease is an autoimmune disease characterized by production of IgG autoantibodies to the TSH receptor. Clinical features include hyperthyroidism, goiter, exophthalmos, and pretibial myxedema. Hyperthyroidism can also be caused by toxic multinodular goiter, toxic adenoma, and transiently during Hashimoto disease and subacute thyroiditis.
- General features of hypothyroidism include fatigue, lethargy, sensitivity to cold temperatures, decreased cardiac output, myxedema, and constipation. Free T4 is decreased and TSH is elevated in primary hypothyroidism and decreased in secondary and tertiary hypothyroidism.
- Congenital hypothyroidism develops secondary to iodine deficiency during intrauterine and neonatal life and causes mental retardation, musculoskeletal problems, and goiter. Endemic goiter is uncommon in the United States and is due to dietary deficiency of iodine.
- Hashimoto thyroiditis is a chronic autoimmune disease characterized by immune destruction of the thyroid gland and hypothyroidism.
- Subacute thyroiditis is a cause of transient hyperthyroidism following a viral illness.
- Riedel thyroiditis is a rare disease of unknown etiology characterized by destruction of the thyroid gland by dense fibrosis of surrounding structures.
- Thyroid adenomas are usually painless, solitary nodules.
- Thyroid carcinomas occur in a number of histologic types, including papillary (most common with excellent prognosis), follicular (tends to spread hematogenously), medullary (secretes calcitonin, makes amyloid, and may be associated with MEN II or III), and anaplastic (rapidly fatal).
- Primary hyperparathyroidism is most often due to parathyroid adenoma or parathyroid hyperplasia, and can be characterized by elevated serum calcium and PTH, kidney stones, osteoporosis and osteitis fibrosa cystica, metastatic calcifications, and neurologic changes. Many cases are asymptomatic. Secondary hyperparathyroidism can be seen in any disease that results in hypocalcemia leading to increased secretion of PTH by the parathyroid glands, including chronic renal failure, vitamin D deficiency, and malabsorption.
- Hypoparathyroidism is characterized by hypocalcemia, tetany, psychiatric disturbances, and cardiac conduction defects. It can be the result of surgical removal of the glands during thyroidectomy, DiGeorge syndrome, or it can be idiopathic.

(Continued)

Chapter Summary (cont'd)

- Pituitary adenomas can produce prolactin (causing galactorrhea, amenorrhea, and infertility), growth hormone (causing gigantism and acromegaly), or other pituitary hormones. Sheehan syndrome is ischemic necrosis of the pituitary secondary to hypotension from postpartum hemorrhage resulting in panhypopituitarism. Diabetes insipidus is ADH deficiency resulting in hypotonic polyuria, hypernatremia, and dehydration. SIADH is excessive production of ADH, resulting in oliguria, water retention, hyponatremia, and cerebral edema.
- Cushing syndrome is characterized by increased levels of glucocorticoids, whose origin may be iatrogenic, pituitary corticotroph adenoma, adrenocortical adenoma, or paraneoplastic syndrome.
- Primary hyperaldosteronism occurs when an adrenocortical adenoma produces aldosterone, leading to hypertension, hypokalemia, elevated aldosterone, and decreased renin.
- Adrenogenital syndromes are adrenal disorders characterized by excess production of androgens and virilization and can be due to either an adrenocortical adenoma/carcinoma or congenital adrenal hyperplasia.
- Waterhouse-Friderichsen syndrome is acute adrenal insufficiency with shock and DIC seen in the setting of bilateral hemorrhagic infarction of the adrenal glands, usually in a child with a *Neisseria meningitidis* infection.
- Addison disease is chronic adrenocortical insufficiency and is due to destruction of the adrenal cortex, leading to a deficiency of glucocorticoids, mineralocorticoids, and androgens.
- Pheochromocytoma is an uncommon tumor of the adrenal medulla that produces catecholamines and may present with severe headache, tachycardia, diaphoresis, and hypertensive episodes.
- MEN I features tumors of the pituitary gland, parathyroids, and pancreas. MEN II features medullary carcinoma of the thyroid, pheochromocytoma, and parathyroid lesions. MEN III features medullary carcinoma of the thyroid, pheochromocytoma, and mucocutaneous neuromas.
- Craniopharyngioma is an important cause of hypopituitarism in children. Hypothalamic disorders can cause hypopituitarism, central diabetes insipidus, precocious puberty, hydrocephalus, and visual field defects. Pineal tumors are usually seminomas or teratomas.

NORMAL BONE

1. **Normal bone** is composed of organic matrix and inorganic matrix. The organic matrix includes cells, type I collagen (90% of bone protein), osteocalcin, glycoproteins, and proteoglycans. The inorganic matrix includes calcium hydroxyapatite $\text{Ca}_{10}(\text{PO}_4)_6(\text{OH})_2$, magnesium, potassium, chloride, sodium, and fluoride.
2. **Cell types.** **Osteoblasts** are responsible for the production of osteoid (unmineralized bone); they contain high amounts of alkaline phosphatase, have receptors for parathyroid hormone (PTH), and modulate osteoclast function. **Osteocytes** are responsible for bone maintenance; they are osteoblasts that have become incorporated in the matrix. **Osteoclasts** are responsible for bone resorption; they contain high amounts of acid phosphatase and collagenase, and resorb bone within Howship's lacunae.
3. **Bone remodeling** occurs throughout life and is necessary to maintain healthy bones. Bone resorption by osteoclasts is tightly balanced with bone formation by osteoblasts.
4. Important **hormones** involved in bone physiology include parathyroid hormone (PTH), calcitonin, vitamin D, estrogen, thyroid hormone, cortisol, and growth hormone.
5. **Formation of bones.** **Intramembranous bone** occurs as direct bone formation without a "cartilage model." Intramembranous bones include flat bones such as the cranium, clavicle, vertebrae, wrist, and ankle bones. Intramembranous growth is also involved in appositional bone growth. **Endochondral bone** is indirect bone formation from a "cartilage model" at the epiphyseal growth plates; this type of bone formation occurs in long bones such as the femur, humerus, tibia, fibula, etc.

Clinical Correlate

Elevated levels of serum alkaline phosphatase and osteocalcin are markers of increased bone turnover.

HEREDITARY BONE DISORDERS

1. **Achondroplasia** is the most common form of inherited **dwarfism**, and is due to an autosomal dominant mutation in fibroblast growth factor receptor 3 (FGFR3) on chromosome 4. Activation of FGFR3 inhibits cartilage synthesis at the epiphyseal growth plate, resulting in *decreased enchondral bone formation and premature ossification of the growth plates*. Long bones are short and thick, leading to dwarfism with short extremities. Cranial and vertebral bones are spared, leading to a relatively large head and trunk. Intelligence, life span, and reproductive ability are normal.
2. **Osteogenesis imperfecta (OGI)** ("brittle-bone disease") is a hereditary defect leading to abnormal synthesis of type I collagen. Patients have *generalized osteopenia* (brittle bones), resulting in *recurrent fractures* and skeletal deformity. Most patients have an *abnormally thin sclera with a blue hue*. Laxity of joint ligaments leads to hypermobility. Involvement of the inner and middle ear bones produces *deafness*. Some patients have dentinogenesis imperfecta, characterized by small, fragile, and discolored teeth due to a deficiency of dentin. The dermis may be abnormally thin, and the skin is susceptible to easy bruising. Treatment is supportive.

Table 27-1. Clinical Phenotypes of OGI

Four clinical phenotypes of varying severity. All are rare.

Type I

- (1) Autosomal dominant
- (2) Fractures
- (3) Blue sclerae
- (4) Hearing loss
- (5) Little progression after puberty

Type II

- (1) Autosomal recessive
- (2) Stillborn infant or death after birth with generalized crumpled bones

Type III

- (1) Autosomal dominant or recessive
- (2) Progressive
- (3) Multiple fractures
- (4) Severe skeletal deformity
- (5) Dentinogenesis imperfecta
- (6) Hearing loss
- (7) Blue → white sclerae

Type IV

- (1) Autosomal dominant
- (2) Variable severity
- (3) Fractures
- (4) Skeletal deformity
- (5) Normal sclerae
- (6) Sometimes dentinogenesis imperfecta

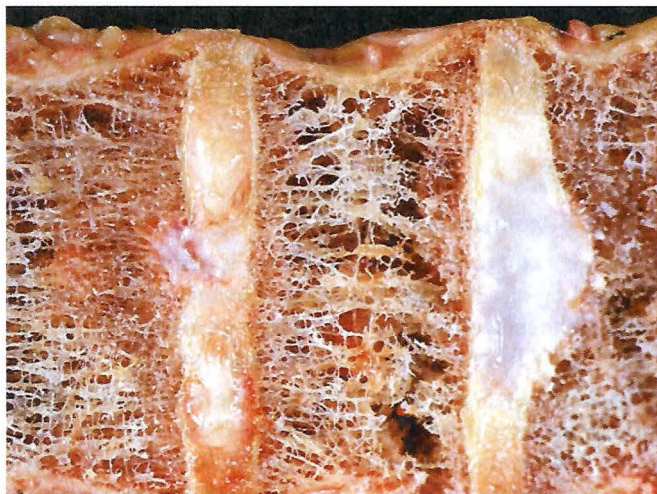3. **Osteopetrosis** (also called marble bone disease and Albers-Schönberg disease) is a hereditary defect leading to decreased osteoclast function, with resulting decreased resorption and thick sclerotic bones. X-ray findings show symmetrical generalized osteosclerosis. Long bones may have broadened metaphyses, resulting in an “Erlenmeyer flask”-shaped deformity. Treatment is with bone marrow transplantation.
 - a. **Major clinical forms.** The **autosomal recessive** (malignant type) form affects infants and children, causing multiple fractures and early death due to anemia, infection, and hemorrhage. The **autosomal dominant** (benign type) form affects adults, causing fractures; mild anemia; cranial nerve impingement. A third form, **carbonic anhydrase II deficiency**, has autosomal recessive genetics and causes renal tubular acidosis and cerebral calcification.
 - b. **Pathology.** There is increased bone density and thickening of bone cortex. The thickened bones are brittle and fracture easily. Myelophthitic process (replacement of hemopoietic tissue in the bone marrow by abnormal tissue, such as fibrous tissue or neoplasia) can occur due to narrowing and fibrosis of the medullary cavities, and may lead to pancytopenia and extramedullary hematopoiesis. Cranial nerve compression due to narrowing of cranial foramina may result in blindness, deafness, and facial nerve palsies. Hydrocephalus may develop due to obstruction of CSF.

PAGET DISEASE (OSTEITIS DEFORMANS)

1. **Paget disease** (osteitis deformans) is a *localized disorder of bone remodeling*, resulting in excessive bone resorption followed by disorganized bone replacement, producing thickened but weak bone that is susceptible to deformity and fracture. It is thought to possibly be related to slow-virus infection with paramyxovirus, and also possibly to have a genetic predisposition. Paget disease begins after age 40 years and is common in those of European ancestry.
2. **Forms of Paget disease.** The monostotic (15%) form involves one bone; while the polyostotic (85%) form involves multiple bones. Common sites of involvement include the skull, pelvis, femur, and vertebrae.
3. Paget disease develops in 3 **stages**:
 - The osteolytic stage (osteoclastic activity predominates)
 - The mixed osteolytic-osteoblastic stage
 - The osteosclerotic stage (osteoblastic activity predominates in this “burnout stage”)
4. **Pathology.** Microscopically, there is a haphazard arrangement of cement lines, creating a “mosaic pattern” of lamellar bone. Involved bones are thick but weak and fracture easily. Skull involvement leads to increased head size and foraminal narrowing that can impinge on cranial nerves, often leading to deafness. Involvement of facial bones may produce a lion-like facies.
5. **Clinical features.** Most cases are asymptomatic at presentation, but Paget disease can also cause bone pain and deformity; fractures; warmth of the overlying skin due to bone hypervascularity. X-rays show bone enlargement with lytic and sclerotic areas. Laboratory studies show highly elevated serum alkaline phosphatase and increased levels of urinary hydroxyproline. Complications include arteriovenous shunts within marrow, which may result in high-output cardiac failure, and an increased incidence of osteosarcoma and other sarcomas.

OSTEOPOROSIS

1. **Osteoporosis** is decreased bone mass (osteopenia), resulting in thin, fragile bones susceptible to fracture. It is the most common bone disorder in the United States, and it most commonly occurs in postmenopausal Caucasian women and the elderly.

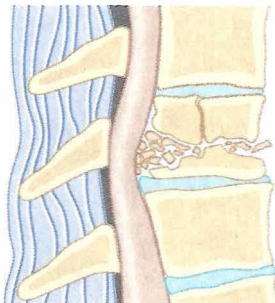


© Katsumi M. Miyaj, M.D., Ph.D.;
Regents of the University of California. Used with permission.

Figure 27-1. Marked thinning of bony trabeculae in osteoporosis.

Note

In osteoporosis, bone is formed normally but in decreased amounts.



Compression Fracture

Note

Rickets and osteomalacia are disorders of osteoid mineralization; osteoid is produced in normal amounts but is not calcified properly.

Clinical Correlate

The laboratory findings help distinguish osteomalacia from osteoporosis.

2. **Pathogenesis.** Primary causes of osteoporosis include estrogen deficiency (postmenopausal, Turner syndrome); genetic factors (low density of original bone); lack of exercise; old age; and nutritional factors. Secondary causes include immobilization; endocrinopathies (e.g., Cushing disease, thyrotoxicosis); malnutrition (e.g., deficiencies of calcium, vitamins C and D, protein); corticosteroids; and genetic disease (e.g., OGI, Gaucher disease).
3. **Clinical features.** Patients may experience bone pain and fractures. Weight-bearing bones are predisposed to fractures, with common fracture sites including vertebrae (compression fracture); femoral neck (hip fracture); and distal radius (Colles fracture). There can be a loss of height and kyphosis. X-rays show generalized radiolucency of bone (osteopenia). Dual-energy x-ray absorptiometry (DEXA) can also be of help in quantitating the degree of osteoporosis. Laboratory studies show normal serum calcium, phosphorus, and alkaline phosphatase. Microscopically, the bone has thinned cortical and trabecular bone.
4. **Treatment** can include estrogen replacement therapy (controversial; not recommended currently); weight-bearing exercise; calcium and vitamin D; bisphosphonate (alendronate); and calcitonin.

OSTEOMALACIA AND RICKETS

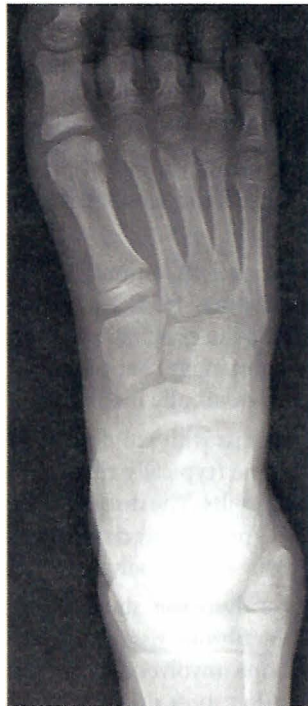1. **Osteomalacia and rickets** are both characterized by decreased mineralization of newly formed bone. The conditions are usually caused by deficiency or abnormal metabolism of vitamin D, with specific causes including dietary deficiency of vitamin D; intestinal malabsorption; lack of sunlight; and renal and liver disease. Treatment is with vitamin D and calcium.
2. **Rickets** (children) occurs in children prior to closure of the epiphyses. Both remodeled bone and bone formed at the epiphyseal growth plate are undermineralized. Enchondral bone formation is affected, leading to skeletal deformities. Skull deformities include craniotabes and frontal bossing. The “rachitic rosary” is a deformity of the chest wall as a result of an overgrowth of cartilage at the costochondral junction. Pectus carinatum (pigeon-breast deformity) is an outward protrusion of the sternum. Lumbar lordosis is a form of spinal curvature related to rickets. Bowing of the legs (curvature of femur/tibia due to weight bearing) also occurs. Fractures may also be present.
3. **Osteomalacia** (adults) is due to impaired mineralization of the osteoid matrix resulting in thin, fragile bones susceptible to fracture. The patient may present clinically with bone pain or fractures (vertebrae, hips, and wrist). X-rays show diffuse radiolucency of bone (osteopenia). Laboratory studies show low serum calcium, low serum phosphorus, and high alkaline phosphatase.

OSTEOMYELITIS

1. **Pyogenic osteomyelitis.**
 - a. The most common **route of infection** is hematogenous spread (leading to seeding of bone after bacteremia); hematogenous spread commonly affects the metaphysis. Other routes of spread include direct inoculation and spread from an adjacent site of infection.
 - b. **Microbiology.** *Staphylococcus aureus* is the most common infecting organism; other important pathogens include *Escherichia coli*, *streptococci*, *gonococci*, *Haemophilus influenzae*, *Salmonella* (common in sickle cell disease), and *Pseudomonas* (common in IV drug abusers and diabetics).
 - c. **Clinically**, osteomyelitis is characterized by fever and leukocytosis; and localized pain, erythema, and swelling. X-ray studies may be normal

for up to 2 weeks, then initially showing periosteal elevation, which can then be followed by a lytic focus with surrounding sclerosis.

- d. **Pathology.** Microscopic examination shows suppurative inflammation. Vascular insufficiency can lead to ischemic necrosis of bone; a sequestrum is an area of necrotic bone, while an involucrum is the new bone formation that surrounds the sequestrum. The diagnosis is established with blood cultures or with bone biopsy and culture.
- e. **Treatment** is by antibiotics with or without surgical drainage.
- f. **Complications** include fracture; intraosseous (Brodie) abscess; secondary amyloidosis; sinus tract formation, squamous cell carcinoma of the skin at the site of a persistent draining sinus tract, and, rarely, osteogenic sarcoma.



© Peter Vangeertruyden:
National Capital Consortium.
Used with permission.

Figure 27-2. Head of third metatarsal shows a subtle radiolucency due to the lytic activity of acute osteomyelitis

2. **Tuberculous osteomyelitis** occurs in 1% of cases of tuberculosis. It presents with pain or tenderness, fever, night sweats, and weight loss. Biopsy shows caseating granulomas with extensive destruction of the bones. Common sites of involvement include thoracic and lumbar vertebrae (“Pott disease”). Complications include vertebral compression fracture; psoas abscesses; and secondary amyloidosis.

MISCELLANEOUS BONE DISORDERS

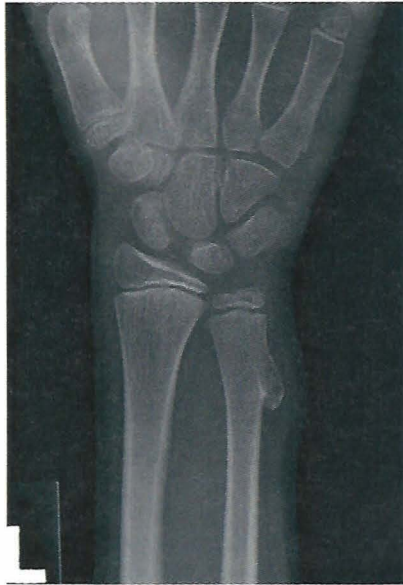1. **Avascular necrosis** (also called aseptic necrosis and osteonecrosis) is the term used for ischemic necrosis of bone and bone marrow. Causes include trauma and/or fracture (most common); idiopathic; steroid use; sickle cell anemia; Gaucher disease; and Caisson disease. Avascular necrosis can be complicated by osteoarthritis and fractures.

2. **Osteitis fibrosa cystica** (also called von Recklinghausen disease of bone) is seen when excessive parathyroid hormone (hyperparathyroidism) causes osteoclast activation and generalized bone resorption, which may cause bone pain, bone deformities, and fractures. Osteitis fibrosa cystica occurs more commonly in primary hyperparathyroidism, and the excess parathyroid hormone may be produced by parathyroid adenoma or parathyroid hyperplasia. The condition can resolve if the hyperparathyroidism is treated.
 - a. **Pathology.** Microscopic examination shows excess bone resorption with increased number of osteoclasts, fibrous replacement of marrow, and cystic spaces in trabecular bone (dissecting osteitis). “Brown tumors” are brown bone masses produced by cystic enlargement of bones with areas of fibrosis and organized hemorrhage.
3. **Hypertrophic osteoarthropathy** presents with painful swelling of wrists, fingers, ankles, knees, or elbows. It can occur in the setting of bronchogenic carcinoma (a paraneoplastic syndrome), chronic lung diseases, cyanotic congenital heart disease, and inflammatory bowel disease; and it will often regress when the underlying disease is treated.
 - a. **Pathologically,** the ends of long bones show periosteal new bone formation, which can produce digital clubbing and often arthritis of adjacent joints.
4. **Osgood-Schlatter disease** is a common cause of knee pain in adolescents which develops when stress from the quadriceps during rapid growth causes inflammation of the proximal tibial apophysis at the insertion of the patellar tendon. Permanent changes to the knees (knobby knees) may develop. The lesion is not usually biopsied.
5. **Fibrous dysplasia** presents with painful swelling, deformity, or pathologic fracture of involved bone (typically ribs, femur, or cranial bones), usually in children and young adults. The disease process is linked to a tissue mutation in a stimulatory G protein on chromosome 20 that causes osteoblasts to produce fibrous tissue rather than bone.
 - a. **Pathology.** Fibrous dysplasia shows benign, non-neoplastic replacement of marrow by fibrous tissue that may involve single or multiple bones. Multiple bone involvement may be associated with Albright syndrome (café-au-lait spots on skin, precocious sexual development).

BENIGN TUMORS OF BONE

1. **Osteoma** is a benign neoplasm that frequently involves the skull and facial bones. “Hyperostosis frontalis interna” describes an osteoma that extends into the orbit or sinuses. Osteoma can be associated with Gardner syndrome.
2. **Osteoid osteoma** is a benign, painful growth of the diaphysis of a long bone, often the tibia or femur. Osteoid osteoma affects males more than females, with peak age 5 to 25 years. The pain of osteoid osteoma tends to be worse at night and relieved by aspirin. X-rays studies show central radiolucency surrounded by a sclerotic rim. Microscopically, these tumors show a small (<2 cm) lesion of the cortex characterized by a central nidus of osteoid surrounded by dense sclerotic rim of reactive cortical bone.
3. **Osteoblastoma** is a tumor that is similar to an osteoid osteoma but is larger (>2 cm) and often involves vertebrae.
4. **Osteochondroma** (exostosis) is a benign bony metaphyseal growth capped with cartilage that originates from epiphyseal growth plate. It typically presents in adolescent males who have firm, solitary growths at the ends of long bones. Osteochondromas may be asymptomatic, cause

pain, produce deformity, or undergo malignant transformation (rare). Osteochondromatosis (multiple hereditary exostosis) produces multiple, often symmetric, osteochondromas.



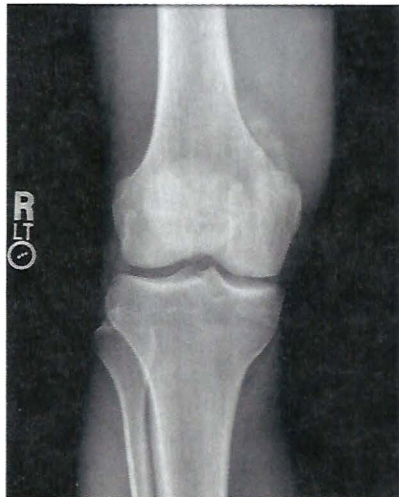© Roger Boodoo -
National Naval Medical Center.
Used with permission.

Figure 27-3. Osteochondroma seen on the bony protuberance on the distal ulna

5. **Enchondroma** is a benign cartilaginous growth within the medullary cavity of bone, usually involving the hands and feet. The tumor is typically solitary, asymptomatic, and requires no treatment. Multiple enchondromas (enchondromatosis) can occur as part of both Ollier disease and Maffucci syndrome.
6. **Giant-cell tumor of bone** (“osteoclastoma”) is an uncommon benign neoplasm containing multinucleated giant cells admixed with stromal cells. More cases occur in females than males, with peak age 20 to 50 years.
 - a. **Clinically**, the tumor produces a bulky mass with pain and fractures. X-rays typically show an expanding lytic lesion surrounded by a thin rim of bone, which may have a “soap bubble” appearance. Treatment is with surgery (curettage or *en bloc* resection). Osteoclastoma is locally aggressive with a high rate of recurrence (40–60%); approximately 4% will metastasize to the lungs.
 - b. **Pathology.** Grossly, the tumor causes a red-brown mass with cystic degeneration that often involves the epiphyses of long bones, usually around the knee (distal femur and proximal tibia). Microscopically, the tumor shows multiple osteoclast-like giant cells are distributed within a background of mononuclear stromal cells.

MALIGNANT TUMORS OF BONE

1. **Osteosarcoma** (osteogenic sarcoma) is the most common primary malignant tumor of bone, and the tumor occurs more frequently in males than in females. Most cases occur in teenagers (ages 10–25 years), and patients with familial retinoblastoma have a high risk.



© James W Graham -
National Naval Medical Center.
Used with permission.

Figure 27-4. Osteosarcoma seen in the the fuzzy calcifications adjacent to the distal femur

- a. **Clinically**, osteosarcoma presents with localized pain and swelling. The classic x-ray findings are Codman triangle (periosteal elevation), “sunburst” pattern, and bone destruction. The treatment is with surgery and chemotherapy. The prognosis is poor, but is improved with aggressive management, such as resecting single pulmonary metastases (hematogenous metastasis to the lungs is common).
 - b. **Secondary osteosarcomas** occur in elderly persons. These highly aggressive tumors are associated with Paget disease, irradiation, and chronic osteomyelitis.
 - c. **Pathology.** Grossly, osteosarcoma often involves the metaphyses of long bones, usually around the knee (distal femur and proximal tibia). The tumor produces a large, firm, white-tan mass with necrosis and hemorrhage. Microscopically, osteosarcoma is characterized by anaplastic cells producing osteoid and bone.
2. **Chondrosarcoma** is a malignant tumor of chondroblasts that may arise *de novo* or secondary to a preexisting enchondroma, exostosis, or Paget disease. Males are affected more frequently than females, with peak age 30–60 years. Chondrosarcoma presents with enlarging mass with pain and swelling, and it typically involves the pelvic bones, spine, and shoulder girdle. Microscopically, chondrosarcoma is composed of atypical chondrocytes and chondroblasts, often with multiple nuclei in a lacuna.
 3. **Ewing sarcoma** is a malignant neoplasm of undifferentiated cells arising within the marrow cavity. Males are affected slightly more often than females. Most cases occur in teenagers (age range 5–20 years). The classic translocation for Ewing sarcoma is t(11;22), which produces the EWS-FLI1 fusion protein.

- a. **Clinically**, patients present with pain, swelling, and tenderness. X-ray studies show concentric “onion-skin” layering of new periosteal bone. The tumor is treated with chemotherapy, surgery, and/or radiation, and has a 5-year survival rate of 75%.
 - b. **Pathology**. Grossly, Ewing sarcoma often affects the diaphyses of long bones, with the most common sites being the femur, pelvis, and tibia. The tumor characteristically produces a white-tan mass with necrosis and hemorrhage. Microscopically, Ewing sarcoma is characterized by sheets of undifferentiated small, round, blue cells resembling lymphocytes, which may form Homer Wright pseudorosettes. The tumor cells erode through the cortex and periosteum and invade surrounding tissues.
4. **Metastasis to bone** is much more common than primary bone tumor. Common primary sites include prostate (often osteoblastic), breast, lung, thyroid, and kidney.

Chapter Summary

- Normal bone is composed of an organic matrix (containing collagen, osteocalcin, glycoproteins, and cells) and an inorganic matrix (containing calcium hydroxyapatite and other minerals). Cell types within bone include osteoblasts (live at edge and make bone), osteocytes (live within and maintain bone), and osteoclasts (live at edge and resorb bone).
- Bone remodeling occurs throughout life and is under complex hormonal control by PTH, calcitonin, vitamin D, estrogen, cortisol, growth hormone, and thyroid hormone.
- Intramembranous bone formation occurs in flat bone and axial bone without a “cartilage model”; endochondral bone formation occurs in long bones by replacement of preexisting cartilage.
- Autosomal dominant achondroplasia is the most common form of inherited dwarfism and is clinically characterized by short extremities, normal head and trunk, and normal life span and intelligence.
- Osteogenesis imperfecta has variable genetics and severity but is in general characterized by brittle bones and often blue sclera, joint hypermobility, deafness, and teeth abnormalities.
- Osteopetrosis, or marble bone disease, is a hereditary disease (variable genetics) characterized by thick sclerotic bones that fracture easily and may secondarily compromise marrow cavities (leading to pancytopenia), foramina (leading to nerve palsies, blindness, or deafness), and CSF flow (leading to hydrocephalus).
- Paget disease of bone is an acquired localized (as opposed to the general involvement in osteopetrosis) disorder of bone remodeling, resulting in excessive bone resorption followed by disorganized bone replacement (in a characteristic “mosaic” microscopic pattern), producing thickened bone that fractures easily and may impinge on cranial nerves.
- Osteoporosis is a common disease in which bone mass decreases, resulting in thin, fragile bones that are susceptible to fracture. Predisposing factors include estrogen deficiency, genetically low density of original bone, lack of exercise (or immobilization), old age, nutritional deficiencies, and corticosteroid use.

(Continued)

Chapter Summary (cont'd)

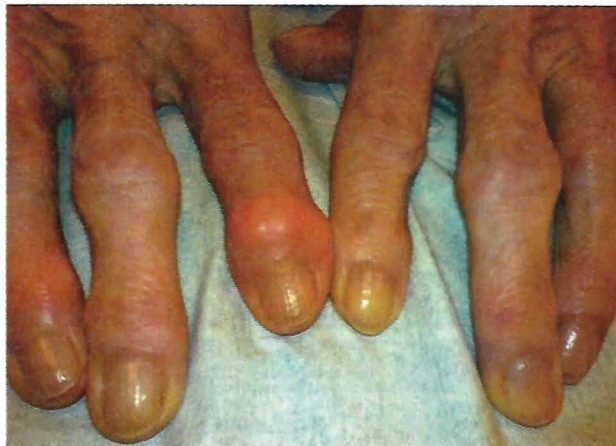- Both osteomalacia (adults) and rickets (children) are characterized by decreased mineralization of newly formed bone, often secondary to vitamin D deficiency or abnormal metabolism. Rickets tends to present with skeletal deformities, while osteomalacia tends to present with fractures.
- Pyogenic osteomyelitis produces local symptoms accompanied by fever and can be due to many bacteria (most commonly *Staphylococcus aureus*) that may reach bone via blood, direct inoculation, or spread from nearby infection.
- Complications include ischemic necrosis of bone, sequestrum formation, fracture, intraosseous abscess, secondary amyloidosis, sinus tract formation (which may rarely develop squamous cell carcinoma of the skin), and (rarely) osteogenic sarcoma. Tuberculous osteomyelitis is a rare but very destructive and difficult-to-treat complication of tuberculosis.
- Avascular necrosis of bone (particularly common in the femoral head) is an ischemic necrosis of bone and bone marrow (predisposing for osteoarthritis and fractures) that can be idiopathic or occur secondary to trauma, steroid use, sickle cell anemia, or other diseases.
- Osteitis fibrosa cystica is the name for the generalized bone resorption with accompanying histologic changes seen in hyperparathyroidism; hemorrhage and fibrosis within the bone may produce “brown tumors.”
- Hypertrophic osteoarthropathy may complicate other diseases (bronchogenic carcinoma, chronic lung disease, cyanotic congenital heart disease, and inflammatory bowel disease) and is due to periosteal new bone formation with pain and swelling of the ends of long bones, notably in wrists, fingers, ankles, knees, or elbows. Osgood-Schlatter disease is a common cause of knee pain in adolescents. Fibrous dysplasia usually occurs in children and young adults, and presents with painful swelling, deformity, or pathologic fracture of the involved bone; multiple bone involvement may be associated with Albright syndrome.
- Benign tumors of bone include osteoma (head, may be associated with Gardner syndrome), osteoid osteoma (tibia or femur of older children to young adults), osteblastoma (vertebrae), osteochondroma (long bones of adolescent boys, bony outgrowth with cartilage cap, may be hereditary syndrome if multiple), and enchondroma (cartilage in medullary cavity, may be part of Ollier disease or Maffucci syndrome if multiple). Giant-cell tumor of the bone is a benign neoplasm that tends to involve the knee of young to middle-aged adults and on x-ray shows an expanding lytic lesion surrounded by a thin rim of bone that may resemble a “soap bubble.”
- Osteosarcoma is the most common primary (aggressively) malignant tumor of bone. It often causes a large mass of the knee in teenagers or young adults, and it may be associated with familial retinoblastoma. Osteosarcoma has a characteristic x-ray pattern with periosteal elevation (Codman triangle), “sunburst” pattern, and bone destruction. Chondrosarcoma tends to cause an enlarging mass of pelvis, spine, or shoulder in middle-aged individuals (male > female) and may arise *de novo* or secondary to a pre-existing enchondroma, exostosis, or Paget disease. Ewing sarcoma is an aggressive (but often responsive to therapy) malignant neoplasm of small, undifferentiated cells that develops within the marrow cavity of femur, pelvis, and tibia of children and teenagers.
- Metastases to bone are more common than primary bone tumors; common primary sites include prostate (may cause new bone formation), breast, lung, thyroid, and kidney.

Table 28-1. Osteoarthritis (OA) Versus Rheumatoid Arthritis (RA)

Osteoarthritis (OA)	Rheumatoid Arthritis (RA)
“Wear and tear”	Systemic autoimmune disease (+) Rheumatoid factor (+) Rheumatoid nodules
Degeneration of articular cartilage	Synovial proliferation
Weight-bearing joints ● Knees, hips, spine	Small joints ● Hands and feet
Asymmetrical	Symmetrical and migratory

OSTEOARTHRITIS (DEGENERATIVE JOINT DISEASE)

- Osteoarthritis** (degenerative joint disease) is a joint degeneration with loss of articular cartilage with no to minimal inflammation. It is the most common form of arthritis. The risk increases with age; osteoarthritis affects at least one joint in 80% of people over 70 years old.
- Clinically**, there is an insidious onset of joint stiffness; deep, aching joint pain, which worsens with repetitive motion; decreased range of motion; crepitus; and joint effusions and swelling. Osteophytes may cause nerve compression. X-ray studies show narrowing of the joint space due to loss of cartilage; osteosclerosis and bone cysts; and osteophytes (osteophytic lipping).
- The **pathogenesis** involves both biomechanical factors (aging or wear and tear of articular cartilage) and biochemical factors (chondrocyte injury and abnormal collagen activity). Predisposing factors include obesity, previous joint injury, ochronosis, diabetes, trauma, and hemarthrosis.
- Pathology.** Osteoarthritis affects weight-bearing joints (knees, hips, and spine), often with asymmetrical involvement. There is degeneration and loss of articular cartilage with eburnation (exposed bone becomes polished) and subchondral bone sclerosis. The changes may include subchondral bone cysts; loose bodies (joint mice), which are free-floating fragments of cartilage and bone); and osteophytes (bone spurs), which are reactive bony outgrowths. Heberden nodes are osteophytes at the distal interphalangeal (DIP) joints, while Bouchard nodes are osteophytes at the proximal interphalangeal (PIP) joints.

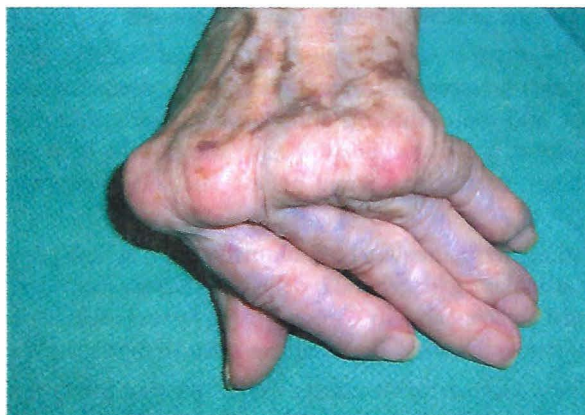

© <http://commons.wikimedia.org>. Used with permission.

Figure 28-1. Heberden's (Distal Interphalangeal Joint) and Bouchard's (Proximal Interphalangeal Joint) Nodes in Patient with Osteoarthritis

RHEUMATOID ARTHRITIS

1. **Rheumatoid arthritis** is a systemic, chronic, inflammatory disease characterized by progressive arthritis, production of rheumatoid factor, and extra-articular manifestations. Females are affected four times more frequently than men, with highest incidence at age 20 to 50 years; some cases have a genetic predisposition (HLA-DR4 and DR1). Rheumatoid arthritis is thought to be caused by an autoimmune reaction triggered by an infectious agent in a genetically susceptible individual.



© Richard P. Usatine, M.D. Used with permission.

Figure 28-2. Ulnar Deviation at the Metacarpophalangeal Joints in Advanced Rheumatoid Arthritis

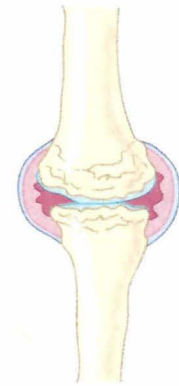Clinical Correlate

The possibility of atlanto-axial subluxation in patients with rheumatoid arthritis should be considered in preoperative evaluations. Anterior-posterior x-rays of the cervical spine with an open mouth should be taken before intubation. These patients may be at risk for severe life-threatening neurological problems.

2. **Clinical features.** Hand, wrist, knee, and ankle joints most commonly involved, and the involvement tends to be symmetrical involvement. There is often morning stiffness that improves with activity. There is typically fusiform swelling, redness, and warmth of the proximal interphalangeal (PIP) joint. X-rays studies show juxta-articular osteoporosis and bone erosions; joint effusion may also be present.
3. **Pathology.** Rheumatoid arthritis causes a diffuse proliferative synovitis; pannus formation (proliferation of the synovium and granulation tissue

over the articular cartilage of the joint); fibrous and bony ankylosis (joint fusion); and joint deformities. The joint deformities can include radial deviation of the wrist and ulnar deviation of the fingers; swan neck deformity (hyperextension of PIP and flexion of distal interphalangeal (DIP)); and boutonniere deformity (flexion of PIP and extension of DIP joints). Baker cysts (synovial cysts in the popliteal fossa) may be present.

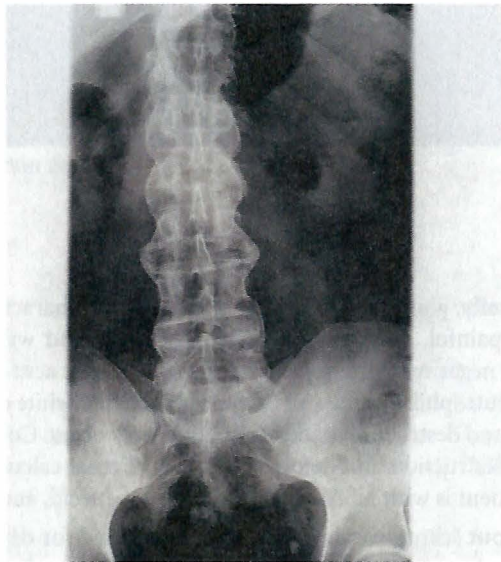4. **Laboratory studies** show elevated sedimentation rate and hypergammaglobulinemia. Rheumatoid factor (RF) is usually an IgM autoantibody against the Fc fragment of IgG that can be positive in 80% of patients with RA. Rheumatoid factor may circulate and form immune complexes, and titer of RF correlates with the severity of the arthritis and prognosis.
5. **Extra-articular manifestations** may be prominent. Systemic symptoms include low-grade fever, malaise, fatigue, lymphadenopathy, and weakness. Arteries may show acute necrotizing vasculitis due to circulating antigen-antibody complexes.
 - a. **Rheumatoid nodules** (25% of patients) are subcutaneous skin nodules that are usually found on extensor surfaces of the forearms or elbows and that are composed of central fibrinoid necrosis surrounded by epithelioid macrophages, lymphocytes, and granulation tissue. Rheumatoid nodules may also be found in the heart valves, lung, pleura, pericardium, and spleen.
 - b. **Syndromes.** Sjögren syndrome (15%) may be present. In Felty syndrome, rheumatoid arthritis accompanies splenomegaly and neutropenia. In Caplan syndrome, rheumatoid arthritis is associated with pneumonococcosis. Secondary amyloidosis may also complicate rheumatoid arthritis.



Rheumatoid Arthritis

SERONEGATIVE SPONDYLOARTHROPATHIES

1. **Ankylosing spondylitis** occurs predominantly in young men with HLA-B27 (90%); usually involves the sacroiliac joints and spine; and may be associated with inflammatory bowel disease.



© Daniel W. Gabier - Naval Medical Center Portsmouth.
Used with permission.

Figure 28-3. Ankylosing spondylitis can cause fusion of vertebrae, leading to a “bamboo spine”

Clinical Correlate

Bamboo spine: Complete fusion of the spine can occur in ankylosing spondylitis and can result in a complete rigidity of the spine, producing a condition known as bamboo spine that shows well on x-rays.

Bridge to Biochemistry

Uric acid is the end-product of purine metabolism.

In a Nutshell

Lesch-Nyhan Syndrome

- X-linked
- Deficiency of hypoxanthine-guanine phosphoribosyl-transferase (HPRT)
- Mental retardation
- Spasticity
- Self-mutilating behaviors
- Hyperuricemia

Clinical Correlate

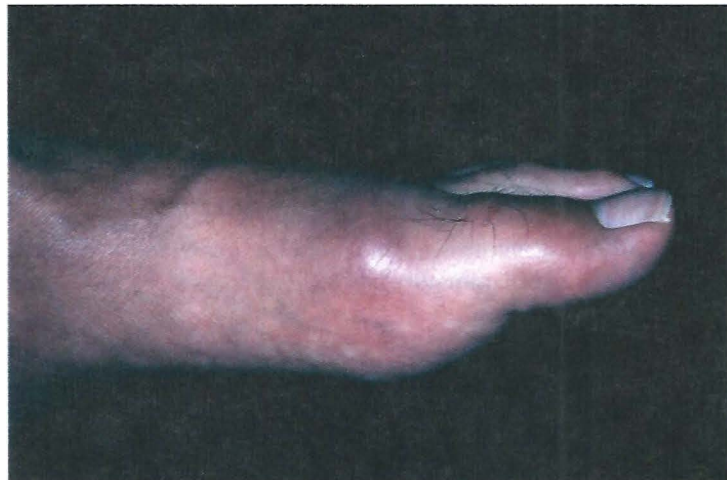Pseudogout: The presence of pseudogout in a patient <50 years old should raise suspicions about one of these metabolic abnormalities (4 H):

- Hemochromatosis
- Hyperparathyroidism
- Hypophosphatemia
- Hypomagnesemia.

2. **Reiter syndrome** affects males more than females; has onset usually in the 20s or 30s; and is characterized by a classic triad of conjunctivitis, urethritis, and arthritis. The arthritis affects the ankles and knees. Onset often follows a venereal disease or bacillary dysentery. Reiter syndrome is associated with HLA-B27 (90%).
3. **Enteropathic arthritis** occurs in 10–20% of patients with ulcerative colitis, who may develop peripheral arthritis or spondylitis. Enteropathic arthritis is associated with HLA-B27 and may respond with treatment of the ulcerative colitis.
4. **Psoriatic arthritis** affects 5–10% of patients with psoriasis; is often a mild and slowly progressive arthritis; has pathology similar to rheumatoid arthritis; and is associated with HLA-B27.

ARTHRITIS RELATED TO CRYSTAL DEPOSITION

1. In **gout**, hyperuricemia and the deposition of monosodium urate crystals in joints result in recurrent bouts of acute arthritis. The hyperuricemia can be due to either overproduction or underexcretion of uric acid. Primary gout (90%) is idiopathic, affects males more than females, and is typically seen in older men. Secondary gout (10%) can be seen with excessive cell breakdown (as in leukemia), renal disease, and Lesch-Nyhan syndrome.



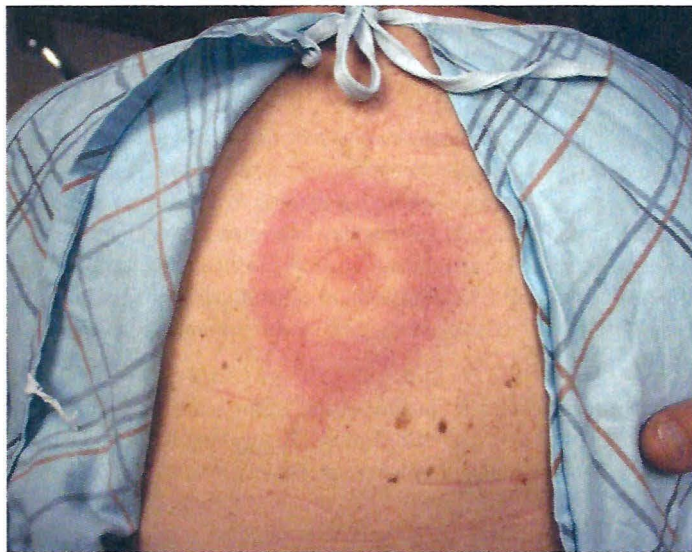© Richard P. Usatine, M.D. Used with permission.

Figure 28-4. Gout

- a. **Clinically**, gout affects the great toe (podagra, characterized by an exquisitely painful, inflamed big toe), ankle, heel, and wrist. Joint aspiration shows negatively birefringent, needle-shaped uric acid crystals and numerous neutrophils. Tophi grossly appear as chalky-white deposits. Skin ulceration and destruction of adjacent joints may occur. Complications include joint destruction and deformity; uric acid renal calculi; and renal failure. Treatment is with NSAIDs, colchicine, probenecid, and allopurinol.
2. **Pseudogout** (chondrocalcinosis) is the term used for deposition of calcium pyrophosphate crystals in joints, leading to inflammation. Affected patients are usually older than 50 years. The knee joint is most commonly involved. Aspiration of the joint demonstrates positively birefringent (weak), rhomboid-shaped crystals. Pseudogout is associated with many metabolic diseases (e.g., diabetes, hypothyroidism, ochronosis), and it may mimic osteoarthritis or rheumatoid arthritis.

INFECTIOUS ARTHRITIS

1. **Suppurative arthritis.** Hematogenous spread is the most common route of spread and is due to seeding of the joint during bacteremia. Other routes include spread from an adjacent site of infection and direct inoculation. Infecting organisms include *gonococci*, *Staphylococcus*, *Streptococcus*, *Haemophilus influenzae*, and gram-negative bacilli.
 - a. **Clinical features.** Infectious arthritis causes a tender, painful, swollen, and erythematous joint. Large joints (knee, hip, shoulder) are most often infected, and the arthritis is usually monoarticular. Joint aspiration shows cloudy synovial fluid that clots readily and has a high neutrophil count. Gram stain and culture are positive in 50–70% of cases. Treatment requires rapid intervention with antibiotics to prevent permanent joint damage.
2. **Lyme disease** is due to the spirochete *Borrelia burgdorferi*. The disease is arthropod-borne, being spread by deer ticks (*Ixodes dammini*). Lyme disease causes skin rash (erythema chronicum migrans), and migratory arthritis involving the knees, shoulders, and elbows. The histology of the arthritic joint is similar to rheumatoid arthritis. Lyme disease can also have central nervous system and cardiac involvement.



© Richard P. Usatine, M.D. Used with permission.

Figure 28-5. Large Targetoid Lesion of Erythema Migrans Considered Pathognomic of Lyme Disease

Bridge to Microbiology

Arthropod-borne diseases transmitted by ticks include:

- Rocky Mountain spotted fever
- *Ehrlichia*
- Babesiosis
- Tularemia
- Lyme disease

NEUROPATHIC ARTHROPATHY (CHARCOT JOINT)

1. **Charcot joint** refers to joint damage secondary to impaired joint innervation (neuropathy) leading to an inability to sense pain. The damage also leads to destruction of joint surfaces, debris in joints, deformity, and dislocations.
2. Different **underlying neurologic diseases** tend to affect different joints. Diabetes mellitus (most common cause) tends to damage the tarsometatarsal joint in the mid foot. Syringomyelia (cavity in spinal cord) tends to damage the shoulder, elbow, and wrist joints. Tabes dorsalis (neurosyphilis) tends to damage the hip, knee, and ankle joints.

Chapter Summary

- Degenerative joint disease is an important cause of chronic joint pain in the elderly populations; most seriously affects the weight-bearing joints and is related to destruction of the articular cartilage as a result of “wear and tear.” Reactive bony spurs (osteophytes, called Heberden nodes if they involve the DIP joints and Bouchard nodes if they involve the PIP joints) and free-floating fragments of cartilage or bone (joint mice) may contribute to the joint pathology.
- Rheumatoid arthritis is a systemic, chronic, inflammatory, autoimmune disease primarily of the hands, wrists, knees, and ankle joints of middle-aged women. It is characterized by progressive arthritis, production of rheumatoid factor, genetic predisposition (HLA-DR4 and DR1), morning stiffness that improves with activity, pannus formation within the joint, and rheumatoid nodules, and it often coexists with other diseases (Sjögren syndrome, Felty syndrome, Caplan syndrome, secondary amyloidosis).
- The seronegative spondyloarthropathies (all associated with HLA-B27) include ankylosing spondylitis (young men, sacroiliac joints and spine, association with inflammatory bowel disease), Reiter syndrome (young men, history of venereal disease or bacillary dysentery, ankles and knees, conjunctivitis, urethritis), enteropathic arthritis (patients with ulcerative colitis who develop peripheral arthritis or spondylitis that may respond as the ulcerative colitis improves), and psoriatic arthritis (some patients with psoriasis develop a rheumatoid arthritis-like condition).
- Gout is an arthritis that classically involves the great toe (also may affect ankle, heel, wrist) as a result of hyperuricemia (primary or secondary due to leukemia, renal disease, or Lesch-Nyhan syndrome) leading to deposition of monosodium urate crystals in joints (can be seen in joint aspirates as negatively birefringent, needle-shaped crystals) and subcutaneous tissues (causing tophi). Pseudogout (chondrocalcinosis) is due to deposition of calcium pyrophosphate crystals (positively birefringent, rhomboid shaped) and commonly involves the knee of older adults.
- Suppurative arthritis typically causes tender, erythematous swelling of a single large joint (primarily knee, hip, and shoulder) as a result of bacterial infection (gonococci, *Staphylococcus*, *Streptococcus*, *Haemophilus influenzae*, and gram-negative bacilli) that has usually reached the joint through a hematogenous route. Lyme disease causes a migratory arthritis (clinically and histologically similar to rheumatoid arthritis) due to the spirochete *Borrelia burgdorferi*, which is spread by the deer tick *Ixodes dammini*. The arthritis is often preceded by a migratory rash (erythema chronica migrans) and may be accompanied or followed by CNS and cardiac involvement.
- Neuropathic arthropathy is joint damage secondary to impaired joint innervation (neuropathy) leading to inability to sense pain. Examples of neurologic disease that cause this are diabetes mellitus, syringomyelia, and tabes dorsalis.

Skeletal Muscle and Peripheral Nerve Pathology

29

SKELETAL MUSCLE

Table 29-1. Type I (Slow-Twitch) Versus Type II (Fast-Twitch) Muscles

	Type I	Type II
Twitch rate	Slow twitch	Fast twitch
Function	Postural weight bearing Sustained tension	Purposeful movement Short, quick bursts
Metabolism	Aerobic (Krebs cycle)	Anaerobic (glycolysis)
Energy source	Fatty acids	Glycogen
Mitochondria	Many	Few
Color	Red	White
Fatigue	Slow fatigue	Rapid fatigue

Note

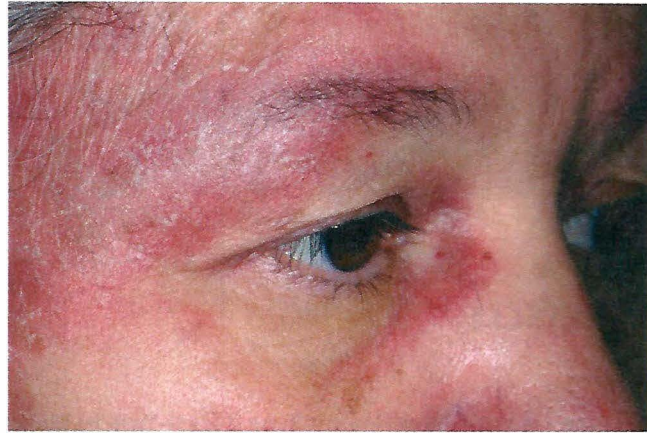Skeletal muscle fiber type is determined by innervation.

INFLAMMATORY MYOPATHIES

1. **Polymyositis** is a chronic inflammation of muscle fibers due to unknown cause. It is a disease of adults that presents with bilateral proximal muscle weakness. Microscopic examination demonstrates endomysial lymphocytic inflammation (mostly cytotoxic T8) and skeletal muscle fiber degeneration and regeneration.
2. **Dermatomyositis** is a connective-tissue disorder involving inflammation of skeletal muscle and skin that can affect children or adults. It presents with bilateral proximal muscle weakness, skin rash of the upper eyelids, and periorbital edema. Microscopic examination demonstrates perimysial and vascular lymphocytic inflammation, perifascicular fiber atrophy, and skeletal muscle fiber degeneration and regeneration. Patients with dermatomyositis have increased risk of lung, stomach, and ovarian cancers.

Clinical Correlate

Anti-tRNA synthetase antibodies such as the anti-Jo-1 antibody are known to be highly specific for inflammatory myopathies.



© Richard P. Usatine, M.D. Used with permission.

Figure 29-1. Periorbital heliotrope rash of dermatomyositis.

3. **Inclusion body myositis** affects adults older than age 50 years, causing asymmetrical distal muscle weakness. Light microscopy demonstrates cytoplasmic vacuoles with basophilic granules and amyloid, while electron microscopy demonstrates filamentous inclusions.

MYASTHENIC SYNDROMES

1. **Myasthenia gravis** is an autoimmune disease characterized by autoantibodies against the acetylcholine (ACh) receptor of the neuromuscular junction, resulting in muscular weakness predominantly affecting the facial muscles. Females are affected more frequently than males. Extraocular muscle weakness may lead to ptosis and diplopia. The weakness worsens with repeated contractions. Respiratory muscle involvement may lead to death. Myasthenia gravis is associated with thymic hyperplasia and thymomas. Treatment is with anticholinesterase agents, steroids, and thymectomy.

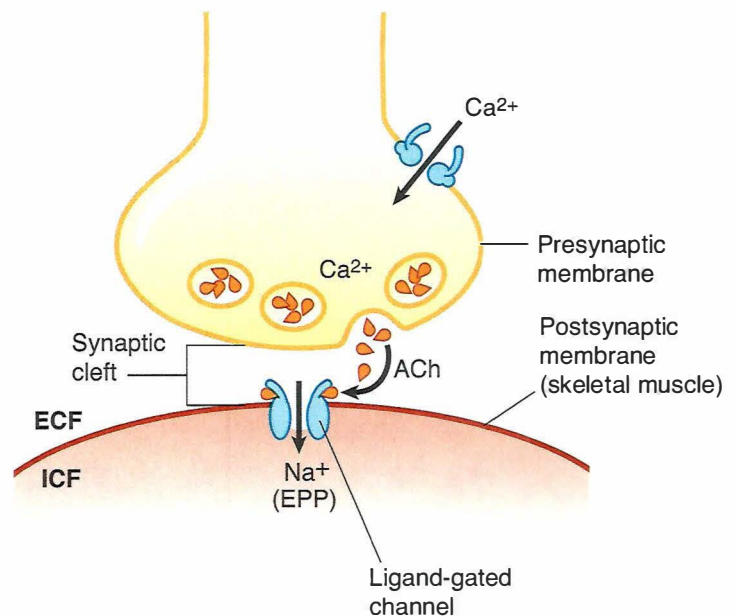


Figure 29-2. Neuromuscular Transmission

2. **Eaton-Lambert syndrome** is a commonly paraneoplastic syndrome of small cell lung cancer which presents with proximal muscular weakness; it improves with repeated contraction. Eaton-Lambert is due to production of autoantibodies directed against the calcium channels of the neuromuscular junction.

MUSCULAR DYSTROPHY

1. **Duchenne muscular dystrophy** is a severe recessive X-linked form of muscular dystrophy leading to rapid progression of muscle degeneration. Duchenne is the most common and severe form of muscular dystrophy. The affected gene is the dystrophin gene on the X chromosome (Xp21); dystrophin protein is an important muscle structural protein and mutation results in a virtual absence of the dystrophin protein.
 - a. **Clinical presentation.** Affected boys are normal at birth but have onset of symptoms by age 5 years. The clinical features include progressive muscular weakness; calf pseudohypertrophy; and proximal weakness of shoulder and pelvic girdles. Heart failure and arrhythmias may occur. Respiratory insufficiency and pulmonary infections can also occur, due to decreased mucociliary clearance.
 - b. **Diagnosis.** Laboratory studies show elevated serum creatine kinase. Muscle biopsy shows muscle fibers of various sizes; necrosis, degeneration, and regeneration of fibers; fibrosis; and fatty infiltration. Immunostains show decreased dystrophin protein. The diagnosis can also be confirmed with DNA analysis by PCR.
2. **Becker muscular dystrophy** is a recessive X-linked inherited disorder leading to slowly progressive muscle weakness of the legs and pelvis. It is less common and not as severe as Duchenne muscular dystrophy. Mutation produces an altered dystrophin protein. When compared to Duchenne muscular dystrophy, Becker muscular dystrophy has a later onset with variable progression. Cardiac involvement is rare and patients may have a relatively normal life span.

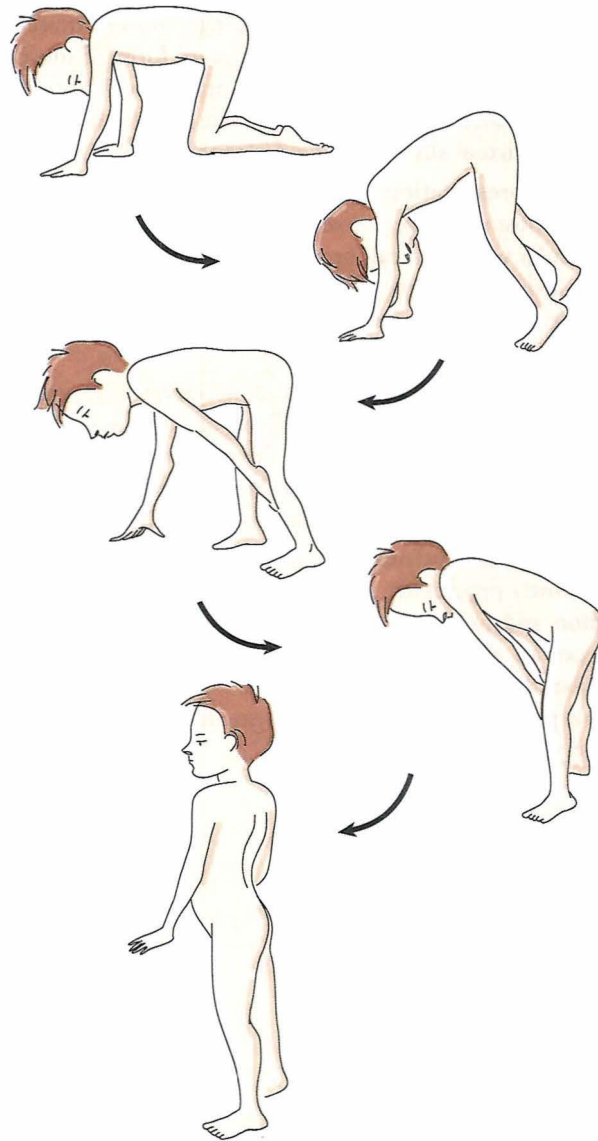


Figure 29-3. Gower Sign in Duchenne Muscular Dystrophy

INFLAMMATORY NEUROPATHY

1. **Guillain-Barré syndrome** is an autoimmune disease leading to the destruction of Schwann cells and peripheral nerve demyelination.
 - a. **Clinically**, Guillain-Barré syndrome is preceded by a viral illness. Muscular weakness occurs with an ascending paralysis, accompanied by loss of deep tendon reflexes. The diagnosis can be established with nerve conduction studies; lumbar puncture shows elevated protein. Guillain-Barré syndrome is fatal in 5% because of respiratory paralysis.
 - b. **Microscopic examination** demonstrates inflammation and demyelination of peripheral nerves and spinal nerve roots, resulting in muscular weakness.

SOFT TISSUE TUMORS AND TUMOR-LIKE CONDITIONS

1. **Lipoma** is a benign adipose tissue tumor that is the most common benign soft tissue tumor. It usually arises in subcutaneous tissue of trunk, neck, or proximal extremities, and is usually more a cosmetic problem than a medical one.
2. **Liposarcoma** is a malignant adipose tissue tumor and the most common adult sarcoma. It most often arises in the thigh or retroperitoneum, and it is distinguished from lipoma by the presence of lipoblasts.
3. **Dermatofibroma** is a benign dermal spindle cell proliferation most often seen on the extremities. Dermatofibroma forms a small red nodule that indents when squeezed.
4. **Fibromatosis** is a non-neoplastic proliferative connective tissue disorder that can histologically resemble a sarcoma. Fibrous tissue infiltrates muscle or other tissue and may cause a mass lesion.
5. **Fibrosarcoma** is a malignant fibrous tumor. Common sites are the thigh and upper limb. Fibrosarcomas may arise spontaneously or after therapeutic/accidental irradiation.
6. **Malignant fibrous histiocytoma** is a malignant tumor that often has strikingly pleomorphic cells. Common sites are the retroperitoneum and thigh. Malignant fibrous histiocytoma may develop following radiation therapy and scarring.
7. **Rhabdomyoma** is a benign striated muscle tumor that can occur in the heart, tongue, and vagina. Cardiac rhabdomyomas may be associated with tuberous sclerosis.
8. **Embryonal rhabdomyosarcoma** is the most common sarcoma of children, and is derived from striated muscle. It typically presents as a grape-like, necrotic mass protruding from the penis or vagina.
9. **Leiomyoma** is a benign smooth muscle tumor that occurs most often in the uterus and stomach.
10. **Leiomyosarcoma** is a malignant smooth muscle tumor that is the most common sarcoma of the gastrointestinal tract and uterus.

Chapter Summary

- Type I (red) skeletal muscle is used in postural weight bearing and produces a slow twitch as a result of aerobic metabolism of fatty acids; type II (white) skeletal muscle is used for purposeful movement and produces a fast twitch as a result of anaerobic glycolysis of glycogen.
- Inflammatory myopathies include polymyositis (adults, bilateral proximal muscle weakness, cytotoxic T8 lymphocytes, and skeletal muscle degeneration and regeneration), dermatomyositis (children or adults with bilateral proximal muscle weakness; periorbital edema with skin rash of eyelids; muscle biopsy with lymphocytes and perifascicular fiber atrophy; and increased risk of lung, stomach, and ovarian cancers), and inclusion body myositis (older adults with asymmetrical distal muscle weakness and odd microscopy with cytoplasmic vacuoles, basophilic granules, amyloid, and, by EM, filamentous inclusions).
- Myasthenic syndromes include myasthenia gravis (autoantibody attack on muscle acetylcholine receptor sometimes related to thymic disease, produces muscle weakness that worsens with use, may cause ptosis and diplopia, and may cause death secondary to respiratory muscle failure) and Eaton-Lambert syndrome (paraneoplastic syndrome of small cell carcinoma of lung with autoantibodies against calcium channels, producing proximal muscle weakness that improves with muscle use).
- Muscular dystrophies include Duchenne muscular dystrophy (X-linked abnormality of the muscle structural protein dystrophin causes progressive muscular weakness related to muscle necrosis and degeneration beginning by age 5, involving initially shoulder and pelvic girdles; death may be due to heart failure, arrhythmias, respiratory insufficiency, or pulmonary infections) and Becker muscular dystrophy (less common, milder variant of Duchenne with relatively normal life span).
- Guillain-Barré syndrome is an inflammatory neuropathy that typically follows a viral illness and may lead to paralysis and sometimes death (respiratory paralysis) as a result of inflammation and demyelination of peripheral nerves and spinal nerve roots.
- Benign soft tissue tumors and tumor-like conditions include lipomas, dermatofibromas, fibromatosis, rhabdomyomas, and leiomyomas. Malignant soft tissue tumors include liposarcoma, fibrosarcoma, malignant fibrous histiocytoma, embryonal rhabdomyosarcoma, and leiomyosarcoma.

Index

A

- A β amyloid, Alzheimer disease, 208
- Abscesses
 - amebic liver, 190
 - cerebral, 199
 - pulmonary, 132
- Acanthocytes, 97
- Acanthosis nigricans, 91
 - pulmonary involvement, 142
- Achalasia, 163
- Achondroplasia, 261
- Acquired immunodeficiency syndrome (AIDS)
 - Kaposi sarcoma, 116
 - secondary immune deficiency syndromes, 63–66
- Acquired megacolon, 168
- Acquired polycystic kidney disease, 148
- Acromegaly, 256
- Actinic keratosis, 94
- Active hyperemia, 29
- Acute alcohol intoxication, 85
- Acute cholecystitis, 182
- Acute endocarditis, 123
- Acute hemorrhagic gastritis, 165
- Acute inflammation, 15–20
- Acute intermittent porphyria, 210
- Acute lymphoblastic leukemia (ALL), 221
- Acute meningitis, 197
- Acute myelogenous leukemia (AML), 226
- Acute nonspecific lymphadenitis, 220
- Acute pancreatitis, 177
- Acute respiratory distress syndrome (ARDS), 138
 - pancreatitis, 177
- Acute rheumatic heart disease, 123
- Acute tubular necrosis, 154–155
- Acute viral hepatitis, 189–190
- Adaptive immunity, acute inflammation, 15
- Addison's disease, 258
- Adenocarcinoma
 - colonic, 173
 - esophagus, 164
 - lung cancer, 141
 - prostate, 251
 - vaginal clear cell, 234
- Adenoma
 - growth hormone-producing, 256
 - hepatic, 194
 - pituitary, 256–257
 - thyroid, 254
- Adenomatous colonic polyps, 172
- Adenomyosis, 235–236
- Adenosine triphosphate (ATP), cellular injury, 7–8
- Adenosis, vaginal, 234
- Adhesion, acute inflammation, 17
- Adrenal gland, pathology, 258
- Adrenogenital syndromes, 258
- Adult polycystic kidney disease, 147–148
- Adult T-cell leukemia/lymphoma, 224
- Alanine aminotransferase (ALT), apoptosis, 11
- Albers-Schönberg bone disease, 262
- Albinism, 49
- Alcohol use and abuse, 85
 - dementia, 210
 - liver disease, 191
- Alkaline phosphatase, biliary tract obstruction, 0
- Alkaptonuria, 49
- α -1-antitrypsin deficiency, 192
- α -Thalassemia, 100–101
- Alport syndrome, 53, 152
- Alzheimer disease, 70
 - epidemiology and genetics, 207–208
- Amebic liver abscesses, 190
- Amphetamines, 86
- Amphibole asbestos, 139
- Amylase
 - pancreatitis, 8, 11
 - salivary gland injury, 11
- Amyloid-associated (AA) amyloid, 69
- Amyloidosis
 - amyloid composition, 69
 - characteristics, 69
 - clinical features, 70
 - defined, 69
 - localized, 70
 - rheumatoid arthritis, 273
 - systemic, 69
- Amyloid precursor protein (APP) gene, Alzheimer disease, 208
- Amyotrophic lateral sclerosis (ALS), 209
- Analgesic nephropathy, 154
- Anaphylactic (type I) hypersensitivity reaction, 59
- Anaplastic astrocytomas, 211
- Anaplastic carcinoma, thyroid, 255
- Anasarca, 29
- Ancillary techniques, 2
- Anemias, 97–105. *See also* Thalassemia syndromes
 - of chronic disease, 100
 - classification, 98
 - lead poisoning, 83
 - macrocytic, 104–105
 - microcytic, 83, 99–101
 - normocytic, 101–104
 - pathogenesis, 99
- Anemic infarcts, 38
- Anencephaly, 204
- Aneurysms, 113–114
- Angelman syndrome, 54
- Angina pectoris, 119
- Angiodysplasia, 171

- Angiomyolipomas, kidney, 155
 Angiosarcoma, 116
 Aniridia, microdeletions, 45
 Anisocytosis, 97
 Ankylosing spondylitis, 273–274
 Anorexia nervosa, 5
 Antibody-mediated (type II) hypersensitivity reaction, 59
 Antigen-antibody complex, hypersensitivity reactions, 53
 Antihistone antibodies, 60
 Antimitochondrial autoantibodies, primary biliary cirrhosis, 188
 Anti-Ro antibodies, congenital complete heart block, 61
 Anti-tRNA synthetase antibodies, 277
 Antral type (type B) chronic gastritis, 166
 Aorta, coarctation, 124
 Aortic dissecting aneurysm, 114
 Aplastic anemia, 104
 Apolipoprotein E gene, Alzheimer disease, 208
 Apoptosis, 10–11
 carcinogenesis and, 78
 Appendicitis, 170–171
 Arachidonic acid, acute inflammation, 18
 Arnold-Chiari malformation, 205
 Arsenic poisoning, 83
 Arteriosclerosis, 111–112
 Arteriovenous fistula, 114
 Arthritis
 crystal deposition, 274
 enteropathic arthritis, 274
 infectious arthritis, 275
 osteoarthritis, 271–272
 psoriatic, 274
 Arthropod-borne disease, 275
 Asbestosis, 139–140
 Ascending cholangitis, 182
 Aspartate aminotransferase (AST), apoptosis, 11
 Aspiration, lung abscess, 132
 Aspirin, platelet disorders, 30–31
 Asthma, 136–137
 Astrocytomas, 211
 Atelectasis, 131
 Atheromatous plaque, 111–112
 renal artery stenosis, 157
 Atherosclerosis
 cellular injury, 5
 risk factors, 111–112
 Atherosclerotic aneurysms, 114
 Atlanto-axial subluxation, rheumatoid arthritis, 272–273
 Atrial septal defect (ASD), 126–127
 Atrophy, cellular injury, 11
 Atypical pneumonia, 132
 Auerbach plexus, 168
 Auer rods, acute myelogenous leukemia, 226
 Autoantibodies, autoimmune disease, 60
 Autoimmune disease, 60–62
 hemolytic anemia, 103–104
 skin, 91–92
 Autosomal genetic disorders
 dominant, 47, 51–53
 osteopetrosis, 262
 polycystic kidney disease, 147–148
 extra autosome, 43–44
 recessive, 47–50
 osteopetrosis, 262
 polycystic kidney disease, 147–148
 Avascular necrosis, 265
 Azotemia, glomerular disease, 149
B
 Babesiosis, 275
 Bacteremia, endocarditis, 123
 Bacterial pneumonia, 131
 Balanitis/balanoposthitis, 247
 Bamboo spine, 273–274
 Baroreceptor reflex, shock and activation of, 39
 Barr bodies, sex chromosome disorders, 45–46
 Barrett esophagus, 12, 163
 Bartholin gland abscess, 233
 Basal cell carcinoma, 94–95
 Basement membranes, tissue connectivity, 27
 Basophilic stippling, red blood cells, 97
 Basophils, chronic inflammation, 20–22
 B cells
 acute inflammation, 15
 peripheral neoplasms, 221–224
 precursor neoplasms, 221
 B-chronic lymphocytic leukemia, 222
 Becker muscular dystrophy, 279
 Benign hyperphenylalaninemia, 49
 Benign hypertension, 113
 Benign neoplasms, 79
 bone, 266–267
 breast, 242
 kidney, 155
 Benign nephrosclerosis, 158
 Benign prostatic hypertrophy (BPH), 250–251
 Benzodiazepines, 85–86
 Berger disease, 151
 Bernard-Soulier syndrome, 30–31
 Berry aneurysm, 114, 202–203
 Berylliosis, 140
 β -Thalassemia, 100–101
 Bilateral acoustic neurofibromatosis, 52–53
 Bilateral renal agenesis, 147
 Bile duct cancer, 182
 Bile resistance, *Viridans streptococci*, 123
 Biliary tract
 cancer, 184
 obstruction, 188
 alkaline phosphatase, 8
 Bilirubin, cellular injury, 13
 Bilirubinemia, unconjugated vs. conjugated, 187
 2,3-Bisphosphoglycerate (2,3 BPG), 104
 Bite cells (red blood cells), 97
 Bladder
 congenital anomalies, 159
 neoplasms, 158–159
 Bleeding disorders, 29–35. *See also* Anemias; Thalassemia syndromes
 acquired coagulopathies, 34
 coagulation cascade, 33–34
 disseminated intravascular coagulation, 34–35
 hemolytic uremic syndrome, 32
 hemophilia A, 34
 hemophilia B, 34
 hemostasis, 30
 immune thrombocytopenia purpura, 32
 platelet adhesion/activation, 30–31

- thrombotic thrombocytopenia purpura, 32
 - vascular wall injury, 30
 - Von Willebrand disease, 34
 - Blisters (skin), 93
 - Blood clot, thrombosis *vs.*, 36
 - Blood loss, anemias of, 101
 - Bone
 - benign tumors, 266–267
 - composition, 261
 - hereditary disorders, 261–262
 - malignant tumors, 268–269
 - miscellaneous disorders, 265–266
 - osteomalacia and rickets, 264
 - osteomyelitis, 264–265
 - osteopetrosis, 262
 - osteoporosis, 263–264
 - Paget disease, 263
 - remodeling, 261
 - Bouchard nodes, osteoarthritis, 271–272
 - Bradykinin, acute inflammation, 19
 - Brain
 - perinatal injury, 205
 - trauma, 203–204
 - BRCA1/BRCA2 gene, breast carcinoma, 243
 - Breast
 - anatomic lesions, 241
 - benign neoplasms, 242
 - fibrocystic changes, 241–242
 - gynecomastia, 244
 - malignant neoplasms, 243–244
 - mastitis, 241
 - Paget disease of nipple, 244–245
 - Bronchial carcinoids, 143
 - Bronchiectasis, 137
 - Bronchitis, chronic, 135
 - Bronchoalveolar carcinoma, 141
 - Bronchogenic carcinoma, 141
 - Bronchopneumonia, 132
 - Bruton X-linked agammaglobulinemia, 53, 62
 - Budd-Chiari syndrome, 193
 - Buerger disease, 110
 - Bullous pemphigoid, 92
 - Burkitt lymphoma, 222–223
 - Burn injuries, 86
 - Butterfly rash, systemic lupus erythematosus effects, 60–61
- C**
- Calcification, cellular injury, 13
 - Calcinosis, 61–62
 - Calcium, cellular injury, 7
 - Cancer. *See* Neoplasms; specific cancers
 - Caplan syndrome, 139
 - rheumatoid arthritis, 273
 - Carbonic anhydrase II deficiency, 262
 - Carbon monoxide poisoning, 83
 - Carcinogenesis, 76–77
 - Carcinogenic agents, 75–76
 - Carcinoid heart disease, 128
 - Carcinoid syndrome, 174
 - Carcinoma
 - breast, 243
 - cervical, 235
 - endometrial, 236
 - Cardiac myxoma, 128
 - Cardiac rhabdomyoma, 128
 - Cardiac transplantation, secondary immune deficiency syndromes, 63
 - Cardiogenic shock, 38
 - Cardiomyopathies, 127–128
 - Chagas disease, 163
 - Caseous necrosis
 - cell death, 9
 - chronic inflammation, 21–22
 - Caspases, apoptosis, 10
 - Castleman disease, 65
 - Catalase, cellular injury, 7
 - CD4 count, human immunodeficiency virus, 64–65
 - Celiac sprue, 168
 - IgA nephropathy, 151
 - Cell death, 9–11
 - Cell-mediated (type IV) hypersensitivity reaction, 59
 - Cell membrane, permeability, 7
 - Cellular injury
 - adaptive responses, 11–12
 - alterations during, 12–13
 - causes of, 5–6
 - changes and responses, 6–9
 - reversible injury, 8
 - Central nervous system
 - trauma, 203–204
 - tumors, 210–213
 - Central pontine myelinolysis, 206
 - Cerebellar tonsillar herniation, 204
 - Cerebral abscess, 199
 - Cerebral amyloid angiopathy, 208
 - Cerebral herniations, 204
 - Cerebrovascular disease, 200–202
 - Cervical intraepithelial neoplasia (CIN), 235
 - Cervical polyps, 235
 - Cervicitis, acute and chronic, 235
 - Cervix, pathology, 234–235
 - Chagas disease
 - achalasia, 163
 - acquired megacolon, 168
 - Charcot joint, 275
 - Chediak-Higashi syndrome, 18
 - Chemical carcinogens, 75–76
 - Chemical injury, cellular response, 5
 - Chemical mediators, acute inflammation, 15, 18–19
 - Chemotaxis, acute inflammation, 17
 - Children, cancer morbidity and mortality, 73–74
 - Cholangitis
 - ascending, 182
 - primary sclerosing, 188
 - Cholecystitis, acute and chronic, 182
 - Cholecystokinin, somatostatinoma, 180
 - Cholelithiasis, 182
 - Cholesterolosis, 182
 - Cholesterol stones, 182
 - Chondrocalcinosis, 274
 - Chondrosarcoma, 268
 - Choriocarcinoma
 - female, 239
 - male, 249
 - Christmas disease, 34
 - Chromosomal deletions, genetic disorders, 45
 - Chromosome 11, mantle cell lymphoma, 223

- Chromosome 14
 - Burkitt lymphoma, 222–223
 - follicular lymphoma, 222
 - mantle cell lymphoma, 223
- Chromosome 18, follicular lymphoma, 222
- Chronic alcoholism, 85
- Chronic bronchitis, 135
- Chronic cholecystitis, 182
- Chronic cutaneous lupus erythematosus, 94
- Chronic gastritis, 166
- Chronic glomerulonephritis, 153–154
- Chronic granulomatous disease, 18
 - chronic inflammation, 21–22
 - X-linked recessive genetics, 53
- Chronic infectious monocyctosis, 219–220
- Chronic inflammation, 20–22
- Chronic ischemic heart disease, 121
- Chronic lymphocytic leukemia (CLL), 221–222
- Chronic myelogenous leukemia (CML), 219, 226–227
- Chronic nonspecific lymphadenitis, 220
- Chronic obstructive pulmonary disease, 84
- Chronic pancreatitis, 177
- Chronic passive congestion of liver, 193
- Chronic renal failure, 157
- Chronic rheumatic heart disease, 123
- Chronic viral hepatitis, 189–190
- Churg-Strauss syndrome, 109
- Chvostek sign, hypoparathyroidism, 255
- Cilium, axoneme cross-section, 138
- Cirrhosis
 - alcoholic, 191
 - liver, 188
 - primary biliary, 188
- Clear cell adenocarcinoma, 234
- Clinical significance, 1
- Clotting mechanism, 29
 - blood clot vs. thrombosis, 36
 - coagulopathies, 34
- Coagulation cascade, 33
- Coagulative necrosis
 - cell death, 9
 - infarction, 38
- Coagulopathies, acquired, 34
- Coal worker's pneumoconiosis, 139
- Coarctation of the aorta, 124
- Cobalamin deficiency, megaloblastic anemia, 104–105
- Cocaine, 85
- Collagen
 - genetic disorders, 51–53
 - tissue connectivity, 27
- Collectins, inflammation, 18
- Colloid osmotic pressure, edema, 29
- Colon
 - angiodysplasia, 170
 - diverticula, 170–171
 - hemorrhoids, 170
 - inflammatory bowel disease, 169
 - ischemic bowel disease, 170
 - malabsorption syndromes, 168–169
 - mechanical obstruction, 167–168
 - melanosis coli, 170
 - neoplasia, 171–174
 - pseudomembranous colitis, 170
 - right-sided vs. left-sided cancer, 173
 - Colonic diverticulosis, 171–172
- Colonoscopy, endocarditis, 123
- Common variable immunodeficiency, 62
- Compensation, shock, 38
- Complement system
 - disorders, 62–63
 - inflammation mediation, 18–20
- Compression atelectasis, 131
- Compression fracture, osteoporosis, 264
- Concussion, 203
- Condyloma acuminatum, 233
 - penis, 247
- Congenital disorders
 - bladder anomalies, 159
 - cellular injury, 5
 - esophagus, 163
 - heart disease, 124–127
 - hypothyroidism, 254
 - kidney, 147
 - nevi, 90
 - stomach, 164
 - ureteral anomalies, 158
- Congestion (passive hyperemia), 29
- Congestion pneumonia, 131
- Congestive heart failure (CHF), 122
- Conn syndrome, 258
- Contraction atelectasis, 131
- Contusions, 203
- Cooley anemia, 101
- Coombs' test, hemolytic anemia, 103
- Coronary artery thrombosis, 120
- Cor pulmonale, 122
- Cortical adenoma, kidney, 155
- Courvoisier law, biliary tract cancer, 184
- Craniopharyngioma, 213, 257
- Creatine kinase, apoptosis, 11
- Creatine phosphokinase, myocardial injury, 8
- Crescendo angina, 119
- CREST syndrome, 61
 - angiodysplasia, 171
- Cretinism, 254
- Creutzfeldt-Jakob disease, 199
- Cri du chat syndrome, 45
- Crigler-Najjar syndrome, 187
- Crohn's disease, 168–170
- Cryptorchidism, 248
- Crystal deposition, arthritis, 274
- Cushing syndrome, 257–258
- Cutaneous lupus erythematosus, 94
- Cyanide poisoning, 84
- Cyclooxygenase pathway, 18
- Cystadenocarcinoma, 237
- Cystadenoma, 236
- Cystic fibrosis
 - apoptosis, 11
 - autosomal recessive disorder, 48
- Cystic fibrosis transmembrane conductance regulator (CFTR), 48
- Cystitis, 158
- Cystitis cystica, bladder, 159
- Cystocele, bladder, 159
- Cysts, kidney, 148
- Cytochrome P450, alcoholism and, 85

Cytokines

- adhesion molecules, 17
 - apoptosis, 10
 - inflammation mediation, 20
- Cytomegalovirus, liver disease, 189
- Cytopathic/cytoproliferative inflammation, 22

D

- Dandy-Walker malformation, 205
- Decompensation, shock, 38
- Deep venous thrombosis (DVT), 36–37, 114
- Degenerative calcific aortic valve stenosis, 122
- Degranulation, acute inflammation, 18
- Dementias, 207–210
- Demyelinating disorders, 205–206
- Dermal lesions, 91–94
- Dermatitis herpetiformis, 92
- Dermatofibroma, 281
- Dermatomyositis, 61–62, 277–278
- Dermoid cyst, 237
- Developmental abnormalities, central nervous system, 204–205
- Dexamethasone suppression test, 258
- Diabetes insipidus, 257
- Diabetes mellitus, 177–179
 - nodular glomerulosclerosis, 153
- Diabetic nephropathy, 178–179
- Diabetic neuropathy, 179
- Diabetic retinopathy, 179
- Diapedesis, acute inflammation, 17
- Diet, iron deficiency anemia, 99–100
- Diffuse axonal injury, 203–204
- Diffuse cortical necrosis, 158
- Diffuse large B-cell lymphoma, 222
- Diffuse scleroderma, 61
- DiGeorge syndrome, 62
- Dilated cardiomyopathy, 127
- Disseminated intravascular coagulation (DIC), 31, 34–35
 - microangiopathic hemolytic anemia, 101–102
- Diverticuli
 - bladder, 159
 - small and large intestine, 171–172
- Diverticulosis, colonic, 171–172
- DNA
 - cellular injury, 7
 - megaloblastic anemias, synthesis impairment, 104–105
- Down syndrome, 43, 53
- Dressler syndrome, 121
- Drowning, 86
- Drug abuse, 85–86
- Dubin-Johnson syndrome, 187
- Duchenne muscular dystrophy, 279–280
- Ductal carcinoma *in situ*, 243
- Dukes staging system, colon cancer, 173
- Duodenal peptic ulcer, 166–167
- Dysplasia
 - cellular injury, 11–12
 - renal, 148
 - renal cell carcinoma, 157
- Dysplastic nevi, 90

E

- Eaton-Lambert syndrome, 279
 - pulmonary involvement, 142
- Echinocytes (red blood cells), 97
- Ectopic pregnancies, 234, 239
- Eczema, 93
- Edema, 29, 40
 - glomerular disease, 140
 - pulmonary, 140–141
- Edwards syndrome, 44
- Effusion, edema, 29
- Ehlers-Danlos (ED) syndrome, 27
 - genetic variants, 51
- Ehrlichia*, 275
- Eisenmenger complex/syndrome, 126
- Ejaculation disorders, 248
- Electrical injury, 86
- Electron transport chain, cellular injury, 5
- Elliptocytes (red blood cells), 97
- Embolism, 36–37
 - cerebral infarction, 200–201
- Embryogenesis, apoptosis, 10
- Embryology
 - adrenal pathology, 258
 - congenital heart disease, 126
- Embryonal carcinoma, 249
- Embryonal rhabdomyosarcoma, 234, 281
- Emphysema, 135
- Encephalitides, viral, 198
- Encephalopathy, multicystic, 205
- Enchondroma, 267
- Endocarditis, 123
- Endochondral bone, 261
- Endocrine/metabolic syndromes, pulmonary involvement, 142
- Endocrine type amyloidosis, 70
- Endodermal sinus tumor, 249
- Endogenous pigments, cellular injury, 13
- Endometrial carcinoma, 236
- Endometriosis, 235
- Endometritis, 235
- Endothelial permeability, edema, 29
- Engulfment, inflammation, 18
- Enteropathic arthritis, 274
- Enzymes, cellular injury, 8
- Eosinophilia, 219
- Eosinophilic granuloma, 229
- Eosinophils, chronic inflammation, 20–22
- Ependymoma, 212
- Epidermal inclusion cyst, 94
- Epidermis, lesions, 91–94
- Epididymitis, 248
- Epidural hematoma, 201–202
- Epidural hemorrhage, 201
- Epilepsy, myoclonic epilepsy, 54
- Epispadias, 247
- Epithelial ovarian tumors, 236–237
- Epitheloid cells, chronic inflammation, 21–22
- Epstein-Barr virus (EBV)
 - liver disease, 189
 - oncogenesis, 76
 - secondary immune deficiency syndromes, 65

Erectile dysfunction, 247
 Erlenmeyer flask deformity, osteopetrosis, 262
 Erythema multiforme, 94
 Erythema nodosum, 94
 Esophageal dysmotility, 61–62
 Esophageal obstruction, lung cancer, 142
 Esophageal varices, 114
 Mallory-Weiss tears *vs.*, 163
 Esophageal webs, 163
 Esophagitis, 163–164
 Esophagus
 carcinoma, 164
 congenital/mechanical disorders, 163
 esophagitis, 163–164
 hematemesis and bleeding, 163
 Essential thrombocytopenia, 227
 Ethyl alcohol, 85
 Etiology, 1
 Ewing sarcoma, 268–269
 Exogenous pigments, cellular injury, 12
 Extracellular matrix, tissue connectivity, 27
 Extramammary Paget disease of the vulva, 233
 Extramedullary hematopoiesis, spleen, 228
 Extravascular (EV) hemolysis, 101
 Extrinsic coagulation pathway, 33
 Exudate fluid, edema, 29
 Exudative inflammation, 22

F

Fabry disease, 49–50
 Factor XII, inflammation mediation, 19
 Familial adenomatous polyposis (FAP), 172
 Familial hypercholesterolemia, 51
 Familial Mediterranean fever, 69
 Fast-twitch muscle, 277
 Fat necrosis
 breast, 241
 cell death, 9
 Fatty change, alcoholic liver, 191
 Fatty streak, atherosclerosis, 111–112
 Felty syndrome, 273
 Female genital tract, tumors, 234–235
 Female pseudohermaphroditism, 46–47
 Fenfluramine, pulmonary hypertension, 139
 Ferritin, iron deficiency anemia, 99–100
 Fibrillary astrocytomas, 211
 Fibrillin gene, Marfan syndrome, 51
 Fibrinoid necrosis, cell death, 9–10
 Fibroadenoma, breast, 242
 Fibroblast growth factor 3, achondroplasia, 261
 Fibrocystic breast changes, 241–242
 Fibroids, uterine, 236
 Fibroma, ovarian, 237
 Fibromatosis, 281
 Fibrosarcoma, 281
 Fibrosis, tissue remodeling, 25
 Fibrous dysplasia, 266
 Fitz-Hugh-Curtis syndrome, 234
 Focal segmental glomerulosclerosis, 152–153
 Folate deficiency, megaloblastic anemia, 105
 Follicular carcinoma, thyroid, 255
 Follicular cervicitis, 235

Follicular lymphoma, 222
 Fragile X syndrome, 53
 Frameshift mutations, Mendelian disorders, 47
 Fraternal twins, 239
 Freckles, 90
 Free radicals, protective agents, 7
 Free rerythrocyte protoporphyrin (FEP), iron deficiency anemia, 99–100
 French-American-British (FAB) acute myelogenous leukemia, 226
 Friction rub auscultation, ischemic heart disease, 121
 Friedreich ataxia, 209
 Fundic type (type A) chronic gastritis, 166
 Fungal meningoencephalitis, 198

G

Gallbladder, cancer, 184
 Gallstones, 182
 Gangrenous necrosis, cell death, 10
 Gardner syndrome, 172
 Gartner duct cyst, 234
 Gastric carcinoma, 167
 Gastric ulcers
 peptic ulcers, 167
 stress ulcers, 165
 Gastrinoma, 180
 Gastritis
 chronic, 166
 hemorrhagic acute, 165
 Gastroesophageal reflux disease, 163–164
 Gaucher disease, 49–50
 Gender, cancer morbidity and mortality, 74–75
 Genes, apoptosis, 10
 Genetic disorders
 Alzheimer disease, 208
 autosomal dominant, 51–53
 autosomal recessive, 48–50
 chromosomal deletions, 45
 extra autosome, 43–44
 genomic imprinting, 54
 hermaphroditism, 46–47
 Mendelian disorders, 47
 mitochondrial DNA, 54
 multifactorial inheritance, 54
 sex chromosomes, 45–46
 triplet repeat mutations, 53–54
 X-linked dominant/recessive conditions, 53
 Genetics, thalassemia syndromes, 100
 Genitourinary tract, anomalies, 45
 Genomic imprinting, 54
 Geography, cancer predisposition and, 75
 Germ cell tumors
 ovarian, 237
 testicular, 248–250
 Germinal matrix hemorrhage, 205
 Gestational trophoblastic disease, 238–239
 Giant cell tumors, bone, 267
 Gilbert syndrome, 187
 Glandularis, bladder, 159
 Glanzmann thrombasthenia, 30–31
 Glioblastoma multiforme, 210–211
 Global cerebral ischemia, 200
 Glomerular disease, 149

- Glomerulonephritis
 acute poststreptococcal, 150
 chronic, 153–154
 secondary, 153
 Glomerulopathies, primary
 nephritic, 150–152
 nephrotic, 152–153
 Glomus tumors, 115
 Glucagonoma, 180
 Glucose-6-phosphatase deficiency, von Gierke disease, 49
 Glucose-6-phosphate dehydrogenase deficiency (G6PD), 103
 Glutathione peroxidase
 cellular injury, 7
 sickle cell disease, 103
 Glycogen storage disease, 12–13
 classification, 49
 Glycolysis, cellular injury, 8
 Glycosaminoglycans, edema, 29
 Glycosylated hemoglobin (HbA1c), hyperglycemia, 177
 Goiter
 endemic, 254
 multinodular, 253
 Goodpasture syndrome, 150
 Gout, 274
 GPIIb-IIIa, bleeding disorders and, 30–34
 Graft arteriosclerosis, 63
 Graft *versus* host disease, apoptosis, 11
 Granuloma, chronic inflammation, 21
 Granuloma annulare, 94
 Granulomatous inflammation, 22. *See also* Chronic granulomatous disease
 Granulosa cell tumor, 237
 Graves disease, 253
 Great vessels, transposition of, 125–126
 Grey hepatization pneumonia, 131
 Gross examination, defined, 1
 Growth factors, apoptosis, 10
 Growth hormone-producing adenoma, 256
 Guillain-Barré syndrome, 281
 Gynecomastia, 244
- H**
- Hageman factor, acute inflammation, 19
 Hairy cell leukemia, 222
 Hairy leukoplakia, secondary immune deficiency syndromes, 65
 Hallucinogens, 85
 Hand-Schüller-Christian disease, 229
 Hashimoto thyroiditis, 254
 Heart disease
 carcinoid, 128
 cardiac tumors, 128
 congenital, 124–127
 congestive heart failure, 122
 ischemic, 119–121
 primary cardiomyopathies, 127–128
 smoking and, 84
 valvular, 122–123
 Heberden nodes, osteoarthritis, 271–272
 Heinz bodies
 glucose-6-phosphate dehydrogenase (G6PD) deficiency, 103
 red blood cells, 97
Helicobacter pylori
 chronic gastritis, 166
 gastric ulcers, 165–167
 Helper T cells, acute inflammation, 15
 Hemachromatosis, 192
 Hemangioblastomas, 115
 Hemangiomas, 115
 liver, 194
 Hematemesis, 163
 Hematoxylin and eosin (H&E) stain, 1–2
 Hematuria, 149
 Heme synthesis, lead poisoning, 83
 Hemodialysis-associated amyloidosis, 69
 Hemodynamics
 acute inflammation, 15–16
 liver diseases, 193
 Hemoglobin
 composition, 100
 electrophoresis, 102
 Hemoglobin C disease, 103
 Hemoglobin H disease, 100
 α -Hemolytic disease, *Viridans streptococci*, 123
 Hemolytic anemias, 101–102
 Hemolytic uremic syndrome (HUS), 31–33
 Hemophilia A, 34
 Hemophilia B, 34
 Hemorrhagic gastritis, acute, 165
 Hemorrhagic infarcts, 38
 Hemorrhoids, 114, 170
 Hemosiderin, 2
 cellular injury, 13
 Hemostasis, 29
 Henoch-Schönlein purpura, 151
 Hepatic adenoma, 194
 Hepatitis
 alcoholic, 191
 transaminases, 8
 viral, 189–190
 Hepatitis A virus, 189–190
 Hepatitis B antigen, polyarteritis nodosa, 109
 Hepatitis B virus, 76, 189–190
 Hepatitis C virus, 189–190
 Hepatocellular carcinoma (HCC), 194
 Hereditary elliptocytosis, 104
 Hereditary hyperbilirubinemias, 187–188
 Hereditary nonpolyposis colorectal cancer, 76
 Hereditary spherocytosis, 103
 Hereditary nonpolyposis colorectal cancer (HNPCC), 172
 Hermaphroditism, 46–47
 Hernia
 congenital diaphragmatic hernia, 164–165
 incarcerated, 168
 Heroin, abuse of, 85
 Herpes viruses, liver disease, 189
 Hirschsprung disease, 168
 Histamine, acute inflammation, 19
 Histiocytosis X, 95
 Histochemical stains, 2
 Histologic cancer diagnosis, 78–79
 HMG-CoA reductase, familial hypercholesterolemia, 51
 Hodgkin lymphoma, 225
 Hormones
 apoptosis, 10
 bone structure, 261

Horner syndrome, 142
 Horseshoe kidney, 147
 Howell-Jolly bodies, red blood cells, 97
 Human herpes virus 8 (HHV8), secondary immune deficiency syndromes, 65, 76
 Human immunodeficiency virus (HIV), 63–65
 encephalitides, 198
 Human papilloma virus (HPV)
 oncogenesis, 76
 penile cancer, 247
 Human T-cell leukemia virus (HTLV-1), 76
 Huntington disease, 53–54, 207
 Hyaline change, cellular injury, 13
 Hyaline membrane disease, 138–139
 Hydatidiform mole, 238–239
 Hydrocele, 248
 Hydrocephalus, 257
 Hydronephrosis, 158
 Hydrops fetalis, 100
 Hydrops of the gallbladder, 182
 Hydrostatic pressure, edema, 29
 Hyperaldosteronism, primary, 258
 Hyperemia, edema, 29
 Hyperlipidemia, glomerular disease, 140
 Hyperparathyroidism, primary/secondary, 255
 Hyperplasia, cellular injury, 11–12
 Hypersegmented neutrophils, acute inflammation, 16
 Hypersensitivity reactions, 59–60
 Hypertension (HTN), 112–113
 glomerular disease, 149
 Hyperthyroidism, 253
 Hypertrophic cardiomyopathy, 128
 Hypertrophic gastropathy, 165
 Hypertrophic osteoarthropathy, 266
 Hypertrophic pulmonary osteoarthropathy, 143
 Hypertrophy
 cellular injury, 11–12
 scarring, wound healing aberrations, 26
 Hypervitaminosis, 5
 Hyphae, secondary immune deficiency syndromes, 65
 Hypoalbuminemia
 edema, 29
 glomerular disease, 149
 Hypocalcemia, hypoparathyroidism, 255
 Hypogammaglobulinemia, 62
 Hypoparathyroidism, 255
 Hypopituitarism, 257
 Hypoplasia, kidney, 147
 Hypospadias, 247
 Hypothalamus, 256–257
 Hypothyroidism, 253–254
 Hypovolemic shock, 38
 Hypoxia, cellular injury, 5, 7

I

Iatrogenic hypothyroidism, 253
 Ichthyosis vulgaris, 93
 Identical twins, 239
 Immune complex (type III) hypersensitivity reaction, 59–60
 Immune deficiency syndromes
 primary, 62–63
 secondary, 63–65

Immune response
 carcinogens, 76
 cellular injury, 5
 Immune thrombocytopenia purpura (ITP), 31–32
 Immunofluorescence microscopy (IFM), 2
 Immunoglobulin A (IgA), 151
 Immunoglobulin G (IgG)
 inflammation, 18
 myeloma, 223
 Immunohistochemical stains, 2
 cancer diagnosis, 79
 Immunosuppression, absence of inflammation, 22
 Immunosuppressive agents, systemic lupus erythematosus therapy, 61
 Incarcerated hernia, 168
 Industrial toxins, 84
 Infantile polycystic kidney disease, 147–148
 Infarction, 37–38
 cerebral, 200–201
 myocardial, 119–121
 pulmonary embolism, 36–37
 renal, 158
 Infection
 acute meningitis, 197
 cellular injury, 5
 cerebral abscess, 199
 fungal meningoencephalitides, 198
 mycobacterial meningoencephalitis, 197
 prion diseases, 199–200
 pulmonary, 131–133
 secondary immune deficiency syndromes, 63–65
 subacute sclerosing panencephalitis, 199
 tissue responses, 22
 toxoplasmosis, 199
 viral encephalitides, 198
 Infectious arthritis, 275
 Infectious bacterial endocarditis, 123
 Infectious mononucleosis, 210
 Infertility
 female, 234–236
 male, 248
 Infiltrative restrictive pulmonary disease, 138–140
 Inflammation
 acute, 15–20
 chemical mediators, 18–19
 chronic, 19–22
 gallbladder, 182
 in immunosuppressed patients, 22
 neutrophils, 16–18
 outcomes, 20
 stomach, 165
 tissue response, 22
 Inflammatory bowel disease, 168–170
 Inflammatory carcinoma, 243
 Inflammatory myopathies, 277–278
 Inflammatory neuropathy, 281
 Inheritance patterns, Mendelian disorders, 47
 Injuries, 86
 Innate immunity, acute inflammation, 15
 Insulin-dependent diabetes mellitus (IDDM), 177–178
 Insulinoma, 180
 Integrins, acute inflammation, 16–17
 Interleukin-1, inflammation mediation, 20
 Interleukin-6, inflammation mediation, 20

- Intermediate filaments, cancer diagnosis, 80
 Interstitial inflammation, 22
 Intracellular killing, acute inflammation, 18
 Intracerebral (intraparenchymal) hemorrhage, 201
 Intraductal papilloma, 242
 Intramembranous bone, 261
 Intravascular (IV) hemolysis, 101
 Intravenous drug abuse, 85
 Intrinsic coagulation pathway, 33
 Intussusception, 167
 Invasive (infiltrating) ductal carcinoma, 243
 Invasive (infiltrating) lobular carcinoma, 243
 Iron deficiency anemia, 99–100
 Irreversible injury
 cells, 8–9
 shock, 38
 Ischemic acute tubular necrosis, 154–155
 Ischemic bowel disease, 170
 Ischemic cerebrovascular disease, 200–201
 Ischemic heart disease, 119–121
 Islet cell tumors, 180
- J**
 Jaundice, 187–188
 JC virus, progressive multifocal leukoencephalopathy, 198
 Jones criteria, rheumatic fever, 122–123
 Jugular venous distention, congestive heart failure, 122
- K**
 Kallikrein, acute inflammation, 19
 Kaposi sarcoma
 oncogenic viruses, 76
 secondary immune deficiency syndromes, 65–66
 vascular neoplasms, 115–116
 Kartagener syndrome, 137
 Karyolysis, cellular injury, 9
 Karyorrhexis, cellular injury, 9
 Kawasaki disease, 110
 Kayser-Fleisher rings, 209
 Keloid formation, wound healing aberrations, 26
 Keratoacanthoma, 94
 Kidney
 congenital anomalies, 147
 cystic disease, 147–148
 tumors, 155–156
 vascular disorders, 157–158
 Kinins, acute inflammation, 19
 Klinefelter syndrome, 45
 Knudson's "two hit hypothesis," tumor suppressor genes, 77–78
 Koilonychia, iron deficiency anemia, 99–100
 Kwashiorkor, cellular injury, 5
- L**
 Langerhans cell histiocytosis, 95, 228–229
 Large cell carcinoma, lung cancer, 142
 Large intestine. *See* Colon
 Laryngeal nerve, lung cancer involvement, 142
 Laryngeal squamous cell carcinoma, 143
 Lead poisoning, 83
 Leber hereditary optic neuropathy, 54
 Left heart failure, 122
 Left-to-right shunt congenital heart disease, 125–127
 Leiomyomas, 236, 281
 Leiomyosarcoma, 281
 Lentigo, 90
 Lesch-Nyhan syndrome, 53, 274
 Letterer-Siwe disease, 228
 Leukemias
 acute lymphoblastic leukemia, 221
 adult T-cell leukemia/lymphoma, 224
 chronic lymphocytic leukemia, 221–222
 hairy cell leukemia, 222
 Leukocyte adhesion deficiency, 17
 Leukocyte alkaline phosphatase (LAP), 219
 Leukocytosis, 219
 Leukopenia, 220
 Lewy body dementia, 209
 Leydig cell tumors, 250
 Lichen sclerosis, 233–234
 Lifestyle choices, 84–85
 Lipase, pancreatitis, 8, 11
 Lipiduria, glomerular disease, 140
 Lipofuscin, cellular injury, 13
 Lipoma, 281
 Liposarcoma, 281
 Lipoxygenase pathway, inflammation mediation, 20
 Liquefaction necrosis
 cell death, 9
 infarction, 38
 Liver
 alcoholic disease, 191
 amebic abscesses, 190
 cirrhosis, 188
 coagulopathies, 34
 hemodynamic diseases, 193
 inflammation mediators, 19
 jaundice, 187–188
 metabolic disease, 191–193
 polycystic kidney disease, 147–148
 tumors, 194
 viral hepatitis, 189–190
 Lobar pneumonia, 131
 Lobular carcinoma *in situ*, 243
 Localized scleroderma, 61
 Long-acting thyroid stimulator (LATS), 253
 Lung abscess, 132
 Lung cancer, 141–143
 smoking and, 84
 Lung disease. *See* Pulmonary disease
 Lyme disease, 275
 Lymphadenitis, 220
 Lymphadenopathy, 220–221
 Lymphatic obstruction, edema, 29
 Lymphedema, 29
 Lymph node, anatomy, 220
 Lymphoblastic lymphoma, 221
 Lymphoblasts, 221
 Lymphocytes. *See also* B cells; T cells
 chronic inflammation, 20–22
 Lymphoid neoplasms, 221
 Lymphoma
 adult T-cell leukemia/lymphoma, 224

Burkitt lymphoma, 222–223
 diffuse large B-cell lymphoma, 222
 follicular, 222
 Hodgkin, 225
 Hodgkin vs. non-Hodgkin, 224
 human herpesvirus 8 and, 65
 lymphoblastic, 221
 lymphoplasmacytic, 223–224
 mantle cell lymphoma, 223
 marginal zone lymphoma, 223
 peripheral T cell, 224
 small lymphocytic lymphoma, 221–222
 testicular, 250
 Lymphoplasmacytic lymphoma, 223–224
 Lyon's hypothesis of X-inactivation, 45
 Lysosomal α -1,4-glucosidase (acid maltase), Pompe disease, 49
 Lysosomal storage diseases, 49–50
 Lysosomes, cellular injury, 8

M

Macrocytic anemias, 104–105
 Macrophages
 acute inflammation, 16
 chronic inflammation, 20–22
 human immunodeficiency virus, 64
 Malabsorption syndromes, small and large intestine, 168–169
 Male pseudohermaphroditism, 47
 Malignant fibrous histiocytoma, 281
 Malignant hypertension, 113
 kidney damage, 158
 Malignant melanoma, 90–91
 Malignant neoplasms
 bone, 268–269
 breast, 243–244
 Mallory-Weiss syndrome, 163
 MALTomas, 223
 Mantle cell lymphoma, 223
 Marantic endocarditis, 123
 Marasmus, cellular injury, 5
 Marble bone disease, 262
 Marfan syndrome, 51
 Marginal zone lymphoma, 223
 Marijuana, 85
 Mast cells
 chronic inflammation, 21–22
 diseases, 229
 Mastitis, 241
 McArdle syndrome, 49
 Mean corpuscular hemoglobin (MCH), anemia, 97
 Mean corpuscular hemoglobin concentration (MCHC), anemia, 97
 Mean corpuscular volume (MCV), anemia, 97
 Meckel diverticulum, 171
 Medullary carcinoma
 breast, 243
 thyroid, 255
 Medullary sponge kidney disease, 148
 Medulloblastoma, 213
 Megacolon
 acquired, 168
 Chagas disease, 163
 Megaesophagus, Chagas disease, 163

Megaloblastic anemias, 104–105
 Meissner plexus, 168
 Melanin, cellular injury, 13
 Melanocytic tumors, 90–91
 Melanoma
 malignant, 90–91
 vulva, 233
 Melanosis coli, 171
 Melasma, 90
 Membranoproliferative glomerulonephritis (MPGN), 151–152
 Membranous glomerulonephritis, 152–153
 Mendelian disorders, 47
 Ménétrier disease, 165
 Meningiomas, 210, 212
 Meningitis, acute, 197
 Meningocele, 204
 Meningoencephalitis
 fungal, 198
 mycobacterial, 197
 Meningomyelocele, 204
 Menkes disease, 51
 Mental retardation, microdeletions, 45
 Mercury poisoning, 84
 Mesothelioma. *See* Asbestosis
 Metabolic liver disease, 191–192
 Metachromatic leukodystrophy, 49–50
 Metaplasia, cellular injury, 11–12
 Metastasis
 to bone, 269
 central nervous system tumors, 211
 defined, 80–81
 liver cancer, 194
 lung cancer, 142–143
 ovarian tumors, 237–238
 prostate cancer, 251
 testicular cancer, 248–250
 Metastatic calcification, cellular injury, 13
 Methyl alcohol, 85
 Microaneurysm, 114
 Microcytic anemia
 classification, 99–101
 lead poisoning, 83
 Microdeletions, genetic disorders, 45
 Microscopic examination, 1
 Migration, acute inflammation, 17
 Mitochondria, cellular injury, 8
 Mitochondrial DNA, disorders, 54
 Mitral valve prolapse, 122
 Mixed connective tissue disease, 62
 Mixed germ-cell tumors, 250
 Molecular techniques, 2
 Mönckeberg medial calcific sclerosis, 111
 Monoclonal gammopathy of undetermined significance, 223
 Monocytosis, 219–220
 Morbidity and mortality, cancer, 73–75
 Morphology, 1
 apoptosis, 10–11
 Mosaicism, 43, 45
 Mucinous (colloid) carcinoma, 243
 Mucocele, gallbladder, 182
 Mucopolysaccharidosis, 49–50
 Multicystic encephalopathy, 205
 Multifactorial inheritance, 54

Multinodular goiter, 253
 Multinucleated giant cells, chronic inflammation, 21–22
 Multiple endocrine neoplasia (MEN) syndromes, 258
 Multiple myeloma, 223
 Multiple sclerosis, 205–206
 Murphy's sign, gallstones, 182
 Muscle glycogen phosphorylase, McArdle syndrome, 49
 Muscular dystrophy, 279–280
 Mushroom poisoning, 83
 Myasthenia gravis, 278
 Myasthenic syndromes, 278–279
 Mycobacterial meningoencephalitis, 197
 Mycosis fungoides, 224
 Myelin figures, cellular injury, 8
 Myelocoele, 204
 Myelodysplastic syndromes (MDS), 226
 Myelofibrosis (MF), 227–228
 Myeloid neoplasms, 226–228
 Myeloma, multiple, 223
 Myeloperoxidase deficiency, 18
 Myeloproliferative syndromes (MPS), 226–228
 Myocardial infarction, 119–121
 Myocardial injury, 8
 Myoclonic epilepsy, 54
 Myopathies, inflammatory, 277–278
 Myxoma, cardiac, 128

N

Na⁺A⁺ ATPase membrane pumps, cellular injury, 8
 Natural killer cell, peripheral neoplasms, 224
 Necrosis, cell death, 9–11
 Necrotizing inflammation, 22
 Neoplasms
 benign vs. malignant, 79
 of bone
 benign, 266–267
 malignant, 268–269
 breast, 242–244
 cancer diagnosis, 79–81
 carcinogenic agents, 75–76
 carcinogenesis, 76
 cardiac tumors, 128
 central nervous system, 210–213
 colon, 172–174
 defined, 73
 epidemiology, 73–75
 esophagus, 164
 female genital tract, 234–238
 gastric carcinoma, 167
 kidney tumors, 155–156
 life style choices, 84–85
 liver tumors, 194
 lymphadenopathy, 221
 lymphoid, 221
 myeloid, 226–228
 oncogenes, 76–77
 ovarian, 237–238
 pancreatic tumors, 180
 peripheral B cell neoplasms, 221–224
 peripheral T cells and natural killer cells, 224
 precursor B- and T-cell neoplasms, 221
 pulmonary, 141–143

soft tissue, 281
 thyroid, 254–255
 tumor suppressor genes, 77–78
 urinary bladder, 158–159
 Nephritic primary glomerulopathies, 150–152
 Nephritic syndrome, 149
 Nephropathy, diabetic, 178–179
 Nephrotic primary glomerulopathies, 152–153
 Nephrotic syndrome, 149
 connective tissue, 27
 Nephrotoxic acute tubular necrosis, 154
 Neural tube defects, 204–205
 Neuritic plaques, Alzheimer disease, 208
 Neurodegenerative disorders, 206–210
 Neuroectodermal tumors, 213
 Neurofibrillary tangles, Alzheimer disease, 208
 Neurofibromatosis type 1 and 2, 52–53
 Neuromuscular transmission, 278
 Neuropathic arthropathy, 275
 Neuropathy
 diabetic, 179
 inflammatory, 281
 Neutrophils
 acute inflammation, 15–18
 leukocytosis (neutrophilia), 219
 Nevi, 90
 Nevocellular nevus, 90
 Newborn, physiologic jaundice of, 187
 Niemann-Pick disease, 49–50
 Nitroblue tetrazolium, acute inflammation, 18
 Nodular glomerulosclerosis, 153
 diabetes, 179
 Nodular sclerosis, 225
 Nonalcoholic fatty liver disease, 193
 Non-Hodgkin lymphoma, 66
 testicular, 250
 Non-insulin-dependent diabetes mellitus (NIDDM), 178
 Nonseminomatous germ-cell tumors, 249–250
 Normocytic anemias, 101–104
 Nutritional imbalance, cellular injury, 5

O

Oat cell carcinoma, lung cancer, 142
 Obesity, 5
 Obstruction/resorption atelectasis, 131
 Obstructive pulmonary disease, 134–138
 Occupational health
 cancer predisposition, 75
 pneumoconiosis, 139
 Oligodendroglioma, 212
 Oligouria, glomerular disease, 149
 Oncogenes, carcinogenesis, 76–77
 Oncogenic viruses, cancer risk, 76
 Opportunistic infection, secondary immune deficiency syndromes, 65
 Opsonins, inflammation, 18
 Optochin resistance, *Viridans streptococci*, 123
 Orchitis, 248
 Organs
 sarcoidosis, 134
 systemic lupus erythematosus effects, 60–61

tissue repair, 26
 tuberculosis dissemination, 133
 Orthopnea, congestive heart failure, 122
 Osgood-Schlatter disease, 266
 Osler-Weber-Rendu syndrome, 171
 Osmotic fragility test, hemolytic anemia, 103
 Osteoclastoma, 267
 Osteitis deformans, 263
 Osteitis fibrosa cystica, 266
 Osteoarthritis, 271–272
 Osteoblastoma, 266
 Osteoblasts, 261
 Osteocalcin, 261
 Osteochondroma, 266–267
 Osteoclasts, 261
 Osteocytes, 261
 Osteogenesis imperfecta, 27, 261–262
 Osteoid osteoma, 266
 Osteoma, 266
 Osteomalacia, 264
 Osteomyelitis, 264–265
 Osteopetrosis, 262
 Osteoporosis, 263–264
 Osteosarcoma, 268
 Ovaries, pathology, 236–237
 Oxygen-dependent/oxygen-independent killing, acute inflammation, 18

P

Paget disease
 of bone, 263
 extramammary disease of the vulva, 233
 of nipple, 244–245
 Pain, mediators, 18
 Pancreatic tumors, 180
 Pancreatitis
 acute, 177
 amylase/lipase, 8
 chronic, 177
 Panhypopituitarism, 257
 Papillary carcinoma, thyroid, 254–255
 Papillary hidradenoma, 233
 Papovavirus, 233
 Pappenheimer bodies, red blood cells, 97
 Paradoxical emboli, 37, 126
 Paraneoplastic syndromes, pulmonary, 142–143
 Parathyroid glands, 255
 Parkinson disease and syndrome, 206–207
 Paroxysmal nocturnal hemoglobinuria, 104
 Partial thromboplastin time (PTT)
 liver disease, 188
 Parvovirus, hemolytic anemias, 101–102
 Patau syndrome, 44
 Patchy atelectasis, 131
 Patent ductus arteriosus (PDA), 126–127
 Pathogenesis, 1
 Pathology
 definitions, 1
 methods, 1–3
 Peau d’Orange skin, breast cancer, 244
 Pelvic inflammatory disease, 234–235
 Pemphigus, 92
 Penis, pathology, 247
 Peptic ulcers, 166–167
 Peptidoglycans, connective tissue, 27
 Perinatal brain injury, 205
 Peripheral B cell neoplasms, 221–224
 Peripheral T cell neoplasms, 224
 Periventricular leukomalacia, 205
 Peutz-Jeghers syndrome, 172–173
 Peyronie disease, 247
 Phagocytosis, acute inflammation, 18
 Phenetermine, 139
 Phenylalanine, cystic fibrosis deletion, 48
 Phenylalanine hydroxylase, phenylketonuria, 48–49
 Phenylketonuria (PKU), 48–49
 Pheochromocytoma, 258
 Philadelphia chromosome, chronic myelogenous leukemia, 226–227
 Phleboscrosis, 85
 Phleothrombosis, 114
 Phyllodes tumor, breast, 242
 Pica, iron deficiency anemia, 99–100
 Pigmentation disorders, 89–90
 Pigmented bilirubinate, 182
 Pigments, cellular injury, 12–13
 Pilocytic astrocytomas, 211
 Pineal gland, 256–257
 Pituitary gland, 256–257
 Pityriasis rosea, 94
 Placental disorders, 238–239
 Plasmacytoma, 223
 Plasma-membrane blebs, cellular injury, 8
 Plasma proteins, inflammation, 18
 Platelet adhesion, 30–31
 Platelet aggregation, 30–31
 Platelet alpha granules, 30
 Platelet disorders, 30–34
 Pleural cavity disease, 143
 Pleural effusion, 143
 Plummer-Vinson syndrome, iron deficiency anemia, 99–100
 Pneumoconioses, occupational-associated, 139
 Pneumocytes, lung injury repair, 138
 Pneumonia, 131–133
 Pneumothorax, 143
 Podocytes, glomerular disease, 140
 Poikilocytosis, 97
 Point mutation, Mendelian disorders, 47
 Poisoning, 83–84
 Polyarteritis nodosa (PAN), 109
 Polycystic kidney disease, 147–148
 Polycystic ovary disease, 236
 Polycythemia vera, 105, 227
 Polymorphous light eruption (skin), 93
 Polymyositis, 61–62, 277
 Pompe disease, 49
 “Porcelain gallbladder,” 184
 Pores of Kohn, 131
 Porphyria, acute intermittent, 210
 Portwine stains, 115
 Postductal coarctation of aorta, 124
 PPD test, chronic inflammation, 21–22
 Prader-Willi syndrome, 54
 Precocious puberty, 257
 Preductal coarctation of aorta, 124
 Preneoplastic disorders, cancer predisposition, 75

- Presenilin-1 gene, Alzheimer disease, 208
 Priapism, 247
 Primary amyloidosis, 69
 Primary biliary cirrhosis, 188
 Primary cardiomyopathies, 127–128
 Primary glomerulopathies, nephritic, 150–152
 Primary hyperaldosteronism, 258
 Primary hyperparathyroidism, 255
 Primary sclerosing cholangitis, 188
 Primary testicular dysfunction, 248
 Primary union, tissue regeneration, 25
 Primitive neuroectodermal tumors, 213
 Prinzmetal variant angina, 119
 Prion diseases, 199–200
 Progressive multifocal leukoencephalopathy, 198
 Prolactinomas, 256
 Prostacyclin, inflammation mediation, 20
 Prostaglandin E2
 inflammation mediation, 20
 patent ductus arteriosus, 126
 Prostaglandins, inflammation mediation, 20
 Prostate pathology, 250–251
 Prostatitis, 251
 Protein synthesis, cellular injury, 8
 Proteinuria, 27
 glomerular disease, 149
 Prothrombin time (PT)
 bleeding disorders, 32–34
 liver disease, 188
 Prussian blue stain, 2
 Pseudogout, 274
 Pseudomembranous colitis, 171
 Psoriasis, 91–92
 Pulmonary disease
 edema, 140–141
 infiltrative restrictive, 138–140
 neoplasia, 141–143
 obstructive, 134–138
 restrictive, 134–135
 vascular disorders, 140–141
 Pulmonary embolism, 36–37, 141
 Pulmonary hypertension, 139, 141
 congestive heart failure, 122
 Pulmonary infarction, 37–38
 Pulmonary infections, 131–133
 Pulmonary tuberculosis, 133
 Pyelonephritis, acute/chronic, 154
 Pyknosis, cellular injury, 9
 Pyloric stenosis, 164
 Pyogenic osteomyelitis, 264–265
 Pyruvate kinase deficiency, 104
- R**
- Race
 cancer predisposition, 75
 sickle cell disease, 103
 Radiation
 cancer risk and, 76
 injury, 86
 Rapidly progressive glomerulonephritis (RPGN), 150–151
 Raynaud phenomenon, 61–62
 Reactive systemic amyloidosis, 69
 REAL lymphoma classification, 221
 Red blood cells
 anemias, 97–105
 jaundice, 187
 macrocytic anemias, 104–105
 microcytic anemias, 99–101
 morphology, 97
 normocytic anemias, 101–104
 polycythemia vera, 105
 Red cell distribution width (RDW), anemia, 97
 Red hepatization pneumonia, 131
 Reed-Sternberg cells, Hodgkin lymphoma, 225
 Reiter syndrome, 274
 Relative polycythemia vera, 105
 Renal agenesis, 147
 Renal artery stenosis, 157
 Renal calculi, 155
 ureteral disorders, 158
 Renal cell carcinoma (RCC), 155–156
 Renal dysplasia, 148
 Renal failure, chronic, 157
 Renal infarction, 158
 Renal transplantation, secondary immune deficiency syndromes, 63
 Resolution pneumonia, 131
 Respiratory distress syndrome of the newborn, 138–139
 Restrictive cardiomyopathy, 128
 Restrictive pulmonary disease, 134–135
 Reticulocytes, anemia, 97–98
 Retinoblastoma, 213
 microdeletions, 45
 Retinopathy, diabetic, 179
 Retroperitoneal fibrosis, 158
 Reversible cell injury, 8
 Reye syndrome, 192–193
 Reynaud disease/phenomenon, 111
 Rhabdomyoma
 cardiac, 128
 soft tissue, 281
 vaginal, 234
 Rhabdomyosarcoma, embryonal, 234
 Rhabdoviruses, 198
 Rheumatic fever, 122–123
 Rheumatoid arthritis, 272–273
 osteoarthritis vs., 271
 Rickets, 264
 Riedel thyroiditis, 254
 Right heart failure, 122
 Right-to-left shunt congenital heart disease, 125–127
 Ring sideroblasts, red blood cells, 97
 Robertsonian translocation, 43–44
 Rocky Mountain spotted fever, 275
 Rokitansky-Kuster-Hauser syndrome, 234
 Romãña's sign, 163
 Rotor syndrome, 188
 Rouleaux (red blood cells), 97
 Rule of 2s, Meckel diverticulum, 171
 Rule of 10s, pheochromocytoma, 258
- S**
- Sarcoidosis, 133–134
S. bovis, endocarditis, 123
 Schistocytes (red blood cells), 97

- Schistosomiasis haematobia, bladder histopathology, 159
- Schwannomas, 213
- Sclerodactyly, 61–62
- Scleroderma, 61
- Scurvy, 27
- Seborrheic keratoses, 91
- Secondary hyperparathyroidism, 255
- Secondary polycythemia vera, 105
- Secondary union, tissue regeneration, 25
- Segmental necrotizing vasculitis, 109
- Selectins, acute inflammation, 16–17
- Seminomas, 249–250
- Senile cardiac/systemic amyloidosis, 70
- Senile cerebral amyloidosis. *See* Alzheimer disease
- Septate hyphae, secondary immune deficiency syndromes, 65
- Seronegative spondyloarthropathies, 273–274
- Serotonin
 - acute inflammation, 19
 - carcinoid syndrome, 174
- Serpentine asbestos, 139
- Sertoli cell tumors, 250
- Sertoli-Leydig cell tumor, 237
- Serum alkaline phosphatase, 261
- Serum amyloid A (SAA), 69
- Serum markers
 - apoptosis, 11
 - cancer diagnosis, 80
 - myocardial infarction, 120
- Severe combined immunodeficiency (SCID), 62
- Sex chromosomes, genetic disorders, 45–46
- Sex cord-stromal tumors, 237, 250
- Sézary syndrome, 224
- Sheehan syndrome, 256
- Shock, 38–39
- Sickle cell disease
 - pathophysiology, 102–103
 - red blood cells in, 97
 - renal infarction, 158
- Sideroblastic anemia, 101
- Silent carriers, thalassemia syndromes, 100
- Silicosis, 140
- Sipple syndrome, 258
- Sjögren syndrome, 61
 - rheumatoid arthritis, 273
- Skeletal muscle, 277
- Skin
 - epidermal/dermal lesions, 91–94
 - malignant tumors, 94–95
 - melanocytic tumors, 90–91
 - pigmentation disorders, 89–90
- Slow-twitch muscle, 277
- Small cell carcinoma, lung cancer, 142
- Small intestine
 - angiodysplasia, 170
 - diverticula, 170–171
 - malabsorption syndromes, 168–169
 - mechanical obstruction, 167–168
 - neoplasia, 171–174
- Small lymphocytic lymphoma (SLL), 221–222
- Small noncleaved lymphoma, 222–223
- Smoking
 - cancer risk and, 84
 - lung cancer, 141–143
- Sodium, edema, interstitial increase, 29
- Soft tissue tumors, 281
- Solitary mastocytoma, 229
- Somatostatinoma, 180
- Spermatocoele, 248
- Spherocytes (red blood cells), 97
- Spina bifida occulta, 204
- Spinal cord
 - injury, 204
 - neural tube defects, 204–205
- Spleen
 - disorders, 228–229
 - extramedullary hematopoiesis, 228
- Splenomegaly, 228
- Sprue
 - celiac, 151, 168
 - tropical sprue, 168
- Squamous cell carcinoma, 65
 - esophagus, 164
 - laryngeal, 143
 - lung cancer, 141–142
 - penis, 247
 - scrotal, 250
 - skin, 94
 - vagina, 234
 - vulva, 233
- Stable angina, 119
- Staghorn calculi, 155
- Steatosis, alcoholic liver, 191
- Stein-Leventhal syndrome, 236
- Steroids, systemic lupus erythematosus therapy, 61
- Stomach
 - acute inflammation and stress ulcers, 165
 - chronic gastritis, 166
 - chronic peptic ulcer, 166–167
 - congenital disorders, 164
 - gastric carcinoma, 167
 - hypertrophic gastropathy, 165
- Stone composition
 - cholelithiasis, 182
 - renal calculi, 155
- Streptococcus pneumoniae*, 131
- Stress ulcers, 165
- Stroke, 200
- Struvite stones, renal calculi, 155
- Subacute endocarditis, 123
- Subacute sclerosing panencephalitis, 199
- Subacute thyroiditis, 254
- Subarachnoid hemorrhage, 202
- Subdural hemorrhage, 202
- Subendocardial infarction, 120
- Subfalcine (cingulate gyrus) herniation, 204
- Succenturiate lobes, placenta, 239
- Sudden death
 - cardiac death, 121
 - pulmonary embolism, 37
- Superior vena cava syndrome, lung cancer, 142
- Superoxide dismutase, cellular injury, 7
- Suppurative arthritis, 275
- Syndactyly, 10
- Syndrome of inappropriate ADH secretion (SIADH), 257
- Syphilitic aneurysms, 114

Syringomyelia, 205
 neuropathic arthropathy, 275
 Systemic arterial emboli, 37
 Systemic lupus erythematosus (SLE), 60
 nodular glomerulosclerosis, 153
 Systemic mastocytosis, 229

T

Tabes dorsalis, neuropathic arthropathy, 275
 Takayasu arteritis, 110
 Target cells (red blood cells), 97
 Tay-Sachs disease, 49–50
 T-cell leukemia/lymphoma, 76
 T cells
 peripheral neoplasms, 224
 precursor neoplasms, 221
 T-chronic lymphocytic leukemia, 222
 Teardrop cells (red blood cells), 97
 Telangiectasia, 61–62
 Temporal arteritis, 110
 Teratoma, 249–250
 ovarian, 237
 Testes, pathology, 247–248
 Testicular cancer, 248–250
 Testicular feminization, 53
 Testicular torsion, 248
 Tetralogy of Fallot, 125
 Thalassemia syndromes, 100–101
 Thrombocytopenia, 31–32
 essential, 227
 Thrombophlebitis, 114
 Thrombosis, 35–36
 Thrombotic thrombocytopenia purpura (TTP), 31–32
 Thromboxane A₂
 inflammation mediation, 18
 platelet production, 30
 Thymus, apoptosis, 10
 Thyroid gland, 253
 neoplasia, 254–255
 Thyroiditis, 254
 Thyroid stimulating hormone (TSH), 253
 Thyroid-stimulating immunoglobulin (TSI), 253
 Tissue
 connective components, 27
 infectious disease response, 22
 injury, shock and, 38–39
 regeneration and healing, 25–26
 wound healing aberrations, 26
 Total iron-binding capacity (TIBC), iron deficiency anemia, 99–100
 Toxins, 83–84
 Toxoplasmosis, 199
 Tracheoesophageal fistula, 163
 “Tram tracking,” membranoproliferative glomerulonephritis, 151–152
 Transaminases, hepatitis, 8
 Transferrin, iron deficiency anemia, 99–100
 Transient ischemic attack (TIA), 200
 Transitional cell carcinomas, 157
 ureteral disorders, 158
 Transmural infarction, 120
 Transplant patients, secondary immune deficiency syndromes, 63–65
 Transtentorial (uncal) herniation, 204
 Transudate fluid, edema, 29

Trauma
 cellular injury, 5
 central nervous system, 203–204
 mechanical injury, 86
 Tricuspid atresia, 125–126
 Triglycerides, cellular injury, 9
 Triplet repeat mutations, 53–54
 Tropical sprue, 168–169
 Trousseau sign, hypoparathyroidism, 255
 Trousseau syndrome, 180
 Truncus arteriosus, 125–126
 Tubal (ectopic) pregnancy, 234, 239
 Tuberculosis, 132–133
 Tuberculous osteomyelitis, 265
 Tuberos sclerososis, 128
 Tubular carcinoma, 243
 Tubulointerstitial nephritis, 154
 Tularemia, 275
 Tumor lysis syndrome, 221
 Tumor necrosis factors, inflammation mediation, 20–22
 Tumor suppressor genes, carcinogenesis, 77–78
 Turcot syndrome, 172
 Turner syndrome, 45–46
 Twins
 fraternal, 239
 identical, 239

U

Ulcerative colitis
 acquired megacolon, 168
 classification, 168–170
 Ulcers
 gastric peptic ulcer, 167
 gastric stress ulcers, 165
 peptic, 166–167
 Ulnar deviation, rheumatoid arthritis, 272–273
 Ultraviolet B sunlight, cancer risk and, 76
 Unilateral renal agenesis, 147
 Unstable/crescendo angina, 119
 Urate nephropathy, 155
 Ureteral disorders, 158
 Ureteritis cystica, 158
 Uric acid, gout, 274
 Urinary bladder
 cystitis, 158
 tumors, 158–159
 Urolithiasis, 155
 Urticaria pigmentosum, 229
 Uterus, pathology, 235–236

V

Vagina, pathology, 234
 Valvular heart disease, 122–123
 Varicocele, 247
 Varicose veins, 114
 Vascular disorders
 diabetes mellitus, 178
 kidney, 157–158
 pulmonary, 140–141
 Vascular neoplasms, 115–116

Vascular wall injury, 30
Vasculitis, 109–110
Vas deferens, obstruction, 248
Vasoactive amines, acute inflammation, 18
Venous disease, 114
Ventricular septal defect, 126–127
VIPoma, 180
Viral disease
 apoptosis, 11
 encephalitides, 198
 hepatitis, 189–190
Virchow's triad, thrombosis, 35–36
Viridans streptococci, endocarditis, 123
Viruses, oncogenic, 76
Visual pathology, hypothalamic disorder, 257
Vitamin B₁₂
 deficiency, 210
 megaloblastic anemia, 104–105
Vitamin D, osteomalacia and rickets, 264
Vitamin deficiencies
 cellular injury, 5–6
 vitamin K deficiency, 34
Vitiligo, 89
Volvulus, small and large intestine, 167
Von Gierke disease, 49
Von Hippel-Lindau disease, 53
Von Recklinghausen disease, 52
 of bone, 266
Von Willebrand disease, 32, 34
Vulva, pathology, 233–234

W

Waldenström macroglobulinemia, 223–224
Waterhouse-Friderichsen syndrome, 258
Wegener granulomatosis, 109–110
Weibel-Palade bodies, acute inflammation, 17
Werner syndrome, 258
Wernicke-Korskoff syndrome, 210
Whipple disease, 168
White blood cells, morphological changes, 219–221
Wilms tumor, 156–157
 microdeletions, 45
Wilson's disease, 191–192, 209
Wiskott-Aldrich syndrome, 62
Wound healing, aberrations, 26

X

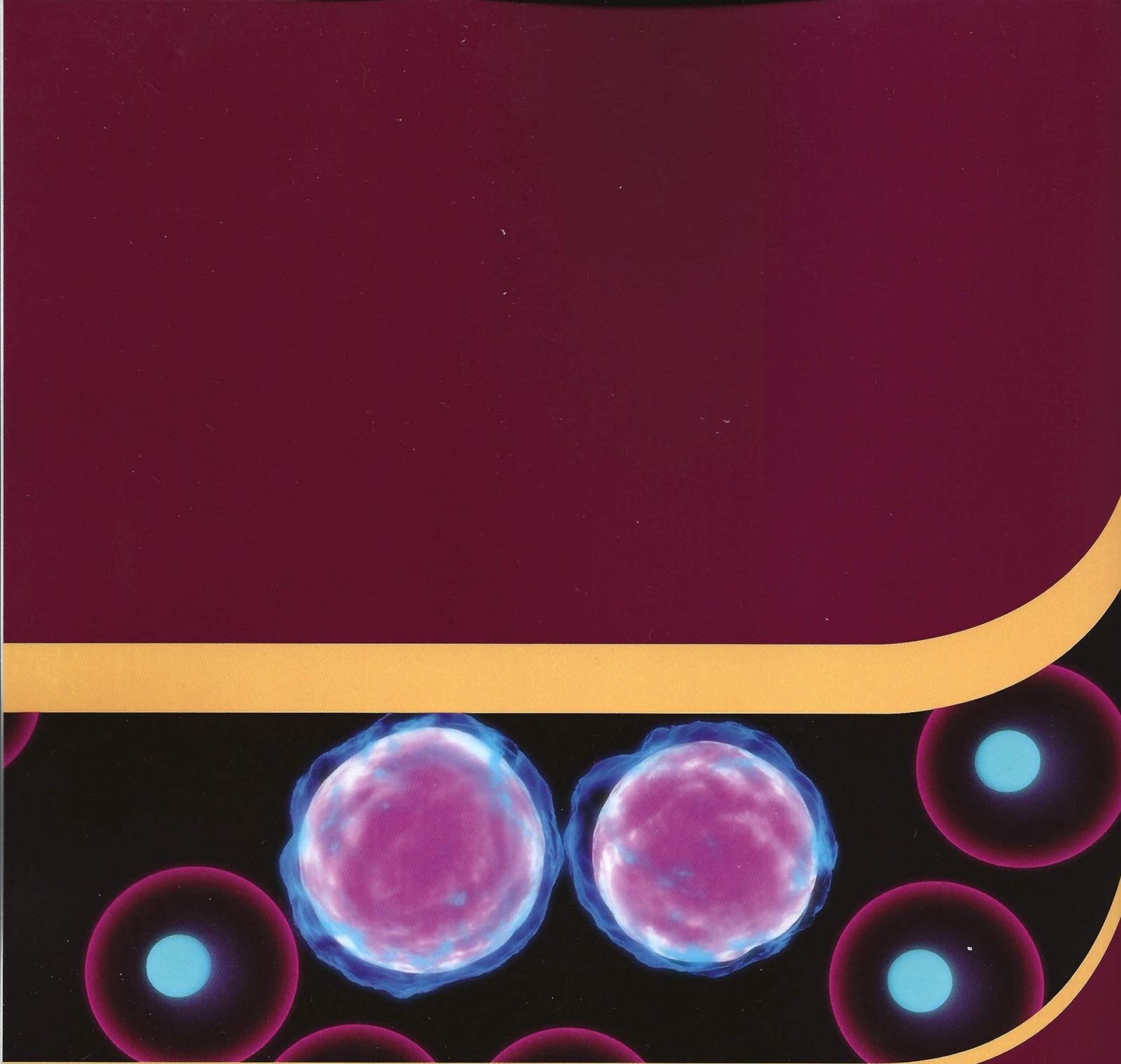
X chromosome, sex chromosome disorders, 45–46
Xeroderma pigmentosum, cancer risk and, 76
Xerosis, 93
X-linked disorders, 53
 Bruton X-linked agammaglobulinemia, 53, 62

Y

Y chromosome, genetic disorders, 45–46
Yellow fever, liver disease, 189
Yolk sac tumor, 249

Z

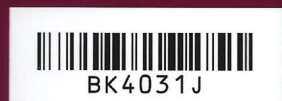Zollinger-Ellison syndrome, 165



KAPLAN

MEDICAL

kaplanmedical.com



Printed in USA